

UNCLASSIFIED

AD NUMBER
AD401301
NEW LIMITATION CHANGE
TO Approved for public release, distribution unlimited
FROM Distribution authorized to U.S. Gov't. agencies and their contractors; Administrative/Operational Use; MAR 1963. Other requests shall be referred to US Army Chemical Biological Radiological Agency, Attn: Pathology Division, Fort Detrick, MD 21701.
AUTHORITY
BDRL, D/A ltr, 27 Sept 1971

THIS PAGE IS UNCLASSIFIED

UNCLASSIFIED

AD_401 301

*Reproduced
by the*

**ARMED SERVICES TECHNICAL INFORMATION AGENCY
ARLINGTON HALL STATION
ARLINGTON 12, VIRGINIA**



UNCLASSIFIED

NOTICE: When government or other drawings, specifications or other data are used for any purpose other than in connection with a definitely related government procurement operation, the U. S. Government thereby incurs no responsibility, nor any obligation whatsoever; and the fact that the Government may have formulated, furnished, or in any way supplied the said drawings, specifications, or other data is not to be regarded by implication or otherwise as in any manner licensing the holder or any other person or corporation, or conveying any rights or permission to manufacture, use or sell any patented invention that may in any way be related thereto.

CATALOGED BY ASTIA
AS AD NO. 401301

TECHNICAL MANUSCRIPT 41

COMPARATIVE PATHOGENESIS
OF CANINE AND SIMIAN
COCCIDIOIDOMYCOSIS

401 301

MARCH 1963

RECEIVED
APR 17 1963
ASTIA A

UNITED STATES ARMY
BIOLOGICAL LABORATORIES
FORT DETRICK

NO OTS

U.S. ARMY CHEMICAL-BIOLOGICAL-RADIOLOGICAL AGENCY
U.S. ARMY BIOLOGICAL LABORATORIES
Fort Detrick, Maryland

The work reported here was conducted under Project 4B11-02-068, "Pathogenesis of BW Aerosol-Induced Infections in Applied Research," Task -03, "Pathogenesis of Biological Agents." The expenditure order was 2073. It is part of a continuing co-operative effort by the Pathology, Medical Bacteriology, and Special Operations Divisions in characterizing the disease coccidioidomycosis. This report was originally submitted as Manuscript 5113.

This report was presented at the Seventh Annual Meeting of the VA-Armed Forces Coccidioidomycosis Study Group, Los Angeles, California, November 1962.

Merida William Castleberry
Edwin Palmer Lowe
James Thomas Sinski
John Lay Converse
John Emil Del Favero
Steven P. Pakes

Pathology Division
DIRECTOR OF MEDICAL RESEARCH

Project 1C022301A07003

March 1963

ABSTRACT

Both man and dog live in the endemic areas of coccidioidomycosis and apparently respond to the disease in a similar manner. Because M. mulatta, used in previous experiments, might have a greater susceptibility to the disease, it was decided to study the aerosol-induced disease in the canine for comparison.

Twenty-five dogs were exposed to aerosols of C. immitis arthrospores. Ten were challenged with an average inhaled dose of 39,000 arthrospores and serially sacrificed over a period of nineteen days. The remaining fifteen dogs were divided into three groups of five each to determine the pathological effect of various doses of aerosol challenge. Each group was challenged with an average inhaled dose of 300, 2000, or 10,000 dry arthrospores of the same strain and sacrificed at 22 weeks post-exposure. The development of the disease was followed by gross and microscopic pathological studies. The results of these studies were then compared with those previously established in the M. mulatta.

The dog was found to be as susceptible to infection as the monkey but was better able to contain the disease. This was manifested by the ability to maintain a blood supply for a longer period of time within the lesion and by a faster and more prolific collagen response to the disease presence. The canine lesion was generally more proliferative and less necrotic than that of the M. mulatta.

The dog's response to challenge was practically the same regardless of dose level.

CONTENTS

Abstract	3
I. INTRODUCTION	5
II. MATERIALS AND METHODS	6
III. RESULTS	7
A. Canine Serial Sacrifices	8
B. Effects of Dose Canines	11
C. Canine Controls	14
D. <u>M. mulatta</u> Response	14
IV. DISCUSSION AND CONCLUSIONS	15
Literature Cited	17

FIGURES

1. Developing Spherule, Third Day, 130X	8
2. Spherule with Endospores, Fourth Day, 130X	8
3. Expanding Fifth-Day Lesion, 130X.	9
4. Gross Appearance of Lungs, Seventh Day	9
5. Lesion Appearance at Seventh Day, 42X	10
6. Gross Appearance of Lungs, Thirteenth Day	10
7. Bosselated Lung Surface, Nineteenth Day	12
8. Coalescing Lesion, Nineteenth Day, 42X.	12
9. Tuberculoid Lesion, Twenty-second Week, 42X	13
10. Pleural Thickening, Twenty-second Week, 42X	13

I. INTRODUCTION

The severity of experimental coccidioidomycosis is related in part to the susceptibility of the laboratory animal used. Previous work in these laboratories indicated that the primate (M. mulatta) might be particularly susceptible to the disease. Extrapolation to man would be of limited value if it were determined that the primate is indeed significantly less resistant.

Man and dog live under similar circumstances in the endemic areas. Any apparent differences in susceptibility might be attributed to dosage factors related to the canine curiosity and smelling instincts. It was believed that by comparing the pathogenesis of the aerosol-induced disease in dogs with that in the M. mulatta, a higher confidence level could be established for extrapolation studies.

In 1896 Rixford and Gilchrist,¹ followed by Posodas² in 1900, hypodermically challenged animals, including dogs, with the disease. The first pulmonic challenge of this animal was made in 1957 when Hugenholtz et al³ inoculated 17 dogs intratracheally with saline suspensions of arthrospores. Their results indicated that the dog might indeed be a more suitable animal than the monkey for the present studies. Maddy has described the canine pulmonic lesion as being more proliferative⁴ and less destructive⁵ than the same lesion in man.

This paper is a report of the studies made to determine the early pathogenesis of the aerosol-induced disease in dogs and to assess the pathologic effects of various challenge levels. These results are then compared with those previously established in the M. mulatta.⁶

II. MATERIALS AND METHODS

Mongrel dogs were used to eliminate the possibility of breed susceptibility. A total of 30 healthy, de-barked, mature dogs of both sexes (males castrated) weighing between 15 and 25 pounds were employed in these studies.*

Ten dogs, designated for serial sacrifice, were subjected to an aerosol cloud of dry arthrospores of the Silveira strain of C. immitis. This was accomplished in the manner described by Blundell et al,⁶ with each dog receiving an average inhaled dose of 39,000 arthrospores. Single sacrifices were made on the third, fourth, and fifth day post-challenge; the remaining seven were sacrificed on alternate days thereafter, up to the nineteenth day post-challenge.

Fifteen other dogs were divided into three groups of five each and were similarly challenged with an average inhaled dose of 300,2000, or 10,000 dry arthrospores of the same strain. Five additional nonchallenged dogs served as environmental controls. The dogs were housed, by dose groups, in temperature-controlled (72° to 75° F) gas-tight cabinet systems.

For comparison with the dogs and to correlate the virulence of the arthrospore with previous studies involving the M. mulatta, 12 monkeys of this species were divided into three groups of four each and challenged with an average aerosol dose of 300, 3000, or 9000 arthrospores. A thirteenth, nonexposed monkey was used as an environmental control.

These monkeys were housed in the same manner as the dogs with the exception that they were individually caged within the gas-tight system. An additional nonexposed M. mulatta was put in the system housing the high-dose group as an environmental control.

The methods of culturing and harvesting the organism and of calculating the inhaled dose were those reported by Blundell et al⁶. Nembutal**, administered intravenously, was used to induce euthanasia in the animals. A detailed necropsy was performed on each animal. All tissues were fixed in 10 per cent buffered formalin, embedded in paraffin, sectioned, and stained by the Giemsa technique.

*The animals used in this study were maintained in compliance with the "Principles of Laboratory Animal Care" as promulgated by the National Society for Medical Research, Bio-medical Purview 1:14, 1961.
**Nembutal (Sodium) Veterinary, Abbott Laboratories, North Chicago, Ill.

III. RESULTS

A. CANINE SERIAL SACRIFICES

No lesions attributable to coccidioidomycosis were seen grossly in the ten sequential sacrifices until the fifth day. However, histological examination of the lungs of the third-day sacrifice revealed small foci of round cells randomly scattered through the terminal portions of the bronchial tree. One such focus contained a developing C. immitis spherule in an alveolar area (Figure 1). Microscopic examination of lung tissue from the fourth-day sacrifice revealed enlarging focal lesions with more polymorphonuclear cells in evidence (Figure 2).

By the fifth day, dark red, pin-point lesions, scattered over the visceral and parietal surfaces of the lungs, were grossly visible. Except for the increased lesion size, the microscope revealed little change from the previous day (Figure 3).

The disease was well established by the seventh day. The lung surfaces were peppered with numerous grey-red to red nodules one to two millimeters in diameter (Figure 4). Microscopic examination revealed spherules in all stages of development surrounded by macrophages and polymorphonuclear leucocytes (Figure 5). This whole process was contained within an alveolar framework that maintained partial identity and blood supply.

The same miliary nodules were scattered evenly throughout all lobes on the ninth day. The lesions were slightly larger than those encountered previously, with beginning coalescence in evidence. Some intra-nodular hemorrhage was noted. The hilar lymph glands were not palpably enlarged, but microscopic examination revealed a mild lymphadenitis surrounding isolated spherules. Except for a slight progressive enlargement of the lesions described previously, no new developments were noted in the eleventh-day sacrifice.

The lungs of the dog sacrificed on the thirteenth day were bosselated and hyperemic (Figure 6). A few fibrinous adhesions were present between the diaphragmatic lobes of the lung and the diaphragm. Microscopic examination revealed a discrete but progressive destruction of pulmonary tissue. However, many of the alveolar walls within the affected areas stubbornly maintained their integrity.

Beginning coalescence of the gross lesions was evident by the fifteenth day. The nodules were slightly larger and had a grey-yellow cast. Microscopic examination revealed additional changes. Small focal eosinophilic areas of purulent inflammation were occasionally seen within the lesions. In addition, a hepatic micro-abscess containing a C. immitis spherule gave evidence of disease dissemination beyond the thoracic cavity.

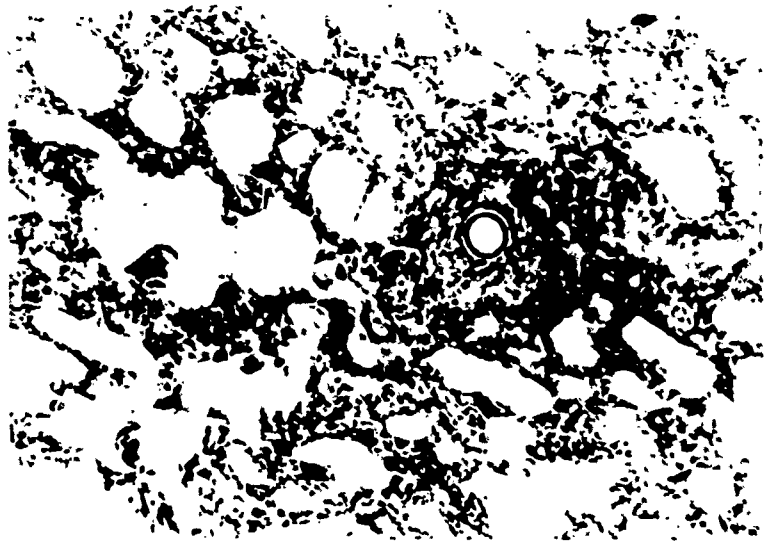


Figure 1. Developing Spherule, Third Day, 130X.
(Path. Div. Neg.)




Figure 2. Spherule with Endospores, Fourth Day, 130X.
(Path. Div. Neg.)




Figure 3. Expanding Fifth-Day Lesion, 130X.
(Path. Div. Neg.)



Figure 4. Gross Appearance of Lungs, Seventh Day.
(Path. Div. Neg.)

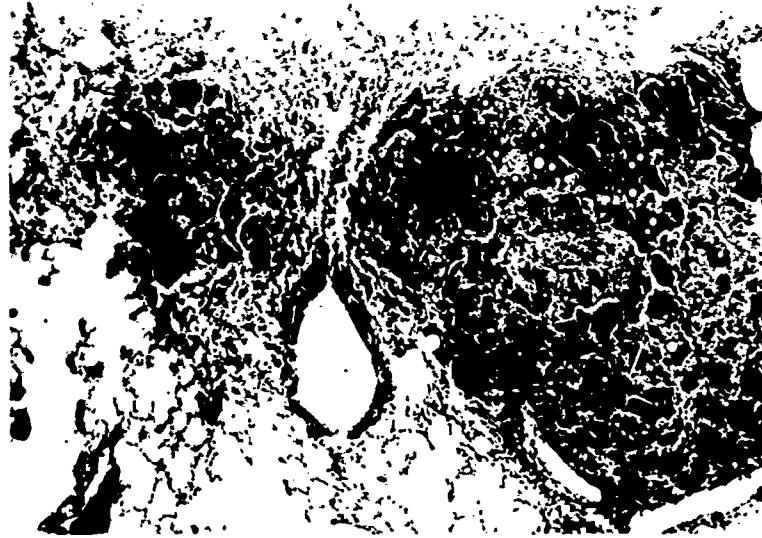


Figure 5. Lesion Appearance at Seventh Day, 42X.
(Path. Div. Neg.)



Figure 6. Gross Appearance of Lungs, Thirteenth Day.
(Path. Div. Neg.)

A progressive enlarging and coalescing of pulmonary lesions characterized the seventeenth- and nineteenth-day sacrifices (Figure 7). Enlarged hilar lymph glands were seen in both of these animals, as were multiple small hepatic coccidioidal granulomas. The only new microscopic finding of interest was the presence of an occasional small Langhans-type giant cell in pulmonary lesions of the nineteenth-day sacrifice. This was the first evidence of giant cell formation. Vascularity of the lesions, although greatly reduced, still remained apparent (Figure 8).

B. EFFECTS OF DOSE ON CANINES

The remaining twenty dogs were sacrificed during the twenty-second week post-challenge. Despite the three dose ranges little, if any, clinical difference was observed among the three groups. Except for a slight inappetence and a mild lethargy noted during the second week among the challenged animals, all dogs except two maintained hearty appetites, were in good flesh, and remained playful throughout the experiment.

At necropsy, the principal gross pathology encountered was in the thoracic cavity. The lungs were characterized by the presence of numerous firm yellow-white nodular lesions that were evenly distributed over the pleural and cut surfaces. These nodules ranged from two-tenths to one centimeter in diameter, were usually discrete, and when cut were firm to cheesy in consistency, although a purulent exudate was occasionally seen.

Small blue areas, up to one centimeter in diameter, were commonly seen on the visceral pleura, usually interspersed between nodules. Although not a prominent finding, thin fibrinous adhesions between the visceral and parietal pleura were noted. The hilar lymph nodes were enlarged.

Microscopic examination of pulmonary lesions indicated a spectrum of small, discrete, noncoalescing granulomas to quite large areas of involvement. The lesions usually contained numerous spherules in various stages of development. Most of these lesions were chronic, with thin fibrous connective tissue collars surrounding them (Figure 9).

Where granulomas were located near the surfaces of the lungs, the pleura was thickened (Figure 10) with depositions of collagenous tissue. This corresponded to the bluish-scarred areas seen at necropsy on the visceral pleura.

In four of the dogs, the disease had disseminated from the thoracic cavity to other body organs. Granulomas containing spherules were noted in the kidneys of three of the dogs and the liver and heart of the fourth. In three additional dogs, granulomas consistent with coccidioidomycosis were noted in body organs other than the lungs, but spherules could not be demonstrated. As noted grossly, most of the dogs had a moderate to severe hilar coccidioidal lymphadenitis.



Figure 7. Bosselated Lung Surface, Nineteenth Day.
(Path. Div. Neg.)



Figure 8. Coalescing Lesion, Nineteenth Day, 42X.
(Path. Div. Neg.)



Figure 9. Tuberculoid Lesion, Twenty-second Week,
42X. (Path. Div. Neg.)



Figure 10. Pleural Thickening, Twenty-second Week,
42X. (Path. Div. Neg.)

One of the two previously mentioned exceptions, a female in good flesh from the 10,000 group, was killed in a fight 84 days after challenge. Her necropsy, however, revealed well-developed focal pulmonary lesions of coccidioidomycosis. The other exception was a male dog in the 2000 group. This dog gradually became very thin and debilitated. During the last weeks of the experiment, he became increasingly reluctant to walk. This dog subsequently proved to have widely disseminated coccidioidomycosis.

C. CANINE CONTROLS

Of the five nonexposed environment control dogs, four were negative for the disease on histopathological examination. The fifth, a high-dose cabinet control dog, however, showed focal pulmonary lesions that contained C. immitis spherules. Exposure was undoubtedly made when this dog sniffed his freshly exposed cabinet mates.

D. M. MULATTA, RESPONSE

The last of the four monkeys in the 9000-arthrospore dose range died 61 days following challenge. The death of these animals was attributed to a confluent, necrotizing, granulomatous coccidioid pneumonia.

No deaths occurred in either the second or third group. At necropsy, however, the lungs of these animals had a bosselated, multicolored appearance. Cut surfaces frequently revealed focal cavitation. The hilar glands were enlarged and frequently necrotic. The micropathology, other than to verify the disease identity, did not differ from that previously reported by Blundell et al.⁶ The disease had disseminated beyond the thoracic cavity in three of these animals. Two others had granulomatous lesions compatible with those of coccidioidomycosis in organs other than the lungs, but no spherules could be found. Microscopic examination of lung tissue of the unexposed environmental control revealed small, focal granulomas containing spherules of C. immitis, indicating secondary aerosol contamination of the housing facilities from the fur of the freshly exposed animals.

IV. DISCUSSION AND CONCLUSIONS

Serial sacrifice revealed a close parallel between mongrel dogs and monkeys (M. mulatta) in both time and pattern of early lesion development. The presence in the dogs of maturing spherules on the third day, a coccidioidal hilar lymphadenitis on the ninth day, and hepatic lesions that contained spherules on the fifteenth day coincided well with the disease pattern in M. mulatta. However, the dog lesions did not tend to spread and coalesce as rapidly as did those in the monkey, nor did they become necrotic as early or as extensively. Pulmonary perilesional edema, characteristic of the early M. mulatta disease, was almost nonexistent in the dog. In addition, the dog apparently was able to maintain at least a partial blood supply to the affected areas for a longer period of time than did the M. mulatta. This, combined with a better ability to contain his lesions by a more vigorous collagenous response, is evidence of, and partially explains, the dog's greater resistance to the disease.

Other variations, relatively minor, were noted between the primate and canine disease. For example, the profuse, purulent, bronchial luminal exudate, which appeared as early as the seventh day post-challenge in the M. mulatta, was rarely seen even in the relatively advanced cases in the dog. In addition, fibrinous and fibrous pleural adhesions, which occurred early and were numerous in all the M. mulatta, were not particularly noteworthy in the canine disease.

Generally speaking, there was little difference in the disease produced among the dog groups, regardless of the challenge dose, whereas all four monkeys died in the high-dose group and massive pulmonary disease was encountered in the lower-dose groups at necropsy.

The following conclusions are drawn from the data presented:

(a) Infectivity of the Silviera strain of C. immitis was 100 per cent for the dog and the M. mulatta in the dose ranges at which they were challenged.

(b) The pathogenesis of experimental respiratory coccidioidomycotic infections in the two species is very similar with respect to location of the lesions and the time of their development.

(c) The histopathological features are generally similar except for the following:

(1) Vascularity of the lesions is maintained for a longer period of time in the dog.

(2) A more pronounced fibroblastic response is elicited in the dog by the presence of the lesion.

(3) The lesion, per se, is more proliferative and less necrotic in the dog than in the M. mulatta.

(d) The dog is more resistant to the effects of coccidioidomycosis than is the M. mulatta.

LITERATURE CITED

1. Rixford, E., and Gilchrist, T.C., "Two Cases of Protozoan (Coccidioidal) Infection of the Skin and other Organs," Johns Hopkins Hosp. Rep. 1, 1896. pp 209-265
2. Posodas, A. "Psorospumiose Infectant Generalise," Rev. Chir. Paris. 20:277-282. 1900.
3. Hugenholtz, P.G.; Reed, R.E.; Maddy, K.T.; Trautman, R.J.; and Barger, J.D. "Experimental Coccidioidomycosis in Dogs," Amer. J. Vet. Res. 19:433-439. 1958.
4. Maddy, K.T. "Disseminated Coccidioidomycosis of the Dog," J. A. Vet. A. 132:483-489. 1958.
5. Maddy, K.T. "A Study of One Hundred Cases of Disseminated Coccidioidomycosis in the Dog," Proc. Sym. on Coccidioidomycosis. U.S. Public Health Service Pub. 575. Dec., 1957. pp 107-118
6. Blundell, G.P.; Castleberry, M.W.; Lowe, E.P.; and Converse, J.L. "The Pathology of Coccidioides immitis in the Macaca mulatta," Amer. J. Path. 39(5) 613-630, 1961.