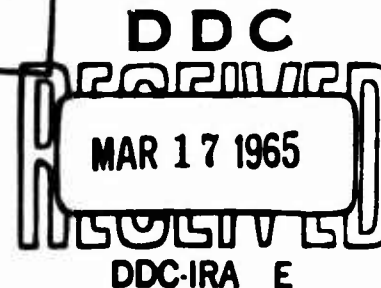


| | | |
|-------------|-----|--|
| COPY | OF | |
| HARD COPY | \$. | |
| INTEROFFICE | \$. | |



AD 612418

Central nervous system effects of laser radiation¹

KENNETH M. EARLE, STIRLING CARPENTER,
UROS ROESSMANN, MARTIN A. ROSS,
J. R. HAYES, AND ELMAR ZEITLER
Armed Forces Institute of Pathology, Washington, D.C.

OUR EXPERIMENTS were designed to determine the effects of focused and unfocused laser radiation upon the heads of animals. This report is the result of our first set of experiments.

While preparing these experiments, Drs. Sam Fine and Edmund Klein told us of their unreported experiments in which they produced subarachnoid hemorrhage and death in mice within a few minutes by directing an unfocused beam from a ruby rod laser onto their heads. They did not do histologic studies at that time. However, unlike the experiments of Fine and Klein, we decided not to shave the heads of most of our animals. This point undoubtedly explains the differences in some of our observations.

Our first set of experiments was designed to repeat those of Fine and Klein and extend them by determining the effect of pulsed laser beams directed in various ways: converging onto the brain through the intact skull, diverging into the brain, converging on the other side of the head, and unfocused.

A good review of the subject of optical masers (lasers) in biology and medicine is found in the articles by Litwin and Glew (1), Malt and Townes (3), and in other presentations in this symposium. Therefore, we will not review the basic theory and current application of lasers, but will confine ourselves to the specific experiments we did and the conclusions reached. The lesions of the skin were studied by Dr. E. B. Helwig, Chief of the Dermatologic Pathology Branch of the Armed Forces Institute of Pathology, and his findings will be the subject of a separate report on the effects of laser radiation on the skin. We shall describe only the gross appearance of the skin lesions here.

EQUIPMENT

A model 3100 laser system (Maser Optics, Inc., 89 Brighton Avenue, Boston 34, Mass.) was used. This system included an optical system with a linear flash

¹This study was supported in part by Research Contract 3A012501A802-01 from the U.S. Army Medical Research and Development Command.

lamp in silvered elliptical cavity. Specifications were as follows:

Laser rod. Ruby (Al_2O_3 -0.04% to 0.05% Cr), 65g x $\frac{3}{8}$ inches. The ends were flat and parallel; they had dielectric coatings on the ends for reflection and partial transmission through one end.

Flash lamp. FX47, 6.5-inch arc length (Edgerton, Germeshausen, and Grier, Inc., Boston, Mass.).

Cooling system. Liquid nitrogen. The cavity was purged with gaseous nitrogen. For some shots, no cooling agent was used; the laser was allowed to cool for 30 min between shots.

Maximum input energy. 10,000 joules at 3 kv.

Pumping pulse. 2.2 milliseconds.

Energy output. 6,943 A, 125 joules nominal.

The laser head was mounted on an optical bench. In most of the experiments a +12-diopter convex lens 2 inches in diameter was used for focusing. The animals were held in specially made tubular plastic cylinders and placed at a distance of 2 m from the end of the laser rod in most of the experiments (Fig. 1). In some experiments the animal was placed 6 inches from the end of the rod, but there was no detectable difference in the response. The distance of the head from the focal point of the beam, however, proved to be very important in damaging the brain.

ANIMALS

The animals used in these experiments were: 14 white Swiss Webster mice, weighing about 40 g each; 9 Long-Evans rats, weighing 150-200 g each (these rats have black hair and pigmented skin over their heads and thorax and white skin and hair elsewhere); and 1 Cebus monkey.

The "Principles of Laboratory Animal Care" promulgated by the National Society for Medical Research were observed during this study.

Measurement of the energy of the laser beam. The energy in the beam was measured by splitting the beam and focusing the reflected portion into the aperture of a TRG model 101 calorimeter with a lens identical to that used to focus the transmitted beam. The thermopile voltages

PROCESSING COPY

ARCHIVE COPY

Copies NOT available
to DDC or Clearinghouse
customers

were measured with a Keithley microvoltmeter. Factory calibration of the calorimeter was performed according to standards of the National Bureau of Standards. As expected, the energy distribution was not uniform across the face of the crystal, and the image size determined photographically was much smaller than that visualized by tungsten light transmitted through the rod and focused in the same optical system. Figure 2 shows a photograph of the emission pattern. The size of the magnified crystal face is outlined. The energy distribution within the area of emission is not even. The pulse train was measured with an E. G. and G. fast-rise photodiode; it was 400 μ sec long during a typical exposure.

EXPERIMENTS AND OBSERVATIONS

Mouse 1

Focus: on head. Shot 1 unfocused, shot 2 focused with convex lens to a 2-mm spot. Lens 20 cm from target. Shots 3 and 5 unfocused, 4 focused (Fig. 3); distance (laser to target): 2 m; input joules: 9,000; output

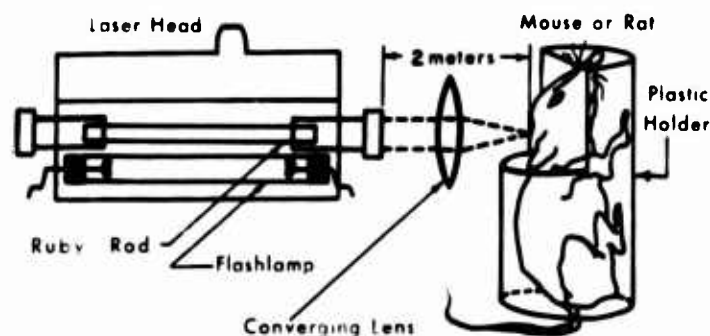


FIG. 1. Arrangement of the laser, lens, and animal.



FIG. 2. Photograph of the image size and shape of the laser beam as seen from the face of the ruby rod. Note that the image is smaller than the round face of the rod and that the shape is irregular, probably due largely to crystal imperfection. $\times 8$.



FIG. 3. Laser beam converging onto scalp produced burned skin but no damage to brain.

FIG. 4. Laser beam converging into brain produced damage to brain parenchyma through intact cranium, provided that it is transmitted. This beam is undoubtedly attenuated by absorption and by scatter.

joules: 30 (estimated), laser head cooled with liquid nitrogen; duration of pulse: 400 μ sec (estimated).

Observations. Shot 1: Unfocused beam. Remainder of clipped hairs burned, but the skin showed no definite burn. The hair and skin of this area were white. Shot 2. Focused on skin. The hair was burned over a 2-mm area where the beam was focused, and the skin was burned brown and crusty but was not perforated. Note: After the first two shots the animal appeared less reactive, but alive. We believed that the white hair and skin were reflecting most of the beam. In order to increase the absorption we blackened the skin of the occiput with India ink. Shot 3. Unfocused. Skin blackened; more hair burned off, but not completely, and we could not observe the skin. Shot 4. Focused on skin. Skin blackened; additional burning of hair, and probably of the skin as well, was observed over the right parietal region where the beam struck. Shot 5. Unfocused. Skin blackened. The animal was alive but poorly responsive before this shot, and we decided to see whether one more shot would be fatal. The animal showed no obvious change as a result of this last shot. The painted skin showed a little additional charring.

Follow-up. After the last shot was delivered the animal appeared stuporous when released and slumped over on one side. When held by the tail he circled in a clockwise motion with the head turned to the right. We suspected that this abnormality indicated some damage to the vestibular system, and we noted that one of the shots was near the base of the right ear. This animal lay on his side, his respirations slowed, and he died approximately 45 min after the last shot and about 75 min after the first shot.

Autopsy. The skin was incised in the midline over the cranium. The subcutaneous tissue showed contusion at the base of the right ear beneath the area of focused shots 2 and 4. The center of this area was blanched and surrounded by a purplish hemorrhagic contusion measuring 7 x 6 mm. No hemorrhage or other signs of injury were found inside of the external auditory meatus. The cranium was intact. The dorsum of the cranium was removed with scissors, and the dura was removed with it. A small amount of subdural hemorrhage was visible over the superior convexities of both hemispheres of the brain. In the right parietal area there was a distinct and slightly elevated round area of subarachnoid and intracerebral

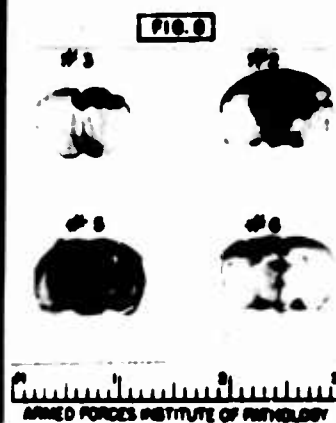
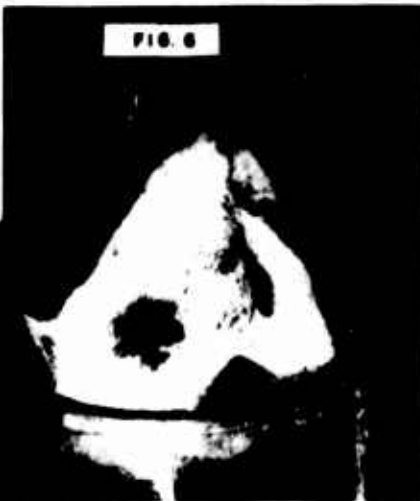
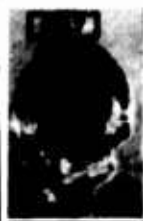
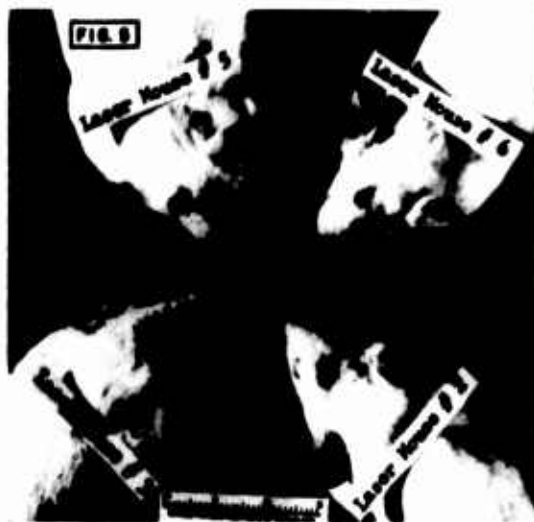FIG. 5. Mice 2, 3, 5, 6 showing the burned areas of the scalp.

FIG. 6. Closer view of mouse 2 showing charring of the scalp at the point where the laser beam struck the head.

FIG. 7. Brain of mouse 2 showing the distribution of subarachnoid hemorrhage. A section of this brain is shown in Fig. 8.

FIG. 8. Brains of the same mice as in Fig. 5 illustrating the distribution of hemorrhage in the brains of these animals.

hemorrhage beneath the area where focused shots 2 and 4 hit the animal. Since the skin was blackened with India ink we could not definitely distinguish between these two shots. This area was well circumscribed and surrounded by a narrow zone of contusion. The intracerebral hemorrhage measured 3 mm in diameter on the surface and extended into the brain for a distance of about 3 mm when it was sectioned.

Comment. This mouse showed signs of injury after shot 2, and he died 45 min after the last shot. The autopsy showed that the beams that were focused produced burning of the skin. The cranium showed no evidence of damage. The subdural hemorrhage, subarachnoid hemorrhage, and the focal intracerebral hemorrhage and contusion of the parietal region of the brain were beneath the area where the focused beams burned the skin, and there is every reason to believe that the focused beams were the ones that produced the damage to the brain. We did not produce brain damage in similar shots to the heads of rats. The focal depth and the thinness of the mouse cranium may be factors that influenced this difference between this mouse and the rats. Also, the head of this mouse was free to move, and the exact focal point at the time of the shot is not certain.

Microscopic observations. Sections showed recent subarachnoid hemorrhage and recent elongated hemorrhages in one parietal region of the cerebral cortex and in the nearby cerebellar cortex. The brain parenchyma stained poorly, and neurones appeared pyknotic for an area of about 1 mm around the slitlike hemorrhages of cortex. The cortical lesions were compatible with recent cortical contusions due to physical trauma.

Mouse 2

Focus: animal positioned so that the focal point of the lens would be within the brain if the scalp and skull did not appreciably alter the focus (Fig. 4); distance (laser to target): 2 m; input joules: 9,000; output joules: 31.4,

laser head cooled with liquid nitrogen; duration of pulse: 400 μ sec.

Observations. Immediately after the shot the mouse appeared dazed and much less active. When released from the holder he could not maintain his posture and tended to slump over on one side. He developed generalized seizures and died 7 min after the shot. His eyes did not appear damaged.

Autopsy. Hair was burned over a circular area of 2.5 cm and skin over an area of 1.5 cm (Figs. 5, 6). In the subcutaneous tissue was seen a blanched central area about 3 mm surrounded by a 1-mm zone of petechial hemorrhage. The calvarium was intact. A small amount of subdural hemorrhage was present, more on the right than the left. In the brain a 7 x 6-mm area of subdural hemorrhage over the medial central part of both hemispheres was seen. Sections showed subarachnoid and intracerebral hemorrhages beneath this area (Figs. 7, 8). The viscera were not remarkable.

Microscopic observations. Sections showed recent subarachnoid hemorrhage over the area described grossly and slitlike intracerebral hemorrhages extending up to 4 mm into the cortex in a direction approximately normal to the surface of the cortex. Transverse, recent slitlike hemorrhages were found in the corpus callosum beneath the area of cortical hemorrhage.

Mouse 3

Focus: animal positioned so that the focal point of the lens would be within the brain if the scalp and skull did not appreciably alter the focus (Fig. 4); distance (laser to target): 2 m; input joules: 9,000; output joules: 28.8, laser head cooled with liquid nitrogen; duration of pulse: 400 μ sec.

Observations. Mouse appeared stunned and immobile immediately after the shot. When removed from the holder he was able to stand, and he reacted sluggishly to movement. 54 min postradiation (p.r.): Mouse showed

rotating movements toward the left. 78 min p.r.: Mouse became inactive at 1 hr 14 min p.r. and was dead 4 min later.

Autopsy (3 hr 54 min p.r.). Burned hair and epidermis (Fig. 5) were present, and the subcutaneous tissue was slightly edematous. A view of subcutaneous tissue of scalp showed a 3-mm area surrounded by a 1-mm zone of petechial hemorrhage. The cranium was intact. Blueish discoloration was seen through the bone. The bone and dura in the brain were intact. The brain showed focal subarachnoid hemorrhage about 2 mm in diameter immediately beneath the area of the shot. This shot was slightly to the right of the midline and the lesion of the brain was in the same path (Fig. 8). The viscera were not remarkable.

Microscopic observations. Sections showed recent subarachnoid hemorrhage and recent slitlike cortical hemorrhages. There was slight blanching around the margins of hemorrhages. Slight vacuolation and pyknosis of neurons for a distance of about 1 mm around the hemorrhages were present.

Mouse 4

Focus: the animal positioned so that the focal point of the lens would be within the brain if the scalp and skull did not appreciably alter the focus (Fig. 4); distance (laser to target): 2 m; input joules: 9,000; output joules: 31.4 (measured), laser head was cooled with liquid nitrogen; duration of pulse: 400 μ sec.

Observations. This shot was intended to hit the mouse over the occiput, but the mouse apparently moved and the beam struck him over the back of the neck. Immediately after the shot the mouse showed no loss of vital signs. He appeared alert. Over the back of the neck about 2 mm caudal to the occipital bone was a 1.5-mm round burn. The hair was incompletely burned over this area, and the skin appeared charred but not perforated. This mouse appeared normal until he was killed.

Autopsy. (3 hr 46 min postradiation). The skin burn was over the neck, about the level of vertebra C-3 or C-4. The epidermis was charred over a 2-mm area. Subcutaneous tissue was edematous. There was an irregular circle of petechial hemorrhage in the corium. A 3-mm area of hemorrhage into neck muscles beneath the skin extended about 1 mm deep. It would appear that the muscle absorbed the beam and protected the deeper structures. The calvarium was intact. No gross abnormalities were observed in the brain. The viscera were not remarkable.

Microscopic observations. No abnormality was seen in the cerebrum or cerebellum. There was a focal area of subarachnoid hemorrhage and a few petechial hemorrhages in one side of the lower medulla, all near the area where the shot struck the head.

Mouse 5

Focus: animal positioned so that the focal point of the lens would be within the brain if the scalp and skull did not appreciably alter the focus (Fig. 4); distance (laser

to target): 2 m; input joules: 9,000; output joules: 28.1 (measured), laser head cooled with liquid nitrogen; duration of pulse: 400 μ sec.

Observations. Immediately after the shot the mouse appeared comatose. When removed from the holder he could not stand. His breathing was slow and he appeared to be dying. When held by the tail he showed a tendency to rotate toward the left. This mouse died 3 min after the shot.

Autopsy. The hair was burned over the shot (Fig. 5). The skin was slightly burned. A blanched area 2 mm surrounded by a 1-mm ring of petechial hemorrhage was seen in the subcutaneous skin. The cranium was intact. Blood could be seen bilaterally through the translucent cranium. The entire head was removed and the brain fixed in situ. Sections of the brain after fixation showed subarachnoid and intracerebral hemorrhages (Fig. 8). The viscera were not remarkable.

Microscopic observations. Recent subarachnoid hemorrhages were found over the convexities of both cerebral hemispheres, with slitlike hemorrhage into the cerebral cortex bilaterally beneath the radiated area (Fig. 9). There was a small amount of intraventricular hemorrhage.

Mouse 6

Focus: animal positioned so that the focal point of the lens would be within the brain if the scalp and skull did not appreciably alter the focus (Fig. 4); distance (laser to target): 2 m; input joules: 9,000; output joules: 23.5 (measured), laser head cooled with liquid nitrogen; Duration of pulse: 400 μ sec.

Observations. Immediately after the shot the mouse appeared to be semicomatose. When released from the holder he fell over on his right side and remained immobile. With some urging he righted himself slowly. A few minutes later he scratched his neck with his left



FIG. 9. Section of brain from mouse 5 showing subarachnoid and slitlike intracerebral hemorrhages caused by acute damage by laser radiation. Hematoxylin and eosin, $\times 50$.

foot and appeared to have recovered some of his movement. 56 min postradiation: Dragging his hind legs, the animal moved very slowly. 2 hr 1 min p.r.: Dead.

Autopsy. The skin was burned over a 2-mm area (Fig. 5). Hyperemic corium for an area of 2mm beneath the burn of epidermis was seen. Blood could be seen through the left side of the calvarium, which was translucent. The right side was clear. There was a thin layer of subarachnoid hemorrhage over the left hemisphere of the brain covering an area of about 4 mm. When this was removed, a 2-mm area of intracerebral hemorrhage was seen. Sections of brain showed subarachnoid and intracerebral hemorrhages (Fig. 8). The viscera were not remarkable.

Microscopic observations. Recent subarachnoid and slitlike intracortical hemorrhages were found in the cerebrum in the area described grossly. Around the hemorrhages the cortex was vacuolated and some of the remaining neurons were pyknotic and others chromatolyzed. Reactions of glial elements were minimal. The largest area of intracerebral hemorrhage was on the left, but there were small hemorrhages just to the right of the midline in the right hemisphere as well.

Mouse 7

Focus: Animal positioned so that the focal point was on the ventral side of the head. If the beam passed through the head (from dorsal to ventral surfaces) the focus would be outside of the head on the ventral side (Fig. 10); distance (laser to target): 2 m; input joules: 9,000; output joules: 20.9 (measured), laser head cooled with liquid nitrogen; duration of pulse: 400 μ sec.

Observations. Immediately after the shot the hair and skin were burned, but less intensely than in the previous shots in which the beam was focused inside the head. Immediately after the shot the mouse appeared completely normal. 5 hr 15 min postradiation: This mouse lived and seemed normal at the time noted above, when he was killed by chloroform anesthesia. The beam was focused to go through the head to a focal point beneath the head. This fact probably accounts for the minimal damage, since the energy of the beam would be distributed over a wide area of scalp, skull, and brain. There was slight brown discoloration of epidermis and hair partially burned off. Subcutaneous tissue was slightly hyperemic under shot area but not definitely hemorrhagic. The calvarium was intact. No sign of blood was beneath. The brain was grossly normal.

Microscopic observations. No definite abnormality of brain was seen.

Mouse 8

Focus: animal positioned so that the focal point was on the ventral side of the head. If the beam passed through the dorsum of the head, the focus would be outside of the head on the ventral side (Fig. 10); distance (laser to target): 2 m; input joules: 9,000; output joules: 20.9 (measured), laser head cooled with liquid nitrogen; duration of pulse: 400 μ sec.

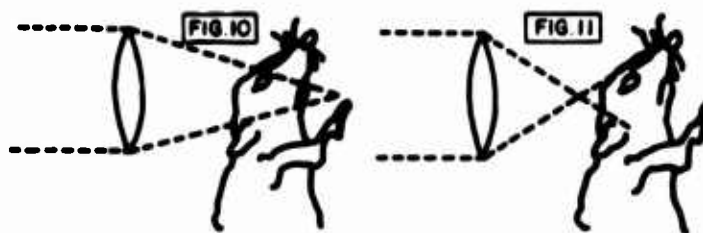

FIG. 10. Laser beam converging beyond the head produced no damage to brain parenchyma, assuming it is transmitted.

FIG. 11. Laser beam diverging onto scalp and transmitted partially into brain, if transmitted. Results variable.

Observations. Immediately after the shot the hair and skin were burned but less intensely than in the previous shots in which the beam was focused inside the head. Immediately after the shot the mouse appeared completely normal.

Autopsy (5-hr 10-min postradiation). The hair was partially burned off, and skin over a small area (1 mm) was slightly burned. Subcutaneous tissue: Not remarkable. The brain was grossly normal; the calvarium was intact.

Microscopic observations. No definite abnormality of brain was seen.

Mouse 9

Focus: beam diverging onto head. Cone of light about 4 mm on surface of head (Fig. 11); distance (laser to target): 2 m; input joules: 8,440; output joules: 32 (measured), laser head uncooled; duration of pulse: 400 μ sec.

Observations. Mouse appeared dazed after shot. 1 min postradiation: Convulsed. About 2-mm area of burned hair and skin over head. 3 min p.r.: Convulsions again after being quiet for 1.5 min. 11 min p.r.: Dead.

Autopsy (26 min p.r.). Autopsy showed epidural and subdural fresh hemorrhage. Recent subarachnoid hemorrhage covered a 6-mm area of the superior surface of the brain.

Microscopic observations. Sections showed recent subarachnoid hemorrhage, but no definite contusion of the brain parenchyma.

Mouse 10

Focus: beam diverging onto head. Cone of light about 10 mm in diameter on head (Fig. 11); distance (laser to target): 1.5 m; input joules: 8,440; output joules: 30 (measured), laser head uncooled; duration of pulse: 400 μ sec.

Observations. Hair burned. Mouse appeared lively and showed no visible effect. 3 min postradiation: Apparently normal. 1 hr 13 min p.r.: Apparently normal. Killed.

Autopsy (1 hr 26 min p.r.). Brain appeared normal.

Microscopic observations. No significant abnormality.

Mouse 11

Focus: beam converging beyond head (Fig. 10); distance (laser to target): 1.5 m; input joules: 8,440; output joules: 32; duration of pulse: 400 μ sec.

Observations. Shot was fired, and the hair burned slightly near left eye. 1 min postradiation: Mouse appeared slightly dazed, but all vital signs were present. 12 min p.r.: Less mobile than before, but he reacted to stimuli. 1 hr 55 min: Killed. Autopsy revealed no lesion of brain.

Microscopic observations. No significant abnormality.

Mouse 12

Focus: beam converging beyond head (Fig. 10); distance (laser to target): 1.5 m; input joules: 8,440; output joules: 34 (measured), laser head uncooled; duration of pulse: 400 μ sec.

Observations. Shot was fired and the animal moved, showing no definite loss of vigor immediately after shots. 1 hr 23 min postradiation: The mouse was killed. Autopsy showed no lesion in the brain.

Microscopic observations. No significant abnormality was seen.

Mouse 13

Focus: beam was focused into the window of the calorimeter, and then the head of a dead mouse was placed in front of the window; distance: 2 m; input joules: 8,440; output joules: 34 (measured), laser head uncooled; duration of pulse: 400 μ sec.

Observations. At first we placed a live mouse in front of the calorimeter, but the mouse's heat was too great and too variable for accurate determination of the percentage of a laser beam that would pass through the head. Therefore, we amputated the head, washed off the blood, cooled the head to room temperature, and then taped it in front of the window of the calorimeter.

When the shot was fired, the meter showed an immediate deflection of 4 μ v. By calculation, this indicated that approximately 0.05% of the beam had been transmitted through the head of the mouse.

Mouse 14

Focus: beam focused into the window of the calorimeter, and then the excised scalp and calvarium were taped in front of the window; distance: 2 m; input joules: 8,400; output joules: 34 (measured), laser head uncooled; duration of pulse: 400 μ sec.

Observations. A marked deflection of the meter of the calorimeter was obtained, and calculations indicated that approximately 9% of the beam had been transmitted. In order to check this result, we took the same piece of scalp and skull and measured the optical density and the per cent transmission of 6,943 Å of red light from the optical source in a Beckman DU spectrophotometer. The skull alone showed an optical density of 1.37 (about 4% transmission of this wavelength), and the scalp showed optical density of 1.45 (also approximately 4% transmission). This percentage of transmission is considerably lower than the transmission of the high-intensity laser beam. Of course, the area of the beam and other factors were not constant, and direct comparisons cannot be made between the laser and the spectrophotometer measurements.

Rat 1

Focus: none; distance (laser to target): 6 inches; input joules: 5,800; output joules: 25 (estimated), uncooled laser head; duration of pulse: 400 microseconds (estimated).

Observations. The beam was aimed (unfocused) mechanically at a distance of 6 inches. After the laser fired, the rat seemed to be unaltered in terms of vital signs, vigor, and reflexes. We smelled the odor of burning hair. The hair over the target area was burned, but the underlying skin appeared unharmed. The circular area of burned hair was slightly conical rather than a perfect cylinder. The outer circle measured 11 mm in diameter, and the inner circle, which was immediately over the skin, measured 6 mm in diameter. The rat did not appear to be in any distress when released. He had a brisk startle reaction; he could see a piece of red cloth placed in front of him, as evidenced by his snapping at it effectively.

Follow-up. This rat was checked daily for any signs of clinical abnormality, and none was found.

23 days postradiation: The rat appeared normal. Rat anesthetized by placing in a glass jar containing a chloroform-soaked gauze sponge. When breathing had almost ceased but heartbeat was good, the rat was pinned to a dissecting table, and the abdomen and chest were opened with scissors. A 0.5-ml dose of $\frac{1}{1000}$ heparin was injected into the left ventricle of the heart. A polyethylene tube was inserted and ligated into the left ventricle. The right atrium was partially excised to allow the venous blood to drain out. Through the catheter in the left ventricle, the entire circulatory system was flushed with normal saline by using a semiautomatic syringe setup. About 50 ml of saline was used. The saline apparatus was then removed, and the catheter was connected to a bottle of neutral formalin suspended from a hanger about 2 ft above the necropsy table. The airway of the formalin bottle was connected to a positive-pressure air source. Under pressure, the formalin was flushed through the entire circulatory system of the rat until all visible tissues appeared to be perfused. About 200 ml of formalin was used. The rat was then placed in toto in a jar of fresh, cold formalin for autopsy later.

Autopsy (27 days p.r.): Hair had regrown over the area of shot, but the skin over a 2-mm area was slightly crusted. No evidence of subcutaneous injury. Brain and viscera appeared normal.

Microscopic observations. No definite abnormality of brain was seen.

Rat 2

Target area: back (different areas of pigmented and nonpigmented skin and hair—three separate shots); focus: unfocused; distance (laser to target): 2 m; input joules: 8,414; output joules: 42 (estimated), uncooled laser head; duration of pulse: 400 μ sec.

The purpose of the experiment was to observe the effects of 1) unclipped hair, black and white, 2) clipped hair, and 3) second shot over same area (all three shots

unfocused); and to see whether the spinal cord or viscera could be damaged by an unfocused beam over the back.

Observations. Shot 1. Beam hit on an area of partly black and partly white hair. Animal did not show any signs of pain or loss of any function after the shot. The hair (black and white) was burned to about half the length of the fibers over a circular area measuring 25 x 20 mm. Shot 2: the hair was clipped over the lumbar vertebrae, and the unfocused beam was aimed over this area. The rat did not show any evidence of damage except for singeing of the margins of the clipped hair. There was no evidence of burning of the skin. The hair was clipped with scissors, and the skin was well protected by the hair that remained. (We think that the rat may have moved during this shot.) Shot 3. We decided to shoot again over the same area as shot 2. We smelled a strong odor of burning hair. The remaining hair was well burned off over an area measuring 20 mm across the outer circle and 15 mm over the skin below. The skin was charred and light brown in color. The burned skin was in a pigmented area.

These shots demonstrated that white hair reflects the beam better than black hair, but either may be burned by an unfocused beam. The pigmented skin was more susceptible to burning than the unpigmented. 23 days postradiation: Rat was killed by chloroform anesthesia followed by formalin perfusion (technique described for rat 1).

Autopsy. Hair had regrown over shot area. No subcutaneous damage was visible. Brain, spinal cord, and viscera appeared normal. Blocks were taken for histologic examination.

Microscopic observations. No definite abnormality of brain was seen.

Rat 3

Target area: occipital area of head; focus: Unfocused; distance (laser to target): 2 m; input joules: 9,000; output joules: 45 (estimated), uncooled laser head; duration of pulse: 400 usec.

Purpose of experiment. To repeat the effect of an unfocused beam over the occiput (same as in rat 1) except that the hair was closely shaved with an electric shaver and the distance from the target to the laser was 2 m instead of 6 inches. Also, the beam was increased from 25 to 42 joules. This beam was focused on the scalp (Fig. 1).

Observations. When the shot was fired the rat did not show any loss of vital signs or of vigor. The pigmented skin beneath the closely clipped hair was burned over an area measuring 25 x 10 mm. 23 days postradiation: Rat was killed by chloroform anesthesia followed by formalin perfusion (same technique as for rat 1).

Autopsy. Hair had grown back very poorly. In fact, the areas of shot appeared more depilated than originally after clipping. No gross abnormalities in subcutaneous tissue, brain, or viscera.

Microscopic observations. No definite abnormality of brain was observed.

Rat 4

Target area: occipital area of head; focus: beam focused optically by a convex lens 5.2 cm in diameter placed at the focal length 20 cm from target; distance (laser to target): 2 m; input joules: 9,000; output joules: 45 (estimated), uncooled laser head; duration of pulse: 400 usec (estimated).

Purpose of experiment. To observe the effect of a focused laser beam aimed over the occiput where the hair had been clipped closely over pigmented skin. This beam was focused on the scalp (Fig. 1).

Observations. The animal showed no evidence of loss of vital signs or of vigor immediately after the shot.

The focused beam was well aimed, and the skin showed a 2-mm hole that appeared to involve full thickness down to the cranium. The edges of the hole were brown and irregular, but there was no bleeding. Around the 2-mm hole the skin had been burned but not penetrated over a circular area, which was light brown and measured 8 mm in diameter. 15 days postradiation: Rat was observed daily after shot and seemed normal. 23 days p.r. Rat was killed with chloroform anesthesia followed by perfusion with neutral formalin.

Autopsy. Black spot (probably color of fixed contusion) appeared beneath the skin wound at site of shot. The skin lesion appeared well healed, but the 2-mm black spot in the corium suggested old blood. The hair had regrown over epidermal lesion. No abnormality of underlying bone or brain were seen and no gross abnormality of viscera was present.

Microscopic observations. No definite abnormality of brain occurred. We identified the pineal gland in this rat, which showed no significant abnormality.

Rat 5

Target area: Five shots, two over the occiput and three over the back were administered; focus: beam was focused optically with a convex lens upon the rat's skin; distance (laser to target): 2 m; input joules: 9,000; output joules: 40, laser head was cooled with liquid nitrogen for these shots, which probably increased output to this estimated level; duration of pulse: 400 usec.

Purpose of experiment. To observe the effects of two shots to the occipital region and of three additional shots of this higher output to pigmented and nonpigmented skin (focused and nonfocused).

Observations. Shot 1. A 2-mm perforation of scalp surrounded by an 8-mm burned area of skin produced no clinical effect on the rat. No loss of vigor or vital signs were observed. Shot 2. Similar wound as shot 1 was administered, but to the left of it. The rat apparently moved from original position. The perforation in this case showed blood in the base that filled the perforation but did not flow out. The rat showed no loss of vital signs or vigor. Shot 3. The beam burned a 2-mm perforation through the skin and an 8-mm superficial burn around the perforation. Note: For the next two shots, the focusing lens was removed. Shot 4. The beam struck the rat on the clipped hair of the back at a

point that was partially covered by paper masking tape. This was not planned, but the animal must have moved. Oddly, the hair and the superficial skin appeared to be burned where the beam struck over the tape and untaped area, but the tape was not burned. Shot 5. The unfocused beam was directed more medially with the masking tape removed. The hair that remained was burned, but the skin was only superficially burned (slight tan color). Note: The rat was examined after each shot and at intervals for 2 hr afterward. The rat showed no loss of vision (snapped effectively at red cloth), moved normally, showed a corneal reflex, and moved when ear or feelers were touched. He seemed as vigorous as before the shots.

This rat was killed by ether anesthesia 2.75 hr after last shot.

Autopsy. On the scalp was seen subcutaneous edema, mostly anterior. Eyes were clear. Midline incision over the scalp between shots 1 and 2 revealed bright red blood (about 1 ml) beneath the scalp. The wound of shot 1 showed contusion of the corium but no gross blood. The wound of shot 2 showed contusion (bluish-black) of the corium over an area 4 x 4 mm and through the full thickness of the scalp. Most of the gross blood was beneath this wound. Incision of shot 3 showed hyperemia of the deeper corium and blanching in center similar to the surface wound. An area of contusion extended 4 mm into the muscle beneath the skin contusion. This wound overlay part of the left kidney, but there was no evidence of damage to the peritoneum or to the kidney. Incisions of region of shots 4 and 5 showed no evidence of subcutaneous damage. The calvarium was intact and was removed over the dorsum of the brain with scissors and the brain exposed. A small amount of fresh subdural hemorrhage was observed, but was probably produced by cutting a venous sinus. The brain was removed and appeared grossly normal. The entire brain was fixed in formalin and cut into blocks. Coronal sections of the entire brain were submitted for histologic sectioning. No gross abnormalities were observed in the coronal sections of this brain. The viscera were not remarkable.

Microscopic observations. No definite abnormality of brain or spinal cord was seen.

Rat 6

Focus: focal point inside brain (animal positioned so that the focal point of the lens would be within the brain if the scalp and skull did not appreciably alter the focus) (Fig. 4); distance (laser to target): 2 m; input joules 9,000; output joules: 20.9 (measured), laser head cooled with liquid nitrogen; duration of pulse: 400 μ sec.

Observations. After the shot the rat seemed active, and he climbed out of the container and then stood braced and immobile. When pushed he would do no more than maintain posture. He appeared dazed. 11 min post-radiation: Animal shivering, not hostile, trying to climb. 18 min p.r.: Animal lethargic, but had a good startle reaction when hands were clapped. Less reaction to visual stimulation. Though he was quite hostile prior to

the shot, he was docile after it. 5 hr 21 min p.r.: Rat appeared somnolent. Startle and corneal reflexes present, but sluggish. He seemed to wobble when he walked. He did not snap at us when we handled him (which he consistently did before). Since this rat appeared to be abnormal, we decided to kill him at this time. 5 hr 26 min p.r.: Rat killed by chloroform anesthesia.

Autopsy. Skin was charred brown superficially but not perforated. The subcutaneous skin appeared slightly hyperemic over a circular area beneath skin burn. The calvarium was intact. A small amount of subdural hemorrhage was found over both convexities. A 6 x 8-mm area of subarachnoid hemorrhage occurred over the medial central areas of both hemispheres (Fig. 12). From the gross appearance there was parenchymal damage of the brain beneath the subarachnoid hemorrhage.

On section the gray matter immediately beneath the hemorrhage was discolored for a depth of 2 mm. Blood was not seen in the ventricle.

Microscopic observations. These sections showed very definite and striking areas of blanching and slitlike hemorrhage over the medial and parasagittal regions of the cortex beneath the point of irradiation (Fig. 13). Fresh subarachnoid hemorrhage elevated the arachnoid. The entire thickness of cortex for a distance of about 2 mm on each side of the midline was pale, vacuolated, and disrupted by elongated hemorrhages. The neurons were markedly pyknotic or chromatolyzed in these regions (Fig. 14). The areas of damage extended to the white matter, a distance of about 4 mm from the surface. These lesions showed features of contusion plus ischemic necrosis. Some of the vacuolation could have been produced by sudden vaporization of the parenchyma.

Rat 7

Target area: Head; focus: animal positioned so that the focal point of the lens would be within the brain if the scalp and skull did not appreciably alter the focus (Fig. 4); distance (laser to target): 2 m; input joules: 9,000; output joules: 22.2 (measured), laser head cooled with liquid nitrogen; duration of pulse: 400 μ sec.

Observations. Immediately after the shot he appeared less active. He was startled when we clapped our hands, but reacted sluggishly. A few minutes later he occasionally reared on his hindlegs, but he seemed not to balance perfectly. He appeared restless and tried to climb out of his cage. 1 hr 17 min postradiation: Killed with chloroform anesthesia. Prior to death this animal appeared to have returned to normal.

Autopsy. A 6-mm skin burn was seen. Hair was completely burned off at lesion site (Fig. 15). Skin showed a small vesicle. Subcutaneous tissue was not remarkable. Area of subarachnoid hemorrhage appeared over superior convexities of the brain (Fig. 16). The viscera were not remarkable.

Microscopic observations. This brain showed a small amount of subarachnoid hemorrhage and a few recent cortical hemorrhages beneath the area of radiation.

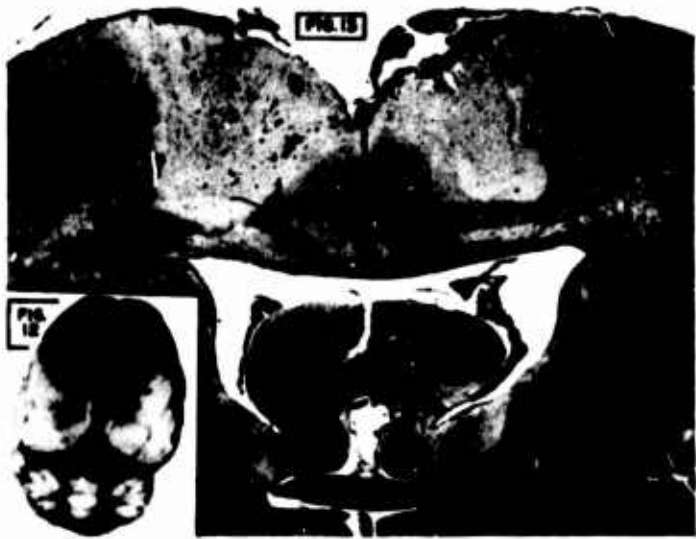

FIG. 12. Brain of rat 6 showing distribution of subarachnoid hemorrhage.

FIG. 13. Section of brain of rat 6 showing acute damage produced by laser radiation. Bilateral subarachnoid and slitlike intracerebral hemorrhages are evident. Note the pallor of the brain parenchyma in the region of damage. Hematoxylin and eosin, X 9.



FIG. 14. Section of brain of rat 6 showing a higher power view of one of the lesions shown in Fig. 15. Hematoxylin and eosin, X 80.

Rat 8

Focus: focal point inside brain (animal positioned so that the focal point of the lens would be within the brain if the scalp and skull did not appreciably alter the focus (Fig. 4)); distance (laser to target): 2 m; input joules: 9,000; output joules: 20.9 (measured), laser head cooled with liquid nitrogen; duration of pulse: 400 μ sec.

Observations. Immediately after the shot the rat appeared to be dazed. A startle reaction to clapping of hands was present, but sluggish. When placed in a

standing position the rat held his posture, but seemed to be a little unsteady. A few minutes later he appeared to be normal again, and tried to jump out of his cage. 11 days postradiation: The area of depilation measured 12 x 6 mm. The central 3-mm area was slightly depressed and whitish, smooth, and glistening. The surrounding zone was bluish black, as though it contained an increased amount of pigment. Rat was killed with chloroform anesthesia.

Autopsy. The area of bluish-black pigmentation on the skin extended full thickness through epidermis and corium. This looked like organizing subcutaneous hemorrhage. Moderate amount of tan-colored material was seen in subarachnoid space beneath area of radiation. Slight depression of cortex occurred. In the cranium the galea appeared slightly roughened, but the bone was intact.

Microscopic observations. These sections showed the features of a healing contusion in the area that was irradiated by the focused beam. The cortex was destroyed in a wedge-shaped zone extending from the surface of the brain to an apex at the junction of subcortical white matter (Fig. 17). All layers of cortex were destroyed. Gitter cells containing brownish pigment and microscopic vacuoles filled the area of destruction. The margins of the contusion were lined by reactive astrocytes. A few capillaries proliferated at the margins, and there was slight fibroblastic activity at the subarachnoid space. For about 1 mm near the margins of the contusion, the neurons were pyknotic. Slight astrocytic gliosis of the subcortical white matter existed beneath the contusion. This lesion was indistinguishable from a healing contusion from any other type of physical trauma.

Rat 9

Focus: animal positioned so that the focal point of the lens would be within the brain if the scalp and skull did not appreciably alter the focus (Fig. 4); distance (laser to target): 2 m; input joules: 9,000; output joules: 19.6

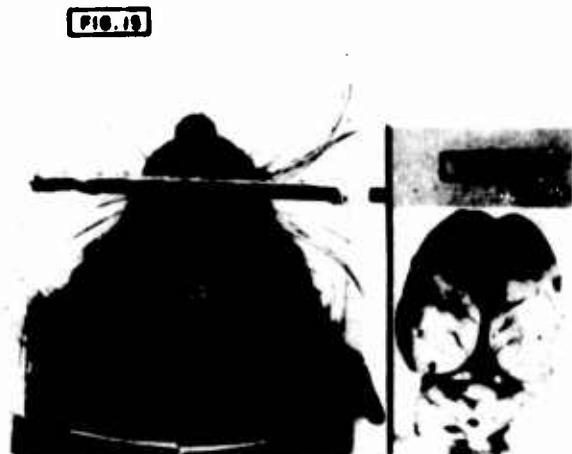

FIG. 15. Head of rat 7 showing area of burned hair and burned scalp as well as the plastic holder used in these experiments.

FIG. 16. Brain of rat 7 showing distribution of subarachnoid hemorrhage.



FIG. 17. Section of brain of rat 8, killed 11 days after a single laser shot to the head. This animal showed a skin lesion similar to that illustrated in Fig. 15. Note the wedge-shaped area of destruction of the cerebral cortex. The wound is filled with glitter cells, and the borders of the wound show early stages of astrocytic gliosis. Hematoxylin and eosin, $\times 80$.

(measured), laser head cooled with liquid nitrogen; duration of pulse: 400 μ sec.

Observations. Immediately after the shot the rat appeared less active and less hostile than before the shot. He maintained his posture, but showed poverty of movement. Startle reaction was present to clapping of hands. 11 days postirradiation: Rat killed with chloroform anesthesia.

Autopsy. An 8.5-mm. zone of depilation existed with a central, depressed, whitish area measuring 3 x 1 mm. Bluish pigmentation of subcutaneous tissue was seen beneath the area of depilation. The cranium was intact. A 2-mm area of subarachnoid and subpial hemorrhage in the brain was seen just to the right of midline in the right hemisphere superiorly. On the superior aspect of the cerebellum, in the midline, there was an area of subarachnoid hemorrhage measuring about 2 mm in diameter.

Microscopic observations. Sections show a wedge-shaped healing cortical contusion almost identical to the one described for rat 8. This contusion was compatible with the time interval of 11 days, and the location was beneath the point of irradiation with the laser beam.

Monkey 1

Focus: focal point 3 cm inside calvarium (if transmitted); distance (laser to target): 2.5 m; input joules:

9,000; output joules: 20 (measured), laser head cooled with liquid nitrogen; duration of pulse: 400 μ sec.

Purpose of experiment. To determine the effect of a focused laser beam centered over the right parietal region of the scalp and aimed from the right parietal region toward the left eye. (The focal point of the beam was found, and the animal was placed so that this point would be within the middle of the brain, probably in the region of the hypothalamus.)

Observations. The monkey was blindfolded, and he seemed quiet just before the shot was fired. To protect our eyes we turned away at the moment of firing. When we observed the monkey immediately after the shot, a small burn of the skin had been produced at the area we had planned to hit. The monkey did not vocalize, and from our observations he did not seem to be harmed in any way except for the burn of the scalp. There was no sign of depression of any of his reflexes.

The wound of the scalp consisted of a 1-mm perforation that we estimated to extend through the thickness of the epidermis. The perforation was surrounded by a 4-mm circle of slightly tanned but intact epidermis. The hair was completely burned off of this area. (The hair had been clipped, but short hairs remained.) The margins of hair were slightly burned for another millimeter around the major burn. This animal was alive and well 54 days postirradiation and seemed unaffected by the lesion of his scalp, which appeared to have healed.

DISCUSSION

We described these experiments in detail because research in this field is relatively new and because we have found it necessary to improvise as unanticipated problems arose. These experiments show that an unfocused laser beam from a ruby rod with a monochromatic wavelength of 6,943 Å and with energy in the 20- to 40-joule range will do no more than burn the hair and sometimes the skin of the head of a white mouse. We found no evidence of damage to the brain under these conditions. Such a beam is spread over an area of about 1 cm (2), and we suspect that most of the beam is reflected.

The brains of certain animals seem to be sensitive to light. The lamprey, for example, has a pineal gland that seems to function as a third eye sensitive to changes of intensity of light. We thought it possible that the brain of a mouse would be sensitive enough to very strong light that intense photic stimulation would produce death, with no visible damage to parenchyma such as that produced by intense heat. Our experiments, however, have failed to produce death in any animal without producing hemorrhages in the brain resembling the effect of contusions to the brain. An unfocused beam of higher energy than we have used may be capable of transmitting enough energy to damage the brain through the thin skull of a mouse, but our experiments were negative in the range of 20-40 joules.

A focused beam is another matter. We consistently produced death in mice within a few minutes when the beam was focused so that the focal point would con-

verge on or diverge into the brain over an area of 1 or 2 mm. Measurements show that approximately 9% of a focused beam can be transmitted into the brain through the thin scalp and skull of a mouse. There are wide variations in optical density, however, due to variations in thickness of the skull and in pigmentation of the skin and hair. About .05% of a focused beam can be transmitted through the entire head of a mouse. Both the incident beam and the secondary radiation of the plume may contribute to the total amount of light transmitted. The damage within the brain is probably caused by the energy absorbed over a path of 1-4-mm in 400 μ sec or less. In the future, we expect to repeat some of these experiments with a Q-switched beam and to photograph the sequence of events with an image-converter camera.

In rats with black hair and deeply melanin-pigmented skin over their heads, a 20- to 40-joule focused beam resulted in clinical evidence that the animal was dazed but not killed within a few minutes, as we had observed in mice. The pigmented skin and the thicker skull of the rat seemed to have absorbed more of the beam, or the animal was more resistant to the effects. We could consistently produce subarachnoid hemorrhages and parenchymal hemorrhages of the brain of black-headed rats, however, with the beam focused so that the focal point would be in the brain if transmitted. The fresh damage to the brain showed features of a cortical contusion along the path of the beam. Two of the animals that appeared to be dazed after a focused shot lived and seemed to recover, although they were not quite as active or as hostile as they were before the shots. When autopsied 11 days after the shots, both animals showed healing contusions of the brain beneath the radiated area. These experiments show clearly that black hair and pigmented skin will not absorb all of the energy of a focused beam in the 20- to 40-joule range.

Our one preliminary experiment on a monkey produced a burn of the scalp, but the monkey showed no clinical evidence of brain injury. We have not killed this animal, but we do not expect to find parenchymal damage of the brain. We expect that the much thicker scalp and skull has absorbed the beam. The hair, scalp, and skull of man can, therefore, be expected to protect the brain against focused or unfocused laser radiation up to 40 joules and probably much greater energy levels.

In none of the animals did we produce any evidence of contrecoup injury. All of the parenchymatous injuries were of the coup type, i.e., immediately beneath the point of contact, along the path of the beam. The hemorrhages extended no more than 4 mm into the brain.

SUMMARY

We conducted experiments to determine the effects of focused and unfocused laser radiation upon the scalp,

REFERENCES

1. LITWIN, M. S., AND D. H. GLEW. *J. Am. Med. Assoc.* 187: 842, 1964.
2. MAIMAN, T. H. *Nature* 187: 493, 1960.
3. MALT, R. A. AND C. H. TOWNES. *New Engl. J. Med.* 269: 1417, 1963.

cranium, and brain parenchyma of mice and rats. The laser, a Maser Optics model 3100 power supply and laser head operated with a ruby crystal had an output energy between 20 and 40 joules. The cavity was purged with nitrogen gas. The head was cooled with liquid nitrogen in some experiments, and the laser was uncooled in other experiments. The laser produced a coherent pulsed flash of red light with a wave length of 6,943 Å that could be focused to a small spot with a convex glass lens.

With an unfocused beam, no gross or microscopic lesions of the brain parenchyma were produced when the beam was directed onto the intact and unshaved scalp and cranium. With a beam focused on the unshaved scalp the skin was burned, but the cranium was intact. Subdural, subarachnoid, and focal intracerebral hemorrhage was produced in the brain parenchyma of mice but not of rats under these conditions.

When the beam was aimed onto the head and focused so that the focal point would (if transmitted) be inside the cranium and within the brain parenchyma along a track that corresponded with the focal depth, most of the mice died within minutes after such experiments when the output was about 20-40 joules. Similar lesions were produced in rats, but the rats were less affected generally and the results were not immediately fatal. The later effects of this type of injury were observed 11 days after injury in two rats allowed to survive. The lesions showed the features of healing contusions of the brain.

In the range of 20-40 joules, subdural hemorrhages of the brain were produced with a focused beam so placed as to diverge into the head with a cone diameter of about 4 mm, but hemorrhages did not result when a cone diameter of 10 mm was used. No parenchymatous hemorrhages were produced with a beam converging on the other side of the head if the beam were transmitted from dorsal to ventral surfaces without changing the focus.

Preliminary experiments indicate that about 9% of a 30-joule beam is transmitted into the brain through the hair, scalp, and cranium of a white mouse. About .05% of a 30-joule beam is transmitted through the entire head of a white mouse if focused to strike a calorimeter placed on the other side of the head.

Our experiments suggest that the human hair, scalp, and skull would be sufficiently thick and dense to protect the brain from focused or unfocused laser radiation up to the 40-joule output and probably much higher energies, but the brains of small animals such as rats and mice can be severely damaged by a focused beam that is partially transmitted through the scalp and skull.