

AD 675632


TRANSLATION NO. 2035

DATE: 23 Oct. 1967

DDC AVAILABILITY NOTICE

Qualified requestors may obtain copies of this document from DDC.

This publication has been translated from the open literature and is available to the general public. Non-DOD agencies may purchase this publication from the Clearinghouse for Federal Scientific and Technical Information, U. S. Department of Commerce, Springfield, Va.



This document is available to the public for public relations purposes; its reproduction is prohibited.

DEPARTMENT OF THE ARMY
Fort Detrick
Frederick, Maryland

Reproduced by the
CLEARINGHOUSE
for Federal Scientific & Technical
Information Springfield Va 22151

DYNAMICS OF MORPHOLOGICAL CHANGES IN GUINEA PIG ORGANS
AFTER INJECTION OF PENICILLIN

Antibiotiki
(Antibiotics)

Ye. Ya. Severova

Vol. 9, 1964, pages 44-49

The high natural sensitivity of guinea pigs to penicillin is reflected in the high death rate of the animals after even a single parenteral administration of the antibiotic. Individual differences are an important factor. While some adult animals are killed by small doses (100 to 500 units), others survive even very large ones (512,000 units in our experiments). The mechanism of this extreme sensitivity is obscure and it has been attributed by different authors to various causes (avitaminosis, dysbacteriosis [change in intestinal flora], allergy).

In studies on the pathogenic effect of penicillin on guinea pigs, attention was focused on the fact that the animals do not die immediately after the injection, but 3 to 4 days later, i.e., at a time when the antibiotic has mostly disappeared from the body (penicillin is known to be eliminated from guinea pigs within 3 to 4 hours [1]). Consequently, it has been conjectured that the death of the animals is related to the onset of an intestinal infection caused by penicillin-resistant microbes. Examination of the animals' intestinal flora after the administration of penicillin [2-4] showed that the antibiotic suppresses the gram-positive flora characteristic of the guinea pig intestine, thus permitting the development of gram-negative flora, which is highly toxic to this species of animal. However, this infection theory does not account for the selective action of different doses of the antibiotic, for small amounts sometimes have a stronger pathogenic effect than large amounts, nor does it explain why pathological changes arise in the intestinal wall before the onset of dysbacteriosis [5].

Reports on morphological changes in the viscera of guinea pigs after the administration of penicillin are conflicting because they refer to animals that died or were sacrificed at different times after the antibiotic was injected. For example, histological examination of the organs of guinea pigs who died 3 or 4 days after a single injection of 10,000 units/kg of penicillin failed to reveal any changes [6]. Necrosis of individual fibers in the myocardium was noted in 2 of 12 animals given doses ranging from 4000 to 40,000 units/kg, while large necrotic areas in the liver were found in some others [7]. In 2 of 10 animals, changes were noted in the adrenals consisting of pronounced hyperemia of the medullary and cortical layers with secondary changes in the parenchymal cells to the point of necrosis [8]. Lesions were detected in the gastrointestinal tract -- hyperemia of the mucosa, hyperplasia of the reticular cells of the small intestine stroma, hypersecretion of mucus in the large intestine between the 3rd and 4th days, and infectious-inflammatory changes thereafter [5].

In an effort to determine why guinea pigs die after the administration of penicillin and to study the pathological process dynamically, we investigated changes in the viscera of animals sacrificed at various intervals after injection of the antibiotic. Thirty experimental animals weighing 200 to 250 g were injected intramuscularly with 32,000 units of the calcium salt of crystalline penicillin in 0.5 ml of physiological saline near the outer surface of the left hind paw. Three animals were sacrificed daily for morphological study. The heart, lungs, brain, liver, kidneys, adrenals, small and large intestines were removed for microscopic examination. The material was embedded in paraffin and the sections were stained with hematoxylin-eosin.

Gross examination of the animals sacrificed 24 hours after the injection of penicillin failed to reveal any unusual changes in the organs. The intestinal loops were collapsed. The liver was of normal size with a smooth surface and transparent capsule through which could be seen the cinnamon-brown-yellow parenchyma, which had in cross section the same color but with a dull tone.

Microscopic examination of the organs of these animals revealed pronounced changes, which were especially severe in 2 of the sacrificed guinea pigs. In the myocardium against a background of hyperemia and occasional hemorrhages, endothelial cells of the capillaries and small blood vessels were proliferating, here and there with marked round-cell and histiocytic perivascular infiltration and patches of necrosis in the walls (Fig. 1). The proliferating endothelium of the small vessels sometimes formed granulomatous growths protruding into the lumens. There was sporadic necrosis of individual

GRAPHIC NOT REPRODUCIBLE




Figure 1. Myocardium. Perivascular round-cell infiltration in the myocardial stroma. Photomicrograph. Enlargement 7 X 40.

muscle fibers or groups of fibers surrounded by infiltrates of histiocytes and fibroblasts. The infiltrates contained large quantities of Anitschkow's myocytes. Infiltrates consisting of lymphoid elements and histiocytes were also found under the endocardium.

The lungs were marked by hemorrhagic foci in the alveolar cavity, focal emphysema, and pronounced proliferation of the endothelium of the capillaries of the interalveolar septa. The bronchial mucosa was folded, with mucus and sometimes masses of erythrocytes in the lumens.

The liver was hyperemic, with degenerative changes in the parenchymal cells and small drops of fat, proliferation of Kupffer's cells. In one case there was necrosis of the walls in some of the small blood vessels, occasionally with constriction of the lumens and round-cell infiltration around them. Isolated hepatic cells were necrotic.

The brain tissue was markedly edematous, especially around the blood vessels. There was proliferation of the capillary endothelium, occasionally of endothelium of the small blood vessels with a few tiny hemorrhages, marked proliferation of cells in the perivascular tissue, and focal proliferation of glia (Fig. 2). Some of the glial cells were swollen with indistinct nuclei. The pia mater

GRAPHIC NOT REPRODUCIBLE




Figure 2. Brain. Edema of cerebral substance with focal proliferation of glial elements. Photomicrograph. Enlargement 7 X 40.

was edematous and hyperemic. The endothelium of the capillaries and small vessels was proliferating and threatening to close the lumens. Perivascular hemorrhages were common.

The kidneys, intestine, and adrenals were characterized by hyperemia and degenerative changes in the epithelial cells in the form of slight swelling.

Gross examination of the animals sacrificed after 48 and 72 hours revealed attenuation of the fatty tissue, distention of the intestinal loops whose lumens contained liquid matter, hyperemia of the serous membranes, uneven blood supply to the lungs, and enlargement of the adrenals to almost twice the normal size. The changes in the viscera revealed by microscopic examination were more or less the same as in the animals sacrificed earlier. For example, after 48 hours the myocardium was hyperemic in two animals with small foci of hemorrhages and focal accumulations in the stroma of histiocytes, fibroblasts, and round cells admixed with eosinophils (in 1 animal). In the lungs -- hyperemia, proliferation of capillaries of the inter-alveolar septa, and blood in some of the alveolar cavities. In the liver -- fatty degeneration and proliferation of Kupffer's cells, necrosis of occasional parenchymal cells. The changes in the brain were similar to those noted in the animals sacrificed after 24 hours.

The changes in the viscera of all the animals sacrificed after 72 hours were relatively minor -- hyperemia, degeneration of parenchymal organs, small drops of fat in the liver (in 2), proliferation of Kupffer's cells, marked proliferation of capillary endo-

thelium in the myocardium, lungs, liver, and brain. The intestine exhibited inflammatory infiltration by round cells and leukocytes mostly in the submucosal layer, edema, and signs of panvasculitis (Fig. 3).

GRAPHIC NOT REPRODUCIBLE




Figure 3. Wall of small intestine. Panvasculitis with massive perivascular infiltration. Photomicrograp. Enlargement 7 X 40.

form of accumulations of round cells, histiocytes, and fibroblasts. One animal showed marked changes in the valves which were edematous; their endothelium was occasionally arranged in layers (Fig. 4). The changes in the intestine were similar to those described above.

After 120 and 144 hours the pathological changes, on gross examination, were relatively minor -- liver normal in size, marbling sharply decreased, intestinal loops collapsed and contents solid, slight hyperemia of the serous membranes, adhesions between the layers of the pericardium. Increased amount of fat visible in the subcutaneous and circumhepatic tissue.

Microscopic examination revealed comparatively minor changes -- hyperemia, slight swelling of the parenchymal organs sometimes

Gross examination of the animals sacrificed after 96 hours revealed the following: exhaustion, pronounced hyperemia of the blood vessels of the serous membranes, occasionally very delicate fibrous adhesions between the folds of the serous membrane, adrenals enlarged to almost three times the normal size with hemorrhages visible on top of one of them. The liver was markedly changed -- enlarged with marbling due to the uneven blood supply. The blood supply to the lungs was also uneven. The loops of the large intestine were distended; the lumens contained liquid matter. The surface of the spleen was rough and slightly grainy.

Microscopic examination of the viscera of these animals revealed changes similar to the above, but with granulomatous formations in the myocardial stroma and under the endocardium in the

GRAPHIC NOT REPRODUCIBLE

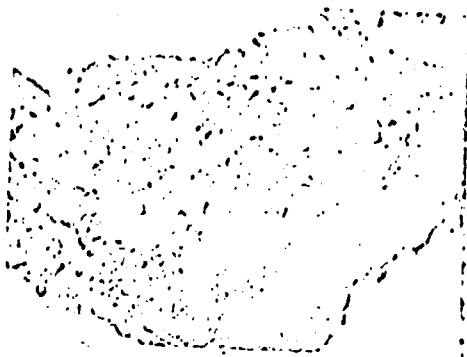

Figure 4. Heart. Proliferation of endothelium and marked edema of valvular tissue. Photomicrograph. Enlargement 7 X 40.

with fatty degeneration, proliferation of vascular endothelium and Kupffer's cells in the liver, occasional hemorrhages in the alveolar cavity. One animal had hemorrhages in the cerebral substance and small infiltrates in the heart containing Anitschkow's myocytes. Five others had only degenerative changes in the parenchymal organs with moderate proliferation of vascular endothelium in the lungs and liver.

One of the guinea pigs sacrificed after 144 hours exhibited changes (microscopic examination) in the myocardium and brain tissue similar to those found in the animals sacrificed after 24 hours along with the changes in the other organs that were common at this time -- focal necrosis of muscle fibers, focal myocarditis, granulomatous formations in the endocardium with valvular involvement in the form of marked swelling of tissue and infiltration by masses of histiocytes and fibroblasts. The endothelium on the valvular surface was succulent with hypochromic nuclei, occasionally arranged in several layers. The brain of this animal was markedly edematous; vasculitis, capillaritis, and focal encephalitis were similar to those in the animals sacrificed after 24 hours. No signs of fatty degeneration were noted in the liver. The myocardium of another animal contained delicate scar changes in the form of young connective tissue rich in cellular elements and capillaries taking the place of the muscle fibers.

Gross examination of the animals sacrificed at the other three times showed no unusual changes as compared with the healthy

controls. The microscopic changes were also slight, and, in our opinion, merely residual phenomena. They consisted mainly in moderate proliferation of capillary endothelium. No degenerative changes were noted in the organs.

Thus, a study of the morphological changes in the viscera of guinea pigs sacrificed at different times after parenteral injection of penicillin showed similar changes in almost all cases. These included the following: some degree of hyperemia in all the organs, degenerative changes in the form of swelling of the parenchymal organs, sometimes with fatty degeneration of the liver (in 12 of 30 cases), and, in general, proliferation of Kupffer's cells in the liver. Another noteworthy feature was the vigorous proliferation of capillary endothelium especially in the myocardium, lungs, liver, and brain with signs of vasculitis against a background of fibrinoid changes in the walls of the small blood vessels. The lungs were characterized by multiple hemorrhages in the alveoli. Focal infiltrates of round cells were observed in the myocardial stroma and sometimes under the endocardium. In isolated cases infiltrates of the intestine, lungs, and heart contained small quantities of eosinophils.

Along with a similar general picture of changes in the organs there were also differences in the degree and severity of the lesions in relation to the time the animals were sacrificed. Animals sacrificed at the same periods exhibited in addition to the severe lesions which probably killed them comparatively slight changes. It is reasonable to assume that such changes take place in the less sensitive individuals who in the natural course of the process apparently remain alive.

The results of our observations show, therefore, that within 24 hours of the administration of penicillin most animals exhibit widespread vascular changes, which we may interpret as forms of vasculitis combined with focal myocarditis, focal encephalitis, symptoms of bronchospasm, and necroses in the liver. These changes are a morphological manifestation of an allergic process. They eventually kill the animals or are reversed. The changes are the background against which dysbacteriosis arises. With a milder course of the process, the animals may develop pathological changes of a different kind at later intervals. For example, if the animals survive, they develop scar changes over the necrotic areas as in the myocardium. Among the cells in the focal infiltrates of the myocardium are some Anitchkow's myocytes, which have been described in widespread systemic vascular diseases, specifically, in systemic lupus erythematosus in man [9]. The process was accompanied by such changes in the organs as the development of granulomatous formations,

necrosis of individual myocardial fibers with cellular infiltration around them, and capillaritis in many organs.

Conclusions

1. A single parenteral injection of 50 guinea pigs with penicillin produced within 24 hours widespread lesions of the blood vessels in the form of vasculitis combined with focal myocarditis, focal encephalitis, bronchospasm, and liver necroses. These changes resemble the morphological picture of an allergic process.
2. The changes in the severe cases resulted in the death of the animals. The changes were reversed when the course was mild.
3. Localization of the changes in the intestines led to the subsequent development of gram-negative flora.

Bibliography

1. Stuart, P. and Slavin, G. Nature, 1951, Vol. 167, p. 319.
2. Rolle, M. and Mayor, H. Arch. Hyg. (Berlin), 1953, Vol. 137, p. 596.
3. De Somer, P., van de Voode, H., Eyssen, H., et al. Antibiot. and Chemother., 1955, Vol. 5, p. 463.
4. Fischer, G. W. Zbl. Bakt. I. Abt. Orig., 1955, Vol. 164, p. 230.
5. Kharitonova, A. M. Zh. Mikrobiol. (Journal of Microbiology), 1958, No. 6, p. 74.
6. Ambrus, C. M., Sideri, C. N., Johnson, G. C., et al. Antibiot. and Chemother., 1952, Vol. 2, p. 521.
7. Moore, D. M., Rake, G., MacKee, C. M., et al. Am. Jour. Med. Sci., 1943, Vol. 206, p. 642.
8. Moischer, G. and Bühm, C. Schweiz. med. Wachr., 1947, Vol. 77, p. 821.
9. Beglaryan, A. G. and Potekayeva, M. A. Trudy I-go Moskensk. med. in-ta (Transactions of the First Moscow Medical Institute), 1962, Vol. 13, p. 45.