

U.S. NAVAL  
MEDICAL RESEARCH LABORATORY



Submarine Base, New London, Conn.

Vol. XX, No. 16

REPORT NO. 362


22 Sept 1961

THE CYTOCHEMISTRY OF ANOXIC AND ANOXIC-ISCHEMIC  
ENCEPHALOPATHY IN RATS

II. Alterations in Neuronal Mitochondria Identified by  
Diphopyridine and Triphosphopyridine Nucleotide Diaphorases

by  
Norwin H. Becker,  
LT, MC, USNR

Bureau of Medicine and Surgery, Navy Department,  
Research Project MR005.14-3100-3.01



## THE CYTOCHEMISTRY OF ANOXIC AND ANOXIC-ISCHEMIC ENCEPHALOPATHY IN RATS

### II. ALTERATIONS IN NEURONAL MITOCHONDRIA IDENTIFIED BY DIPHOSPHOPYRIDINE AND TRIPHOSPHOPYRIDINE NUCLEOTIDE DIAPHORASES

NORWIN H. BECKER, LT. (MC), USNR

*From the Medical Research Laboratory, United States Naval Submarine Base,  
New London, Conn.*

The first part of this investigation concerned the alterations in neuronal lysosomes identified by acid phosphatase activity.<sup>1</sup> Significant changes in the lysosomes were noted early in the course of necrobiosis before any abnormalities could be detected in conventional hematoxylin and eosin and Nissl stains. In view of these promising observations, it was considered desirable to extend these studies to include other enzyme systems.

The development of refined histochemical techniques employing tetrazolium salts<sup>2</sup> has permitted the investigation of several dehydrogenases and diaphorases in the central nervous system. Observations on unfixed frozen sections<sup>3,4</sup> and unfixed frozen-dried<sup>5</sup> as well as fresh tissue<sup>6</sup> have been reported. Recently, the localization, both cytologic and histologic, in the normal rat brain and spinal cord, of several enzyme systems that survive cold formol-calcium fixation has been described.<sup>7,8</sup> The advantage of this fixative is that it preserves morphologic detail while permitting visualization of such enzyme activities as diphosphopyridine and triphosphopyridine nucleotide (DPN and TPN) diaphorases in mitochondria and basophilic substance, adenosine triphosphatase in cell membranes and acid phosphatase in lysosomes.

The purpose of this investigation is to describe alterations in neuronal sites of DPN and TPN diaphorase activity in the rat brain during post-mortem autolysis and in anoxic and anoxic-ischemic encephalopathy.

#### METHODS

Both male and female Sprague-Dawley rats (150 to 250 gm.) were used in all the experiments. They were killed by crushing the cervico-thoracic spinal cord; the cranial vault was rapidly reflected and the brain removed intact.

#### *Postmortem Autolysis*

The brains were first separated into halves by longitudinal section. One half, cut into coronal sections, was placed directly in the fixative. Before fixation the remaining half was placed in a sterile Petri dish and incubated at 37° C. for periods ranging from 5 minutes to 24 hours.

Accepted for publication, December 19, 1960.

### *Anoxic-Ischemic Encephalopathy*

Animals were subjected to the procedure of Levine,<sup>6</sup> nitrogen serving as the anoxic agent. Anoxic exposure was initiated 40 to 60 minutes after ligation of the left common carotid artery under ether anesthesia. The animals were maintained in a relatively stable unconscious state for periods of 30 to 60 minutes. During this period, depressed respiratory rates of 25 to 50 per minute were observed. Following the anoxic episode, animals were allowed to survive for periods ranging from immediate sacrifice to 3 days. The brain was then divided into coronal sections, 2 or 3 mm. thick, and placed in fixative.

### *Anoxic Encephalopathy*

Three different schedules of anoxic exposure were used. One group was exposed to a continuously flowing atmosphere of 100 per cent nitrogen for 60 to 90 seconds. Exposure was ended when apnea supervened. These animals were killed at 30 minutes, 6 and 24 hours after exposure.

In the second group, 3 such acute exposures were given 1 hour apart. The animals were killed 6 and 24 hours after the last exposure.

The third group was placed in a continuously flowing atmosphere consisting of 8 per cent oxygen and 92 per cent nitrogen containing traces of carbon dioxide. Increased bursts of nitrogen were given at hourly intervals so that oxygen levels were lowered sufficiently to produce severe agitation and respiratory distress. The rats were exposed to this environment in 4 daily periods of 4 hours each.

### *Control Groups*

Normal rat brains were processed as controls during these experiments. In another control group, rats given 5 minutes of deep ether anesthesia or those with common carotid artery ligation without further anoxia were killed 6 and 24 hours after the respective procedures.

### *Histologic Technique*

The blocks were allowed to fix for 18 to 24 hours in cold formol-calcium (2° to 4° C.). Frozen sections, 10 to 20  $\mu$  thick, were prepared with the use of a Sartorius sliding freezing microtome. The sections were rinsed in distilled water and stained for DPN and TPN diaphorase activity.<sup>7</sup> Sections were incubated for 40 minutes (DPNH) or 60 minutes (TPNH) at 37° C. in the following freshly prepared mixture:

Reduced diphosphopyridine nucleotide (DPNH) or reduced triphosphopyridine nucleotide (TPNH) (Sigma Chemical Corporation), 4 mg.; 1.2 ml. of H<sub>2</sub>O; 0.8 ml. of 0.1 M phosphate buffer, pH 7.4; 1 ml. of Nitro BT [2,2'-di-p-nitrophenyl-5,5'-diphenyl-3,3'-(3,3'-dimethoxy-4,4'-biphenylene)-ditetrazolium chloride (Dajac Division, Borden Chemical Company)], 1 mg. per ml. The sections were then rinsed in distilled water and mounted in glycerogel. In the case of some of the injured tissue, sections were allowed to incubate for only 10 to 15 minutes. In addition to these short incubation trials, some sections were carried through 2 changes of ice-cold acetone (60 seconds each) prior to being placed in the incubation media. In all cases, substrate control sections were incubated in the absence of DPNH or TPNH.

Unfrozen blocks of tissue adjacent to those taken for frozen sections were embedded in paraffin. Sections 6 to 8  $\mu$  thick were stained with hematoxylin and eosin or thionine ("paraffin-Nissl").

## RESULTS

### *Normal and Control Animals*

In addition to 16 normal brain halves procured in the autolysis ex-

periments, the brains of 10 normal animals were available for examination.

As previously noted,<sup>7</sup> there was prominent cytochemical staining of the larger neurons in the cerebral cortex, the Purkinje and granule cells of the cerebellar cortex and the neurons of the cranial and cerebellar nerve nuclei. Moderate staining was present in the remaining neurons. Within the neurons, diformazan deposits were more extensive with DPNH than with TPNH as substrate. While the localization of the TPNH diaphorase appeared to be chiefly mitochondrial, DPNH activity was present in both mitochondria and Nissl substances (Fig. 1). Some freezing and osmotic damage inherent in the techniques used undoubtedly occurred. This resulted in some variation in the distribution and size of the sites of enzyme activity.

Nevertheless, a normal base line could be established, against which pathologic alterations could be compared. All substrate control sections were negative. There were no histologic or histochemical abnormalities present in the brains of 5 animals given ether anesthesia only or in those (6 animals) obtained after unilateral common carotid artery ligation without further anoxic treatment.

#### *Autolysis*

In the sections stained for Nissl substance and with hematoxylin and eosin, no abnormalities were noted earlier than 45 minutes (6 animals). From 45 minutes to 24 hours (10 animals) increasingly severe alterations were present; these were similar to those previously noted.<sup>1</sup>

In sections stained for DPNH diaphorase activity, no abnormalities were observed earlier than 30 minutes. At this time neurons with swollen sites of enzyme activity (swollen mitochondria) could be seen in many zones, particularly in the cerebral cortex (Fig. 2), cerebellum and corpus striatum. A loosening and an increased pallor of the basophilic substance and an occasional loss of all neuronal activity could also be seen in these cells. Many of the abnormal mitochondria were perinuclear in location. By 8 hours most neurons were similarly altered in all parts of the brain. In addition, there was a marked reduction in the staining of the neuropil so that the blood vessels and dendritic processes which remained stained appeared more prominent (Fig. 3). At 12 hours there was considerable over-all loss of neuronal enzyme activity, and by 24 hours most of the activity had disappeared. However, even at these long periods of autolysis, a few neurons containing dense globular cytoplasmic diformazan deposits could always be detected.

Substitution of TPNH for DPNH as substrate revealed essentially similar mitochondrial swelling. The earliest changes, however, could be

seen at 20 minutes, and most of the enzyme activity was lost by 12 hours. With both substrates, the altered sites of activity could be visualized at shorter incubation times and following pre-incubation washing in acetone. In normal tissue the staining was contributed predominantly by the blue diformazan. However, after 2 hours of autolysis, a considerable amount was contributed by a red formazan. This was particularly true when TPNH was used as the substrate.

#### *Anoxic-Ischemic Encephalopathy*

Of the 61 rats subjected to the anoxic-ischemic procedure, 19 died during or after the period of anoxia. A right hemiparesis was evident in 22 of the 42 animals surviving. The distribution of the neuronal lesions was similar in extent and localization to those described by Levine<sup>9</sup> (Fig. 4).

Histologic lesions were noted in 11 of 17 animals allowed to survive past 24 hours and in 3 of 13 animals in the 12 to 18 hour survival group. No histologic lesions were present in 5 animals killed immediately after the anoxic period or in 7 animals killed 4 to 6 hours later.

Cytochemical studies of DPNH diaphorase activity revealed no abnormalities earlier than 12 hours. After 12 hours, in 1 of 2 animals revealing injury in sections stained for Nissl substance, scattered groups of neurons in the pyriform cortex appeared abnormal. This abnormality was again characterized by swelling of the mitochondria with increased diformazan deposition (Fig. 5). The intervening basophilic substance and neuropil became relatively unstained. Similarly abnormal neurons were noted in the cerebral cortex, corpus striatum, hippocampus and thalamus in 2 of 8 animals surviving 18 hours.

The cytochemical alterations were most marked in the 24 to 72 hour survival group. They were present in 14 of 17 rats, and were most frequent in the cerebral cortex (Fig. 6), corpus striatum and thalamus. Even at 72 hours, many neurons with swollen mitochondria were manifest. In addition, many neurons lost a good deal of their enzyme activity, and only a few swollen mitochondria remained. The surrounding neuropil showed a reduced over-all staining (Fig. 7) although many abnormally large discrete deposits of diformazan could be seen. These deposits were morphologically similar to those observed in the perikaryon. Many were as large as 3 to 5  $\mu$  in diameter. Occurring with greatest frequency on the side of the carotid ligation, occasional foci of injured neurons were present in the contralateral cerebral cortex.

The substitution of TPNH for DPNH as substrate revealed essentially similar findings although the over-all staining and morphologic detail was usually less satisfactory. However, swollen mitochondria as well as an ultimate loss of enzyme activity could be discerned. As in the

case of autolysis, much of the staining in the advanced lesions appeared to be contributed by the red formazan. The cytochemical abnormalities could be visualized at shorter incubation times and after pre-incubation washing in acetone.

#### *Anoxic Encephalopathy*

In the first groups, 9 of 14 animals survived acute exposure to 100 per cent nitrogen. Early acute cell alterations were noted only in Nissl stained sections in a few Purkinje cells of 1 in 4 animals of the 24 hour survival group. No cytochemical abnormalities were identified in these animals.

In the second group 9 of 16 animals survived repeated exposure to nitrogen. The conventionally stained paraffin sections and the cytochemical stains revealed no abnormalities.

In the third group, 7 of 11 animals survived a schedule of prolonged critical hypoxia. In 2 of 7 survivors, acute cell changes were noted in Nissl stained sections in the corpus striatum, cerebral cortex and Purkinje cells. In 4 animals, cytochemical abnormalities were noted with both DPNH and TPNH as substrates. These were characterized by swollen mitochondria which could be identified in neurons of the cerebral cortex and Purkinje cells. These abnormalities persisted in tissue incubated for short periods and in those washed in acetone prior to incubation (Fig. 8).

#### DISCUSSION

The demonstration of pathologically altered mitochondria by means of the diaphorase reactions has been reviewed by Pearse.<sup>2</sup> An increased staining intensity of these abnormal organelles is apparently related to increased accessibility of substrate and dye following injury.

In the present investigation detectable changes in neuronal mitochondria were observed in both autolysis and necrobiosis. In both events the alterations were similar and consisted of abnormal swelling and ultimately by loss of the mitochondria with disappearance of all sites of diaphorase activity. There was usually an associated reduction of staining intensity of the basophilic substance. A loss of diaphorase activity in the neuropil suggested that the neuroglia was quite sensitive to autolytic and anoxic-ischemic damage. In the anoxic-ischemic lesions, the Purkinje cells at no time revealed any abnormalities of diaphorase activity or in conventionally stained paraffin sections. Early alterations in lysosomes, however, were observed.<sup>1</sup> This suggested that the early lysosomal changes might have been reversible while the mitochondrial abnormalities were associated with irreversible neuronal damage. In the

anoxic lesions, the low incidence of neuronal damage made it difficult to evaluate the sequence of enzyme changes although cytochemically altered neurons could be seen. In comparably injured anoxic tissue, alterations in lysosomes were more frequent than those in mitochondria.

Diformazan is said to be insoluble in lipid.<sup>2</sup> On the other hand, the possibility of artifactual deposition of this pigment in lipoidal products of neuronal degeneration must be considered.<sup>10</sup> However, the persistence of these cytochemical abnormalities after short incubation times and following pre-incubation washing in acetone suggests that this is not the case.

Although the mitochondrial alterations occurred relatively late in the course of both the anoxic and the anoxic-ischemic lesions, it should be emphasized that injured neurons were often seen where they were inapparent with conventional stains. Therefore, cytochemical studies of both mitochondria and lysosomes contribute promising techniques in the investigation of neuronal necrobiosis.

#### SUMMARY

Alterations in neuronal mitochondria have been described in the course of postmortem autolysis and in both anoxic and anoxic-ischemic encephalopathy. The mitochondria were identified in formol-calcium fixed tissue by virtue of their diphosphopyridine and triphosphopyridine nucleotide diaphorase activity. Swelling of the mitochondria was noted during the early phases of both autolysis and necrobiosis. Loss of enzyme activity became prominent during the later phases. In some cases the earliest cytochemical lesions preceded those which could be detected by Nissl stains and by hematoxylin and eosin.

#### REFERENCES

1. BECKER, N. H., and BARRON, K. D. The cytochemistry of anoxic and anoxic-ischemic encephalopathy. I. Alterations in neuronal lysosomes identified by acid phosphatase activity. *Am. J. Path.*, 1961, 38, 161-176.
2. PEARSE, A. G. E. *Histochemistry, Theoretical and Applied*. Little, Brown & Co., Boston, 1959, pp. 536-586.
3. SHIMIZU, N., and MORIKAWA, N. Histochemical studies of succinic dehydrogenase of the brain of mice, rats, guinea pigs and rabbits. *J. Histochem.*, 1957, 5, 334-345.
4. FRIEDE, R. L. Histochemical investigations on succinic dehydrogenase in the central nervous system. I. The postnatal development of rat brain. II. Atlas of the medulla oblongata of the guinea pig. *J. Neurochem.*, 1959, 4, 101-123.
5. WOLFGRAM, F., and ROSE, A. S. The histochemical demonstration of dehydrogenases in neuroglia. *Exper. Cell Res.*, 1959, 17, 526-530.
6. POTANOS, J.; WOLF, A., and COWEN, D. Cytochemical localization of oxidative enzymes in human nerve cells and neuroglia. *J. Neuropath. & Exper. Neurol.*, 1959, 18, 627-635.

7. BECKER, N. H.; GOLDFISCHER, S.; SHIN, W., and NOVIKOFF, A. The localization of enzyme activities in rat brain. *J. Biophys. & Biochem. Cytol.* (In press)
8. SAMORAJSKI, T. The application of the diphosphopyridine nucleotide diaphorase methods in study of dorsal ganglia and spinal cord. *J. Neurochem.*, 1960, 5, 349-353.
9. LEVINE, S. Anoxic-ischemic encephalopathy in rats. *Am. J. Path.*, 1960, 36, 1-17.
10. NOVIKOFF, A. B. Enzyme cytochemistry; pitfalls in the current use of tetrazolium techniques. (Abstract) *J. Histochem.*, 1959, 7, 301-302.

The technical assistance of Jonathan Sparks, HM1, USN, is acknowledged. The photographic prints were prepared by Mr. J. Walker.

[ Illustrations follow ]

## LEGENDS FOR FIGURES

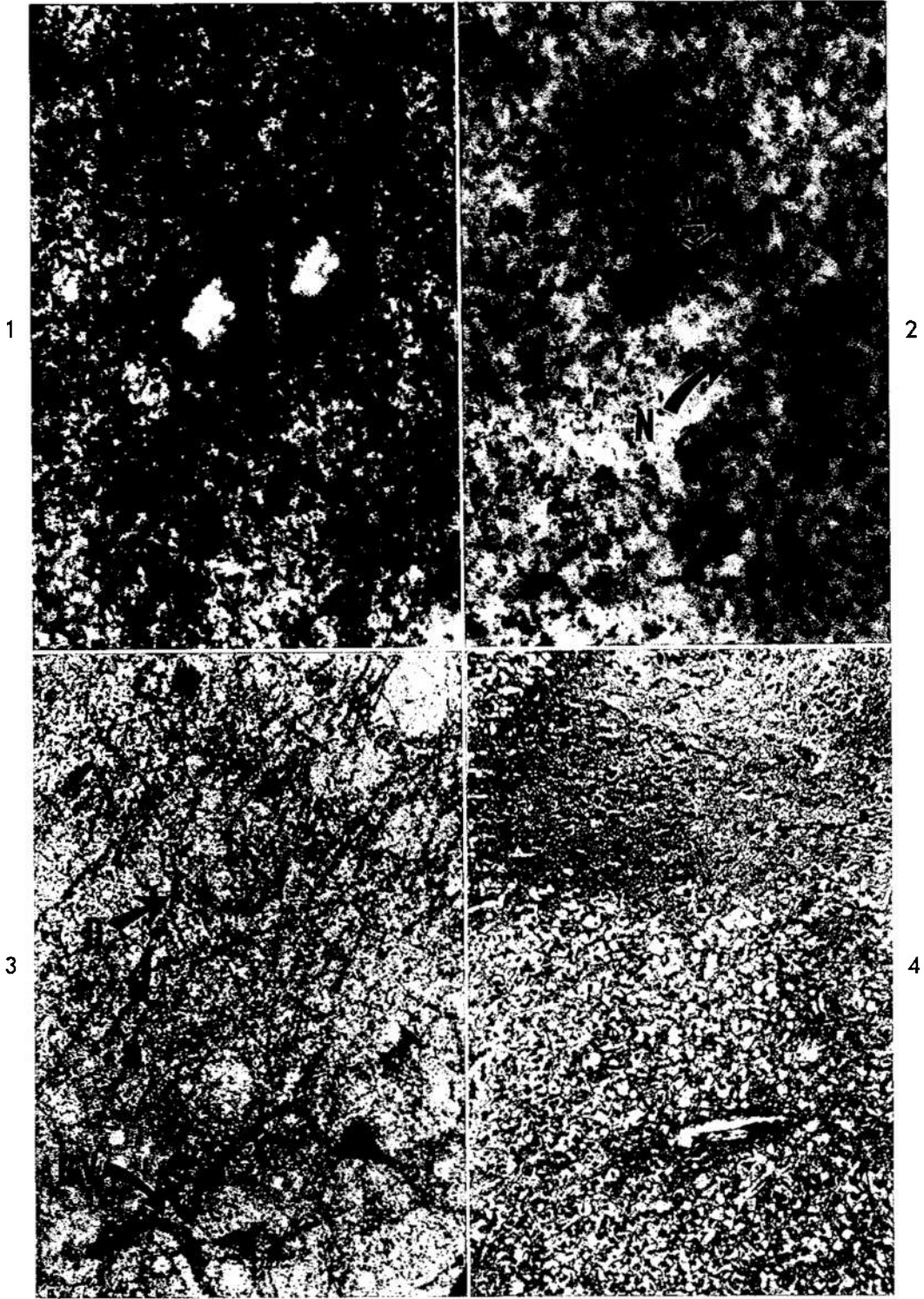
In the preparation of specimens for these illustrations, incubation times were 40 minutes for DPNH and 60 minutes for TPNH.

FIG. 1. Normal neocortex. There is staining of the mitochondria (M) and diffuse staining of the basophilic substance of pyramidal cells. DPNH stain.  $\times 800$ .

FIG. 2. Neocortex. Autolysis, 30 minutes. Considerable swelling and clumping of the mitochondria (M) are evident. Neurons (N) exhibit loss of enzyme activity. DPNH stain.  $\times 700$ .

FIG. 3. Neocortex. Autolysis, 8 hours. Mitochondria are swollen and clumped in most of the neurons. The reduced staining of the neuropil contributes to the prominent appearance of dendritic processes (D) and blood vessels (BV). DPNH stain.  $\times 300$ .

FIG. 4. Neocortex. Anoxic-ischemic lesion, 24 hours. There is shrinkage and loss of neurons with spongy degeneration of the neuropil. Thionine stain.  $\times 100$ .



- FIG. 5. Pyriform cortex. Anoxic-ischemic lesion, 12 hours. Note neurons with swollen mitochondria (M). DPNH stain.  $\times 600$ .
- FIG. 6. Neocortex. Anoxic-ischemic lesion, 48 hours. Neuronal mitochondria are swollen. There is decreased staining of the basophilic substance and neuropil. DPNH stain.  $\times 600$ .
- FIG. 7. Neocortex. Anoxic-ischemic lesion, 24 hours. At low magnification the loss of staining in the neuropil is evident in this area of zonal necrosis. DPNH stain.  $\times 100$ .
- FIG. 8. Neocortex. Prolonged critical hypoxia, 4 days. Due to pre-incubation washing in acetone, there is some blurring of morphologic detail. Nevertheless, neurons with swollen mitochondria are easily identified. TPNH stain.  $\times 700$ .

