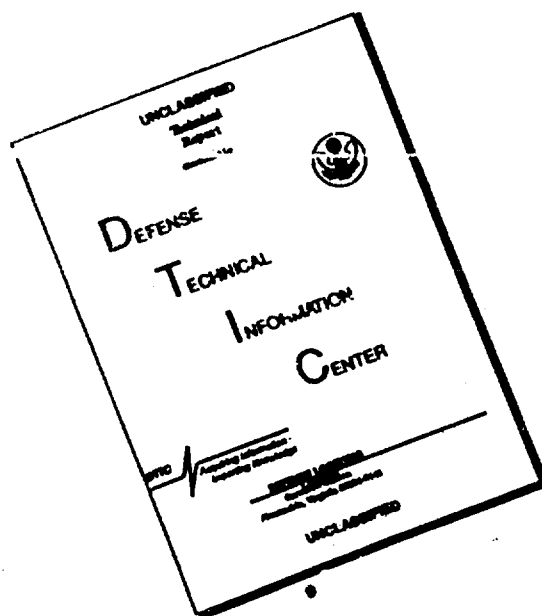


DISCLAIMER NOTICE



THIS DOCUMENT IS BEST QUALITY AVAILABLE. THE COPY FURNISHED TO DTIC CONTAINED A SIGNIFICANT NUMBER OF PAGES WHICH DO NOT REPRODUCE LEGIBLY.

#2323

Vrachebnoe Delo, No.12:95-101, 1962

Pathomorphological Changes in Rabbit Organs Actuated by Botulism
Microbes and Type A and E Botulinal Toxins

By: prof. E.A. USPENSKII (ODESSA)

Faculty of Pathological Anatomy (director: prof. E.A. USPENSKII),
State Medical Institute, ODESSA

(Translated by: Edward Lachowicz, Maryland, Medical-Legal Foundation, Inc., 700 Fleet Street, Baltimore, Maryland, 21202)

It has been established that, in natural sources and in the soil, the encountered spores of *Cl. botulinum* are of the A, B, C and D types, as well as the E type; also, that the latter variety of the causative agent is predominant in certain countries such as: USA, Denmark Sweden, Japan and the USSR. This has also been confirmed by the data on epidemiology (L.A. ZUBKO, 1960).

We know from the bibliography that, in natural conditions of botulinal infection, the organs of man and animals are invaded by microbes with a certain quantity of toxin. Small doses of toxin weaken ("sensitize") the organism, consequently conditions develop in which botulinal bacillus is able ^{to} multiply and to produce new quantities of toxin (S.M. MINERVIN and KOTLYAREVSKAYA, 1937).

The concept of the action of the botulism microbic group had been considerably widened following the isolation of pure toxins of that group. S.M. MINERVIN et al. discovered that botulinal toxins of the A, B, C and E types paralyse the phagocytic function of

Uspenskiy

leukocytes. Later, YU.I. DONETS noticed in coeloms the same characteristics of the toxins with respect to the reticuloendothelial system. It has been determined by way of experimental tests that the action of the B toxin is much weaker and of shorter duration, if compared with the toxin type A (V.V. KHATUNTSEV, 1960). The potential effects of the A and B toxins on the nervous system were studied in complicated physiological experiments, which proved that, simultaneously with the paralysis of the cholinergic nerves, a profound disorder in the synergy between the adrenergic and cholinergic processes takes place during the intoxication with botulism (V.V. MIKHAILOV, 1956).

Following the discovery of E microbe and its toxin (E.D. KUSHNIR, 1937, 1960), along with other investigations, studies were also conducted which involved white mice and guinea pigs in testing the effects of pure toxin and the effects of the microbe + toxin of this type of botulism. The obtained data permitted us to determine that most extensive injuries in the organs and in the system were found in all experimental animals infected with these microbes (culture) (L.A. ZUBKO, 1960).

Such many-sided research, involving individual biological properties of various types of the causative agents of botulism, along with a study of the action of pure toxin and of the microbes + toxin, has so far never been duplicated in the pathomorphological investigations. At the same time, it is important, no doubt, to know in such investigations the course of morphological reactions in tissues and in organs. In a plan of this kind, the examination

of morphological reactions peculiar to botulism has to be considered also for this reason that, on the one hand, there exists a sufficient number of slip-ups about the causative agent's histotrophism to the elements of neural tissues (I.I. ZILBERG, N.A. GOVSEEV, 1937) and, on the other hand, about botulism as a disease of the toxinfectious nature, which inflicts injuries to various organs and to the system.

Our task included an explanation of the extent of characteristic morphological changes that occur in the organism of animals as a result of poisoning with pure toxins and due to infection with microbes + toxin of *Cl. botulinum* of the A and E types. In addition, we strived as much as possible to determine a prevalent degree of the characteristic morphological changes in the organism of animals.

We run tests at the laboratory of the Microbiological Department, Medical Institute, Odessa, supervised by prof. S.M. MINERVIN. The experiments were performed on 20 young male rabbits. The rabbits were selected in pairs, each animal weighed 2 kg. In order to exclude prior to the experiment a possibility of infectious or alimentary diseases in experimental animals, the rabbits remained under observation for one month and, at the same time, they received a highcaloric food. The animals were sufficiently beefed by the end of this period, as their weight increased by 250 to 300 gm, and they had no symptoms of any disease. We infected one rabbit of each pair with botulinal microbes and the toxin (MT), while the other rabbit received pure toxin (T). The first 10 animals received botulinal toxin type A (first group) and the other 10 rabbits received type B toxin (second group). The infection and the poisoning

of most animals were accomplished with a single enteral administration, except for 2 rabbits in the first group and 4 in the second group, which received the microbes (MT) and pure toxin (T) also with a single administration, but subcutaneously into the anterior abdominal wall. The doses were computed in D₁₀₀ and their titer was determined on white mice. In per volume ratio this implied one cubic centimeter of diluted toxin and the same dose was used for diluted microbic culture.

The clinical symptoms of botulism developed in animals of both groups to a lesser or a higher degree after 30 hours following the administration of microbes (MT) and pure toxin (T), although the symptoms were much clearer and more widespread in animals of the second group. The effects of the microbes and toxin (MT) of the E type were more intense and caused respiratory disorders, paresis of extremities, weakening of the trunk muscles and salivation in all animals of this experimental group. Toward the 5th day we observed in rabbits of both groups a decreased weight, on the average by 150 to 200 gm. After 30 hours following the administration of microbes and toxin, two animals died in each group due to air embolism. Four rabbits died on the 5th day, one of the first group and three of the second group, and concurrently with these animals died their pairs poisoned with pure toxin. On the 12th day died two pairs of the first group and one pair of the second group. The last pair of the first group of animals died on the 23d day following the beginning of the experiment, during which time we observed in one rabbit infected with microbes (MT) in addition to the paresis

of limbs, also severe respiratory disorders and adynamia at the time, when the other animal of this pair showed no symptoms of any disease.

The autopsy performed on the first group of animals 30 hours after the beginning of the experiment showed no observable changes in the conditions of the organs and tissues of rabbits infected with microbes and toxin (MT), and the same applied to the animals poisoned with pure toxin (T). A considerable hyperemia was visible in pia mater encephali and in pia mater spinalis, also in the mucous membrane of the respiratory tract and in the gastrointestinal tract with multiple small hemorrhages there. The liver, kidneys, lungs and skeletal muscles were plethoric and succulent. Changes of this kind prevailed on subsequent days only in the organs of animals, which were infected with microbes (MT). We also noticed hemodynamic disorders in the organs of animals of the second group. Even during the first 30 hours of the experiments, we detected microscopic traces of the parenchymatous dystrophy in addition to vascular disorders in the kidneys and liver of rabbits poisoned with the toxin (T). The discussed changes in the organs of animals infected with microbes (MT) were observed on days much later. Yet, the hemodynamic disorders disappeared by the 12th day of the experiment. By this time, the lungs, liver and kidneys retained no excessive succulence, nor any moderate hyperemia.

We used in the histological research: parts of the brain of the spinal cord with ganglions intervertebrale; parts of the femoral nerve and of the solar ganglion; parts of the lungs; of the gastro-

intestinal tract; of liver, spleen, kidney and heart; muscles of the dorsum and shin, and the thyroid and adrenal glands. For staining the preparations we used van GIZON'S hematoxylin-eosin according to the method of NISSL, and we also used HERIHEIMER'S scarlet red.

We mentioned in our macroscopic report that rabbits of the first group showed an increased succulence in tissues and in organs after 30 hours following the beginning of experiments. At the time of the histological investigation, this condition appeared like a separation of fibers to various degrees in the structures of connective tissues, accompanied by spacious fissures. Similar changes were detected in pia mater encephali and in the stroma of its vascular plexuses, with the presence of the dropsical dystrophy in the epithelial villi (figure 1). The separation of fibers and the swelling

Figure 1 - Nuclei of the epithelial villi of the vascular plexus with diffused contours and large vacuoles in the protoplasm. Hematoxylin-eosin. Ocular 8, lens 40.

of the elements of connective tissues could be detected in the intermuscular cellular tissues of the shin and in dorsal muscles,

also in the trabeculae of the liver, in the submucosa layer of the intestines, in the intervertebral capsules and in those of the sympathetic ganglions, in the epineural and perineural membranes of the femoral nerve, in the stroma of the spleen and in the cerebral layer of the suprarenal glands. Separate follicles in the thyroid gland were observed stretched, with flattened epithelial cells and with a pale-colored colloid. Frequently, with the discussed changes with also detected diapedetic hemorrhages in the serous tegmina and in the parenchyma of the organs.

On the fifth day of the experiments, the histological changes in the organs of animals assumed already considerable diversities on account of the effects of the toxin and due to microbic factor. The organs of animals infected with microbes (MT) manifested more changes and this condition expressed itself in the increased appearance of the symptoms of dropsical dystrophy, which encroached on ependymal cells of the lateral and third ventricles, as well as on the tissues of white matter in the brain, also in the appearance of a distinct swelling of the nerve cells in part of the brain stem and in the development of hydromyelia (figure 2).

We observed in the lungs the capillaries with a swollen and basophil-stained endothelium; alveoli were filled with a pale-stained homogenous mass in which single leukocytes were as numerous, as the cells of the alveolar epithelium. In some of the pulmonary veins we noticed a dilated lumen and recently intermixed thrombi (figure 3).

The epithelium of the convoluted renal canaliculi (sic!) showed a condition of incipient parenchymatous dystrophy. The capillary

TEXT NOT REPRODUCIBLE

nots of the brain, of kidneys and liver were partly dilated, and one could often observe in the surrounding tissues the emergence

Figure 2 - Hydromyelia in the thoracic cord. Staining according to NISSL. Ocular 8, lens 20.

Figure 3 - Pulmonary vein. Parietal thrombus recently intermixed. Hematoxylin-eosin. Ocular 8, lens 20.

of erythrocytes. The morphological changes in the organs of animals poisoned with the toxin were less developed close to the 12th day.

However, following the infection with microbes, the changes in tissues (connective tissues) and the intracellular hydropic changes remained. They were detected in neural cells of the brain stem, in intervertebral ganglions, as well as in the cells of the solar ganglion knots, alternating with the appearance of the hyperchromatism and a distinct swelling of the cellular body.

A slight cellular proliferation was noticed in the cerebral hemispheres around individual vessels of the subcortical white substance. The cells in the central part of the liver lobules contained small lipoidal inclusions. Arteries of the spleen were dilated and filled with hemolyzed erythrocytes.

Changes of similar kind were also noticed in organs of a rabbit, which was infected with microbes (MT) and died on the 23rd day; at the same time, no morphological changes could be detected in the organs of the other rabbit of this pair.

The pathomorphological changes revealed many peculiarities in a group of animals sick either from the toxin (T), or due to the microbes (MT) of the type E botulism. After 30 hours of the toxin's action, considerable dystrophy changes appeared in addition to the hemodynamic disorders; they reached, e.g. in the convoluted renal canaliculi, the stage of necrobiosis and necrosis (figure 4).

Although disorders in the metabolism of water were not encountered to such an extent as in the case of poisoning with the toxin of the type A botulism, yet we also detected here a peculiar widespread swelling in the elements of connective tissues. This was noticed in interstitial tissues of the lungs, in the myocardium

(figure 5), liver, submucosa layer of the small intestine, stroma of the thyroid gland, in the capsules of the suprarenal glands, in

Figure 4 - Epithelial necrosis in convoluted renal canaliculi with a serous impregnation of BOWMAN'S capsules. Hematoxylin-eosin. Ocular 15, lens 7.

Figure 5 - Swelling of intermediate tissues in myocardium. Hematoxylin-eosin. Ocular 10, lens 20.

spleen and in fiber structures of the pia mater encephali and pia mater spinalis.

Apparently, the indicated changes were unrelated to the per-

sistent processes which follow the action of the toxin, because they were considerably less developed on the fifth experimental day. However, in the organs of animals infected with the microbes (MT), the appeared swelling in the intermediate connective tissues was more significant qualitatively and quantitatively; it distinguished itself by duration lasting from the first 30-hour experimental period to 5 and even 12 days.

This process could be observed in the lungs as early as during the 30-hour experimental period; it appeared as a swelling of adventitial and periadventitial tissues around the dilated arteries of the muscular type (figure 6). Frequently, the area of the swelling was extensive and it often encroached on parts of the vessel tunica muscularis (indicated by arrow on figure 6); it stained faintly with hematoxylin, but well with toluidine blue. The swelling strongly magnified in some parts appeared like a homogeneous mass, while in other parts of the preparation it had a lumpy appearance. In addition to the changes already mentioned, we noticed, after 5 to 12-day experimental period, a parenchymatous and fatty dystrophy in the liver and kidneys. We also observed in two rabbits a serous impregnation of the liver lobules with the separation of ties from the capillary network, and a developed cellular reaction in the stroma (figure 7).

As we know, one can frequently detect, even in healthy rabbits, histiocytic congestions in the liver stroma, but, in the case of botulism, in our experiments they appeared in considerably increased

numbers and more diversified. A serous impregnation of the liver ties,

Figure 6 - Lungs. Swelling of intermediate tissues spread around dilated artery. Hematoxylin-eosin. Ocular 10, lens 8.

Figure 7 - Serous hepatitis. Hematoxylin-eosin. Ocular 10, lens 40. combined with a similarly expressed cellular reaction, suggests to us to regard this process as a serous hepatitis.

The cellular proliferation in other organs, also in the organs

of animals of the first group, was hardly noticeable.

The discussed data of the pathomorphological investigation showed under experimental conditions a diversity in activities of the causative agents of botulism of the A and E types. A separate administration of the toxin (T) and microbes (MT) to rabbits conditioned a development of various pathological processes in the organs and tissues of animals. This diversity revealed itself in the morphological peculiarities of processes, as well as in a stage of their manifestations.

The most interesting morphological changes followed the action of the toxin (T) and the microbes (MT) of the type E botulism. The duration and the prevalence of the process appeared characteristic of microbic infections. Among the basic manifestations of pathological processes we noticed hemodynamic disorders, dystrophic and necrotic changes, peculiar swellings in intermediate tissues and slightly developed cellular proliferations.

The enumerated morphological changes have some similarity with the pathology of botulism in man. Thus, E.A. KURAEV, describing in detail the anatomical pathology of this disease, stressed the spreading of changes in the vascular system and the early destructive disorders in connective tissues, along with a slight cellular reaction. R.M. FISHMAN, examining fatal cases of botulism, noticed in the first two days, besides the changes in the vascular system, also a necrosis of the epithelium in canaliculi of the kidneys. S.A. SNEGUROVSKII mentioned a frequent appearance of dystrophic changes in the liver and occurrences of serous hepatitis. A.P. AVTSIN,

L.M. POPOVA and I.E. BONDAREVSKAYA published their histopathologic studies of the organs of a victim of botulism, who died on the 6th day after the infection. These authors also refer to the first category of changes: injuries in the vascular wall in the form of a focal swelling of endothelium, its necrobiosis and, sometimes, the homogenation of the vascular wall in the celom. They discovered the quoted changes in a section of the brain stem, in peripheral parts of the nervous system and in other internal organs.

Regardless of the numerous investigations of microbiologists, the question about the pathogenesis of botulism is up to the present time left open (K.I. MATVEEV, 1959). Many theories have been advanced which describe the causative agent of the disease as a destructive antimetabolite of the fermentative kind that is capable to spread by hematogenic means. It follows hence that the circulatory system is one of the first involved in the pathological process which conditions the disease even at its early stage in a patient, and by way of many hemodynamic disorders in experiments, by dystrophic and necrotic changes in the organs and in tissues of various systems, including the nervous system. Judging from the data obtained in a physiological research (V.V. MIKHAILOV, 1956), the discussed hemodynamic disorders originate, according to all probabilities, from a disturbance in the synergism of the vascular innervation.

However, the prevalence of dystrophic and necrotic processes in the organism of rabbits tends to provide a basis to confirm the statements of microbiologists about the toxoinfectious genesis of this disease.

Conclusions

1. The morphological changes, which appeared in the organs and tissues of rabbits due to the action of microbes and pure toxin of the A and E types of botulism, were diverse.

2. The effect of microbes and of pure toxin of the E type causes the most significant and widespread morphological changes in the organs of many systems in experimental animals. These morphological changes, as such, are characteristic indications of disturbances in the metabolic processes, including those of necrosis and of the peculiar swellings in the connective-tissue formations. The cellular reaction was slightly developed in the presence of both types of the causative agents.

3. The duration of the pathogenic effects of pure toxins of botulism is considerably shorter (up to 5 days) than the effects of microbes (up to 22 days).

Literature Cited

ABROSIMOV, V.N. Arkhiv Patologii, 1956, No.1, p.86. - AVTSIN, A.P., POPOVA, L.M., BONDAREVSKAYA, K.E. Collection of reports in commemoration of the 70th anniversary of N.N. ANICHKOV, academician. Medgiz, Leningrad, 1957. - BATURENKO, T.I. Botulism. Dnepropetrovsk, 1937. - ZUBKO, L.A. Collection of reports in commemoration of the 70th anniversary of prof. S.M. MINERVIN, Odessa, 1960. - KUSHNIR, E.D. Botulism. Dnepropetrovsk, 1937. - KUSHNIR, E.D. Collection of reports in commemoration of the 70th anniversary of prof. S.M. MINERVIN, Odessa, 1960. - MATVEEV, K.I. Botulism. Medgiz. Moscow, 1959.

MINERVIN, S.M., KOTLYAHEVSKAYA, E.N. Botulism. Dnepropetrovsk, 1937. -
MIKHAILOV, V.V. Arkhiv Patol., 1956, No.4, p.29. - MIKHAILOV, V.V.
Byull. Eksp. Biol. i Medits., 1956, No.1, p.42. - SAVIN, V.R.
Collection of reports in commemoration of the 70th anniversary of
prof. S.M. MINERVIN, Odessa, 1960. - KHATUNTSEV, V.V. Collection of
reports in commemoration of the 70th anniversary of prof. S.M. MI-
NERVIN, Odessa, 1960. -

Summary (copied)

Experiments were conducted on 20 rabbits given pure toxin
and infected with microbes + botulism toxins of A and E type.
Pathomorphological studies showed that the actions of these patho-
genic factors are different for the one and the other types of
botulism pathogens. Characteristic of the A type botulism are
hemodynamic disorders of the endothelium with formation of perinural
venous thrombi, metabolic disorders with the prevalence of hydropic
dystrophy. The action of the E type botulism pathogene causes deep
changes in the parenchyma including necrosis and also caused a
peculiar swelling in the connective tissue. The cellular reaction
was slightly expressed in both types of pathogens.