

UNCLASSIFIED

AD-740 987

Security Classification

DOCUMENT CONTROL DATA - R & D

(Security classification of title, body of abstract and indexing annotation must be entered when the overall report is classified)

1. ORIGINATING ACTIVITY (Corporate author) USAF School of Aerospace Medicine Aerospace Medical Division (AFSC) Brooks AFB, Texas 78235		2a. REPORT SECURITY CLASSIFICATION UNCLASSIFIED	
		2b. GROUP	
3. REPORT TITLE AEROMEDICAL CONSULTATION SERVICE CASE REPORT: EVALUATION OF ASYMPTOMATIC FLYING PERSONNEL WITH INTERMITTENT SUPRAVENTRICULAR ARRHYTHMIAS			
4. DESCRIPTIVE NOTES (Type of report and inclusive dates)			
5. AUTHOR(S) (First name, middle initial, last name) John E. Douglas, Maj, USAF, MC			
6. REPORT DATE August 1971		7a. TOTAL NO. OF PAGES 8	7b. NO. OF REFS 4
8a. CONTRACT OR GRANT NO. None		9a. ORIGINATOR'S REPORT NUMBER(S) SAM-TR-71-416	
b. PROJECT NO. 7755		9b. OTHER REPORT NO(S) (Any other numbers that may be associated with this report)	
c. Task No. 775501			
d. Work Unit No. 004			
10. DISTRIBUTION STATEMENT Approved for public release; distribution unlimited.			
11. SUPPLEMENTARY NOTES Aerosp. Med. 43(3):323-330 (1972)		12. SPONSORING MILITARY ACTIVITY USAF School of Aerospace Medicine Aerospace Medical Division (AFSC) Brooks AFB, Texas 78235	
13. ABSTRACT Two patients with wandering cardiac pacemakers are discussed to illustrate techniques for deciphering the pathophysiology and clinical significance of such intermittent supraventricular arrhythmias.			

Reproduced by
NATIONAL TECHNICAL
INFORMATION SERVICE
Springfield, Va. 22151

10

UNCLASSIFIED

Security Classification

14. KEY WORDS	LINK A		LINK B		LINK C	
	ROLE	WT	ROLE	WT	ROLE	WT
Supraventricular arrhythmias Electrocardiographic dysrhythmia						

UNCLASSIFIED

Security Classification

AD 740987

SAM-TR-71-116

DDC
RECEIVED
MAY 4 1972
B

Aeromedical Consultation Service Case Report: Evaluation of Asymptomatic Flying Personnel With Intermittent Supra- ventricular Arrhythmias

JOHN E. DOUGLAS

Internal Medicine Branch, USAF School of Aerospace Medicine, Brooks Air Force Base, Texas 78235

DOUGLAS, J. E. *Aeromedical Consultation Service Case Report: Evaluation of Asymptomatic Flying Personnel With Intermittent Supraventricular Arrhythmias.* *Aerospace Med.* 43(3):323-330, 1972.

Two patients with wandering cardiac pacemakers are discussed to illustrate techniques for deciphering the pathophysiology and clinical significance of such intermittent supraventricular arrhythmias.

THE CARDIAC RHYTHM sampling obtained during a routine electrocardiogram represents less than 0.1% of that patient's rhythm on that specific day. This sampling problem has plagued clinicians for decades, particularly when dealing with intermittent rather than sustained arrhythmias. This has led to the logical solution of continuous monitoring of the electrocardiogram with either immediate display or delayed printout. The availability of such technical equipment is limited. Therefore, a physician, when confronted by a patient with either an isolated rhythm disturbance during a routine electrocardiogram or a history which suggests a possible rhythm disturbance, needs other diagnostic tools. It is the purpose of this paper to outline several relatively simple procedures which may be conducted in a physician's office to reproduce and/or elucidate the mechanisms of a patient's electrocardiographic dysrhythmia. Two case histories of patients evaluated in the Aeromedical Consultation Service of the USAF School of Aerospace Medicine because of supraventricular dysrhythmias will serve as illustrative examples.

A 45-year-old pilot was referred to the USAF School of Aerospace Medicine for evaluation of cardiac arrhythmia. Five weeks previously he had noted the onset of "skipping heart beats." These occurred one to five times a minute while he was in the recumbent position, would persist for several hours, and were associated with a pressure sensation in the suprasternal notch. Jogging in place would occasionally eliminate them. Concern about the significance of his symptoms prompted medical evaluation. There was no history of rheumatic fever, diphtheria, parasitic infection, heavy metal exposure, or chest trauma. At age 30 he had had a three-day episode of right chest pleurisy which was not associated with hemoptysis. He had always been physically active and never noted chest pain or discomfort during his athletic activities. The remainder of his history was noncontributory.

Physical examination revealed the patient to be well-developed, moderately obese, and large-boned. His pulse was regular at 70 beats per minute, blood pressure 150/90, right arm recumbent. Peripheral pulses in all extremities were normal as were his Allen tests. There was no clubbing, cyanosis nor edema of the extremities. The thyroid was palpable, of normal size and free of nodules. The diaphragms moved well bilaterally and the lungs were clear to percussion and auscultation, there specifically being no friction rub over the right chest. The cardiac point of maximum impulse was 10 cm. to the left of the midsternal line in the fifth intercostal space. There were no palpable thrills. The first and second heart sounds were physiologically split. There was a midsystolic sound heard best over the point of maximum impulse during mid-inspiration, and loudest with the patient in the knee-chest position. There were no diastolic sounds, opening snaps, or gallops. The remainder of his physical examination was unremarkable.

Routine laboratory studies, including hemoglobin and differential counts, fasting blood sugar, serum cholesterol, total protein, blood urea nitrogen, serum uric acid, urinalysis, pulmonary function studies and abdominal roentgenograms were all normal. Routine P-A and lateral chest roentgenograms demonstrated a left apical and a left hilar calcified lesion thought to represent an old Golm complex present also five years before. His resting electrocardiogram (Figure 1) demonstrated an abnormal P vector of approximately -90 degrees. Further electrocardiographic studies were performed employing Lewis and Wilson leads to accentuate P-waves. While the patient was in the resting recumbent po-

Further reproduction is authorized to satisfy the needs of the U.S. Government.

EVALUATION OF PERSONNEL WITH ARRHYTHMIAS—DOUGLAS

sition, his cardiac pacemaker site shifted from a normal sinus focus, at a rate of 84 per minute, to an intermittent coronary sinus or low atrial rhythm, at a rate of 68 per minute. The P-R interval under either case was 0.14 second. With right carotid massage the slower atrial focus became the dominant pacemaker at a rate of approximately 54. Within 30 sec. of discontinuing right carotid massage the patient reverted to a normal sinus pacemaker. During phase II of a standard 10-sec. Valsalva maneuver, the atrial bradycardia reverted to a normal sinus rhythm which was

again at a rate of approximately 80 per minute. Simple exercise such as 3-sec. hand-squeezing promoted the appearance of the more normal sinus rhythm (Figure 2) as did active leg-raising to 45 degrees for 6 sec. (Figure 3). Passive leg-raising to the same height and for the same duration, however, had no effect on the pacemaker focus, the slower atrial focus persisting unmodified. Following 300 μ g. of sublingual nitroglycerin, the patient's cardiac pacemaker focus reverted from the slower atrial rhythm to the sinus focus at a rate of approximately 95 beats per minute.

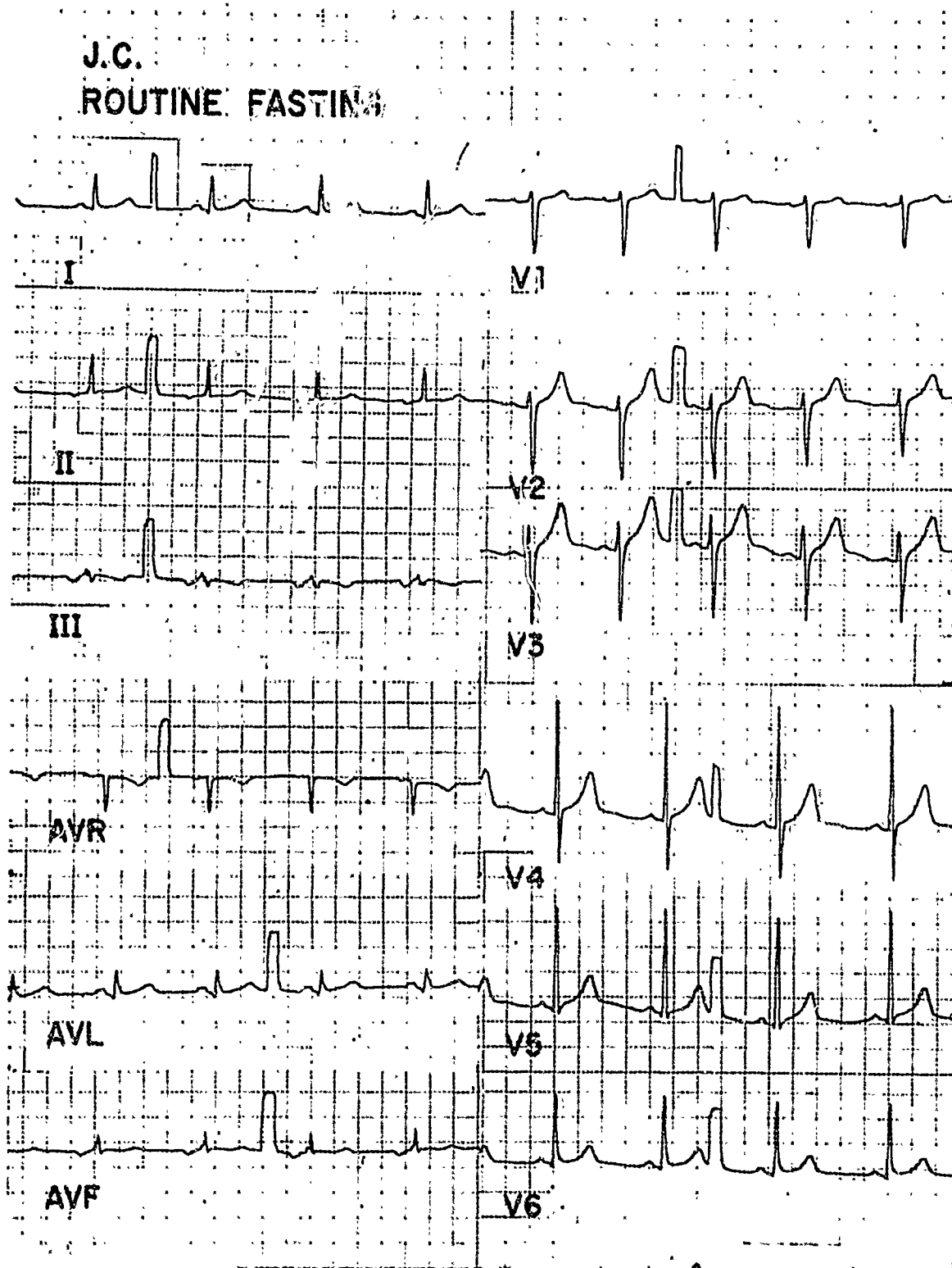


Fig. 1. Baseline electrocardiogram for Patient No. 1. Note particularly the P-vector in leads II, III, and aVF.

This rhythm persisted despite alternate right or left carotid massage.

COMMENTS

One could postulate that the patient's normal vagal tone tended to slow his sinus node so that some more excitable atrial focus, probably in the region of the coronary sinus along the right atrial wall, emerged as dominant pacemaker. Inasmuch as the aberrant pacemaker complex had a P-R interval greater than 0.12 sec., a nonendocardial site would be the most likely choice.¹ Thus, increased vagal activity to the S-A node, as with

carotid massage, produced or promulgated the low atrial focus. Stimuli decreasing vagal tone to the sinus node promoting sinus tachycardia through peripheral vasal dilatation, such as with sublingual nitroglycerin, allowed the normal sinus pacemaker to assume a more rapid rate and overdrive the lower atrial focus.

There did not appear to be a pacemaker focus shift on the basis of altered venous return. If this had been the case, passive leg-raising should have promoted the same change in pacemaker focus that active leg-raising produced. The rate of passive leg-raising was not sufficient to cause an abrupt augmentation of venous return

**J.C.
RESPONSE TO ISOMETRIC EXERCISE**

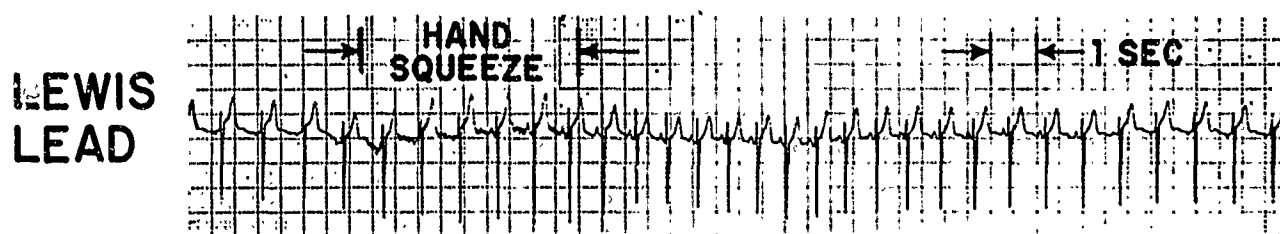


Fig. 2. Lewis Lead electrocardiogram of Patient No. 1 during 4-sec. isometric hand-squeezing exercise and recovery. Note that the fourth P-wave after the onset of exercise is upright and re-

mains so for approximately 13 sec. and then returns to the pre-exercise configuration.

**J.C.
PASSIVE & ACTIVE LEG RAISING**

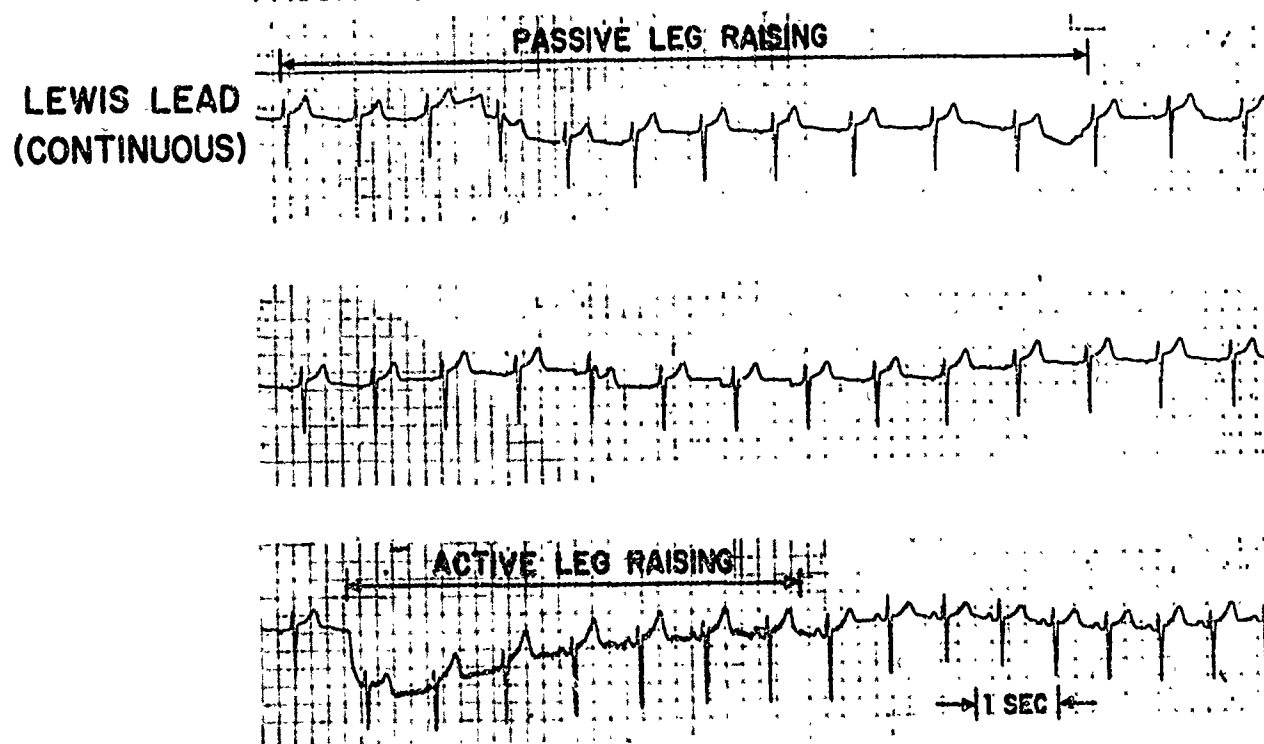


Fig. 3. Lewis Lead electrocardiogram of Patient No. 1 during passive and active leg-raising while in the recumbent position. Note that passive leg-raising does not alter the pacemaker site, although it does lead to a slight acceleration of the ectopic pacer.

maker. Active leg-raising, which is a mild form of exercise, produces a shift in pacemaker site and an acceleration of the heart rate similar to that illustrated in Figure 2.

and thereby an acute atrial distention. Such a maneuver might have elicited the so-called Bezold-Jarisch reflex or reflex bradycardia secondary to acute atrial distention.²

Inasmuch as patient J.C. was able to accelerate his cardiac rate by a normal sinus mechanism when stimu-

lated to do so by exercise, peripheral vasodilatation, or vagal inhibition, and because his atrial escape beats appeared only during a relative sinus bradycardia, his dysrhythmias were considered to be normal variants, requiring no restriction in physical activity.

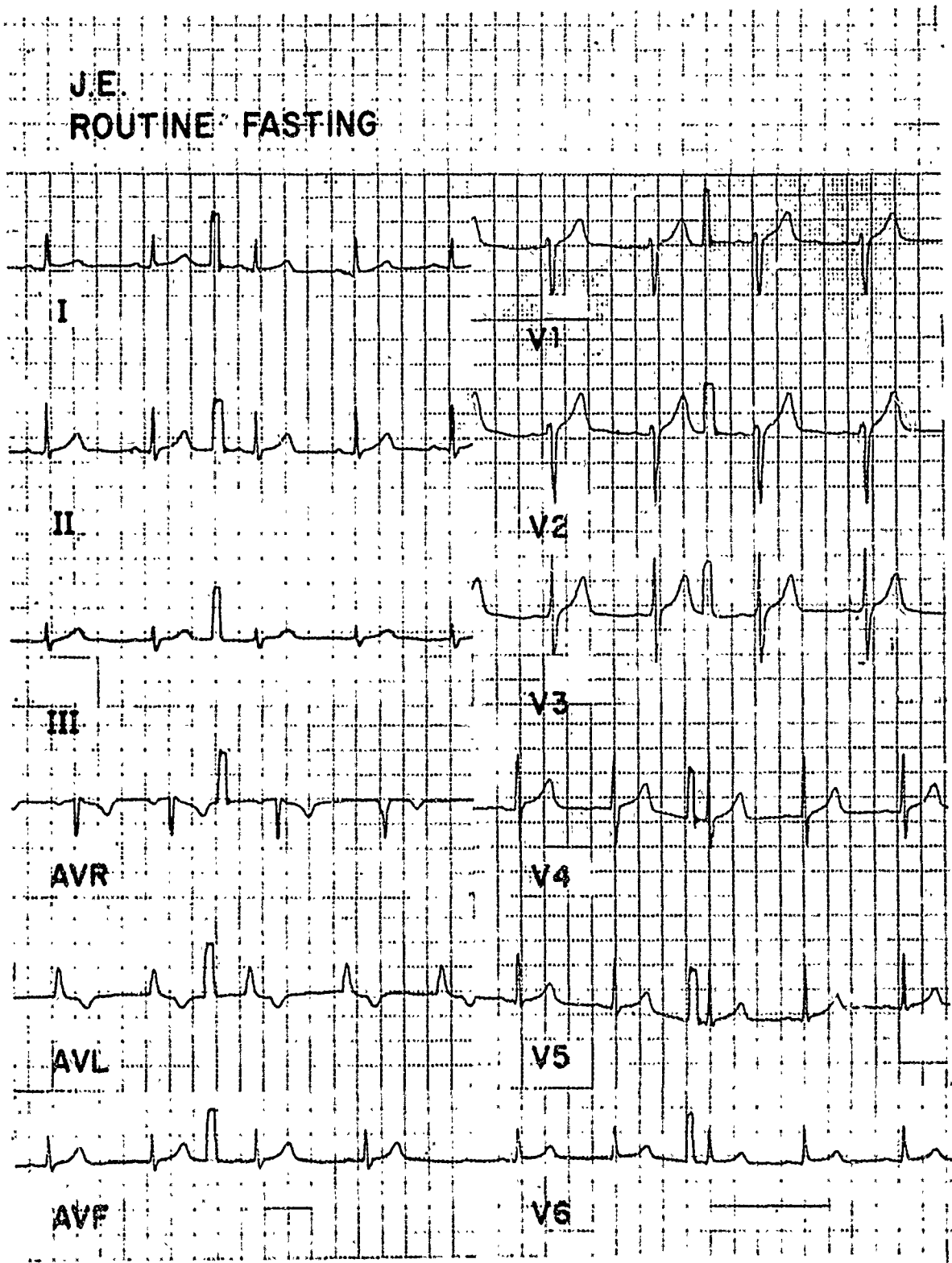


Fig. 4. Baseline electrocardiogram of Patient No. 2. Note the absence of P-waves in lead aVL, and the last complex in aVR.

In these same segments the QRS is deformed. See text for further discussion.

Case No. 2: J.E.

This 36-year-old pilot was referred for evaluation because an annual electrocardiogram was interpreted as showing A-V dissociation with A-V block and abnormal intra-ventricular conduction. At the age of eight the patient had undergone a tonsillectomy and adenoidectomy under general anesthesia. At the age of 18 he had had German measles and been hospitalized at his college dispensary for two nights. That same year he had undergone a herniorrhaphy under spinal anesthesia without complication. At the age of 24 years he had been hospitalized with severe fever and malaise both of which had responded to penicillin therapy within two or three days. Because of the possibility of infectious mononucleosis, however, he had been held in the dispensary for a total of 30 days and had been told to limit his activities for approximately four months thereafter. At no time during his illness was he jaundiced. Except for these infectious illnesses and surgical procedures, the patient recalled no history of other infectious diseases or intercurrent medical problems. He specifically had no history of diphtheria, rheumatic fever, scarlet fever, Rocky Mountain spotted fever, or venereal disease. He had had no excessive exposure to heavy metals, had not received multiple transfusions or extradietary iron therapy, knew of no allergies to food or drugs, and though stationed in South Viet Nam for 10½ months, knew of no possible exposure to parasitic infections. Although he may have been exposed to insect bites, he did not recall any cutaneous sores or pustules which might have been construed as insect bites.

Physical examination revealed him to be well-developed, with an irregular pulse of 80 beats per minute and a blood pressure of 110/70, right arm seated. There were no xanthemas, abnormalities in skin elasticity nor evidence of cutaneous infiltrations. Head examination was unremarkable. Specifically there was no Kayser-Fleischer ring. The examination of the neck revealed abnormal neck vein pulsations characterized predominantly by an A-wave superimposed on a C-wave. Occasionally a small cannon wave was visible. The trachea was midline and there was no thyromegaly. Chest examination was unremarkable. The cardiac point

of maximal impulse was normal in position and configuration. The first heart sound varied in intensity and the second heart sound was physiologically split. There were no pathologic extracardiac sounds, murmurs or gallops. The remainder of his physical examination was unremarkable. All routine laboratory blood studies and roentgenograms were normal.

His routine electrocardiogram (Figure 4) was quite remarkable, however, demonstrating a unique arrhythmia. cursory examination might have failed to disclose it; The last QRS complex in aVr, and all of them in aVl are broader than those complexes in the other leads and also show initial notches or slurring. No discernible P-waves precede these QRS complexes and their repolarization is distorted. Except for this transient abnormality the electrocardiogram is quite normal. To decipher this problem further, relatively simply electrocardiographic studies were performed.

Once again, with Lewis and Wilson leads, the patient in the recumbent position performed a standard 10-sec. Valsalva maneuver. Phases III and IV (the recovery phases) from his electrocardiogram are shown in Figure 5. The tracing demonstrates a His bundle or peripheral conduction tissue (formerly referred to as a "low nodal") pacemaker rhythm.³ The onset of the QRS complex is difficult to determine inasmuch as the P-wave coincides with the QRS onset in several complexes. Compare beats 1, 2, and 3 where there is no fusion with beats 4, 7, and 12. Complex 9 produces retrograde depolarization of the atrium manifested by the inverted P-wave in the S-T segment. The QRS duration of the infra A-V nodal beats at their longest is equal to or less than 0.12 sec., and their configuration is quite similar to the beats normally induced by the sinus pacemaker. The nodal rhythm is 78 per minute while the sinus rate varies between 72 and 90 per minute. Thus, when the sinus rate slows below the nodal rate, the nodal focus supervenes as the dominant pacemaker. This competition for pacemaker dominance was also brought out during recovery from mild exercise (Figure 6). The nodal rate persisted at approximately 80 per minute. Exercise however, decreased vagal tone on the S-A node with a resulting acceleration of its rate. As the patient recovered from the exercise, vagal

J.E.
VALSALVA RESPONSE: PHASE III & IV

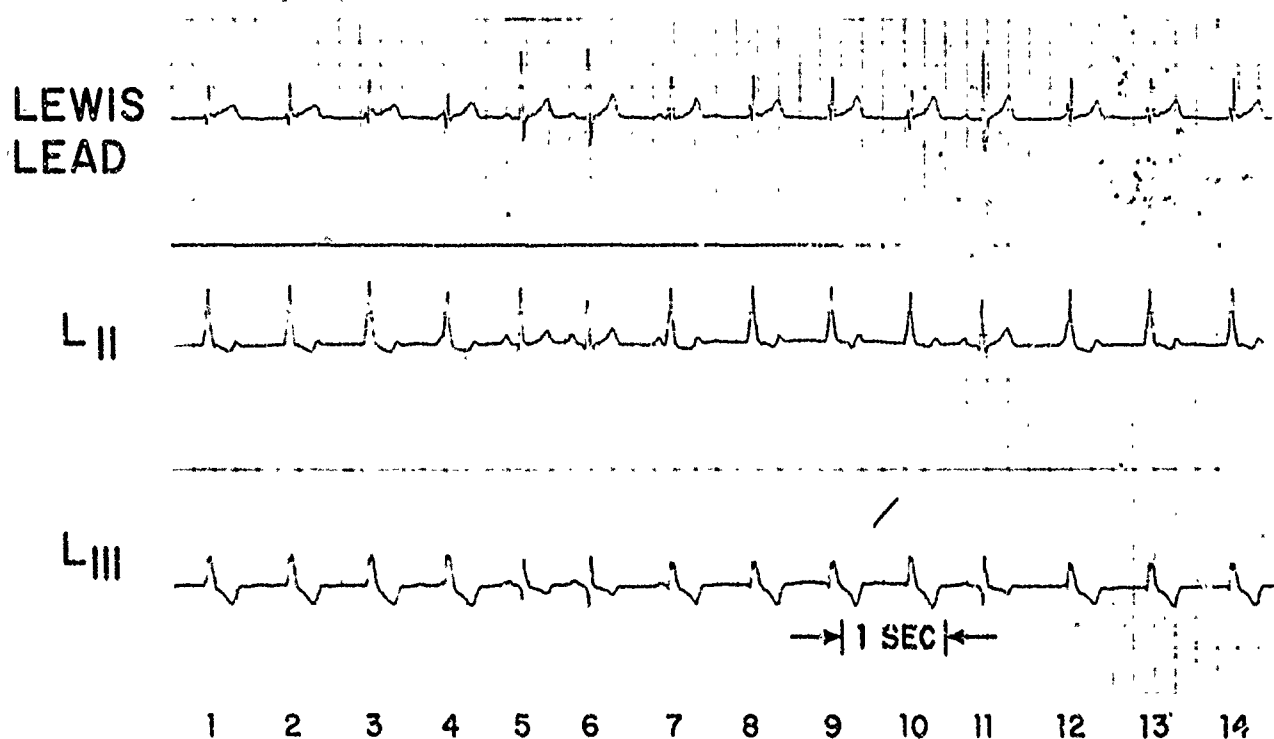


Fig. 5. Wandering pacemaker demonstrated in Patient No. 2 in several simultaneous leads during the recovery from Valsalva maneuver. See text for discussion.

tone slowly increased so that the two pacemaker sites were synchronous—the first complex designated with an asterisk, and the third complex in the second portion of the rhythm strip—the infra A-V nodal focus controlled when the sinus rate slowed to about 74, and then was depressed when the sinus sped to 95 at the end of the rhythm strip.

To further substantiate the physiologic explanation proposed, the patient received 0.3 mg edrophonium chloride intravenously during electrocardiographic monitoring. His response is illustrated in Figure 7. Edrophonium chloride, a cholinesterase inhibitor, potentiates existing or provoked vagal activity. Thus, there was a slowing of both pacemaker sites with exaggeration of the effect from carotid sinus massage. The sinoatrial rate slowed to approximately 63 per minute, which allowed the infra A-V

nodal focus to intermittently escape at a rate of approximately 65 per minute.

The physiologic variables in this patient, therefore, are similar to those in Case No. 1. Inasmuch as no cardiovascular abnormalities were noted, both patients were recommended for continuation of flying duties.

DISCUSSION

The clinical significance of supraventricular arrhythmias is variable. It is strategic that we be able to distinguish the pathologic arrhythmias which could jeopard-

**J.E.
EXERCISE RECOVERY**

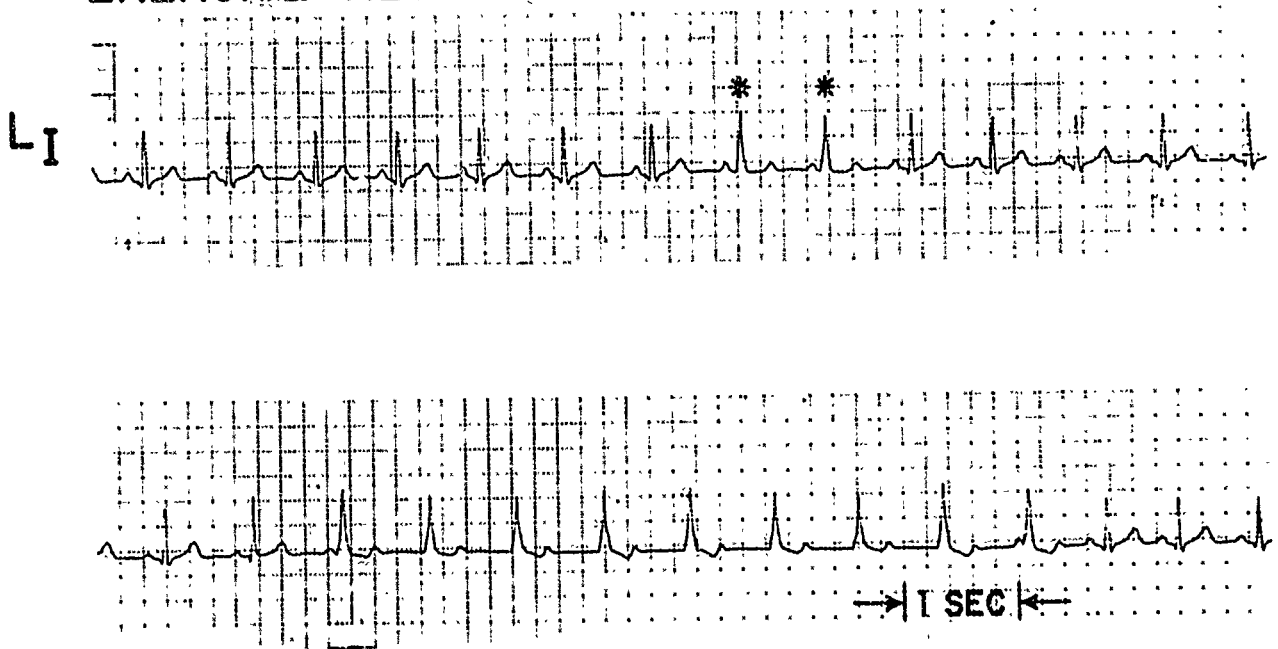


Fig. 6. Wandering pacemaker with fusion beats (designated with asterisk) and dominant low nodal rhythm. See text for discussion

**J.E.
EDROPHONIUM CHLORIDE 0.3 mgm**

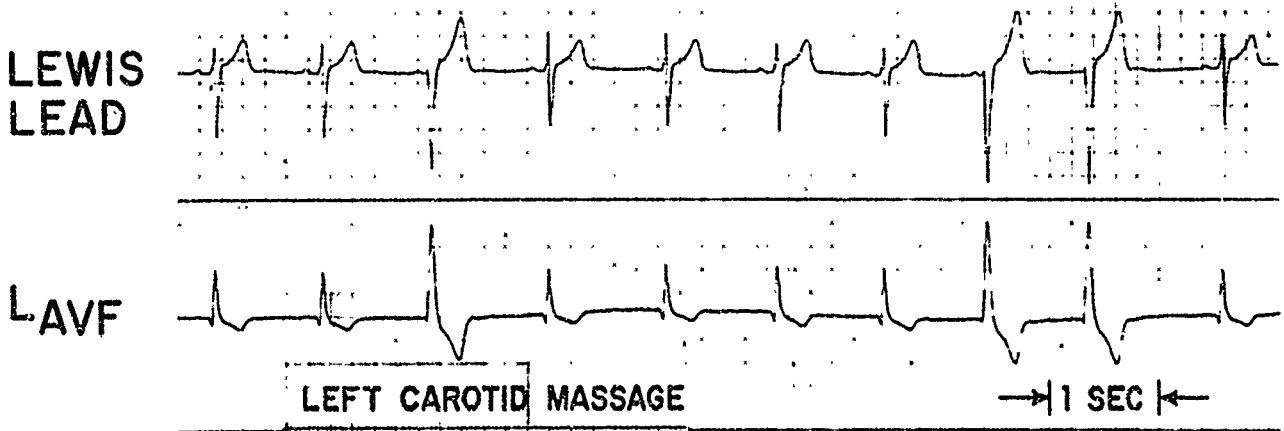


Fig. 7. Sinus bradycardia with wandering pacemaker accentuated with edrophonium chloride and carotid sinus massage in Patient No. ...

EVALUATION OF PERSONNEL WITH ARRHYTHMIAS—DOUGLAS

dize a pilot's life from physiologic variant arrhythmias with no morbid potential. Certain arrhythmias such as atrial fibrillation, atrial flutter, atrial arrest, and third-degree heart block have been diagnosed arbitrarily as pathologic, either on the basis that they result from some underlying disease or that the arrhythmia itself might compromise cardiovascular function, particularly in a pilot under stress. Other arrhythmias such as sinus arrest, first-degree A-V block, occasional uniform premature ventricular depolarizations, and wandering supraventricular pacemakers, may result from normal physiologic mechanisms without ominous portent. To misinterpret these is to risk not only the unnecessary grounding of healthy personnel but also the production of cardiac neuroses. The two cases herein presented had been diagnosed prior to USAFSAM evaluation as having atrial arrest, third-degree A-V heart block, and intermittent bundle-branch block. In actuality, they both represent wandering pacemakers, the first shifting from sino-atrial node to the atrium, the second shifting from sino-atrial node to the infra A-V nodal region. Monitoring the patient during minor physical or pharmacologic maneuvers frequently will allow more specific differentiation of the rhythm's etiology. Table I summarizes several such maneuvers.

A brief commentary on each of the agents may serve to expedite their clinical application. Edrophonium chloride (Tensilon) potentiates the effect of available acetylcholine. Patients may manifest a variable sensitiv-

ity to this drug and for this reason a test dose of 0.1 mg. administered intravenously is recommended. It is always wise when manipulating vagal tone to have a syringe with atropine sulfate available at the time. Although rarely necessary, it is of considerable benefit should the patient prove unduly sensitive to the anticholinesterase drugs. Side effects from edrophonium chloride are abdominal cramps, increased lacrimation and salivation, muscle tremor and fasciculation. These symptoms generally occur quite mildly with an arrhythmic diagnostic dose of 0.4 mg. intravenously. They usually disappear within one to two minutes and the cardiovascular responses rarely last longer than this.

Carotid sinus massage may often be used in an adjunct capacity with Tensilon (as illustrated in Figure 7), or may be used by itself.⁴ Generally, it is not recommended in any patient having carotid bruits or a history suggesting carotid or vertebral insufficiency or emboli. It is important that massage be performed in the region of the carotid bulb, this generally being at the angle of the jaw. Palpation and massage at a point below the carotid bulb may actually produce decreased carotid bulb distention registering as hypotension, with a resulting decreased vagal tone and cardio-acceleration rather than the expected enhanced vagal tone with cardiac slowing. After locating by palpation the carotid pulse at the angle of the jaw, rocking massage compression should be applied to it for a timed 10-sec. period. After a 60-sec. recovery period, the contralateral carotid bulb

TABLE I

AGENT	MODE OF ACTIVITY	INTERMEDIARY RESPONSE OR EFFECT	CARDIOVASCULAR	RHYTHM RESPONSE
(1) Edrophonium chloride	Anticholinesterase	Increased vagal effect	Slowing of the sinoatrial node; prolongation of atrial ventricular conduction; slight myocardial depression	Sinus bradycardia atrial and atrioventricular nodal escapes; first- and second-degree heart block
(2) Carotid massage	Increased carotid sinus nerve activity	Increased vagal firing	"	"
(3) Phenylephrine (Neosynephrine)	Increased peripheral resistance; increased blood pressure; with increased carotid sinus nerve activity	"	and sino-atrial and atrial ventricular nodal arrest	and sino-atrial arrest with nodal escapes and ventricular escapes
(4) Amyl nitrite	Decreased peripheral resistance with decreased blood pressure; decreased carotid sinus nerve activity; (there may also be an increased venous tone and increased venous return).	Increased vagal increase; sympathetic nervous system tone	Acceleration of sino-atrial node; decreased A-V conduction time	Sinus tachycardia with suppression of other pacemaker sites
(5) Atropine sulfate	Blocks receptor site for acetylcholine	Decreased vagal effect	Acceleration of sino-atrial node; decreased A-V conduction time	Sinus tachycardia with suppression of other pacemaker sites
(6) Passive leg-raising				
(a) Gradual	Increased venous return	Increased right atrial filling	Bainbridge reflex (?)	Slight increase in sinus rate
(b) Abrupt	Rapid venous return	Abrupt right atrial distension	Bezold-Jarisch reflex	Sino-atrial arrest
(7) Exercise	Many varied effects	Decreased vagal tone; increased adrenergic tone	As with Amyl nitrite, plus increased irritability	Sinus tachycardia and occasional premature atrial and/or ventricular depolarizations

may be similarly manipulated. It is worthwhile noting that right carotid stimulation usually has a dominant effect on the sino-atrial node, with only slight effect on the atrio-ventricular node, while left carotid stimulation produces a predominant effect on the atrio-ventricular node with lesser effects on the sino-atrial node. Individual variation in this regard is marked because of the dual innervation of both the SA and A-V nodes. Nonetheless, left carotid massage will usually increase-atrioventricular block more effectively than right carotid massage.

Phenylephrine (Neosynephrine), being predominantly an alpha-adrenergic catecholamine, produces its major cardiac effect via baroreceptor reflexes and vagal cardiac suppression. The magnitude of the response to intravenous phenylephrine is thus related. Considerable caution should be exercised with this drug because of its marked potency. Few situations justify a dose greater than 0.1 mg. Sufficient drug usually is left adhering to the walls of a tuberculin syringe after the syringe is emptied to produce the desired physiologic effects by merely flushing the emptied syringe with the patient's venous blood after a venipuncture. The following procedure is recommended: (1)-draw 0.2 cc. of 1% phenylephrine hydrochloride into a 1-cc. syringe; (2) remove needle and syringe from the drug vial and empty the syringe in a waste receptacle; (3) using this now emptied syringe and a new needle, perform venipuncture; (4) allow the syringe to fill with 0.8 cc. of blood; (5) inject the 0.8 cc. of blood back into the vein over a 5- to 10-sec. interval.

Amyl nitrite inhalation, as a diagnostic maneuver, has many attractive advantages. It is relatively innocuous, its effect is transient, and it decreases cardiac work. The patient should be cautioned, however, that he may experience a 1- to 2-min flushing headache and blurred vision.

Atropine sulfate, 0.4 mg. intravenously, will usually

provide sufficient vagal blockade to allow deciphering of arrhythmias resulting from neurogenic reflexes. Occasionally, however, a dose of 2.0 mg. is required. The major side effects (which are usually just nuisances) are mydriasis, which may last for two to three hours, and obstipation. Passive and active leg-raising, as well as exercise, are readily employed as the most physiologic maneuvers available to assist arrhythmia analysis.

SUMMARY

Diagnosis and aeromedical evaluation of the significance of supraventricular arrhythmias may frequently be assessed in the Flight Surgeon's Office with the assistance of an electrocardiographic machine, simple physical maneuvers, and a few pharmacologic agents, which are herein tabulated and briefly discussed. Two cases are presented in which the rhythm interpretation was facilitated by such studies.

ACKNOWLEDGEMENT

The author wishes to thank Mrs. Cecilia C. Manschot for her invaluable assistance in the preparation of this manuscript, and Mrs. Glorin Oakenshield for her advice and encouragement.

REFERENCES

1. DAMATO, A. N., S. H. LAU, K. M. ROSEN, C. STEINER, E. STEIN, and W. D. BERKOWITZ: His bundle rhythms. *Circulation* 40:527-534, 1969.
2. SCHAEFER, H.: Central control of cardiac function. *Physiol. Rev.* 40 (Suppl. No: 4): 213-231, 1960.
3. SCHERF, D., J. COHEN and M. RAFAELZADEH: Excitatory effects of carotid sinus pressure. *Amer. J. Cardiol.* 17:240-252, 1966.
4. WALDO, A. L., K. J. VTIKAINEN, G. A. KAISER, J. R. MAL, and B. F. HOFFMAN: The P wave and P-R interval. *Circulation* 42:653-671, 1970.

STI

WHITE SECTION

CG

BUFF SECTION

ANNOUNCED

SIGNATURE

DISTRIBUTION/AVAILABILITY

DIST.	AVAIL.	RESERVED
120		