

AD 748095

AD

TECHNICAL REPORT

73-3-FL

**SOME OBSERVATIONS ON INVAGINATION OF
THE COLON WITH PROLAPSE THROUGH THE ANUS IN
THE GOLDEN SYRIAN HAMSTER
(*Mesocricetus a. auratus*)**

by

W. B. Pollock

DDC
RECEIVED
SEP 13 1972
RECEIVED
C

Approved for public release,
distribution unlimited.

August 1972

UNITED STATES ARMY
NATICK LABORATORIES
Natick, Massachusetts 01760



Food Laboratory

FL-170

B

DISCLAIMER NOTICE

**THIS DOCUMENT IS BEST QUALITY
PRACTICABLE. THE COPY FURNISHED
TO DTIC CONTAINED A SIGNIFICANT
NUMBER OF PAGES WHICH DO NOT
REPRODUCE LEGIBLY.**

UNCLASSIFIED

Security Classification

DOCUMENT CONTROL DATA - R & D

(Security classification of title, body of abstract and indexing annotation must be entered when the overall report is classified)

1. ORIGINATING ACTIVITY (Corporate author) US Army Natick Laboratories Natick, Massachusetts 01760		2a. REPORT SECURITY CLASSIFICATION UNCLASSIFIED	
		2b. GROUP	
3. REPORT TITLE Some observations on invagination of the colon with prolapse through the anus in the Golden Syrian hamster (<u>Mesocricetus a. auratus</u>).			
4. DESCRIPTIVE NOTES (Type of report and inclusive dates)			
5. AUTHOR(S) (First name, middle initial, last name) William B. Pollock			
6. REPORT DATE August 1972	7a. TOTAL NO. OF PAGES 10	7b. NO. OF REFS 6	
8a. CONTRACT OR GRANT NO.	9a. ORIGINATOR'S REPORT NUMBER(S) 73-3-FL		
b. PROJECT NO. 1J061102A71C	9b. OTHER REPORT NO(S) (Any other numbers that may be assigned this report) FL-170		
c.			
d.			
10. DISTRIBUTION STATEMENT Approved for public release; distribution unlimited			
11. SUPPLEMENTARY NOTES		12. SPONSORING MILITARY ACTIVITY US Army Natick Laboratories Natick, Massachusetts 01760	
13. ABSTRACT The occurrence of invagination of the colon with prolapse through the anus in six Golden Syrian hamsters is reported. The gross pathological findings are described. Observations on the probable pathogenesis are discussed.			

1A

DD FORM 1473
NOV 65

REPLACES DD FORM 1473, 1 JAN 64, WHICH IS OBSOLETE FOR ARMY USE.

UNCLASSIFIED

Security Classification

UNCLASSIFIED

Security Classification

14. KEY WORDS	LINK A		LINK B		LINK C	
	ROLE	WT	ROLE	WT	ROLE	WT
Observations	8					
Reports	8					
Occurrences	8					
Invagination	8					
Prolapse	8					
Colon (intestines)	1					
Hamsters	1					
Golden	0					
Syrian	0					

ib

Security Classification

Approved for public release;
distribution unlimited

AD _____

TECHNICAL REPORT

73-3-FL .

SOME OBSERVATIONS ON INVAGINATION OF THE COLON WITH PROLAPSE THROUGH THE
ANUS IN THE GOLDEN SYRIAN HAMSTER (Mesocricetus a. auratus)

by

W. B. Pollock

August 1972

Project reference:
1J061102A71C

Series: FL-170

Food Laboratory
U. S. ARMY NATICK LABORATORIES
Natick, Massachusetts 01760

ic

FOREWORD


Intussusception, a term referring to invagination of the bowel upon itself, has been limited in use to the small intestine. The condition has been reported in many species of animals. Invagination of the colon with prolapse through the anus has been described as a rarely occurring event in all species and, in fact, is a rarely reported event. This condition is easily mistaken for prolapse of the rectum. This report takes issue with the conclusion that invagination of the colon with prolapse through the anus is "a rare event in all species", and presents the findings of six cases from 120 male, Golden Syrian hamsters. Observations are made on the probable influencing factors involved. Particular mention is made of the anatomical configuration of the hamster's colon which, this writer believes, is primarily the responsible factor.

The work reported was conducted under Project No. 1J061102A71C.

- ¹ In conducting the research described in this report, the investigator adhered to the "Guide for Laboratory Animal Facilities and Care" as promulgated by the Committee on the Guide for Laboratory Animal Resources, National Academy of Sciences - National Research Council, and by the National Society for Medical Research.

ABSTRACT

The occurrence of invagination of the colon with prolapse through the anus in six Golden Syrian hamsters is reported. The gross pathological findings are described. Observations on the probable pathogenesis are discussed.



INTRODUCTION

The most common position for invagination of the intestine is in the ileum and jejunum and cecum (1, 2). This process occurs in all species of animals, but is most common in dogs, young horses, adult cattle and lambs (2).

The etiology(ies) of intestinal invaginations has(have) not been clearly defined (2). However, enteritis, increased peristalsis, dysperistalsis, pedunculated tumors projecting into the lumen, foreign bodies, and parasites have all been found associated with the invagination (1-6). Intestinal irritations secondary to infectious diseases (i.e., canine distemper) have also been incriminated, as has the introduction of cold foods and/or fluids (1).

Invagination of the colon with prolapse through the rectum (not to be confused with simple prolapse of the rectum and anus) is a much less common finding in all species (1-6).

This report is concerned with reporting occurrences of invagination of the colon, which have been observed in six hamsters from six groups of twenty each during an eleven-month period.

FINDINGS

Young, growing, male Golden Syrian hamsters, 90 to 110 grams in weight were housed individually in galvanized cages. Water and laboratory chow (Purina^(R)) were supplied ad libitum. The hamsters discussed in this paper were from groups receiving intragastric inoculations of live salmonella organisms (10^8 - 10^9 orgs/ml/50 grams body weight) as part of studies of mechanisms of food poisonings. The problems evidenced by these hamsters occurred at intervals over an eleven-month span of time. The test animals were maintained for a two-week period for the food poisoning experiment.

One of the six hamsters was found dead in its cage in the morning. The only visible gross sign was the protrusion of 1 to 1.5 cm. of colon from the anus (see Figure 1). The other five animals were found with colonic protrusion from the anus prior to death. These five animals exhibited different degrees of awareness of their plights. Three had blood and debris caked around their noses and mouths and the protruding segments had evidence of self-inflicted trauma. These three also showed a watery diarrhea. The other two hamsters had made no attempt to bother the protruding intestine at time of discovery. Three were euthanatized shortly after discovery (within one hour) and necropsied. Two were allowed to progress before euthanasia was performed. The latter two animals developed classical signs of intestinal obstruction, i.e., distended abdomen, dehydration,

anorexia, pain on palpation, etc. These symptoms appeared in one animal within thirty hours and in the other within forty-eight hours (time from discovery to euthanasia). By this time, the protruding intestine had become edematous and necrotic (see Figure 2). Other animals in each test group displayed varying degrees of clinical signs associated with salmonellosis, but were not afflicted with the colonic invagination.

Gross Pathology

The necropsy findings were similar in the six animals. The colon was distended with ingesta and gas proximal to the point of invagination. Generalized petechiae and echymoses were evident. The distal segment (descending colon) and the invaginated segment were edematous and necrotic. Fibrinous adhesions were evident when traction was applied to remove the invaginated segment. In all six animals the invagination process had proceeded to a point corresponding to the junction of the transverse and descending colon. At this point in the hamster, there is a fold of mesentery that incorporates the spleen and effectively acts as a ligament binding the spleen and this junction of the colon together. The lengths of the descending colon varied from 4.8 cm to 6.2 cm. Thus, the invaginated portion of the colon traveled distances of approximately 6 to 8 cm before the process was terminated (i.e., either by death, euthanasia, or the holding capacity of the spleno-colic-mesenteric ligament).

DISCUSSION

Invagination of the colon with protrusion through the anus has rarely been described. The process is probably uncommon in most animals. However, the hamster is unique in the anatomical configuration with respect to the colon (see Figure 3). The transverse colon of the hamster is very long (up to 8 cm), while the ascending colon is more than twice as long (up to 21 cm). Further, instead of being a straight tube, the ascending colon winds tortuously towards the junction with the transverse colon with several foldings on itself in its mesenteric sheath. The fold of mesentery incorporating the spleen and colon at the junction of the transverse and descending colon has the capability of acting as ligamentous attachment to the colon at this point, preventing further invagination. To invaginate further would have the effect of incorporating the spleen into the invagination.

As noted earlier, the list of suggested etiologies associated with invagination of the intestine includes infections and other irritants. However, regardless of the initiating irritant, peristalsis is the major operator. At some point in the intestine, spasm of the circular muscle occurs, produced by a violent

peristaltic motion (1). A following peristaltic wave in the longitudinal muscle carries the spastic portion into the lumen of the distally-relaxed intestine (1). However, it is this writer's opinion that the hamster is predisposed to this type of intestinal invagination process in an area 6 to 8 cm proximal to the junction of the transverse and descending colon and that the spleno-colic-mesenteric fold acts as a ligament preventing further invagination.

Several points are worthy of mention here: (1) the hamster appears to be more susceptible to invagination processes in the colon than in the small intestine as opposed to most other species in which the reverse is true; (2) investigators wishing to maintain animals for long-term experiments should be cautioned against assuming that they are dealing with a simple anal-rectal prolapse that is correctible via simple replacement and peri-anal purse-string suture. Colonic invagination must be considered in the differential diagnosis; and (3) future investigators might consider the hamster a useful biological model in working with problems associated with intestinal invagination processes.

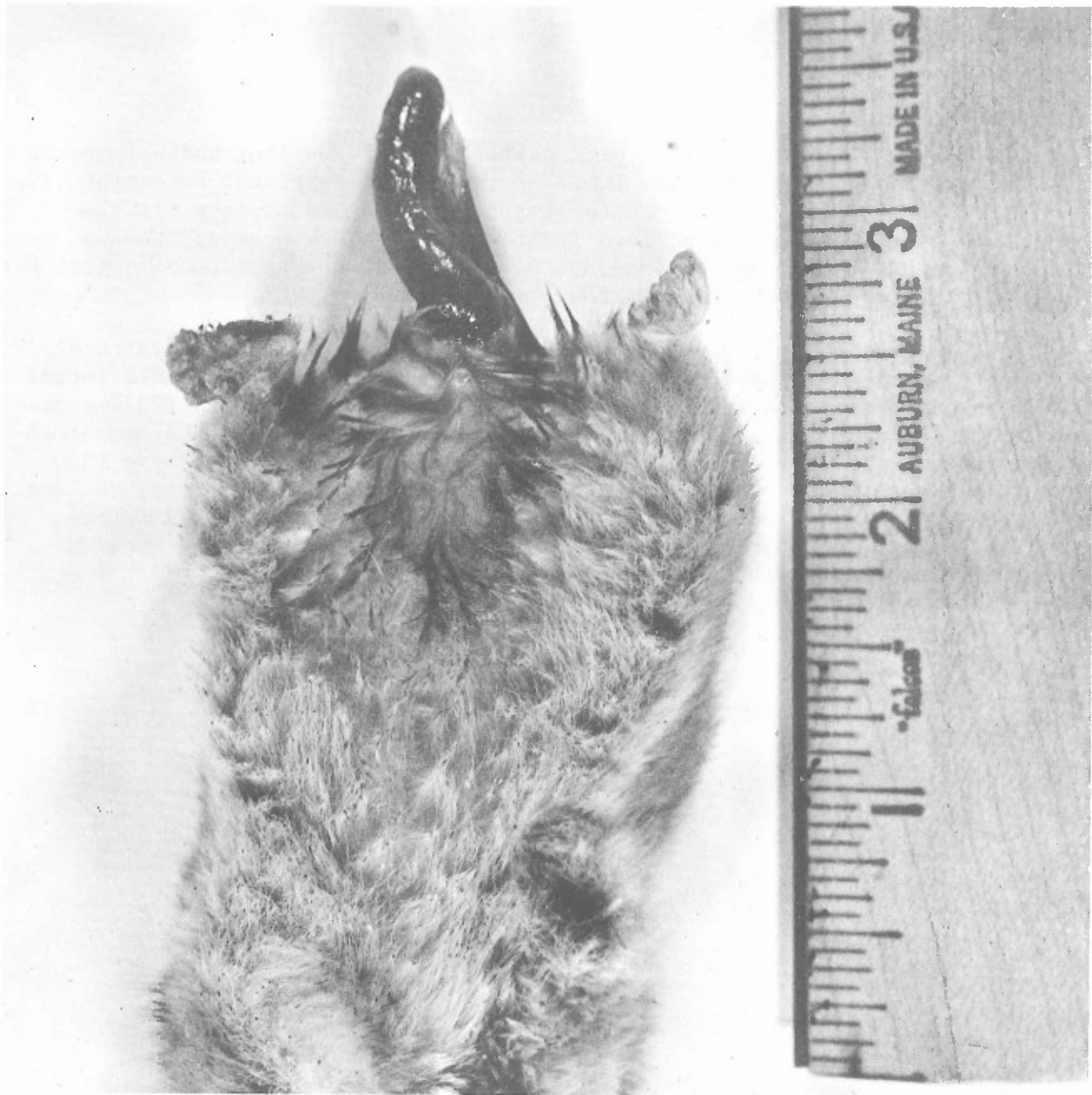

FIGURE 1

Anesthetized Hamster with Protruding Colon

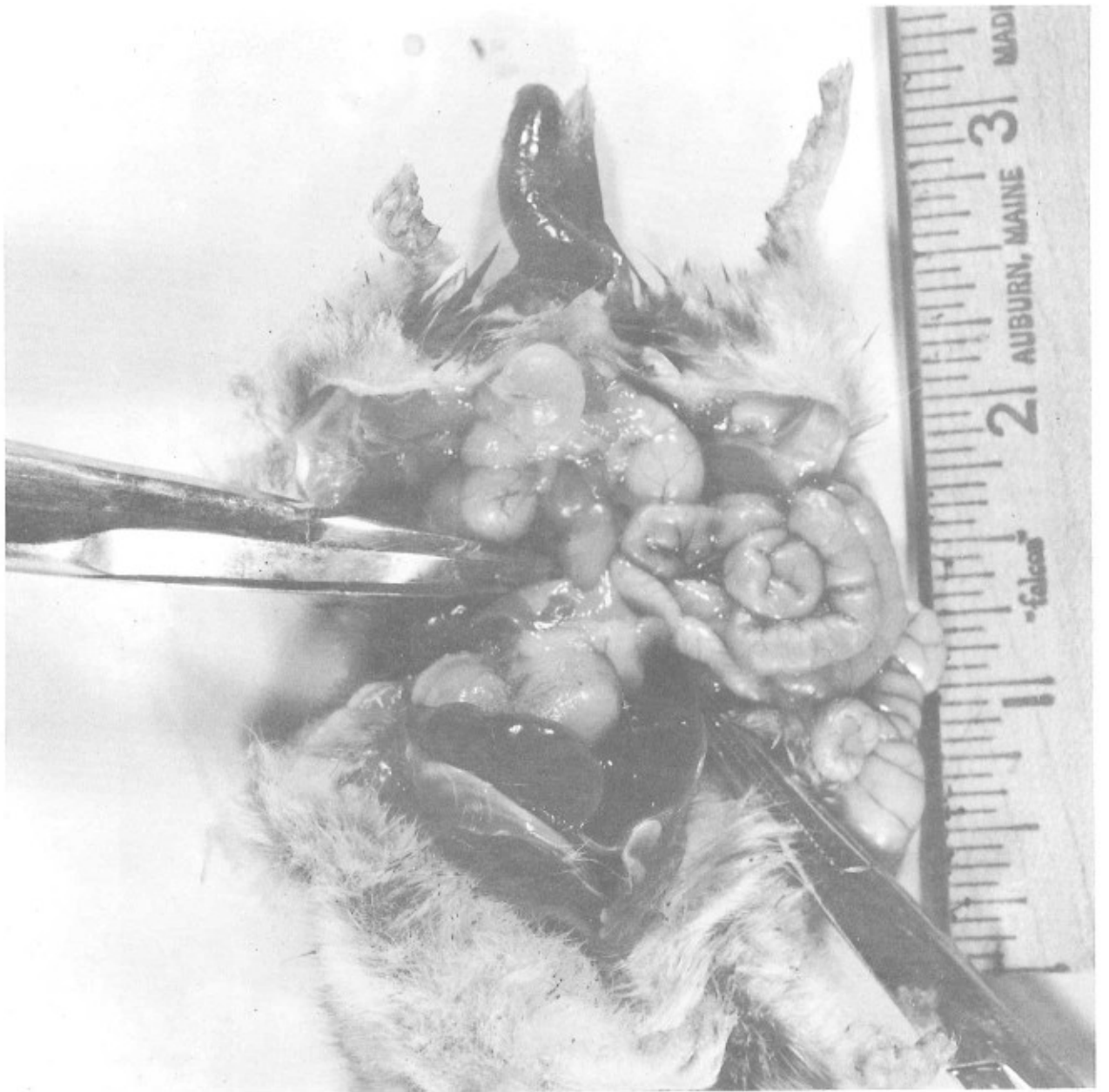


FIGURE 2

Same Hamster Showing Extent of Invagination

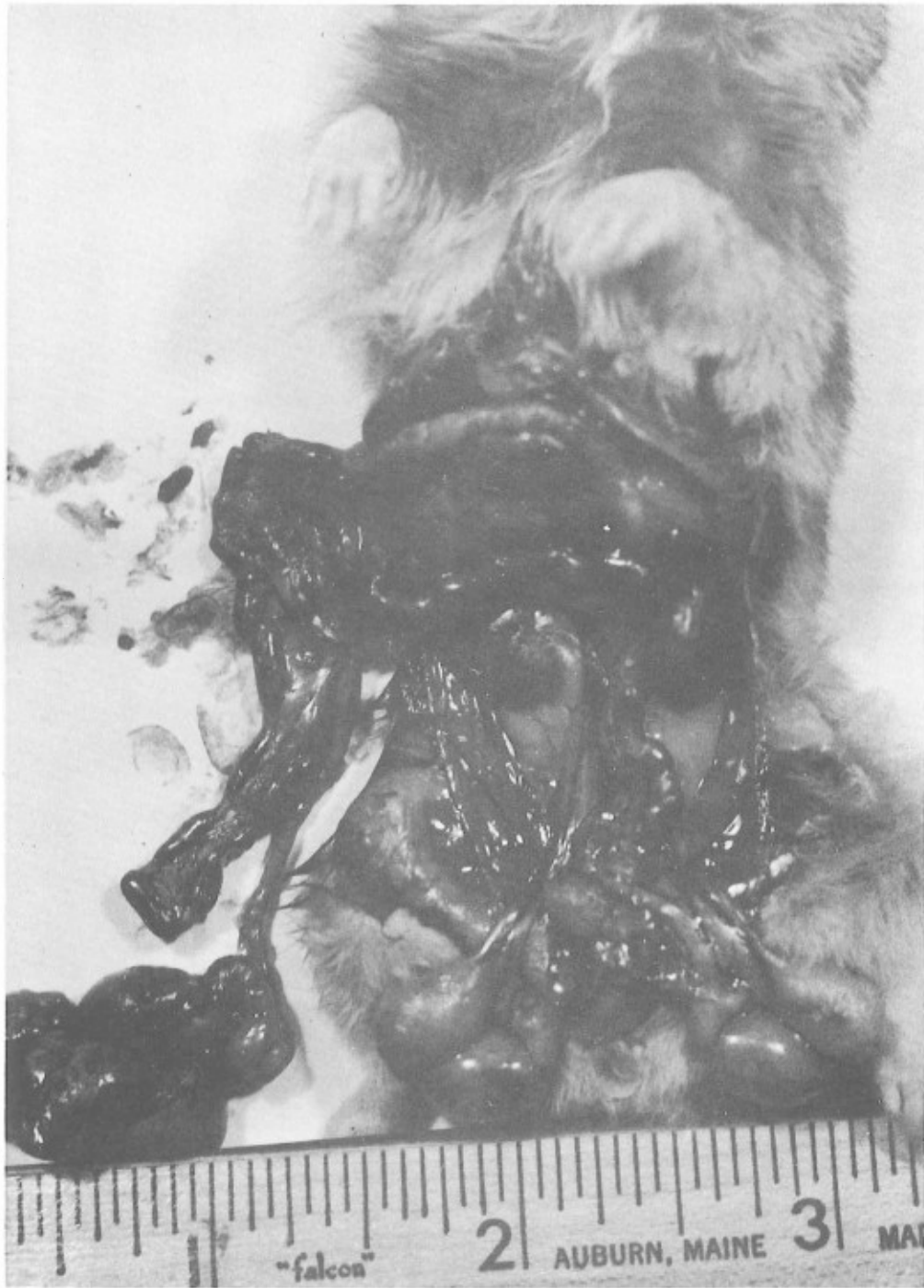

FIGURE 3

Showing the Length and Curvature
of the Normal Hamster Colon

REFERENCES

1. Cohrs, P. 1967. In Textbook of the Special Pstholgical Anatomy of Domestic Animals, p. 402. Pergamon Press, Oxford.
2. Jubb, K. F. V. and Kennedy, P. C. 1970. Pathology of Domestic Animals, 2nd Edition, Vol. 2, p. 96. Academic Press, New York.
3. Fox, J. G. and Hall, W. C. 1970. Fluke (Gastrodescooides hominis) infection in a Rhesus monkey with related intussusception of the colon. J. Amer. Vet. Med. Assn. 157: 714.
4. Guffy, M. M., Wallace, L. J. and Anderson, N. V. 1970. Inversion of the cecum into colon of a dog. J. Amer. Vet. Med. Assn. 156: 183.
5. Harris, M. D. 1968. Intussusception in the cat. Vet. Rec. 83: 597.
6. Puzet, G. 1970. Invagination of the colon with prolapse through the anus in a Galago senegalensis. Wienertieraerztlich Monatsschrift 57: 109 (German).