

AD-753 383

CASE FOR DIAGNOSIS

Bruce H. Smith, et al

Armed Forces Institute of Pathology  
Washington, D. C.

1972

DISTRIBUTED BY:

**NTIS**

National Technical Information Service  
U. S. DEPARTMENT OF COMMERCE  
5285 Port Royal Road, Springfield Va. 22151

D D C  
RECEIVED  
JAN 4 1973  
REGULATED

### Case for Diagnosis\*

**A** 42 year old Latin-American man was hospitalized because of headache, nausea, and vomiting. He also had nocturia, straining, and dysuria, which were increasing in severity, and constipation.

He had been hypertensive for at least two years and had suffered a cerebral hemorrhage eight months prior to admission, with residual right hemiplegia and expressive aphasia.

Other than neurologic deficits, physical examination of the patient revealed only blood pressure of 182/122 and suprapubic tenderness. Laboratory studies showed albuminuria. The levels of blood urea nitrogen and creatinine were within normal limits, and creatinine clearance was slightly reduced. The chest film was clear. Continuous-infusion IVP showed bilateral ureteral dilatation, with pyelocaliectasis on the left. The bladder was displaced out of the true pelvis and had a toplike configuration, and both ureters were tortuous (Fig. 1). Cystoscopy showed that the bladder had an elevated base and a questionable left lateral extrinsic defect. Barium enema elicited an elongated and narrowed rectum with no mucosal irregularity (Fig. 2). Biopsied specimens from the prostate, bladder, and rectum showed minimal inflammatory changes.

After the patient's hypertension was controlled, he had an exploratory laparotomy, and biopsy specimens were taken of the pelvic mass (Fig. 3).

\* Prepared by Bruce H. Smith, M.D. and CAPT Elias G. Theros, MC, USN, Armed Forces Institute of Pathology, Washington, D.C. 20305. Dr. Smith was Director of the Institute and CAPT Theros is Chief of the Radiologic Pathology Division.

AD 753383

Reproduced by  
NATIONAL TECHNICAL  
INFORMATION SERVICE  
U.S. Department of Commerce  
Springfield, VA 22151

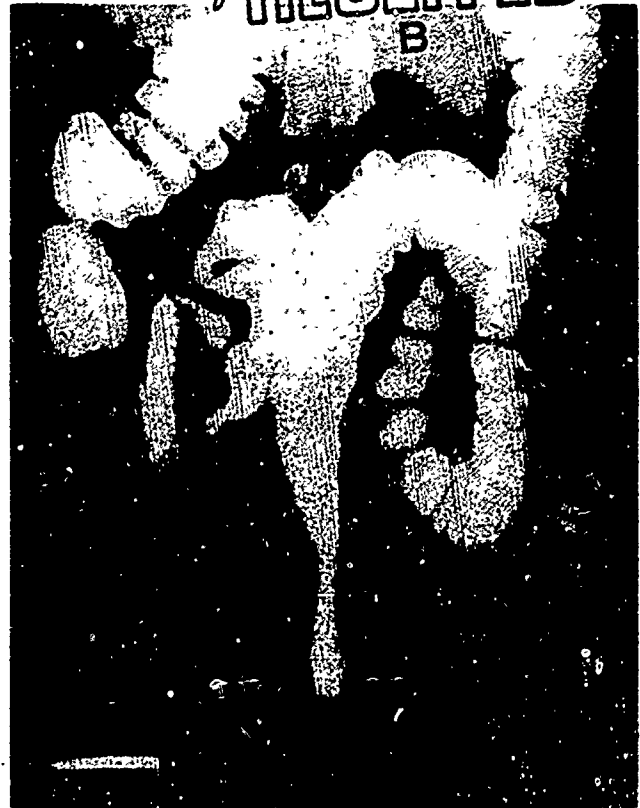

Fig. 2. Radiograph made after barium enema showing an elongated and narrowed rectum but no mucosal irregularity.

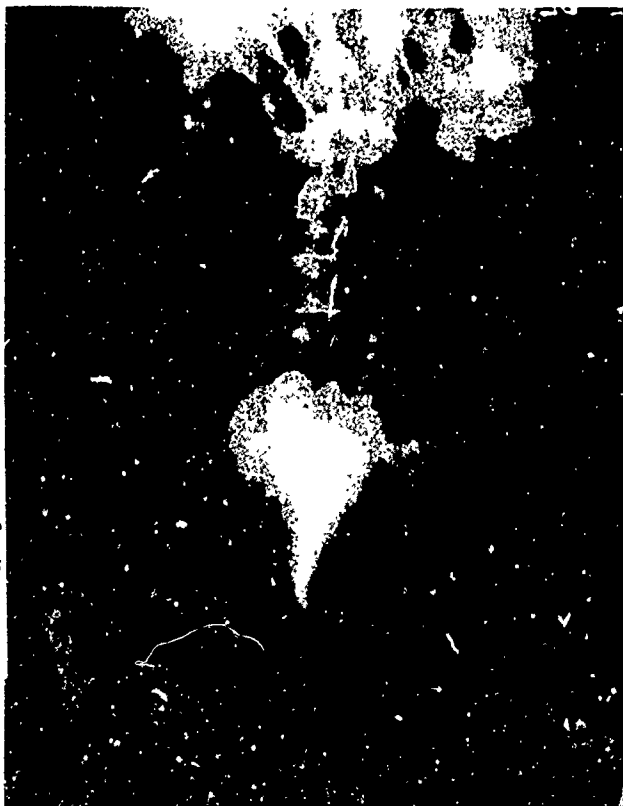

Fig. 1. Pyelogram showing dilated tortuous ureters and an elevated pear-shaped urinary bladder.




Fig. 3. Section of biopsy specimen taken from pelvic mass at laparotomy, x60.

· copies of illustrations in  
this document may be better  
studied on microfiche.

## Case for Diagnosis (Solution)

This is a case of pelvic lipomatosis. It is presented here because this is an entity that has been recognized relatively recently. To date, only 19 cases have been reported in the literature (Table I) and it appears to be almost exclusively a disease of the middle-aged male. It is found in both Caucasians and Negroes but no cases have been described in other races to date. It is a slowly progressive overgrowth of pelvic fat with gradual compression of the pelvic organs, some of which are lifted out of the pelvis. As of this writing, treatment is rather ineffective, and because of the limited number of cases and limited follow-up time, no conclusions can be drawn as to the eventual outcome.

### References

- <sup>1</sup> Becker, J. H. *et al.*: Pelvic Lipomatosis. Arch. Surg. (Chicago), 100:94-96, 1970.  
<sup>2</sup> Bender, L. and Kass, M.: Periureteral Lipomatosis. J. Urol., 103:293-295, 1970.  
<sup>3</sup> Fogg, L. B. and Smyth, J. W.: Pelvic Lipomatosis: A Condition Simulating Pelvic Neoplasm. Radiology, 90:558-564, 1968.

TABLE I  
PELVIC LIPOMATOSIS CASE REPORTS

Authors	Date	No. of Cases	Sex	Race	Age
Engles	1959	5	M	C	38
			M	C	
			M	C	
			M	N	
			M	N	
Leuzinger <i>et al</i>	1961	1	M	C	80
Rosenberg <i>et al</i>	1963	1	M	C	62
Fogg and Smyth	1968	5	M	N	50
			M	N	48
			M	C	54
			M	C	48
			M	N	57
M	N	63			
Mahlin	1968	1	M	N	47
Becker <i>et al</i>	1969	5	M	N	67
			M	C	76
			M	N	56
			M	?	?
			M	?	?
Bender and Kass	1979	1	F	N	51

ACCESSION for	
RTIS	White Section <input checked="" type="checkbox"/>
G.S.	Buff Section <input type="checkbox"/>
UNAR C.M.P.C.	<input type="checkbox"/>
JUSTIFICATION .....	
BY .....	
DISTRIBUTION/AVAILABILITY CODES	
Dist.	AVAIL. and/or SPECIAL
A 20	