

UNCLASSIFIED

AD NUMBER
AD815554
NEW LIMITATION CHANGE
TO Approved for public release, distribution unlimited
FROM Distribution authorized to U.S. Gov't. agencies and their contractors; Administrative/Operational Use; Apr 1966. Other requests shall be referred to Commanding Officer, U.S. Army Biological Laboratories, Fort Detrick, Frederick, MD.
AUTHORITY
SMUFD, D/A ltr, 14 Feb 1972

THIS PAGE IS UNCLASSIFIED

CONCERNING THE PATHOGENESIS OF THE TULAREMIA INFECTION
IN NONIMMUNE AND IMMUNE ORGANISMS

AD815554

Translation No. 1666

APRIL 1966

~~SECRET~~

STATEMENT #2 UNCLASSIFIED

This document is subject to special export controls and each transmittal to foreign governments or foreign nationals may be made only with prior approval of U.S. ARMY

BIOLOGICAL LABORATORIES
FORT DETRICK, FREDERICK, MARYLAND

DDC AVAILABILITY NOTICE

Qualified requestors may obtain copies of this document from DDC.

This publication has been translated from the open literature and is available to the general public. Non-DOD agencies may purchase this publication from Clearinghouse for Federal Scientific and Technical Information, U. S. Department of Commerce, Springfield, Va.

Technical Library Branch
Technical Information Division

CONCERNING THE PATHOGENESIS OF THE TULAREMIA INFECTION
IN NONIMMUNE AND IMMUNE ORGANISMS

[Following is the translation of an article by R. A. Savelyeva and A. P. Gindin, Gamaleya Institute of Epidemiology and Microbiology, AMN, USSR, published in the Russian-language periodical Zhurnal Mikrobiologii, Epidemiologii i Immunobiologii (Journal of Microbiology, Epidemiology and Immunobiology, No. 8, 1965, pages 43--50. It was submitted on 1 Apr 1964. Translation performed by Sp/7 Charles T. Ostertag, Jr.]

The reaction of an immune organism to infection with the virulent tularemia microbe has been dealt with by only a few authors, and here there is no single opinion relative to the degree of protection of an immune organism from subsequent infection. Thus, Tinker and Drozhevkina (1949) consider that in white mice, guinea pigs, and rabbits which have been immunized with live vaccine, following infection with a virulent culture the tularemia microbes do not go beyond the limits of the primary complex -- the site of injection of the causative agent and the regional lymph nodes. At the same time, in analogous tests by Mashkov on white mice (1953) and by Yudenin on guinea pigs (1956), it was established that in a vaccinated organism the tularemia microbe penetrates the internal organs along with the regional lymph nodes -- the spleen, liver, etc., causing a specific granulomatous process in the tissues. Khakhina (1947) also reports of the presence of granulomas in the internal organs of guinea pigs which had been subjected to infection with a virulent tularemia culture following vaccination.

We considered it expedient to study this problem in animals which had the maximum immunity to tularemia. In these animals non-susceptibility was created by means of infection with a virulent culture following preliminary vaccination with live tularemia vaccine.

All told we used 66 guinea pigs (36 test and 30 control) weighing 300--350 grams. They were vaccinated cutaneously and after 3--5 weeks were infected subcutaneously with 1,000 microbial cells of the virulent strain No 503. Usually the infection of vaccinated pigs with such a dose caused a brief illness in them with subsequent recovery. Pigs which were prepared in the stated manner were subjected to intracutaneous infection with two doses of the virulent strain No 503: 10 and 10 million microbial cells based on the optical bacterial standard (18 pigs for each dose). The infection was carried out after 5 and 5½ months following the administration of 1,000 microbial cells, since we calculated that in the animals by this time the

pathological changes which are connected with recovery should be reduced to a minimum. However, histological investigations showed that by this time there still remained in the animals a number of specific changes, which we will speak about in more detail.

The virulent culture was administered in the opposite side in respect to the site of the initial infection. Serving as the control were 26 guinea pigs which had been infected in an analogous manner (13 pigs for each dose). For guinea pigs, 1 Dcl of strain No 503 constitutes one microbial cell based on the standard. During the period of the test we noted in all the animals the changes in the skin at the site of infection and the condition of the regional lymph nodes, and we also measured the body temperature. The test (immune) and control (nonimmune) pigs (2 for each dose) were sacrificed in 1, 2, 3, 4, 6, and 8 days, and test immune pigs also in later periods -- after 10, 15, and 30 days. Of the control 5 pigs were autopsied following death on the 4--11th day. Changes, even though detected in one of the 2 investigated pigs, are presented in figure 1.

The organs of the sacrificed guinea pigs (or those which died) were investigated in a biological probe on white mice, by seeding on convolute vitelline medium, and histologically. The regional lymph node, spleen and liver were subjected to a compulsory bacteriological investigation, and the same organs with the addition of the skin from the site of infection -- to a histological investigation. The organs were fixed in formalin and alcohol-formalin and poured into paraffin. Sections were stained by the ordinary histological methods.

In the analysis of the material we used the graduation of the infectious tularemia process in guinea pigs according to the plan of Olsufyev and Dunayeva (1961), which represents a somewhat simplified version of the plan of Mayskiy (1949) and Tinker and Drozhevkina (1949).

In the nonimmune guinea pigs which were infected with 10 Dcl, on the 1st and 2nd days a small sector of light hyperemia appeared only at the site of infection. There were no macroscopic changes on the part of the internal organs, and in like manner a febrile reaction was lacking. Thus, it can be considered that the phase of adaptation lasted around 2 days. Then the infectious process passed into the phase of regional infection.

During the histological investigation of these animals after 24 hours, at the site of infection in the skin hyperemia and a small accumulation of polymorphonuclear leucocytes were noted, in the deeply situated sectors of the derma and in the cells -- there were small foci of proliferation of histocytic elements, and in the regional lymph nodes -- only a swelling of the reticuloendothelium of the sinuses.

After 3 days in all the test animals a fever was noted, and at the site of infection -- a more distinct sector of hyperemia and edema. The causative

agent was detected in the regional lymph nodes, and also in the spleen (in the latter only by a bioprobe), which testified to the transition of the pathological process to the next phase -- the hematogenic dissemination and focal spreading.

Upon autopsy, by this time there was injection of the vessels of the subcutaneous cellular material, hyperemia and enlargement of the regional lymph nodes. No changes were noted in the internal organs. Histologically, in the skin an increase of leucocytic infiltration was detected with the spreading of the process into the deeper layers (to the subcutaneous cellular material, skin muscles and the areolar tissue under it) with the subsequent formation of submiliary tularemia granulomas.

The cellular composition of such granulomas has been described more than once in the literature (Dvizhkov, 1930; Vygodchikov and Khatenever, 1932; Kartasheva, 1936; Lilli and Frensis, 1937; Pozhariskiy, 1946). Granulomas were formed in the regional lymph nodes. The central portion of the granulomas represented an accumulation of polymorphonuclear leucocytes, and the peripheral portion -- macrophages, reticular cells, individual epithelial and lymphoid cells, among which a certain amount of polymorphonuclear leucocytes encountered. Small foci of proliferation of the reticular cells had already appeared in the spleen.

After 4 days the dimensions of the inflammatory focus in the skin had increased up to 1.5 cm in diameter with clear contours of necrosis in the center. The regional lymph nodes (inguinal) were easily determined by palpation. The liver and spleen were enlarged and condensed, with gray-yellowish nodules. Tularemia bacteria were detected in all the organs investigated, and in the regional lymph node and the spleen this was not only by a bioprobe but also by seeding, which testified to the further accumulation of bacteria in the tissues. As already stated, in the regional lymph nodes there was a granulomatous process with the presence of macrophages, epithelioid cells and the beginning of breakdown in the center. After 4 days a significant portion of the foci of proliferation in the spleen had converted into typical tularemia granulomas.

After 6 and 8 days distinct changes were detected macroscopically both at the site of infection and in the internal organs. The tularemia causative agent was detected with the help of bioprobes and by inoculation in all the organs investigated. This pointed to the transition of the process to the phase of septicemia. At the site of infection the pathological process continued to progress, descending into the deeper layers, into the cutaneous muscle and the areolar tissue under it. In the regional lymph nodes and the spleen necrotization of the tularemia granulomas was detected and during the process it involved new sectors of tissue of these organs.

Thus, based on time the necrotization of granulomas coincided morphologically with the transition of the infectious process to the phase of

septicemia. In this group the death of pigs was observed on the 10th day (figure 2, a and b).

Thus, in nonimmune guinea pigs following infection with 10 Dcl, the pathomorphological changes in the tissues of various organs developed on a parallel with the distribution of the causative agent.

In the pigs which were infected with 10 million Dcl the process developed in a similar manner, but in shortened periods. Already after 24 hours all the pigs had fever, and the skin at the site of infection became edematous and in the center an inflammatory focus of a small papule was formed.

Upon autopsy apparent changes in the internal organs were not noted, but the causative agent was detected in all the organs investigated with the help of not only bioprobes but also with seedings. Histologically in the skin, the subcutaneous cellular material and the skin muscle, a significant inflammatory reaction was detected, with hyperemia, edema, leucocytic infiltration suppuration. Based on intensity, in 24 hours this reaction reached the same state of development as in the pigs infected with 10 microbial cells in 3--4 days following infection. In the regional lymph node along with leucocytic infiltration there were granulomas with a necrotic center. In the spleen an intense proliferation of reticulo-endothelial elements was exposed. After 2 days a still more intense proliferation and the presence of granulomas were noted. In the following days an intensification of the inflammatory process was detected both at the site of infection and in the internal organs.

After 3 days at the site of infection an extensive sector of the skin was necrotized, and the regional lymph nodes were enlarged and necrotized. In the enlarged spleen and liver a diffuse proliferation of the reticulo-endothelium was observed along with the presence of granulomas and necrotic symptoms in them. Death of the pigs in this group was observed on the 4--8th day.

In the immune pigs we were able to note a completely different reaction in response to the administration of a virulent culture. In the animals infected with 10 microbial cells, the febrile reaction was absent throughout the entire test. The local reaction became noticeable after 2 days and was expressed in a very insignificant edema and hyperemia of the skin in a sector up to 0.5 cm in diameter, and it began to fade away on the 4th day.

No macroscopic changes were noted in the organs following autopsy. Bacteriological findings were extremely scarce -- the causative agent was detected only with the help of a biological probe in the regional lymph node in 3 pigs and in the spleen of 2 pigs (all told in 5 out of the 18 animals investigated) during the period between the 6th and 30th days, since the results of the bacteriological investigation of the pigs up to 4 days following infection remained negative (see figure 1).

Histologically, in the first 2 days following infection the skin showed a weak leucocytic infiltration and a still weaker proliferation of the histiocytic elements, and after 3--4 days granulomas were formed which were subsequently reduced by the 10--20th day. Polynuclear gigantic cells were encountered in the granulomas.

In the first 3--4 days following infection, in the regional lymph nodes there was noted a moderate leucocytic infiltration, proliferation of reticulo-endothelial elements, and desquamation of the endothelium of the sinuses, and after 6--8 days -- the intensive formation of granulomas. The latter were detected up until the end of the period of observation. Gigantic cells were often encountered in them. The central sectors of the granulomas were intensively infiltrated with well preserved leucocytes. As a rule, necrosis and suppuration were not observed (figure 3, a and b).

It should be noted that granulomas were not detected in the liver, and in the spleen only individual ones were encountered -- on the 3rd, 6th, and 30th days. On the 6th day the causative agent was also detected in the spleen in one case. In the first days following infection, in the peri-follicular zones of the spleen proliferation of the reticular cells was exposed, and in subsequent days intensive regeneration of the lymphoid tissue was observed, as well as the formation of granulomas, but without dystrophic processes in them.

The reaction of immune guinea pigs to infection with 10 million Dcl was quite unique. Already after 24 hours at the site of administering the culture in the skin there was a vast hyperemia with necrosis in the center, reaching 1 cm in diameter. This reaction should be evaluated as an allergic reaction to the repeated administration of the antigen. In this group of animals a febrile reaction was absent throughout the entire test; in spite of the fact that a generalization of the process was noted in the first days, and the causative agents, though in small quantity (only by a bioprobe), were detected in the organism throughout the entire period of observation.

*In another test under similar conditions, a febrile reaction was observed in individual pigs.

During an autopsy after 2 days foci of necrosis were also noted in the subcutaneous cellular material and there was a small enlargement of the regional lymph nodes, and after 3 days grayish nodules were detected in a section of the regional lymph nodes.

The enlargement of the liver and the spleen with single gray-yellowish nodules in a section was observed only in certain pigs after 6--8 days. Every time the presence of macroscopic changes coincided with the detection of the tularemia causative agent with the help of a bioprobe.

The histological investigations showed that after 24 hours, in the skin and the subcutaneous cellular material there was an inflammatory process of the same intensity and nature as in nonimmune animals infected with the same dose of the culture. And after 2--3 days in some of the animals necrosis of the skin was expressed even more intensively than in nonimmune animals. By the 4th day a large expanse of the skin turned out to be necrotized and ulcerous. Under the ulceration a dense leucocytic infiltrate was found, and deeper a zone of granulomas had formed. After 6--8 days the granulomatous tissue with the typical epithelioid cells, macrophages and gigantic cells (some of these were similar to Langhans') occupied a large area under the ulceration. Epithelization of the skin defect took place between the 20th and 30th days, but even after 30 days in the subcutaneous cellular material of macroscopically unchanged skin it was still possible to detect submiliary granulomas.

In all the periods of observation the cutaneous muscle in the immune animals, in contrast to the nonimmune, seldom was involved in the inflammatory process. In the course of the first 2 days in the regional lymph nodes there was noted just a proliferation of the reticular elements and in places the desquamation of the endothelium of the sinuses, but by the 3rd and especially the 4th day formed granulomas were found. In contrast to the granulomas which were exposed in nonimmune animals, they contained many epithelioid and gigantic cells. The centers of the granulomas were infiltrated with leucocytes. After 6--8 days the lymph nodes, almost devoid of lymphoid tissue, represented a conglomerate of earlier formed large granulomas and newer -- submiliary.

In contrast to the nonimmune pigs, the necrobiotic processes in immune pigs were expressed considerably more weakly. In this period and later the proliferation of fibroblastic elements was noted between the granulomas. However, the granulomatous process passed to the surrounding cellular material.

Between the 10th and 15th days it was possible to observe the regeneration of lymphoid tissue in the vicinity with the granulomas. In the spleen in the course of the first 3 days following infection, the same changes developed as in the immune animals which were infected with 10 microbial cells. Granulomas in the spleen were detected inconstantly.

The histological investigations of the organs of the control pigs, that is, those infected only with 1000 microbial cells and sacrificed after 5--5½ months, made it possible to evaluate some of the changes which were described in the immune guinea pigs as residual phenomena as a result of the initial infection. Thus, after 5½ months in the lymph nodes of individual pigs incapsulated necrotized granulomas were detected with the deposit in them used up, which testified to the oldness of the process. In one pig submiliary granulomas were found in such a capsule.

The histological investigations showed that after 24 hours, in the skin and the subcutaneous cellular material there was an inflammatory process of the same intensity and nature as in nonimmune animals infected with the same dose of the culture. And after 2--3 days in some of the animals necrosis of the skin was expressed even more intensively than in nonimmune animals. By the 4th day a large expanse of the skin turned out to be necrotized and ulcerous. Under the ulceration a dense leucocytic infiltrate was found, and deeper a zone of granulomas had formed. After 6--8 days the granulomatous tissue with the typical epithelioid cells, macrophages and gigantic cells (some of these were similar to Langhans') occupied a large area under the ulceration. Epithelization of the skin defect took place between the 20th and 30th days, but even after 30 days in the subcutaneous cellular material of macroscopically unchanged skin it was still possible to detect submiliary granulomas.

In all the periods of observation the cutaneous muscle in the immune animals, in contrast to the nonimmune, seldom was involved in the inflammatory process. In the course of the first 2 days in the regional lymph nodes there was noted just a proliferation of the reticular elements and in places the desquamation of the endothelium of the sinuses, but by the 3rd and especially the 4th day formed granulomas were found. In contrast to the granulomas which were exposed in nonimmune animals, they contained many epithelioid and gigantic cells. The centers of the granulomas were infiltrated with leucocytes. After 6--8 days the lymph nodes, almost devoid of lymphoid tissue, represented a conglomerate of earlier formed large granulomas and newer -- submiliary.

In contrast to the nonimmune pigs, the necrobiotic processes in immune pigs were expressed considerably more weakly. In this period and later the proliferation of fibroblastic elements was noted between the granulomas. However, the granulomatous process passed to the surrounding cellular material.

Between the 10th and 15th days it was possible to observe the regeneration of lymphoid tissue in the vicinity with the granulomas. In the spleen in the course of the first 3 days following infection, the same changes developed as in the immune animals which were infected with 10 microbial cells. Granulomas in the spleen were detected inconstantly.

The histological investigations of the organs of the control pigs, that is, those infected only with 1000 microbial cells and sacrificed after 5--5½ months, made it possible to evaluate some of the changes which were described in the immune guinea pigs as residual phenomena as a result of the initial infection. Thus, after 5½ months in the lymph nodes of individual pigs encapsulated necrotized granulomas were detected with the deposit in them used up, which testified to the oidness of the process. In one pig submiliary granulomas were found in such a capsule.

9. Khakhina, Z.D., In the book: Tularemia, Rostov/Don, 1947, page 54.
10. Yudenich, V.A., Zh. mikrobiol., 1956, No 5, page 14.

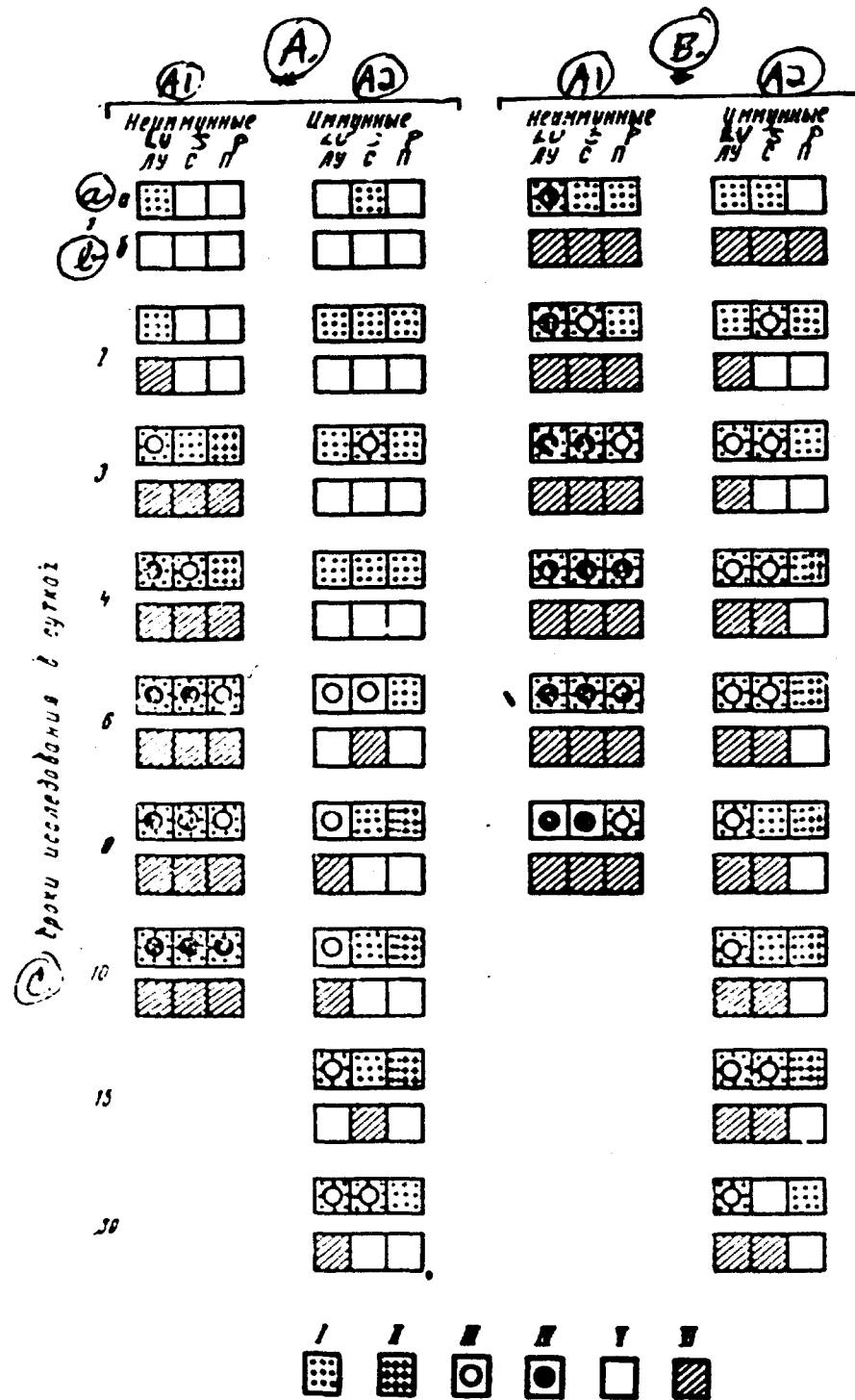


Figure 1. Dynamics of the distribution of the microbe and the level of morphological changes in the organs and tissues of nonimmune and immune guinea pigs, infected with 10 microbial cells (A) and 10 million microbial cells (B) of a virulent strain.

Legend on following page.

Figure 1. Legend.

A1 -- Nonimmune; A2 -- Immune.

a -- results of morphological investigation; b -- results of bacteriological investigation; LU -- regional lymph node; S -- spleen; P -- liver.

I -- focal or scattered proliferation of the the elements of the RES;

II -- foci of dystrophy and necrobiosis in the tissue of the organ;

III -- presence of granulomas;

IV -- suppuration or necrosis of granuloma;

V -- absence of the causative agent in the tissue of the organ and the absence of morphological changes;

VI -- presence of the causative agent in the tissue of the organ.

c -- period of investigation in days.

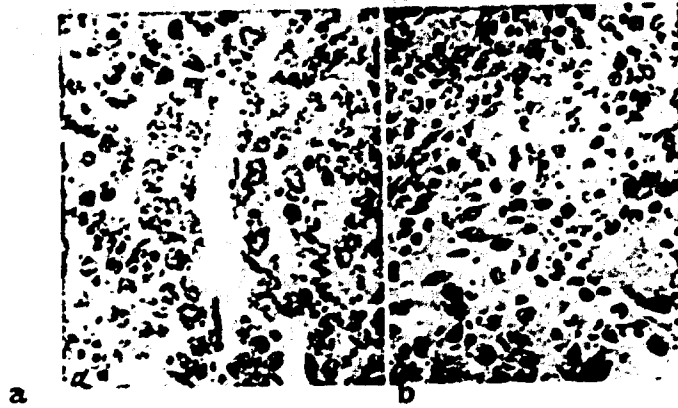

Figure 2. a -- spleen of a nonimmune guinea pig after 6 days following infection with 10 microbial cells; necrosis of the granulomas; adventitial elements of the vessel, located in the necrotic focus, were preserved; b -- subcutaneous cellular material of an immune guinea pig, infected with 10 million microbial cells and sacrificed on the 15th day; granulomas.

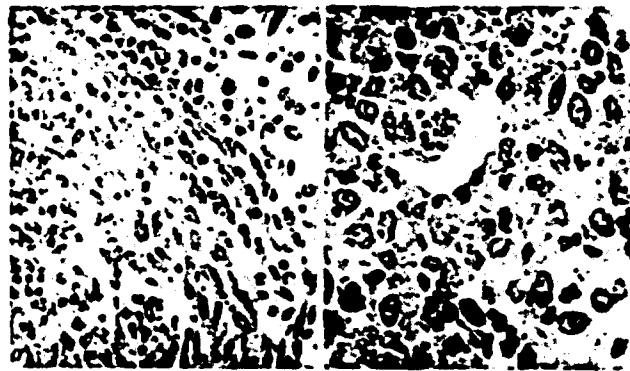


Figure 3. a -- lymph node of an immune guinea pig, sacrificed after 6 days following infection with 10 million microbial cells; onset of capsule formation (focal flabelliform growth of fibroblasts); b -- lymph node of an immune guinea pig, sacrificed after 8 days following infection with 10 million microbial cells; sector of granuloma with predominance of epithelioid cells.