

UNCLASSIFIED

AD NUMBER
AD833627
NEW LIMITATION CHANGE
TO Approved for public release, distribution unlimited
FROM Distribution authorized to U.S. Gov't. agencies and their contractors; Critical Technology; JUN 1966. Other requests shall be referred to Department of the Army, Fort Detrick, Attn: Technical Releases Branch, Frederick, MD 21701.
AUTHORITY
Fort Detrick/SMUFD ltr dtd 15 Feb 1972

THIS PAGE IS UNCLASSIFIED

AD833627

TRANSLATION NO. 1762

~~DDDC~~ CA-18-064-D6-00030(A)

DATE: 2 June 1966

DDC AVAILABILITY NOTICE

Reproduction of this publication in whole or in part is prohibited. However, DDC is authorized to reproduce the publication for United States Government purposes.

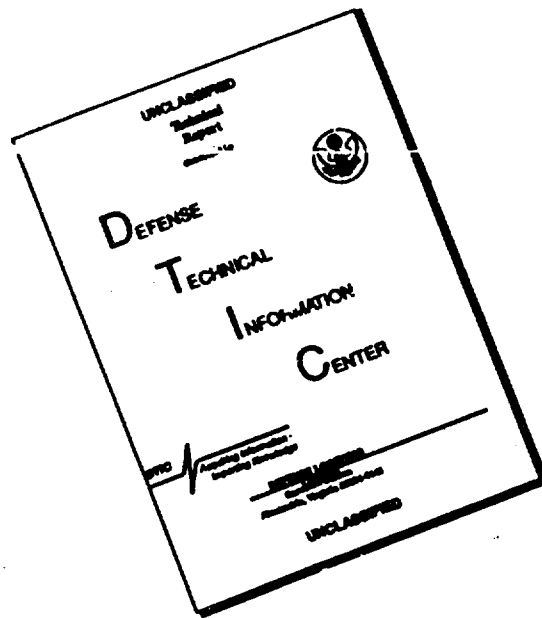
DDC
RECEIVED
JUN 14 1968
RECEIVED

STATEMENT #2 UNCLASSIFIED

This document is subject to special export controls and each transmittal to foreign governments or foreign nationals may be made only with prior approval of ~~DEPARTMENT OF THE ARMY~~

Fort Detrick
Frederick, Maryland 21701

DISCLAIMER NOTICE



THIS DOCUMENT IS BEST QUALITY AVAILABLE. THE COPY FURNISHED TO DTIC CONTAINED A SIGNIFICANT NUMBER OF PAGES WHICH DO NOT REPRODUCE LEGIBLY.

CA-18-064-D6-00030(A)

T-417-1

2 June 1966

VITAMIN K THERAPY IN CUTANEOUS BLASTOMYCOSIS

This translation is protected by international copyright law and is provided solely for internal use at these laboratories. Reproduction or release by recipients is prohibited. Queries concerning availability should be directed to the Technical Releases Branch, Technical Information Division.

FOR DESK USE ONLY. Not for use in Dept of Army Publication. See AR 310-1, Par. 16.

VITAMIN K THERAPY IN CUTANEOUS BLASTOMYCOSIS

[Following is a translation of an article by Ludwig Nékam from the Clinic for Skin and Venereal Disease of the Medical University, Budapest Hungary, Director: Professor Dr. F. Földvari, in the German-language periodical Der Hautarzt (The Dermatologist) Vol 15, 1964, pp 601-604.]

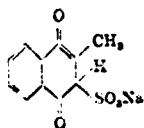
Vitamins besides their so-called "vitamin effect" in the more narrow sense frequently also have other "pharmacodynamic" characteristics which can be used in therapy. It suffices, for example, to mention the vasodilator property of nicotinic acid amide or the direct effect of Vitamin D against tuberculosis granuloma. The fungus- and bacteriostatic effect of Vitamin K can also now be accounted for.

My attention was first called to this condition when in 1948 with my colleague Polgar, I examined the effect of various vitamins and hormones on the growth of pathogenic fungi with bacteria. To this end we prepared 0.05 - 0.25 and 0.5% nutrient media with twelve vitamins (Vitamin A, Vitamin B, Nicotinic Acid Amide, Pantothenic Acid, Folic Acid, P.a.b. [Para-amino-benzoic?] acid, Vitamin B₆, Vitamin C, Vitamin D, Vitamin E, Vitamin F, Vitamin P) and six important hormones and injected these with a staphylococcus strain or a trichophytosis crateriform strain.

The effect of these substances on growth was indifferent, partially promoting or also inhibiting. Only the nutrient media prepared with Vitamin K remained sterile.

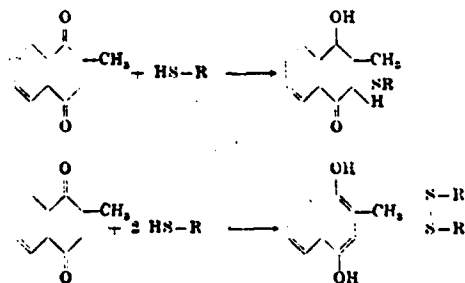
Thereafter, using Angyal with the diffusion and dilution method we established that the synthetic water soluble sulfonated Vitamin K preparation as compared with the majority of pathologically important bacteria and fungi in man exerts a static effect which extends from about 1:5000 to

1:50000 exceptionally. Average values amount to 1:20000. *Pseudomonas aeruginosa* which are known to be resistant also to other antibiotics are especially resistant and in more limited amounts also *Escherichia Coli* which themselves produce Vitamin K in the intestines.



How then can the mechanism of this anti-parasitic effect be clarified? It is known that naphthoquinone compounds represent an oxy-redox system which by taking up two H-atoms is readily converted to naphthohydroquinone and thus keeps an oxidation capability dependent on the redox potential of the substrate. This oxidation capability will be increased under aerobic conditions and by using oxidation media (e.g., 2% H₂O₂-solution), on the other hand it will be reduced by reduction media (eg. 1% vitamin C-solution) as I have been able to confirm with the band method.

Vitamin K loses its antibacterial effect in sulfhydryl, or in 2% cysteine containing media which suggests that the effect exerts itself by oxidation of SH-groups of the enzymes important for the life of the bacteria (pyruvic acid oxidase, succinic acid dehydrogenase). These enzymes are either coupled in the sulfur atom to Vitamin K or oxidised in a manner incompatible with their function; they are transformed from an active cysteine configuration into an inactive form corresponding to cysteine.



In 1949 together with Polgar we used this fungi-static effect to hasten the treatment of a patient suffering from trichophytosis profundus. We injected nine patients each according to the extent and duration of the illness with 0.1 to

0.3 g daily into the granulomatous tissue and could reduce the duration of the illness by about one-third (from 36 days to 24 days) as compared with the usual treatments of X-ray irradiation, vaccination, etc. Our experiments were confirmed in 1951 by Grimmer and Rust in guinea pigs injected with trichophytosis.

From these experiments it can be conjectured that perhaps other fungus infections which are hard to control could also be treated with Vitamin K. Therefore, Foldvari and Polgar in 1950 caused a fist-sized actinomycotic tumor of a cortex to resorb in several weeks by daily injections of 0.05 - 0.25 g Vitamin K-total 5.03. After ten weeks only scar tissue remained.

In 1953 Kimmig and Rieth also indicated these antimycotic properties of Vitamin K.

About 1½ years ago I began Vitamin K treatment of patients suffering from Blastomycosis. Since high doses are necessary for this the toxicity of the vitamin preparation had to be determined first. In extensive experiments I found, in agreement with the literature, that the lowest lethal dose in white mice is about 300 mg/kg body weight and the highest tolerable dose 150 mg/kg. In a 60 kg man, this would be 18 g or 9 g. In therapy, however, I used at the most 3.0 g orally given during the day and 0.1 to 0.3 g intrafocally. In addition the fistulae were rinsed daily with a 1% solution. Intravenous infusion of 0.3 to 1.0 g Vitamin K is also useful in lung candidiasis and septic disturbances, mostly without occurrence of by-effects. In the cases treated the total dose amounted to maximally 60 g orally and the intrafocally applied amount 3 - 4 g.

In Hungary there are two types of blastomycosis: a Papillomatous-verrucose superficial form slowly progressing peripherally, leaving behind a scar in the middle (Gilchrist's disease) and a second, deep form, mostly gluteally localized, which differs, however, from the one described by Busse and Buschke in that it is not inclined to metastasize and that it is mostly produced by various candidic types and less by cryptococcus neoformans. These divergent characteristics were first observed by Foldvari and Florian on a large number of patients and thus provided a new nosologic entity.

Such a division is also useful from the point of view of Vitamin K therapy since in the first group a local infiltration with 1% Vitamin K solution is usually easily carried out and we can expect final cure with high probability. In the deep blastomycosis the manner of ramifications of the

processes of pus retention and the difficult to examine infiltration is much more fastidious. Therefore, local therapy must be associated with higher internal doses: to a certain extent ineffectiveness and recurrence must be reckoned with. A mixed infection caused by Vitamin K resistant bacteria and a frequently occurring resistance of fungus elements also prove detrimental.

A possibility of resistance development can also be established in vitro. In the diffusion method this is expressed in a diminution of the inhibition zone in series inoculations of the terminal culture material. In dilution experiments an 8-fold resistance against a candida-strain was attained by determination of the minimal inhibitory dose. As regards the blastomycosis patients I had the opportunity in sixteen cases to use Vitamin K. In all cases the presence of budding fungi in the partially pathologic giant cell granulation tissue was first established histologically. We regard this finding along with the typical clinical picture as evidence of the pathognomy of these fungi. In four cases the strain could also be cultivated: once cryptococcus neoformans, once an ascosporogenic budding fungus and twice candida albicans.

Intracutaneous testing (mixed vaccines of various strains) is not especially valuable in the estimation of the clinical picture since it is known that cryptococcus neoformans, because its mucous capsule only develops a sparse allergy toward albumin substances; otherwise a positive candida reaction is not decisive, since candida albicans is also present in the mouth and feces of healthy subjects and can thus already develop an allergic reaction in earlier life.

The duration of the disease extends from one-half to forty years in all treated patients; during this time in most cases all possible remedies, thus also nystatin and especially tuberculostatifa, are applied without effect.

As regards the results, all cases show, at the start of treatment, a striking improvement. Three cases of Gilchrist's type as well as four deep cases were symptom-free at the end of treatment. Five patients left the clinic in considerably better condition even though later in three of them various marked recurrences were observed. In a deep blastomycosis the therapy had to be interrupted because of the occurrence of anemia and fever outbursts -- probably conditioned by mobilization of suppurative foci. One case with extensive occurrence in the gluteal region remained unaffected despite high doses of Vitamin K (in total 50 g orally). In him, at the end, only Vitamin K resistant staphylococci



Fig. 1a. Blastomycosis profunda



Fig. 1b. Blastomycosis profunda after 0.12 g Vitamin K intrafocally



Fig. 2a. Blastomycosis profunda



Fig. 2b. Blastomycosis profunda after 15.5 g Vitamin K orally and 1.4 g intrafocally

could be cultivated; later through delivery of a broad spectrum antibiotic significant improvement was achieved. A patient who was already weak at the beginning of treatment died




Fig. 3a. Blastomycosis profunda



Fig. 3b. Blastomycosis after 9 g Vitamin K orally and 0.5 g intrafocally



Fig. 4a. Blastomycosis Gilchrist



Fig. 4b. Blastomycosis Gilchrist after 6 g Vitamin K orally and 2.8 g intrafocally

after average local improvement from a septic syndrome. However, on autopsy fungus elements were no longer demonstrable. Finally a patient suffering from actinomycosis and blastomycosis became symptom-free after several recurrences.

Summary

Average good results in the treatment of cutaneous blastomycosis with Vitamin K are described and the mode of action of Vitamin K is presented.

Bibliography

- Foldvari, F., Dermatologica (Basel) 192, 2 (1951).
- Foldvari, F., and E. Florian, Hautarzt 7, 294 (1955), Dermatologica trop. 1. 103 (1962).
- Grimmer, H., and S. Rust, Z. Haut- and Geschl. Kr. 14, 137 (1953).
- Nekam, L., and J. Angyal, Hautarzt 10, 547, (1959).
- Nekam, L., and P. Polgar, Orv. Hetil. 16, 599 (1949).
- Acta derm. venereol. (Stockh.) 30, 200 (1950); 31, 344 (1951).

- END -