

TRANSLATION NO. 1790

DATE: Aug 1966

AD834613

DDC
RECEIVED
JUL 1 1968
RECEIVED
C

[REDACTED]

[REDACTED]

ON PASTEURRELLA PSEUDOTUBERCULOSIS-INFECTIONS OF MAN

(Following is the translation of an article by Joachim Schmidt, University Institute for Medical Microbiology, Leipzig, appearing in the German language periodical Archives for Hygiene and Bacteriology, 143(4), 1959, pages 262-86. Translation performed by Constance L. Lust.)

In recent years there have been repeated reports of human infection with Pasteurella pseudotuberculosis. Although these illnesses seem to occur quite seldom, they nevertheless deserve increased attention, as our experiences indicate.

A) A look at the literature (An extensive bibliography by Knapp appears in vol. 32 of "Ergebnisse der Mikrobiologie, Immunitätsforschung und experimentellen Therapie")

1. Clinically, the disease appears as an acute or sub-acute or, more rarely, recurring appendicitis (Masshoff, Knapp, Hecker, Haenselt, Becker, H. Schmidt). Pains are found especially in the middle and right lower abdomen with a concurrent rise in temperature to 38°-40° C. The leucocytes are regularly increased in acute cases and the ESG is speeded up. At times a tumor of slight mobility and of thumb's thickness (Haecker) can be felt under the abdomen. Further symptoms like nausea and vomiting in connection with the pressure pain and the clear defensive tautness often lead to the diagnosis of suspected appendicitis. But there have also been cases reported in which the disease appeared as acute gastroenteritis (Knapp³; Braun and Muller) or as sub-acute or chronic enteritis (Kuhlmann and Hermann). And Knapp (cited by Braun and Muller) has even observed a case which had the appearance of a paratyphus.

The clinical symptomatology can therefore vary; but in most cases the symptoms leading to a suspicion of appendicitis predominate and it is not surprising that these patients are laparotomized.

Past. pseudotbc.-infections occur mostly in young people, most often among children between 5 and 10-13 years of age. This is especially true for the cases that appear as appendicitis whereas the gastroenteritic forms can also affect adults. Knapp and Masshoff, Masshoff and Dolle, Graber and Knapp, as well as Haenselt have all stated, that as far as sex is concerned, boys are more often affected than girls.

In operating the appendix shows no signs of disease, but the lymph-nodes in the ileocecal region and in the mesenterium of the small intestine are swollen. The lymphnodes are enlarged singly or in bunches, of soft consistency and inflamed, and the intestinal wall of the caecum and the lower ilium feels doughy and infiltrated. There are slight inflammations of the serosa in the ileocecal region, especially near the

enlarged lymph nodes. The abdominal cavity almost always contains a clear or sometimes slightly cloudy watery exudate. The evidence of the operation is "uniformly typical" (Hecker) and allows a makroscopic tentative diagnosis of a Pasteurella pseudotuberculosis infection. After the operation the symptoms disappear quickly, and there were no complications reported, even without additional antibiotic treatment.

Histologically it is found that the appendix is also not diseased, and only in two cases could Masshoff find in the lymphatic tissue of the appendix reticulocytic inflammation identical with those in the lymph-nodes.

Characteristic for mesenterial lymphadenitis, caused by Pasteurella pseudotuberculosis, is the histological evidence of the lymphnode. In 1953 Masshoff and Dolle described a heretofore unknown form of inflammation of the lymphoreticular tissue, which they characterized as unusual and presumably pathogenetically independent on the basis of morphogenesis and manifestation. The essential histological symptoms "consist in a reticulocytic proliferation that is at first knot-like and then confluent and spreads diffusely and is followed by a leukocytic infiltration, which leads to a sharply circumscribed fusion." For this new mode of infection of the visceral lymphnodes they chose the designation "abscessing reticulocytic lymphadenitis", with which they hoped to describe its morphological peculiarities.

Horstebroek was able to corroborate the evidence produced by Masshoff a short time later. Various other authors (Graber, Schoen, Lennert, Riniker, Haenselt) described their research on mesenterial lymphadenitis caused by Past. pseudotbc., and they led basically to the identical conclusions.

However, the histological changes were described by Masshoff as not specific, but rather only characteristic. The differentiation from lymphadenitis from other causes lymphogranuloma inguinale benign viral lymphadenitis cat-scratch-tularemia which often has largely similar mode of infection in the lymphatic tissues, can be very difficult and is really only to be determined by microbiological examinations. But as Haenselt stresses, this weakness can be partially compensated for by taking into account of the situation of the diseased lymphnodes in the mesenterium. By using these two factors the diagnosis of an abscessing reticulocytic lymphadenitis as caused by Past. pseudotbc. can be histologically determined with the greatest probability.

The explanation of the etiology followed in 1954 through the research of Knapp' as well as Knapp and Masshoff. They were able to isolate Pasteurella pseudotuberculosis from the lymphnodes of three patients who had been operated on for suspected appendicitis. In two cases they were also able to carry out serological examinations of the patients' blood. Through the existence of specific antibodies they were able to prove that there had been immunizing contact between the human organism and the pasteurella germ, which must be considered as the cause of the

disease. Finally, in experiments with guinea pigs infected with the isolated Pasteurella strains, the authors were able to determine the typical pattern of the disease. The histologically discovered evidence was in complete accord with that for the mode of infection of human abscessing reticulocytic lymphadenitis. On the basis of these results it might be considered as proven that abscessing reticulocytic lymphadenitis can be caused by *Past. pseudotuberculosis*.

But other causes can also lead to forms of mesenterial lymphadenitis that will also follow the pattern of a "pseudo-appendicitis". The etiology of these various forms is therefore obviously different. Kjellen was able to breed a cytopathogenic virus by means of a tissue culture from the lymphnodes of a child and to prove the existence of complement forming antibodies directed against the patients own virus strain in the serum. And the diagnosis of benign viral lymphadenitis must also be differentiated, as the evidence of Useri, Wegmann and Hedinger shows. They found enlarged lymphnodes in the mesenterium of three children who had been operated on for appendicitis without concurrent inflammation of the appendix. The intracutaneous reaction for benign viral lymphadenitis was strongly positive. It is not known if there are other viruses which play a role in the etiology. Flamm and Jonas reported a case of mesenterial lymphadenitis in which *actinobacillus lignieresii* could be cultured from the ileocecal lymphnodes. In the blood serum of the patient the authors were able to prove the existence of agglutinins against the cultured bacteria strain. We must therefore consider (non-tubercular) lymphadenitis mesenterialis to be a symptom complex of varying etiology, in which the *pasteurella pseudotuberculosis* is especially important.

As far as the pathogenesis is concerned, Graber and Knapp are of the opinion that the disease begins with an intestinal infection that is than localised in the cecum and the appendix and that the ileocecal lymphnodes are affected secondarily by lymphangitis. Mesenterial abscessing reticulocytic lymphadenitis is, therefore, not a disease itself, but rather a series of changes which can be interpreted as part of the manifestation of an intestinal infection in the sense of a primary complex. (This opinion is supported by the recently reported studies of H. Flamm and W. Kovac (Schweiz. Zsch. f. Allg. Path. u. Bakt. Vol. 21 (1958); 1127) as well as by their experiments with animals.) Riniker, on the other hand, thinks that the ulcerations and irritations of the intestinal walls are not primary infections, but rather secondary lesions.

Pasteurella pseudotuberculosis is a gram-negative organism whose special morphological characteristic is a bipolar strain; as is typical for the entire class of *Pasteurella*. The germs grow on the selected host for the culture of gram-negative intestinal bacteria (Endo, Gassner) as well as on blood agar within 24 hours in the form of round half-spherical arched and smooth colonies, which are at first light and clear and only develop a slight gray-yellow discoloration (Knapp) later. Hemolysis is missing on blood agar.

Past. pseudotuberculosis is the only member of the pasteurilla group with mobility. Proof of the mobility of strains isolated from humans is difficult however, and is only successful at an incubation temperature of 22°C not 37°C. In comparative experiments Baders U-flasks proved superior to the U-tubes after Vahlne for this process (Knapp¹).

Dextrose is split in the formation of acid, lactose and saccharose are not, the gelatine liquefaction is negative, there is a breakdown of urea. These characteristics, as well as the testing of further biochemical factors enable us to make a sure diagnosis of Past. pseudotuberculosis and to separate it from other bacterial strains of the pasteurilla group (Past. multocida, Past. tularensis, Past. pestis).

In animal experiments, for which guinea pigs are especially useful, after intraperitoneal infection there appears the pattern recognised as pseudotuberculosis, of which the animals usually die within a few days. There is a viscous exudate in the abdominal cavity, spleen and liver are covered with gray-white nodes the size of a millet seed or somewhat larger, which have necrotic destructions in the center. The same characteristic changes are recognized in the pea-to-hazel nut sized mesenterial lymph nodes. The histological evidence coincides with those of the human Past. pseudotbc. infection and show the pattern of abscessing reticulocytic lymphadenitis (Knapp and Masshoff).

Pasteurella pseudotuberculosis is serologically not uniform, and we can (according to Thal) distinguish 5 serological types (Type I-V), which differ in their O-antigen structure. Types I and II can each be subdivided into 2 sub-types (IA and IB and IIA and IIB), which is not possible with Types III, IV, and V. All past. pseudotbc. types except Type IV have the same geisselantigene.

Their specification is not necessary for the serological differentiation of the types. A sure diagnosis is not possible on the basis of clinical symptoms alone, but rather only with the help of bacteriological-serological methods.

The bacteriological-serological diagnosis can be determined by proving the existence of the disease causing agent in the blood or in the removed lymph nodes. This is a very difficult procedure, since it is often carried out too late (Knapp²) so that one can no longer expect to find any live infectious agents. On the other hand there is the possibility of proving the existence of specific antigens. For the above-mentioned reasons, this procedure has greater significance for the diagnosis of human past. pseudotuberculosis infections. One uses Widal's agglutination procedure, using past. pseudotuberculosis antigens. In the examination of patient sera it is necessary to use live or carefully killed (at 65°C), or formalinized or phenolized antigens, since these are the only one (according to Knapp) with which reliable and useful results can be obtained, whereas cooked or autoclaved antigens are often not agglutinated, or only on very low titer level. If one absorbs the sera with cooked antigens they no longer react even with live antigens. Knapp explains this reaction by assuming the existence of another O-antigen,

thermally unstable in its agglutination and propensity to agglutination but thermally stable in its binding of agglutinins, which can greatly hinder the formation of agglutinogens against the thermally stable O-antigen in the organism under conditions as yet unknown to us.

Knapp⁵ recommends the use of several Type I strains as antigens on the Widal procedure since it has been observed that the agglutination ability varies so greatly that one strain produces none whatsoever. The titer is most often higher with the homologous Pasteurella strain (that is, from the patient himself) than with heterologous strains, as has already been discovered by Saisawa and Roman using animal sera (cited in Knapp²). Perhaps this explains those cases in which the anamnesis as well as the clinical and histological evidence point to the diagnosis of past. pseudotuberculosis, but there is no serological proof.

Antibodies against the H-antigen of past. pseudotuberculosis occur very seldom in humans, and if at all, then only on low titer levels, since the development is greatly hindered at body temperature (Knapp⁵).

At least two blood tests, taken 10-14 days apart are necessary to determine a rise or decline in the antibody picture in a positive case. The results of a single test are obviously not as trustworthy as those of a series of tests. According to Hermann (1957), an agglutination titer of 1:160 and higher should be considered as proof. Knapp (cited by Braun and Muller) considers only titers of 1:100 and higher as positive in recently discovered cases.

Recently Knapp⁵ has succeeded in proving the existence of incomplete blocking antibodies (univalent antibodies) in the cases of two patients whose clinical and histological symptoms pointed to past. pseudotuberculosis, while Widal's procedure showed a lack of agglutinogens and thereby gave serological proof of the diagnosis. There occur cases in pasteurilla diseases (similar to those in brucellosis diseases) in which the immunizing processes express themselves only in the existence of blocking antibodies, which makes it advisable to use the blocking-test in cases where clinical evidence arouses suspicion.

Discoveries up to this point indicate the specialization of the Widal Agglutination Procedure for serological types I, III and V (Knapp 2,5) of the test strains. Paragglutinations with other antigenic are not known. However, there do exist antigenic relations between Past. pseudotuberculosis Type II and Salmonella bacteria group B (O-antigen 4), as well as between Past. pseudotuberculosis type IV and Salmonella bacteria of group D (O-antigen 9) (Knapp 2, 5). Positive Widal titers with test-strains of type II and IV can, therefore, be on an unspecific nature and can only be used to prove the existence of a pasteurilla infection if the serum still reacts positively with the pasteurilla antigen after absorption with the salmonella group B or D.

Complement-forming antibodies are not found with the same regularity as agglutinogens in the case of these illnesses, and they are lacking in a large number of cases (Knapp and Steuer). For this reason the Widal Agglutination procedure is preferable to KBR.

The following is known about the epidemiology of *Pasteurella pseudotuberculosis* infections: The main reservoirs for the agents are rodents such as field mice, rabbits, hares, hamsters, guinea pigs, squirrels, rats, and a red beaver. This led to the former name of the bacteria - *Bact. pseudotbc. rodentium* (Pfeiffer 1939). According to Olt it is the field mice above all that spread the germs. Other animals, such as fowl (turkey, chickens, and pigeons), canaries as well as cats, foxes, deer (Miesner) and dogs, horses, cattle and goats (Olt) are less often infected. The animals fall ill of an acute septicemia or a chronic pseudotuberculosis. Olt has suggested that these diseases be given the name Rodentiosis. The *past. pseudotbc.* is passed by the animals in stool or urine and can be found in duct, earth, stream water and animal feeds (after Haecker). The germs have little resistance to heat or drought but show almost no sensitivity to cold (Poppe).

We are therefore, dealing with an animal disease that is only occasionally carried over to humans, in which case the germs enter the intestinal canal orally. Knapp and Maschoff believe that the method of infection "is probably not only direct contact with animals (cats, rats, rabbits, chickens), as is assumed by many." Nevertheless, in the cases studied by Haecker 11 of the 16 answers to questionnaires he sent indicated that the children had had close contact with animals (dogs, cats, rabbits, chickens)-"a noteworthy result for a large city like Hamburg."

In this connection it is interesting to note the case of a farmhand who milked cows who suffered from pseudotuberculosis (bacterio-serologically and histologically proved) studied by Graber and Knapp. They did some testing of his environment and found that five of the fifteen cows he milked had positive agglutination titers with *past. pseudotuberculosis* antigen (1:20 to 1:200). Infection from human to human have not yet been noted nor do we have any knowledge of possible passing of the germs by humans in stool or urine.

According to the studies of Haenselt, Knapp (cited in Haenselt) and Haecker, the number of human infections varies seasonally. They were especially numerous in the spring, but also occurred in the fall and winter months. This leads Haecker to suspect a connection with the Rodentiosis of rodents, which occurs more frequently after periods of rain.

2. Before the etiological clarification of abscessing reticulocytic lymphadenitis there were only a few cases of human *past. pseudotuberculosis* infections known in medical literature. In the literature available to him, Knapp found 15 cases that could be considered as bacteriologically proven *Pasteurella pseudotuberculosis* infections. They generally took the course of severe septicemic (sometimes typhous) general infections which mostly ended in death. The diagnosis generally followed after death by demonstrating that pathogens were present in the organs (liver, spleen) which showed the appropriate suspicious pathological and anatomical changes.

To this severe form of the disease Knapp and Maschoff opposed the benign form of abscessing reticulocytic lymphadenitis, which generally

appeared as appendicitis. To this group belong the cases described by Albrecht in 1910 and by Picchaud in 1952, which therefore represent the first bacteriologically proven cases of pseudoappendicitic diseases. Albrecht reported on a 15-year old boy who was operated on for appendicitis, but did not show the expected symptoms. It was possible to isolate past. pseudotuberculosis from a lymphnode in the iliocecal canal by means of an animal experiment, and the blood serum proved to have agglutinating antibodies to the homologous strain. In Picchauds case a girl was operated on for appendicitis; past. pseudotuberculosis was cultured from a mesenterial lymph node.

Knapp has the largest number of case observations of abscessing reticulocytic lymphadenitis. In a paper in 1956 he listed 99 bacteriologically and (or) histologically proven cases. In 59 cases there was agreement between the clinical picture and the serological and histological examination. The remaining 13 cases were only proved histologically or bacteriologically-serologically. Knapps was able to prove the pathogens 11 times all together (10 times from lymph nodes and once from the blood). The majority of the cases was caused by strains of type I, infections by the other past. pseudotuberculosis types occur very rarely in humans. Knapp^s was able to prove one case caused by type IV and two by type II serologically. Type III infections were considered probable in 3 cases, but could not be proved due to lack of clinical evidence and examinations. Type V was isolated from two patients who had been operated on for appendicitis. The serological and histological results were negative in spite of the proof of organisms. In an animal experiment the typical changes were shown.

After Knapp and Masshoff had drawn attention to the benign form of pasteurellosis, similar infections were noticed elsewhere. They do not seem to be as unusual as was previously assumed and this is proven by the endemic occurrence in the vicinity of Tübingen (Knapp). From 10 histologically proven cases Knapp and Graber were able to present bacteriologic and serologic proof of a past. pseudotuberculosis infection as well. The cases studied by Becker as well as by H. Schmidt, which also appeared as appendicitis showed the typical histological changes. Bacteriological and serological tests were not carried out.

Kuhlmann and Hermann (Essen) reported eight patients who had suffered for years from unusual intestinal troubles, and whose clinical and x-ray pictures indicated chronic enteritis. Two other patients had fallen ill with a sub-acute enteritis. In all cases the Widal Aggl.-Procedure with Past. pseudotbc.-antigen resulted in titers of 1:80 and higher. Another case caused by past. pseudotbc. was described by Braun and Müller (Erlangen). A 2 year old child had fallen ill with enteritis. In the serum were antibodies against past. pseudotbc. type I with a titer of 1:320. Serological tests on other children with various stomach disorders showed no similar findings.

In recent years Haenselt has seen 33 histologically proved infections

that occurred in northern Thuringia. In 26 cases serological tests were made; in 24 cases they were positive, in only 2 cases were no specific antibodies found. The agglutination titers of the blood samples taken 6 to 36 days after the operation varied from 1:20 to 1:3200.

Haecker reports on 20 histologically diagnosed past. pseudotbc. infections. Bacteriological tests were possible in 7 cases in which it was possible to prove presence of organisms in the culture and in the animal test in one case, and in the animal test only in the case of another child. Blood samples from 10 patients were available for the serological agglutination procedure, which was positive 7 times with titers between 1:20 and 1:80.

In the vicinity of Leipzig there have also been many cases in which histological evidence from the lymph nodes or from the lymphatic tissue of the appendix has indicated past. pseudotbc. infection (Seifert).

Studies Conducted

1. In the framework of studies which served partially to determine the degree of infection among the people, and partially to study clinically suspicious cases we have in the last few months observed quite a few cases of past. pseudotbc. infections.

Materials and Methods

We performed bacteriological and histological studies on lymphocytes, as well as the Widal reaction on sera. Five serologic types of Past. pseudotbc. were used in the Widal agglutination test. Test strain (I¹, 1779II, II², IV, 32^{IV}, 25^V) were incubated 48 hours on agar slants (at 22° C), then washed with physiological saline and put into the Widal test. (500 million organism/ml.) Sera were used 1:20 to 1:640. After 20 hours at 52° C the tests were read. As controls rabbits were injected with serum, boiled Past. pseudotbc.-antigens of type I-V. If no agglutination occurred with the patients serum the blocking test was used by adding immune serum.

One half of the lymphocytes were fixed in formalin and examined histologically. The remaining $\frac{1}{2}$ was examined bacteriologically. We inoculated nutrient broth and 5% sheep's blood-agar, and then transferred the lymphocytes into grape sugar broth. Later on we used a part of the lymphocytes in animal trials. Incubation of the nutrient plates was for 5 days and 37° C. Endo and gassner-nutrient agar as well as blood agar were inoculated at appropriate times.

Results and Discussion

In the following section the results of the bacteriological and serological tests for past. pseudotbc. infections as well as the clinical and histological evidence will be presented.

Case 1.

J. St., 9-year old boy. Since 1/17/58 lack of appetite and strong

pains in the lower right quadrant. Temperatures not measured. Nothing is known of contact with animals, but the child is said to play in garbage dumps.

Result of Examination: Strong pressure pain at the Mac Burney with considerable tension.

Diagnosis: Acute appendicitis.

Operation: On the 1/20/58: appendix is not affected, shows only some malformation, highly inflamed lymph nodes the size of a hazel- or walnut in the mesenterium of the cecum. A lymph node directly adjoining the cecum is removed and sent for histological examination. Large quantity of serous exudate in the abdomen.

Development: Would healing normally. Tuberculin test 1:1000 negative. BSG⁺ at first still rapid (40/87 mm). Since histological results were now known, streptomycin therapy (total: 6g) was used. The depression normalized itself, all irritation ceased.

Results of the Pathologic Anatomical Tests: (Prof. Dr. Guthert, Pathol. Inst. of Med. Academy Erfurt) macroscopic: several gray-white lymph nodes up to cherry-size, partially grown together in some cases, in which there are numerous irregularly bounded yellow-ish areas. Microscopically the structure of the lymph node is largely destroyed. Many nodes consist only of reticulo cells. At other places there are large diffuse areas.

Diagnose: Abscessing reticular lymphadenitis

Serological Tests: Serum from 2, 15, 58. Widal's Agglutination Procedure with past. pseudotbc.-antigen:

Type I 1:320+

1:640(+)

Type II, III and IV negative

Type V 1:160+

Serum from 4.2.58: Widal Procedure

Type I 1:40(+)

Type II, III and IV negative

Type V 1:40+

Serum from 5.6.58: Widal Procedure

Type I 1:20+

Type II, III, IV

Type V, 1:40(+)

In all three sera the agglutination tests with the usual salmonella- and shigella- as well as abortus bang antigens were negative.

Epicrisis: According to the anamnesis as well as clinical and operational evidence this was a typical past. pseudotbc. infection of the benign type which is histologically and serologically supported.

As far as the type of agent is concerned, the histological evidence indicates a type-I infection. In reduction of 1:640 the serum still showed a clearly recognizable agglutination of the antigen from serological type I, the titer values with the antigen from type V were essentially lower. We would like to consider this as the result of an infection occurring some time back. The low rise in the titer value with the antigen V must be considered to an anamnestic reaction. The first blood sample was taken four weeks after the beginning of the infection. The peak of antibody building had already been passed. Six weeks later only a low antibody picture could be determined.

Case 2.

R. T., 9-year old boy, fell ill a few days before admittance with acute stomach pain. No contact with animals in recent months, only earlier (from March to September 1957) did the child have contact with many animals when it stayed at a farm after its mother had fallen ill with tuberculosis.

Symptoms: Pressure at the Mac Burney only moderate, so that a sub-acute appendicitis was suspected. Therefore, the operation was not performed the same day, but one day later.

Operation: 4/1/58: Appendix macroscopically unchanged. In the ileocecal angle there were a number of plum-sized lymphnodes, one of which was removed.

Development: No complications, no supplementary medicinal treatment necessary.

Pathological-Anatomical Symptoms: (Prosektor Doz. Dr. Seifert) loosening of the lymph node structure with swelling of the reticulo collis and sinus endothelia; vesicular infiltration of the lymph node capsule; no abscessing.

Diagnosis: Unspecific lymphadenitis and perilymphadenitis.

Bacteriological Symptoms: Cultures sterile.

Serological Tests: Serum from 4/1/58: agglutination test with past. pseudotbc. antigen:

Type I 1:6400+
1: 12800 (+)
Type II-V negative

Agglutination with salmonella-, shigella-, and abortus bang antigens negative. Serum from 4/10/58: agglutination test with past. pseudotbc. antigen:

Type I 1:3200+
1:6400 (+)
Type II-V negative

Agglutination with salmonella typhi, H-antigen 1:100+, with the remaining salmonella-, shigella- and abortus bang antigen negative.

Serum from 4/25/58: Agglutination test with past. pseudotbc. antigen:
Type I 1:200+
Type II-V negative

Serum from 6/11/58: Agglutination test with past. pseudotbc. antigens:
Type I 1:100+
Type II-V negative

Agglutination test with the usual salmonella-, shigella- and abortus bang antigens was negative in the last two series.

Epicrisis: The case was a past. pseudotbc. infection of the benign type which appeared as sub-acute appendicitis and could be proven serologically.

The serological test clearly indicate a type I past. pseudotbc. infection. At the time of the operation there was a very high antibody titer, the disease had obviously been present for some time, so that the building of antibodies could begin and reach its highpoint. The titer remained at nearly the same level for 8 days, and then sank again quickly in the following weeks.

The negative histological evidence only seems to be contrary to the serological result; for it is possible that the pasteurilla infection (like tuberculosis) does not affect all the lymph nodes in the ileocecal region in the same way. On the basis of serological results, the disease had reached the stage in which histological changes were to be expected. Knapp 5 has also observed such cases.

Case 3

R. D., 12 year old boy, fell ill on the 4/8/58 in the evening with pains in the lower right quadrant. Temperatures up to 39°C+. No vomiting, no diarrhea. Besides 2 birds (zeisig, stieglitz) there are no domestic animals with which the child could have come into contact. But he plays in a meadow near the house and in a sandbox in which there were dog feces.

Symptoms: Strong pressure pain in the lower right quadrant with skin tension. Leukocytosis of 15,000.

Diagnosis: Acute appendicitis

Operation: On the 4/8/58 irritation exsudate in abdominal cavity. Ileocecal region shows a considerable serous inflammation with numerous greatly swollen lymph nodes. The appendix shows only slight inflammation outwardly. A lymphnode is removed for bacteriological and histological examination.

Development: Without complications.

Histological Results: from the cherry-size lymphnode (Prosektor Doz. Dr. Seifert): strong cell proliferation in the lymphatic sinus with

swelling of the sinus endothelium. Loosening of the lymph node structure with swelling and proliferation of reticulo cells as well as permeation with leucocytes; swelling of the reaction center: clear cell infiltration of the lymph node capsule; also increased number of plasma cells.

Diagnosis: Severe lymphadenitis and perilymphadenitis with sinus catarrh and lymphoreticular hyperplasia (Ill. 1 and 2).

Bacteriological Evidence: The solid cultures remained sterile. In the grape-sugar bouillon there appeared slight diffuse cloudiness on the third day. Inoculating resulted in gray-white smooth round colonies on blood agar as well as on the Endo- and Cassner hosts without any change in indicator color. No hemolysis. Gram-negative, short, thick: coccoid stab slightly rounded at the ends and partially of bipolar coloring. There was good mobility in the U-shaped flask according to Bader.* (I am thankful to Dr. Knapp of the Hygiene Institut of the University of Tübingen for carrying out this test).

The organisms did not spread out throughout the U-tube, despite several passages through broth. Growth was for about 3 cm. After inoculating agar, cloudy zones appeared near the needle inoculum. The biochemical observations were (incubation up to 30 days at 37°C.)

Indole 0; H₂S formation 0; urea (urea-glucose-agar n. preuss) 0; glucose acid +; Gas 0, lactose 0, sucrose 0; maltose +, mannitol +; dulcitol 0; trehalose +; inositol 0; rhamnose +, inulin 0; salicin; arabinose; adonitol; xylose +, sorbitol d-tartrate 0, nitrate reduced to NH₃ and nitrite; liquefaction of gelatin 0, methylene blue is reduced without coagulation.

The strain was tested in the rabbit-immune serum with antibodies against *Past. pseudotbc.* type I and titer 1:800.

Animal Test: (1 ccm of a 24-hours old bouillon culture was injected intraperitoneally into a guinea pig) typical symptoms of pseudotuberculosis; the animal died on the sixth day. There was a slightly cloudy serous exsudate in the abdominal cavity. The mesenterial (especially ileocecal) lymphnodes were enlarged, at times clumped together in large numbers, and showed gray-yellow necrotic areas. Millet seed sized areas with similar characteristics were found in the liver and spleen, in the lymphatic tissue of the lower ileum and the large intestine and singly in the kidneys. From the pathological changes in lymphnodes, liver and spleen it was easily possible to isolate the pathogen in pure culture. The histological results were also typical (Ill.3).

Bacteriological Diagnosis: *Past. pseudotuberculosis* type I.

Resistance to the main antibiotics was determined by the use of the plate test, using blood agar and various antibiotic concentrations. The tests were read after 24 hours. Incubation temperature 37°C, at which the absolute arrest of growth was determined. These are the results.

Chloronitrim - absolute arrest of growth at 5y/ml.
Streptomycin - absolute arrest of growth at 5y/ml.
Aureomycin - absolute arrest of growth at 10y/ml, considerable decrease at 5y/ml.
Terramycin - absolute arrest of growth at 10y/ml, strong decrease already at 5y/ml.
Penicillin - absolute arrest of growth at 5 IE/ml.

Serological Tests: Serum from 4/2/58: Agglutination-procedure with Past. pseudotbc. antigen:
Type I-V negative

Serum from 5/7/58: Agglutination-procedure with Past. pseudotbc. antigen:
Type I 1: 640+
Type II-V negative

Serum from 6/9/58: Agglutination-procedure with Past. pseudotbc. antigen:
Type I 1:200+, 1:400 (+)
Type II-V negative

In all 3 sera there were no indications of antibodies against salmonella-, shigella- and abortus bang antigens.

Epicrisis: A bacteriologically and serologically proven infection with past. pseudotbc. type I.

Thanks to the availability of many blood samples it was possible to follow the immunizing process. Up to the time of the operation it was impossible to determine any specific antibodies in the blood serum in spite of a positive proof of the presence of the organism, not even with the blocking-test. The infection must therefore have been in the early stages. Four weeks later the titer was 1:640 and one month later it had already sunk again to 1:200. The titer levels obtained with the patients own strain were the same as those obtained with the test strain used otherwise. In the first serum test the patients own pasteurilla strain also showed no antibodies.

Due to the early discovery of the disease, it was possible to isolate the pathogen from an ileocecal lymph node. The cultured bacteria strain showed the typical morphological, cultural, biochemical and serological characteristics of Past. pseudotuberculosis. In a comparison with the three pasteurilla strains described by Knapp (Knapp & Masshoff) there was only one difference - in the salizir-splitting test, which was positive with our strain. A similar positive reaction has been reported by Schutze, Bergey as well as Winkle (with exceptions). The reports on the ability to form H₂S vary: according to Winkle, Hallmann and Kaufmann they are negative, according to Bergey positive. Our strain formed no H₂S, even after thirty days of incubation in lead acetate agar at 37°C. Proving mobility turned out to be very difficult, as Knapp had already found in his studies, and was impossible to do with certainty with the usual

methods. Only by using the U-flasks according to Bader was Knapp able to observe clear mobility.

As far as reaction to various antibiotics was concerned our strain reacted like the pasteurilla strains studied by Knapp 3. Only the aureomycin values for Aureomycin and Terramycin were somewhat higher with our strain.

The histological report on the lymph node is of particular interest (Ill. 1 and 2). It shows a severe lymphadenitis with reticular hyperplasia but lacks the typical signs of abscessing reticulo-cytic lymphadenitis. There is reticular cell-proliferation with increased leucocytic saturation, especially around the edges; that is, changes described by Hasshoff as the first phase in the development of abscessing reticulo-cytic lymphadenitis. Node-like formations of reticulo cells are not yet evident. We might interpret the histological evidence as the beginning of mesenteric lymphadenitis, caused by pasteurilla pseudotuberculosis. This would also be in agreement with the results of the bacteriological and serological tests.

Case 4:

A. P., 58 years old, fell ill 5/24/58 with pains in the upper quadrants, vomiting and varying diarrhea, at times constipation also. BSG 46/77 mm, nothing unusual in the blood picture. He had similar complaints in the summer of 1954, when an anacidity with still exists today and an injury to the liver parenchyma were diagnosed. No contact with animals.

Symptomatic treatment, 8-10 days after disappearance of discomforts.

Serological Tests: Serum from 6/2/58 Aggl.-procedure with past. pseudotbc. antigen.

Type I-IV negative
Type V 1:3200 +, 1:6400 (+)

Serum from 6/18/58 Aggl.-procedure with past. pseudotbc. antigen:

Type I-IV negative
Type V 1:2000, 1:400(+)

In both sera the Widal Agglutination Procedure with salmonella-, shigella- and abortus band antigens was negative.

Epicrisis: The 58 year old patient had a serologically proven past. pseudotbc. infection of type V, which developed clinically with gastro-enteritic symptoms.

Infections caused by serological type V of past. pseudotbc. have been very rare so far. Only Knapp 5, reported 2 cases, mentioned above. It must be remembered, however, that many times only the type I antigen is used in serological tests, so that type V infections may have escaped detection. Even if they do occur much less frequently than type I infections, it is necessary in practice (as Knapp emphasized) to use all five pasteurilla antigens. As far as the clinical picture is concerned,

it has already been reported by Knapp 3 as well as Kuhlmann and Hermann that we should expect the past. pseudotbc. infection to appear in the form of gastroenteritis or other uncharacteristic intestinal troubles in adults. In the case studied here, these symptoms predominated, and no pains in the lower right quadrant were ever reported.

Case 5:

A. B., 8 year old girl, pain in body since 5/25/58. She loves animals, has frequent contact with cats; pain on Mac Burney.

Findings on operating: Appendix red at distal end. On the small intestine large gland-like bodies (big as hazelnuts). Post operative events-no complications.

Histological Findings: Swollen lymph nodes showed acute lymphadenitis and perilymphitis, lymphocytic hyperplasia.

Serological Investigations: Serum 6/13/58, Agglutination tests with pasteurilla strains, negative.

Serum 7/16/58 with strains I-IV negative, with antigen V, 1:40 +

Indirect Race-Cooms-Test with Past. pseudotbc.-antigen

Type I negative

After absorption with *S. paratyphi* B agglutination (which appeared with antigen II was no longer visible. Widal test with salmonella, shigella, abortus bang, and tularemia antigens were negative; KBR with orinbosis antigen (Behring works) negative; KBR with a virus antigen; serum 6/13, 1:20 and 1:40 negative.

Intracutaneous injection with antigen from lymphadenitis-virus (9/28/58) negative.

Episcirisis: This case was an acute appendicitis (lymphadenitis) which could not be definitively proven to be a pasteurilla infection with serological techniques.

In the serum tests it was only possible to prove with the antigen V antibody in low titer. It was possible to show a rise in titer. Floccing antibodies were missing, the indirect Race-Cooms Test was negative in the last two sera with use of antigen type I. The original agglutination with antigen II proved to be a paragglutination with salmonella antibodies. Based on these negative results as well as the positive histological findings we used other pasteurilla strains as antigens, as was recommended by Knapp; type I, II, III of four strains were used. Perhaps a higher agglutination titer would have been observed with use of other strains of type V. The present findings do not suffice to prove serologically a Past. pseudotbc. infection.

A differential diagnostic procedure was provided by the mesenterial course of the benign lymphadenitis virus infection (cat-scratch). This

was ruled out because all tests performed were negative in this regard. The diagnostic value of KBR with the antigen of a virus of the Psittacosis-Lymphogranuloma group (Mollaret, Francis and Chairman) was less applicable here (Zwissler). In our case the KBR was also negative with Ornithosis antigen, as with a virus antigen of sheep, which can be used to demonstrate Psittacosis-Ornithosis infections according to Beer. Therefore in the last analysis a Past. infection can only be suspected with high probability, since other infections with similar morphology were excluded. Definite serological proof for the presence of a Past. pseudotbc. infection was not brought forth, however.

Case 6

D. K. 15 year old patient became ill with pains in the right lower abdomen, no vomiting, temperature 39.5°C.

Findings 5/20/1958; minimal pain with pressure on Mac Burney. RSG 50/78 mm, leukocytosis of 12,000, temperature 38°C. Diagnosis; subacute appendicitis, possibly consider lymphadenitis mesenterialis. Treated conservatively with bed rest, diet. After 3 days no more complaints and temperature normal. No further complications.

Serological investigations: Serum 5/22/58, Aggl. test with past. pseudotbc. antigen.

Type I 1:320+, 1:664 (+)

Type II-V negative

Serum 6/3/58

Type I 1:6400+, 1:12800 (+):

Type II-V negative

Serum 6/13/58

Type I 1:660+, 1:1280 (+)

Type II-V negative

Spicrisis: In the 15 year old patient clinically mesenterialistic lymphadenitis was suspected and it was serologically shown to be a pasteurilla infection. With conservative treatment improvement was rapid.

Case 7 and 8

K. H. Sch. mal 16 years; P. R., male 16 years; M. S. female 10 years. All three contained the following similar observations. Sera was studied several times (animal values 1:3200+) and it was definitely shown to be Past. pseudotbc. infections. These cases showed no peculiarities of special interest.

2. The following facts became evident when a complete study was made about Pasteurella pseudotbc. infections in man:

The clinical illness corresponded to that described by Knapp and Mashof and was similar to a subacute or acute appendicitis. In only one case did gastroenteric symptoms predominate.

The course was always without complications, even if no antibiotic therapy was used. Only in the first case was streptomycin employed.

In reference to age of our patients our results support those of others, Eight children, 8 to 16 years, one adult, 58 years. The adult became ill from gastroenteritis, whereas all others showed appendicitis symptoms. Males predominated in our report.

Only in case 5 (questionable Past. infection) was contact with animals apparent. However, in two other children (cases 1 and 3) a possibility existed that they may have had contact with animal waste products in their play areas. To answer this would like to agree with Knapp that in order to minimize transfer of germs to humans direct contact with animals should be avoided. Another important factor is transmission of organisms in dirt, etc. It is usually rather difficult to determine the "chain of infectivity."

Since our observations were conducted only over several months we shall refrain from discussing long-term diseases (years). A sure clinical diagnostic method is not at hand, as is apparent from the literature, one can merely suspect that a Past. pseudotbc. infection is present. Of eight cases, six were operated on because of a diagnosis of appendicitis. In case 6 conservative therapy was recommended because of suspicion of mesenterial lymphadenitis, while in case 4 it appeared to be gastroenteritis.

The histological findings of the mesenterial lymphnodes allows for a definite diagnosis with high probability but not 100% surety. Other infections may elicit similar histological alterations.

To ensure that an infection is definitely Past. pseudotbc. one must employ bacteriological and serological methods. Probably serologic methods are of greater importance. Demonstrating the presence of pathogens from the blood of lymph nodes is difficult (Knapp, Necker). We could only grow out Past. pseudotbc. once in a total of 4 lymph nodes. This could be dependent on the time the specimen was taken (Knapp). In case 3 this appeared to be the case, where the operation was performed on the first day of illness. Blood serum taken simultaneously contained no specific antigen. However, consideration must be given to the differential susceptibility of individual, ileocecal, lymph nodes. Since the organism does not require much in terms of nutrients, no great advances are expectable from merely increasing the nutritional quality of the nutrient media. It is improbable that a better medium will give a better cell growth. Perhaps animals like the guinea pig, which is in routine use, in aiding diagnoses, will prove to be more sensitive and will help in identifying the infection more effectively and rapidly. It is relatively easy to differentiate gram negative Pasteurella with the stab method using commonly used bacterial methods. This was more extensively discussed in the literature section, as under case 3.

Since the organism can only be isolated infrequently the specific antibody in the blood serum plays a more important role. The method of choice was the Widal agglutination test. A single determination of the pasteurella Widal test, especially if titers are not high, may not be definitive. At least two blood specimens are required in order to follow

the titer over a period of a few weeks. The borderline titer we will call values of 1:100 (Hermann and Knapp). Titers of 1:80 must be viewed with suspicion, but should lead to further determinations on the serum. Low values, of 1:40 can be observed in normal, well humans (Hermann's own). A positive finding here does not say much about a Past. pseudotbc. infection, but merely shows that an infection had occurred.

In this regard one must be cautious in using assumptions which may confuse the issue later. In case 1 the reaction of antigen V in the presence of a type I-infection is a case in point.

The use of pasteurilla titers of types II and IV in the sense of meaning past. illness, is only possible if the corresponding antibodies can still be demonstrated after absorption with salmonella antigen (Groups B, D). We corroborated the experiences of Knapp in case 5.

Of 8 reported cases of Past. pseudotbc. infections, 7 were of serologic type I and only one type V. Even if type I infections predominate, one must nevertheless consider that the more rare ones may contain Pasteurella type also. Using Widal's test strains of all 5 types should find utility. If these are negative other strains with a differential ability to agglutinate should be used, as was recommended by Knapp.

It has already been mentioned in the literature that the "Zone-phenomenon" of incomplete blocking antibodies should be considered. We did not observe any cases of this.

Specific antibody was demonstrable in those cases where the pathogen could be cultured out, because the antibodies are an expression of the active release processes of the host with the pathogen. Their presence represents an important member of the proof of infection "chain" as originally outlined by Robert Koch.

An important question after its determining by the agglutination test, is the course of recovery (healing) from a past. pseudotbc. infection. In our cases, which were simple and free from complications, antibody titers were still demonstrable 2-3 weeks after the operation. Then a rapid decrease ensued which in some cases went to "below-normal" values. Serologically and clinically it was shown that complete recovery was at hand. This is seen even in cases of rapid recovery (clinically). It may be possible that germs can still be in the mesenteric lymph nodes (Knapp 5). Therefore the serological course may be of prognostic as well as diagnostic importance.

In concluding mentions should be made of the discrepancies between bacteriological-serological results on one side and histologic results on the other. This sort of pattern, of "non agreement" was already observed by Knapp. Case 2 of our report is similar in that the serologic data indicated Past. pseudotbc. infection, but this was not substantiated histologically. In the discussion it was mentioned that the differential susceptibility of the ileocecal lymph nodes may be responsible for this.

The reverse result; positive histological finding with no antibody formation was again reported (Knapp 5, Graber, Haenselt, Hecker). It must be mentioned that more than 10-14 day intervals are needed in order to give

an indication when antibody is made. Also the zone-phenomenon and the blocking test should be performed to show the presence of incomplete antibodies. If possible the Coombs test should be performed; no previous reports are available about this. In case of negative results more strains of the same type should be used, before concluding that Fast. pseudotbc. are absent. But as in illness -c- 5- there are still illnesses which do not completely conform to these considerations. A final explanation can only be expected from microbiological research, which also includes other infections as cat-scratch illness, tularemia and still unknown viruses.

Recently the experiences of Knapp and of Masshof demonstrated that Fast. pseudotbc of man is of more importance than was usually assumed previously. Also, when a case is suspected clinically, bacteriologic, serologic and histologic evidence must be included to ensure the correct diagnosis.

Summary

Following a review on the literature a report is given on 9 clinical cases (one questionable case) due to infection by *Pasteurella pseudotuberculosis*. Eight cases were confirmed serologically and occurred as a benign form under the clinical picture of an appendicitis (seven cases) and gastroenteritis (one case). Seven cases were caused by type I and one case by type V. In one case the causative microorganism was isolated from an excised mesenteric lymph node. The possible bacteriological and serological methods for the diagnosis, the problems connected with the diagnosis and the importance of the infection of human beings by *Pasteurella pseudotuberculosis* have been discussed.

Literature

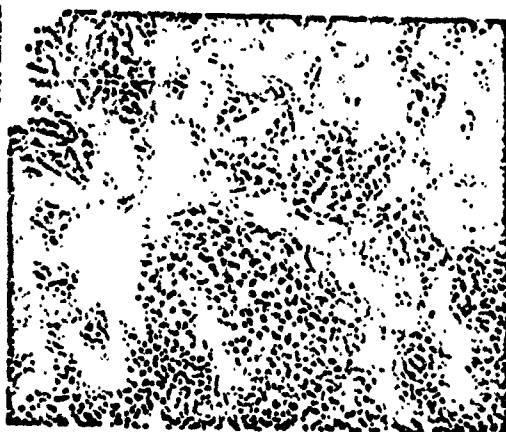
Schrifttum

- Albrecht, H., Wien. klin. Wochr. 1910: 991 — Becker, B., Chirurg. 25 (1954): 423 — Beer, J., Zschr. Vet. Med. 3 (1958): 305 — Braun, O. H. u. K. Müller, Zschr. Kinderhk. 80 (1957): 7 — Flamm, H. u. R. Jonas, Wien. klin. Wochr. 68 (1956): 671 — Francis, Th. u. Chairman, Diag. Procedures Viral a. Rick. Dia. New York — Graber, H., Chirurg. 27 (1956): 401 — Graber, H. u. W. Knapp, Frankf. Zschr. Path. 68 (1955): 309 — Haensell, V., Arzil. Wochr. 1957: 509 — Harcker, W. Ch., Arch. Kinderhk. 156 (1957): 151 — Herrmann, W., Zbl. Bakt. I. Orig. 170 (1957): 33 — Hörstebroek, R., Zbl. Path. 91 (1954): 221 — Keuffmann, F., Zschr. Hyg. 114 (1933): 97 — Kjellén, L., Arch. Virusforsch. 6 (1955): 45 — Knapp, W., (1) Zbl. Bakt. I. Orig. 161 (1954): 422 — (2) ders., ebda. 164 (1955): 57 — ders., (3) Chirurg. 26 (1955): 440 — ders., (4) Zschr. Hyg. Infekt. 142 (1956): 219 — ders., (5) ebda. 143 (1956): 261 — Knapp, W. u. W. Masshoff, Dtsch. med. Wochr. 1954: 1266 — Knapp, W. u. W. Steucr, Zschr. Immunit.forsch. 113 (1953): 370 — Kuhmann, F. u. W. Herrmann, Med. Klin. 1955: 1735 — Lennert, K., Vortr. Tag. Nordwestd. Pathol. Bad Pyrmont am 6. 10. 1956, zit. n. Haensell — Masshoff, W., Dtsch. med. Wochr. 1953: 532 — Masshoff, W. u. W. Döfle, Virchows Archiv, 323 (1953): 664 — Miessner, Tierseuchen und ihre Bekämpfung, 7. Auflage, Hannover, 1948 — Ott, A., Zschr. Infekt.Krkh., parasitäre Krkh. u. Hygiene d. Haustiere 32 (1938): 89 — Piéchaud, M., Ann. Inst. Past. 83 (1952): 420 — Poppe, K., Hdb. path. Mikroorganismen, 4 (1928): 414 — Riniker, P., Schweiz. Zschr. f. Allg. Path. u. Bakt. Vol. 20 (1967): 53 — Roman, B., Virch. Arch. 223 (1916): 53 — Seisawa, K., Zschr. f. Hyg. 73 (1913): 339 — Schmidt, H., Med. Monatsschr. 1955: 36 — Schoen, zit. n. W. Knapp (3) — Schütze, H., Arch. Hyg. 100 (1926): 181 — Seifert, G., mündl. Mitt. — Usteri, C., T. Wegmann u. Ch. Wedinger, Schweiz. Med. Wochr. 82 (1962): 1267 — Zussler, Th., Zschr. f. klinische Medizin 154 (1906): 237

Heavy reticular cell
proliferation - enlarged 1:160

Figure 1


Abb. 1. Starke retikuläre
Zellproliferationen. be-
sonders in dem Randbe-
reik. (H. E. Vergr. 1:160)



Same as figure 1 -
enlarged 1:800

Figure 2

Abb. 2. Wie Abb. 1.
(H. E. Vergr. 1:800)



Heavy reticular cell proliferation
Enlarged 1:160

Figure 3

Abb. 3. Knochenformige
retikuläre Prolifera-
tion mit beginnender
Abscheidung. (H. E. Ver-
gr. 1:160)