

UNCLASSIFIED


AD NUMBER
AD834633
NEW LIMITATION CHANGE
TO Approved for public release, distribution unlimited
FROM Distribution authorized to U.S. Gov't. agencies and their contractors; Administrative/Operational Use; DEC 1966. Other requests shall be referred to Department of the Army, Fort Detrick, Attn: Technical Releases Branch, Frederick, MD 21701.
AUTHORITY
Fort Detrick/SMUFD ltr dtd 15 Feb 1972

THIS PAGE IS UNCLASSIFIED

AD834633

TRANSLATION NO. 1897

DATE: 31 December 1966



DDC AVAILABILITY NOTICE

Reproduction of this publication in whole or in part is prohibited. However, DDC is authorized to reproduce the publication for United States Government purposes.

STATEMENT #2 UNCLASSIFIED

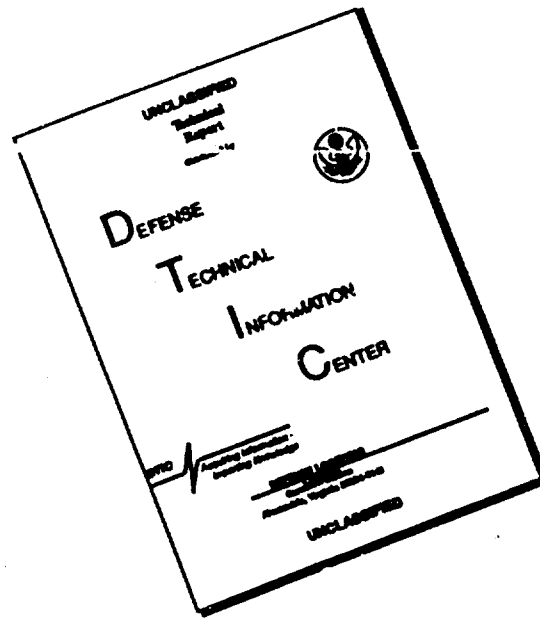
This document is subject to export control and each copy is may be
distributed only to those personnel authorized by the
Att'n: Tech Release Br

DEPARTMENT OF THE ARMY
Fort Detrick
Frederick, Maryland

21701

15

DISCLAIMER NOTICE



THIS DOCUMENT IS BEST QUALITY AVAILABLE. THE COPY FURNISHED TO DTIC CONTAINED A SIGNIFICANT NUMBER OF PAGES WHICH DO NOT REPRODUCE LEGIBLY.

TRANSMISSION OF SPOROTRICHOSIS TO MAN BY THE BITES OF A WHITE
RAT INOCULATED WITH A NEW VARIETY OF SPOROTRICHUM.

Bull. Mem. Soc. Med. Hop. Paris
(Bulletin of the Minutes of the
Medical Society of the Paris
Hospitals) Vol. 31, pp. 287-301, 1911

M. E. Jeanselme
N. Paul Chevallier

During an operation on a white rat infected with experimental sporotrichosis (Sporotrichum Jeanselmei, Brumpt and Langeron, 1910), a young syphilitic and tubercular woman who was holding the animal was deeply bitten on both thumbs. A few days after this accident, a slightly painful, inflammatory reaction appeared around each bite. This soon resembled a subepidermic paronychia.

These were sporotrichotic chancres whose characteristics we have previously described (1): almost complete apathy, viscous pus, gummatous nodule subjacent to ulceration.

(1) E. Jeanselme and Paul Chevallier, Sporotrichotic Chancres on the fingers produced by the bite of a rat inoculated with sporotrichosis. Soc. Med. des Hop. de Paris (Medical Society of the Paris Hospitals) 29 July 1910.

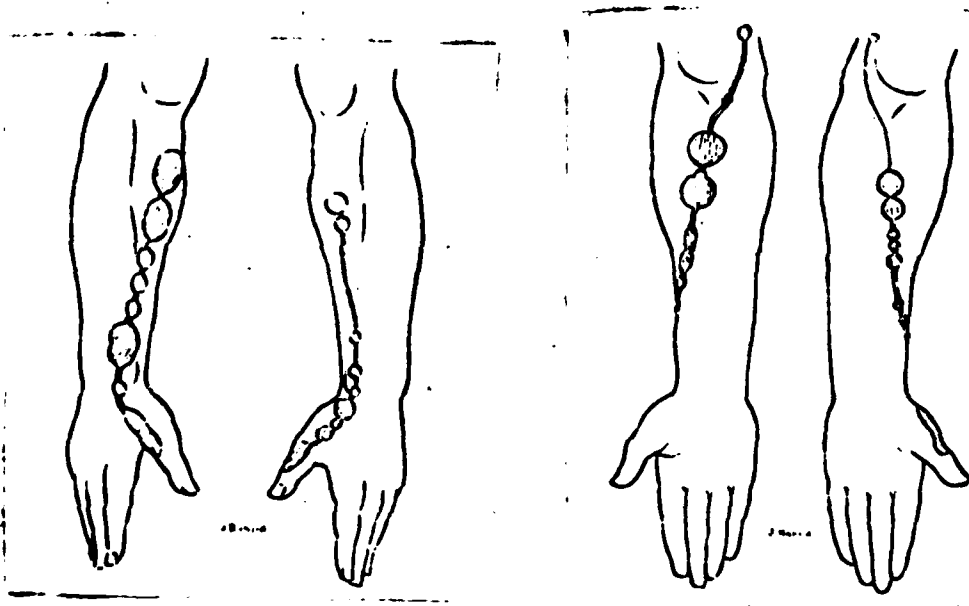
Under iodide treatment (4 grams of potassium iodide per day), the chancres regressed rapidly. At the end of July, eight weeks after the accident, the superficial ulcerations were only a few millimeters in diameter and the subjacent gummatous nodules were smaller in size and consistence.

But, during August, the patient showed several signs of intolerance with attacks of diarrhoea. These were so bad that the iodide treatment had to be interrupted; thereafter only weak doses were prescribed.

At the end of August, a little less than three months after the accident, subcutaneous gummata the size of a pea appeared on the hands and on both forearms, mostly the right side. The largest was above the radial styloid.

These lesions worsened at a rapid rate and, at the beginning of September, lymphagitic trails had invaded the forearms, almost reaching the bend of the elbow. On September 7, the lesions looked as follows:

In the place of primitive chancres, are knobbed, verrucose layers whose epidermis is peeling slowly, leaving visible rings at the base of small pimples. The superficial aspect of this layer is one of elastic consistency. The deep aspect is firm and almost solid; it is a true dermohypodermic gummatous infiltrate which does not follow the tendon or deep aponeurosis pattern.



Thus, the verrucose sporotrichose encircles all the skin which had chancres but it is definitely more extended. On the left thumb, the tumor originates on the external palm portion of the first phalangeal segment, reaches the contour of the external edge of the finger and extends into the external dorsal portion of the hand to the middle of the first

metacarpus. On the right, the verrucose layer is on the internal edge of the thumb at the first phalanx, and extends into the back of the hand the length of the first metacarpus.

The lesions continue in a lymphangitic line which stops about two finger widths from the fold of the elbow. Its path is that which anatomists assign to the superficial radial vein which cannot be marked because of the adiposeness of our patient; it follows the internal edge of the first metacarpus to the dorsal face of the hand, reaches the radial styloid apophysis, where it makes a contour of the internal side (the forearm being supinated). It then travels higher and a little to the outside, follows the external side of the forearm a little below the junction of the inferior third with the two superior thirds, then it moves higher and a bit further in, following the internal side of the fleshy body the length of the extended arm.

The lymphangitic trail stops a few centimeters from the elbow bend, a bit lower to the left than to the right. The line is discontinued and is constituted by a series of noniliformed segments; projecting gummata mark the path.

They are larger on the right forearm. The lowest, which is also the smallest, is pea sized and is situated behind the radial styloid immediately below and in it. Three others are nut sized; the first is above the radial styloid, the two others are arranged at one centimeter intervals on the upper extremity of the lymphangitic trail on the anterior face of the forearm.

To the left, the gummata are smaller but in larger numbers; there are six pea sized gummata from the metacarpus to the extremity of the line.

All of these gummata are covered with light pink healthy skin; they are semi-fluctuating or resistant.

There are no epitrochlear or axillary ganglions to the right; to the left, the axillary and epitrochlear ganglions, contemporaries of the chancre (and of a painful nature) persist but have not increased in size.

In spite of the resumed iodide treatment, the evolution continues. The gummata continue to grow and become painful to press; the larger are definitely fluctuating. The skin which covers them is purple red; the central portion becomes white. Spontaneously or by acupuncture, a whitish pus appears, extremely viscous and thick. The opening has no tendency to close; it enlarges; its edges become thinner; the bottom of the ulceration swells and at the slightest pressure, oozes a serous or seropurulent liquid which is often bloody.

At the same time, new gummata appear which undergo the same evolution. Some are in the heart of the verrucose layer, they soften and suppurate. The others give rise to swellings of the lymphangitic line; many remain closed and subcutaneous.

On the first of October, the patient called our attention to a very important fact: the ascension of the processus. At the bend of the left elbow, exactly on the biceps' tendon and above, along the internal face of the same muscle, on the lower third of the left arm, two small nodules have appeared which have the size and hardness of grains of lead.

These nodules grow: around 20 October, one can see an indurated line along the lymphatic path which connects these nodules with the anti-brachial gummata on one side and on the other side, to within a few finger thicknesses above these nodules along the internal edge of the biceps.

At the end of October, the node of the internal bicipital groove is the size of a nut. The epitrochlear ganglion seems to have little increase in volume.

At the same time, in the bend of the right elbow, two nodules the size of lead grains appear, and on the middle portion of the bicipital groove of the same side, a gumma appears which is soon the size of a large pea.

Improvement started at the beginning of November and was without interruption. Some gummata which seemed closed sometimes suppurated again for a few days, issuing either a small quantity of thick and viscous pus or a liquid more serous than purulent.

The disappearance of the nodules and gummata was obvious by the beginning of December 1910. At the start of January 1911, the lymphatic path is marked by a trail of dark red spots which mark the points where the gummata adhered to the skin. The scars visible in the center of these spots are flat or slightly elevated and under several one can feel a resistant plaque.

The verrucose layers have left a light hardened tissue.

The hypodermic nodules which did not adhere to the skin have not completely disappeared, and one can still feel a few which are ill-defined and small. To the left, there are small axillary ganglions, not too hard, whose significance is debatable.

In February, the antibrachial spots are less red, but in many places their center still has a superficial scar-like hardening. All the nodules have disappeared. However, in the middle of the left arm, one can feel a small, rather hard, ill-defined grain in the hypodermis which is the residue of the large nodule we described.

The patient, believing that she was cured, left the hospital, warned that she must continue the treatment for several weeks.

In short, typical gummatous nodular sporotrichotic lymphangitis was the diagnosis.

The cold paronychia, which was the inoculation chancre, is softened and ulcerated as it usually is: it seemed healed by the iodide treatment.

The appearance of lymphangitis about three months after inoculation was abnormally late, if we compare our case to published observations: it occurred a short time after the almost complete cessation of the iodide treatment. One is thus tempted to attribute it to the saturation of the organism by the medication and the late invasion of the lymphatic pathways.

Nevertheless, the patient of M. M. de Beurmann and Gagnieres (1) had no treatment: lymphangitis appeared two months after the injury. Today, on the other hand, it is well known that if iodide dissolves the sporotrichomes, it does not prevent the opening of new foci (2).

(1) De Beurmann and Gagnieres. A case of ascending gumma-ulcerative lymphangitic sporotrichosis. Bull. et Mem. de la Soc. med. des Hop. de Paris (Bulletin and Minutes of the Medical Society of the Paris Hospitals), 28 April 1910, No. 11. pp. 438-439.

(2) M. M. Sicard and Gougero. M. Vidal were the first to insist on these facts. Sicard and Gougerot: Accidental inoculation of sporotrichum to a sporotrichosis convalescent given intensive iodide treatment: absence of the preventative power of iodide. Soc. Med. des Hop. de Paris (Medical Society of the Paris Hospitals), 10 July 1908, No. 28, P. 234. -- Vidal: Rapid multiplication of gummata during iodo-iodide treatment. Ibid., 31 July 1908, No. 28, p. 238.

However we believe that the iodide retarded the lymphangitis. The halting of the treatment let the parasites multiply rapidly, no doubt because of the sensitization state (1) of the organism, which spore-agglutination (positive to 1/50 limit) discovered one month after the inoculation.

(1) De Beurmann and Gougerot. The "sensitization" state of sporotrichosis patients. Soc. med. des Hop. de Paris (Medical Society of the Paris Hospitals), 8 October, 1909, P. 397, No. 29.

Our patient surely had all the signs of a severe sporotrichosis. This was an extremely fat woman, but weak and lethargic. She suffered from a gonorrhoeal metritis, and she had frequent uterine hemorrhages; an anal fistula, dullness, humid crackings of the top [Translator's note: perhaps top of lungs] affirmed tuberculosis. The cutaneous and mucous

symptoms of secondary syphilis barely ceded after six months of mercurial treatment.

After the progressive sensitization of the organism and the decrease of the resistance of the area, M. M. de Beurmann and Gougerot called attention to the increase in virulence of the parasite as a cause for the worsening of the sporotrichosis. But the sporotrichum inoculated into our patient was an extremely virulent parasite.

The animal which transmitted the sporotrichosis was not hardy like the rat who ate the contents of a case as was observed by Lutz and Splendore (2). It was not a mule temporarily placed at rest for lymphangitic abscesses, as in the Carougeau case (3). The rat who bit the thumbs of our patient had received a large dose of *Sporotrichum Jeanseimeii* culture; he had severe lesions of the epididymis and testes. The autopsy a few days later showed organs (hypodermis, liver, spleen kidneys, lungs) stuffed with mycosic granulations: the heart blood and the urine produced extremely abundant parasite cultures.

(2) Lutz and Splendore. Sobre una mycose observada em Homens e Ratos (contribuicao para o conhecimento dos anim chamados sporotrichose), Rivista med. de Sao Paulo, 1907, and Ueber eine bei Menschen und Ratten beobachtete Mycose. Centralblatt fur Bakteriologie, Bd XLV, 1907 Heft 7, p. 631.

(3) Carougeau. First African case of Beurmann's sporotrichosis, Transmission of sporotrichosis from mule to man. Soc. Med. des Hopitaux de Paris (Medical Society of the Paris Hospitals), 12 Nov. 1909, p. 507. Lymphagitis due to *Sporotrichum Schenckii* would be the most frequent of the types studied according to Hyde and Davis. Sporotrichosis in Man with Incidental Consideration of its Relation to Mycosic Lymphagitis in Horses, in The Journal of cutaneous Diseases. July 1910 (with a bibliography on the question).

With the combined action of these various factors: sensitization of the organism, decrease in the resistance of the area, due to syphilis and earlier phthisis and increased virulence of the parasite, sporotrichosis invades rapidly and reacts slowly to iodide treatment as one easily sees.

The lymphagitis was ascending and it seemed to do this by a series of small eruptions. Actually, we never saw the regular progression of nodules noted in many observations and which is the typical evolution in chronic sporotrichotic lymphagitis. Without apparent cause, in our patient, a lymphatic segment previously undamaged seems to have parasites in a few days. Gummata appear on its trail rapidly. Often the highest gummata become big and fluctuating very fast, while the lower ones have a slow evolution.

It is thus that the patient's upper right arm had three lymphatic eruptions:

In the middle of August, carpal and lower antibrachial lymphangitis terminated by a large susepiphysial radial guma;

At the beginning of September, antibrachial lymphagitis, terminated by two superimposed voluminous gummata;

At the end of October, brachial lymphangitis terminated by a rapidly developing nodule which treatment retards.

It would be exaggerating to break the process down into distinct sentences in our treatise on sporotrichotic lymphangitis (insufficient, it is true), because the progression did not follow a regular plan (1). The eruptions have no relationship with any definite exterior cause: they coincide with the maturity of the highest gummata of the path. It is the state of these gummata and terminal nodules that is necessary to watch during treatment; their growth reveals their insufficiency; their disappearance is more difficult to obtain than that of the subjacent gummata or nodules.

(1) In a case of M. M. Beurmann and Gougerot [Thirteenth case of sporotrichosis. Sporotrichosis localized in the arm. Ascending gummatous lymphangitis. Soc. Med. des Hopitaux de Paris (Medical Society of the Paris Hospitals), 26 July 1907, p. 950; and Comparison of sporotrichoses and cocci infections... Ann. de Dermat. et de Syph. (Annals of Dermatology and Syphilis), t. X. 1909, February, pp. 81-97], on the path of a lymphangitis, (sometimes on the upper portion, sometimes on the lower portion) in which a certain number of sporotrichotic abscesses appeared by phlegmatic eruptions.

During its irregular evolution, the lymphangitis remained on a precise path which is that of the white satellite vessels of the principal venous current: radial vein, oblique vein of the elbow, basilic vein. The lack of lateral expansion can perhaps explain that epitrochlear adenopathy was not on one side and was slightly marked (and of a painful nature) on the other.

We know that ganglions, as a rule, remain whole in lymphangitic sporotrichosis. In our patient, not only was the epitrochlear ganglion unharmed in the right upper member but also the axillary ganglions. To the left, the glands reported with the first symptoms did not increase in volume during the disease. A like absence of adenopathy is noted in the observations of M. M. de Beurmann and Gagnieres (1), Tremolieres and J. du Castel (2), Robert Stain (3), Dominici and R. Duval (4), de Beurmann and Gougerot (5) which in many points are comparable to ours.

(1) De Beurmann and Gagnieres. A case of ascending gummatous lymphangitic sporotrichosis. Soc. med. des Hop. de Paris, (Medical Society of the Paris Hospitals), 28 April 1910, No. 11, pp. 438-439.

- (2) Tremolieres and J. du Castel. Disseminated sporotrichosis in a diabetic. Initial pustular lesion on the forehead. Generalization. Muscular and subcutaneous gummata, dermal nodules. Lymphatic propagation. *Ibid.* 29 April 1909, No. 14, pp. 735-738.
- (3) R. Stain (of Berne). Disseminated sporotrichosis gummata. Gummatus nodular sporotrichosis lymphangitis. *Ibid.* 24 June 1909, No. 22, p. 1271-73.
- (4) Dominici and R. Duval, Sporotrichosis of the index finger. Consecutive sporotrichosis lymphangitis, *Ibid.* 25 October 1907, No. 30, p. 1069.
- (5) de Beurmann and Gougerot. Ascending sporotrichosis knotty lymphangitis. Bull. de la Soc. de Dermatologie, 2 May 1907 p. 243. (Bulletin of the Society of Dermatology)

Adenitis is reported in only a small number of cases; it is then precocious and phlegmatic, accompanying a subacute lymphangitis [rosy lymphangitic trail] with secondary appearance of gummata, Carougeau (6); large and painful adenopathy constituting the predominating lesion Josset-Moure (7)].

(6) Carougeau. Loc. cit.

(7) Josset-Moure. Sporotrichosis Adenitis. Soc. med. des Hop. de Paris (Medical Society of the Paris Hospitals), 29 January 1909, p. 133 of the Bulletins.

In the chronic forms, the sporotrichum does not have the tendency to diffuse; "the mycosis remains localized in the invaded segment (8)." Here it is a question of a clinical rule. The absence of adenopathy is not a synonym for the anatomic integrity of the ganglions (9); in any case it should not keep us from searching for a generalized blood infection (10).

(8) Gougerot. Clinical forms of de Beurmann's sporotrichosis. Gazette des hopitaux. (Hospital Gazette) 12 April 1909, No. 44, p. 545.

(9) Pierre Marie and Gougerot. Primitive hypertrophic sporotrichosis osteitis of the tibia complicated by ascending ulcerative lymphangitis and sporotrichosis inguinal adenitis. Soc. med. des Hop. de Paris (Medical society of the Paris Hospitals), 28 May 1909, pp. 994-1007. It is a question of a femorotibial ulcerative lymphangitis ending about 15 centimeters above the bend of the groin and without appreciable clinical adenopathy.

(10) R. Stain. Die sporotrichose von de Beurmann und ihre differential Diagnose gegen Syphilis und Tuberkulose. Arch. f. Dermat. und Syph. No. 7, p. 3, 1909. Disseminated sporotrichosis gummata. Gummatus nodular

lymphangitis. Soc. med. des hop. de Paris (Medical Society of the Paris hospitals), 24 June 1909, No. 22. In spite of the absence of axillary ganglions, we find a few small gummata in the abdominal wall.

As is usually the case, the evolution of each of the lymphangitic nodules was like that of the hematogenic nodules of common sporotrichosis: little lead-grain-sized nodes, mobile nodules, then closed gumma which adheres to the skin, softens and contains a viscous pus (1). More or less rapidly, the cold sporotrichotic abscess opens through the skin by a narrow hole. The bottom of the gumma swells while the opening seems to close; a serum, at times bloody, seeps upon pressure. None of our patient's gummata had any tendency towards spontaneous healing.

(1) The sporotrichotic pus is at times "serous, limpid, citrine," a little bloody; at times seroclotted or seropurulent; sometimes it is a question of laudable pus, "frank pus." In the majority of the cases, the pus is whitish and viscous, and it is like this in our two patients infected by *sporotrichum Jeanselmei*. It seems to be constant in closed gummata developing relatively slowly. When the gumma becomes fluctuating and threatens to open, the pus becomes more fluid. But it is erroneous to consider that the pus is "very fluid, easy to withdraw with a syringe" as one of the differential characteristics of mycosic gummata [Spillmann and Gruyer. Two cases of sporotrichosis: gummatus gyphiloid sporotrichosis and nodular type tuberculoid sporotrichosis. Annales de dermat. et de syph. (Annals of dermatology and syphilis), 1908, p. 580/. It is not a question of a pure sporotrichosis because the pus produced tuberculosis in the guinea pig while, on Sabouraud's maltose agar, it produced "precociously downy" colonies of a *sporotrichum* assimilated as *Sp. Beurmanni* by Vuillemin.

After treatment, the ulcerated gummata, as several authors have already remarked, leave a notable quantity of scar tissue which disappears slowly.

TREATMENT. -- We were able to heal our patient by associating potassium iodide ingestion with lipiodol injections in the buttocks (2).

(2) We heartily thank M. Lafay who placed this medication at our disposal.

Here are the treatments we tried previously;

Four radiotherapy sessions, of five hours each, were made by Dr. Darbois to try to dissolve the verrucose sporotrichomes of the hands: the results were not appreciable.

Several times, we have emptied certain large gummata as much as possible by aspiration and we have injected a half cubic centimeter of a sterilised solution of potassium iodide to the fifth. Severe pain followed the injection made with this technique. The latter is delicate because the

use of a fine needle does not allow very thick sporotrichotic pus to be withdrawn, and the distension of the gumma is painful, even if only one or two drops are injected. Elsewhere, a needle large enough to evacuate the pus makes a hole for the iodide solution to escape.

Gummata injected four times by a suitable method did not show any notable improvement.

An interesting fact must be noted here; each local iodide injection was followed by an increase in the volume of the small nodules of the lymphatic line and sometimes even the appearance of new nodes on the sub-jacent lymphangitic segment of the treated gumma. It is not a question of a passing reaction but rather a lasting modification. What ever the significance of this sporotrichotic eruption is, it disturbed our patient and did not allow us to continue our trials.

For several gummata, we tried camphorated thymol; very rapidly, the infiltrate softens and evacuates. But the bottom of the gumma swells and sporotrichotic granulomata form. The camphorated thymol does not appear to have antiseptic action, because the pus taken from gummata thus treated and having the characteristic odor always gave typical cultures of the parasite. The tubes inoculated with pus from iodide gummata were often sterile (1).

(1) The destruction of the parasite is the result of the cellular and humoral activity of the infiltrate during resorption. The camphorated thymol has no necrotic action and leaves the sporotricha intact. In the absence of reactionary phenomena of the inflamed tissues, the same goes for iodide which does not inhibit the appearance of mycosic colonies (de Beurmann, Gougerot, Widal, etc.) more in vivo than in vitro.

The thymol pus has a special aspect; it is so thick, so consistent that it can only be aspirated by a large-mouthed syringe and is expelled moulded into a cylinder which does not break.

We have tried the local arsenic treatment recently defined by M. M. de Beurmann and Gougerot. But the rapid improvement under the influence of large doses of iodine soon made the direct treatment of gummata useless.

In summary, local therapy gave us no success and it is the general treatment which was able to heal our patient.

From the beginning of July 1910 to February 1911, each day the patient took 4 to 6 grams of potassium iodide. Intolerance phenomena occurred several times, diarrhea or nausea. We did not try to associate iodine with belladonna, or to give it as a washing (enema), which was badly accepted by our patients.

Twice we injected hecine with a daily dose of 0.10 to 0.20 centigrams for 15 days. During the first series, the gummata first seemed to regress, then soon continued their evolution.

The second series was given as a treatment for the general health during convalescence.

Recovery seemed incontestably due to the simultaneous use of potassium iodide by mouth and lipiodol by injection in the buttocks. Each day we first injected a cubic centimeter, then two centimeters, and sometimes more, of this oil which contained a large quantity of iodine in suspension. From 27 October to 3 February, we thus gave a daily iodide dose (lipiodol iodine being counted as iodide) of 10 to 12 grams.

At the beginning of the treatment, a certain degree of exacerbation of the local phenomena was produced: the gummata had increased in size, had become more painful, and the patient had a feeling of tension around her lesions "which numbed the entire arm." Through the openings, the ulcerated gummata appeared to be granular swellings. These phenomena, which are perhaps reactional phenomena, disappeared rapidly. The ulcerations started to form scars and the infiltrates diminished. The rough healing was extremely rapid; the nodular remains took longer to dissolve. One of the latter, as large as a small lentil, persisted on the left arm when the patient was discharged. The presence of this nodule could not convince her that she was not cured.

GENERAL HEALTH. -- As we said, our patient is syphilitic, and her last series of gray oil ended on 14 September 1910. At this time, she still had a few vulvovaginal mucous plaques and an extremely pronounced Venus' collar. Today, she has no specific symptoms and the syphilitic pigmentation of the neck is disappearing.

This patient is also tubercular; she had a retro-ano-rectal fistula and pulmonary stethoscopic signs. The exterior disreputable fistula, which could be penetrated by a stylus to a depth of up to 10 centimeters, is less deep today. The opening is smaller and the edges epidermized; the suppuration is greatly decreased.

On the other hand, the pulmonary state seems to have worsened, and this confirms the opinion of the authors that the association of tuberculosis and sporotrichosis is most unfavorable. The tops [Translator's note: perhaps tops of lungs], in particular the left one, have a bad sound when tapped. Auscultation reveals many sub-crackling rales on both sides. However, the patient does not cough, or only sometimes at night; she has never had hemoptysis.

Her adiposity is extreme; she gained a lot during her stay at the hospital. Her muscular force is minimum; the teguments are pale. --Note that in July 1910, the patient showed signs of sub-jaundiced conjunctives without discoloration of matter or normal bile pigments in the urine.

The uterine hemorrhages became particularly frequent from the month of December. The possible causes of these metrorrhoea are too numerous to be discussed. Their verification can explain, for the most part, the marked anemia of the patient.

In January 1911, an examination of the blood shows;

Erythrocytes 2,580,000 Globular value 38. (Gowers' hemoglobino-meter).

Hematoblasts, very numerous (790,000 average from several points of a thin drop, spread, fixed by osmic acid and Giemsa stained).

Leucocytes 18,000 (Hem. Eos. -- Or. Tbl. -- El de Unna): Polynuclear neutrophiles 45; polynuclear eosinophiles 1.5; large mononuclears 24; medium mononuclears 23.5; lymphocytes 1; small mononuclears with non-metachromatic basophil granulations (Turck's cells?) 5; there are no granular erythrocytes. --Another examination was made after the patient, in spite of us, has almost completely stopped the liiodol injections. The mononucleosis was less marked, there were no abnormal leucocytes and 3,500,000 erythrocytes were counted.

The globular resistance, measured by the method of M. M. Widal, Abrami and Brule, is normal. Hemolysis begins at 0.0048 and is intense at 0.0040.

The serum is both hemolytic and milky. We were able to demonstrate a cause relation between these two phenomena.

The serum very rapidly hemolyzes sheep erythrocytes. After a half hour of heating at 56 degrees and an addition of fresh guinea pig serum, it hemolyzes them even faster. We are assured that this hemolytic ability is very much greater than that of normal human serum. The human erythrocytes and the patient's erythrocytes are not destroyed in the same conditions, even after cooling action.

The serum obtained by decantation of coagulated blood, or the blood plasma, is milky. This milkiness does not have the same intensity all day; in the morning it is almost zero and the serum has a slightly bluish opaline aspect which is frequent in syphilitics. A venipuncture made two to three hours after the liiodol injection (two cubic centimeters), withdraws a definitely milky serum (the blood is gathered about one half

hour after the 11:30 meal, as it is for all our Wasserman tests) (1). Its microscopic characteristics and its chemical composition, studied by M. J. Charles-Bongrand, cannot determine the proteic or fatty origin of the milkiness. The quantities of fats extracted by Adam's liquid are not different from the normal proportions in the classical manuals and in M. Jousset's (1904) thesis.

(1) Our patient, laboratory girl, badly represents all exceptions which could be interpreted as a purely scientific experiment. The question of milky sera is too complex to go into here.

We have not eliminated the influence of digestion. However, it is possible to suppose that the particular aspect of the serum is dependent on the injections of iodined oil. But the serum does not contain iodine or free fats foreign to the organism. This is not an argument against the preceding hypothesis because one can even admit an increase of certain serum albumins under the influence of the introduction of a large quantity of fat (1).

(1) the subcutaneous injection of olive oil in large quantities definitely caused an increase in the destruction of albumin. E. Heilner. Ueber den Einfluss der subkutanen Fettzufuhr auf den Eiweisstoff-Wechsel. Zeitschrift fur experiment Pathol. u. Therapie., LIV, pp. 54-63, 1910. The author uses this fact to prescribe the medical usage of injections of fatty material. It would be attractive to admit that, in our patient, the introduction of fat causes blood abnormalities and muscular weakening, the true thinning being masked by an exaggerated adiposity. We have no element which allows us to form this hypothesis.

The urine never contained albumin or bile pigments.

HUMORAL REACTIONS. -- Sporotrichosis intradermo and subcuti-reactions.
-- On 15 October, we simultaneously made a subcutaneous and an intradermic injection of sporotrichosine. Our mycosic extract was prepared by crushing a three-week-old first culture of Sp. Jeanselmei on Sabouraud's glucose agar, and by diluting the broth or carrot bouillon inoculated several months earlier.

The still thick mixture was sterilized for 20 minutes at 120°, placed in the hot air oven at 37° for 48 hours, filtered on Chardin paper, diluted with physiological water to reduce the spore concentration and again sterilized for 55 minutes at 120°.

This method of preparation draws its theoretic justification (maximum endo and exotoxin obtainment) from M. M. de Beurmann and Cougerot. Following the example of M. Pautrier, we thought it preferable not to inject a spore rich liquid. We have used a dilution approximately similar to the dilution defined by this author.

The injected quantity was quite strong (even too strong): about one cubic centimeter, half intra-dermic and half subcutaneous. Two syphilis patients and a man with indefinite nodules who were controls had no general or local reaction. At the point of injection, a small rosy painless tumefaction was produced which disappeared the following day.

Our patient, to the contrary, reacted strongly. Her temperature, which for the preceding days, was between 37.2 in the morning and 37.4 in the afternoon and up to 37.8 in the evening rose to 37.9 the next morning and 38.2 at five o'clock in the afternoon. On the third day, her temperature returned to normal. The rise in temperature was accompanied by general malaise and insomnia.

The local reaction was very strong. On the external side of the thigh at the injection site, an indurated and raised area appeared which reached its maximum size on the third day when the general phenomena were disappearing. It was then three finger widths high and four wide; its center was dark red. Its borders were wide, higher than the bottom and had an oedema aspect and a pale red coloration. It was extremely painful when pressed and during movement, and the patient complained of a burning sensation which was both smarting and purulent. The affected area started to shrink on the fifth day and had completely disappeared in ten days.

Some time after the complete healing of the infiltrated area, a type of painful gummatous ulceration, similar to a boil appeared at the inoculation site. The culture of the pus did not reveal the presence of sporotrichum. The symptom was thus attributed to the excessive quantity of dead mycosic bodies which we injected. The sporotrichotic sensitization occurred because the controls had no reaction. However, we believe that the scraping due to the itching and the secondary infection of the cutaneous scratches played a considerably role in the production of the ulcerous nodule.

FIXATION REACTION. -- In the fixation reaction, the Beurmanni or Jeanselmei antigens used in the Wassermann reaction, performed several times in December and January, were negative. The paradox is in relation with the intense hemolytic ability of our patient's serum.

These same antigens yielded a positive fixation reaction in the patient we just presented to the Medical Society of Hospitals in July. This patient left the hospital too early and is presently in a relapse for visceral and osseous sporotrichosis.

SPORE-AGGLUTINATION. -- The spores of Sp. Beurmanni, taken from one to two months old Sabouraud's glucose agar cultures, were definitely agglutinated at 1/300, more than ten times during the months of September, October, November, December and January.

The Sp. Jeanselmei spores, to the contrary, produced no agglutination most of the time; all pubescent Jeanselmei cultures (first cultures after several weeks, second or third cultures) never gave agglutinable spores. It is only after the tenth to the thirtieth culture that, inconsistently, one sees the large spores gathered in small groups separated by many isolated spores.

Twice in January 1911, we made trials with smooth but not too young cultures; the reaction was positive at a high titer, the agglutination limit being around 1/300. Thus it is almost always impossible to prove the serum of a patient with Sp. Jeanselmei spores. It is to our interest to use the small and abundant spores from the round de Beurmanni colonies.

A positive reaction, such as M. Widal and his students (particularly M. M. Abrami and Joltrain) have shown, only indicates a probability of sporotrichosis and authorizes no hypothesis on the variety of sporotrichum. It is only with the process defined by M. M. de Beurmann and Gougerot and the easy and rapidly positive culture on Sabouraud's medium, that one can base a precise diagnosis.