

UNCLASSIFIED

AD NUMBER
AD843453
NEW LIMITATION CHANGE
TO Approved for public release, distribution unlimited
FROM Distribution authorized to U.S. Gov't. agencies and their contractors; Foreign Government Information; FEB 1968. Other requests shall be referred to Department of the Army, Fort Detrick, Attn: Technical Release Branch, Attn: TID, Frederick, MD 21701.
AUTHORITY
SMUFD D/A ltr, 15 Feb 1972

THIS PAGE IS UNCLASSIFIED

AD 843453

TRANSLATION NO. 2133


DATE: 13 February 1968

DDC AVAILABILITY NOTICE

Reproduction of this publication in whole or in part is prohibited. However, DDC is authorized to reproduce the publication for United States Government purposes.

STATEMENT #2 UNCLASSIFIED

This document is subject to special export controls and each transmittal to foreign governments or foreign nationals may be made only with prior approval of Dept. of Army, Fort Detrick, ATTN: Technical Release Branch/TID, Frederick, Maryland 21701



DEPARTMENT OF THE ARMY  
Fort Detrick  
Frederick, Maryland

USE OF FLUORESCENT MICROSCOPY IN DERMATOLOGY  
AND VENEREOLOGY. IMMUNOHISTOCHEMICAL  
FLUORESCENT ANTIBODY METHOD

Ceskoslovenska dermatologie  
(Czechoslovak Dermatology)  
Vol. 40, No. 1, pages 51-56, 1965

V. Winter

In the last 20 years fluorescent microscopy has become the basis for immunohistochemical methods. With these methods one can demonstrate antigens and determine their localization. A substance is called an antigen if upon injection into an animal it stimulates production of antibodies. Antibodies have the peculiar ability to specifically bind antigens forming antigen-antibody complexes, which can precipitate. The fluorescent antibody method is based upon this principle. Antigenic material present in a tissue section will react specifically with its complementary antibody. This immunological reaction will take place in deposits of minute amounts of antibody over those areas of the tissue section where antigen is present. If conjugation of antibody with fluorescein had been previously carried out the microdeposit of fluorescent antibody becomes visible under a fluorescence microscope. Specificity of the reaction rests in selection of the specific antibody by the antigen from a solution of fluorescent proteins. Other serum protein molecules present in the fluorescent solution are washed out of the tissue section and the specific deposit remains in situ.

Preparation of the tissue sections must be done without chemical fixation so as to avoid interference with immunologic activity of the antigenic material. It is therefore best to use native section prepared in a cryostat.

The fluorescent immunohistochemical method was introduced and developed by Coons, Creech and Jones (1941). Coons' method for localization and identification of antigens has in the past ten years been applied in various areas of biology and medicine. It developed that this method could be modified for diagnostic as well as basic research purposes such as bacterial and viral pathogenesis, collagenoses, etc.

The method has certain limitations such as non-specific staining, poor contrast in some tissues which exhibit primary fluorescence. Experience has shown, however, that when critically utilized and interpreted the fluorescent antibody method can to a large degree serve medical research.

The first fluorochrome used for conjugation was fluorescein isocyanate. Its process of conjugation was worked out in detail by Coons and Kaplan (1950). This fluorochrome is unstable and conjugation with it is technically demanding; for this reason other fluorochromes were sought. Of the many proposed materials two proved to be the most suitable and these are most commonly used. Riggs et al. (1958) introduced fluorescein isothiocyanate which is more stable and produces better results than isocyanate (Marshall et al., 1958). Chadwick et al. (1958) used lissamine, a sulfonyl chloride derivative of rhodamine B 200. This fluorochrome has an orange fluorescence that is as intense as fluorescein, which has a yellowish-green fluorescence and has also proved useful.

The technique of demonstrating antigens can involve a direct or indirect method. In the direct method a test animal is sensitized to the test antigen and the resulting antibody is conjugated with the fluorescent stain. The conjugated antibody (FL) in the tissue section is bound to the cell specifically by the antigen so that under a fluorescence microscope areas where the antigen is found, fluoresce. This method was worked out by Coons, Creech and Jones (1941) (figure 1).

In more recent times the direct technique has been supplemented by various indirect methods. Thus for example, in order to demonstrate an antibody (FL) bound to a cell, Coons et al. (1951, 1955) overlaid a tissue section with unconjugated homologous antigen (AG). The resulting antigen-antibody complex is demonstrated by another conjugated antibody which is joined to the bound antigen. This is called the sandwich method.

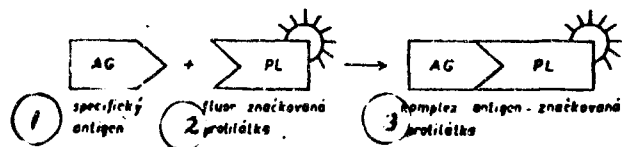


Figure 1. Direct staining technique

1. specific antigen
2. fluorescence-marked antibody
3. antigen-antibody complex

In order to increase the sensitivity of the reaction and eliminate cross-reactions during determination of cell bound antigens the following method is now used:

The section containing antigen (AG) is treated with unconjugated homologous antibody (PL) and the resulting antigen-antibody complex is determined with the aid of a conjugated anti-antibody (PPL) from a different animal source (figure 2). The indirect staining technique simplifies some investigations since it only requires one conjugate for each animal type. In the direct technique a special conjugate is required for every antigen that is to be studied. Basically the same method as for the indirect technique is used in fixed complement and fluorescence-conjugated anticomplement method first introduced by Goldwasser and Shephard (1958) (figure 3).

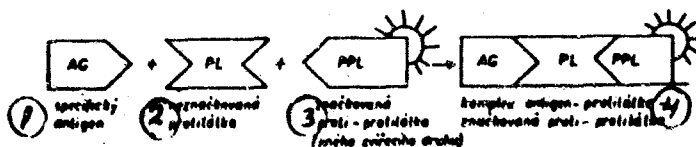
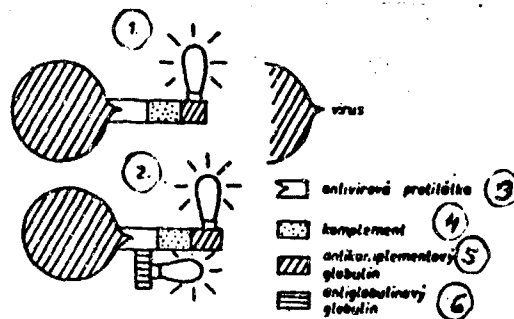


Figure 2. Indirect staining technique

1. specific antigen
2. unmarked antibody
3. marked anti-antibody (of a different animal species)
4. antigen-antibody/marked anti-antibody complex

This procedure represents further simplification of the method since conjugated anti-guinea pig serum is the only conjugate necessary for studying antibodies of a large number of animal types. In this method antigen is overlaid with immune serum to which is added guinea pig serum con-

taining complement (the necessary presence of C<sub>1</sub>, C<sub>2</sub>, and C<sub>4</sub> fractions). The result of this reaction is the formation of an antigen-antibody-complement complex. The guinea pig complement -- and thus the original antigen -- is demonstrated with marked rabbit globulin against guinea pig serum.



**Figure 3. Characterization of antigen with aid of complement (according to Albrecht).**

In the first phase antigen combines with antibody and complement; in second phase, with marked anticomplement globulin (1). Increased intensity of fluorescence of the immunological complex may be achieved by using marked antibodies against globulin of antiviral serum (2).

3. antiviral antibody    4. komplement  
5. antik. splementnyy globulin  
6. antiglobulinnyy globulin

Immunohistochemical methods aided by fluorescent antibodies are analyzed in detail in the work of Meyersbach (1956) and Coons (1958).

Since 1950 application of the fluorescent antibody technique spread rapidly to many fields. Coons published several extensive reviews on this theme (1954, 1956, 1957, 1958) as did Mellors (1959). Considering the aim of this work toward dermatology and venerology we shall only briefly mention the application of this method in other fields.

Antibodies conjugated with fluorescein can be used to advantage for many antigenic materials: polysaccharides, proteins and lipopolysaccharides. Fluorescence-marked sera were successfully used for rapid identification of cell antigens -- bacteria, viruses, parasites (Liu, 1956; Thomason et al., 1961; etc.). The technique was also applied to basic research and to study of the pathogenesis of viral, rickettsial and bacterial infections (Coons, 1956; Noyes

and Watson, 1955; Buckley, 1956; Lebrun, 1957; etc.). In many works the fluorescent antibody method was used to aid in the study of foreign antigens of a nonviral nature, introduced into the organism by injection (Kaplan, Coons and Deane, 1950; Hill, Deane and Coons, 1950). Many studies were devoted to investigations of the fate of foreign protein antigens in an organism after parenteral introduction into animals (Coons, Leduc and Kaplan, 1951; Mayersbach and Pearse, 1956; etc.).

Marshall (1951) used fluorescence-marked serum for determining localization of native proteins in tissues, i.e. ACTH, enzymes (Marshall, 1954). Coons et al. (1955) and Leduc et al. (1955) introduced this method in studies of the place and mechanism of antibody formation. This work confirmed the validity of the plasmocytic theory of the origin of antibodies.

In recent times the fluorescent immunological technique was used to investigate the location of antigens and antibodies in organs during pathological states and was also utilized for histopathological demonstration of auto-antibodies against antigenic tissue components. Mellors (1955), Mellors and Ortega (1956), Mayersbach et al. (1956) and others by means of this technique confirmed the immun-allergic pathogenesis theory of human nephritis. Vazquez and Dixon (1957) used a combination of the fluorescent method and autoradiography in the study of gamma globulin in secondary human amyloidosis. Gitlin et al. (1957) demonstrated the basis of fibrinoid material in collagenoses such as arthritis rheumatica, lupus erythematosus, etc., with the aid of conjugated antisera against human fibrin, albumin and gamma globulin. They identified the substance as fibrin. More recently the fluorescent technique was extended to studies of hypersensitivity. For example, McKinnon et al. (1957) investigated intravascular precipitation of the antigen-antibody complex and its role in anaphylaxis. Oort (1961) studied the localization and concentration of fluorescent antigen in Arthus' phenomenon when injected into actively and passively immunized guinea pigs.

The works cited represent only a brief review of the possibilities in applying the technique of fluorescence-marked antibodies. The literature is too extensive to be evaluated in more detail here, nor is this the purpose of this report.

As far as we could determine from literature available to us, there is very little work in dermatology using

fluorescent antibody techniques for diagnostic purposes or in research. This method has penetrated into dermatology only gradually in recent years. Most work is found in the field of venerology, mycology and an occasional study of dermatoses such as collagenoses, skin tumors and virus diseases. In this area we include the work of microbiologists and virologists insofar as they are related to dermatology.

Weller and Coons (1954) used the fluorescent antibody method to study varicella and herpes zoster in tissue cultures. Lebrun (1956, 1958), using this method studied cell localization of herpes simplex and herpes zoster.

Hiramoto and Pressman (1957) carried out a study of the immunohistochemical properties of human skin and tumors related to them. Using conjugated antiserum against human skin and human malignant melanoma, they demonstrated that the latter is not of epidermal but of neuroepidermal origin. Skin antibodies stained only skin and not the melanoma while melanoma antibodies stained only melanoma cells, the papillary margin of the skin and neurilemma of vagus tissues. Noyes and Rappaport (1956) studied the distribution and localization of tissue antigens in rats with lymphosarcoma and found a common antigen in lymphosarcoma cells, intestinal epithelium, thymus and skin of these animals.

Mellers and Ortega (1956) in his work on lipid nephroses also found gamma globulin deposits in periarteritis nodosa. They determined gamma globulin by an indirect method using antihuman rabbit gamma globulin. During their studies of various tissue protein compounds and their distribution in pathologically changed tissues, Craig and Gitlin (1955) found fibrin in areas of fibroid necrosis of arteries.

Most investigators were engaged in study of collagenoses, particularly lupus erythematosus. Gitlin and Craig (1957) found fibrin in fibrinoid deposits of L. erythematosus. Vargas (1956) also found an increased amount of gamma globulin there. Localization of gamma globulin in lupus erythematosus was studied by Mellers, Ortega and Hollman (1957). These authors described the "staining" of leucocyte nuclei in material obtained in this disease and proceeded with anti-human fluorescent gamma globulin. Salberow, Weiz and Johnson (1957) used

the indirect method in their studies of the LE phenomenon. Normal tissue sections were treated with LE positive serum and then fluorescent anti gamma globulin was added. Specific fluorescence was found in nuclei of cells in various organs. Control sections, untreated with LE positive serum and ones treated with normal serum did not produce this result. Wignall et al. (1961) used the fluorescent antibody method to distinguish between desoxyribonucleic acid of amorphous inclusions contained in neutrophils of patients affected with lupus and desoxyribonucleic acid from the nucleus.

Allergic reactions were the subject of interest of previously mentioned authors McKinnon et al. (1957) and Cort et al. (1961). Rappaport (1960) studied the antigen-antibody reaction in allergic human tissue and in his work he pursued localization of reagins in human skin and their relationship to globulins.

Normal fluorescence microscopy and fluorescent immunohistochemistry is being used more and more in mycology. Vogel and Padula (1958) first used indirect staining reactions with fluorescent antibody for the detection of antibodies against pathogenic fungi. Gordon (1958) with the aid of fluorescent antibody carried out differentiation of yeasts. Macotela-Ruiz (1961) applied the fluorescent antibody technique in the study of pityriasis rosea Gibert. The same dermatosis was studied with this technique by Wright and Francis (1961). The authors tried to demonstrate a viral etiology for this disease. Neither serological methods nor the fluorescent antibody technique proved successful in identifying the infectious agent. Sternberg and Keddie (1961) carried out immunofluorescent studies with pityriasis versicolor. Through their work the authors attempted to clarify the pathological significance of Pityrosporum orbiculare which along with P. malassezia (M. furfur) is found regularly in pityriasis versicolor. In patient sera they found high-titer agglutinating antibodies and demonstrated a common antigen for P. orbiculare and the cells. It would seem that M. furfur and P. orbiculare are closely related if not serologically identical.

The study of chronic dermatitis and dermatoses occupied Derbes (1961) and Wise et al. (1961). They used the direct staining technique and patient sera with presumed antibodies to tissue antigens and conjugated with

fluorescein. They investigated skin of patients with atopic dermatitis, eczema, lupus erythematosus, l. erythematosus disseminatus, eczema nummulare, verrucae and apinocellular carcinoma. In only two patients with atopic dermatitis was there a positive reaction with affected skin and in both patients the reaction was negative with clinically normal skin. For all the other dermatoses there were only non-specific reactions. No conclusions can be drawn from these results except perhaps that in atopics there are strong auto-immunological reactions.

Immunohistochemical reactions, aided by the fluorescent antibody method found greatest application in venerology. Here also the best results were attained and were worked out in detail for diagnostic purposes.

The first two applications of fluorescent antibodies in the field of venerology were made by Deacon, Falcone and Harris (1957) and (1958) with lues. It was shown that the results obtained were very specific and extremely sensitive (U. S. Communicable Disease Center, 1959) and more recent publications demonstrated the growing significance of the fluorescent treponemal antibody (FTA) test for syphilis. Borel and Darel (1959) compared the FTA and TPI (Treponema pallidum immobilization) test with Kolmer's cardiolipin antigen reaction and showed that in normal persons and with non-specific reactions the FTA was always negative. According to the authors the FTA is extremely sensitive and surpasses other methods, including TPI. This was also clearly shown with the quantitative method where FTA was much more sensitive than TPI. Olansky and McCormick (1960) also consider FTA as a boon in solving serological problems in lues. According to them the reaction is specific 99% of the time. Harris, Bossack, Deacon and Bunch studied other diseases in parallel with TPI, Kolmer's test and the VDRL reaction (Venereal Disease Research Laboratory, USA). It was shown that FTA was the most sensitive of all the reactions even when used quantitatively.

Deacon et al. (1957, 1958, 1960) worked out details of the fluorescence test for Treponema pallidum. They used the indirect reaction. The FTA test is performed as follows: Treponema pallidum (prepared in a rabbit as for the TPI test) is placed on a slide and covered with the human serum to be studied. The surplus serum is washed off with physiological saline and fluor-

escein-conjugated anti-human globulin is added as a reaction indicator. The Treponemata which had been bound to the human antibody are also bound from the other side to the fluorescent conjugate. Under the fluorescence microscope we then see fluorescing Treponemata. A control reaction is obtained by acting upon the organism with specific, unconjugated antiserum (e.g. rabbit serum), and after careful washing, applying fluorescein-conjugated goat anti-rabbit globulin for detection of any rabbit antibodies present. Abroad conjugated anti-human and anti-rabbit globulins are currently available; in our country they are beginning to be produced by USOL.

Among Soviet authors Ovchinnikov (1961) used FTA for the diagnosis of lues. According to this author the FTA reaction is specific, sensitive, rapid and simple. It is more sensitive than both the BWR reaction with cardiolipin antigen and the TPI test. It is not suitable for establishing the success of lues treatment because the test remains positive for a long period of time despite treatment. FTA is important in detecting non-specific reactions.

Not long ago an application of the fluorescent antibody method in identification of Neisseria gonorrhoeae was published (Deacon, Peacock, et al., 1959, 1960). This will certainly be of considerable value in the epidemiology of gonorrhoea and in the battle against venereal disease. Anti-N. gonorrhoeae conjugates can now be prepared and used for identification of the organism in 16-20 hours while the conventional culture technique requires approximately ten days. The authors have also worked out a delayed fluorescent antibody method by which questionable gonococci are grown on an enrichment medium. This method is particularly valuable for the detection of gonorrhoea in women.

Soviet authors are also using this method for diagnosis of gonorrhoea. Migulina (1961) utilizes the direct method for differential diagnosis of chronic urethritis. She produced anti-gonococcal and anti-staphylococcal hyperimmune sera and conjugated them with fluorescein. The degree of fluorescence of gonococci depended upon the lot of conjugate, dilution of conjugates and age of cultures.

Ovchinnikov (1961) used fluorescent antibodies for identification of gonococci and their L-forms. As antibodies he used fluorescent anti-gonococcal sera conjugated with fluorescein isocyanate. Immune sera were obtained by immunization of rabbits with a polyvalent gonococcus vac-

cine and others with a polyvalent gonococcus L-form vaccine. With the help of tagged antibodies it was possible to identify gonococci and their L-forms. It was not possible to demonstrate L-forms in acute gonorrhoea. The fluorescent antibody method will in the future aid in clarifying the question of the presence of microbial L-forms in urethritis patients.

#### Literature Cited

1. Borel, L.J., Durel, P.: Path. Biol. 7, 2317, 1959.
2. Buckley, S.M.: Federat. Proc. 15, 509, 1956a.
3. Buckley, S.M.: Arch. ges. Virusforsch. 6, 388, 1956b.
4. Coons, A.H., Creech, H.J., Jones, R.N.: Proc. Soc. Exp. Biol. (N.Y.) 47, 200, 1941.
5. Coons, A.H., Kaplan, M.H.: J. Exp. Med. 91, 1, 1950.
6. Coons, A.H.: Federation Proc. 10, 558, 1951.
7. Coons, A.H., Leduc, E.H., Kaplan, M.H.: J. Exp. Med. 93, 173, 1951.
8. Coons, A.H., Leduc, E.H., Connolly, J.M.: J. Exp. Med. 102, 49, 1955.
9. Coons, A.H.: Fluorescent antibody methods, General Cytochemical Methods, Vol. 1, 399, 1958.
10. Coons, A.H.: Ann. Rev. Microbiol. 8, 333, 1954.
11. Coons, A.H.; Int. Rev. Cytol. 5, 1, 1956.
12. Coons, A.H.: Ann. N.Y. Acad. Sci. 69, 658, 1957.
13. Craig, J.M., Gitlin, D.: Federat. Proc. 14, 401, 1955.
14. Chadwick, C.S., McEntegart, M.C., Nairn, N.C.: Immunology (Oxford) 1, 315, 1958.
15. Deacon, W.E., Falcone, V.H., Harris, A.: Proc. Soc. Exp. Biol. (N.Y.) 96, 477, 1957.
16. Deacon, W.E., Falcone, V.H., Harris, A.: Ber. wiss. Biol. 123, 27, 1958.
17. Deacon, W.E., Freeman, M.E.: J. Invest. Biol. 34, 249, 1960.
18. Deacon, W.E., Peacock, W.L., Freeman, E.M., Harris, A.: Proc. Soc. Exp. Biol. Med. (N.Y.) 101, 322, 1959.
19. Deacon, W.E., Peacock, W.L., Freeman, E.M., Harris, A., Bunch, W.L.: Publ. Hlth. Rep. (Wash.) 75, 125, 1960.
20. Derbes, J.V.: Arch. Derm. 84, 37, 1961.
21. Gitlin, D., Craig, J.M., Janeway, C.A.: Amer. J. Pathol. 33, 55, 1957.
22. Goldwasser, R.A., Shephard, C.C.: J. Immunol. 80, 122, 1958.
23. Gordon, M.A.: Proc. Soc. Exp. Biol. 97, 694, 1958.
24. Hill, A.G.S., Deane, H.W., Coons, A.H.: J. Exp. Med. 92, 35, 1950.
25. Hiramoto, R., Pressman, D.: Cancer Res. 17, 1, 1957.
26. Holborow, E.J., Weir, D.M., Johnson, G.D.: Br. J. Med. 2, 732, 1957.

27. Kaplan, M.H., Coons, A.H., Deane, H.W.: J. Exp. Med. 91, 15, 1950.
28. Lebrun, J.: Virology 2, 496, 1956.
29. Lebrun, J.: Bull. Micr. Appl. 6, 94, 1953.
30. Lebrun, J.: Ann. Inst. Pasteur 93, 225, 1957.
31. Leduc, E.H., Coons, A.H., Connolly, J.M.: J. Exp. Med. 101/102, 61, 1955.
32. Liu, C.: Proc. Soc. Exp. Biol. 92, 883, 1956.
33. Macotela-Ruiz, M.M.E.: Bull. Soc. Franc. Dermat. Syph. 68, 374, 1961.
34. Marshall, J.M.: J. Exp. Med. 94, 21, 1951.
35. Marshall, J.M.: Exp. Cell Res. 6, 240, 1954.
36. Marshall, J.D. Jr., Eveland, W.C., Smith, C.W.: Proc. Soc. Exp. Biol. Med. 98, 898, 1958.
37. Mayersbach, H., Pearse, A.G.E.: Brit. J. Exp. Pathol. 37, 81, 1956.
38. Mayersbach, H.V.: IV. Symposium d. Arbeitsgemeinschaft Histochemie, Mainz, 1956, Acta Histochem. 3, 256, 1957.
39. McKinnon, G.E., Andrews, E.C. Jr., Heptinstall, R.H., Germuth, F.G. Jr.: Bull. Johns Hopk. Hosp. 101, 258, 1957.
40. Mellors, R.C., Ortega, L.D.: Amer. J. Pathol. 32, 455, 1956.
41. Mellors, R.C., Ortega, L. D., Holman, H.R.: J. Exp. Med. 106, 191, 1957.
42. Mellors, R.C.: Fluorescent antibody methods, Analytical Cytology, 2nd ed., N.Y., McGraw-Hill, 1, 1959.
43. Mellors, R.C.: J. Histochem. Cytochem. 3, 284, 1955.
44. Migulina, V.M.: Vestn. Dermat. Vener. 35, No 1, 54, 1961.
45. Noyes, W.F., Rapport, M.M.: Fed. Proc. 15, 527, 1956.
46. Noyes, W.F., Watson, B.K.: J. Exp. Med. 101/102, 237, 1955.
47. Olansky, S., McCormick, G.E.: Arch. Derm. 81, 59, 1960.
48. Oort, J., Rijssel, T.G. van: Immunology 4, 329, 1961.
49. Ovchinnikov, N.M., Lurie, S.S., Byednova, V.N.: Vestn. Derm. Vener. (Moscow) 35, No 11, 27, 1961.
50. Ovchinnikov, N.M., Lurie, S.S., Byednova, V.N.: Laborat. dyelo 12, 30, 1961.
51. Rappaport, Ben Z.: J. Exp. Med. 112, 725, 1960.
52. Riggs, J.L., Seiwald, R.J., Burckhalter, J.H., Downs, C.M., Metcalf, T.G.: Amer. J. Pathol. 34, 1081, 1958.
53. Sternberg, T.H., Keddie, F.M.: Arch. Derm. 84, 999, 1961.
54. Thomason, B.M., Cherry, W.B., Davis, R.B., Pomales-Lebron, A.: Bull. Wld. Hlth. Org. 25, 137, 1961.
55. Vazquez, J.J., Dixon, F.J.: J. Exp. Med. 104, 727, 1956.
56. Vazquez, J.J., Dixon, F.J.: Lab. Invest. 6, 205, 1957.
57. Vogel, R.A., Padula, J.F.: Proc. Soc. Exp. Biol. 98, 135, 1958.
58. Weller, T.H., Coons, A.H.: Proc. Soc. Exp. Biol. 86, 789, 1954.

59. Wignall, N., Culling, C.F.A., Vassar, P.S.: Amer. J. Clin. Pathol. 36, 469, 1961.
60. Wise, J.L., Shames, J.M., Derbes, V.J., Hunter, F.M.: Arch. Derm. 84, 37, 1961.
61. Wright, A.D., Francis, R.D.: Arch. Derm. 84, 87, 1961.