

UNCLASSIFIED

AD NUMBER
AD846266
NEW LIMITATION CHANGE
TO Approved for public release, distribution unlimited
FROM Distribution authorized to U.S. Gov't. agencies and their contractors; Critical Technology; DEC 1968. Other requests shall be referred to Department of Army, Fort Detrick, Attn: Technical Release Branch/TID, Frederick, MD 21701.
AUTHORITY
Biological Defense Research Lab ltr dtd 29 Sep 1971

THIS PAGE IS UNCLASSIFIED

AD846266


AD

TECHNICAL MANUSCRIPT 486

SPONTANEOUS CRYPTOCOCCOSIS  
IN A BURRO (EQUUS ASINUS)  
AND A RHESUS MONKEY (MACACA MULATTA):  
TWO CASE REPORTS

Robert E. Froehlich  
John Q. Mitten

DECEMBER 1968



STATEMENT #2 UNCLASSIFIED

This document is subject to special export controls and each transmittal to foreign governments or foreign nationals may be made only with prior approval of Dept. of Army, Fort Detrick, ATTN: Technical Release Branch/TID, Frederick, Maryland 21701

ACCESSION NO.		
DPSTI	WHITE SECTION	<input type="checkbox"/>
DDC	DIFF SECTION	<input checked="" type="checkbox"/>
UNANNOUNCED		<input type="checkbox"/>
REGISTRATION		
.....		
.....		
.....		
DISTRIBUTION/AVAILABILITY CODES		
DIST.	AVAIL. and/or	SPECIAL
2		

Reproduction of this publication in whole or in part is prohibited except with permission of the Commanding Officer, Fort Detrick, ATTN: Technical Releases Branch, Technical Information Division, Fort Detrick, Frederick, Maryland, 21701. However, DDC is authorized to reproduce the publication for United States Government purposes.

DDC AVAILABILITY NOTICES

Qualified requesters may obtain copies of this publication from DDC.

Foreign announcement and dissemination of this publication by DDC is not authorized.

Release or announcement to the public is not authorized.

DISPOSITION INSTRUCTIONS

Destroy this publication when it is no longer needed. Do not return it to the originator.

The findings in this publication are not to be construed as an official Department of the Army position, unless so designated by other authorized documents.

DEPARTMENT OF THE ARMY  
Fort Detrick  
Frederick, Maryland 21701

TECHNICAL MANUSCRIPT 486

SPONTANEOUS CRYPTOCOCCOSIS IN A BURRO (EQUUS ASINUS)  
AND A RHESUS MONKEY (MACACA MULATTA):  
TWO CASE REPORTS

Robert E. Froehlich

John Q. Mitten

Pathology Division  
MEDICAL SCIENCES LABORATORIES

Project 1B562602A059

December 1968

ABSTRACT

Spontaneous cases of Cryptococcus neoformans infection were diagnosed in a burro (Equus asinus) and a rhesus monkey (Macaca mulatta). The burro, which was native to Maryland, had a single cryptococcal lung granuloma, which was an incidental finding seen during a routine necropsy performed after sacrifice of the animal. The disease in the monkey, a recent arrival from India, was a disseminated, overwhelming infection to which the animal was apparently unable to react effectively. This is the first report of the disease in a burro and the second natural occurrence in the rhesus monkey.

## I. INTRODUCTION

Cryptococcosis (European blastomycosis, torulosis) has been recognized for over than a quarter of a century as both a chronic meningeal and a systemic fungal disease in man and animals. In the past few years it has been demonstrated with increasing frequency in a variety of wild and domestic animals.<sup>1,2</sup> The organism responsible for the disease in both man and animals is Cryptococcus neoformans. In man, this fungus has a special affinity for the central nervous system, especially the meninges, although it has been reported to occur in the lungs or as disseminated disease. In animals, it has been found in the central nervous system, mammary glands, nasal cavities, lungs, lymph nodes, and occasionally generalized throughout the body.<sup>1</sup> There is no positive evidence that indicates this disease is transmitted directly from host to host. The isolations of C. neoformans from soil and pigeon droppings strongly suggest these to be possible sources of infection.<sup>3</sup>

Information about cryptococcosis in Equus spp. and Macaca spp. is insufficient to determine whether it is a localized entity or a generalized disease. The available literature lists only eight cases of cryptococcosis in Equus spp., five of these having been reported before 1940.<sup>4-8</sup> In four of the eight cases the lesions were found in the nasal cavity.<sup>4-7</sup> The organism was isolated from a lip lesion of one horse which was later found to have systemic disease. In three cases only central nervous system lesions were found.<sup>9-11</sup> Although the reported cases are apparently few, the authors are acquainted with four additional cases that were histologically confirmed as having the disease but that have not been reported in the literature. In primates there are only two reported cases of spontaneous cryptococcosis. Both of these cases were in marmosets (Leontocebus geoffroyi) captured and housed in Panama.<sup>12</sup> Two additional cases of naturally occurring disseminated cryptococcosis in primates are being prepared for publication, one a rhesus and the second a Formosan monkey (Macaca cyclopsis).\*

---

\* Ford, D.; Garner, F.M.; personal communication.

## II. REPORT OF CASES

### A. CASE 1

An adult male burro (Equus asinus) with a non-contributory history, born and maintained at Fort Detrick, was part of an investigation involving a biological toxin. At the termination of the experiment the animal was sacrificed and a necropsy was performed.

The gross examination revealed a burro in good health and without any gross lesions related to the experiment. Near the ventral border of the left apical lung lobe, a circumscribed, firm, fibrous nodule approximately 2.5 cm in diameter was evident. The cut surface was smooth and almost cartilaginous in texture, and no cavitation or mineralization was visible. There was no attempt to isolate organisms.

The histologic architecture of the lesion was that of an active fibrocaceous granuloma with a large central abscess. Many small abscesses were scattered around the periphery obliterating the normal relationship of alveolar spaces, bronchioles, and small bronchi (Fig. 1). Myriads of fungus cells with necrotic debris and mixed inflammatory cells were prominent in the center of the lesion. The periphery was invested with plasma cells, large foamy histiocytes, a few multinucleate giant cells, and fibroblasts that appeared to be forming a weak fibrous capsule.

The diameter of the majority of the fungus cells, not including the capsules, ranged from 4 to 7 $\mu$  (Fig. 1). An occasional cell from 2 to 15 $\mu$  occurred. In the hematoxylin- and eosin-stained sections, a clear halo 3 to 5 $\mu$  in thickness usually separated the fungus cell wall from the adjacent lung tissue. When stained with Mayer's mucicarmine, the halo was revealed as a capsule containing carminophilic substances in the form of very small, blunt, irregularly shaped spines radiating from the deeply stained wall of the fungus cell. Budding cells were infrequent. India ink preparations made from formalin-fixed tissue clearly demonstrated the organism with its thick capsule.




FIGURE 1. (Left) Burro Lung Granuloma (Case 1) (Hematoxylin & Eosin, 80X); (Right) Yeast Cells Within Burro Lung Lesion (Case 1) (Periodic Acid Schiff, 250X).

## B. CASE 2

An adolescent male rhesus monkey with a non-contributory clinical history was found dead in its cage at the Animal Farm Division where it was undergoing routine quarantine and conditioning. The animal had arrived at this facility directly from India via air freight approximately 3 months prior to its death.

At autopsy the animal appeared to be in good physical condition. The axillary lymph nodes were moderately enlarged but were free of abscesses and caseation. No notation was made of gross lesions in the thoracic or abdominal viscera with the exception of a greatly enlarged cluster of lymph nodes at the root of the mesentery, the largest of which measured 1.8 by 1.4 by 1 cm. These nodes were firm, and their cut surfaces contained small amounts of cream-colored mucoid exudate, although they were grossly free of caseating and abscessing processes. No remarkable lesions were noted in the other organs. Acid-fast stains of impression smears of the mesenteric nodes failed to reveal the presence of mycobacteria. Homogenate from one node was inoculated onto Lowenstein-Jensen agar slants and incubated at 37 C.\* —

Colonies were visible at 48 hours, and India ink suspensions of this culture demonstrated the yeast cells surrounded by large halos. Examination of fixed tissue during preparation for routine histologic processing revealed the lungs, which were intratracheally perfused with formalin, to be diffusely firm, and their cut surfaces appeared relatively dry and contained irregular, pale areas up to 4 mm in diameter. Multiple incidental subpleural lesions of Pneumonyssus simicola were seen. The cut surfaces of the mesenteric nodes were variegated and lacked follicular definition except at the extreme periphery. The liver, spleen, kidneys, small intestine, colon, and heart were unremarkable. No brain tissue was available for examination.

Histologic preparations stained with hematoxylin and eosin revealed the presence of yeast cells in the lungs, mesenteric and axillary lymph nodes, spleen, liver, kidneys, and heart, while the enteric tissue was free of involvement. The yeast cells were of the same approximate diameter as described in Case 1, and sporadic cells displayed single budding.

Yeast cells and mononuclear inflammatory cells caused an irregular thickening of the lung alveolar walls to the extent of causing occlusion of some alveoli (Fig. 2). Alveolar consolidation and fibrosis were absent. Sparse numbers of neutrophils, small giant cells, and plasmacytes were

---

\* Isolation was made by Dr. Raymond Ediger, Animal Farm Division, and identified by Dr. Donald L. Greer, Chief of the Mycology Laboratory of the Public Health Service, Kansas City, Kansas, and by Dr. John P. Utz, of the Medical College of Virginia, Richmond, Virginia.

also seen. Abscesses, necrosis, mineralization, and fibrous proliferation were absent and bronchiolar structures were unaffected. A yeast embolus was seen in a pulmonary arteriole.

Virtually every glomerular capillary of both kidneys was distended with large numbers of yeast cells, some with budding elements (Fig. 3). Most glomeruli were invaded with or surrounded by mononuclear cells, although some contained yeast cells with no apparent inflammatory response. Several Bowman's spaces contained eosinophilic proteinaceous material. The inflammation often extended into parenchymal tissue with occasional invasion toward medullary areas.

Moderate numbers of organisms were seen in both the splenic follicular and sinusoidal areas; the basic splenic architecture, however, was intact. In the liver, organisms appear singly or in small clusters within the sinusoids, causing slight displacement of the hepatic cords. There was no evidence of inflammation.

Large numbers of organisms were observed within the follicles and medullary sinuses of the mesenteric nodes. The follicles at the extreme periphery of the node were somewhat less affected (Fig. 4), and the remnants of several medullary cords helped to maintain histologic identity. The axillary node was involved to a lesser degree but had similar characteristics, and, in addition, fungal organisms and plasma cells were seen in the adjacent dermis and underlying muscle tissue.

The cardiac lesions were limited to a small focus of fungus cells and chronic inflammatory infiltrate in the pericardial fat. A small embolic cluster of organisms was seen in the left ventricular heart blood.

Mayer's mucicarmine stain confirmed the presence of the densely stained yeast cells with clear halos containing the spinous carminophilic processes of shrunken capsular material.

There is presently no evidence of transmission of the disease from the two animals described to other animals in contact with them.

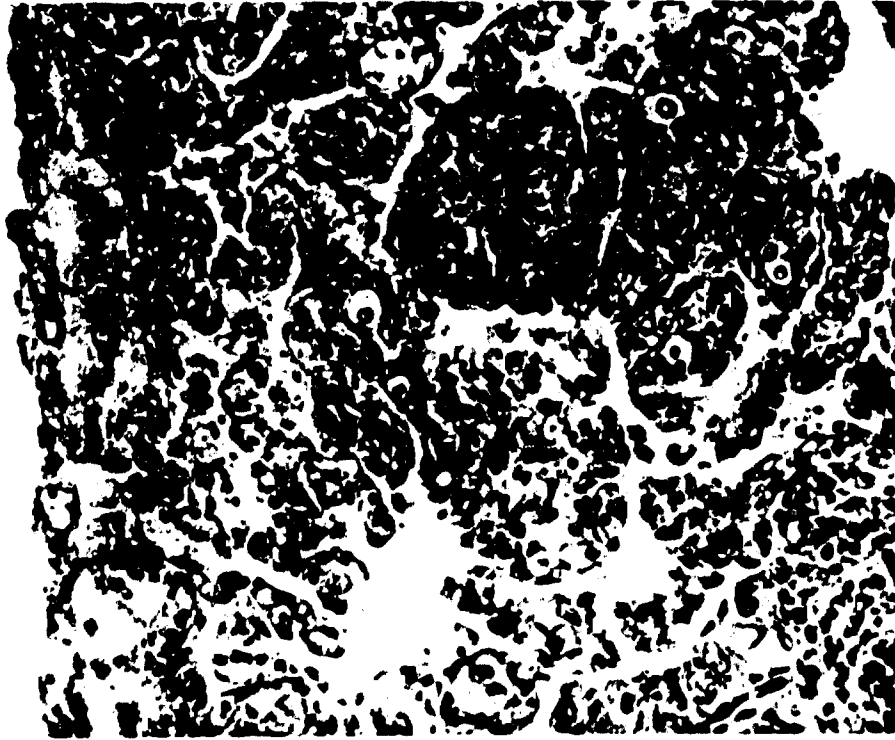


FIGURE 2. Organisms Within Lung Interstitium (Case 2). Note the clear capsular halos and relative lack of inflammation. (Hematoxylin & Eosin. 100X.)

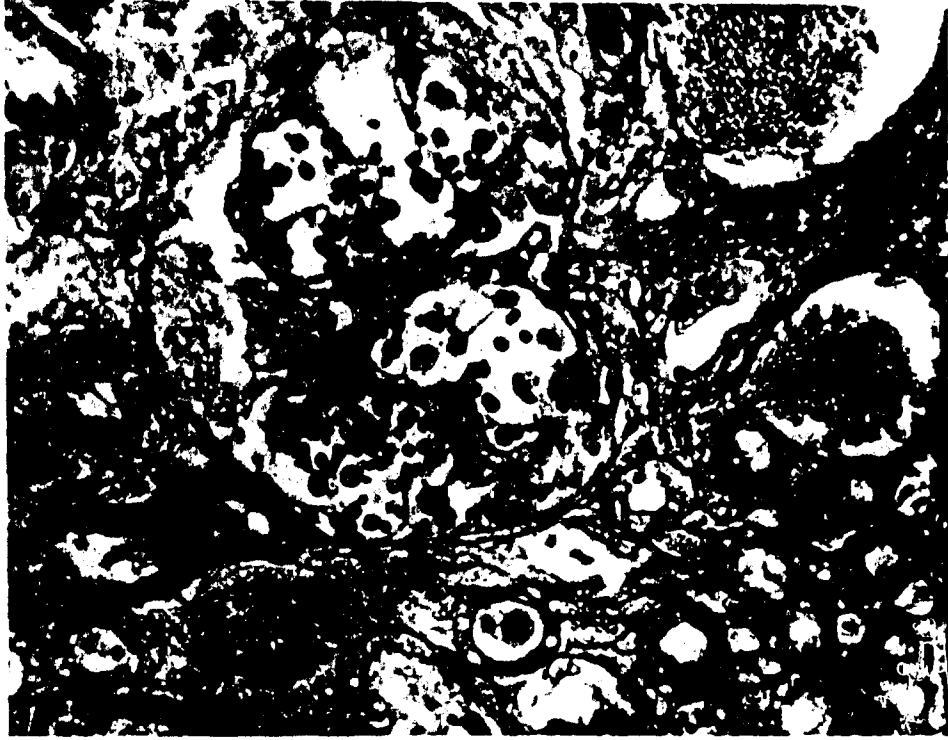

FIGURE 3. Invasion of Monkey Renal Glomerulus with Large Numbers of Organisms (Case 2). (Gomori's methenamine silver, 100X.)

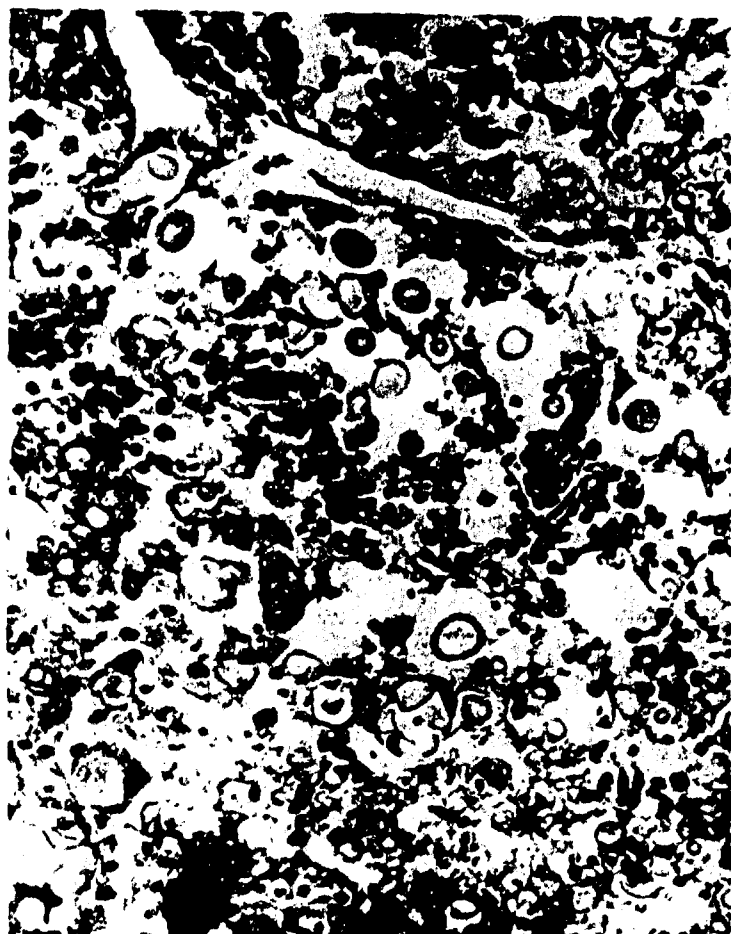

FIGURE 4. Medullary Area of a Mesenteric Lymph Node (Case 2). The normal sinusoidal architecture is obscured by organisms. (Hematoxylin & Eosin, 100X.)

### III. COMMENT

The lung lesion in the burro was that of a very active fibrocaceous granuloma containing large numbers of fungus cells. Contrary to previous reports, frank necrosis in pulmonary cryptococcosis is seldom observed. Likewise, in a lesion with this architecture, organisms are few and may be almost impossible to find, thus making differentiation from other granulomatous diseases difficult. This lesion in the burro is probably analogous to the scarred, apparently healing, pulmonary lesion in man.<sup>13,14</sup> Semarak<sup>15</sup> suggests that the infection can spread systemically from the nasopharynx. The lungs, however, are more frequently involved and consequently appear to be the more common portal of entry. Emmons' finding<sup>3</sup> that the fungus is frequently saprophytically associated with pigeon droppings provides a clue to the possible source of infection. Central nervous system lesions were found in only three of the previously reported cases of cryptococcosis in the Equus spp., while respiratory tract involvement was described in four cases. In the three cases of central nervous system infection, the primary pulmonary focus might have been either missed at the necropsy or resolved, as has been speculated in man.<sup>16</sup> Because cryptococcosis is a sporadic disease in man and animals, it is probably seldom seriously considered as a diagnosis of lung disease unless accompanied by central nervous system signs or those referable to other organs.<sup>11</sup>

The disease in the monkey was remarkable in its degree of dissemination and only limited host reaction to the organism. The kidney contained the most pronounced inflammatory reaction. In view of the fact that not all glomeruli exhibited responsive cells, one might infer that the inflammation may have been secondary to tissue destruction rather than a reaction to the yeast cells themselves. Fibrous encapsulation or abscess formation, mineralization, and giant-cell response were conspicuously absent. This lack of host defense is reminiscent of tuberculosis in the monkey, where one frequently fails to find encapsulation of a granuloma, and giant cells and even epithelioid cell transformation may be absent as well.

The origin of the Cryptococcus spp. in this infection cannot be ascertained. Bird droppings, which frequently heavily contaminate the monkey crates, may deserve consideration as a source of the fungus.

These two cases demonstrate the ability of Cryptococcus neoformans to cause either a local disease or a widespread, overwhelming and lethal infection in a poorly reactive host.

LITERATURE CITED

1. Barron, C.N. 1955. Cryptococcosis in animals. J. Amer. Vet. Med. Ass. 127:125-132.
2. Saunders, L.Z. 1948. Systemic fungus infections in animals: A review. Cornell Vet. 38:213-238.
3. Emmons, C.W. 1955. Saprophytic sources of Cryptococcus neoformans associated with the pigeon (Columba livia). Amer. J. Hyg. 62: 227-232.
4. Frothingham, L. 1902. A tumor-like lesion in the lung of a horse caused by a Blastomyces (Torula). J. Med. Res. 8:31-43.
5. Kikuchi, K. 1923. Über einen Fall von Blastomyose beim Pferd. J. Jap. Soc. Vet. Sci. 2:4-5.
6. Meyer, K.F. 1913. A pathogenic blastomyces from the horse. Proc. Pathol. Soc. 16:28.
7. Schellner, \_\_. 1935. Über eine beim Pferde durch Hefezellen verursachte Geschwulst in der Nasenhöhle und deren Nebenhöhlen. Z. Veterinark. 47:111-116.
8. Weidman, F.O.; Wile, U.J. 1935. Cutaneous torulosis. Arch. Dermatol. Syph. 31:58-66.
9. Herin, V.; Dormal, R. 1962. Relation dun cas de Cryptococcose Cérébrale Équine à Léopoldville. Ann. Soc. Belge Med. Trop. 42:865-870.
10. Irwin, C.F.P.; Rac, R. 1957. Cryptococcus infection in a horse. Australian Vet. J. 33:97-98.
11. McGrath, J.T. 1954. Cryptococcosis of the central nervous system in domestic animals. Amer. J. Pathol. 30:651. (Abstr.)
12. Takos, M.J.; Elton, N.W. 1953. Spontaneous cryptococcosis of marmoset monkeys in Panama. Arch. Pathol. 55:403-407.
13. Stoddard, J.L.; Cutler, E.C. 1916. Torula infection in man. Monograph Rockefeller Inst. Med. Res. No. 6, 115 p.
14. Sheppe, W.M. 1924. Torula infection in man. Amer. J. Med. Sci. 167-91-108.

15. Semarak, C.B. 1928. *Torula leptomeningitis*. Arch. Pathol. 6:1142-1150.
16. Wilson, J.W.; Plunkett, O.A. 1965. The fungous diseases of man. p. 111-129. Univ. California Press, Los Angeles, California.

DOCUMENT CONTROL DATA - R & D

(Security classification of title, body of abstract and indexing annotation must be entered when the overall report is classified)

1. ORIGINATING ACTIVITY (Corporate author)		27. REPORT SECURITY CLASSIFICATION	
Department of the Army Fort Detrick, Frederick, Maryland, 21701		Unclassified	
3. REPORT TITLE		28. GROUP	
SPONTANEOUS CRYPTOCOCCOSIS IN A BURRO ( <u>EQUUS ASINUS</u> ) AND A RHESUS MONKEY ( <u>MACACA MULATTA</u> ): TWO CASE REPORTS			
4. DESCRIPTIVE NOTES (Type of report and inclusive dates)			
5. AUTHOR(S) (First name, middle initial, last name)			
Robert E. Froehlich John Q. Mitten			
6. REPORT DATE		7a. TOTAL NO. OF PAGES	7b. NO. OF PAGES
December 1968		15	16
8a. CONTRACT OR GRANT NO.		9a. ORIGINATOR'S REPORT NUMBER(S)	
b. PROJECT NO. 1B562602A059		Technical Manuscript 486	
c.		9b. OTHER REPORT NO(S) (Any other numbers that may be assigned this report)	
d.			
10. DISTRIBUTION STATEMENT			
Qualified requesters may obtain copies of this publication from DDC. Foreign announcement and dissemination of this publication by DDC is not authorized. Release or announcement to the public is not authorized.			
11. SUPPLEMENTARY NOTES		12. SPONSORING MILITARY ACTIVITY	
		Department of the Army Fort Detrick, Frederick, Maryland, 21701	
13. ABSTRACT			
Spontaneous cases of <u>Cryptococcus neoformans</u> infection were diagnosed in a burro ( <u>Equus asinus</u> ) and a rhesus monkey ( <u>Macaca mulatta</u> ). The burro, which was native to Maryland, had a single cryptococcal lung granuloma, which was an incidental finding seen during a routine necropsy performed after sacrifice of the animal. The disease in the monkey, a recent arrival from India, was a disseminated, overwhelming infection to which the animal was apparently unable to react effectively. This is the first report of the disease in a burro and the second natural occurrence in the rhesus monkey.			
14. Key Words			
Cryptococcosis Burros Monkeys <u>Cryptococcus neoformans</u>			