

AWARD NUMBER: W81XWH-13-1-0492

TITLE: The Comparative Efficacy of the Masquelet versus Titanium Mesh Cage
Reconstruction Techniques for the Treatment of Large Long Bone Deficiencies

PRINCIPAL INVESTIGATORS: Zbigniew Gugala, MD, PhD

CONTRACTING ORGANIZATION: The University of Texas Medical Branch;
Galveston, TX 77555

REPORT DATE: October, 2015

TYPE OF REPORT: Annual

PREPARED FOR: U.S. Army Medical Research and Materiel Command
Fort Detrick, Maryland 21702-5012

DISTRIBUTION STATEMENT: Approved for Public Release;
Distribution Unlimited

The views, opinions and/or findings contained in this report are those of the author(s) and should not be construed as an official Department of the Army position, policy or decision unless so designated by other documentation.

REPORT DOCUMENTATION PAGE

Form Approved
OMB No. 0704-0188

Public reporting burden for this collection of information is estimated to average 1 hour per response, including the time for reviewing instructions, searching existing data sources, gathering and maintaining the data needed, and completing and reviewing this collection of information. Send comments regarding this burden estimate or any other aspect of this collection of information, including suggestions for reducing this burden to Department of Defense, Washington Headquarters Services, Directorate for Information Operations and Reports (0704-0188), 1215 Jefferson Davis Highway, Suite 1204, Arlington, VA 22202-4302. Respondents should be aware that notwithstanding any other provision of law, no person shall be subject to any penalty for failing to comply with a collection of information if it does not display a currently valid OMB control number. **PLEASE DO NOT RETURN YOUR FORM TO THE ABOVE ADDRESS.**

1. REPORT DATE 1 October 2015		2. REPORT TYPE Annual		3. DATES COVERED 30 Sep 2014 - 29 Sep 2015	
4. TITLE AND SUBTITLE The Comparative Efficacy of the Masquelet versus Titanium Mesh Cage Reconstruction Techniques for the Treatment of Large Long Bone Deficiencies				5a. CONTRACT NUMBER	
				5b. GRANT NUMBER W81XWH-13-1-0492	
				5c. PROGRAM ELEMENT NUMBER	
6. AUTHOR(S) Zbigniew Gugala, MD, PhD Ronald W. Lindsey, MD E-Mail: zgugala@utmb.edu; rlindsey@utmb.edu				5d. PROJECT NUMBER	
				5e. TASK NUMBER	
				5f. WORK UNIT NUMBER	
7. PERFORMING ORGANIZATION NAME(S) AND ADDRESS(ES) The University of Texas Medical Branch 2.316 Rebecca Sealy Hospital 301 University Blvd Galveston, TX 77555-0165				8. PERFORMING ORGANIZATION REPORT NUMBER	
9. SPONSORING / MONITORING AGENCY NAME(S) AND ADDRESS(ES) U.S. Army Medical Research and Materiel Command Fort Detrick, Maryland 21702-5012				10. SPONSOR/MONITOR'S ACRONYM(S)	
				11. SPONSOR/MONITOR'S REPORT NUMBER(S)	
12. DISTRIBUTION / AVAILABILITY STATEMENT Approved for Public Release; Distribution Unlimited					
13. SUPPLEMENTARY NOTES					
14. ABSTRACT The study comprises a single center, randomized, two-arm clinical trial conducted at the Department of Orthopaedic Surgery & Rehabilitation, University of Texas Medical Branch, Galveston, TX, with a primary objective to assess and compare the functional outcome of patients with large segmental bone defects reconstructed with the Masquelet technique (MT) versus the titanium mesh cage technique (TMCT). The secondary objectives include the radiographic determination of defect healing, and comparative assessment of cost and resource expenditures between the two techniques. From 11 patients with segmental defects presented to our institution over the last 12-month trial period, 6 met the study eligibility criteria and were successfully enrolled, and they include 3 MT, 3 TMCT. There are total 9 patients who have been enrolled in the study, with 7 actively participating. One patients (study subject #2) has been noncompliant with the postoperative management and developed superficial wound infection which progressed into deep infection/cellulitis and culminated with limb amputation. This SAE has been reported to PI's IRB and DoD, and this subject has been excluded from the study. Another subject (study subject #3) did not show up for surgery after signing informed consent. This subject has also been removed from the study. Both these subjects have been reported in the previous annual report. So far, 7 study subjects (4MT, 3 TMCT) are being followed, and they study course is uneventful. There are 3 additional potentially eligible study patients identified. The trial is ongoing and patients' enrollment actively in progress.					
15. SUBJECT TERMS Segmental bone defects reconstruction; Masquelet technique; Titanium mesh cage technique					
16. SECURITY CLASSIFICATION OF: U			17. LIMITATION OF ABSTRACT UU	18. NUMBER OF PAGES 10	19a. NAME OF RESPONSIBLE PERSON USAMRMC
a. REPORT Unclassified	b. ABSTRACT Unclassified	c. THIS PAGE Unclassified			19b. TELEPHONE NUMBER (include area code)

Table of Contents

	<u>Page</u>
1. Introduction.....	3
2. Keywords.....	3
3. Overall Project Summary.....	3
4. Key Research Accomplishments.....	8
5. Conclusion.....	8
6. Publications, Abstracts, and Presentations.....	9
7. Inventions, Patents and Licenses.....	9
8. Reportable Outcomes.....	9
9. Other Achievements.....	9
10. References.....	9
11. Appendices.....	9

1. Introduction

A United States Department of Defense grant funds a clinical trial that can be a major improvement in the treatment of extremity trauma associated with segmental bone defects. These devastating injuries occur in both civilians and the military population. They typically result from motor vehicle accidents, high-energy fractures, gunshot injuries, and blast injuries, but also can result from iatrogenic resections of a bone segment due to infection or tumor. Despite many recent advances in this area, achieving adequate bone defect healing and restoring injured limb function have been extremely challenging. Standard treatment options are exceedingly complex, require highly specialized equipment and/or skills, and typically require multiple surgical procedures over a protracted period of time. Moreover, major complications frequently occur with all the standard options and return to acceptable limb function is typically rare, and, in many instances amputation is required.

The present clinical study addresses this issue by assessing and comparing two innovative surgical bone defect treatment techniques that can be significantly more effective than the standard treatment options for civilian and military patients with these conditions. One treatment method—the Masquelet technique—involves two-stage surgery. In the first stage, a biomembrane around the defect is induced by the application of a cement spacer. The second-stage surgery is performed 6-8 weeks later and consists of cement spacer removal and bone graft placement while preserving the biomembrane. The other method—the cage technique—has been developed by the study principal investigators (PIs), and comprises one-stage surgical procedure in which a cylindrical, fenestrated titanium cage is packed with bone graft and implanted in the defect. Initial clinical experience with both of these techniques has been very promising, and there have been no prospective clinical studies comparing these two novel defect treatment methods. The present study aims to address that void.

The study is a randomized two-arm, single-center clinical trial conducted at the Department of Orthopaedic Surgery and Rehabilitation, The University of Texas Medical Branch (UTMB) in Galveston, Texas. The trial's primary objective is to assess and compare the functional outcomes of patients with large segmental bone defects reconstructed with the Masquelet technique versus the cage technique. The trial's secondary objectives include the radiographic determination of defect healing and the comparative assessment of cost and resource expenditures between the two techniques.

2. Keywords

Critical-size bone defects;
Segmental bone defect reconstruction;
Masquelet technique;
Titanium mesh cage technique

3. Overall Project Summary

Study Continuation and Approvals: As per annual renewal, all necessary approvals for the continuation of clinical trial were obtained from the UTMB Institutional Review Board (IRB) on Mar 26, 2015. No time lapses occurred between the renewed IRB approvals. The study has been progressing uneventfully in all its stages: the identification, recruitment, enrollment, consenting of the study eligible patients, the study surgical interventions, and the followup visits. No deviations from the protocol have been noted. No adverse events (AEs) have occurred for the study patients since the last annual report. A total of 9 patients have been enrolled in the study, of

which 2 were withdrawn (subjects #2 and #3) as reported in the previous annual report. In the last 12-month period encompassing the present annual report, 1 patient continued study followup, and 6 other patients were successfully enrolled and are being followed up uneventfully as per the study protocol. At present, a total of 7 patients have been enrolled, have received the respective surgical treatments for segmental bone defects as per study arm randomization with a specific bone grafting option, and are all actively being followed up, meeting all designated study time points, ie 2 weeks, 6 weeks, 3 months, 6 months, 12 months, and 18 months.

Patient Enrollment and Followup: Overall, patient enrollment in the trial has been sluggish, progressing at a slower rate than anticipated. Over the last 12-month period, a total of 10 patients with segmental defects presented to our institution. Among these patients were 2 civilian prisoners who met the study clinical eligibility criteria but were excluded because of lack of approval to include this vulnerable patient population (UTMB IRB disapproved the inclusion of the civilian prison patients in the trial); the other 2 were non-prison patients with segmental defects who did not meet the study inclusion/exclusion criteria due to a change in a treatment course or being considered noncompliant. The remaining 6 patients met all the study eligibility criteria, and they were all successfully enrolled, subsequently randomized to the respective study treatment arms, received the respective surgical treatment, and are currently being followed up as per the study protocol. The patients enrolled in the trial are the following:

- (1) **Patient #1:** A 66-year-old male with segmental bone loss in the distal femur due to a close-range, high-caliber civilian gunshot injury was enrolled. He was randomized to study Arm I and received the two-stage Masquelet technique in combination with a Reamer-Irrigator-Aspirator (RIA)-harvested bone graft (Option A) according to the study protocol. The patient has completed five of the required study followup visits (ie 2w, 6w, 3m, 6m, 12m), and is currently scheduled for his final 18-month followup visit (to take place in 3 weeks), thereby reaching the study endpoint. The patient's followup has been uneventful to date, and the patient has demonstrated very successful functional and radiographic defect treatment outcomes.

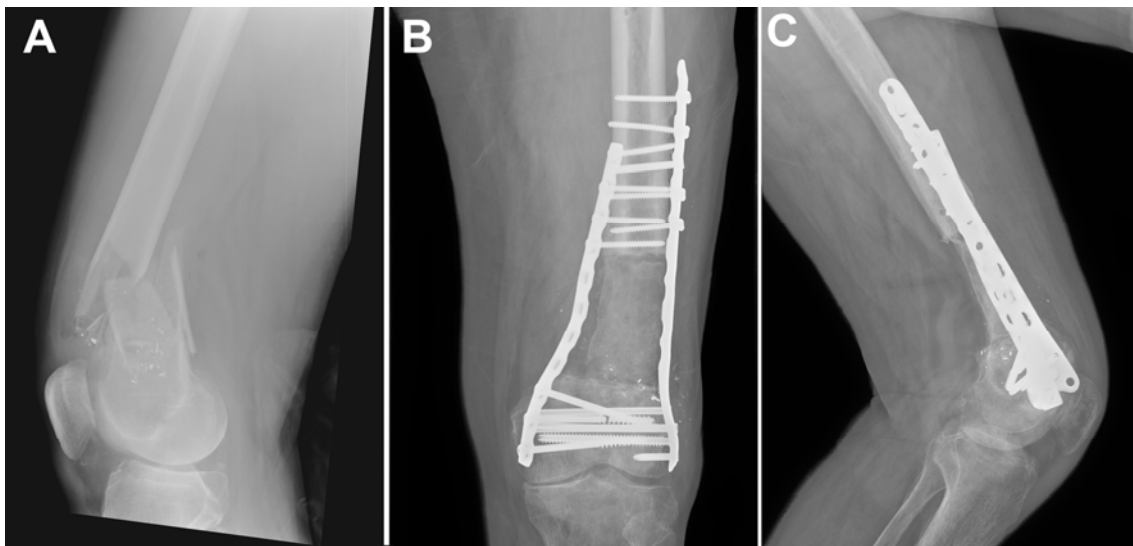


Fig 1. A short-range, high-caliber gun shot injury to the supracondylar portion of the femur (A) was initially treated with a fixed-angle condylar screw-plate construct. An infected nonunion developed, and infected bone was excised and the resultant segmental defect was treated using 2-stage Masquelet technique with RIA bone grafting and double-plate stabilization. The defect healing progressed uneventfully and graft consolidation was evident at 16 months post-surgical reconstruction (B,C).

- (2) **Patient #2:** A 36-year old female with a protracted infected proximal tibia nonunion treated with iatrogenic resection of the infected bone segment was enrolled. She was randomized to

Arm II and received the cage technique in combination with allograft cancellous croutons-demineralized bone matrix (DBM) composite (Option B). The surgical procedure was uneventful, and the patient was discharged from the hospital. At 2 weeks post-surgery, the patient developed a superficial wound infection, and did not appear for the scheduled 2-week followup visit. The wound infection subsequently progressed to deep soft tissue involvement and concomitant tissue necrosis. During the course of infection treatment which included intravenous antibiotics and several surgical wound irrigation and debridement procedures, the patient requested limb amputation despite being repeatedly offered limb salvage options. The patient wound complication was reported as a serious adverse event (SAE) to the UTMB IRB and to the DoD, and following limb amputation the patient was withdrawn from the study.

- (3) **Patient #3:** A 62-year-old male with an infected femur shaft nonunion/malunion was enrolled in the study and randomized to study Arm II. Prior to the scheduled surgery to resect nonunion and reconstruct the defect in accordance with the trial arm, ie the cage technique, the patient voluntarily left the hospital and has not returned for scheduled surgery. He could not be contacted despite numerous attempts. The patient has been removed from the study as noncompliant.
- (4) **Patient #4:** A 44-year-old female with humerus chronic osteomyelitis that has resulted in diaphyseal bone deficiency was enrolled in the study and randomized to Arm II. The patient received the cage technique for defect reconstruction in combination with allograft cancellous croutons-DBM composite (Option B). She has completed five study followup visits (2w, 6w, 3m, 6m, 12m), and is currently at 14 months post defect reconstruction period, and to date has demonstrated uneventful defect healing with very good radiographic and functional outcomes.

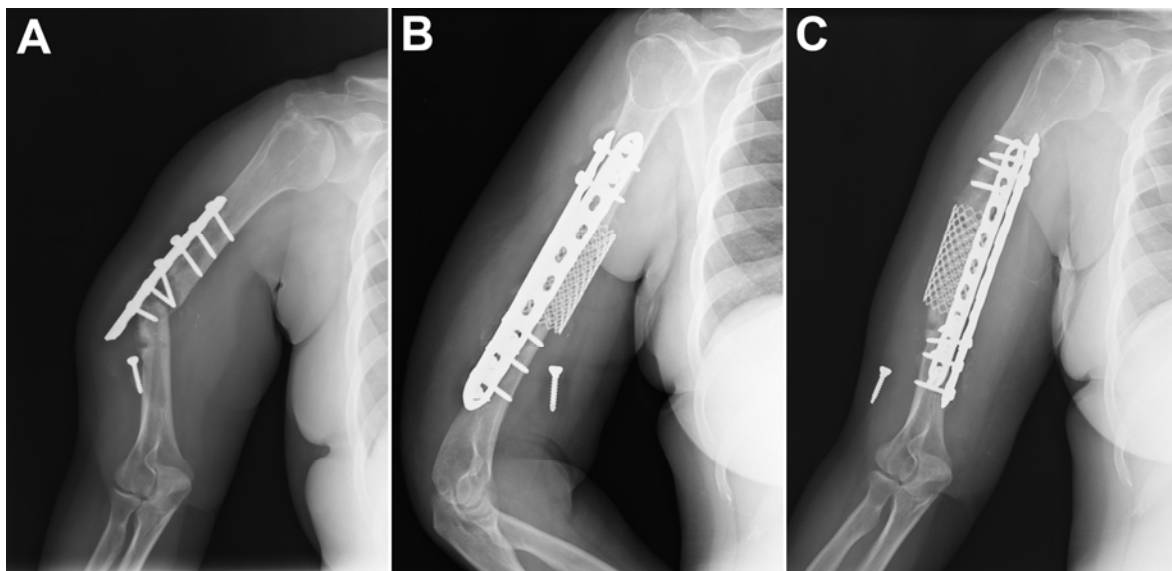


Fig 2. A chronic infected nonunion of the humerus midshaft (A) was treated with intravenous antibiotics and infected bone excision. The resultant iatrogenic defect was reconstructed with a cylindrical titanium cage in combination with allograft-DBM and stabilized with double adjacent plate-screw constructs. The defect healing progressed uneventfully and good functional outcome was achieved at 12 months post-surgery (B,C).

- (5) **Patient #5:** A 58-year-old female presented with a humerus segmental defect temporarily stabilized with an external fixator. This patient was enrolled and randomized to study Arm I,

and received the two-stage Masquelet technique in combination with an RIA-harvested bone graft (Option A) according to the study protocol. The patient completed four required study followup visits (2w, 6w, 3m, 6m), and is currently 8 months post definitive stage of defect reconstruction. The patient's followup has been progressing uneventfully to date, and she demonstrates very successful functional and radiographic defect treatment outcome.

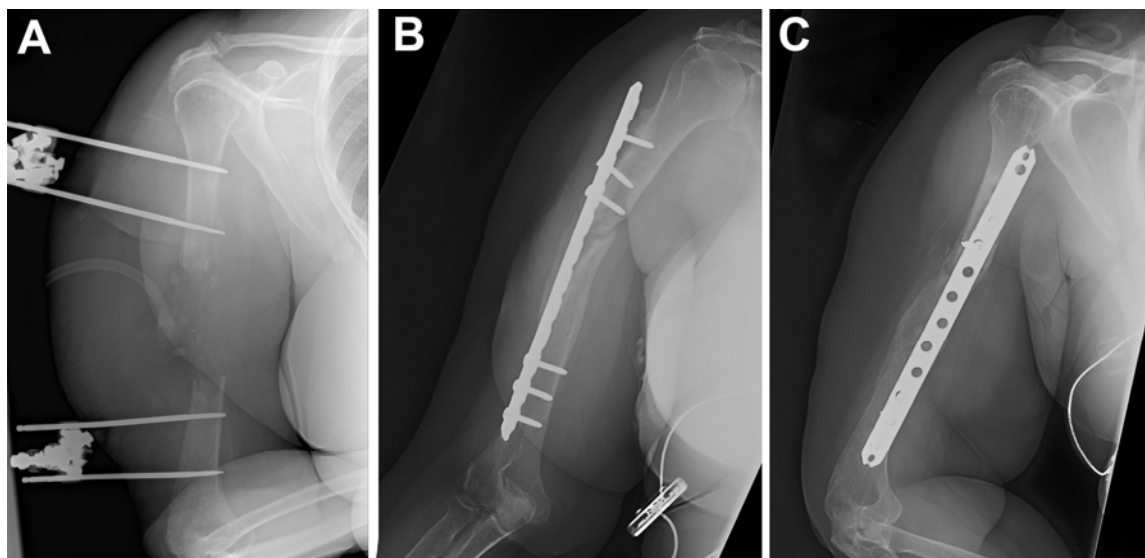


Fig 3. A humerus segmental defect (A) was treated with two-stage Masquelet technique in combination with RIA-bone grafting and locking plate-screw stabilization. Graft consolidation and defect healing are evident at 16 months post-surgical reconstruction (B,C).

- (6) Patient #6: A 59-year-old male presented with infected nonunion in the tibia as a result of open fracture. The patient was recruited into the study, and randomized to receive the cage technique for defect reconstruction in combination with allograft cancellous croutons-DBM composite (Option B). He has completed three study followup visits (2w, 6w, 3m), and is currently at 4 months post defect reconstruction. He has demonstrated uneventful defect healing as evidenced by plain radiography and functional assessment.

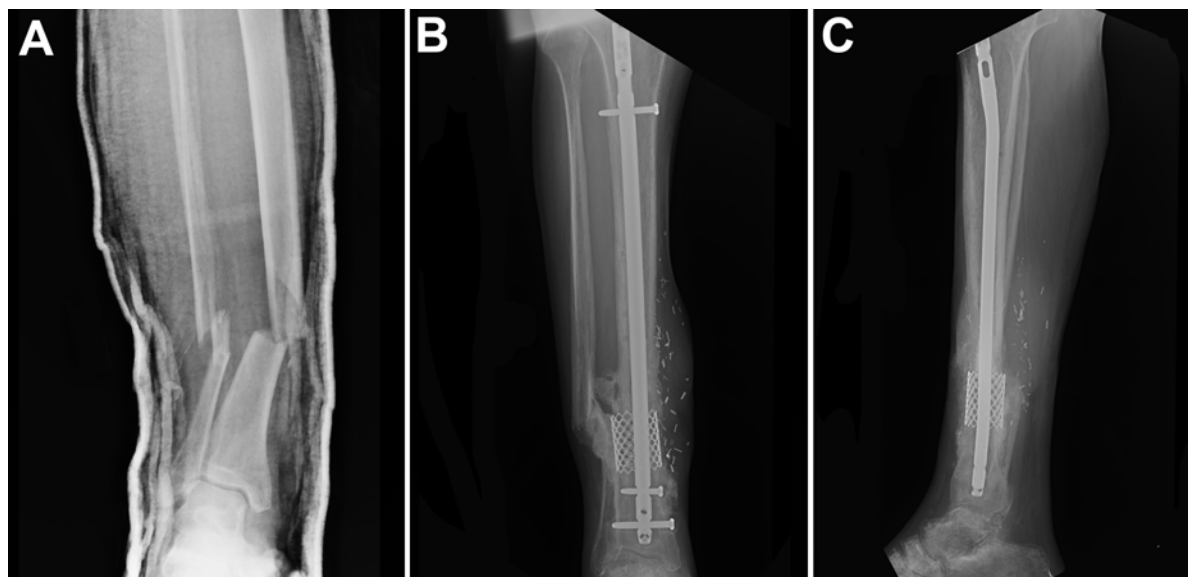

Fig 4. A chronic infected nonunion developed post Grade IIIB open tibia fracture (A). The excised infected bone resulted in an iatrogenic segmental deficiency, which was treated with a cylindrical titanium cage in combination with allograft-DBM, and stabilized with an intramedullary nail. The defect healing progressed uneventfully at 4 months post-surgery (B,C).

- (7) Patient #7: A 73-year-old male with a chronic infected nonunion/defect in the tibial mid-diaphysis was enrolled to the study and randomized in study Arm I. The patient received the two-stage Masquelet technique for defect reconstruction in combination with allograft cancellous croutons-DBM composite (Option B). The decision was made not to use RIA graft harvesting from the femur because of an ipsilateral knee prosthesis present in the operated extremity. The patient completed one study followup visit (2w), and is currently at 4 weeks post defect reconstruction. To date, he has demonstrated uneventful defect healing with very good radiographic and functional outcomes.

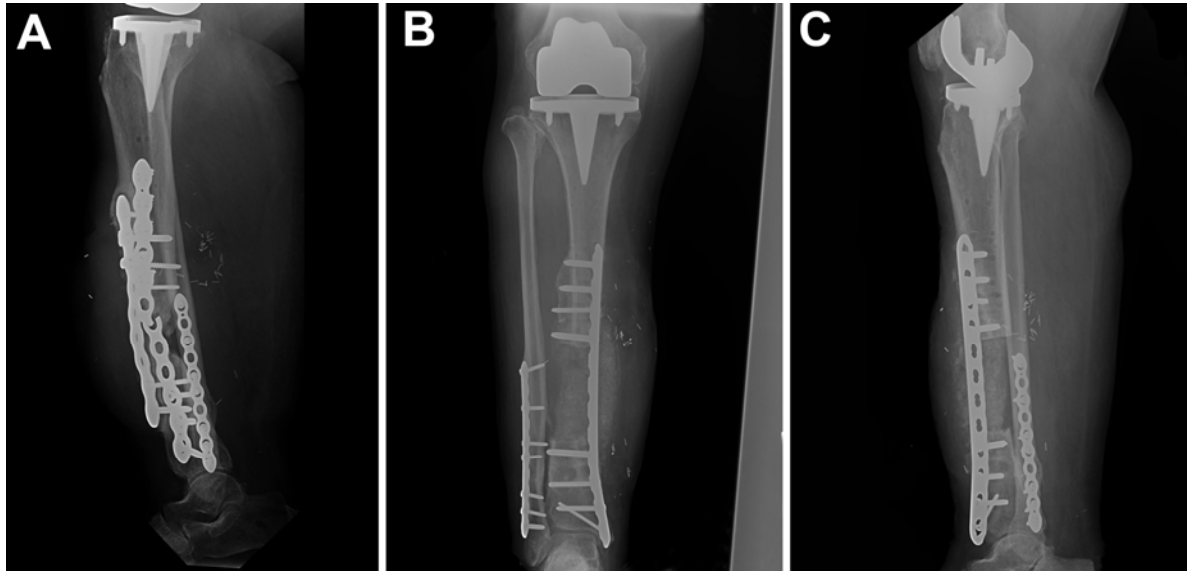


Fig 5. A tibial mid-diaphyseal infected nonunion with hardware failure (A) was treated with two-stage Masquelet technique combined with allograft cancellous-DBM graft and locking plate-screw stabilization. Initial graft consolidation within the defect is apparent at 4 weeks post-surgical reconstruction (B,C).

- (8) Patient #8: A 57-year-old male presented with a traumatic open Grade IIIB mid-diaphyseal femur defect resulting from a motor vehicle accident. The patient was enrolled in the study and randomized to study Arm I. He received the two-stage Masquelet technique in combination with a RIA+ autogenous iliac crest cancellous bone graft (Option A). The patient has completed the first, 2-week study follow up visit.

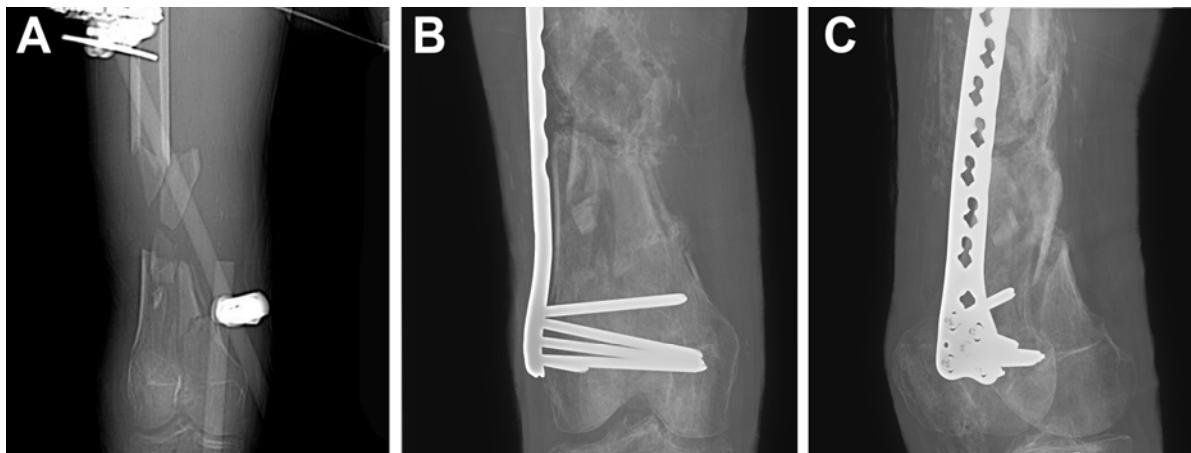


Fig 6. A comminuted open IIIB distal diaphyseal femur fracture (A) resulted in an infected nonunion, which was treated with two-stage Masquelet technique with RIA and cancellous autograft in conjunction with a condylar fixed-angle locking plate-screw stabilization. Early graft consolidation within the defect is apparent at 2 weeks post-surgical reconstruction (B,C).

- (9) Patient #9: A 38-year-old female with a chronic infected proximal tibia nonunion/defect was enrolled in the study and randomized to study Arm II. The patient received the cage technique for defect reconstruction in combination with allograft cancellous croutons-DBM composite (Option B). She has completed two study followup visits (2w, 6w), and is currently 7 weeks post defect reconstruction. To date, she has demonstrated uneventful defect healing.

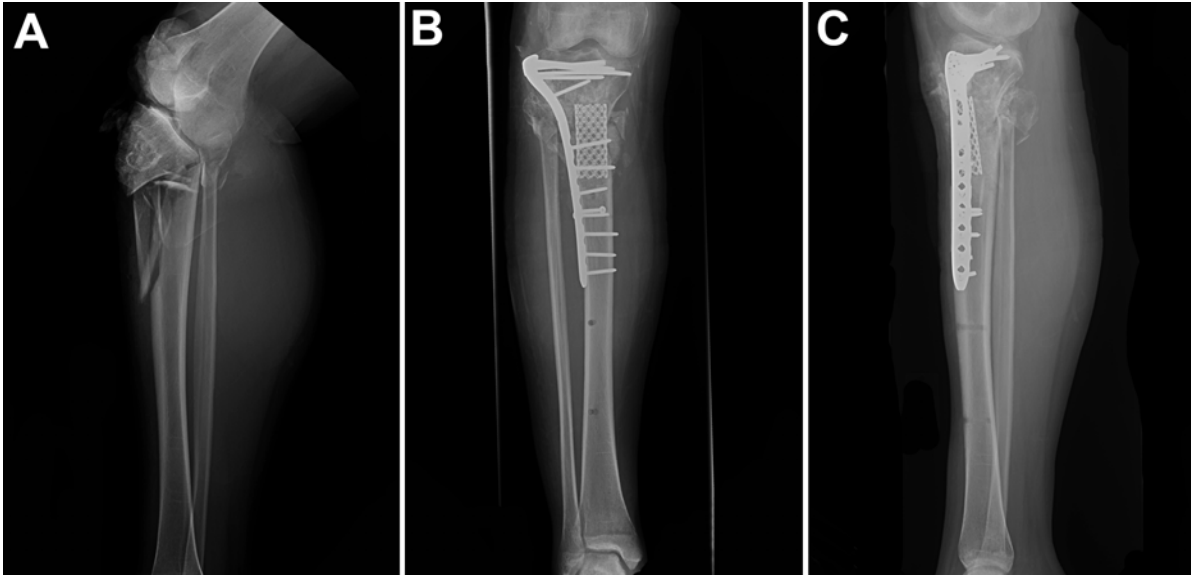


Fig7. A comminuted, open Grade IIIB proximal tibial fracture (A) resulted in an infected nonunion. The patient was treated with systemic and local antibiotics, infected bone was resected and the iatrogenic segmental defect treated with the cage technique in combination with cancellous-DBM allograft and angular locking plate-screw stabilization. Initial graft consolidation within the defect can be appreciated at 7 weeks post-surgical defect reconstruction (B,C).

Enhancement of Study Enrollment: The study PIs identified 4 additional eligible patients who are now in the pre-reconstruction phase of their defect management. These patients have been informed about study participation, and their successful enrollment is expected once they become suitable (ie, in 4-6 weeks) for the surgical defect reconstruction.

Eligible patient identification and enrollment for the trial is actively ongoing, although it is progressing more slowly than expected. The PIs will solicit referrals of the eligible patients from UTMB satellite out- and inpatient clinic locations. The PIs' institution recently expanded its clinical enterprise to include new out- and inpatient treatment sites, and this is expected to enhance eligible patient referral and recruitment.

4. Key Research Accomplishments

The study is ongoing.

UTMB IRB approvals/renewals have been obtained for study continuation.

Conduct of the trial in accordance with the IRB-approved protocol has been optimized, and the trail has been progressing uneventfully since the last annual report.

5. Conclusion

Study enrollment has been slow. Solutions to enhance patient accrual will include enhancement of referrals of the eligible patients from UTMB satellite clinic sites. The study has enrolled 9

patients, of whom 7 are actively participating. Since the last annual report 6 patients have been enrolled and they all remain as active study subjects. The followup of all enrolled patients in proceeding uneventfully. No study protocol deviations have occurred. No adverse events have been encountered. The PIs critically review each eligible patient's case for compliance, to avoid such problems as those encountered with patients #2 and #3, ie SAEs and/or mandating removal from the study.

Initial functional and radiographic outcomes of limb/defect healing for patients treated with both the Masquelet (Arm I) and the cage (Arm II) techniques are very favorable.

Utilizing the UTMB's EPIC electronic medical records facilitates planning the patients' followup clinic visits, informing/reminding the enrolled patients about the study participation and filling out the questionnaires. Using gift cards streamlines and simplifies the process of patient reimbursement for study participation including followup visits.

6. Publications, Abstracts, and Presentations

Lindsey RW & Gugala Z. The Comparative Efficacy of the Masquelet Technique versus Titanium Mesh Cage Technique in the Reconstruction of Segmental Bone Defects. A DoD-UTMB Clinical Trial. Baylor College of Medicine Grand Rounds, Houston, TX, on Oct 10, 2014.

Lindsey RW & Gugala Z. A DoD-UTMB Clinical Trial Determining the Efficacy of the Masquelet Technique versus Titanium Mesh Cage Technique in the Reconstruction of Segmental Bone Defects. UTMB Monthly Conference, Victory Lakes, TX, on Jan 21, 2015.

7. Inventions, Patents and Licenses

Nothing to report.

8. Reportable Outcomes

Nothing to report.

9. Other Achievements

Nothing to report.

10. References

Nothing to report.

11. Appendices

Nothing to report.