

AWARD NUMBER: W81XWH-13-1-0500

TITLE: Novel Therapy for Bone Regeneration in Large Segmental Defects

PRINCIPAL INVESTIGATOR: Jeffrey Anglen

CONTRACTING ORGANIZATION: INDIANA UNIVERSITY
INDIANAPOLIS IN 46202-5130

REPORT DATE: October 2015

TYPE OF REPORT: Annual

PREPARED FOR: U.S. Army Medical Research and Materiel Command
Fort Detrick, Maryland 21702-5012

DISTRIBUTION STATEMENT: Approved for Public Release;
Distribution Unlimited

The views, opinions and/or findings contained in this report are those of the author(s) and should not be construed as an official Department of the Army position, policy or decision unless so designated by other documentation.

REPORT DOCUMENTATION PAGE

Form Approved
OMB No. 0704-0188

Public reporting burden for this collection of information is estimated to average 1 hour per response, including the time for reviewing instructions, searching existing data sources, gathering and maintaining the data needed, and completing and reviewing this collection of information. Send comments regarding this burden estimate or any other aspect of this collection of information, including suggestions for reducing this burden to Department of Defense, Washington Headquarters Services, Directorate for Information Operations and Reports (0704-0188), 1215 Jefferson Davis Highway, Suite 1204, Arlington, VA 22202-4302. Respondents should be aware that notwithstanding any other provision of law, no person shall be subject to any penalty for failing to comply with a collection of information if it does not display a currently valid OMB control number. **PLEASE DO NOT RETURN YOUR FORM TO THE ABOVE ADDRESS.**

1. REPORT DATE October 2015		2. REPORT TYPE Annual		3. DATES COVERED 30/09/2014-29/09/2015	
4. TITLE AND SUBTITLE Novel Therapy for Bone Regeneration in Large Segmental Defects				5a. CONTRACT NUMBER W81XWH-13-1-0500	
				5b. GRANT NUMBER	
				5c. PROGRAM ELEMENT NUMBER	
6. AUTHOR(S) Melissa Kacena, Jeffrey Anglen, Tien-Min Chu E-Mail: mkacena@iupui.edu ; tqchu@iupui.edu ; jeffreyannglen@gmail.com				5d. PROJECT NUMBER	
				5e. TASK NUMBER	
				5f. WORK UNIT NUMBER	
7. PERFORMING ORGANIZATION NAME(S) AND ADDRESS(ES) Indiana University 980 Indiana Ave. RM 2232 Indianapolis, IN 46202-5130				8. PERFORMING ORGANIZATION REPORT NUMBER	
9. SPONSORING / MONITORING AGENCY NAME(S) AND ADDRESS(ES) U.S. Army Medical Research and Materiel Command Fort Detrick, Maryland 21702-5012				10. SPONSOR/MONITOR'S ACRONYM(S)	
				11. SPONSOR/MONITOR'S REPORT NUMBER(S)	
12. DISTRIBUTION / AVAILABILITY STATEMENT Approved for Public Release; Distribution Unlimited					
13. SUPPLEMENTARY NOTES					
14. ABSTRACT The purpose of this study is to test the efficacy of thrombopoietin (TPO) to heal a segmental bone defect (SBD) in a large animal model, the minipig. The scope of the research comprises the following specific aims (i) to determine the union rate of tibial midshaft defects in minipigs treated with BMP-2, TPO, or saline control; and (ii) to evaluate the safety and side effects of treating tibial midshaft defects in minipigs treated with BMP-2, TPO, or saline control. In the previous research period we completed surgeries and collection of tissue/data from 27 minipigs which had surgeries. we completed a pilot study to work out the surgical and equipment logistics and completed 12 minipig surgeries (plus the 4 pilot minipig surgeries). As we had to wait until all minipigs were euthanized before completing the majority of the analyses, we have only just begun these preparations. We have confirmed the quality of our blood samples and will begin blood chemistry analysis this reporting period. That said, the most significant findings during this period is that TPO is able to heal the critical size defect in minipigs. Our xray data show significant improvement compared to saline treated controls. We however also determined that our scaffolds were not weight bearing and with a different fixation method we believe we can even further improve TPO's efficacy which will be another goal in Year 3.					
15. SUBJECT TERMS Bone healing, bone morphogenetic protein (BMP), thrombopoietin (TPO), therapy, fracture healing, bone regeneration, minipig, pig					
16. SECURITY CLASSIFICATION OF:			17. LIMITATION OF ABSTRACT	18. NUMBER OF PAGES	19a. NAME OF RESPONSIBLE PERSON
a. REPORT	b. ABSTRACT	c. THIS PAGE			USAMRMC
Unclassified	Unclassified	Unclassified	Unclassified	26	19b. TELEPHONE NUMBER (include area code)

Table of Contents

	<u>Page</u>
1. Introduction.....	4
2. Keywords.....	4
3. Overall Project Summary.....	4
4. Key Research Accomplishments.....	5
5. Conclusion.....	7
6. Publications, Abstracts, and Presentations.....	7
7. Inventions, Patents and Licenses.....	7
8. Reportable Outcomes.....	7
9. Other Achievements.....	8
10. References.....	8
11. Appendices.....	8

1. INTRODUCTION: The **subject** of this research is the need for improved treatment of segmental bone defects. The **purpose** of this study is to test the efficacy of thrombopoietin (TPO) to heal a segmental bone defect (SBD) in a large animal model, the minipig. The **scope** of the research comprises the following specific aims (i) to determine the union rate of tibial midshaft defects in minipigs treated with BMP-2, TPO, or saline control; and (ii) to evaluate the safety and side effects of treating tibial midshaft defects in minipigs treated with BMP-2, TPO, or saline control.

2. KEYWORDS: Bone healing, bone morphogenetic protein (BMP), thrombopoietin (TPO), therapy, fracture healing, bone regeneration, minipig, pig

3. OVERALL PROJECT SUMMARY:

Task 1 and Milestone 1. Obtain Regulatory Approvals – Completed by **Drs. Kacena, Chu, and Anglen** (led by **Dr. Kacena**). Most recent amendment was approved 09/04/14 (ACURO).

Task 2. Perform surgeries on minipigs and evaluate bone healing with xray.

Task 2a. Fabricate Scaffolds –completed by **Dr. Chu**.

Task 2b. Perform surgeries on minipigs – 27 minipig surgeries completed – surgeries performed by **Drs. Anglen, Chu, and Cheng** (plus other approved trainees and vet technicians). **Drs. Chu and Anglen** optimized the surgical protocol on cadaver minipigs and live pilot minipigs first, tested hardware on tibia curvature etc. **Drs. Kacena and Chu** ordered all required supplies/equipment/reagents/animals and confirmed schedule. **Dr. Kacena** has been responsible for management of personnel/trainees for post-operative animal care. The time, effort, and even drugs required (pain management) for post-operative management of minipigs has been substantially larger than was anticipated. The veterinarian was in charge of deciding our post-operative pain management protocol. These studies required significantly more time, effort, and budget than we anticipated. We obtained significant internal funding and cost shared significant effort to accomplish the surgeries and post-operative care to date (we enlisted in the assistance of 6 medical students, 2 additional orthopaedic surgeons (Drs. Todd McKinley and Karl Shively), a graduate student, and a postdoctoral fellow (the latter has been averaging 60-90 hours/week since the surgeries have begun) in addition to our original team of 4 (**Drs. Kacena, Chu, Anglen, and Cheng**) and everyone is well over their anticipated % effort). We have not increased the salary associated with the effort or added salary for any of the additional personnel at this time, but for subsequent studies may need to reallocate funding.

Task 2c. Perform radiographic assessments. X-rays have been obtained for the 27 minipigs. Completed by **Drs. Anglen, Chu, and Cheng**.

Task 3. Determine the bone union rate of the minipigs after implant retrieval using uCT and histology.

Task 3a. Retrieve tibiae from minipigs – completed for 27 minipigs by **Drs. Chu and Cheng (and Dr. Kacena's medical students, postdoctoral fellows as well as pathologists)**.

Task 4. Determine the biomechanical properties of the newly formed callus.

Task 4a. Retrieve samples – completed for 27 minipigs by **Drs. Chu and Cheng (and Dr. Kacena's medical students, postdoctoral fellows as well as pathologists)**.

Task 4b. Perform torsion testing – completed for 27 minipigs by **Dr. Chu**.

Task 5. Evaluate potential systemic side effects of TPO by studying the blood of the minipigs before and post-surgery.

Task 5a. Collect blood samples. We have completed the collection of the blood samples as per approved IACUC/ACURO protocols. Completed for 27 minipigs by **Drs. Kacena and Cheng**

Task 5b. Evaluate platelet numbers. Complete blood counts were completed on all blood samples, data has been collected and is being analyzed. It appears there is no specific trend/changes for any of the minipigs assessed. Completed for 27 minipigs by **Drs. Kacena and Cheng**

The remaining tasks/milestones will be achieved in our final granting period.

The surgical method is detailed in our IACUC/ACURO protocols. Briefly, Prior to surgery, x-rays of the right tibia will be collected to confirm skeletal maturity (epiphyses are closed). Also prior to surgery, PPF/TCP scaffolds of 17 mm in the outer diameter, 10 mm in the inner diameter, and 25 mm in height will be fabricated using the casting method described in our previous publication. (Chu et al 2007) As a carrier for saline, BMP-2, or TPO we have chosen to use an FDA approved type I bovine collagen sponge (Helistat, 7.5 cm x 10.0 cm x 5.0 mm, ½ of a sponge will be used for each pig or 7.5 cm X 5.0 cm X 5.0 mm). Collagen sponges will be treated with BMP-2, TPO, or saline and allowed to sit for 15 minutes prior to implantation.

The animals will be induced and maintained under sodium thiopental and fentanyl dihydrogen citrate for the duration of the procedure. First, a subcutaneous implantable port system will be inserted into each minipig to provide better access for later blood sampling and injections. The animals will be properly draped and surgical site will be prepared using sterile technique. The right hind-limb will be prepared with betadine. A 10 cm incision will be made in the proximal diaphysis of the tibia using an anteromedial approach. The exposure will be carried down between the tibia and the TA muscle and the tibia will be circumferentially exposed through muscle elevation. The tibia will be marked for length and orientation to ensure rotational accuracy. Two parallel, transverse osteotomies will be made 25 mm apart with a reciprocating saw (Stryker, Kalamazoo, MI). The resulting free segment of bone will be removed, creating a critical-size defect. The scaffold will be placed into the segmental defect. The scaffold will be circumferentially surrounded by a type I collagen sponge soaked with BMP-2, TPO, or saline control and the joined ends will be secured with Vicryl suture. The intramedullary (IM) nail will be inserted through the proximal incision. The IM nail will be inserted in an antegrade fashion from the proximal bone fragment, through the central canal of the scaffold, terminating in the distal bone fragment, ensuring tight apposition between the cut bone ends and the scaffold. The IM nail will then be locked with 2 locking screws proximal and 2 locking screws distal to the segmental defect. The fascia and subcuticular layer will be closed with Vicryl suture. Vicryl suture will be used for skin closure. From our preliminary minipig study, we have not observed deformation of locking screws but have needed to tighten the screws. A fixed defect size is critical to the validity of our study and we will be cognizant during monthly x-rays to look for deformation of the nail and the need to tighten or replace screws. Thus far our surgical technique and hardware maintain defect size without mechanical failure.

Amoxicilline, benzylpenicillin and clavulanate will be given 24 hrs prior to the surgery and daily for 3 days after the surgery as prophylactic antibiotics; the animals will be monitored postoperatively and given analgesic drugs such as dexmedetomidine, buprenorphine, hydromorphone, and ketamine for three postoperative days at which time tramadol will then be given for up to 4 weeks based on veterinarian recommendations. Anteroposterior and lateral radiographs of both tibiae will be taken during the acclimation period before implantation to serve as controls as a standard for normal tibia mineralization (Toshiba Infinix VC with Vitrea 2 work station) and to exclude animals with pre-existing bone pathology.

4. KEY RESEARCH ACCOMPLISHMENTS: We recently completed surgeries and tissue collection from all 27 minipigs. 8 = saline control, 8 = 1.5mg BMP-2, 8 = 1.5 mg TPO, 3= 7.5 mg TPO. As the sample size was low in the high dose TPO group and there were complications observed with a pig in that group below we focus on data from the 3 groups with the higher sample sizes.

Figure 1 demonstrates the key methods.

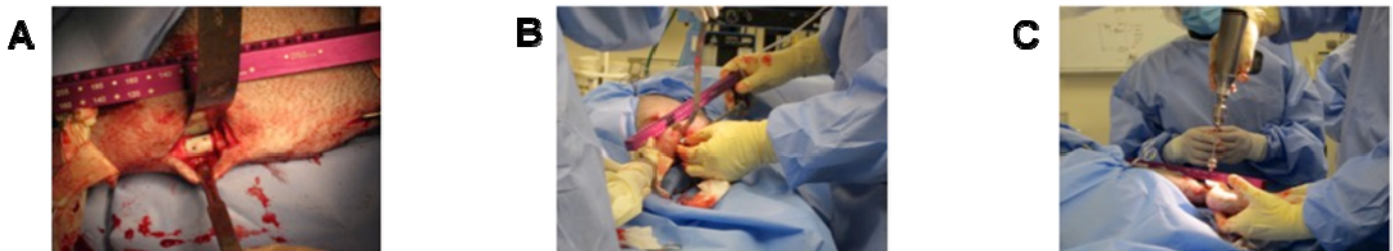

Figure 1: (A) Pig tibia with scaffold in place. (B) Manipulation of the surgical site to place collagen sponge loaded with treatment. (C) Fixation of the intramedullary nail. We created critical size defects in the tibiae of 24 Yucatan mini-pigs. Into these defects were placed synthetic scaffolds composed of polypropylene fumarate/tricalcium phosphate supported by an intramedullary nail that was further fixed with screws. Overlaying the scaffold was a collagen sponge impregnated with saline (control), BMP-2 (1.5 mg), or TPO (1.5 mg). After surgery, the animals were allowed to heal for 6 to 9 months during which they ambulated as tolerated. Healing progress was monitored with plain radiography at baseline and then monthly until euthanasia. Whole blood was collected at baseline, 1 and 2 weeks post-operatively, and then monthly until euthanasia. At euthanasia, experimental tibiae with the scaffold in place were collected and the specimens are being processed for micro-CT and histological examination.

Figure 2 shows the key x-ray findings.

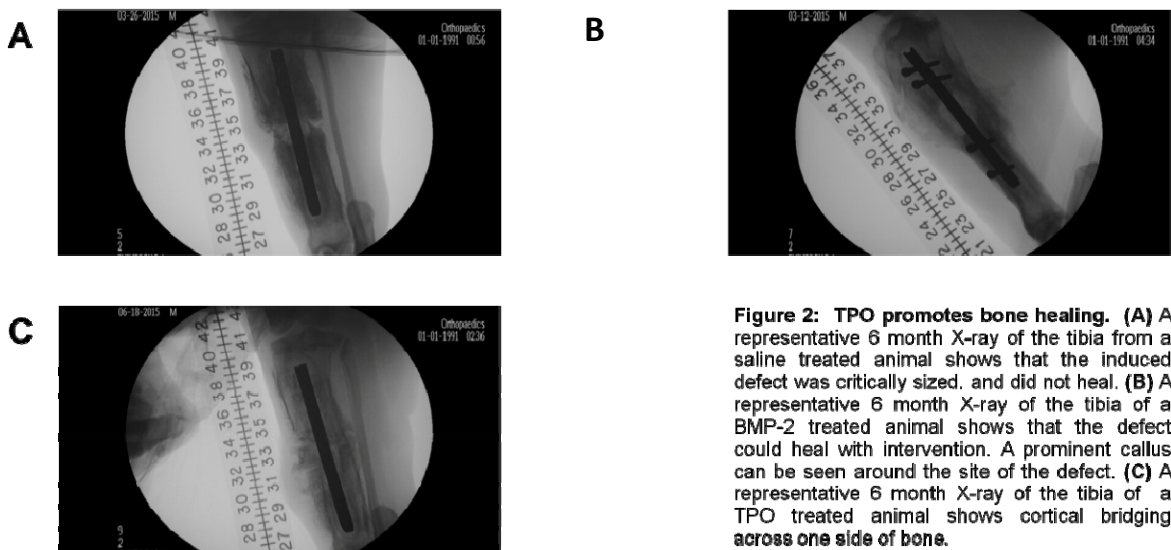


Figure 2: TPO promotes bone healing. (A) A representative 6 month X-ray of the tibia from a saline treated animal shows that the induced defect was critically sized, and did not heal. (B) A representative 6 month X-ray of the tibia of a BMP-2 treated animal shows that the defect could heal with intervention. A prominent callus can be seen around the site of the defect. (C) A representative 6 month X-ray of the tibia of a TPO treated animal shows cortical bridging across one side of bone.

Figure 3 shows the biomechanical data.

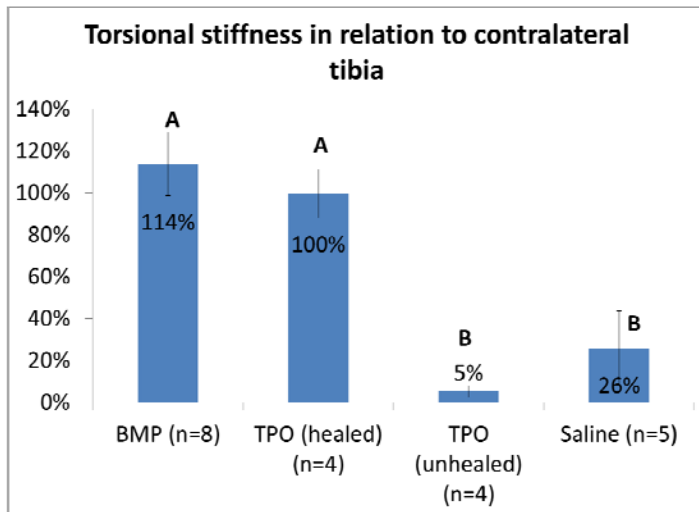


Figure 3. Both operated tibia and contralateral un-operated tibia were retrieved at sacrifice and were subjected to non-destructive torsional test using a digital torque gauge. All operated tibia in the BMP group healed and demonstrated a torsional stiffness of $114 \pm 15\%$ of the contralateral tibia. Four out of eight tibia in the 1.5 mg TPO group healed and showed a torsional stiffness of $100 \pm 12\%$ of the contralateral tibia. Another four tibia in the 1.5 mg TPO group did not heal. None of the tibia in the saline group healed. There were no statistical significant differences between the BMP and the healed TPO group ($p > 0.05$). These two groups are statistically significantly higher than the unhealed TPO and the saline groups. Due to retrieval issues and/or hardware/technical failures we unfortunately lost 3 of the saline specimens (experimental limb or contralateral limb), and thus only have $n=5$ rather than $n=8$ for the torsional stiffness data.

Figure 4 shows the key platelet data.

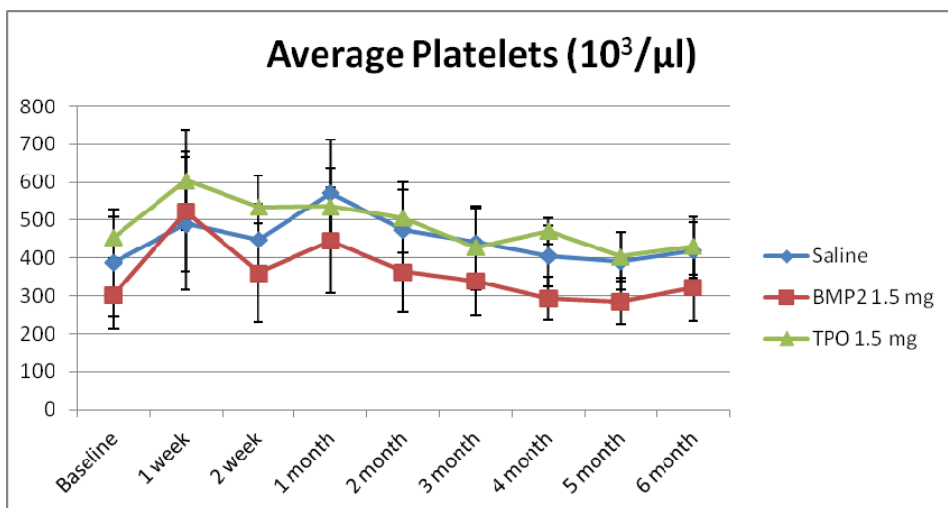


Figure 4. Blood was collected from the minipigs prior to surgery (baseline) as well as 1 week, 2 weeks, 1 month, 2 months, 3 months, 4 months, 5 months, and 6 months post-surgery. A complete blood count was completed on all blood samples. Platelet concentrations are reported as the mean \pm standard deviation. Platelet concentrations were significantly elevated in all minipigs 1 week after surgery (compared to respective baseline samples, $p < 0.001$). No differences were observed in platelet concentrations between minipigs treated with saline or TPO. However, using a 2-way anova we determined that platelet concentrations were significantly reduced in BMP-2 treated minipigs compared to that observed in saline treated controls ($p < 0.001$).

5. CONCLUSIONS:

- All eight of the saline control treated animals failed to demonstrate healing across the induced tibial defect.
- All eight of the BMP-2 treated animals showed healing across the induced tibial defect and had a torsional stiffness of $114\pm 15\%$ of the contralateral tibia.
- Four of the eight TPO treated animals showed healing across the tibial defect and had a torsional stiffness of $100\pm 12\%$ of the contralateral tibia.
 - No adverse effects from TPO treatment have been identified from blood measurements, organ pathology, or veterinary inspection.
 - Healed tibiae had torsional stiffness values which were not statistically different from their contralateral counterparts.
- While healing with TPO is better than that observed with saline, TPO did fail in 4 of 8 of our pigs. Based on our 4 healed tibia and our previous mouse/rat data, TPO morphologically appears to promote robust bone growth by direct bone healing, which takes longer to accomplish than BMP-2. Thus, if our fixation fails before our healing process is allowed to occur (which appears to have been the problem in the 4 tibiae that failed to heal), we cannot properly assess the value of TPO as a bone healing therapy. To better investigate this we have recommended completion of one more group of pigs with a different fixation strategy (more rigid fixation). As we secured internal funding to assist with defraying our expenses to date as well our revising our protocol to euthanize the pigs earlier than the original 1 year time point, we would have sufficient funds to complete this testing. Dr. Todd McKinley discussed this with Dr. Yadav in person at the August meeting in Florida.
- Platelet concentrations were significantly elevated in all minipigs 1 week after surgery (compared to respective baseline samples, $p < 0.001$).
- Platelet concentrations were significantly reduced in BMP-2 treated minipigs compared to that observed in saline treated controls ($p < 0.001$).
- TPO treatment did not result in a significant systemic increase in platelet concentration as significant differences were not observed in platelet concentrations between minipigs treated with saline or TPO.

Future plans: Complete uCT and histological analysis of tibias. Complete blood analyses. Develop new fixation strategy and test it. Finalize transition of co-PI from Dr. Jeffrey Anglen to Dr. Todd McKinley due to Dr. Anglen having left our institution.

6. PUBLICATIONS, ABSTRACTS, AND PRESENTATIONS:

a. Manuscripts submitted for publication during award period

1. Lay Press: N/A

2. Peer-Reviewed Scientific Journal:

1.) Davis KM, Griffin KS, **Chu T-MG**, Wenke JC, Corona BT, **McKinley TO**, **Kacena MA**. Muscle-bone interactions during fracture healing. *J Musculoskelet Neuronal Interact*, 15:1-9, 2015.

3. Invited Articles:

1.) Jewell E, Rytlewski J, **Anglen JO**, **McKinley TO**, Shively KD, **Chu T-MG**, **Kacena MA**. Surgical Fixation Hardware for Regeneration of Long Bone Segmental Defects: Translating Large Animal Model and Human Experiences. *Clinical Reviews in Bone and Mineral Metabolism*, in press.

2.) Griffin KS, Davis KM, **McKinley TO**, **Anglen JO**, **Chu T-MG**, Boerckel JD, **Kacena MA**. Evolution of bone grafting: Bone grafts and tissue engineering strategies for vascularized bone regeneration. *Clinical Reviews in Bone and Mineral Metabolism*, in press.

4. Abstracts:

1.) Rytlewski J, Childress P, Cheng Y, **Anglen JO**, Shively KD, **McKinley TO**, **Chu T-MG**, **Kacena MA**. Safety and efficacy of thrombopoietin as a novel bone healing agent in a large animal model. *SRPinAM Research Day*, 2015.

b. Presentations made during the last year:

1.) Rytlewski J, Childress P, Cheng Y, **Anglen JO**, Shively KD, **McKinley TO**, **Chu T-MG**, **Kacena MA**. Safety and efficacy of thrombopoietin as a novel bone healing agent in a large animal model. *SRPinAM Research Day*, 2015.

7. INVENTIONS, PATENTS AND LICENSES: Nothing to report.

8. REPORTABLE OUTCOMES: Nothing to report.

9. OTHER ACHIEVEMENTS:

Based in part on work supported by this award we have applied for several grant opportunities. From the Center for the Advancement of Science in Space (CASIS) we obtained funding for spaceflight ground testing “NASA Ames Grounds Testing – Rodent Research-4” (\$91,370). To further explore the role of TPO in stimulating angiogenesis during the bone healing process we obtained a grant from the Indiana Clinical and Translational Institute “Delivery of Recombinant Human Thrombopoietin for Large Bone Defect Regeneration” (\$27,951)

10. REFERENCES:

- 1.) **Chu TM**, Warden SJ, Turner CH, Stewart RL. Segmental bone regeneration using a load-bearing biodegradable carrier of bone morphogenetic protein-2. *Biomaterials*. 2007;28(3):459-467.
- 2.) Davis KM, Griffin KS, **Chu T-MG**, Wenke JC, Corona BT, **McKinley TO**, **Kacena MA**. Muscle-bone interactions during fracture healing. *J Musculoskelet Neuronal Interact*, 15:1-9, 2015.
- 3.) Jewell E, Rytlewski J, **Anglen JO**, **McKinley TO**, Shively KD, **Chu T-MG**, **Kacena MA**. Surgical Fixation Hardware for Regeneration of Long Bone Segmental Defects: Translating Large Animal Model and Human Experiences. *Clinical Reviews in Bone and Mineral Metabolism*, in press.
- 4.) Griffin KS, Davis KM, **McKinley TO**, **Anglen JO**, **Chu T-MG**, Boerckel JD, **Kacena MA**. Evolution of bone grafting: Bone grafts and tissue engineering strategies for vascularized bone regeneration. *Clinical Reviews in Bone and Mineral Metabolism*, in press.

11. APPENDICES:

We will include the final accepted version of the manuscript in next year’s report from references 3&4 above as revisions are still forth coming.

Note, updated Quad chart is submitted as an attachment as directed in the instructions.

Full publication related to scaffold creation (Chu et al 2007). Full publication related to muscle-bone interactions during fracture healing (Davis et al, 2015).

Segmental bone regeneration using a load-bearing biodegradable carrier of bone morphogenetic protein-2

Tien-Min G. Chu^{a,b,*}, Stuart J. Warden^c, Charles H. Turner^{a,b}, Rena L. Stewart^b

^a*Department of Biomedical Engineering, Purdue School of Engineering and Technology, Indiana University-Purdue University Indianapolis, Indianapolis, IN 46202, USA*

^b*Department of Orthopaedic Surgery, Indiana University School of Medicine, Indianapolis, IN 46202, USA*

^c*Department of Physical Therapy, School of Health and Rehabilitation Sciences, Indiana University, Indianapolis, IN 46202, USA*

Received 12 July 2006; accepted 3 September 2006

Available online 25 September 2006

Abstract

Segmental defect regeneration has been a clinical challenge. Current tissue-engineering approach using porous biodegradable scaffolds to delivery osteogenic cells and growth factors demonstrated success in facilitating bone regeneration in these cases. However, due to the lack of mechanical property, the porous scaffolds were evaluated in non-load bearing area or were stabilized with stress-shielding devices (bone plate or external fixation). In this paper, we tested a scaffold that does not require a bone plate because it has sufficient biomechanical strength. The tube-shaped scaffolds were manufactured from poly(propylene) fumarate/tricalcium phosphate (PPF/TCP) composites. Dicalcium phosphate dehydrate (DCPD) were used as bone morphogenetic protein-2 (BMP-2) carrier. Twenty-two scaffolds were implanted in 5 mm segmental defects in rat femurs stabilized with K-wire for 6 and 15 weeks with and without 10 µg of rhBMP-2. Bridging of the segmental defect was evaluated first radiographically and was confirmed by histology and micro-computer tomography (µCT) imaging. The scaffolds in the BMP group maintained the bone length throughout the duration of the study and allow for bridging. The scaffolds in the control group failed to induce bridging and collapsed at 15 weeks. Peripheral computed tomography (pQCT) showed that BMP-2 does not increase the bone mineral density in the callus. Finally, the scaffold in BMP group was found to restore the mechanical property of the rat femur after 15 weeks. Our results demonstrated that the load-bearing BMP-2 scaffold can maintain bone length and allow successfully regeneration in segmental defects.

© 2006 Elsevier Ltd. All rights reserved.

Keywords: Bone morphogenetic protein (BMP); Bone regeneration; Calcium phosphate cement; Bone tissue engineering; Free form fabrication

1. Introduction

Segmental bone defects resulting from trauma or pathology represent a common and significant clinical problem. Limb amputation was historically the principal treatment option for these defects as they typically do not heal spontaneously [1]. With advances in medicine and science, alternative treatment options have developed such as the use of bone-grafting techniques. Autologous bone grafts are preferred as they possess inherent osteoconductivity, osteo-

genicity and osteoinductivity. However, there is often limited supply of suitable bone for autologous grafting, and its collection is frequently associated with donor-site morbidity. An alternative is to use allogeneic bone grafts from donors or cadavers. These circumvent some of the limitations associated with harvesting autologous grafts, but allogeneic bone grafts lack osteogenicity, have limited osteoinductivity and present a risk of disease transmission. These limitations necessitate the pursuit of alternatives for the management of segmental bone defects, with the latest approach being to use tissue-engineering techniques.

Tissue engineering for bone typically involves coupling osteogenic cells and/or osteoinductive growth factors with osteoconductive scaffolds [2,3] In terms of osteoinductive growth factors, most research has focused on the use of the bone morphogenetic proteins (BMPs) and, in particular,

*Corresponding author. Department of Biomedical Engineering, Purdue School of Engineering and Technology, Indiana University-Purdue University Indianapolis, Indianapolis, IN 46202, USA.

Tel./fax: +1 317 278 8716.

E-mail address: tgchu@iupui.edu (T.-M.G. Chu).

BMP-2 [1,4–8]. BMP-2 is a bone matrix protein that stimulates mesenchymal cell chemotaxis and proliferation, and promotes the differentiation of these cells into chondrocytes and osteoblasts [6,8]. These cellular effects bestow BMP-2 potent osteoinductive capabilities, which are primarily evident by the induction of new bone formation via a process of endochondral ossification when implanted at ectopic sites [9,10]. This osteoinductive action of BMP-2 is well established to be beneficial during the repair of fractures and segmental bone defects [1,5,7,8].

BMP-2 induces bone regeneration following injury and has been approved for limited clinical use in the form of recombinant human BMP-2 (rhBMP-2) [5]. However, rhBMP application has been limited by ongoing delivery issues. To facilitate retention of rhBMP-2 at the treatment site and reduce the effective dose, an appropriate carrier is required [9]. The preferred carrier consists of a scaffold that is both biocompatible and bioresorbable in order to limit tissue rejection and exposure to the scaffold material, respectively [11]. While numerous scaffolds have been manufactured that meet these requirements [12] many lack the ability to tolerate appreciable loads. This is of importance as segmental defects frequently occur in load-bearing bones. Scaffolds need to be able to tolerate loading so that patient morbidity is minimized during reparation and the structure of the engineered bone is optimized to the local mechanical environment. Few load-bearing scaffolds have been described in the literature, with many studies of tissue engineered bone regeneration with BMP-2 being conducted at non-load-bearing sites [13–16] or in defects stabilized with stress-shielding devices (bone plates or external fixation) [17–20].

In the current paper, we present a tissue-engineering strategy for bone regeneration using rhBMP-2 carried by a novel load-bearing biodegradable scaffold. Tube-shaped scaffolds were fabricated from a high strength biodegradable composite and calcium phosphate cement, and implanted into critical-sized defects in an established rodent model [21]. Defects and scaffolds were stabilized with a load-sharing device (intramedullary pin). The aim was to investigate the effect of our novel load-bearing scaffold carrying rhBMP-2 on segmental defect repair in the rat femur.

2. Materials and methods

2.1. Animals

Twenty-two adult male Long-Evans rats (weight = 450–550 g) were purchased from Charles River Laboratory (Wilmington, MA) and acclimatized for a minimum of 1 week prior to experimentation. Animals had ad libitum access to standard rat chow and water at all times, and all procedures were performed with prior approval of the Institutional Animal Care and Use Committee of Indiana University.

2.2. Scaffold manufacture

Polypropylene fumarate (PPF) with a molecular weight of 1750 g/mol and PI = 1.5 was obtained from Prof. Antonios Mikos (Rice University,

Houston, TX). A thermal-curable PPF/tricalcium phosphate (TCP) suspension was prepared by mixing PPF, *N*-vinyl pyrrolidinone (NVP), and TCP at a weight ratio of 1:0.75:0.66 [22]. Tube-shaped structures (outer diameter = 4 mm, inner diameter = 2 mm, height = 5 mm, with four side holes of 800 μ m diameter) were created by the indirect casting technique developed by Chu et al. [23,24]. Briefly, a scaffold design was generated using commercial Computer-Aided-Design software and a negative model obtained by using Boolean computer operation. Wax casting-molds were fabricated on a 3-D Inkjet Printing Machine (T66, Solidscape Inc. NH) according to the model design. The PPF/TCP slurry was combined with 0.5% benzoyl peroxide (thermal initiator) and 10 μ l of dimethyl *p*-toluidine (accelerator), and cast into the wax mold. Following polymerization, the wax mold was removed by acetone to reveal the scaffold. rhBMP-2 was aseptically added to half of the scaffolds prior to surgery by adding 10 μ g of rhBMP-2 (Wyeth, Cambridge, MA) to porous dicalcium phosphate dihydrate (DCPD) cement previously packed into the side holes of the scaffold (BMP-2 group). In the remaining scaffolds, DCPD without rhBMP-2 was added to the side holes (control group).

2.3. Segmental defect induction and surgical implantation of the scaffolds

All animals underwent surgery to create a unilateral midshaft femur segmental defect into which either a rhBMP-containing scaffold (BMP group) or control scaffold (control group) was implanted. A non-scaffold control group was not used in this study since the non-healing nature of 5 mm segmental defects in the rat femur is well established [25,26]. Following a pre-operative subcutaneous dose of buprenorphine hydrochloride analgesia (0.05 mg/kg; Buprenex[®]—Reckitt Benckiser Pharmaceuticals Ltd., Inc., Richmond, VA), surgical anesthesia was achieved using a mixture of ketamine (60–80 mg/kg; Ketaset[®]—Fort Dodge Animal Health, Fort Dodge, IA) and xylazine (7.5 mg/kg; Sedazine[®]—Fort Dodge Animal Health, Fort Dodge, IA) introduced intraperitoneally. The fur was clipped and cleaned using alternating chlorhexidine and 70% ethanol scrubs. Using a sterile technique, a 30-mm longitudinal incision was made over the lateral thigh, beginning just distal to the lateral knee joint and extending proximally. The intermuscular septum between the vastus lateralis and hamstring muscles was divided using blunt dissection to localize the femur. The lateral structures stabilizing the patella were divided and the patella manually dislocated medially. A 5 mm segment of the midshaft femur was removed following two parallel osteotomies under irrigation using a Dremel drill (Robert Bosch Tool Corporation, Mount Prospect, IL) with attached diamond-embedded wafer blade (Super Flex Diamond Disc, Miltex Inc, York, PA). To stabilize the fracture, a 1.25 mm diameter stainless steel K-wire (Synthes Inc, West Chester, PA) was inserted retrograde into the distal intramedullary canal, beginning in the knee between the femoral condyles. The wire was advanced to the segment defect and a scaffold centered over the tip. The wire passed through the central canal of the scaffold and was further advanced in a retrograde fashion into the proximal intramedullary canal and through the greater trochanter (Fig. 1). The distal tip of the wire was cut flush with the femoral condyles. After thorough irrigation, the patella was relocated and stabilized with an absorbable suture, and the muscle and skin layers closed and sutured.

2.4. Radiographic analysis

In vivo X-rays were taken of eight rats ($n = 4$ /group) at 1, 3, 6, 12 and 15-weeks post-operatively using a portable X-ray machine (AMX-110, GE Corp, Waukesha, WI). The rats were anesthetized using isoflurane (Abbott Laboratories, North Chicago, IL) and placed prone on an X-ray film cassette 29 inches beneath the X-ray source. Exposure was at 60 kVp for 2.5 mAs. All films were evaluated in a blinded fashion by three independent evaluators using a three-point radiographic scoring system (0 = no callus formation; 1 = possible union across the gap; 2 = complete callus bridging across the gap).

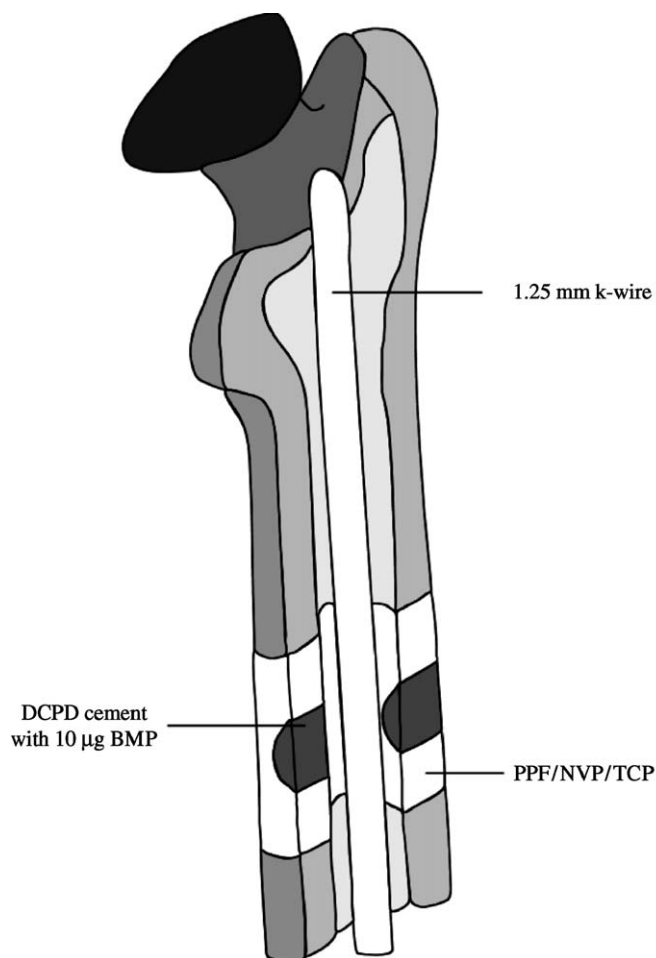


Fig. 1. Illustration of the BMP scaffold placed in rat femur segmental defect stabilized with intramedullary pin.

2.5. Assessment time points and specimen preparation

Animals were killed at 6 ($n = 4$ /group) and 15 ($n = 7$ /group) weeks post-operatively by inhalation of carbon dioxide followed by bilateral pneumothorax. In four rats per group, both femora were dissected free, and prepared for micro-computed tomography (μ CT), peripheral quantitative computed tomography (pQCT) and histological assessment by fixing in 10% neutral buffered formalin for 48 h and storing in 70% alcohol. In the remaining six rats in the 15-week group, hind limbs were prepared for mechanical testing by wrapping in gauze and storing in normal saline at -4°C .

2.6. μ CT

μ CT was performed on a randomly selected subgroup of segmental defects to visualize in three dimensions the stage of healing at 6- and 15-weeks post-operatively. The intramedullary K-wires were carefully removed before further assessment as metal causes beam-hardening artifacts during quantitative radiographic imaging. Each femur was centered in the gantry of a desktop μ CT machine (μ CT-20; Scanco Medical AG, Bassersdorf, Switzerland) and scanned at 50 kVp/32 keV (160 μ A) with an isotropic voxel size of 8 μ m. The scanned slices were reconstructed to show in three dimensions the external and cut-away views of the reparative callus and scaffold.

2.7. pQCT

pQCT was used to assess callus and scaffold volumetric bone mineral density (vBMD; mg/cm^3) at 6- and 15-weeks post-operatively. Each femur

was centered in the gantry of a pQCT machine (XCT Research SA+; Stratec Medizintechnik, Pforzheim, Germany) and scanned with a 70 μ m voxel size. Five 0.46 mm cross-sectional slices were scanned at 1 mm intervals, with the center slice coinciding with the center of the scaffold. Contouring mode 1 with a threshold of 240 mg/cm^3 was used to separate bone from soft tissue. Areas containing only the callus or scaffold were selected from the images using the region-of-interest (ROI) tool function, and the vBMD of the callus and scaffolds were determined, respectively.

2.8. Histological assessment

Femurs were processed for histomorphometry by washing, dehydrating in graded alcohols, and infiltrating and embedding undecalcified in methyl methacrylate (Aldrich Chemical Co., Inc., Milwaukee, WI). Thin (7 μ m) sections were taken through the long axis of each femur in the sagittal plane using a rotating microtome (Reichert-Jung 2050; Reichert-Jung, Heidelberg, Germany). Alternating sections were stained with hematoxyline-and-eosin and McNeals tetrachrome. Sections were viewed on Nikon Optiphot fluorescence microscope (Nikon, Inc., Garden City, NJ).

2.9. Mechanical testing

For mechanical testing, femurs were brought to room temperature overnight in a saline bath, the gauze wrapping removed, soft-tissue dissected free and the intramedullary pin carefully removed. A custom-made four-point bending fixture with a span width of 22.0 mm between the lower contacts and 8.0 mm between the upper contacts was used. The femurs were positioned cranial side up across the lower contacts. A preload of 1.0 N and crosshead speed of 20.0 mm/min were used to break the femurs. Measurements made using force-versus-displacement curves included: ultimate force (N) or the height of the curve, stiffness (N/mm) or the maximum slope of the curve, and energy to ultimate force (mJ) or the area under the curve up to ultimate force.

2.10. Statistical analyses

Statistical analyses were performed with the Statistical Package for Social Sciences (SPSS 6.1.1; Norusis/SPSS Inc., Chicago, IL) software. All comparisons were two-tailed with a level of significance set at 0.05, unless otherwise indicated. Mann–Whitney *U*-tests were used to compare radiographic scores between scaffold groups (BMP vs. control) at each time point. vBMD was compared by two-way factorial analyses of variance (ANOVA), with scaffold group (BMP vs. control) and time since surgery (6 vs. 15 weeks) being the independent variables. Mechanical properties were compared by two-way, one-repeated measure ANOVA, with scaffold group (BMP vs. control) and surgical group (segmental defect vs. intact control) being the between- and within-animal independent variables, respectively. Paired or unpaired *t*-tests were performed in the event of a significant ANOVA interaction, with a Bonferroni correction to the level significance for the number of pair-wise comparisons. ANOVA main effects were explored in the event of a non-significant interaction. Surgical group effect sizes were assessed using mean percentage differences and their 95% confidence intervals (CIs) between femurs with segmental defects and contra-lateral intact control femurs, whereas time since surgery effect sizes were determined using mean differences and their 95% CI between 6 and 15 weeks.

3. Results

3.1. Radiographic analysis

Qualitative assessment of the X-rays films showed no bone formation in any specimen at 1 week after surgery. At 3 weeks, continuous callus had formed and bridged across the gap defect in two of the four rats in the BMP group.

In the control group, some cortical bone thickening and callus formation was noticed immediately adjacent to the scaffold; however, callus did not bridge the gap. At 6 weeks, the callus bridge in the BMP group showed signs of consolidation and further thickening of the cortex next to the scaffold. In the control group, isolated radiopaque spots were noticed (islands of bone formation), but callus bridging was not present. Further thickening and remodeling of the callus was seen at 12 and 15 weeks in the BMP groups. At 12 and 15 weeks the control group showed increased callus size in the area adjacent to the scaffold, but there was no X-ray evidence of bridging callus (Fig. 2). In the X-ray score, all rats in the BMP group showed a score of 0 at week 1. Three rats received scores of 1 and 2 at week 3. At 6 weeks, all rats received a score of 2. All rats in the control group received a score of 0 till 12 weeks. One rat received a score of 1 at 15 weeks (Table 1).

There were no significant differences on radiographic scoring between the BMP and control groups after 1 ($p = 1.00$) or 3 ($p = 0.11$) weeks. After 6, 12 and 15 weeks, defects in the BMP group had significantly greater radiographic scores than those in the control group (all $p = 0.03$), indicating that the former had more advanced healing.

3.2. Histology

Histology sections at 6 weeks showed mineralized callus bridging the gap in the BMP group. Normal trabeculae were found between the periosteal callus and the scaffold (Fig. 3A). Residual DCPD can be seen in the side holes (Fig. 3B). Under H&E stain, normal fatty bone marrow was restored at 6 weeks (not shown). No inflammation reaction was seen in either BMP group or control group.

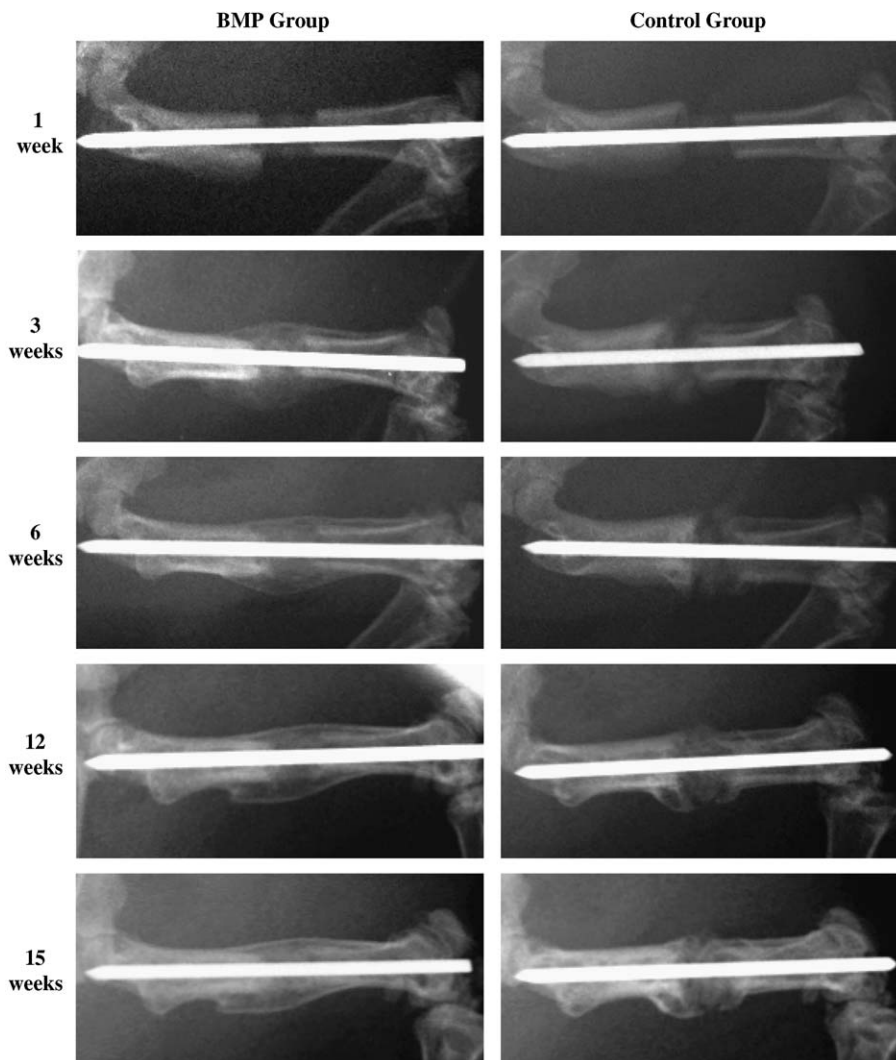


Fig. 2. Representative serial radiological images of segmental defects in the BMP and control groups at 1, 3, 6, 12 and 15 weeks post-operatively. At 3 weeks, callus had formed and bridged the segmental defect in the BMP group. In the control group, some cortical bone thickening and callus formation was evident immediately adjacent to the scaffold; however, there was no bridging callus. Between 6 and 15 weeks, the bridging callus in the BMP group showed signs of consolidation and remodeling. In contrast, in the control group only isolated regions of radio-opacity were evident within the defect region and no bridging callus was present.

In the control group, the histology showed characteristics of psuedoarthrosis with cartilage forming at the junction between the scaffold and the bone end. The periosteal callus did not bridge the gap (Fig. 3C). The histology of the BMP group at 15 weeks showed mature trabeculae between the scaffold and the periosteal callus (Fig. 3D). In the

control group, the gap was filled with fibrous tissue and the scaffolds started to crumble (not shown).

3.3. μ CT analysis

μ CT scans showed continuous callus formation around the scaffold in the BMP group at 6 weeks. Bone has also formed inside the marrow cavity next to the intramedullary pin (pin removed prior to scanning). Normal trabecular bone was found between the cortical layer of the callus and the BMP group scaffolds. In contrast, the control group at 6 weeks shows minimal bone formation outside the scaffold and the callus did not bridge the gap. At 15 weeks, the bridging callus and the trabeculae between the scaffold and the cortex of the callus is evident in the BMP group (Fig. 4).

The histology and μ CT results confirms the radiographic finding that defects in the BMP group to be bridged with mineralized callus that was integrated with the scaffold.

3.4. pQCT analysis

At 6 weeks, the measured vBMD of the callus for the BMP group and the control group was 724.05 ± 108.71 and $742.00 \pm 54.46 \text{ mg/cm}^3$, respectively. At 15 weeks, the vBMD of the callus increased to 959.06 ± 81.47 and

Table 1
Table showing the scores on bridging based on x-ray films at 1, 3, 6, 12, and 15 after surgery. X-ray scores: 0 = no callus formation; 1 = possible union across the gap; 2 = complete callus bridging across the gap

	Week	X-ray score		
		0	1	2
Control group (N = 4)	1	4	0	0
	3	4	0	0
	6	4	0	0
	12	4	0	0
	15	3	1	0
BMP group (N = 4)	1	4	0	0
	3	1	1	2
	6	0	0	4
	12	0	0	4
	15	0	0	4

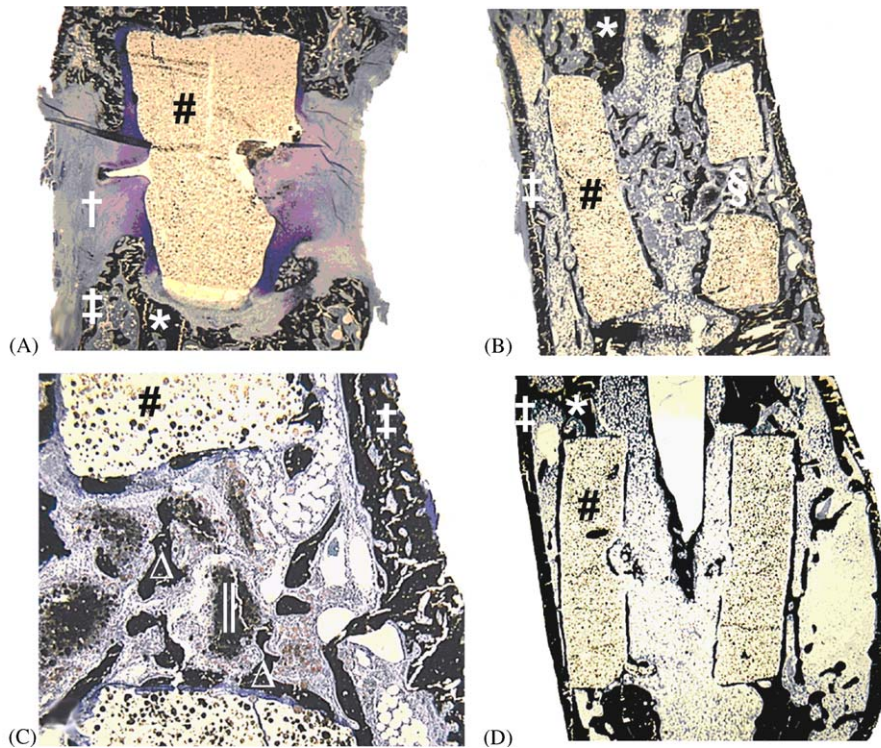


Fig. 3. Representative histological images of segmental defects in the (A) control and (B and C) rhBMP groups at 6-weeks post-operatively. Sections are stained with McNeal’s tetrachrome, which stains bone black. (A) Segmental defects in the control group demonstrated cartilaginous union, whereas (B) defects in the BMP group were bridged by mineralized callus that (C) invaded the side hole and was on the surface of the scaffold, indicating scaffold osteoconductivity. Inflammatory cells were not present in either scaffold group. (D) By 16-weeks post-operatively in the BMP group, the osteoconductivity of the scaffold is evident by the formation of new bone on its surfaces. * = original cortex of the femoral diaphysis, # = weight bearing biodegradable scaffold, † = cartilaginous tissue, ‡ = mineralized callus, § = side hole within the scaffold, || = residual dicalcium phosphate dihydrate cement carrying rhBMP-2, Δ = mineralized callus within the side hole and on the surface of the scaffold.




Fig. 4. Representative external and cut-away images of segmental defects in the (A) control and (B) BMP groups, as assessed by microcomputed tomography at 6-weeks post-operatively. (A) Segmental defects in the control group had minimal bone surrounding the scaffold and the reparative callus did not bridge the defect. (B) In contrast, the BMP group had a continuous mineralized callus around the scaffold, and bridging trabeculae beneath the cortical layer of the callus were integrated with the scaffold, indicating scaffold osteoconductivity. (C) By 16-weeks post-operatively in the BMP-group, the bridging trabeculae had thickened and there is evidence of bone formation of bone on the surfaces of the scaffold, indicating scaffold osteoconductivity. * = original cortex of the femoral diaphysis, # = weight bearing biodegradable scaffold, † = mineralized callus, ‡ = side hole within the scaffold.

$894.66 \pm 59.82 \text{ mg/cm}^3$ for BMP group and control group. The measured vBMD in the native femur was $920.95 \pm 49.53 \text{ mg/cm}^3$.

The mineral density of the scaffold was measured to evaluate the in vivo absorption of TCP in the scaffold. The mineral density of the scaffolds after 6 weeks of implantation in vivo was $625.96 \pm 26.14 \text{ mg/cm}^3$ in the BMP group and $613.59 \pm 16.35 \text{ mg/cm}^3$ in the control group. After 15 weeks of implantation in vivo, the mineral density of scaffold was $579.42 \pm 13.99 \text{ mg/cm}^3$ in the BMP group and $574.82 \pm 37.50 \text{ mg/cm}^3$ in the control group.

There were no significant interactions between group (BMP vs. control) and time since surgery (6 vs. 15 weeks) on either callus ($p = 0.28$) or scaffold ($p = 0.79$) vBMD (Fig. 4). Similarly, there were no group main effects on either callus ($p = 0.36$) or scaffold ($p = 0.62$) vBMD. In contrast, there were significant main effects for time since surgery on both callus ($p < 0.001$) and scaffold ($p < 0.01$) vBMD. Callus vBMD was 26% greater (mean difference = 193.2 mg/cm^3 , 95% CI = 118.2 to 268.2 mg/cm^3) and scaffold vBMD was 6.9% lower (mean difference = -42.4 mg/cm^3 , 95% CI = -65.7 to -19.1 mg/cm^3) at 15-weeks post-surgery than at 6 weeks (Fig. 5).

3.5. Mechanical property results

Mechanical properties of the femurs were only measured at 15 weeks. There were significant interactions between scaffold group (BMP vs. control) and surgical group (segmental defect vs. intact control) on ultimate force ($p = 0.01$) and stiffness ($p < 0.05$), but not energy to ultimate force ($p = 0.10$) (Fig. 6). Segmental defects in the BMP group had 290%, 286% and 234% greater ultimate force ($p < 0.01$), stiffness ($p = 0.04$) and energy to ultimate force ($p = 0.02$) than segmental defects in the control group, respectively (Fig. 6). There were no side-to-side differences in ultimate force (%diff = -1.4% , 95% CI = -35.7% to 32.8%), stiffness (%diff = -15.5% , 95% CI = -68.5% to 37.6%) or energy to ultimate force (%diff = -11.7% , 95% CI = -28.8% to 5.3%) in the BMP group between femurs with segmental defects and contra-lateral, intact control femurs (all $p = 0.15$ – 0.64). In contrast, femurs with segmental defects in the control group had lower ultimate force (%diff = -66.1% , 95% CI = -105.8% to -26.5%) and stiffness (%diff = -62.6% , 95% CI = -96.6% to -28.5%) than contra-lateral, intact control femurs (all $p < 0.02$). Energy to ultimate force between femurs with segmental defects and

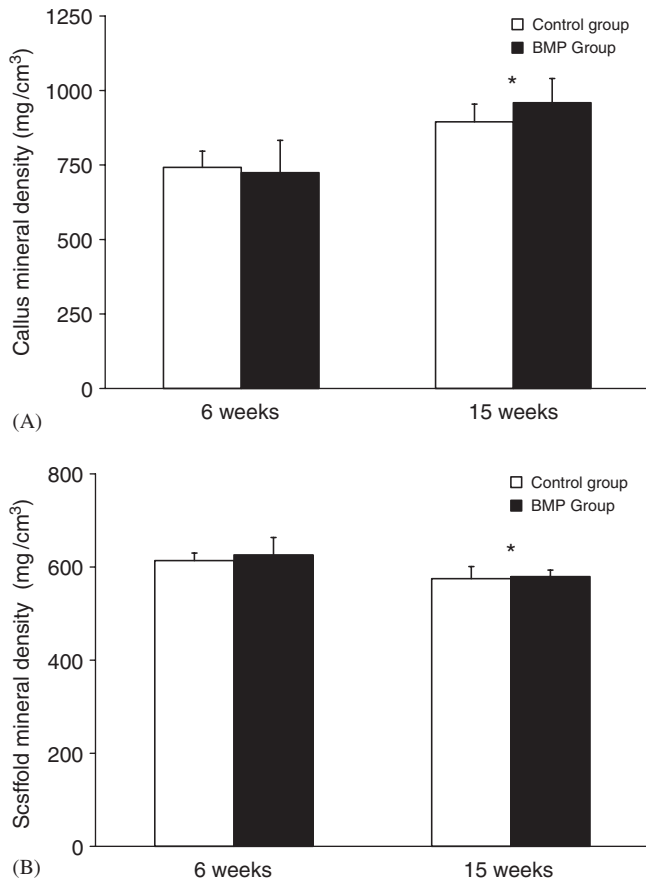


Fig. 5. Effect of scaffold group on volumetric bone mineral density (vBMD) of the: (A) callus and (B) scaffold, as assessed by peripheral quantitative computed tomography at 6- and 15-weeks post-operatively. * indicates significant main effect for time since surgery (6 vs. 15 weeks) ($p < 0.01$).

contra-lateral, intact control femurs did not differ in the control group (%diff = -61.4%, 95% CI = -126.4% to 3.6%) ($p = 0.06$).

4. Discussion

We have shown that scaffold made from high-strength biodegradable composite can be used as BMP-2 carrier to facilitate segmental defect regeneration in partial load-bearing condition, such as in the intramedullary pin fixation. This is clinically relevant since intramedullary pin fixation is commonly used for segmental defect fixation. In a retrospective study of ten patients treated for large bone defects, six of the 10 treatments involve the use of intramedullary pins [27]. In another retrospective study, six of the seven patients treated for acute segmental defects involve the use of intramedullary pins [28]. In research, Tiyapatanaputi et al. [29] demonstrated the use of pin to stabilize autograft, isograft and allograft in rat femoral defect model and found that the fixation using K-wire as intramedullary pin provided reproducible results in stabilized structural allograft. However, studies using

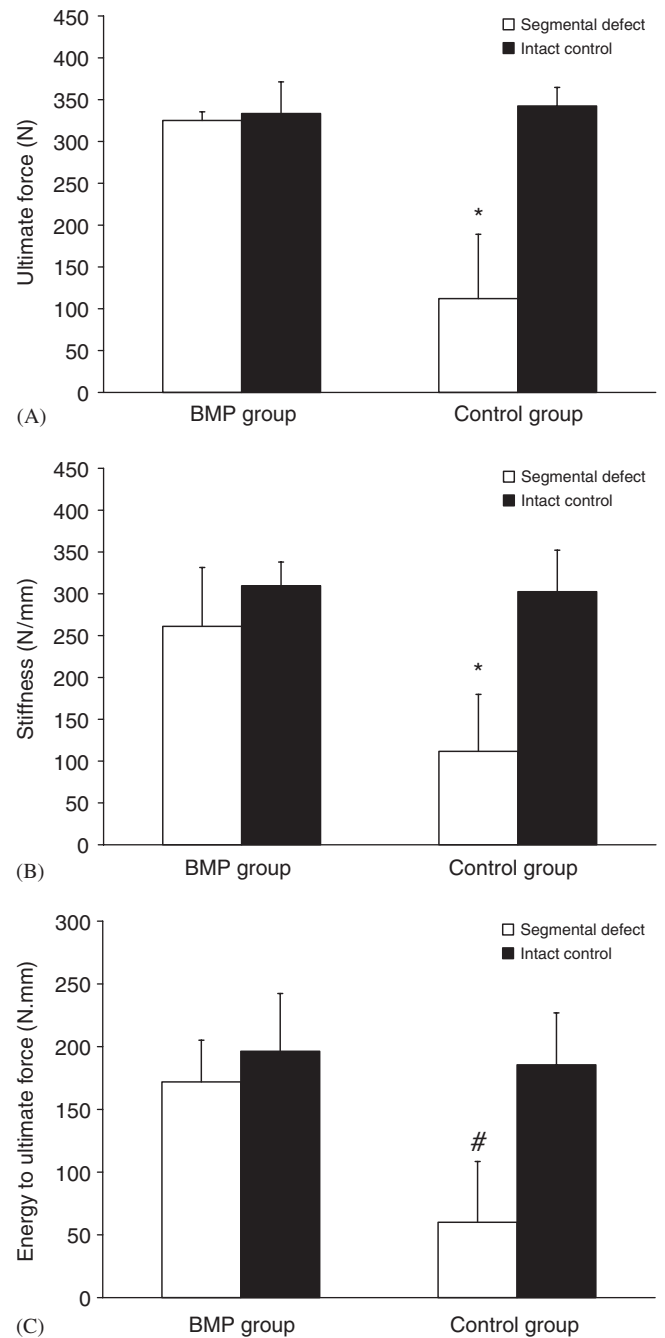


Fig. 6. Effect of scaffold group on femoral: (A) ultimate force, (B) stiffness and (C) energy to ultimate force, as assessed by mechanical testing at 15-weeks post-operatively. * indicates significantly different from all other groups ($p < 0.01$). # indicates significantly different from segmental defect in BMP group ($p = 0.02$).

intramedullary pin for stabilization tissue-engineering scaffolds has been lacking.

In this paper, we stabilized the PPF/TCP tissue-engineering scaffold by a 1.25 mm K-wire as intramedullary pin. This is a load-sharing model since the loads are shared by the friction between the intramedullary pin and the contact areas in the medullary canal and by the scaffolds. All BMP groups show bridging callus, indicating

a stable biomechanical environment conducive to the formation of callus. Our previous experience showed that the scaffolds made from DCPD by itself (compressive strength = 0.5 MPa) collapsed 1 day after implantation, indicating that the rats bear load on the scaffolds (unpublished results). The PPF/TCP scaffold has an initial compressive strength of 23 MPa, but gradually reduces to 12 MPa after 12 weeks of incubation in phosphate buffered solution at 37 °C [30]. The fact that PPF/TCP scaffold did not collapse during implantation indicates that the initial strength of the scaffold is sufficient to sustain the femoral loading in the rat model. When callus bridging failed to occur, the PPF/TCP scaffolds eventually collapsed after 15 weeks demonstrating that the degraded compressive strength of PPF/TCP at 15 weeks is no longer sufficient to support rat locomotor loads. This result together with the fact that the scaffold in the BMP group is still intact at 15 weeks also indicates that the bridging callus in the BMP group has assumed loading sharing/bearing function in the defect.

DCPD is biodegradable and has been used as BMP-2 carrier [25]. In this study, a dose of 10 µg of BMP-2 was found to induce callus formation, similar to the results by Ohura et al. [25] and Yasko et al. [26]. PPF/TCP is biodegradable [31], though very slowly, as pQCT measurements demonstrated that the scaffold density was reduced by less than 10% in 15 weeks of implantation. The long effect of the degradation byproduct on tissue is critical and will need to be studied in the future. Nonetheless, this study established that a compressive strength of 23 MPa will provide sufficient strength to withstand the initial load placed on the scaffold when the scaffold is implanted in rat femoral gap stabilized with intramedullary pin.

In BMP group and control group, we found no difference in callus vBMD, in consistent with the findings by Hyun et al. [32] where bone density in BMP-2 induced new bone was the same as normal bone. From our results, we conclude that it is the quantity and the distribution of the callus, but not the bone mineral density, that makes the difference between the BMP group and the control group.

5. Conclusions

In this study, investigated a tissue-engineering strategy for bone regeneration using BMP-2 carried by a load-bearing biodegradable scaffold. We found that critical-sized segmental defects in the rodent femur have advanced radiological, histological and mechanical healing using our tissue engineering strategy of load-bearing scaffold stabilized with intramedullary pins. Radiographical and histological healing is enhanced with weight-bearing biodegradable scaffolds of rhBMP-2.

The weight-bearing biodegradable scaffold of BMP-2 do not influence the callus mineral density. Finally, the mechanical properties of the segmental defects are restored with weight-bearing biodegradable scaffolds of BMP-2.

Acknowledgments

The authors would like to thank Prof. Antonio Mikos for providing the poly(propylene fumarate) used in this study. The authors would also like to thank Wyeth Co. for providing the rhBMP-2. The research was supported by NIH EB005426.

References

- [1] Giannoudis PV, Pountos I. Tissue regeneration. The past, the present and the future. *Injury* 2005;36(Suppl. 4):S2–5.
- [2] Buma P, Schreurs W, Verdonchot N. Skeletal tissue engineering—from in vitro studies to large animal models. *Biomaterials* 2004; 25(9):1487–95.
- [3] Mistry AS, Mikos AG. Tissue engineering strategies for bone regeneration. *Adv Biochem Eng Biotechnol* 2005;94:1–22.
- [4] Cowan CM, Soo C, Ting K, Wu B. Evolving concepts in bone tissue engineering. *Curr Top Dev Biol* 2005;66:239–85.
- [5] Mont MA, Ragland PS, Biggins B, Friedlaender G, Patel T, Cook S, et al. Use of bone morphogenetic proteins for musculoskeletal applications. An overview. *J Bone Joint Surg Am* 2004;86-A(Suppl. 2):41–55.
- [6] Reddi AH. Role of morphogenetic proteins in skeletal tissue engineering and regeneration. *Nat Biotechnol* 1998;16(3):247–52.
- [7] Termaat MF, Den Boer FC, Bakker FC, Patka P, Haarman HJ. Bone morphogenetic proteins. Development and clinical efficacy in the treatment of fractures and bone defects. *J Bone Joint Surg Am* 2005;87(6):1367–78.
- [8] Wozney JM, Rosen V. Bone morphogenetic protein and bone morphogenetic protein gene family in bone formation and repair. *Clin Orthop Relat Res* 1998(346):26–37.
- [9] Urist MR, Lietze A, Dawson E. Beta-tricalcium phosphate delivery system for bone morphogenetic protein. *Clin Orthop Relat Res* 1984(187):277–80.
- [10] Wang EA, Rosen V, D'Alessandro JS, Bauduy M, Cordes P, Harada T, et al. Recombinant human bone morphogenetic protein induces bone formation. *Proc Natl Acad Sci USA* 1990;87(6):2220–4.
- [11] Seeherman H, Wozney JM. Delivery of bone morphogenetic proteins for orthopedic tissue regeneration. *Cytokine Growth Factor Rev* 2005;16(3):329–45.
- [12] Perry CR. Bone repair techniques, bone graft, and bone graft substitutes. *Clin Orthop Relat Res* 1999(360):71–86.
- [13] Akamaru T, Suh D, Boden SD, Kim HS, Minamide A, Louis-Ugbo J. Simple carrier matrix modifications can enhance delivery of recombinant human bone morphogenetic protein-2 for posterolateral spine fusion. *Spine* 2003;28(5):429–34.
- [14] Arosarena OA, Collins WL. Bone regeneration in the rat mandible with bone morphogenetic protein-2: a comparison of two carriers. *Otolaryngol Head Neck Surg* 2005;132(4):592–7.
- [15] Hu Y, Zhang C, Zhang S, Xiong Z, Xu J. Development of a porous poly(L-lactic acid)/hydroxyapatite/collagen scaffold as a BMP delivery system and its use in healing canine segmental bone defect. *J Biomed Mater Res A* 2003;67(2):591–8.
- [16] Suzuki A, Terai H, Toyoda H, Namikawa T, Yokota Y, Tsunoda T, et al. A biodegradable delivery system for antibiotics and recombinant human bone morphogenetic protein-2: a potential treatment for infected bone defects. *J Orthop Res* 2006;24(3):327–32.
- [17] Baltzer AW, Lattermann C, Whalen JD, Wooley P, Weiss K, Grimm M, et al. Genetic enhancement of fracture repair: healing of an experimental segmental defect by adenoviral transfer of the BMP-2 gene. *Gene Ther* 2000;7(9):734–9.
- [18] Betz OB, Betz VM, Nazarian A, Pilpil CG, Vrahas MS, Boussein ML, et al. Direct percutaneous gene delivery to enhance healing of segmental bone defects. *J Bone Joint Surg Am* 2006;88(2):355–65.

- [19] Lieberman JR, Daluiski A, Stevenson S, Wu L, McAllister P, Lee YP, et al. The effect of regional gene therapy with bone morphogenetic protein-2-producing bone-marrow cells on the repair of segmental femoral defects in rats. *J Bone Joint Surg Am* 1999;81(7):905–17.
- [20] Xu XL, Tang T, Dai K, Zhu Z, Guo XE, Yu C, et al. Immune response and effect of adenovirus-mediated human BMP-2 gene transfer on the repair of segmental tibial bone defects in goats. *Acta Orthop* 2005;76(5):637–46.
- [21] Einhorn TA, Lane JM, Burstein AH, Kopman CR, Vigorita VJ. The healing of segmental bone defects induced by demineralized bone matrix. A radiographic and biomechanical study. *J Bone Joint Surg Am* 1984;66(2):274–9.
- [22] Chu TM, Flanagan CL, Hollister S, Feinberg SE, Fisher JP, Mikos AG. The mechanical and in vivo performance of 3-D poly(propylene fumarate)/tricalcium phosphate scaffolds. In: *Biomaterials SF*, editor. 29th annual meeting of Society for Biomaterials. Reno, NV: Society for Biomaterials; 2003. p. 660.
- [23] Chu TM, Halloran JW, Hollister S, Feinberg SE. Hydroxyapatite implants with designed internal architecture. *J Mater Sci: Mater Med* 2001;12:471–8.
- [24] Chu TM, Orton DG, Hollister SJ, Feinberg SE, Halloran JW. Mechanical and in vivo performance of hydroxyapatite implants with controlled architectures. *Biomaterials* 2002;23(5):1283–93.
- [25] Ohura K, Hamanishi C, Tanaka S, Matsuda N. Healing of segmental bone defects in rats induced by a beta-TCP-MCPM cement combined with rhBMP-2. *J Biomed Mater Res* 1999;44(2):168–75.
- [26] Yasko AW, Lane JM, Fellingner EJ, Rosen V, Wozney JM, Wang EA. The healing of segmental bone defects, induced by recombinant human bone morphogenetic protein (rhBMP-2). A radiographic, histological, and biomechanical study in rats. *J Bone Joint Surg Am* 1992;74(5):659–70.
- [27] Wilson Jr PD. A clinical study of the biomechanical behavior of massive bone transplants used to reconstruct large bone defects. *Clin Orthop* 1972;87:81–109.
- [28] Chmell MJ, McAndrew MP, Thomas R, Schwartz HS. Structural allografts for reconstruction of lower extremity open fractures with 10 centimeters or more of acute segmental defects. *J Orthop Trauma* 1995;9(3):222–6.
- [29] Tiyyapatanaputi P, Rubery PT, Carmouche J, Schwarz EM, O'Keefe RJ, Zhang X. A novel murine segmental femoral graft model. *J Orthop Res* 2004;22(6):1254–60.
- [30] Chu TG, Sargent PW, Warden SJ, Turner CH, Stewart RL. Preliminary evaluation of a load-bearing BMP-2 carrier for segmental defect regeneration. *Biomed Sci Instrum* 2006;42:42–6.
- [31] Peter SJ, Miller ST, Zhu G, Yasko AW, Mikos AG. In vivo degradation of a poly(propylene fumarate)/beta-tricalcium phosphate injectable composite scaffold. *J Biomed Mater Res* 1998; 41(1):1–7.
- [32] Hyun SJ, Han DK, Choi SH, Chai JK, Cho KS, Kim CK, et al. Effect of recombinant human bone morphogenetic protein-2, -4, and -7 on bone formation in rat calvarial defects. *J Periodontol* 2005;76(10):1667–74.

Muscle-bone interactions during fracture healing

K.M. Davis^{1*}, K.S. Griffin^{1*}, T-M.G. Chu², J.C. Wenke³, B.T. Corona³, T.O. McKinley¹, M.A. Kacena¹

¹Department of Orthopaedic Surgery, Indiana University School of Medicine, Indianapolis, IN;

²Department of Restorative Dentistry, Indiana University School of Dentistry, Indianapolis, IN;

³Extremity Trauma & Regenerative Medicine Task Area, United States Army Institute of Surgical Research, San Antonio, TX

*contributed equally to this work

Abstract

Although it is generally accepted that the rate and strength of fracture healing is intimately linked to the integrity of surrounding soft tissues, the contribution of muscle has largely been viewed as a vascular supply for oxygen and nutrient exchange. However, more is becoming known about the cellular and paracrine contributions of muscle to the fracture healing process. Research has shown that muscle is capable of supplying osteoprogenitor cells in cases where the periosteum is insufficient, and the muscular osteoprogenitors possess similar osteogenic potential to those derived from the periosteum. Muscle's secretome includes proteins capable of inhibiting or enhancing osteogenesis and myogenesis following musculoskeletal injury and can be garnered for therapeutic use in patients with traumatic musculoskeletal injuries. In this review, we will highlight the current knowledge on muscle-bone interaction in the context of fracture healing as well as concisely present the current models to study such interactions.

Keywords: Muscle, Bone, Fracture, Mesenchymal Stem Cells, Paracrine

Introduction

In the orthopaedic field, the muscle-bone relationship is of utmost importance as surgeons must often battle increased complications, morbidity, and delayed fracture healing in cases with extensive soft tissue damage resulting from high energy trauma. The Gustilo-Anderson open fracture classification scale, which has been commonly used for nearly 4 decades, classifies severity almost solely on soft tissue (primarily muscle) injury, and the complication rate is much higher in fractures with soft tissue damage¹. Although it has long been accepted that intact surrounding soft tissues are important in the fracture healing process, the underlying mechanisms have not been fully elucidated. However, basic science and translational research have made advances in the understanding of how muscle injuries impede fracture healing.

To understand muscle's potential role in fracture repair, a comprehension of the repair process is necessary. In brief, fracture repair consists of three chronological and overlapping phases: a reactive phase, a reparative phase, and a remodeling phase. The reactive phase peaks within the first 24-48 hours and lasts less than 1 week. During this phase, endothelial damage to the vasculature causes a hematoma, drawing in inflammatory cells (lymphocytes, polymorphonuclear cells, monocytes) and fibroblasts to form granulation tissue². The granulation tissue is important for vascular ingrowth as well as the recruitment of mesenchymal stem cells (MSCs). The inflammatory cells release cytokines such as TNF- α , IL-1, IL-6, IL-11, and IL-18 to induce osteogenic differentiation of MSCs as well as promote angiogenesis³. The reparative phase begins within a few days after fracture and lasts several weeks. Pluripotent mesenchymal cells, dependent on local strain and oxygen tension, differentiate into fibroblasts, chondroblasts, or osteoblasts. Healing can occur through intramembranous ossification alone (direct healing) or a combination of intramembranous and endochondral ossification (indirect healing), depending on the degree of mechanical stability⁴. In endochondral ossification, a fibrocartilage callus forms and is subsequently replaced by a bony callus with woven bone deposition. In intramembranous ossification, lamellar bone regeneration occurs without the need for remodeling, but it requires stable fixation². Thus, the ossification process is dependent on

The authors have no conflict of interest.

Corresponding author: Melissa Kacena, Ph.D., August M. Watanabe Translational Scholar, Showalter Scholar, Associate Professor of Orthopaedic Surgery, Indiana University School of Medicine, 1120 South Drive FH 115, Indianapolis, IN 46202, United States
E-mail: mkacena@iupui.edu

Edited by: M. Hamrick
Accepted 8 December 2014

the stability of the fracture site. During the remodeling phase, the woven bone is replaced with lamellar bone, and the bone is gradually remodeled under mechanical stress to its original contour. This phase can last for several years^{2,5}.

Vascularization and fracture healing

The importance of vascularization in osteogenesis cannot be overemphasized, as a nearby vascular supply is required for both normal development and bone regeneration⁶⁻⁹. Indeed, an early step in the fracture healing process is the formation of granulation tissue consisting of connective tissue and small blood vessels^{10,11}, reinforcing the importance of vascularization in healing. Surrounding soft tissues at the fracture site primarily have been considered an important vascular source¹² to deliver oxygen¹³, nutrients¹³, and potential osteoprogenitor cells to the injured area^{14,15}. In the surrounding soft tissue are MSCs and pericytes, which are crucial for angiogenesis in the wounded tissue^{16,17}. In the clinical arena, the rate of non-union is 4 times higher in cases with reduced vascular function¹⁸, and in animal fracture models that disrupt angiogenesis, bone formation is hindered through the suppression of osteoblast proliferation¹⁸⁻²⁰. Muscle flap coverage has been shown to increase bone blood flow and the rate of osteotomy union compared to skin tissue coverage, supporting the vascular role of muscle in bone regeneration²¹⁻²³.

Although vascularization has been shown to be critical for regeneration, there has been evidence of nearly equal vascularization in healed bone and non-unions in animal studies as well as in human patients^{20,24-26}. In a murine open tibial fracture model, Harry et al. observed faster fracture healing in musculocutaneous compared to fasciocutaneous flaps, despite the musculocutaneous flaps having decreased vascularization²⁷. These studies point to a more extensive role of muscle in the repair process than solely as a vascular supply.

Osteoprogenitors derived from muscle

The relationship between muscle and bone has been observed for decades and continues to be elucidated. Urist first deduced muscle's ability to induce bone formation in 1965 when decalcified bone implanted into muscle resulted in new bone formation^{28,29}. In fracture healing studies in multiple species, callus formation tends to be the largest and most dense at the interface between bone and muscle³⁰, suggesting that muscle contributes to callus formation or provides a suitable environment for its occurrence.

Muscle is also a common site for ectopic bone formation following physical trauma³¹, orthopaedic surgery³², or due to disease like fibrodysplasia ossificans progressiva, which has been identified to be a result of a mutation in a gene encoding a bone morphogenetic protein (BMP) receptor³³. BMPs, a group of growth factors involved in tissue architecture throughout the body, are of particular importance to bone formation as they induce osteoblast differentiation.

In the presence of BMPs, cells derived from muscle are ca-

pable of differentiating into cells expressing bone markers³⁴⁻³⁷. That muscle-derived cells capable of displaying osteogenic potential under proper conditions could partly explain the importance of muscle in fracture healing aside from their role in vascularization. In addition, muscle may be able to influence bone in a manner unlike any other tissue. When both muscle and fat are activated by exposure to a BMP-2 encoded adenovirus, the "gene-activated" muscle results in more consistent bone regeneration than the "gene-activated" fat³⁸. Furthermore, when muscle-derived stem cells (MDSCs) are recruited and driven to osteogenic differentiation by BMPs, they display an osteogenic potential that is equivalent to those derived from bone marrow³⁹. Lineage-traced MDSCs in a fracture healing model have been found to alter gene expression to give rise to chondrocytes, up-regulating chondrogenic markers Sox9 and Nkx3.2 and down-regulating the muscle marker Pax3³⁶. These studies provide evidence that, in the appropriate environmental conditions, muscle can supply osteoprogenitor cells required for the fracture repair process.

It should be noted, however, that MDSCs are not the sole osteoprogenitor cells derived from muscle. C2C12 myoblasts infected with a retroviral vector have been found to overexpress osteoactivin (OA) and transdifferentiate into osteoblasts and express bone-specific markers⁴⁰. Muscle-derived stromal cells, when administered TNF- α at low concentrations, are also capable of undergoing recruitment and osteogenic differentiation⁴¹. Muscle satellite cells were originally believed to be muscle stem cells restricted to the myogenic lineage⁴², but the osteogenic potential of these cells has been observed under several conditions. Satellite cell-derived myoblasts have been shown to differentiate into osteocytes following treatment with BMPs⁴³, into osteoblasts *in vivo* and *in vitro* in the presence of platelet-rich plasma⁴⁴, and the osteogenic potential of satellite cells can increase in response to cutaneous burn trauma⁴⁵. Satellite cells have been observed to express both myoblastic (Pax7, MyoD) and osteoblastic (alkaline phosphatase, Runx2) markers and are capable of differentiating into osteoblasts spontaneously⁴⁶.

The abundance of potential osteogenic cells derived from muscle could have applications in the future in tissue engineering techniques, particularly in cases where the bone marrow or periosteum is compromised. It has been commonly believed that in fractures in which the periosteum is intact, repair occurs largely through endochondral ossification driven by a periosteal supply of cells^{10,47-50}. Indeed, in open fractures with a stripped periosteum, Liu et al. found that myogenic cells of the MyoD-lineage contributed to fracture repair, but MyoD-expressing cells were not incorporated into the callus in the case of a closed fracture with intact periosteum⁵¹. Such a study demonstrates that myogenic cells can be activated to serve as a secondary supply of cells when the periosteal supply becomes compromised^{52,53}. These recent findings of muscle's ability to augment the periosteal supply of osteoprogenitor cells provide insight into the clinical observations of prolonged recovery time and increased morbidity that is especially seen associated with high energy fractures with substantial soft tissue damage.

Muscle-bone paracrine interactions in bone repair

Only within the past two decades has the muscle secretome been identified and explored. With the recent advent of improved characterization instruments, the muscle secretome has rapidly expanded to over 200 proteins⁵⁴. Muscle secreted proteins important in muscle-bone interactions include, but are not limited to: myostatin, BMPs, secreted protein acidic and rich in cysteine (SPARC or osteonectin), interleukin (IL)-1, IL-4, IL-6, tumor necrosis factor (TNF) α , and insulin-like growth factor (IGF)-1^{41,54-56}. Many of the muscle derived factors have previously been described to play a role in muscle-bone interactions without addressing the interactions specifically during fracture repair. Importantly, the presence of inflammation differentiates fracture repair from bone formation during development. That is, fracture healing is initiated by an inflammatory cascade, which is mediated by a number of factors, including but not limited to: neutrophils, macrophages, lymphocytes, and various inflammatory cytokines (i.e., IL-1, IL-6, TNF α)^{2,57-59}. Mounting and maintaining an appropriate inflammatory response in early fracture healing is critical for adequate repair and multiple studies have demonstrated that interference with the inflammatory process can either impair^{60,61} or improve⁶² fracture healing. This review focuses primarily on four factors known to be involved in muscular injury and fracture repair and are therefore likely to contribute to muscle-bone interactions in the presence of inflammation.

Insulin-like growth factor-1

IGF-1 is recognized as a key myokine that may direct local fracture healing⁶³. IGF-1 is expressed by maturing osteoblasts in culture⁶⁴ and expression has been localized using *in situ* hybridization to osteoblasts during phases of matrix formation and remodeling in fractured human bone⁶⁵. Further signifying the importance of IGF-1 to fracture healing, delivery of IGF-1 to ovine bone defects promotes accelerated bone formation^{66,67}. The association of low systemic levels of IGF-1 with osteoporosis^{68,69} suggests that local production of IGF-1 by nearby skeletal muscle tissue may support bone healing. Given that skeletal muscle up-regulates expression of IGF-1 in response to injury⁷⁰⁻⁷², the context of fractures involving muscle trauma specifically highlight this possibility. Overexpression of IGF-1 in skeletal muscle can result in increased systemic concentrations evidencing the capacity of skeletal muscle as a paracrine organ to support nearby bone healing⁷³. IGF-1 plays a role in muscle fiber repair and regenerative processes via a number of mechanisms to include increasing protein synthesis via PI3-AKT-mTOR pathway and by activating and promoting proliferation of satellite cells^{74,75}. Perhaps most interesting in the context of complex musculoskeletal injury is the anti-inflammatory (i.e., inhibition of NF- κ B) role of IGF-1 in muscle^{76,77} and bone⁶⁷.

Myostatin

Perhaps the most well-known muscle derived protein, myostatin, has been implicated to play a significant, albeit inhibitory, role in fracture repair. Myostatin is a member of the TGF- β superfamily, negatively regulating muscle growth, development, and regeneration^{78,79}. Its negative trophic influence has been supported in myostatin null mice that demonstrate increased bone strength and increased bone mineral density⁸⁰⁻⁸². Furthermore, myostatin inhibition by decoy receptors increases musculoskeletal mass⁸³. Interestingly however, expression of myostatin is elevated with significant musculoskeletal injury, specifically in the early part of bone repair^{84,85}. Due to its negative role in musculoskeletal development, interventions were targeted toward inhibiting myostatin after skeletal injury. Small molecule inhibition of myostatin following orthopaedic trauma has been demonstrated to improve muscle regeneration and fracture healing^{79,85,86}. These data suggest that inhibition of myostatin may be a plausible intervention to improve fracture healing outcomes in patients with significant musculoskeletal injuries. However, the conundrum of elevated myostatin after musculoskeletal injury remains poorly understood.

Bone morphogenetic proteins

Generally speaking, BMPs are growth factors for various skeletal tissues and are required for skeletal development. Conditional knockout mice deficient in BMPs displayed a wide range of skeletal defects^{87,88}. There are 7 members of the BMP family, of which BMPs 2-7 belong to the TGF β superfamily⁸⁹. Multiple BMPs have been demonstrated to promote osteoblastic differentiation of bone marrow stromal cells^{90,91}. Specifically, BMP-2 and BMP-7 are FDA approved for use in clinical musculoskeletal therapeutics due to their role in osteoblast differentiation and musculoskeletal repair. Unfortunately, concerns have arisen regarding the multiple side effects and off-label usage of BMPs including a recent link to oncogenic side effects with use of BMP-2^{92,93}. More novel approaches to utilization of BMP-2 in fracture healing includes modified muscle cells that secrete BMP-2. Critical size rat femoral defects underwent quicker bridging and restored mechanical strength when receiving activated muscle secreted BMP-2³⁸. Though not a member of the TGF β superfamily and not used in the clinical setting currently, BMP-1 is secreted by muscle and may play a role in fracture healing. BMP-1, specifically, is a protease secreted by muscle that cleaves procollagen⁹⁴. In patients with traumatic blast injuries, both BMP-1 protein and mRNA levels were elevated⁹⁵, suggesting a significant role for BMP-1 in musculoskeletal repair. Therefore, better understanding of the roles of muscle derived BMPs in skeletal tissue regeneration is warranted to improve musculoskeletal repair in patients who suffer extensive traumatic injuries.

SPARC or osteonectin

Osteonectin is a phosphorylated glycoprotein present in developing bone in many animal species⁹⁶. Osteonectin is suggested to serve multiple functions in the developing bone

matrix, including collagen organization, osteoblast growth and proliferation, and matrix mineralization⁹⁷. Mice deficient in osteonectin display osteopenia and decreased bone mineral content⁹⁸. Importantly, osteonectin is secreted by injured and regenerating myotubes and muscle fibers⁹⁹. Osteonectin expression by these sources is dependent on injury severity, suggesting that more severe musculoskeletal injuries result in greater osteonectin expression⁹⁹. Longitudinal studies of fracture healing show detectable osteonectin transcripts throughout the healing phase^{100,101}, most notably from days 9 to 15¹⁰². These studies provide evidence for the significant role osteonectin plays in bone regeneration and suggest muscle may be a source of osteonectin during musculoskeletal repair.

Mechanical muscle-bone interactions

It would be remiss to forego some discussion of the mechanical influences involved in muscle bone interactions. The cellular mechanisms by which mechanical strain affects bone are largely uncharacterized, but some data suggest it is due in part to gap junctions in bone formed by connexin43^{103,104}. Though characterization of mechanically induced cellular mechanisms remains limited, multiple studies have pointed to the importance of muscle's mechanical interactions on bone health¹⁰⁵. Disuse atrophy via denervation or immobilization has been shown to decrease bone integrity in animal models¹⁰⁶⁻¹⁰⁸. Furthermore, multiple studies have demonstrated that muscle paralysis induced by administration of botulinum toxin impairs bone quality and/or fracture healing¹⁰⁹⁻¹¹³. Further research into the cellular mechanisms of the mechanical influence of muscle is warranted to better understand how bone can be further modified by muscle during the healing process.

Muscle in fracture healing - current models

Murine

Multiple murine studies have been conducted to examine the extent to which muscle enhances bone repair after significant musculoskeletal injury. Zacks and Sheff¹¹⁴ conducted early sentinel research addressing the potential for muscle to contribute to bone regeneration in 1982. Zacks and Sheff utilized experimental groups where after limb muscle resection, isotopic or heterotopic minced muscle implants were placed immediately adjacent to the periosteum. Their control groups consisted of liver minced implant or no implant. They concluded that isotopic and heterotopic minced muscle preparations implanted adjacent to the periosteum could directly induce new bone formation *in situ* as demonstrated by the formation of exostoses and metaplastic nodules in the minced muscle implants¹¹⁴. The work of Zacks and Sheff confirmed the importance of studying the trophic influence of muscle on bone.

As previously mentioned, Harry et al. conducted a murine study addressing the importance of muscle in open tibial fracture repair²⁷. The authors demonstrated that musculocutaneous flaps performed superior to the fasciocutaneous flaps, though the fasciocutaneous flaps provided more angiogenic capacity. There-

fore, the osteogenic capability of muscle is greater than that of cutaneous flaps and extends beyond simply angiogenesis.

Rattus

Multiple studies have also been conducted utilizing rat models to assess bone healing in light of soft tissue injuries. A study by Hao et al.¹⁰⁹ evaluated the effect of muscle atrophy and paralysis on femoral fracture healing. Atrophy of the quadriceps muscle, induced by administration of botulinum A toxin, negatively impacted the healing capacity of femoral fractures in rats. Utvag et al. conducted three critical studies¹¹⁵⁻¹¹⁷ assessing the role of periosteum or surrounding soft tissue in bone healing. In 1998 Utvag et al.¹¹⁵ demonstrated that fracture healing was impaired when periosteal tissue was mechanically removed from interacting with surrounding muscle. Additionally, Utvag et al. showed that significant muscle injury and absence of muscle by resection, or by traumatic injury in the clinical setting, significantly compromised the regeneration potential of non-augmented healing bone^{116,117}. The importance of muscle for bone healing was further confirmed by the work of Willett et al. that demonstrated that volumetric muscle loss (VML) also impairs the effectiveness of BMP-2 in the healing of a critical size bone defect¹¹⁸. Taken together, it is clear that frank loss of muscle tissue (VML) is a significant comorbidity to poor bone healing outcomes.

Humans

Since the mid 1970s, open fractures have been graded clinically according to the Gustilo-Anderson classification scale^{1,119}, which is largely based on the severity of soft tissue injury associated with open fractures. Gustilo and Anderson identified 3 types of fractures: Type I - open fracture with a wound <1 cm and clean; Type 2 - open fracture with a wound >1 cm without extensive soft tissue damage; and Type 3 - open fracture with extensive soft tissue damage¹¹⁹. Type 3 fractures were later subdivided into 3 subcategories¹. The Gustilo Anderson classification makes it evident that soft tissue injury plays a significant role in the musculoskeletal repair process in the clinical setting. Specifically, open fractures (Type 3) with extensive soft tissue injury demonstrate greater complication rates than open fractures without soft tissue injury (Types 2 & 3)^{120,121}.

Similar to the results observed from animal studies, substantial clinical data exist characterizing the importance of muscle integrity in bone repair. A multitude of studies have demonstrated soft tissue damage associated with fractures impairs the ability of bone to repair properly^{122,123}, while the quality of the muscle bed is essential for appropriate bone formation and bone healing^{30,51}.

Similar to the murine study conducted by Harry et al.²⁷, Gopal et al.¹²⁴ specifically examined the treatment of open tibial fractures with fasciocutaneous flaps versus muscle flaps in humans. The results of their study were then later confirmed by Harry et al. in the mouse model, with both groups concluding that muscle flaps are superior in bone healing. Even in clinical

practice, the gold standard of treating critical size defects or extensive fractures includes soft tissue coverage, supporting the significance of muscle-bone interactions during bone healing.

A more recent meta-analysis by Reverte et al.¹²⁵ analyzed 16 studies addressing the union rate and time to fracture union in patients with tibial fractures and associated compartment syndromes. Reverte et al. demonstrated that tibial fractures with associated soft tissue injury significantly impaired fracture healing. The rate of delayed union or non-union in tibial fractures with associated compartment syndrome was 55% compared to only 18% in patients with tibial fracture without associated compartment syndrome¹²⁵. This study points to the importance of soft tissue integrity in the quality of fracture healing.

Conclusion

Taken together, these studies illustrate the importance of muscle-bone interactions in bone regeneration. Exact mechanisms by which muscle is responsible for bone formation in the healing process are not well elucidated. Most of the current literature is limited to qualitative findings of muscle's role in bone healing. Therefore, more rigorous models with aims directed toward identification and quantification of muscle-derived effectors of bone regeneration are required. Identifying and characterizing the muscle-derived factors responsible for bone healing may provide opportunities to develop therapies to augment normal physiologic mechanisms underlying bone regeneration.

Current strategies, such as the use of BMPs, in fracture healing have recently been thought of as having more limited benefit due to the more robust understanding of detrimental side effects. This review outlines some potential targets for therapeutic development, including stimulation of MDSCs, inhibition of myostatin, or administering or enhancing the targeted expression of osteonectin. Future studies addressing muscle factors associated with bone healing may provide insight into these mechanisms necessary to promote bone regeneration. Soft tissue integrity is crucial to appropriate bone regeneration, but our understanding of the mechanisms is limited at the present time. A better understanding of muscle's effect on fracture healing at the cellular and molecular levels will open translational opportunities to incorporate the findings into clinics and operating rooms abroad.

Acknowledgements

This work was supported by the Medical Student Affairs Summer Research Program in Academic Medicine, Indiana University School of Medicine funded in part by NIH grant HL110854 (KMD) and the Department of Orthopaedic Surgery, Indiana University School of Medicine (MAK, TOM). In addition, research reported in this publication was supported in part by the following grants: NIH NIAMS R01 AR060863 (MAK), USAMRMC OR120080 (MAK, T-MGC), an Indiana University Health Values Grant (MAK), an Indiana Clinical and Translational Sciences Institute Grant partially supported by NIH UL1TR001108 (MAK, T-MGC), and an Indiana University Collaborative Research Grant (MAK, T-MGC). The content of this manuscript is solely the responsibility of the authors and does not necessarily represent the official views of the NIH.

The opinions or assertions contained herein are the private views of the authors and are not to be construed as official or as reflecting the views of the Department of the Army or the Department of Defense.

References

1. Gustilo RB, Mendoza RM, Williams DN. Problems in the management of type III (severe) open fractures: a new classification of type III open fractures. *J Trauma* 1984;24:742-6.
2. Marsell R, Einhorn TA. The biology of fracture healing. *Injury* 2011;42:551-5.
3. Gerstenfeld LC, Cullinane DM, Barnes GL, Graves DT, Einhorn TA. Fracture healing as a post-natal developmental process: molecular, spatial, and temporal aspects of its regulation. *J Cell Biochem* 2003;88:873-84.
4. Gerstenfeld LC, Alkhiary YM, Krall EA, et al. Three-dimensional reconstruction of fracture callus morphogenesis. *J Histochem Cytochem* 2006;54:1215-28.
5. Claes L, Recknagel S, Ignatius A. Fracture healing under healthy and inflammatory conditions. *Nat Rev Rheumatol* 2012;8:133-43.
6. Schipani E, Maes C, Carmeliet G, Semenza GL. Regulation of osteogenesis-angiogenesis coupling by HIFs and VEGF. *J Bone Miner Res* 2009;24:1347-53.
7. Glowacki J. Angiogenesis in fracture repair. *Clin Orthop Relat Res* 1998:S82-9.
8. Zelzer E, Olsen BR. Multiple roles of vascular endothelial growth factor (VEGF) in skeletal development, growth, and repair. *Curr Top Dev Biol* 2005;65:169-87.
9. Kristensen HB, Andersen TL, Marcussen N, Rolighed L, Delaisse JM. Increased presence of capillaries next to remodeling sites in adult human cancellous bone. *J Bone Miner Res* 2013;28:574-85.
10. Colnot C, Zhang X, Knothe Tate ML. Current insights on the regenerative potential of the periosteum: molecular, cellular, and endogenous engineering approaches. *J Orthop Res* 2012;30:1869-78.
11. Zuscik MJ, Hilton MJ, Zhang X, Chen D, O'Keefe RJ. Regulation of chondrogenesis and chondrocyte differentiation by stress. *J Clin Invest* 2008;118:429-38.
12. Rhinelander FW. Tibial blood supply in relation to fracture healing. *Clin Orthop Relat Res* 1974:34-81.
13. Laroche M. Intraosseous circulation from physiology to disease. *Joint Bone Spine* 2002;69:262-9.
14. Brighton CT, Lorch DG, Kupcha R, Reilly TM, Jones AR, Woodbury RA, 2nd. The pericyte as a possible osteoblast progenitor cell. *Clin Orthop Relat Res* 1992:287-99.
15. Diaz-Flores L, Gutierrez R, Lopez-Alonso A, Gonzalez R, Varela H. Pericytes as a supplementary source of osteoblasts in periosteal osteogenesis. *Clin Orthop Relat Res* 1992;(275):280-6.
16. Mills SJ, Cowin AJ, Kaur P. Pericytes, mesenchymal stem cells and the wound healing process. *Cells* 2013;2:621-34.
17. Kumar A, Salimath BP, Stark GB, Finkenzeller G.

- Platelet-derived growth factor receptor signaling is not involved in osteogenic differentiation of human mesenchymal stem cells. *Tissue Eng Part A* 2010;16:983-93.
18. Lu C, Miclau T, Hu D, Marcucio RS. Ischemia leads to delayed union during fracture healing: a mouse model. *J Orthop Res* 2007;25:51-61.
 19. Green N, French S, Rodriquez G, Hays M, Fingerhut A. Radiation-induced delayed union of fractures. *Radiology* 1969;93:635-41.
 20. Liu R, Schindeler A, Little DG. The potential role of muscle in bone repair. *J Musculoskelet Neuronal Interact* 2010;10:71-6.
 21. Richards RR, Schemitsch EH. Effect of muscle flap coverage on bone blood flow following devascularization of a segment of tibia: an experimental investigation in the dog. *J Orthop Res* 1989;7:550-8.
 22. Richards RR, McKee MD, Paitich CB, Anderson GI, Bertoia JT. A comparison of the effects of skin coverage and muscle flap coverage on the early strength of union at the site of osteotomy after devascularization of a segment of canine tibia. *J Bone Joint Surg Am* 1991;73:1323-30.
 23. Richards RR, Orsini EC, Mahoney JL, Verschuren R. The influence of muscle flap coverage on the repair of devascularized tibial cortex: an experimental investigation in the dog. *Plast Reconstr Surg* 1987;79:946-58.
 24. Choi P, Ogilvie C, Thompson Z, Miclau T, Helms JA. Cellular and molecular characterization of a murine non-union model. *J Orthop Res* 2004;22:1100-7.
 25. Brownlow HC, Reed A, Simpson AH. The vascularity of atrophic non-unions. *Injury* 2002;33:145-50.
 26. Reed AA, Joyner CJ, Brownlow HC, Simpson AH. Human atrophic fracture non-unions are not avascular. *J Orthop Res* 2002;20:593-9.
 27. Harry LE, Sandison A, Paleolog EM, Hansen U, Pearse MF, Nanchahal J. Comparison of the healing of open tibial fractures covered with either muscle or fasciocutaneous tissue in a murine model. *J Orthop Res* 2008;26:1238-44.
 28. Urist MR. Bone: formation by autoinduction. *Science* 1965;150:893-9.
 29. Chan JK, Harry L, Williams G, Nanchahal J. Soft-tissue reconstruction of open fractures of the lower limb: muscle versus fasciocutaneous flaps. *Plast Reconstr Surg* 2012;130:284e-95e.
 30. Stein H, Perren SM, Cordey J, Kenwright J, Mosheiff R, Francis MJ. The muscle bed--a crucial factor for fracture healing: a physiological concept. *Orthopedics* 2002;25:1379-83.
 31. Davis TA, Lazdun Y, Potter BK, Forsberg JA. Ectopic bone formation in severely combat-injured orthopedic patients - a hematopoietic niche. *Bone* 2013;56:119-26.
 32. DeLee J, Ferrari A, Charnley J. Ectopic bone formation following low friction arthroplasty of the hip. *Clin Orthop Relat Res* 1976;(121):53-9.
 33. Kaplan FS, Lounev VY, Wang H, Pignolo RJ, Shore EM. Fibrodysplasia ossificans progressiva: a blueprint for metamorphosis. *Ann N Y Acad Sci* 2011;1237:5-10.
 34. Kato S, Sangadala S, Tomita K, Titus L, Boden SD. A synthetic compound that potentiates bone morphogenetic protein-2-induced transdifferentiation of myoblasts into the osteoblastic phenotype. *Mol Cell Biochem* 2011;349:97-106.
 35. Wong E, Sangadala S, Boden SD, et al. A novel low-molecular-weight compound enhances ectopic bone formation and fracture repair. *J Bone Joint Surg Am* 2013;95:454-61.
 36. Cairns DM, Liu R, Sen M, et al. Interplay of Nkx3.2, Sox9 and Pax3 regulates chondrogenic differentiation of muscle progenitor cells. *PLoS One* 2012;7:e39642.
 37. Lee JY, Qu-Petersen Z, Cao B, et al. Clonal isolation of muscle-derived cells capable of enhancing muscle regeneration and bone healing. *J Cell Biol* 2000;150:1085-100.
 38. Evans CH, Liu FJ, Glatt V, et al. Use of genetically modified muscle and fat grafts to repair defects in bone and cartilage. *Eur Cell Mater* 2009;18:96-111.
 39. Gao X, Usas A, Tang Y, et al. A comparison of bone regeneration with human mesenchymal stem cells and muscle-derived stem cells and the critical role of BMP. *Biomaterials* 2014;35:6859-70.
 40. Sondag GR, Salihoglu S, Lababidi SL, et al. Osteoactivin induces transdifferentiation of C2C12 myoblasts into osteoblasts. *J Cell Physiol* 2014;229:955-66.
 41. Glass GE, Chan JK, Freidin A, Feldmann M, Horwood NJ, Nanchahal J. TNF-alpha promotes fracture repair by augmenting the recruitment and differentiation of muscle-derived stromal cells. *Proc Natl Acad Sci U S A* 2011;108:1585-90.
 42. Jankowski RJ, Deasy BM, Huard J. Muscle-derived stem cells. *Gene Ther* 2002;9:642-7.
 43. Asakura A, Komaki M, Rudnicki M. Muscle satellite cells are multipotential stem cells that exhibit myogenic, osteogenic, and adipogenic differentiation. *Differentiation* 2001;68:245-53.
 44. Huang S, Jia S, Liu G, Fang D, Zhang D. Osteogenic differentiation of muscle satellite cells induced by platelet-rich plasma encapsulated in three-dimensional alginate scaffold. *Oral Surg Oral Med Oral Pathol Oral Radiol* 2012;114:S32-40.
 45. Wu X, Rathbone CR. Satellite cell functional alterations following cutaneous burn in rats include an increase in their osteogenic potential. *J Surg Res* 2013;184:e9-16.
 46. Hashimoto N, Kiyono T, Wada MR, et al. Osteogenic properties of human myogenic progenitor cells. *Mech Dev* 2008;125:257-69.
 47. Malizos KN, Papatheodorou LK. The healing potential of the periosteum molecular aspects. *Injury* 2005;36 Suppl 3:S13-9.
 48. Dwek JR. The periosteum: what is it, where is it, and what mimics it in its absence? *Skeletal Radiol* 2010;39:319-23.
 49. Zhang X, Xie C, Lin AS, et al. Periosteal progenitor cell fate in segmental cortical bone graft transplantations: im-

- plications for functional tissue engineering. *J Bone Miner Res* 2005;20:2124-37.
50. Hutmacher DW, Sittlinger M. Periosteal cells in bone tissue engineering. *Tissue Eng* 2003;9 Suppl 1:S45-64.
 51. Liu R, Birke O, Morse A, et al. Myogenic progenitors contribute to open but not closed fracture repair. *BMC Musculoskelet Disord* 2011;12:288.
 52. Kaufman H, Reznick A, Stein H, Barak M, Maor G. The biological basis of the bone-muscle inter-relationship in the algorithm of fracture healing. *Orthopedics* 2008;31:751.
 53. Utvag SE, Grundnes O, Reikeras O. Early muscle-periosteal lesion inhibits fracture healing in rats. *Acta Orthop Scand* 1999;70:62-6.
 54. Bortoluzzi S, Scannapieco P, Cestaro A, Danieli GA, Schiaffino S. Computational reconstruction of the human skeletal muscle secretome. *Proteins* 2006;62:776-92.
 55. Norheim F, Raastad T, Thiede B, Rustan AC, Drevon CA, Haugen F. Proteomic identification of secreted proteins from human skeletal muscle cells and expression in response to strength training. *Am J Physiol Endocrinol Metab* 2011;301:E1013-21.
 56. Seale P, Bjork B, Yang W, et al. PRDM16 controls a brown fat/skeletal muscle switch. *Nature* 2008;454:961-7.
 57. Kon T, Cho TJ, Aizawa T, et al. Expression of osteoprotegerin, receptor activator of NF-kappaB ligand (osteoprotegerin ligand) and related proinflammatory cytokines during fracture healing. *J Bone Miner Res* 2001;16:1004-14.
 58. Ai-Aql ZS, Alagl AS, Graves DT, Gerstenfeld LC, Einhorn TA. Molecular mechanisms controlling bone formation during fracture healing and distraction osteogenesis. *J Dent Res* 2008;87:107-18.
 59. Mountziaris PM, Mikos AG. Modulation of the inflammatory response for enhanced bone tissue regeneration. *Tissue Eng Part B Rev* 2008;14:179-86.
 60. Park S, Silva M, Bahk W, McKellop H, Lieberman J. Effect of repeated irrigation and debridement on fracture healing in an animal model. *J Orthop Res* 2002;20:1197-204.
 61. Grundnes O, Reikeras O. The importance of the hematoma for fracture healing in rats. *Acta Orthop Scand* 1993;64:340-2.
 62. Glass GE, Chan JK, Freidin A, Feldmann M, Horwood NJ, Nanchahal J. TNF- α promotes fracture repair by augmenting the recruitment and differentiation of muscle-derived stromal cells. *Proceedings of the National Academy of Sciences* 2011;108:1585-90.
 63. Hamrick MW. A role for myokines in muscle-bone interactions. *Exerc Sport Sci Rev* 2011;39:43-7.
 64. Kalajzic I, Staal A, Yang WP, et al. Expression profile of osteoblast lineage at defined stages of differentiation. *J Biol Chem* 2005;280:24618-26.
 65. Andrew JG, Hoyland J, Freemont AJ, Marsh D. Insulin-like growth factor gene expression in human fracture callus. *Calcif Tissue Int* 1993;53:97-102.
 66. Luginbuehl V, Zoidis E, Meinel L, von Rechenberg B, Gander B, Merkle HP. Impact of IGF-I release kinetics on bone healing: a preliminary study in sheep. *Eur J Pharm Biopharm* 2013;85:99-106.
 67. Meinel L, Zoidis E, Zapf J, et al. Localized insulin-like growth factor I delivery to enhance new bone formation. *Bone* 2003;33:660-72.
 68. Ljunghall S, Johansson AG, Burman P, Kampe O, Lindh E, Karlsson FA. Low plasma levels of insulin-like growth factor 1 (IGF-1) in male patients with idiopathic osteoporosis. *J Intern Med* 1992;232:59-64.
 69. Liu JM, Zhao HY, Ning G, et al. IGF-1 as an early marker for low bone mass or osteoporosis in premenopausal and postmenopausal women. *J Bone Miner Metab* 2008;26:159-64.
 70. Hill M, Goldspink G. Expression and splicing of the insulin-like growth factor gene in rodent muscle is associated with muscle satellite (stem) cell activation following local tissue damage. *J Physiol* 2003;549:409-18.
 71. Marsh DR, Criswell DS, Hamilton MT, Booth FW. Association of insulin-like growth factor mRNA expressions with muscle regeneration in young, adult, and old rats. *Am J Physiol* 1997;273:R353-8.
 72. Hammers DW, Merritt EK, Matheny RW, Jr., et al. Functional deficits and insulin-like growth factor-I gene expression following tourniquet-induced injury of skeletal muscle in young and old rats. *J Appl Physiol* (1985) 2008;105:1274-81.
 73. Shavlakadze T, Winn N, Rosenthal N, Grounds MD. Reconciling data from transgenic mice that overexpress IGF-I specifically in skeletal muscle. *Growth Horm IGF Res* 2005;15:4-18.
 74. Machida S, Booth FW. Insulin-like growth factor 1 and muscle growth: implication for satellite cell proliferation. *Proc Nutr Soc* 2004;63:337-40.
 75. Han B, Tong J, Zhu MJ, Ma C, Du M. Insulin-like growth factor-1 (IGF-1) and leucine activate pig myogenic satellite cells through mammalian target of rapamycin (mTOR) pathway. *Mol Reprod Dev* 2008;75:810-7.
 76. Mourkioti F, Rosenthal N. IGF-1, inflammation and stem cells: interactions during muscle regeneration. *Trends Immunol* 2005;26:535-42.
 77. Lee WJ. IGF-I Exerts an Anti-inflammatory Effect on Skeletal Muscle Cells through Down-regulation of TLR4 Signaling. *Immune Netw* 2011;11:223-6.
 78. Elkasrawy M, Fulzele S, Bowser M, Wenger K, Hamrick M. Myostatin (GDF-8) inhibits chondrogenesis and chondrocyte proliferation *in vitro* by suppressing Sox-9 expression. *Growth Factors* 2011;29:253-62.
 79. Hamrick MW, Arounleut P, Kellum E, Cain M, Immel D, Liang LF. Recombinant myostatin (GDF-8) propeptide enhances the repair and regeneration of both muscle and bone in a model of deep penetrant musculoskeletal injury. *J Trauma* 2010;69:579-83.
 80. Hamrick MW, McPherron AC, Lovejoy CO, Hudson J. Femoral morphology and cross-sectional geometry of adult myostatin-deficient mice. *Bone* 2000;27:343-9.
 81. Hamrick MW, McPherron AC, Lovejoy CO. Bone min-

- eral content and density in the humerus of adult myostatin-deficient mice. *Calcif Tissue Int* 2002;71:63-8.
82. Hamrick MW. Increased bone mineral density in the femora of GDF8 knockout mice. *Anat Rec A Discov Mol Cell Evol Biol* 2003;272:388-91.
 83. Bialek P, Parkington J, Li X, et al. A myostatin and activin decoy receptor enhances bone formation in mice. *Bone* 2014;60:162-71.
 84. Elkasrawy M, Immel D, Wen X, Liu X, Liang LF, Hamrick MW. Immunolocalization of myostatin (GDF-8) following musculoskeletal injury and the effects of exogenous myostatin on muscle and bone healing. *J Histochem Cytochem* 2012;60:22-30.
 85. Elkasrawy MN, Hamrick MW. Myostatin (GDF-8) as a key factor linking muscle mass and bone structure. *J Musculoskelet Neuronal Interact* 2010;10:56-63.
 86. Kellum E, Starr H, Arounleut P, et al. Myostatin (GDF-8) deficiency increases fracture callus size, Sox-5 expression, and callus bone volume. *Bone* 2009;44:17-23.
 87. Gazzero E, Canalis E. Bone morphogenetic proteins and their antagonists. *Rev Endocr Metab Disord* 2006;7:51-65.
 88. Chen D, Zhao M, Mundy GR. Bone morphogenetic proteins. *Growth Factors* 2004;22:233-41.
 89. Wozney JM. Bone Morphogenetic Proteins. *Progress in Growth Factor Research* 1989;1:267-80.
 90. Yamaguchi A, Ishizuya T, Kintou N, et al. Effects of BMP-2, BMP-4, and BMP-6 on osteoblastic differentiation of bone marrow-derived stromal cell lines, ST2 and MC3T3-G2/PA6. *Biochem Biophys Res Commun* 1996;220:366-71.
 91. Lavery K, Swain P, Falb D, Alaoui-Ismaili MH. BMP-2/4 and BMP-6/7 differentially utilize cell surface receptors to induce osteoblastic differentiation of human bone marrow-derived mesenchymal stem cells. *J Biol Chem* 2008;283:20948-58.
 92. Carragee EJ, Hurwitz EL, Weiner BK. A critical review of recombinant human bone morphogenetic protein-2 trials in spinal surgery: emerging safety concerns and lessons learned. *Spine J* 2011;11:471-91.
 93. Carragee EJ, Chu G, Rohatgi R, et al. Cancer Risk After Use of Recombinant Bone Morphogenetic Protein-2 for Spinal Arthrodesis. *J Bone Joint Surg Am* 2013;95:1537-45.
 94. Kessler E, Takahara K, Biniaminov L, Brusel M, Greenspan DS. Bone morphogenetic protein-1: the type I procollagen C-proteinase. *Science* 1996;271:360-2.
 95. Jackson WM, Aragon AB, Onodera J, et al. Cytokine expression in muscle following traumatic injury. *J Orthop Res* 2011;29:1613-20.
 96. Villarreal XC, Mann KG, Long GL. Structure of human osteonectin based upon analysis of cDNA and genomic sequences. *Biochemistry* 1989;28:6483-91.
 97. Brekken RA, Sage EH. SPARC, a matricellular protein: at the crossroads of cell-matrix communication. *Matrix Biol* 2001;19:816-27.
 98. Delany AM, Amling M, Priemel M, Howe C, Baron R, Canalis E. Osteopenia and decreased bone formation in osteonectin-deficient mice. *J Clin Invest* 2000;105:1325.
 99. Jorgensen LH, Petersson SJ, Sellathurai J, et al. Secreted protein acidic and rich in cysteine (SPARC) in human skeletal muscle. *J Histochem Cytochem* 2009;57:29-39.
 100. Yamazaki M, Majeska R, Moriya J. Role of osteonectin during fracture healing. *Trans Orthop Res Soc* 1997;22:254.
 101. Hiltunen A, Metsaranta M, Virolainen P, Aro HT, Vuorio E. Retarded chondrogenesis in transgenic mice with a type II collagen defect results in fracture healing abnormalities. *Dev Dyn* 1994;200:340-9.
 102. Jingushi S, Joyce ME, Bolander ME. Genetic expression of extracellular matrix proteins correlates with histologic changes during fracture repair. *J Bone Miner Res* 1992;7:1045-55.
 103. Grimston SK, Goldberg DB, Watkins M, Brodt MD, Silva MJ, Civitelli R. Connexin43 deficiency reduces the sensitivity of cortical bone to the effects of muscle paralysis. *J Bone Miner Res* 2011;26:2151-60.
 104. Grimston SK, Brodt MD, Silva MJ, Civitelli R. Attenuated response to *in vivo* mechanical loading in mice with conditional osteoblast ablation of the connexin43 gene (*Gja1*). *J Bone Miner Res* 2008;23:879-86.
 105. Gross TS, Poliachik SL, Prasad J, Bain SD. The effect of muscle dysfunction on bone mass and morphology. *J Musculoskelet Neuronal Interact* 2010;10:25-34.
 106. Ijiri K, Ma YF, Jee WS, Akamine T, Liang X. Adaptation of non-growing former epiphysis and metaphyseal trabecular bones to aging and immobilization in rat. *Bone* 1995;17:207S-12S.
 107. Tuukkanen J, Wallmark B, Jalovaara P, Takala T, Sjogren S, Vaananen K. Changes induced in growing rat bone by immobilization and remobilization. *Bone* 1991;12:113-8.
 108. Liu D, Zhao CQ, Li H, Jiang SD, Jiang LS, Dai LY. Effects of spinal cord injury and hindlimb immobilization on sublesional and supralesional bones in young growing rats. *Bone* 2008;43:119-25.
 109. Hao Y, Ma Y, Wang X, Jin F, Ge S. Short-term muscle atrophy caused by botulinum toxin-A local injection impairs fracture healing in the rat femur. *J Orthop Res* 2012;30:574-80.
 110. Poliachik SL, Bain SD, Threet D, Huber P, Gross TS. Transient muscle paralysis disrupts bone homeostasis by rapid degradation of bone morphology. *Bone* 2010;46:18-23.
 111. Thomsen JS, Christensen LL, Vegger JB, Nyengaard JR, Bruel A. Loss of bone strength is dependent on skeletal site in disuse osteoporosis in rats. *Calcif Tissue Int* 2012;90:294-306.
 112. Ellman R, Grasso DJ, van Vliet M, et al. Combined effects of botulinum toxin injection and hind limb unloading on bone and muscle. *Calcif Tissue Int* 2014;94:327-37.
 113. Aliprantis AO, Stolina M, Kostenuik PJ, et al. Transient muscle paralysis degrades bone via rapid osteoclastogenesis. *FASEB J* 2012;26:1110-8.
 114. Zachs SI, Sheff MF. Periosteal and metaplastic bone for-

- mation in mouse minced muscle regeneration. *Lab Invest* 1982;46:405-12.
115. Utvag SE, Grundnes O, Reikeras O. Effects of lesion between bone, periosteum and muscle on fracture healing in rats. *Acta Orthop Scand* 1998;69:177-80.
 116. Utvag SE, Grundnes O, Rindal DB, Reikeras O. Influence of extensive muscle injury on fracture healing in rat tibia. *J Orthop Trauma* 2003;17:430-5.
 117. Utvag SE, Iversen KB, Grundnes O, Reikeras O. Poor muscle coverage delays fracture healing in rats. *Acta Orthop Scand* 2002;73:471-4.
 118. Willett NJ, Mon-Tzu LA, Uhrig BA, et al. Attenuated human bone morphogenetic protein-2-mediated bone regeneration in a rat model of composite bone and muscle injury. *Tissue Eng Pt C-Meth* 2013;19:316-25.
 119. Gustilo R, Anderson J. Prevention of infection in the treatment of one thousand and twenty-five open fractures of long bones: retrospective and prospective analyses. *J Bone Joint Surg Am* 1976;58:453-8.
 120. Papakostidis C, Kanakaris NK, Pretel J, Faour O, Morell DJ, Giannoudis PV. Prevalence of complications of open tibial shaft fractures stratified as per the Gustilo–Anderson classification. *Injury* 2011;42:1408-15.
 121. Giannoudis PV, Harwood PJ, Kontakis G, et al. Long-term quality of life in trauma patients following the full spectrum of tibial injury (fasciotomy, closed fracture, grade IIIB/IIIC open fracture and amputation). *Injury* 2009;40:213-9.
 122. Landry PS, Marino AA, Sadasivan KK, Albright JA. Effect of soft-tissue trauma on the early periosteal response of bone to injury. *J Trauma* 2000;48:479-83.
 123. Duda GN, Taylor WR, Winkler T, et al. Biomechanical, microvascular, and cellular factors promote muscle and bone regeneration. *Exerc Sport Sci Rev* 2008;36:64-70.
 124. Gopal S, Majumder S, Batchelor AG, Knight SL, De Boer P, Smith RM. Fix and flap: the radical orthopaedic and plastic treatment of severe open fractures of the tibia. *J Bone Joint Surg Br* 2000;82:959-66.
 125. Reverte MM, Dimitriou R, Kanakaris NK, Giannoudis PV. What is the effect of compartment syndrome and fasciotomies on fracture healing in tibial fractures? *Injury* 2011;42:1402-7.