

AWARD NUMBER: W81XWH-13-2-0087

TITLE: Optimization of Soft Tissue Management, Spacer Design, and Grafting Strategies for Large Segmental Bone Defects using the Chronic Caprine Tibial Defect Model

PRINCIPAL INVESTIGATORS:

Dr. Pluhar

CONTRACTING ORGANIZATION:  
Regents of the University of Minnesota  
Minneapolis, MN 55455

REPORT DATE: **October 2015**

TYPE OF REPORT: **Annual**

PREPARED FOR: U.S. Army Medical Research and Materiel Command  
Fort Detrick, Maryland 21702-5012

DISTRIBUTION STATEMENT: Approved for Public Release;  
Distribution Unlimited

The views, opinions and/or findings contained in this report are those of the author(s) and should not be construed as an official Department of the Army position, policy or decision unless so designated by other documentation.

<b>REPORT DOCUMENTATION PAGE</b>			<i>Form Approved</i> <i>OMB No. 0704-0188</i>		
Public reporting burden for this collection of information is estimated to average 1 hour per response, including the time for reviewing instructions, searching existing data sources, gathering and maintaining the data needed, and completing and reviewing this collection of information. Send comments regarding this burden estimate or any other aspect of this collection of information, including suggestions for reducing this burden to Department of Defense, Washington Headquarters Services, Directorate for Information Operations and Reports (0704-0188), 1215 Jefferson Davis Highway, Suite 1204, Arlington, VA 22202-4302. Respondents should be aware that notwithstanding any other provision of law, no person shall be subject to any penalty for failing to comply with a collection of information if it does not display a currently valid OMB control number. <b>PLEASE DO NOT RETURN YOUR FORM TO THE ABOVE ADDRESS.</b>					
<b>1. REPORT DATE</b> October 2015		<b>2. REPORT TYPE</b> Annual		<b>3. DATES COVERED</b> 30 Sep 2014- 29 Sep 2015	
<b>4. TITLE AND SUBTITLE</b> Optimization of Soft Tissue Management, Spacer Design, and Grafting Strategies for Large Segmental Bone Defects using the Chronic Caprine Tibial Defect Model			<b>5a. CONTRACT NUMBER</b>		
			<b>5b. GRANT NUMBER</b> W81XWH-13-2-0087		
			<b>5c. PROGRAM ELEMENT NUMBER</b>		
<b>6. AUTHOR(S)</b> Dr. G. Elizabeth Pluhar E-Mail(s): <a href="mailto:pluha006@umn.edu">pluha006@umn.edu</a>			<b>5d. PROJECT NUMBER</b>		
			<b>5e. TASK NUMBER</b>		
			<b>5f. WORK UNIT NUMBER</b>		
<b>7. PERFORMING ORGANIZATION NAME(S) AND ADDRESS(ES)</b>  University of Minnesota 200 Oak Street SE Minneapolis, MN. 55455-2009			<b>8. PERFORMING ORGANIZATION REPORT</b>		
<b>9. SPONSORING / MONITORING AGENCY NAME(S) AND ADDRESS(ES)</b> U.S. Army Medical Research and Materiel Command Fort Detrick, Maryland 21702-5012			<b>10. SPONSOR/MONITOR'S ACRONYM(S)</b>		
			<b>11. SPONSOR/MONITOR'S NUMBER(S)</b>		
<b>12. DISTRIBUTION / AVAILABILITY STATEMENT</b> Approved for Public Release; Distribution Unlimited					
<b>13. SUPPLEMENTARY NOTES</b>					
<b>14. ABSTRACT</b> This proposal addresses the treatment of segmental bone defects and methods that can be used to manipulate the Masquelet induced membrane (IM) to create a graft bed that optimizes bone regeneration. The results showed that scraping the inner surface of the induced membrane provided a highly desirable environment that promoted more bone regeneration by exposing the autograft placed in the defect site to fresh blood and competing non-osteogenic cells.					
<b>15. SUBJECT TERMS</b> Optimization of the Masquelet induced membrane to improve bone healing.					
<b>16. SECURITY CLASSIFICATION OF:</b>			<b>17. LIMITATION OF ABSTRACT</b>	<b>18. NUMBER OF PAGES</b>	<b>19a. NAME OF RESPONSIBLE PERSON</b> USAMRMC
<b>a. REPORT</b> U	<b>b. ABSTRACT</b> U	<b>c. THIS PAGE</b> U			UU

## Table of Contents

	<u>Page</u>
<b>1. Introduction.....</b>	<b>4</b>
<b>2. Keywords.....</b>	<b>4</b>
<b>3. Overall Project Summary.....</b>	<b>4</b>
<b>4. Key Research Accomplishments.....</b>	<b>16</b>
<b>5. Conclusion.....</b>	<b>16</b>
<b>6. Publications, Abstracts, and Presentations.....</b>	<b>17</b>
<b>7. Inventions, Patents and Licenses.....</b>	<b>17</b>
<b>8. Reportable Outcomes.....</b>	<b>17</b>
<b>9. Other Achievements.....</b>	<b>17</b>
<b>10. References.....</b>	<b>17</b>
<b>11. Appendices.....</b>	<b>17</b>

## 1. INTRODUCTION:

Despite substantial advances in the availability of bone graft substitute materials in recent years, large bone defects and chronic bone defects represent large, and as yet unsolved, clinical challenges. Bone defects are of particular relevance to the recovery and function of injured soldiers [1]. This research addresses the treatment of segmental bone defects and methods that can be used to optimize the Masquelet induced membrane [2-6] technique to create a superior graft bed for bone regeneration. Using the Chronic Caprine Tibial Defect (CCTD) model, this study specifically aims to assess the effects of surgical technique and spacer design in optimizing the biology of the “Induced Membrane” (IM), and to define the characteristics of an optimal membrane with respect to the parameters of cell composition, histology, and gene expression. Optimizing the Masquelet IM method and characterization of the biological features of the IM has significant potential to enhance the clinical care of wounded warriors who require bone regeneration procedures and to guide the ongoing development of advanced methods for bone regeneration. This program includes a nested development program for Dr. Jean-Claude D’Alleyrand, a junior orthopaedic surgeon at the Walter Reed National Military Medical Center, to nurture his interest in translational and clinical research by fostering relationships with established, independent clinician scientists with proven track records. The specific aim of this proposal for year 1 is to test the hypothesis that removal of the thin glistening inner surface of the IM created around a smooth polymethylmethacrylate (PMMA) spacer will enhance bone regeneration. Our plan is to characterize the histological, biochemical, cellular and gene expression features of the IM and define the features that best predict the magnitude of bone regeneration following an ACBG.

The broad objective of our team is to accelerate the rate at which clinically significant questions related to surgical management of the “induced membrane”, advanced spacer design, and advanced bone regeneration strategies can be translated into clinical practice to improve the care of wounded warriors and civilians.

2. **KEYWORDS:** segmental bone defect, caprine tibia, animal model, chronic, bone graft, Masquelet induced membrane, bone regeneration

## 3. OVERALL PROJECT SUMMARY:

### 1) Method

Aim 1 and Aim 2 used 32 animals. All animals had muscle excised. A smooth spacer was placed at the time of the “Pre-Procedure” in Aim 1 and a textured spacer in Aim 2. Four weeks later, at the “treatment” procedure, autogenous Cancellous Bone Graft (ACBG) harvested from the sternum at the time of the treatment surgery was used as the graft material. The spacer was removed and the graft was placed in a scraped bed for half of the animals, and not scraped bed for the half of the animal.

- Aim 1:  
Group 1 – Smooth spacer and intact (unscraped) IM  
Group 2 – Smooth spacer and scraped IM
- Aim 2:  
Group 1 – Textured spacer and intact (unscraped) IM  
Group 2 – Textured spacer and scraped IM

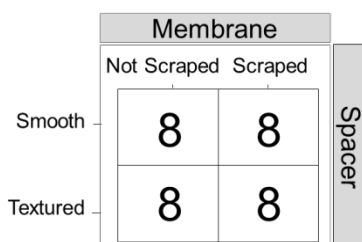


Figure 1 – Test matrix used

## Surgical Protocol

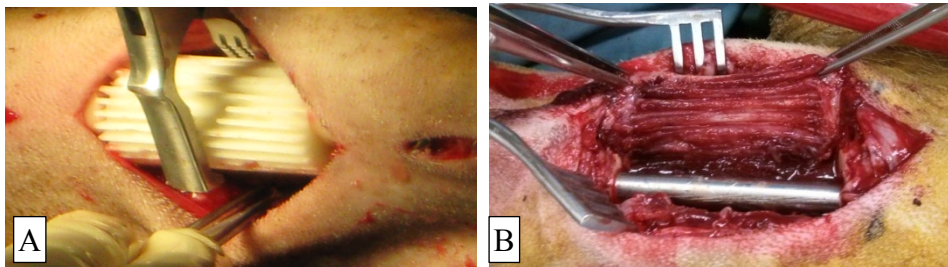
Each animal undergoes two surgeries defined here as: 1) the “pre-procedure” to create the tibia defect and the IM and 2) the “treatment” (4 weeks after “pre-procedure”). Autogenous cancellous bone graft (ACBG) is placed into the IM that is scraped for half of the goats and not scraped in the other half.

The “Pre-Procedure” (Figure 2A) is comprised of the following essential features:

1. Make a medial skin incision and excise a 5-cm segment of tibial diaphysis and periosteum.
2. Excise an additional 2 cm of periosteum on the proximal and distal bone segments.
3. Debride 10 grams of tibialis anterior and gastrocnemius muscles.
4. Place an interlocking intramedullary nail using a custom spacer to maintain 5-cm defect length.
5. Place a pre-molded 5 cm long x 2 cm diameter PMMA spacer around the nail in the defect.
6. Irrigate the wound with normal (0.9 %) saline and close the wound..

The “Treatment” (Figure 2B) is performed 4 weeks after the “Pre-Procedure” and is comprised of the following steps:

1. Collect ACBG from sternbrae. 12 cc of cancellous graft is needed for each defect; all graft available is collected from sternebra 4 or 5, approaching other sternebra only as needed.
2. Open the previous skin incision on the medial aspect of the tibia.
3. Open the IM surrounding the PMMA spacer using a “bomb bay door opening”.
4. Remove the spacer without damaging the membrane or nail.
5. Collect appropriate IM samples as defined below (see section b).
6. In Aim 1, the inner layer of the IM was scraped away in one half of the goats before grafting and the graft was placed in the intact IM in the remaining goats.
7. Close the IM with 3-0 nylon to provide an intrinsic marker and close the remaining tissues.



**Figure 2. Intraoperative images for Aim 2. A) Placement of a textured spacer during the “pre-procedure” surgery. B) Textured spacer removal 4 weeks after “preprocedure” showing resulting induced membrane.**

The procedures after engraftment included:

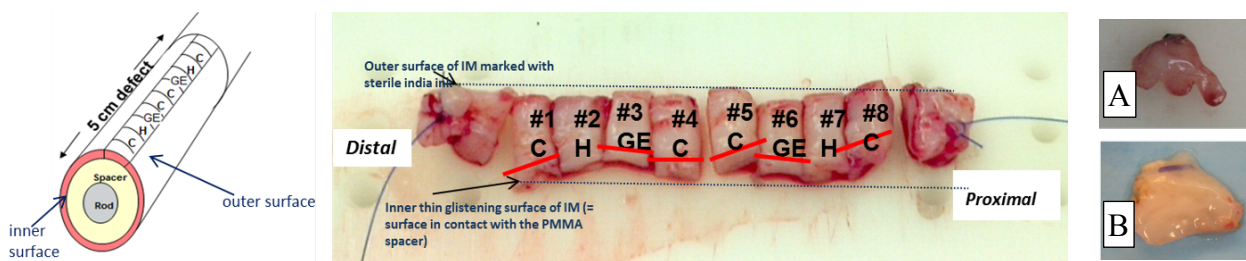
- Orthogonal radiographs (anterior-posterior (AP) and mediolateral (ML) projections) of tibia every 4 weeks,
- Physical examination including daily lameness grading for two weeks, then biweekly until euthanasia 12 weeks after “Treatment” surgery.

Euthanasia was 12 weeks after “Treatment” surgery at which time tibias were harvested and fixed in 10% formalin. Micro CT and histologic analyses of regenerate tissue were then performed.

### Induced membrane collection protocol during “Treatment” surgery

By placing a textured PMMA spacer in the defect site at the “Pre-procedure” surgery, we obtained an induced membrane with a ribbed surface that doubles the surface area when compared to a smooth

spacer. The protocol for sampling the induced membrane at Treatment surgery remains the same as Aim 1. Figure 3 illustrates the methods used to harvest and subsample the IM. Data collected from each sample include weight and thickness. Specific segments are analyzed for cells and osteogenic connective tissue progenitors (CTP-Os) (“C”), histology (“H”), and gene expression (“GE”). In the case of “C” and “GE” samples, each segment is divided into an “inner layer” (thin, friable and vascular, immediately adjacent to the spacer) and an “outer” layer (thicker, fibrous, mechanically robust, and less vascular). Samples for cell and CTP analysis are minced and digested in collagenase I and dispase. A standard assay for CTP-Os is performed. Two samples H2 and H7 were fixed in 10% neutral buffered formalin and transferred to 70% ethanol at 48 hours then shipped to the laboratory of Dr. Carlson at the University of Minnesota for processing. Two samples GE3 and GE6 were collected and shipped to Dr. Davis at the NMRC for gene expression analysis.

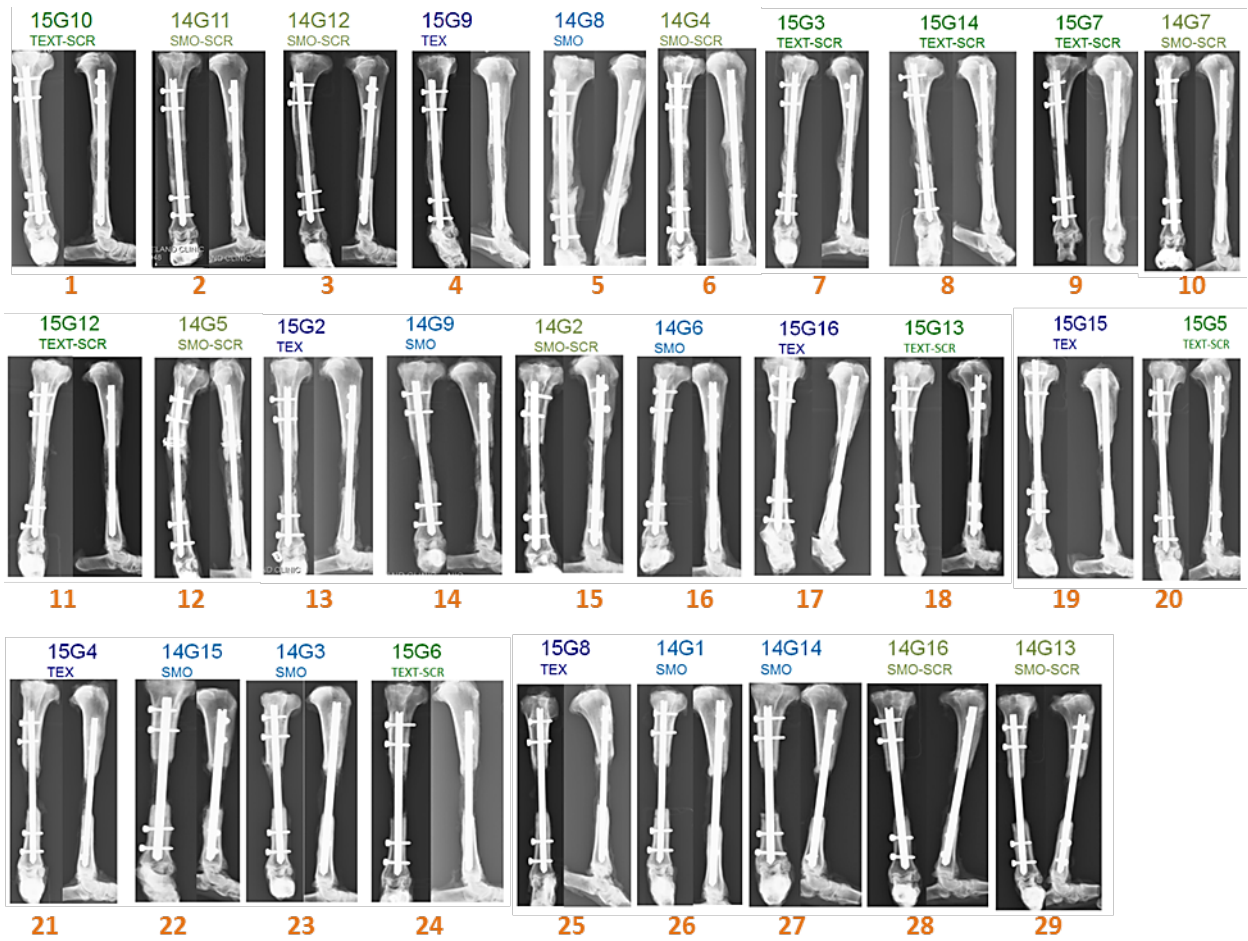


**Figure 3. Induced Membrane sample (7-mm width x 5-cm length) excised at the “treatment” surgery. Each IM strip is sectioned into inner and outer portions for analysis of cells and gene expression (GE3, GE6). The histology sections are kept intact. A) Example image of a piece of textured induced membrane; B) Example image of a piece of smooth induced membrane section.**

## 2) Results

- a) Aim 2 Animal Surgeries (Cleveland Clinic – Drs. Muschler, Pluhar and D’Alleyrand)  
Surgery was performed on 16 goats at Cleveland Clinic by the surgical team consisting of Drs. Muschler, Pluhar and D’Alleyrand in Year 2. Each goat had the pre-procedure surgery to create the segmental defect and the subsequent treatment surgery four weeks later. We had two adverse complications after the “Treatment” surgery (2<sup>nd</sup> surgery) that led to two goat euthanasias at 1 month after their second surgery. One goat (15G1) developed swelling in the defect leg and was unable to bear weight for 1.5 weeks with unmanageable inflammation, pain, and distress that would not respond to medication. The post-explant samples for this animal revealed an abscess at the defect site with cultures identifying *Staphylococcus aureus* infection. Another animal (15G11) developed swelling of lymph nodes in her neck. Samples from her neck abscess confirmed a diagnosis of caseous lymphadenitis (i.e. cultures identified *Corynebacterium pseudotuberculosis*). The animal was euthanized 1 month after her treatment surgery due to intractable disease. This reduction in the animal cohort might compromise the power of the statistical analysis to demonstrate differences between groups.
- b) Radiographic Assessment (Cleveland Clinic – Dr. Muschler)  
Orthogonal radiographs (anterior-posterior (AP) and mediolateral (ML) projections) of all 14 goats were made every 4 weeks for Aim 2.

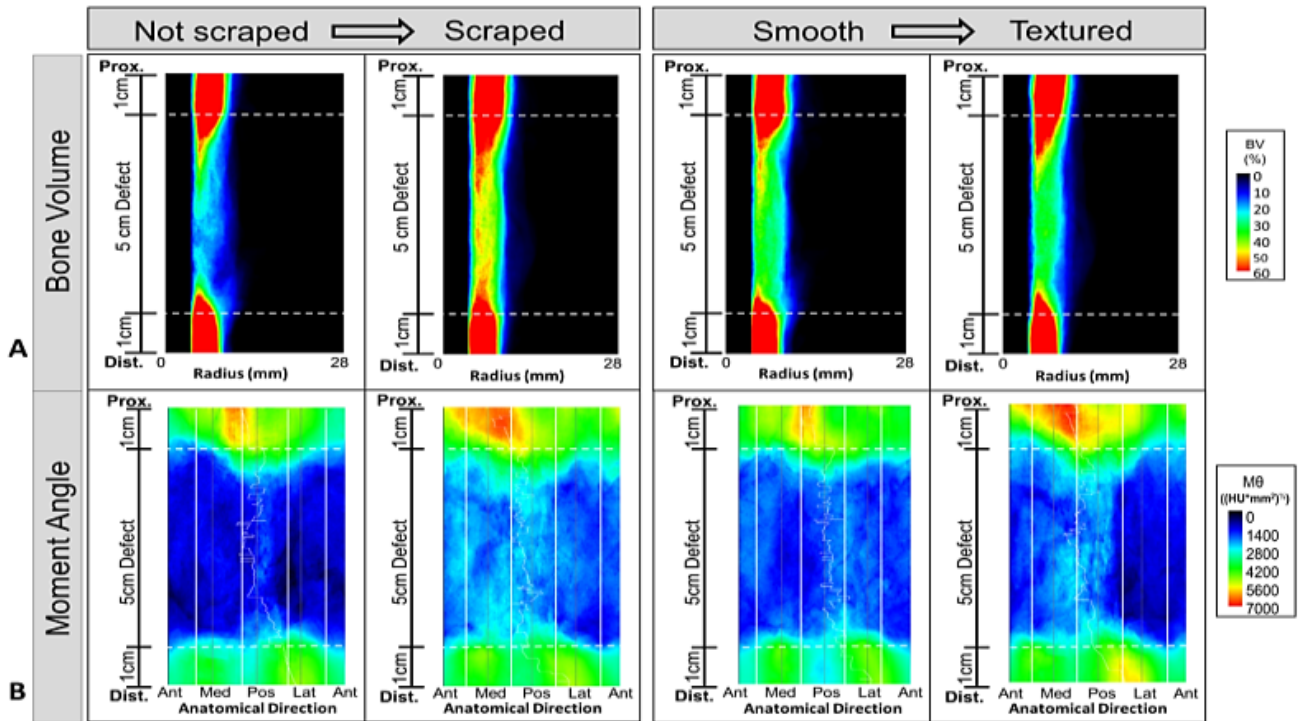
The 12-week radiographs from Aim 2 were analyzed with the radiographs collected in Aim 1. A blinded reviewer experienced in reading xrays ranked the radiographs from best to worst in terms of bone healing. Figure 4 below shows the images, ranked from left to right and top to bottom, from greatest bone healing of the tibia to no healing. The best-healed bone was assessed by the number of cortices that had bridged. The radiographs demonstrated that the animals whose IM’s were scraped showed better bone formation than those whose IM’s were not scraped.



**Figure 4. 12-week radiograph ranking. Higher rank number indicates greater tibial bone formation (1 = greatest bone healing to 29 = no healing).**

c) MicroCT analysis (Cleveland Clinic - Dr. Muschler)

The primary outcome of bone formation was assessed by microCT. These data are graphically presented using a heat map in figure 5. The plots (mean percent bone volume (%BV)) in Figure 5 illustrate that there is greater bone formation (>60%) near the osteotomies. The angular moment plots in figure 5 illustrate that bone tended to form along the posterior aspect of the defect with less bone formation medially and laterally in the not scraped groups. In the scraped IM groups, more bone formed posteriorly and medially, with little bone formation laterally. Greater bone formation in the scraped induced membrane group but textured and smooth spacer groups had comparable new bone formation. Statistical analysis is shown below.



**Figure 5. MicroCT plots illustrating the differences in bone formation and distribution resulting from the matrix study design. Scraping of the inner layer induced membrane to remove the foreign body reaction and expose a bleeding vascular surface significantly increased bone formation in the defect site. Adding texture to a smooth PMMA spacer had no effect.**

- d) Statistical analysis of total bone volume calculated from MicroCT analysis in 2.5 cm centered region of the defect.

Continuous measures were described as means, standard deviations, and percentiles. Categorical measures were summarized using frequencies and percentiles. General linear models using one-sided tests were performed. In this model, the response variable (the outcome variable) is total bone volume (TBV) calculated from the microCT scans in the middle 2.5 cm of the overall 5 cm defect region ( $\text{mm}^3$ ), and the risk factors (treatment factors) are scraped or not and spacer textured or smooth. All tests were performed at a significance level of 0.05. SAS 9.4 software (SAS Institute, Cary, NC) was used for all analyses.

As shown in Table 1, scraping of the inner layer induced membrane significantly increased bone formation in the defect site ( $p=0.041$ ) while adding texture to a smooth PMMA spacer had no significant effect ( $p=0.475$ ).

Parameter	Estimate	Standard Error	P-value
Induced Membrane:			
Scraped vs. unscraped	929.303	514.989	0.041
Spacer:			
Smooth vs. Textured	36.301	522.629	0.475

**Table 1. Statistical analysis of total bone volume in 2.5 cm centered defect region**

e) Histology analysis (University of Minnesota - Dr. Carlson)

1) Induced membrane histology

All IM samples were stained with H&E and trichrome stains, examined by a board-certified pathologist, and imaged using a 1X and 10X objective. A grading scheme for the induced membrane samples has been developed to define overall thickness, cellularity, fibrosis, and vascularity.

Grading scheme for Induced Membranes is defined below:

1) If sample contains clearly defined inner and outer zones, measure total thickness in three equidistant sites and express as mean thickness; do not measure samples that appear to have been cut tangentially.

2) Grade the following, on a 0-4 scale:

Fibrosis (on trichrome sections)

- 0 = none
- 1 = < 10% of tissue area is trichrome positive
- 2 = 10-25% of tissue area is trichrome positive
- 3 = >25-75% of tissue area is trichrome positive
- 4 = >75% of tissue area is trichrome positive

Vascularity

- 0 = none
- 1 = minimal (very few vessels present, <5)
- 2 = mild (low numbers of vessels present diffusely throughout the section, 5-10)
- 3 = moderate (contains areas of increased numbers of vessels 9vessel area > tissue area)
- 4 = severe (majority of section contains vessel area that is greater than tissue area)

\*Cellularity

- 0 = No inflammatory cells
- 1 = Inflammatory cells confined to inner 10% of membrane thickness
- 2 = Inflammatory cells present in 10-25% of membrane thickness
- 3 = Inflammatory cells present in 25-75% of membrane thickness
- 4 = Inflammatory cells present in >75% of membrane thickness

\*Note in comments if these include cells other than mononuclear cells.

Any other relevant findings will be included in a “Comments” section of the grading table.

2) Sternum autograft cancellous bone graft (ACBG) histology

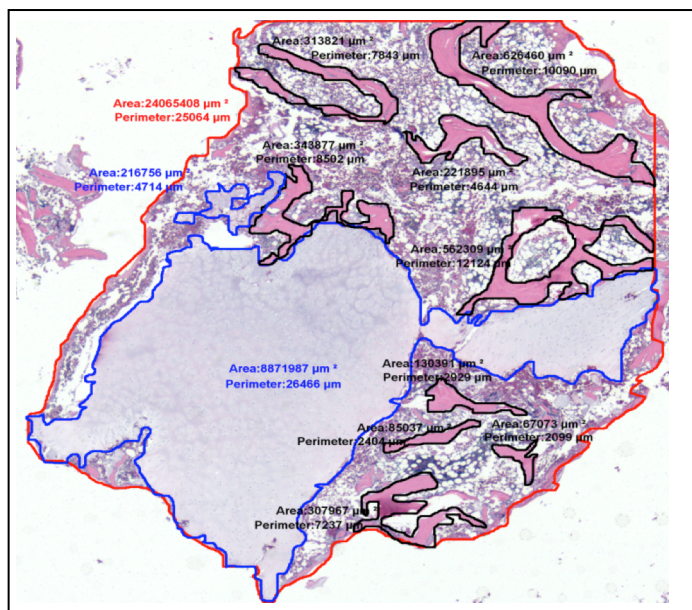
A scoring system for ACBG histology has been developed to define areas of hematopoietic marrow, bone, adipose, vascular spaces, fibrosis, and voids.

The following protocol was followed for measuring these samples:

1. Each ACBG was processed for histology, stained with H&E, examined by a board-certified pathologist, and imaged using 1X and 10X objectives.
2. Assess for uniformity of samples. If all samples are closely similar, choose one of sufficient size (>1mm X 1mm). If samples are variable morphologically, measure several representative samples in order to account for this variability.
3. Measure the following (mm<sup>2</sup>) using a 2X objective:
  1. Total tissue area (mm<sup>2</sup>)

2. Total bone area
  3. Prominent vasculature
  4. Marrow area diffusely populated with hematopoietic cells
  5. Marrow area composed only of adipose tissue
  6. Fibrous connective tissue
  7. Hyaline cartilage
  8. Void area
- (Values for #2-8 are expressed as % of total tissue area)

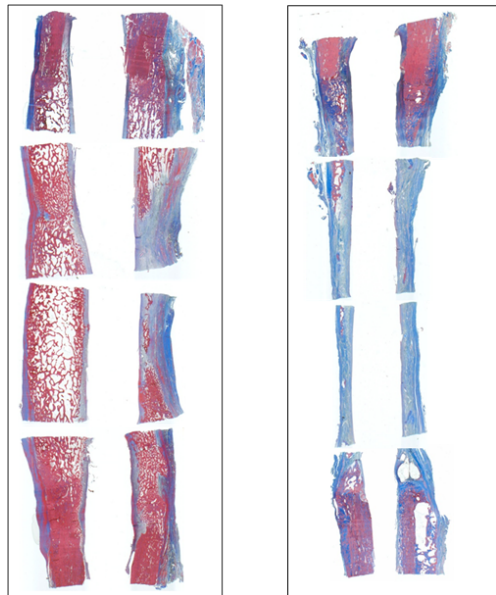
The ACBG morphology of all goats was similar, with little variation from sample to sample. The average bone area was 22.9 % (range: 11-44.9 %). A few of the samples contained areas of hyaline cartilage that occupied up to 30.8% of the tissue area (Figure 8). However, the average area of hyaline cartilage from all samples was only 3.9% (range: 11-44.9 %), whereas the average area of hematopoietic marrow was 73% (range: 54.9-86.0 %).



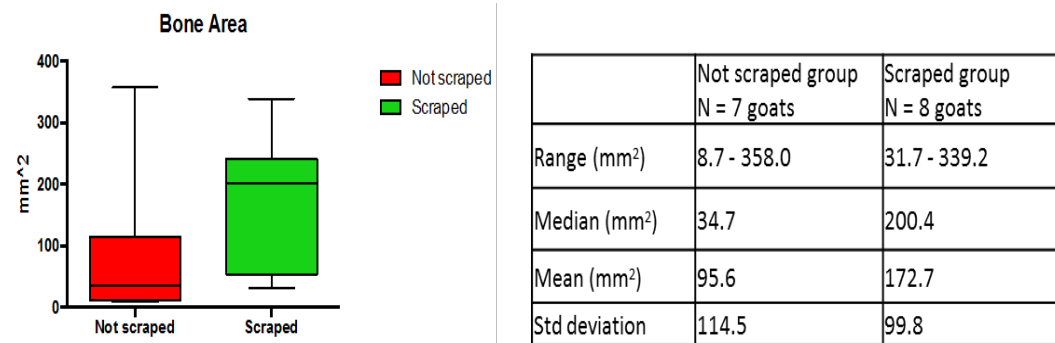
**Figure 6. Example of the ACBG measurement scheme: representative piece of ACBG determined, total perimeter traced and outlined in red, cartilage traced and outlined in blue, bone traced and outlined in black, hematopoietic marrow determined by subtracting cartilage + bone from total area.**

### 3) Tibia histology for Aim 1

The histology of the tibias collected in Aim 1 are complete. Although one goat in the non-scraped group (ID # 14G8) had a large amount of bone within the defect, the remaining 6 of 7 goats from this group had minimal bone area within the defect. The amount of bone in the defects in the scraped group was greater than that in the non-scraped group; this confirmed the microCT findings.



**Figure 7. Example of tibia specimens with abundant bone (stained red) present within the defect (left) vs. one with minimal bone present within the defect (right)**

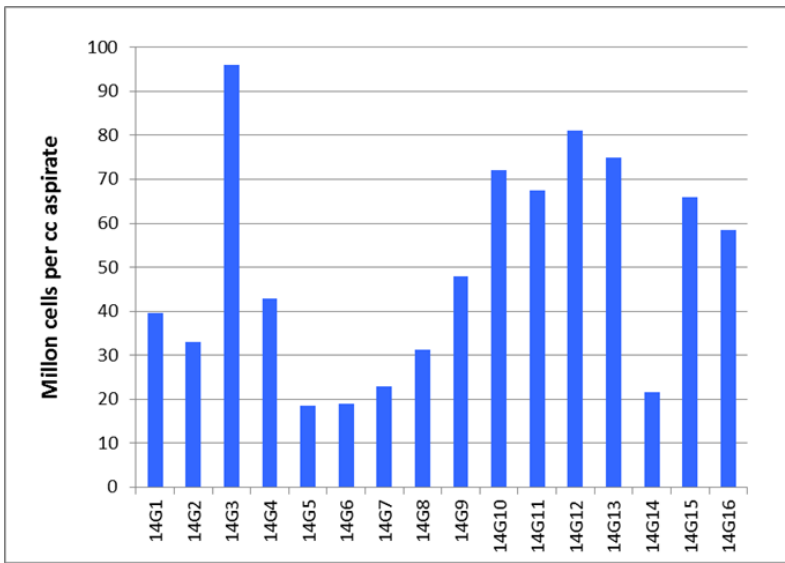


**Figure 8. Bone area measurement for each treatment group**

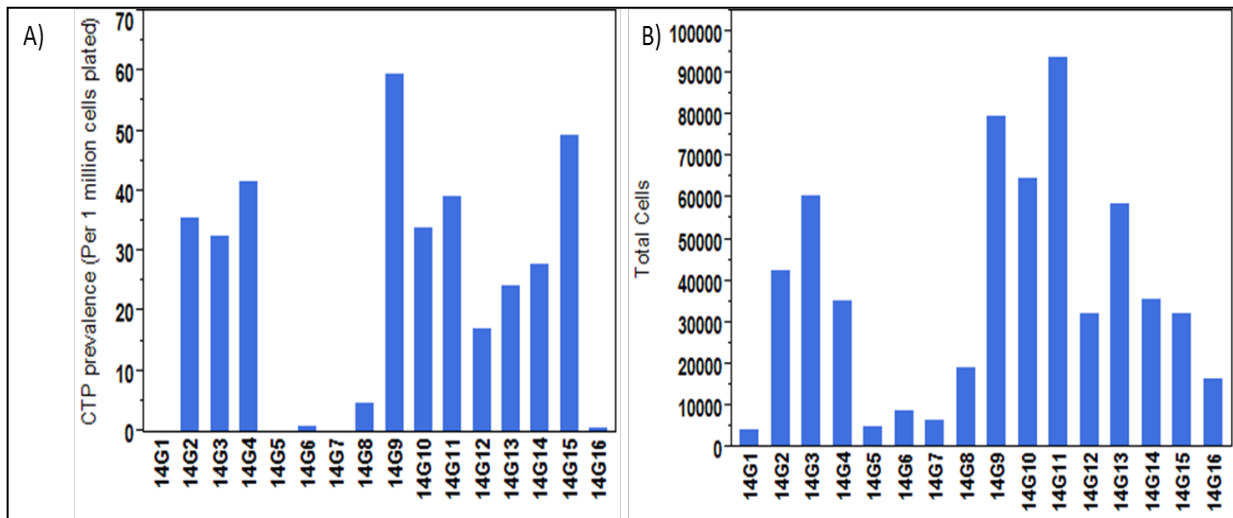
f) Characterization of cell concentration, prevalence, and biological performance of ACBG and Induced Membrane for Aim 1 (Cleveland Clinic – Dr. Muschler)

- 1) Cell/CTP-O analysis of sternum bone marrow aspirate (BMA) samples from Aim 1 (16 samples)

The mean cellularity in BMA sample was 44.2 +/- 22.7 million cells per cc. The CTP-O prevalence and the total cell yield measured within the chamber at Day 6 were respectively 24.6 +/- 23.1 CTP-Os and 40,146 +/- 29,190 cells.



**Figure 9. BMA cellularity plotted per goat**



**Figure 10. A) CTP-O prevalence; B) Total cells at Day 6 within one chamber plotted per goat**

2) Cell/CTP-O analysis of IM samples from Aim 1 (16 samples / 32 samples)

The cellularity of the induced membrane was significantly higher in the inner section than in the outer section ( $p < 0.05$ ), at  $26.0 \pm 24.1$  million cells per gram and  $11.4 \pm 8.7$  million cells per gram for the inner and outer induced membrane sections, respectively. However, the CTP-O prevalence and the total cell yield measured within the chamber at Day 6 showed no difference between the inner and outer sections. Mean CTP-O prevalence was  $6,775 \pm 4,201$  and  $6,044 \pm 4,5991$  for the inner and outer IM sections, respectively. Mean total cell yield was  $68,305 \pm 42,900$  and  $68,764 \pm 40,237$  for the inner and outer IM, respectively. Note that due to the higher plating density used, the number of colonies was difficult to measure in Colonyze™. The data presented here are an underestimate of the true yield of the induced membrane sample.

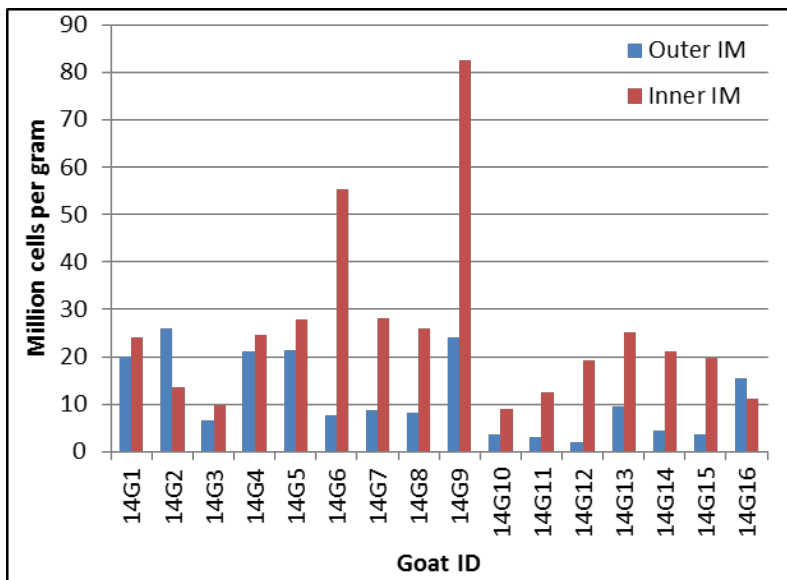


Figure 11. Cellularity in the inner (red) and outer (blue) membrane sections, plotted per goat

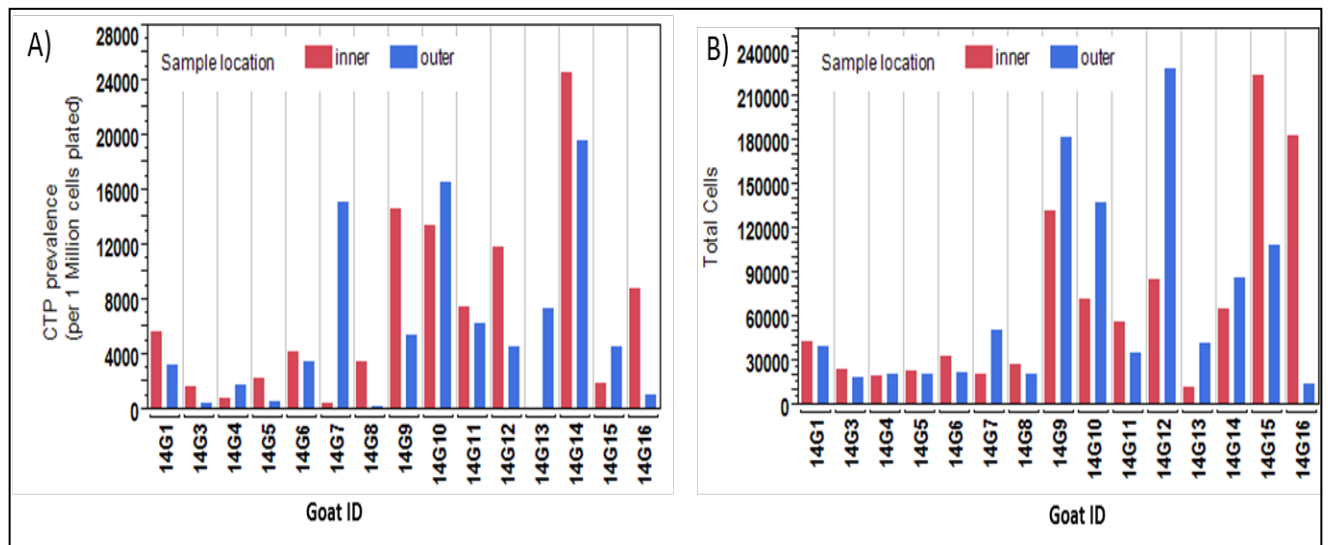


Figure 12. A) CTP-O prevalence; B) Total cells at Day 6 within one chamber, plotted per goat and per inner (red) and outer (blue) sections.

### 3) Cell/CTP-O analysis of MS and TS samples from Aim 1 (16 goats/32 samples)

The cellularity in the MS fraction was 2.3 times higher than in the TS fraction, at  $199.0 \pm 202.7$  million cells per gram  $70.3 \pm 72.9$  million cells per gram for the MS and TS fractions, respectively. However, the CTP-O prevalence was higher in the TS fraction than in the MS fraction. The mean CTP-O prevalence in the TS fraction was 1.9 times higher than in the MS fraction. Mean CTP-O prevalence was  $188.18 \pm 114.9$  and  $23.79 \pm 18.04$  for the TS and MS fractions, respectively. The total cell yield measured within a chamber at Day 6 was higher in the MS fraction than in the TS fraction, which indicates that a larger population of cells in the MS fraction were single cells, not associated with colony formation. Mean total cell yield at Day 6 was  $25,627.3 \pm 21,695.0$  and  $53,364.6 \pm 36,745.4$  for the TS and MS fractions, respectively.

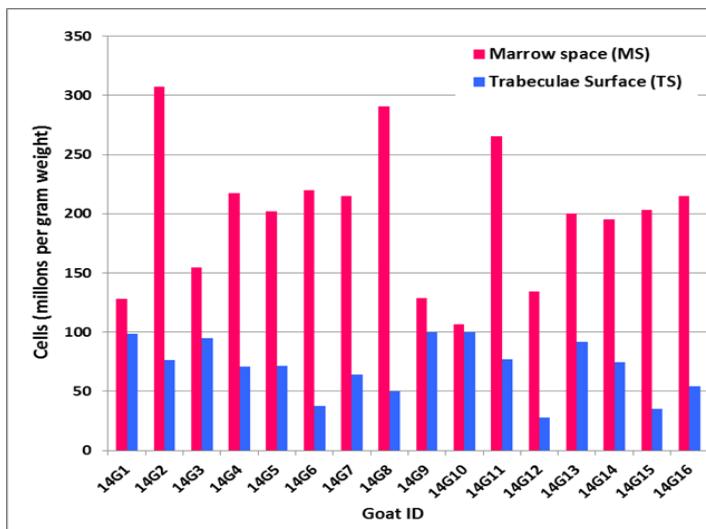


Figure 13. Cellularity in MS (red) and TS (blue) fractions, plotted per goat

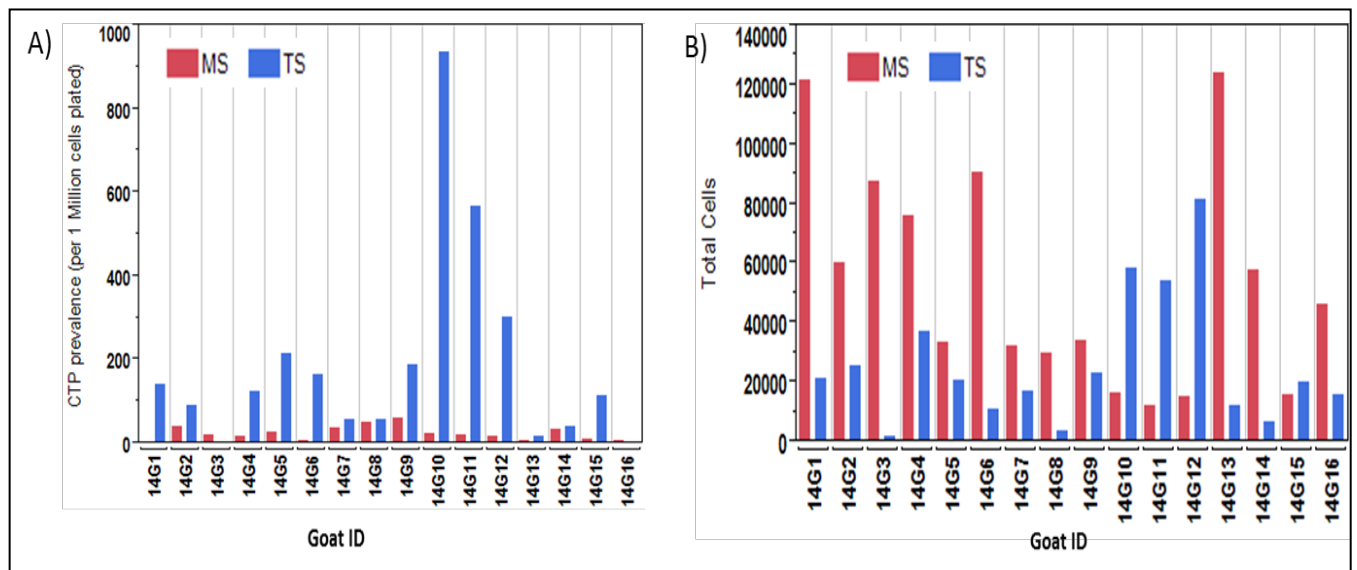


Figure 14. A) CTP-O prevalence; B) Total cells at Day 6 within one chamber plotted per goat and per MS (red) and TS (blue) fraction sections.

g) Gene expression analysis of IM samples from Aim 1 (16 goats/ 32 samples) (NMRC - Drs. Davis/Forsberg)

Gene expression analysis was performed on Aim 1 samples. The statistical analysis (one-way ANOVA) revealed increased expression (fold-changes greater than 2.0) in almost all genes analyzed, but no significant differences in fold-change between target genes across samples ( $P=0.495$ ). No significant main effects were found for target gene fold-change between sections 3o, 3i, 6o, 6i sections ( $P=0.360$ ); outer or inner membrane position ( $P=0.223$ ); or distal or proximal section position ( $P=0.307$ ). Similarly, no significant secondary effects between the main factors were found with Tukey's HSD post hoc analysis. Several target genes such as Oct4, Sox2, TGF $\beta$ 1, and Col1A1 were generally up-regulated in all sections. In distal sections, VWF, PDGFB, and EGFR were up-regulated while TGF $\beta$ 1 was up-regulated in proximal sections, though Col2A1 was down-regulated in proximal (and outer) sections. Outer membrane sections show up-regulation of VWF, PDGFB, IBSP, and NANOG while inner membrane sections have up-regulated IBSP expression but down-regulated NANOG expression. Taken together, there generally appears to be greater up-regulation in genes involved with stem differentiation, pluripotency, and cell-fate (Oct4, NANOG, Sox2 respectfully) as well as cytokine growth-factors (TGF $\beta$ 1) and members of the collagen family with

Col2A1, a cartilage-specific collagen, being up-regulated on inner distal (3i) sections. Current experiments have further optimized cDNA synthesis to minimize fold change error due to genomic DNA contamination.

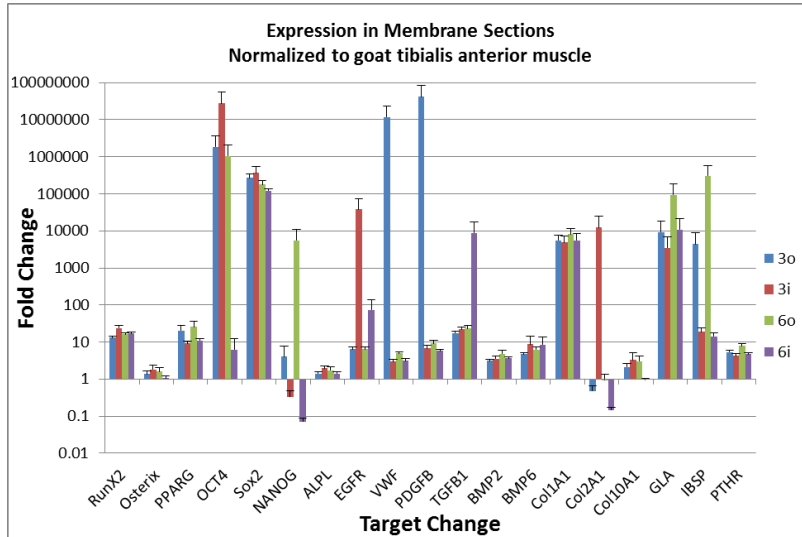


Figure 15. Gene expression for all membrane samples.

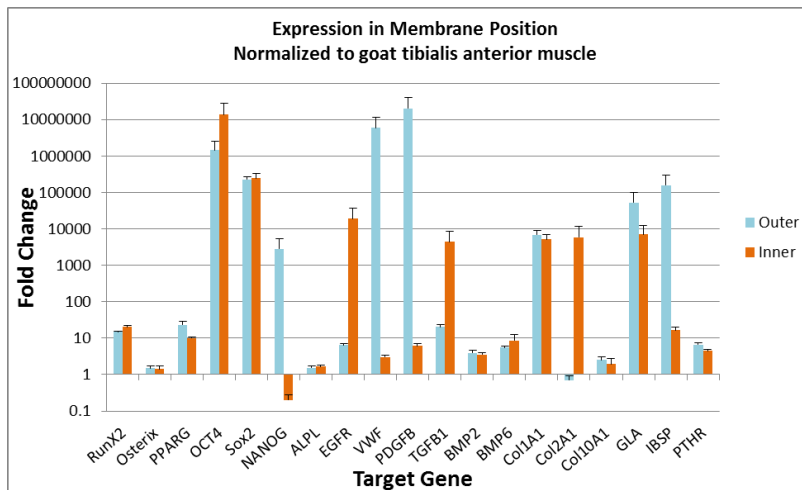


Figure 16. Gene expression in membrane sections normalized to goat tibialis anterior muscle in outer and inner IM sections.

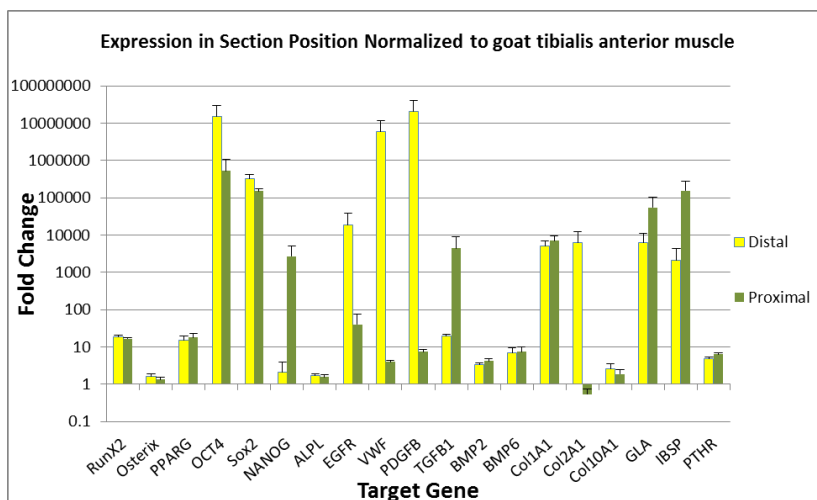


Figure 17. Gene expression in membrane sections normalized to goat tibialis anterior muscle in distal and proximal IM sections.

h) Predictive modeling (NMRC/WRNMC - Dr. Forsberg)

Development of database resource for collection and management of data from above sources and construction of the data shell are in progress and will be ready to be populated by the data collected in Aim 1 and Aim 2.

i) Nested development award (NMRC/WRNMC - Dr. D'Alleyrand)

Dr. D'Alleyrand had continued his interaction with Drs. Pluhar and Muschler and the veterinary staff at Cleveland Clinic during the animal surgeries in Aim 2. He became engaged and knowledgeable regarding the animal care process and participated in group laboratory discussions. He had received more specialized training and orientation to microCT analysis, both on a theoretical and practical level. He worked with raw CT images and gain operating experience with the process of moving from raw images to quantitative data, including sources of variation and error. He had participated intimately in the process of preparing summary data, presentation materials and will contribute as an author and editor for manuscript submissions and give presentations in selective settings (e.g. OTA, SOMOS).

#### **4. KEY RESEARCH ACCOMPLISHMENTS:**

- All surgeries and all animal care in this project have been completed.
- All microCT data have been performed for Aim 1 and Aim2 and showed significantly increased bone formation in the scraped membrane group while there was no significant improvement of bone healing when textured spacer was used.
- Histomorphometry data from the Aim1 tibia samples are consistent with the data obtained in the microCT analysis.
- The characterization of the cellularity and prevalence of osteogenic connective tissue progenitors from the induced membrane from Aim 1 samples showed that individual induced membranes vary widely with respect to weight, cellularity and CTP prevalence. Inner membrane was more cellular than outer membrane but there was no difference in CTP-O prevalence.
- The gene expression analysis from the Aim 1 samples presented several upregulated target genes such as Oct4, Sox2, TGFB, and Col1A1 in all sections. No significant main effects were found for target gene fold-change between outer or inner membrane position or distal or proximal section position.
- Data from cellular analysis, histology, gene expression analysis and microCT are being assembled for the predictive model development.

#### **5. CONCLUSION:**

The effect of surgical management of the IM combined with spacer texture demonstrated a significant benefit of scrapping ( $p=0.41$ ), but no independent benefit of spacer texture in this setting. Histological analysis of the induced membrane samples has revealed a relatively bland collagenous matrix of variable thickness of low cellularity and moderate vascularity, covered by a thin inner surface layer (foreign body response) with rare inflammatory cells, covering an underlying vascular plexus that varies in density.

In the next year, our goal is to finalize all cell analysis and histology analysis from the samples collected in Aim 2. We also plan to complete aim 3 which relates to the development of the predictive model and IM metrics associated with a positive outcome, and advancing progress of the CCTD model as an ASTM standard method.

**6. PUBLICATIONS, ABSTRACTS, AND PRESENTATIONS:**

- a. Publication: Nothing to report.
- b. Presentations:

Weinzierl A, Toth F, Pluhar GE, Muschler G, Bechtold J, Luangphakdy V, Carlson C  
“**Histomorphometric Comparison of Graft Efficacy Using a Caprine Chronic Tibial Defect Model**”, 2015 Orthopaedic Research Society (ORS) Meeting, March 28-31, 2015, Las Vegas, Nevada.

**7. INVENTIONS, PATENTS AND LICENSES:**

Nothing to report

**8. REPORTABLE OUTCOMES:**

The results from this study showed that removal of the inner surface of the induced membrane by scraping with a curette provided an environment that promoted greater bone regeneration, relative to intact membranes, by exposing the autograft placed in the defect site to fresh blood and competing non-osteogenic cells. Removal of the innermost layer of the induced “Masquelet” membranes improves healing of large segmental defects that might otherwise require multiple grafting procedures.

**9. OTHER ACHIEVEMENTS:**

Nothing to report

**10. REFERENCES:**

1. Johnson, E.N., et al. Infectious complications of open type III tibial fractures among combat casualties. *Clin Infect Dis*, 2007. 45(4):409-15.
2. Viateau, V., et al. *Induction of a barrier membrane to facilitate reconstruction of massive segmental diaphyseal bone defects: an ovine model*. *Vet Surg*, 2006. 35(5): p. 445-52.
3. Masquelet, A.C., et al. *[Reconstruction of the long bones by the induced membrane and spongy autograft]*. *Ann Chir Plast Esthet*, 2000. 45(3): p. 346-53.
4. 14. Masquelet, A.C. and T. Begue. *The concept of induced membrane for reconstruction of long bone defects*. *Orthop Clin North Am*, 2010. 41(1): p. 27-37; table of contents.
5. 15. Giannoudis, P.V., et al. *Masquelet technique for the treatment of bone defects: tips-tricks and future directions*. *Injury*, 2011. 42(6): p. 591-8.
6. 16. Karger, C., et al. *Treatment of posttraumatic bone defects by the induced membrane technique*. *Orthop Traumatol Surg Res*, 2012. 98(1): p. 97-102.
7. Muschler, G. *Standard Test Method for Automated Colony Forming Unit (CFU) Assays – Image Acquisition and Analysis Method for Enumerating and Characterizing Cells and Colonies in Culture*, A. International, Editor. 2012.

**11. APPENDICES:** Attach all appendices that contain information that supplements, clarifies or supports the text. Examples include original copies of journal articles, reprints of manuscripts and abstracts, a curriculum vitae, patent applications, study questionnaires, and surveys, etc.