

AWARD NUMBER: W81XWH-10-1-0975

TITLE: Heterotopic Ossification Following Extremity Blast Amputation:  
An Animal Model in the Sprague Dawley Rat

PRINCIPAL INVESTIGATOR: Vincent D. Pellegrini, Jr, MD

CONTRACTING ORGANIZATION:  
Medical University of South Carolina  
Charleston, SC 29425

REPORT DATE: March 2016

TYPE OF REPORT: FINAL

PREPARED FOR: U.S. Army Medical Research and Materiel Command  
Fort Detrick, Maryland 21702-5012

DISTRIBUTION STATEMENT: Approved for Public Release;  
Distribution Unlimited

The views, opinions and/or findings contained in this report are those of the author(s) and should not be construed as an official Department of the Army position, policy or decision unless so designated by other documentation.

<b>REPORT DOCUMENTATION PAGE</b>			<i>Form Approved</i> <i>OMB No. 0704-0188</i>		
Public reporting burden for this collection of information is estimated to average 1 hour per response, including the time for reviewing instructions, searching existing data sources, gathering and maintaining the data needed, and completing and reviewing this collection of information. Send comments regarding this burden estimate or any other aspect of this collection of information, including suggestions for reducing this burden to Department of Defense, Washington Headquarters Services, Directorate for Information Operations and Reports (0704-0188), 1215 Jefferson Davis Highway, Suite 1204, Arlington, VA 22202-4302. Respondents should be aware that notwithstanding any other provision of law, no person shall be subject to any penalty for failing to comply with a collection of information if it does not display a currently valid OMB control number. <b>PLEASE DO NOT RETURN YOUR FORM TO THE ABOVE ADDRESS.</b>					
<b>1. REPORT DATE</b> March 2016		<b>2. REPORT TYPE</b> FINAL		<b>3. DATES COVERED</b> 30Sep2010 - 31Dec2015	
<b>4. TITLE AND SUBTITLE</b>  Heterotopic Ossification Following Extremity Blast Amputation: An Animal Model in the Sprague Dawley Rat			<b>5a. CONTRACT NUMBER</b>		
			<b>5b. GRANT NUMBER</b> W81XWH-10-1-0975		
			<b>5c. PROGRAM ELEMENT NUMBER</b>		
<b>6. AUTHOR(S)</b> Vincent D. Pellegrini, Jr, MD  E-Mail: pellegvd@musc.edu			<b>5d. PROJECT NUMBER</b>		
			<b>5e. TASK NUMBER</b>		
			<b>5f. WORK UNIT NUMBER</b>		
<b>7. PERFORMING ORGANIZATION NAME(S) AND ADDRESS(ES)</b> Medical University of South Carolina Charleston, SC 29425			<b>8. PERFORMING ORGANIZATION REPORT NUMBER</b>		
Univ of Maryland, Department of Orthopaedics 22 S Greene Street, S11B Baltimore, MD 21201					
<b>9. SPONSORING / MONITORING AGENCY NAME(S) AND ADDRESS(ES)</b> U.S. Army Medical Research and Materiel Command Fort Detrick, Maryland 21702-5012			<b>10. SPONSOR/MONITOR'S ACRONYM(S)</b>		
			<b>11. SPONSOR/MONITOR'S REPORT NUMBER(S)</b>		
<b>12. DISTRIBUTION / AVAILABILITY STATEMENT</b> Approved for Public Release; Distribution Unlimited					
<b>13. SUPPLEMENTARY NOTES</b> PI relocated to MUSC in April, 2013. Closure of prior UMD email and relocation have contributed to tardiness of this and prior reports.					
<b>14. ABSTRACT</b> Prior phase I protocols demonstrated water and the hind limb as the preferred medium and location in the animal model. Phase II demonstrated <i>increased</i> tissue damage from pulsed lavage, and a beneficial effect from amputation above the zone of blast injury. Phase III was designed to investigate effects of nonsteroidal anti-inflammatory (NSAID) medication and external beam radiation on development of HO; prior studies served as the control group in order to limit animal numbers. Twenty-four animals were divided into 2 groups; each rat underwent isolated below-the-knee blast amputation followed by one of the two interventions. Both groups received pulsatile lavage followed by direct wound closure. Group 1 (12 rats) received 3mg/kg indomethacin for 10 days starting at postop op day 1 and Group 2 (12 rats) received one-time radiation on post-operative day 3. Each group was monitored for HO in the residual limb for <b>24 weeks</b> with radiographs postoperatively, at 10 days and at weeks 4, 8, 12, 16, 20, and 24. All animals were euthanized and tissue harvested at 24 weeks for histology. Ultimately, 25 animals underwent hind limb blast amputation and 23 animals were evaluable at 24 week follow-up. Neither indomethacin nor irradiation effectively reduced post-blast HO compared with controls. Non-healing granuloma-like lesions were associated with severe ectopic bone in 4 animals and likely represent a manifestation of heterotopic ossification.					
<b>15. SUBJECT TERMS</b> Heterotopic ossification, blast injury, amputation, local wound management, prophylaxis, radiation, indomethacin					
<b>16. SECURITY CLASSIFICATION OF:</b>			<b>17. LIMITATION OF ABSTRACT</b>	<b>18. NUMBER OF PAGES</b>	<b>19a. NAME OF RESPONSIBLE PERSON</b> USAMRMC
<b>a. REPORT</b> U	<b>b. ABSTRACT</b> U	<b>c. THIS PAGE</b> U			<b>19b. TELEPHONE NUMBER</b> (include area code)
			UU	55	

## Table of Contents

I. Introduction .....	4
II. Body .....	4
III. Key Research Accomplishments .....	5
IV. Reportable Outcomes.....	5
V. Conclusions.....	6
VI. Personnel Receiving Support From the Research Effort .....	7
VII. References .....	8
VII. Appendix .....	10
a. Supporting Data .....	10
b. Posters.....	12
c. Manuscripts.....	17

## **I. INTRODUCTION:**

In the recent conflicts in Iraq and Afghanistan, >80% of military personnel sustained an extremity injury, of which approximately 66% were attributed to blast (IED) mechanism. Enhancement in body armor technology and medical treatment has led to increased survival following extremity injury/amputation. However, having survived the initial trauma and resulting limb amputation, soldiers face complications such as development of heterotopic ossification (HO) within the residual limb causing pain, overlying skin and muscle breakdown, poor prosthetic fitting and function, a need for surgical revision of the residual limb, and delayed rehabilitation. Heterotopic ossification is the pathologic formation of mature, lamellar bone within non-osseous tissues. This abnormal growth results from a disturbance in the regulation of normal skeletogenesis. Between 2001-2005, greater than 60% of combat amputees developed HO. Current treatment options are limited and are restricted to surgical excision of the offending bone rather than primary prevention. Investigation of the effects of blast trauma on the musculoskeletal system, specifically the prevention of HO in the residual limbs of blast amputees, is a priority in the care of our war-wounded veterans. To this end, after refinement of a reliable and reproducible model of HO after blast amputation (phase I), the focus of this study was to investigate the effects of local wound management (phase II), specifically pulsatile lavage and debridement above the zone of injury, and various prophylactic measures (phase III) on the formation of ectopic bone following extremity blast amputation in Sprague-Dawley rats using a previously established animal model.

## **II. BODY:**

*Phase I and Phase II work were accomplished in years 1 and 2 of the funding period, respectively.* Phase I addressed specific aims 1 and 2 regarding the influence of blast medium and anatomical location on the appearance of heterotopic ossification in the residual limb. **Results:** Water as a blasting medium and the hind limb as the anatomical location were preferred in the animal model. Phase II work addressed specific aim 3 regarding the influence of local wound care. **Results:** Pulsatile lavage imparted unexpected incremental tissue injury to the blast-amputated limb and resulted in dystrophic calcification of the soft tissues and potentiation of the HO response in the residual limb. Aggressive soft tissue debridement above the zone of blast injury effectively eliminated to the risk of clinically significant heterotopic ossification.

*Phase III was accomplished in year 3 of the funding period.* Phase III addressed specific aim 4 and tasks 6 and 7. Specific aim 4 investigated the therapeutic interventions of nonsteroidal anti-inflammatory medication (indomethacin) versus external beam radiation to mitigate the formation of heterotopic bone. Tasks 6 and 7 examined the prevalence and severity of heterotopic bone formation after 10 days of indomethacin treatment and radiation therapy 3 days after surgery, respectively. **Results:** Of the 36 animals subjected to the left hind limb blast amputation, all survived the procedure, ambulated almost effortlessly once they recovered from anesthesia, and returned to their pre-injury baseline activities after a week. One animal assigned to the irradiation group died at two weeks post op of unknown causes and was not replaced. Two animals in each of the treatment intervention groups, and one control animal underwent at least one wound revision to remedy either dehiscence or protrusion of the bony stump through the skin envelope at approximately four weeks post op. The revision included minimal shortening of the tibial stump with a rongeur, copious irrigation with sterile saline by syringe, and repeat closure of the fascial layer and skin. Of these animals, only two developed any subsequent evidence of HO. Appropriate analgesia and antibiotic coverage were provided.

Additionally, one animal in each of the control and indomethacin groups, and two animals in the irradiation group developed persistent granuloma-like lesions over their residual stumps, and all had radiographic evidence of underlying severe HO. None of these animals required stump revision surgeries at any time. All animal surgery, survival, follow-up, euthanasia, plain radiography, and limb harvest under this protocol were completed at the University of Maryland as of June 30, 2013.

The mean HO severity was 1.5, 1.14, and 1.97 in the control, indomethacin, and irradiation groups, respectively (Fig. 9). The mean values for qualitative type of HO were 1.5, 1.47, and 2.12 in the control, indomethacin, and irradiation groups, respectively (Fig. 10). Fleiss' kappa statistic for the percent of overall inter-observer agreement of HO severity and type was calculated as 0.41 and 0.37 respectively. This correlates with a fair to moderate strength of agreement. Kruskal-Wallis one-way analysis of variance revealed no statistical significance in the severity or type of HO between either treatment group and controls. There were no notable histological differences in HO that occurred after indomethacin compared with radiation prophylaxis that would lead to an understanding of the reasons for failure of these interventions. Further micro CT analysis of specimens from the U of Maryland at MUSC was not possible because of issues related to specimen preparation and preservation. However, the blast-induced HO model is now successfully operational at MUSC under DOD CDMRP OR#120071, contract W81XWH-13-2-0084. Small animal micro CT is readily available in contiguous facilities at MUSC and quantitative characterization of HO specimens on future protocols will facilitate recognition of small differences in effectiveness of various prophylaxis regimens that may lead to better interventions.

While indomethacin and XRT used prophylactically have shown efficacy in the prevention of HO in civilian non-blast extremity injuries, these interventions administered in a similar fashion did not reduce development of HO in the setting of high energy blast-injured extremities with resultant amputation. This result may be indicative of the overwhelming intensity of the inciting blast stimulus that rendered conventional interventions ineffective. The effect of NSAIDs administered pre-blast, earlier XRT post-blast, or both treatment modalities combined immediately after blast injury may warrant further study. Nevertheless, the failure of these time-honored methods of civilian HO prevention in the high energy blast victim is noteworthy and should inform future investigations and therapeutic interventions.

### **III. KEY RESEARCH ACCOMPLISHMENTS:**

- Work concerning specific aims 1 through 4 and statement of work tasks 1-7 have been completed according to the proposed schedule and include the following specific research accomplishments:
  - Hind limb blast with water medium provided the animal model that most reproducibly resulted in HO after blast amputation without complicating infection of the local wound.
  - Amputation above the zone of injury substantially mitigated, and often eliminated, the HO response to blast amputation.
  - Pulsatile wound lavage was associated with an unanticipated radiodensity within the soft tissues of the irrigated limb;
    - Early reaction to pulsatile lavage histologically represented dystrophic calcification in association with cellular death, with substantial spontaneous resolution over time.
    - Persistent late reaction to pulsatile lavage histologically contained areas of HO with chondrocytes undergoing characteristic endochondral ossification.
  - Neither indomethacin nor external beam irradiation, as employed for HO prophylaxis in civilian practice, demonstrated efficacy in reducing heterotopic ossification as compared to untreated controls.
  - Late granuloma-like non-healing wound lesions were associated with severe ectopic bone formation in the residual limb, and were seen both in animals that did, and did not, receive HO prophylaxis.

### **IV. REPORTABLE OUTCOMES:**

- Manuscripts (appendix):
  - Jaffe DE, Yoo D, Blevins J, Gasbarro G, Hughes T, Paryavi E, Nguyen T, Fourney WL, Pellegrini VD Jr. Does Blast Medium Affect Heterotopic Ossification in a Blast-amputation Model? *Clinical Orthopaedics and Related Research*. 2015;473(8):2680-2687. doi:10.1007/s11999-015-4320-z
  - Manuscripts from Phase II and III work in preparation for submission

- Meeting poster and podium presentations (appendix):
  - Eastern Orthopaedic Assn (10/2011 - poster); “Heterotopic Ossification Following Blast Amputation: A Comparison of Hindlimb and Forelimb Injury in an Animal Model”
  - Orthopaedic Research Society (3/2012 - poster); “Heterotopic Ossification Following Blast Amputation in Forelimbs and Hindlimbs of a Sprague-Dawley Rat”
  - Maryland Orthopaedic Association (5/2012 - podium); “The Influence of Limb Selection and Blast Medium on Heterotopic Ossification Following Blast Amputation in a Rat Model”
  - Eastern Orthopaedic Assn (6/2012 – podium); “The Influence of Limb Selection and Blast Medium on Heterotopic Ossification Following Blast Amputation in a Rat Model”
  - AAOS EWI Symposium (2/2013 - poster); “The Effect of Local Wound Care on Heterotopic Ossification Following Blast Amputation in a Rat”
  - AAOS EWI Symposium (2/2014 - poster); “Pulsatile Lavage of Open Musculoskeletal Wounds Causes Muscle Necrosis and Dystrophic Calcification”
  - AAOS EWI Symposium (2/2014 - poster); “Failure of Indomethacin and Radiation to Prevent Blast-Induced Heterotopic Ossification in an Animal Model”
  - Orthopaedic Research Society (3/2014 - poster); “Failure of Indomethacin and Radiation to Prevent Blast-Induced Heterotopic Ossification in an Animal Model”
  - Combined Meeting of AOA and COA, Montreal, CA (6/2014 - poster); “Failure of Indomethacin and Radiation to Prevent Blast-Induced Heterotopic Ossification in an Animal Model”
  - Combined Meeting of AOA and COA, Montreal, CA (6/2014 - podium); “Pulsatile Lavage of Open Musculoskeletal Wounds Causes Muscle Necrosis and Dystrophic Calcification”
  - Orthopaedic Trauma Association (10/2014 - podium); “Pulsatile Lavage of Open Musculoskeletal Wounds Causes Muscle Necrosis and Dystrophic Calcification”
  - Orthopaedic Trauma Association (10/2014 - podium); “Failure of Indomethacin and Radiation to Prevent Blast-Induced Heterotopic Ossification in an Animal Model”
  - 2016 AOA Annual Meeting, Seattle, WA (6/2016 – poster); “Failure of Indomethacin and Radiation to Prevent Blast-Induced Heterotopic Ossification in an Animal Model”
- CDMRP PRORP TRPA: funded application started October, 2013 with work in progress at MUSC:
  - OR 120071; Early Identification of Molecular Predictors of Heterotopic Ossification following Extremity Blast Injury: Animal Model Correlation with Human Disease. V Pellegrini, PI.

## **V. CONCLUSIONS:**

The principal observations from this project have important implications for immediate translation to clinical practice and deserve further study:

- Current methods of HO prophylaxis in civilian practice (indomethacin and external beam irradiation) failed to demonstrate any significant mitigation of heterotopic ossification following blast amputation in Phase III experiments in our animal model. This observation suggests that the intensity of the tissue trauma and subsequent inflammatory response to blast injury overwhelms the known mitigating effects of these two interventions. It is unclear whether increased dose or prolonged treatment period would increase effectiveness of these interventions, but related wound complications may ultimately limit their utility. Additional novel interventions to mitigate the effects of blast-induced HO must be explored.
- Only amputation above the zone of blast injury substantially mitigated, and often eliminated, heterotopic ossification as observed in Phase II experiments. This observation may represent an important initial wound management strategy that is most applicable to mid to distal tibia blast amputations, where primary below knee amputation can be performed above the zone of injury while still retaining a functional knee joint. Similarly, this

suggests that high below-knee blast amputations may be best managed by early surgical through-knee amputation. While seemingly radical at first blush, this approach may expedite wound healing and facilitate functional recovery, and is worthy of further study.

- The use of pulsatile lavage is associated with incremental soft tissue injury characterized by dystrophic calcification in the blast-injured limb and is observed to potentiate the HO response in the residual limb. This observation may have immediate implications for clinical practice and supports abandonment of pulsatile lavage in high energy blast wounds. While more pronounced HO was observed on plain XR and CT with pulsatile lavage, a modified Potter scale was not sufficiently sensitive to discern any difference between the groups. Future studies should further detail and quantify the potentially harmful effects of pulsatile lavage in high-energy blast wounds; in the interim, it may be prudent to suspend the use of pulsed lavage in these clinical settings.

#### **VI. PERSONNEL RECEIVING SUPPORT FROM THE RESEARCH EFFORT**

Vincent D. Pellegrini, Jr, MD, PI

William Fourney, PhD – Collaborator

Ulrich Lieste, PhD - Collaborator

Astor Robertson, MBBS – Resident Research Technician

Thao Nguyen, MD – Resident Research Technician

David Jaffe, MD – Resident Research Technician

## VII. REFERENCES:

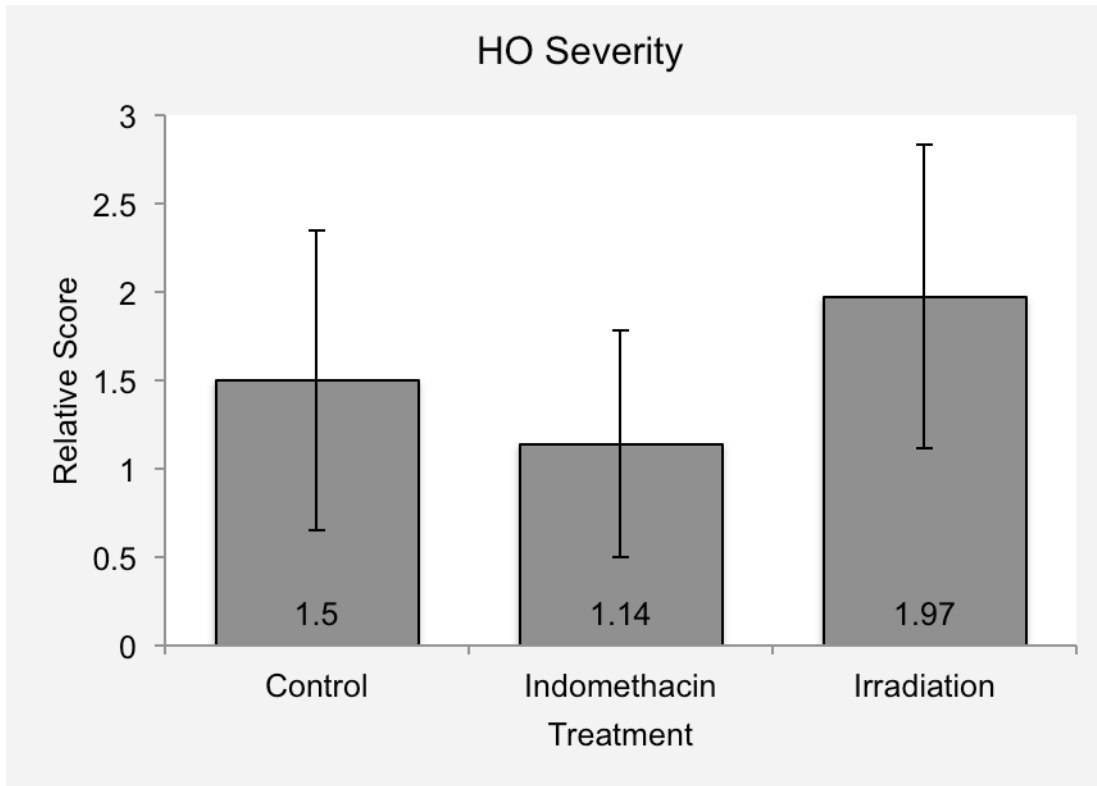
1. Baldwin K, Hosalkar HS, Donegan DJ, Rendon N, Ramsey M, Keenan MA. Surgical resection of heterotopic bone about the elbow: an institutional experience with traumatic and neurologic etiologies. *J Hand Surg Am.* 2011;36:798-803.
2. Billings PC, Fiori JL, Bentwood JL, O'Connell MP, Jiao X, Nussbaum B, Caron RJ, Shore EM, Kaplan FS. Dysregulated BMP signaling and enhanced osteogenic differentiation of connective tissue progenitor cells from patients with fibrodysplasia ossificans progressiva (FOP). *J Bone Miner Res.* 2008;23:305-13.
3. Brooker AF, Bowerman JW, Robinson RA, Riley LH Jr. Ectopic ossification following total hip replacement: incidence and a method of classification. *J Bone Joint Surg Am.* 1973;55:1629-32.
4. Brown KV, Dharm-Datta S, Potter BK, Etherington J, Mistlin A, Hsu JR, Clasper JC. Comparison of development of heterotopic ossification in injured US and UK Armed Services personnel with combat-related amputations: preliminary findings and hypotheses regarding causality. *J Trauma.* 2010 Jul;69 Suppl 1:S116-22.
5. Cipriano CA, Pill SG, Keenan MA. Heterotopic ossification following traumatic brain injury and spinal cord injury. *J Am Acad Orthop Surg.* 2009;17:689-97.
6. Covey DC. Combat orthopaedics: a view from the trenches. *J Am Acad Orthop Surg.* 2006;14 Suppl 10:S10-7.
7. Covey DC. Blast and fragment injuries of the musculoskeletal system. *J Bone Joint Surg Am.* 2002;84:1221-34.
8. Forsberg JA, Pepek JM, Wagner S, Wilson K, Flint J, Andersen RC, Tadaki D, Gage FA, Stojadinovic A, Elster EA. Heterotopic ossification in high-energy wartime extremity injuries: prevalence and risk factors. *J Bone Joint Surg Am.* 2009;91:1084-91.
9. Garland DE. A clinical perspective on common forms of acquired heterotopic ossification. *Clin Orthop Relat Res.* 1991;263:13-29.
10. Genêt F, Jourdan C, Schnitzler A, Lautridou C, Guillemot D, Judet T, Poiraudou S, Denormandie P. Troublesome heterotopic ossification after central nervous system damage: a survey of 570 surgeries. *PLoS One.* 2011;6:e16632.
11. Helm PA, Walker SC. New bone formation at amputation sites in electrically burn-injured patients. *Arch Phys Med Rehabil.* 1987;68:284-6.
12. Jackson WM, Aragon AB, Bulken-Hoover JD, Nesti LJ, Tuan RS. Putative heterotopic ossification progenitor cells derived from traumatized muscle. *J Orthop Res.* 2009;27:1645-51.
13. Jaffe DE, Yoo D, Blevins J, Gasbarro G, Hughes T, Paryavi E, Nguyen T, Fournery WL, Pellegrini VD Jr. Does Blast Medium Affect Heterotopic Ossification in a Blast-amputation Model? *Clin Orthop Relat Res.* 2015;473(8):2680-2687. (appendix)
14. Kaplan FS, Glaser DL, Hebel N, Shore EM. Heterotopic ossification. *J Am Acad Orthop Surg.* 2004;12:116-25.
15. Lineaweaver W, Seeger J, Andel A, Rumley T, Howard R. Neutrophil delivery to wounds of the upper and lower extremities. *Arch Surg.* 1985;120:430-1.
16. Mavrogenis AF, Soucacos PN, Papagelopoulos PJ. Heterotopic ossification revisited. *Orthopedics.* 2011;34:177.
17. Murray CK, Hsu JR, Solomkin JS, Keeling JJ, Andersen RC, Ficke JR, Calhoun JH. Prevention and management of infections associated with combat-related extremity injuries. *J Trauma.* 2008;64 Suppl 3:S239-51.
18. Owens BD, Kragh JF Jr, Macaitis J, Svoboda SJ, Wenke JC. Characterization of extremity wounds in Operation Iraqi Freedom and Operation Enduring Freedom. *J Orthop Trauma.* 2007;21:254-7.
19. Pape HC, Marsh S, Morley JR, Krettek C, Giannoudis PV. Current concepts in the development of heterotopic ossification. *J Bone Joint Surg Br.* 2004;86:783-7.
20. Potter BK, Burns TC, Lacap AP, Granville RR, Gajewski D. Heterotopic ossification in the residual limbs of traumatic and combat-related amputees. *J Am Acad Orthop Surg.* 2006;14 Suppl 10:S191-7.
21. Potter BK, Burns TC, Lacap AP, Granville RR, Gajewski DA. Heterotopic ossification following traumatic and combat-related amputations: prevalence, risk factors, and preliminary results of excision. *J Bone Joint Surg Am.* 2007;89:476-86.
22. Rumi MN, Deol GS, Bergandi JA, Singapuri KP, Pellegrini VD Jr. Optimal timing of preoperative radiation for prophylaxis against heterotopic ossification: a rabbit hip model. *J Bone Joint Surg Am.* 2005;87:366-73.

23. Rumi MN, Deol GS, Singapuri KP, Pellegrini VD Jr. The origin of osteoprogenitor cells responsible for heterotopic ossification following hip surgery: an animal model in the rabbit. *J Orthop Res.* 2005;23:34-40.
24. Schneider DJ, Moulton MJ, Singapuri K, Chinchilli V, Deol GS, Krenitsky G, Pellegrini VD Jr. The Frank Stinchfield Award: inhibition of heterotopic ossification with radiation therapy in an animal model. *Clin Orthop Relat Res.* 1998;355:35-46.
25. Thomas BJ, Amstutz HC. Results of the administration of diphosphonate for the prevention of heterotopic ossification after total hip arthroplasty. *J Bone Joint Surg Am.* 1985;67:400-3.
26. Vasileiadis GI, Sakellariou VI, Kelekis A, Galanos A, Soucacos PN, Papagelopoulos PJ, Babis GC. Prevention of heterotopic ossification in cases of hypertrophic osteoarthritis submitted to total hip arthroplasty: etidronate or indomethacin? *J Musculoskelet Neuronal Interact.* 2010;10:159-65.

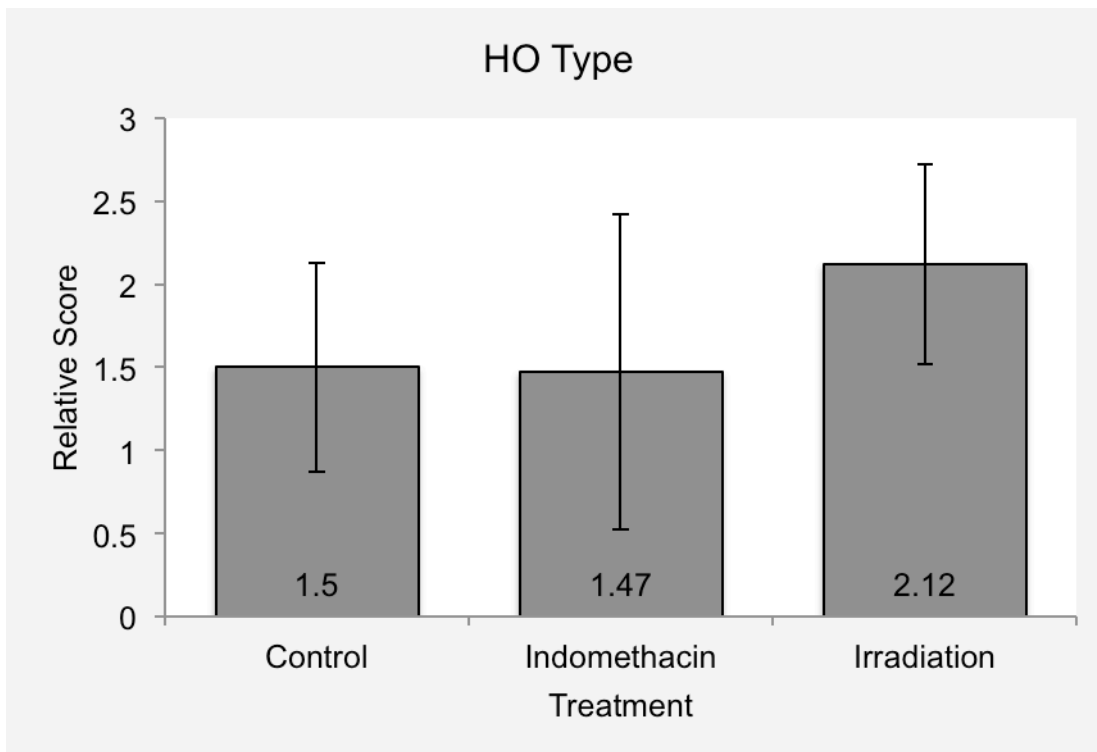
## IX. APPENDIX:

### a. Supporting Data

**Figure 1** – Grade of HO severity following blast amputation and prophylaxis per protocol.

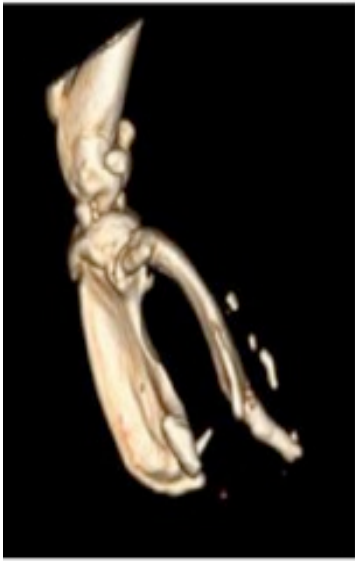

**Figure 2** - Type of HO severity following blast amputation and prophylaxis per protocol.

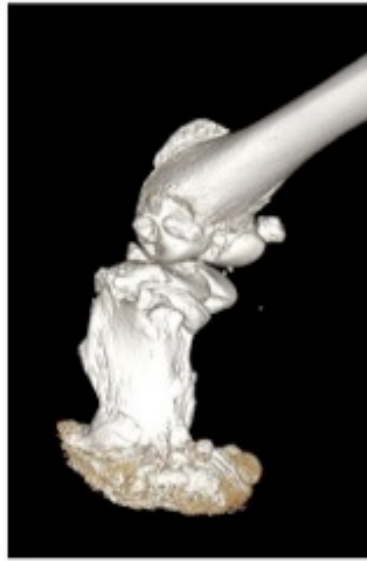

**Figure 3**

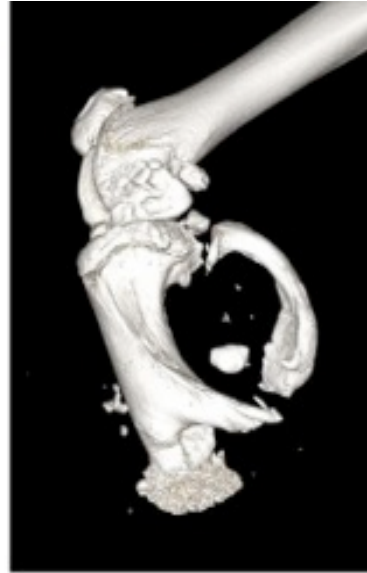
Representative images of 24 week post-blast residual limb specimens after prophylaxis per protocol.



Control



Irradiation



Indomethacin

Heterotopic ossification (HO) commonly complicates extremity blast amputations in soldiers in the contemporary war theater. This injury has become more prevalent due to the increased use of improvised explosive devices in modern warfare. Rates of HO in the residual limbs of blast amputations have been reported as high as 66%(1-3). This complication can potentially lead to pain, overlying skin and muscle breakdown, poor fit and function of prostheses, a need for surgical excision, and delayed rehabilitation.

Using a previously established animal model, the objective of this project was to compare the frequency, severity, and quality of heterotopic bone following blast amputation of the hindlimb and forelimb in a Sprague-Dawley rat.

## METHODS

On an IACUC-approved protocol, twenty-five 12-week old, male Sprague-Dawley (SD) rats, anesthetized on a customized protective platform, underwent extremity blast amputation with a column of propelled water after detonation of a submerged explosive. The blast-injured limb was irrigated with a bulb syringe containing 40:1 saline/chlorhexidine solution prior to immediate surgical closure of the fascia. Only minimal skin debridement was performed to facilitate primary wound healing. Thirteen rats underwent forelimb amputation and 12 underwent hindlimb amputation. The rats were followed clinically and with serial radiographs until euthanasia at 24 weeks.

AP and lateral radiographs were assessed at 24 weeks by three independent graders for classification of HO severity (mild-1, moderate-2, or severe-3) and type (contiguous with bone or islands of bone in the soft tissues).

This work was funded by the Department of Defense.

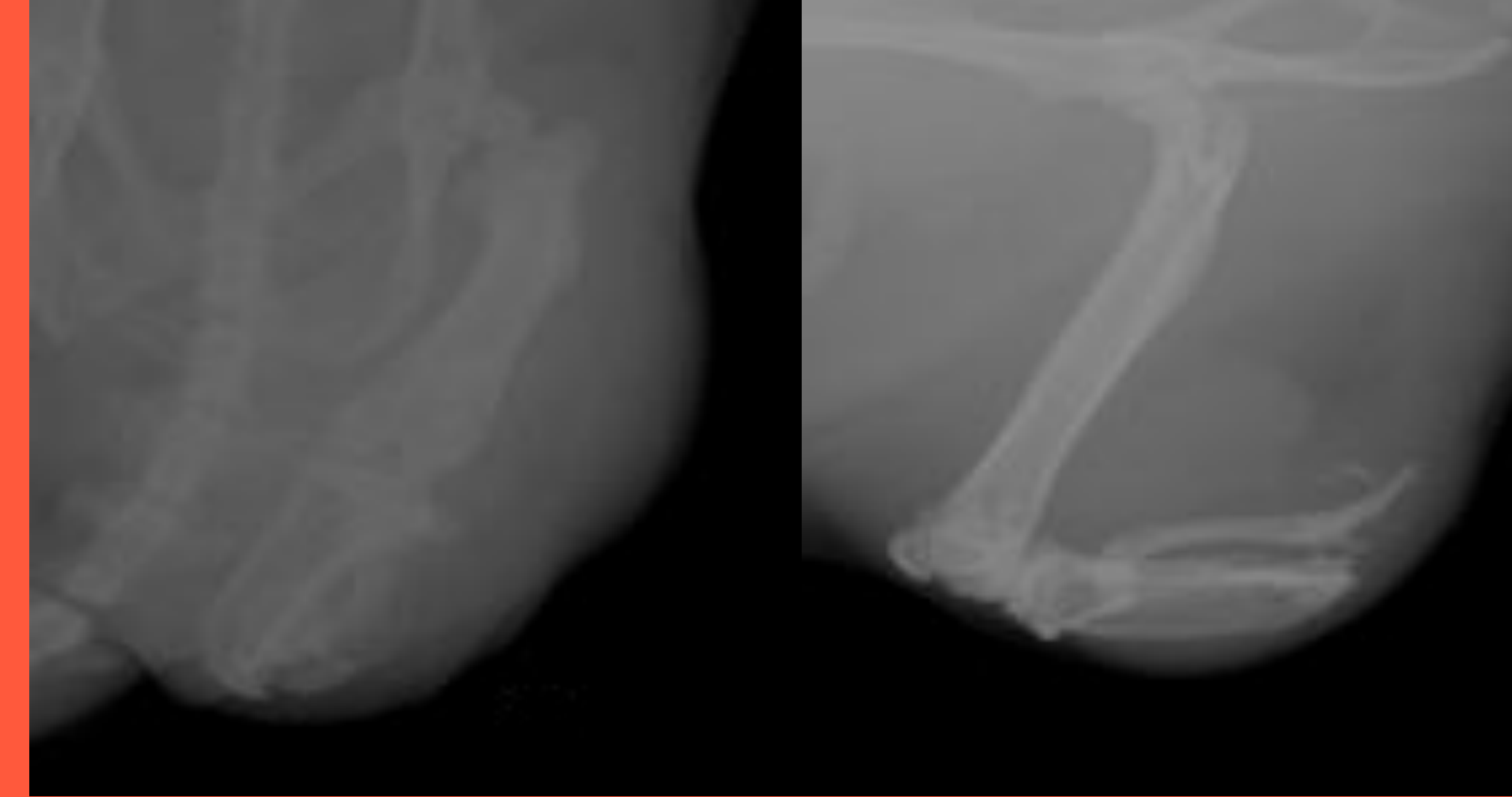


Figure 1: AP and lateral radiographs of hindlimb stump at 24 weeks.

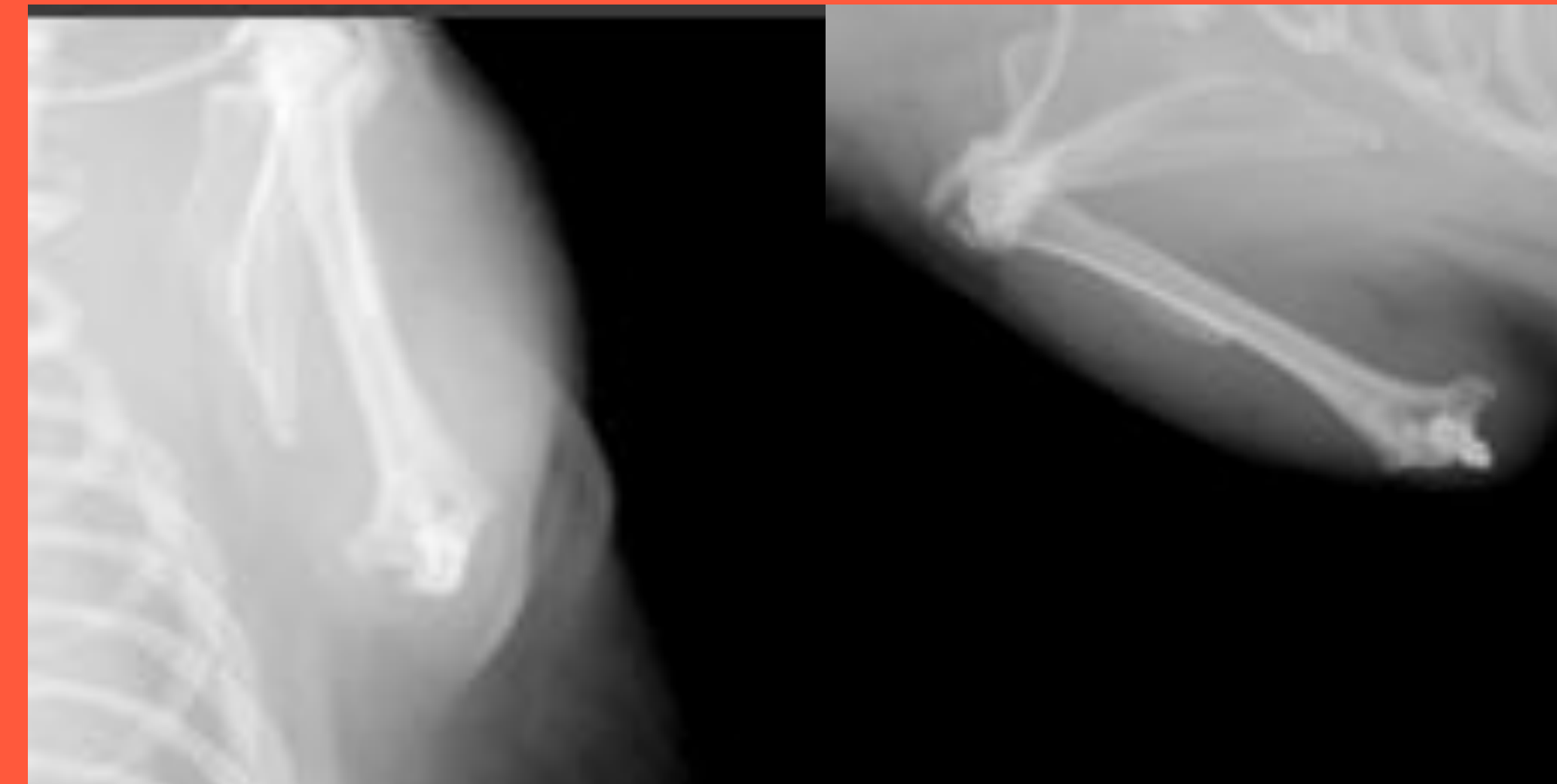

Figure 2: AP and lateral radiographs of forelimb stump at 24 weeks.

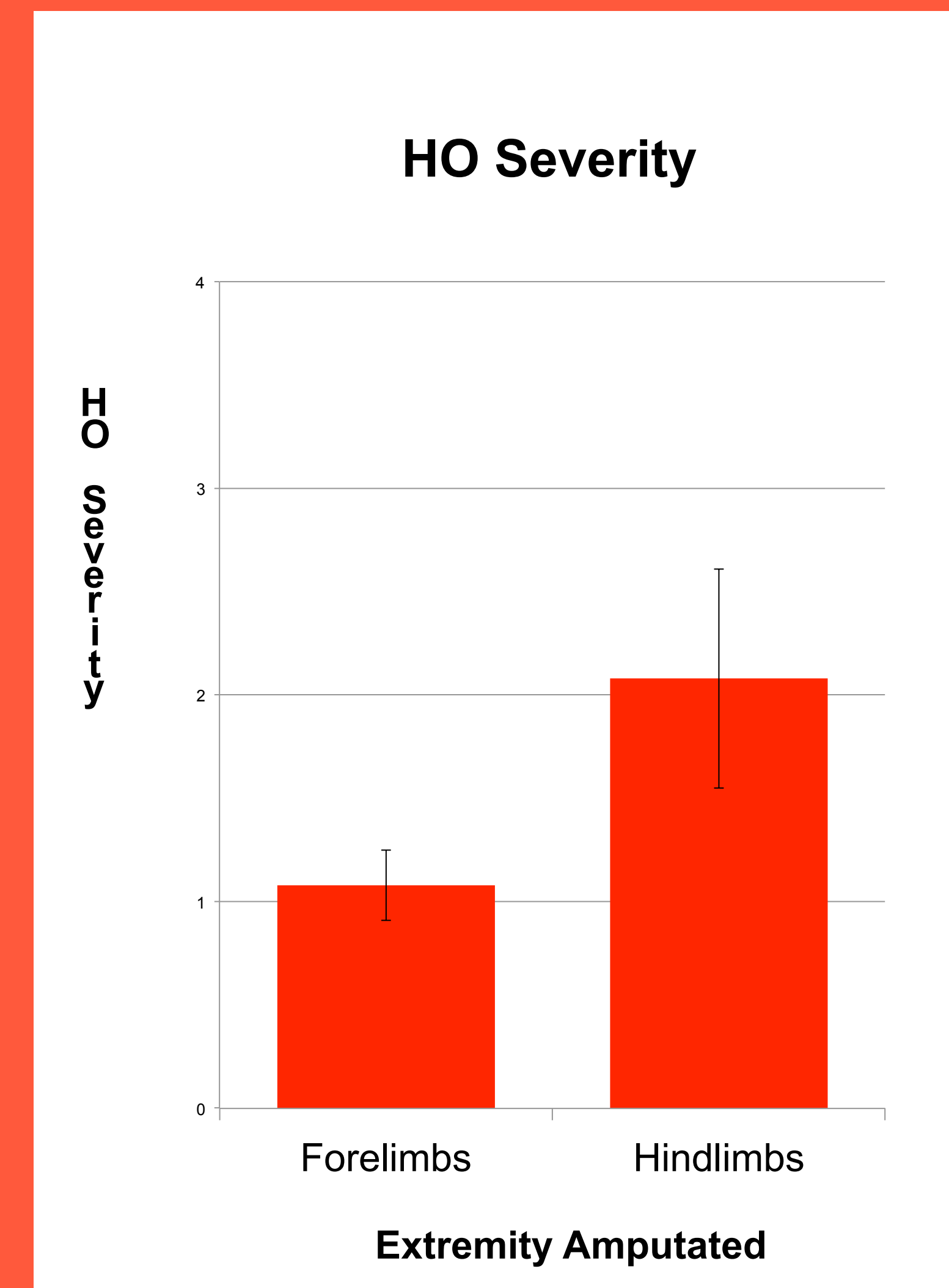


Figure 3: HO severity in forelimb and hindlimb stumps at 24 weeks.

Add CT images here

One rat anesthetized amputation developed wound dehiscence 2 weeks post-surgery. This animal had a mild HO compared to the control (p=0.002). Complications following amputation of developing forelimbs.

This study showed a high prevalence of HO in stump wounds. Hindlimb HO was significantly more severe than the forelimb (p=0.002).

1. Potter BK, et al. Traumatic Amputation: A Review of Excision and Reconstruction. *Orthopedics*. 2010;32(9):e1-e6.
2. Potter BK, et al. Residual Limb Pain: A Review of Pathophysiology and Management. *Orthopedics*. 2010;32(9):e1-e6.
3. (14) Forsberg, et al. Heterotopic Ossification: A Review of Pathophysiology and Management. *Surg Am* 2010;32(9):e1-e6.

4. Would

warrant and the use of body armor that increases victim survival. High rates of heterotopic ossification are clinically important since ectopic bone growth represents a painful and devastating problem for the wounded soldier; complications related to heterotopic bone in blast amputation stumps include pain, overlying skin and muscle breakdown, poor prosthetic fitting and function, a need for surgical stump revision, and delayed rehabilitation.

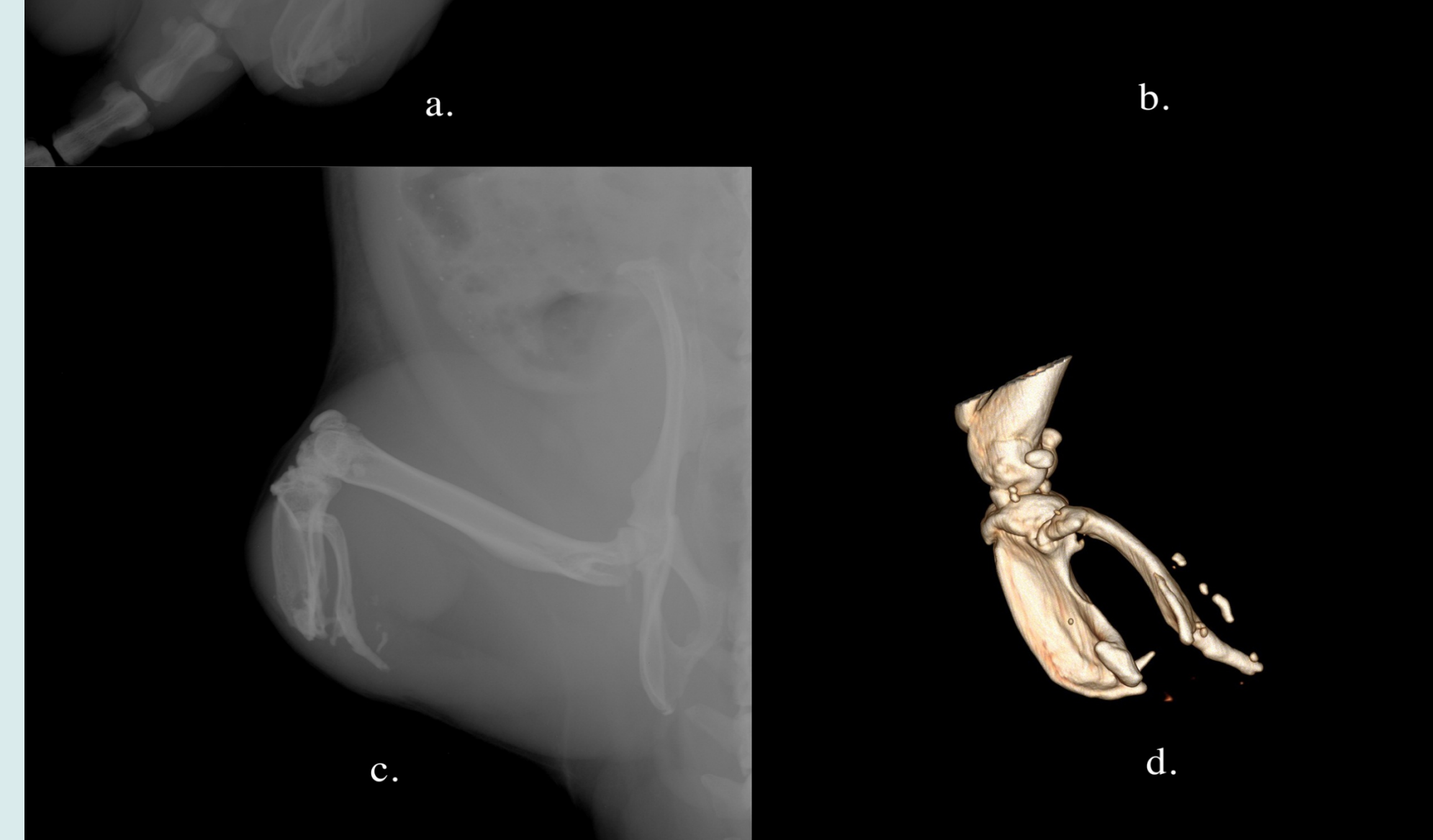
The objective of this project is to compare the frequency, quantity, and quality of heterotopic bone following blast amputation of the hindlimb and forelimb in a rat model.

### METHODS

Twenty-five 12-week old, anesthetized male Sprague-Dawley (SD) rats, underwent controlled extremity blast amputation with a column of propelled water after detonation of a submerged explosive. The blast-injured limb was manually irrigated with a 40:1 saline/chlorhexidine solution prior to fascial closure. Minimal skin debridement was performed to facilitate primary wound healing. Thirteen rats underwent forelimb and 12 underwent hindlimb amputation. The rats were followed clinically and with serial radiographs until euthanasia at 24 weeks. Half of the specimens underwent post-mortem CT imaging of the residual limb.

Three independent observers quantified and classified HO on radiographs and CTs. HO severity was defined as absent, mild, moderate, or severe and given a corresponding numerical score (0, 1, 2, or 3 respectively). Each stump was classified as one of three types. Type I was defined as new bone growth within the normal bony distribution; Type II was defined as heterotopic bone outside of the normal bony envelope, but still contiguous with the stump; and Type III was defined as ectopic bony islands developing within the surrounding soft tissue. The radiographic system for quantifying and classifying HO was validated using a kappa statistic. The severity and type of HO was compared amongst forelimbs and hindlimbs.

This work was funded by CDMRP PRORP, award W81XWH-10-1-0975.



bone, type 3, noted to be present on both plain radiographs (a, c) and computed tomography 3D reconstruction images (b,d).

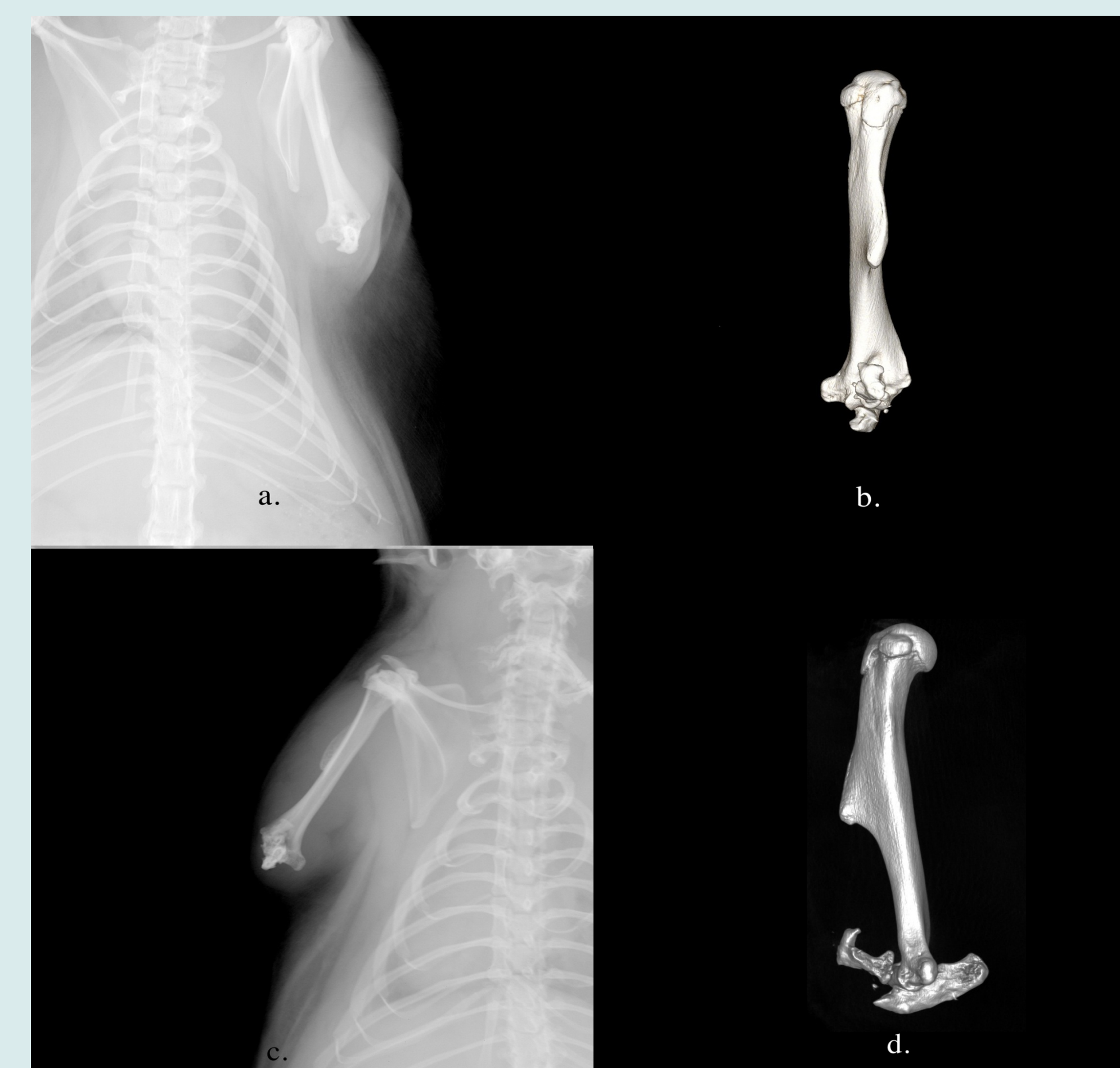

Figure 2: 24 week images of a forelimb amputation stump graded as mild heterotopic ossification on both radiographs (a,c) and 3D computed tomography (b,d), classified as type 1 on radiographs and type 2 on computed tomography.

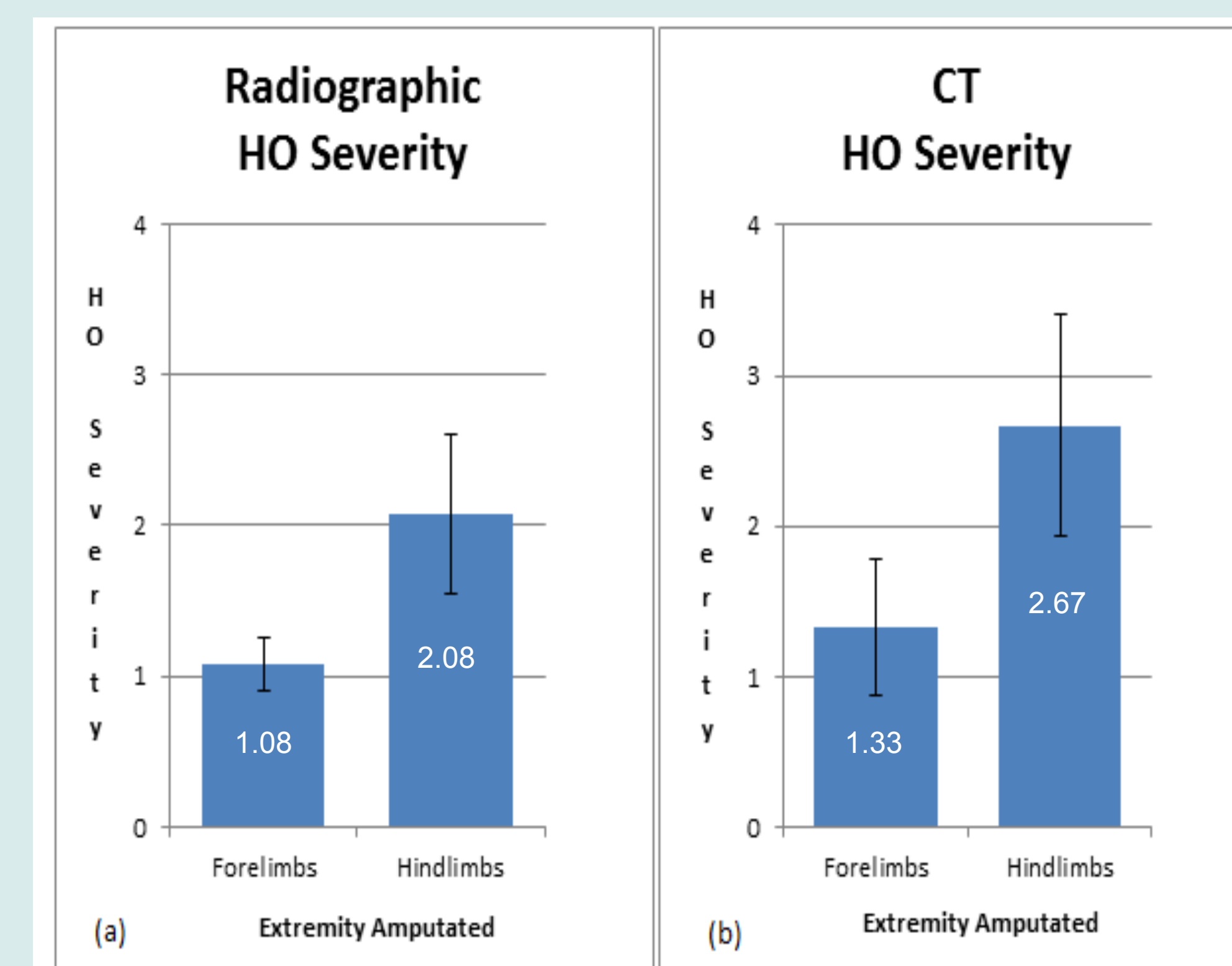


Figure 3: Mean HO Severity of Radiographic (a) and CT (b) evaluation.

resection developed High in assessment respective (moderate Moderate forelimbs developed CT evaluation radiograph correlation

This simulation heterotopic of any exo developed HO severity correlated sensitivity definitively scans. Hind forelimbs a the forelimb parallels th

1. Potter BK, Br Traumatic an Excision. J B
2. Potter BK, Br Limbs of Tra (10):S191-19
3. Forsberg JA, in High-Ener 2009 May 1;
4. Tannous O, C Amputation in

# The Effect of Local Wound Care on Heterotopic Ossification Following Blast Amputation in a Rat

Thao P. Nguyen MD, Astor Robertson MBBS, Leila Jelvani BS, David Yoo MS, David Jaffe MD, William Fourney PhD, Joseph Stains PhD, Vincent D. Pellegrini Jr. MD  
Department of Orthopaedics, University of Maryland School of Medicine, Baltimore, MD

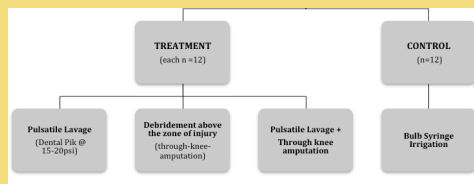


## INTRODUCTION

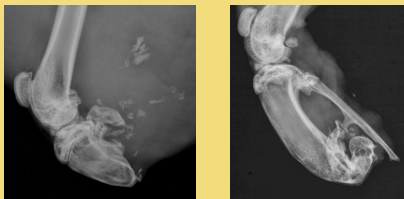
- The development of heterotopic ossification (HO) in the residual limb following extremity blast amputation causes numerous complications, including pain, overlying skin and muscle breakdown, poor prosthetic fitting and function, surgical stump revision, and delayed rehabilitation.
- The objective of this study was to investigate the effects of local wound management, specifically pulsatile lavage and debridement above the zone of injury, on ectopic bone formation following blast amputation in a rat model.

## METHODS

- Thirty-six (36) Sprague-Dawley rats underwent hindlimb blast amputation via column of propelled water with a submerged explosive.

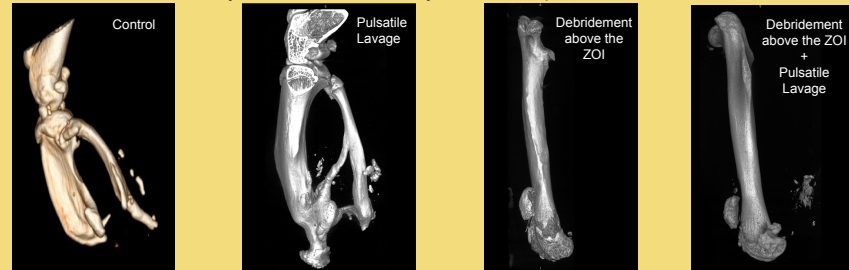

- Serial AP and lateral radiographs were obtained until euthanasia (24 weeks)
- Based on the 24-week plain radiographs, HO *type* (defined as contiguous with the stump or as distinct ectopic bony islands) and *severity* were compared with the controls.



## RESULTS

- Significantly more severe HO was observed in the pulsatile lavage group while debridement above the ZOI markedly reduced the severity of HO compared to controls:



- Ectopic bony islands:

	No. (out of 12) with ectopic bony islands		No. (out of 12) with ectopic bony islands
Control	5	Through-knee Amputation	4
Pulsatile Lavage	11 (p= 0.0272)	Pulsatile Lavage + Through-knee Amputation	11 (p=0.0094)

- No animals in the through-knee amputation group developed HO contiguous with the residual limb skeleton.
- Three animals in the pulsatile lavage groups had wound dehiscence in the immediate postoperative period, two of which also had wound breakdown without signs of infection several weeks after the blast procedure; all required simple re-closure without substantial debridement.

## CONCLUSIONS

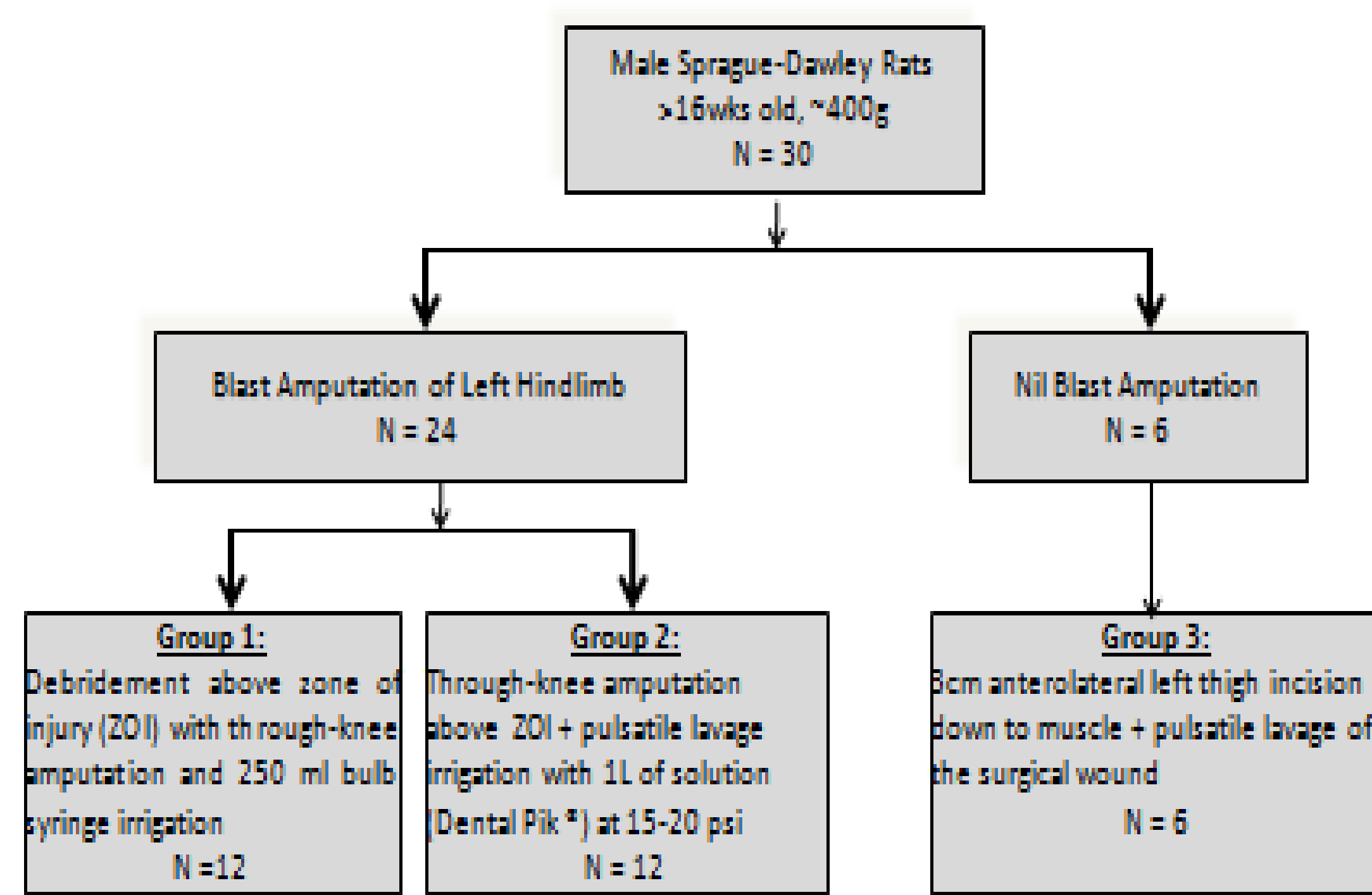
- Animals treated with pulsatile lavage, managed with amputation either through or above the zone of injury, developed more severe HO and more ectopic bony islands than animals irrigated with a bulb syringe; the implication that incremental trauma is induced by high-pressure irrigation deserves further study.
- No HO contiguous with the amputated residual skeleton occurred in animals treated with through-knee amputation above the zone of injury; this suggests that the local inflammatory milieu plays a critical role in HO induction.

## INTRODUCTION

- Adequate wound irrigation of open musculoskeletal (MSK) injuries is widely regarded as indispensable in the prevention of infection by decreasing bacterial load and other contaminants.<sup>1,2</sup>
- While the removal versus further seeding of debris into host tissue has been the subject of numerous studies, detrimental effects of pulsed saline lavage on muscle tissue have been infrequently reported.
- We aimed to assess muscle damage caused by pressurized pulsatile lavage compared with bulb syringe irrigation.

## METHODS

- Twenty-four Sprague-Dawley rats were subjected to hind limb blast amputation under an IACUC-approved protocol utilizing a column of propelled water following detonation of a submerged explosive.
- Six Sprague-Dawley rats did not undergo a blast procedure and served as controls.
- In 18 of 30 animals, with both blast and incisional wounds, pulsatile lavage at 20psi was used with 40:1 dilute chlorhexidine.



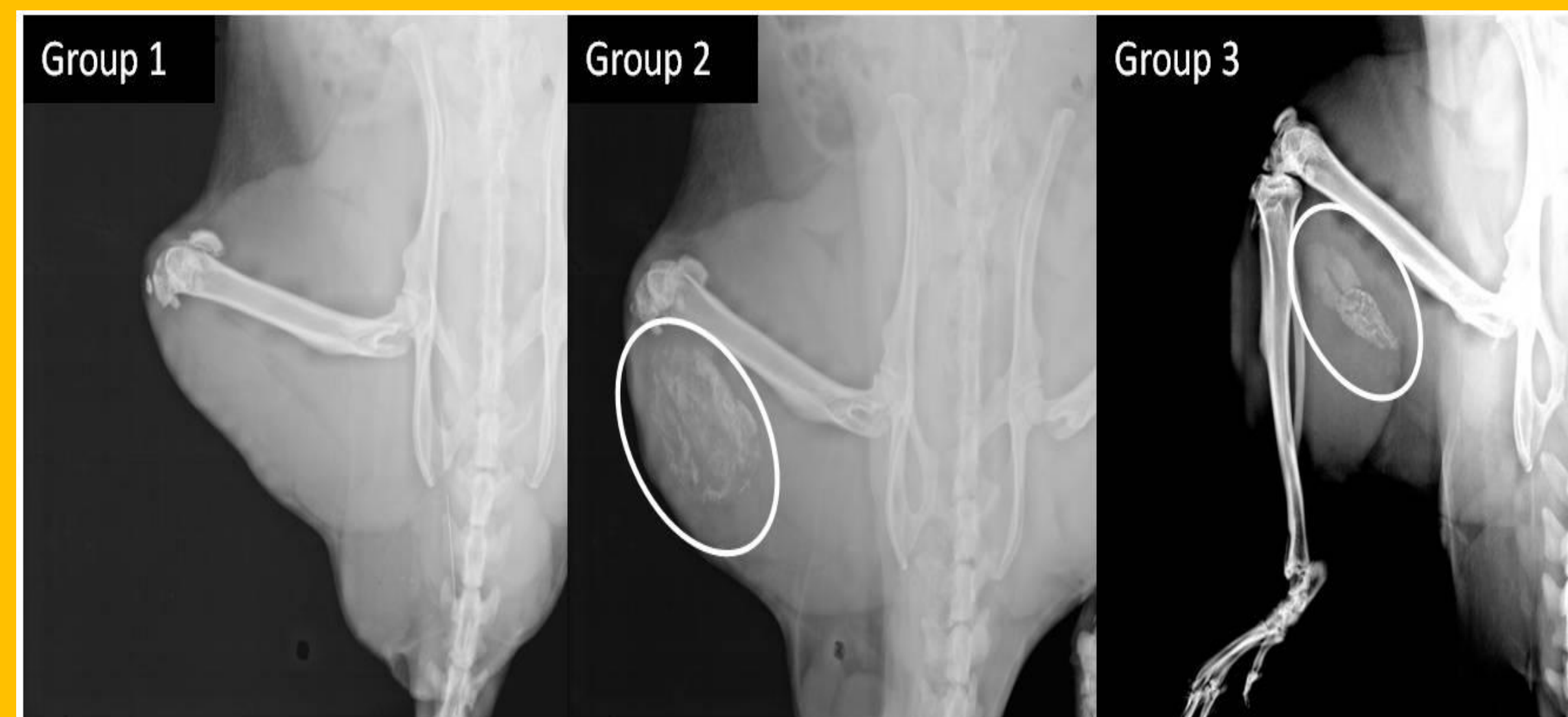
\* All animals followed with serial AP and lateral radiographs monitoring for the appearance and evolution of any soft tissue radiopacities until euthanasia at 24 weeks.

\* Xray guided excisional muscle biopsies on a few representative animals from each group were done at 6 weeks and post euthanasia.

\* Histologic analysis with Haematoxylin and eosinophil (H&E), Alizarin Red, and Von Kossa stains. Both of the latter are special stains for calcium deposits.

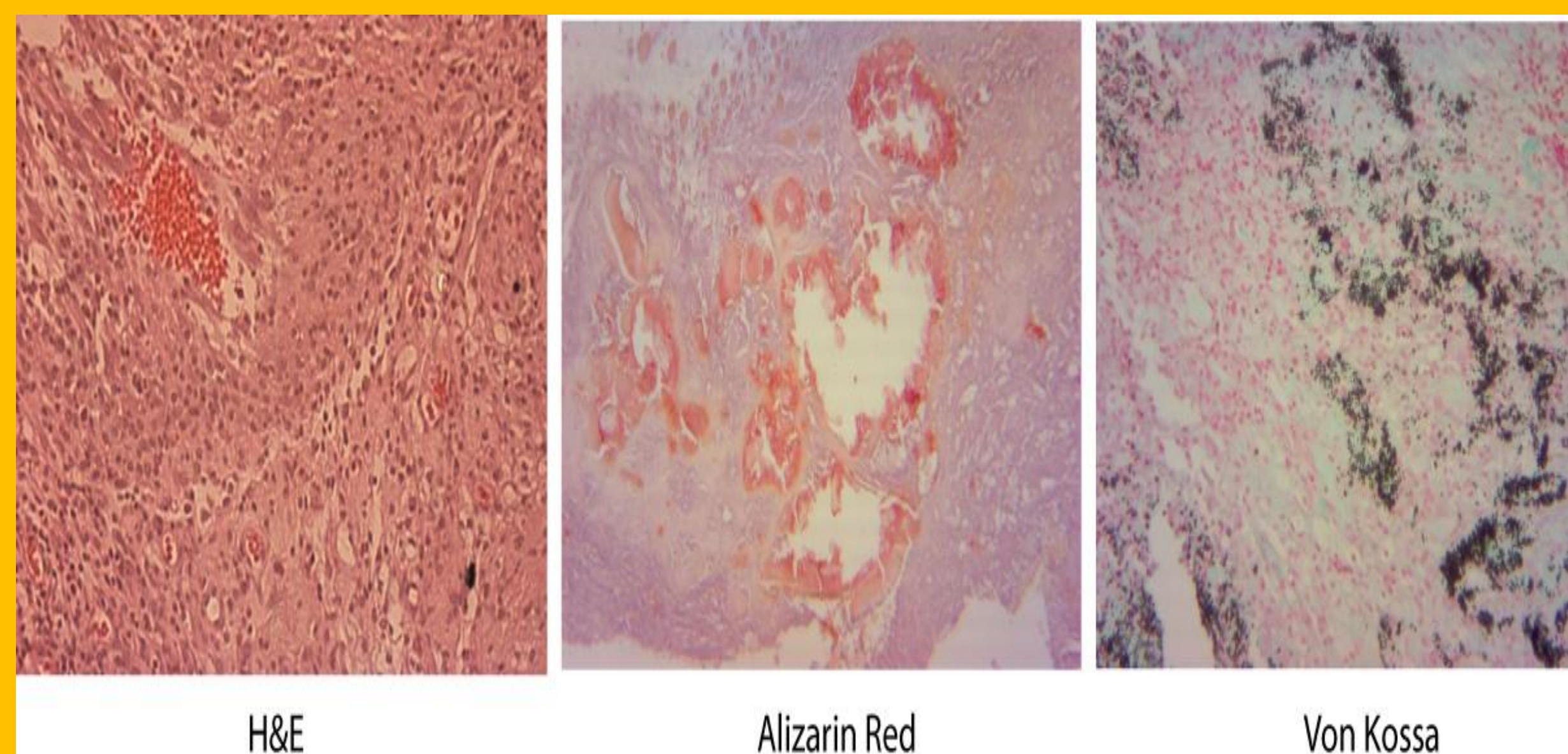
## RESULTS

- All animals treated with through-knee amputation and bulb syringe irrigation had a benign radiographic course; none developed any evidence of HO, dystrophic calcification, or other radiopaque lesions.
- In contrast, all animals having pulsatile lavage after through-knee amputation developed radio-opaque lesions first appearing at 10 days post-op.
- Soft tissue radiodensity increased until approximately 16 weeks, and thereafter showed signs of gradual and incomplete regression.



Dystrophic calcification is apparent in blast amputation (Group 2) and non-blast (Group 3) limbs following pulsed lavage, and absent in blast amputated limb irrigated with bulb syringe (Group 1)

- H&E, Alizarin Red (red), and Von Kossa (black) staining of pulsed lavage biopsy specimens all revealed evidence of tissue damage and necrosis with abundant inflammatory cells and dystrophic calcification.



H&E

Alizarin Red

Von Kossa

- No histologic evidence of true ectopic bone formation was seen in any specimen from an animal that underwent through-knee amputation.

## CONCLUSIONS

- Amputation above the zone of injury through-the-knee in this animal model eliminated the appearance of heterotopic ossification in the residual limb following blast amputation.
- Pulsatile lavage, used in the setting of high energy musculoskeletal blast injury, may cause an additional insult to the limb resulting in tissue necrosis and dystrophic calcification.
- Bulb syringe irrigation, while perhaps not as effective as pulsatile lavage, appears to be a safer irrigation method following high energy blast trauma.

## REFERENCES

- Allen, D., LaBarbera, L. A., Bondre, J., Lessing, M. C., Rycerz, A. M., Kilpadi, D., Collins, B. A., Perkins, J. and McNulty, A. (2012), Comparison of tissue damage, cross-contamination potential during wound cleansing via two methods: lavage and negative pressure wound therapy with instillation. International Wound Journal. 2012 Aug 21; doi: 10.1111/j.1742-481X.2012.01073.x
- Boyd JI 3rd, Wongworawat MD. High-pressure pulsatile lavage causes soft tissue damage. Clinical Orthopaedics and Related Research. Oct;(427):13-7.

## CONTACT

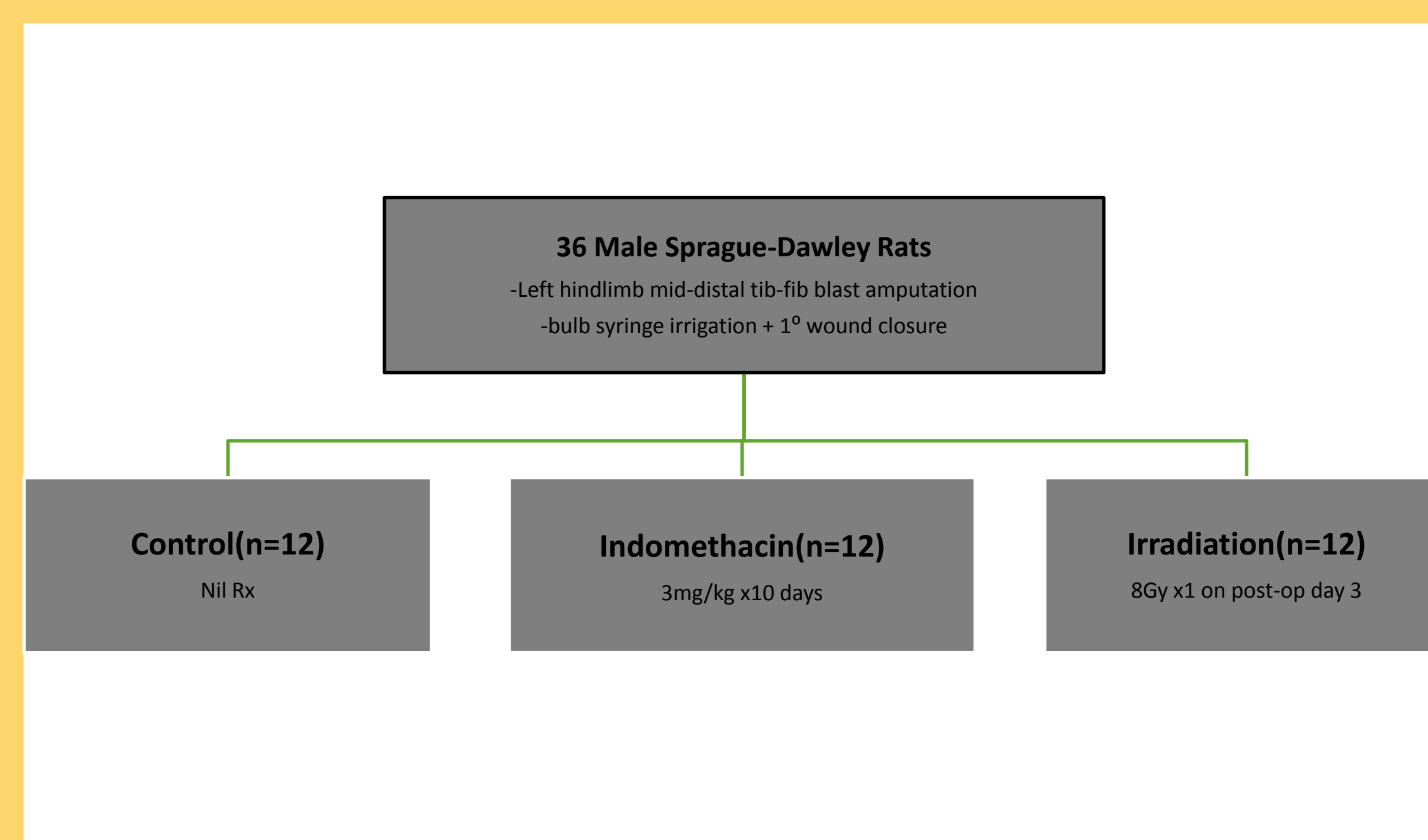
Vincent D. Pellegrini, Jr, MD  
John A. Siegling Professor and Chair  
Department of Orthopaedics  
Medical University of South Carolina  
96 Jonathan Lucas Street, CSB 708  
Charleston, South Carolina 29425  
843-792-2433 office  
843-792-3674 fax  
[pellegvdmusc.edu](mailto:pellegvdmusc.edu)

## INTRODUCTION

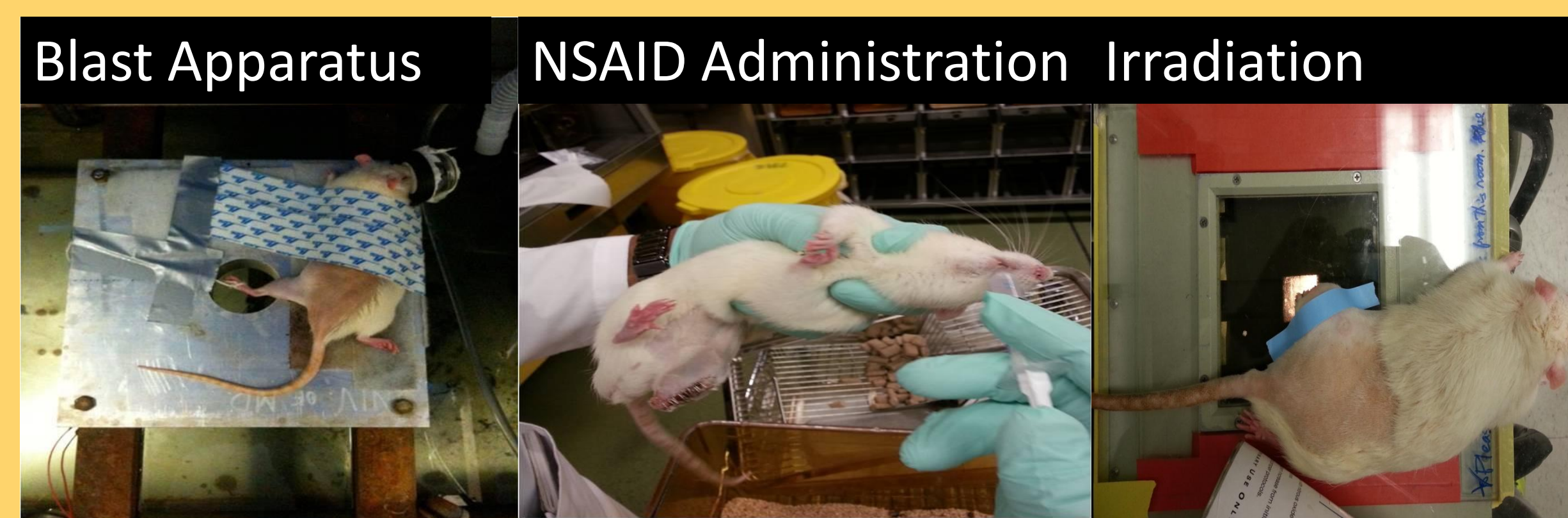- Heterotopic ossification (HO) in the residual limb has been a common morbidity in soldiers who survive extremity amputation via blast mechanisms during recent war conflicts.
- Once formed in the residual limbs of amputees, HO may cause pain, skin breakdown, need for revision surgeries, and even delay rehabilitation by complicating or preventing optimal prosthesis fitting and utilization
- While several Level 1 clinical studies have demonstrated the efficacy of prophylactic regimens using either nonsteroidal anti-inflammatory drugs (NSAIDs) or low-dose external beam irradiation (XRT) to prevent HO formation following total hip arthroplasty and surgical treatment of acetabular fractures, the HO prophylactic potential of any of these treatment modalities in the setting of trauma or trauma related amputation have never been assessed.
- This study was aimed at investigating the effectiveness of the NSAID indomethacin and irradiation, in the prevention of HO formation following extremity blast amputation in a rat model.

## METHODS

- Thirty-six Sprague-Dawley rats were subjected to blast amputation of a hind limb under a well-established IACUC-approved experimental protocol utilizing a column of propelled water following detonation of a submerged explosive.



## METHODS



- AP and Lat xrays were done immediately post-op, on day 10, and every 4 wks thereafter until 6 mths
- Radiographs were analyzed by independent graders using a modified scale from that of Potter et al

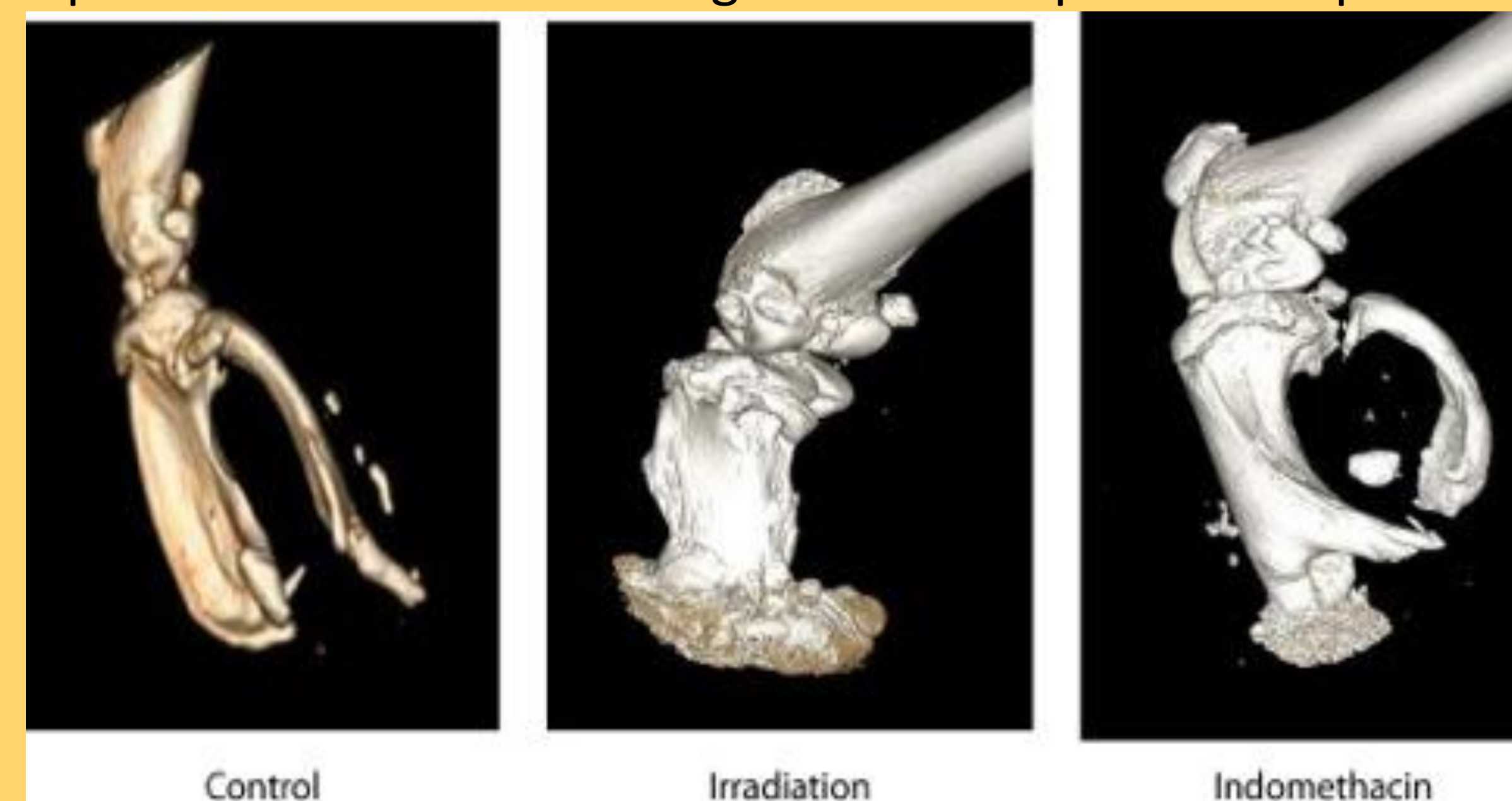Table 1

Severity	Type
0-Absent	0-Absent
1-Mild - <25% of width of tibial plateau of residual limb	1- as bone growing contiguously with the stump while remaining within the normal bony configuration
2-Moderate - 25-50% of width of tibial plateau of residual limb	2- bone contiguous with the bony stump but outside the normal bony Envelope
3-Severe (3)- >50% of width of tibial plateau of residual limb	3- ectopic bone originating within the surrounding soft tissues of the residual limb (not contiguous with the bony stump)

## RESULTS

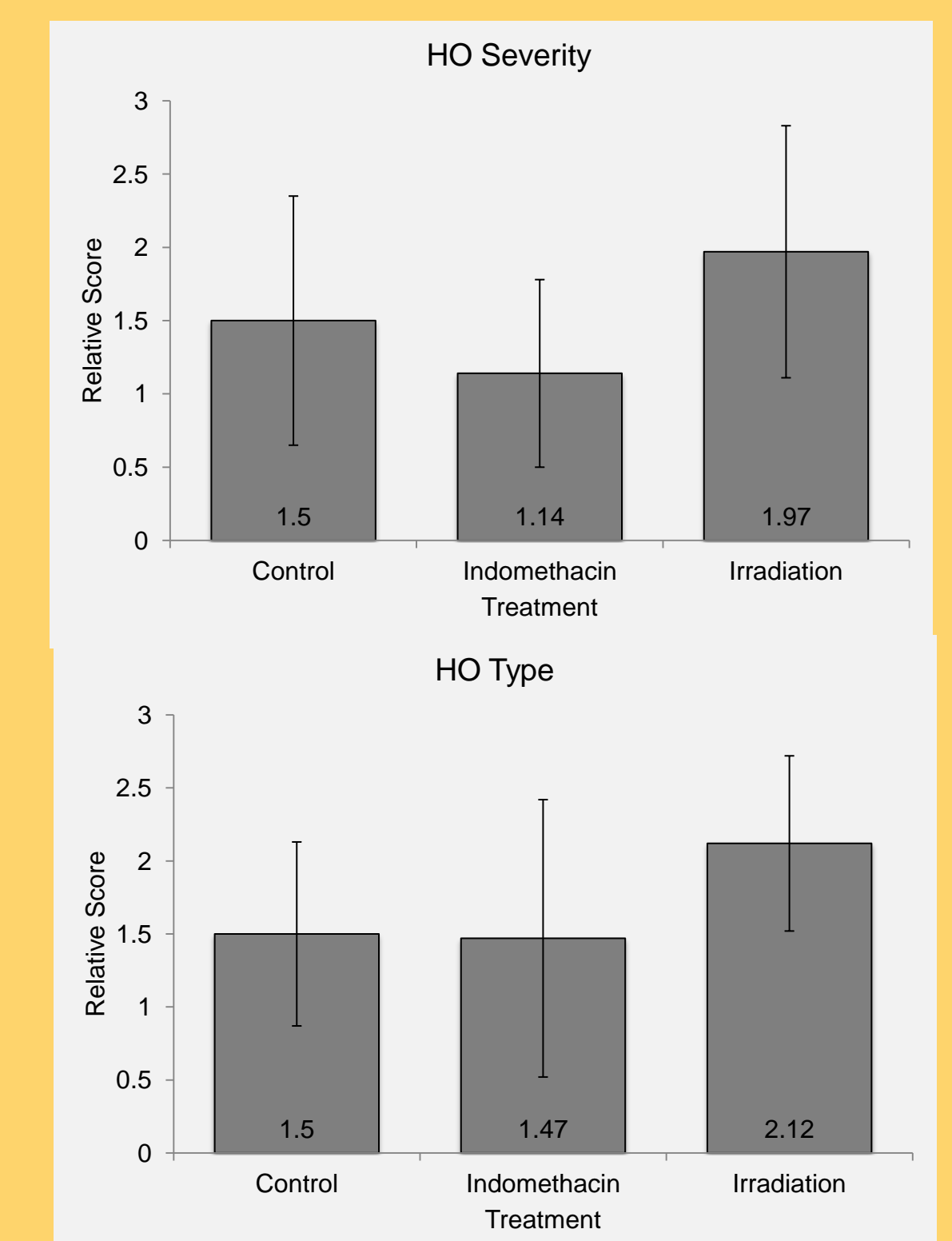
- One animal in the irradiation group died two weeks post-op and was not replaced.
- One animal each in the control and indomethacin groups, and 2 animals in the irradiation group developed persistent granuloma-like lesions on their residual stumps, and were all accompanied by radiographic evidence of HO.

Representative micro-CT images of 24 wks post-blast specimens



- No animals in either of the groups developed ectopic bony islands. However, there were two animals with severe HO amongst controls versus one in each of the treatment groups.

## RESULTS



- Kruskal-Wallis one-way analysis of variance revealed no significant difference between treatment groups and control animals

## CONCLUSIONS

- While indomethacin and XRT have been shown to be effective in the prevention of heterotopic ossification in non-blast related injuries, these same interventions administered in a similar fashion after extremity blast amputation in an animal seem to be ineffective in preventing residual limb HO.
- The failure of these proven agents to prevent HO in this setting may be indicative of an inciting blast stimulus of such overwhelming magnitude that conventional interventions are ineffective in preventing cell stimulation and progression down an osteogenic cell pathway.
- The effect of NSAIDs administered earlier XRT post-blast, or both treatment modalities combined immediately after injury warrants further study.

## REFERENCES

Potter BK, Burns TC, Lacap AP, Granville RR, Gajewski DA. Heterotopic ossification and combat-related amputations. Prevalence, risk factors, and preliminary results. *Joint Surg Am.* 2007 Mar;89(3):476-86.

## CONTACT

Vincent D. Pellegrini, Jr, MD  
John A. Siegling Professor and Chair  
Department of Orthopaedics  
Medical University of South Carolina  
96 Jonathan Lucas Street, CSB 708  
Charleston, South Carolina 29425  
843-792-2433 office  
843-792-3674 fax  
pellegrvd@musc.edu

## Does Blast Medium Affect Heterotopic Ossification in a Blast-amputation Model?

David E. Jaffe MD, David Yoo MS, Jason Blevins BA, Gregory Gasbarro MS, Tyler Hughes BA, Ebrahim Paryavi MD, MPH, Thao Nguyen MD, William L. Fourney PhD, Vincent D. Pellegrini Jr MD

Received: 29 October 2014 / Accepted: 15 April 2015 / Published online: 28 April 2015  
© The Association of Bone and Joint Surgeons® 2015

### Abstract

**Background** Heterotopic ossification (HO) develops after nearly  $\frac{2}{3}$  of traumatic blast amputations in the contemporary battlefield. This phenomenon has potentially devastating consequences for servicemen and women and its pathophysiology warrants further investigation using a previously developed animal blast model.

**Questions/purposes** We asked, what is the (1) severity (quantity) and (2) type (location) of HO bone formation

after a hindlimb blast amputation with two distinct blast media. We hypothesized that a more “war-relevant” blast medium could be a more accurate model and potentially intensify the development of HO.

**Methods** Using a Sprague-Dawley rat model, the pathophysiology of ectopic bone formation in a traumatic hindlimb blast amputation was evaluated. Twenty-four animals underwent blast amputations and closure based on a previously established experimental model. Half the amputations were subjected to blasted sand and the other 1/2 to blasted water. Serial orthogonal radiography was performed on each animal until euthanasia at 24 weeks to track the development of HO. Heterotopic bone severity and type were assessed by three independent graders at each time using a novel grading scale to assess quantity and quality of HO.

**Results** All animals had radiographic evidence of HO develop. No differences were observed in ectopic bone development between sand and water blasting regarding severity or type at any time. Animals that received water and sand blasting had moderate HO develop at 24 weeks (median, 2.0 and 2.5 weeks, respectively; range, 1–3 weeks; difference of medians, 0.5;  $p = 0.67$ ). At the time of euthanasia, 10 animals that were water blasted had Type 3 HO compared with 11 in the sand-blasted group ( $p = 1.00$ ).

---

The institution of one or more of the authors (DEJ, VDP) has received, during the study period, funding from the United States Department of Defense Congressionally Directed Medical Research Program (Washington, DC, USA). One of the authors certifies that he (VDP), or a member of his immediate family, has or may receive payments or benefits, during the study period, an amount of USD 100,000–USD 1,000,000, from the United States Department of Defense Congressionally Directed Medical Research Program (Washington, DC, USA), an amount of USD 100,000–USD 1,000,000 from DePuy Orthopaedics (Warsaw, IN, USA), and USD 100,000–USD 1,000,000 from the Agency for Healthcare Research and Quality (Rockville, MD, USA).

All ICMJE Conflict of Interest Forms for authors and *Clinical Orthopaedics and Related Research*® editors and board members are on file with the publication and can be viewed on request. Each author certifies that his or her institution approved the animal protocol for this investigation and that all investigations were conducted in conformity with ethical principles of research. This work was performed at the Department of Orthopaedics, University of Maryland School of Medicine, Baltimore, MD, USA.

---

D. E. Jaffe, D. Yoo, J. Blevins, G. Gasbarro, T. Hughes, E. Paryavi, T. Nguyen  
Department of Orthopaedics, University of Maryland School of Medicine, Baltimore, MD, USA

W. L. Fourney  
Department of Mechanical Engineering, A. James Clark School of Engineering, University of Maryland at College Park, College Park, MD, USA

V. D. Pellegrini Jr (✉)  
Department of Orthopaedics, Medical University of South Carolina, 96 Jonathan Lucas Street, CSB 708, Charleston, SC 29425, USA  
e-mail: pellegvd@musc.edu

**Conclusions** Our study showed a clear development of HO after hindlimb blast amputation in a Sprague-Dawley rat model; however, no difference was observed in HO development based on the type of blast media. This suggests it is the blast mechanism that induces ectopic bone development, regardless of the blasted medium. The grading scale we developed for our animal-model study provided a reliable means of assessing HO severity and type.

**Clinical Relevance** We anticipate that future investigations will elucidate similarities between service members' wartime extremity injuries and the animal model used in our study, and with focused future research this model may have beneficial therapeutic implications as the pathophysiology of HO development is further understood.

## Introduction

Recent conflicts in Iraq and Afghanistan have resulted in large increases in combat-related amputations among service members. Advances in protective equipment and evacuation protocols have led to a lower mortality rate for those who have experienced limb-compromising events. Consequently, the prevalence of wounded service members surviving major battlefield injury has increased substantially, with more than 88% of reported events in the Iraq conflict being survivable [9]. In the Middle East, nearly 70% of injuries are isolated to the extremities, and 80% of injuries are caused by explosive devices, resulting in high rates of survivable combat-related amputations [5, 6, 15]. Having survived initial trauma and resulting limb amputation, service members face complications that can compromise return to productive civilian life, including the development of heterotopic ossification (HO) in the residual limb.

HO is the formation of mature, lamellar bone in nonosseous tissues. Abnormal growth results from a disturbance in regulation of normal skeletogenesis and frequently is encountered in other orthopaedic settings, including THA and elbow fracture [1, 3, 11, 20–22, 24, 25] and traumatic brain injury and spinal cord injury [4, 8]. Despite being documented as far back as the Civil War, few comprehensive reports on HO frequency in combat-related injuries exist [7, 18, 19]. Potter et al. [18, 19] examined rates of ectopic bone formation in cases of battlefield amputations and found a prevalence approaching nearly  $\frac{2}{3}$  of veterans who had undergone amputation. Compared with nonblast mechanisms of injury, blast-caused amputations correlated with increased rates of HO (66% blast-caused versus 42% nonblast mechanism) [19]. Forsberg et al. [7] reported similarly high rates of ectopic bone in service members with blast-

related amputations. High rates of HO are clinically important because ectopic bone growth can be devastating for the wounded service member. Complications related to heterotopic bone in residual limbs include pain, overlying skin and muscle breakdown, poor prosthetic fit and function, need for surgical revision, and delayed rehabilitation [18]. Current treatment options are restricted to surgical excision of the offending bone [17]. Investigation of the effects of blast trauma on the musculoskeletal system must be a priority to enhance the care of war-wounded veterans.


A previously conducted pilot study established a survivable, reproducible model for development of heterotopic bone in a blast-injured rat without the use of exogenous growth factors [23]. This original pilot model created clean amputations via a jet of blasted water. Using this original model design, we sought to further understand the factors that influence the development of ectopic bone in the residual limb of a blast-injured rat. Specifically, we asked, what are the comparative differences in (1) severity (quantity) and (2) type (location) of ectopic bone growth after blast amputation of hindlimbs under two different blast conditions of sand and water? Blasting with sand may better represent the local wound contamination that results from such an injury to soldiers during battle and offer a more accurate injury model. The contamination and residual debris of a sand-blasted amputation might encourage an environment of increased inflammation and potential for increased heterotopic bone. Accordingly, we hypothesized that more ectopic bone would develop in hindlimbs subjected to blast amputation with sand than those amputated with a column of propelled water.

## Materials and Methods

The study was conducted under a protocol approved by our Institutional Animal Care and Use Committee and was funded by the Department of Defense under the Congressionally Directed Medical Research Program. Twenty-four male Sprague-Dawley rats (12–14 weeks old) underwent hindlimb blast amputation and immediate surgical closure, with minimal débridement of charred skin edges to facilitate primary wound healing. Twelve animals underwent amputation via a column of blasted sand (commercially purchased, nonsterile, coarse sand), while the other 12 underwent blast amputation with propelled, nonsterilized water. After wound closure, postoperative AP and lateral radiographs of the residual limb were obtained as baseline images. The rats were maintained for 24 weeks, and serial orthogonal radiographs of the residual limb were obtained at 10 days and at 4, 8, 12, 16, 20, and 24 weeks. Euthanasia was planned for all animals at 24 weeks.

## Blast Amputation Procedure and Monitoring

Inhaled isoflurane anesthesia was induced and maintained. Buprenorphine (0.05 mg/kg) and enrofloxacin (5 mg/kg) were administered subcutaneously for preemptive analgesia and prophylactic antibacterial coverage, respectively. The left hindlimb was cleared of hair with a clipper and cleansed with chlorhexidine and 70% isopropyl alcohol. Maintaining deep inhalation anesthesia by nose cone, the rat was positioned prone on a 2-inch-thick aluminum platform that featured a 2.5-inch hole at its center; the animal was tightly secured with industrial strength Velcro® (Velcro USA Inc, Manchester, NH, USA) (Fig. 1). The selected limb was positioned across the hole and centered at the desired amputation level with the use of silk suture and duct tape. The platform was located above a 2 foot × 2 foot × 2 foot steel tank filled with tap water or commercially purchased wet sand. An explosive charge (0.75 g of pentaerythritol tetranitrate) was submerged below the surface of the water or sand at a calibrated distance to provide an equivalent force at the injury site, directly beneath the center of the hole in the platform. Because of differences in mass of the blasted media, the standoff distance was adjusted to result in equivalent force transmission through the selected extremity. These adjustments were made by using test blasts of standard lead pencils to mimic rat femora and then confirming with cadaveric



**Fig. 1** The setup for blast amputation of the left hindlimb of a Sprague-Dawley rat is shown.

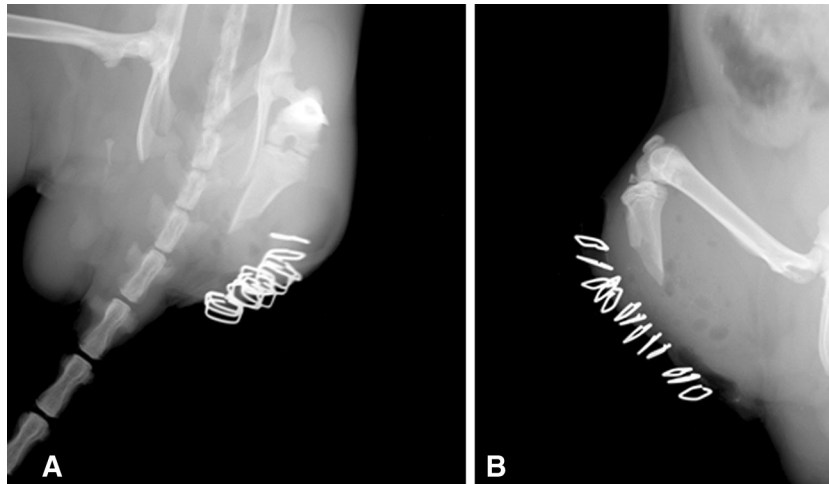
specimens (standoff distance of 1 inch and depth of buried explosive of 0.5 inch for water blasts compared with 0 inch and 0.25 inch for sand blasts). The explosive was detonated with a commercially available detonation box (FS-10 firing system, Reynolds Industries Inc, Los Angeles, CA, USA). The resulting chemical reaction created a large volume of hot, high-pressured gases that acted against the surrounding medium, accelerating the blasted medium upward at velocities approaching four times the speed of sound in air (Mach 4). The high velocities were converted into pressure on impact with the plate and the animal's exposed extremity. Pressures on the order of tens of thousands of pounds per square inch were absorbed by the limb, which was quickly and cleanly amputated [12]. The protective platform effectively shielded the animals from injury to internal organs.

After amputation, the animals were maintained on inhaled isoflurane anesthesia and transferred to a nearby sterile operating table. Modest char was observed on the soft tissues, and minimal blood loss occurred because of cauterization of the vessels from the high temperature and pressure of the blast. The wound was irrigated with 150 to 250 mL of a 40:1 saline: chlorhexidine solution with a bulb syringe. Only prominent bone spikes underwent débridement. Damaged muscle was inverted without débridement to allow a primary fascial closure with a running 4-0 Vicryl® suture (Ethicon; Novartis Animal Health US, Inc, Greensboro, NC, USA). The charred skin edges underwent sharp débridement to facilitate primary wound healing and were stapled and sealed with Histoacryl® tissue adhesive (B. Braun Corporation, Bethlehem, PA, USA). The animal was placed in a clean cage with warmed bedding and was monitored until awakening from anesthesia. Baseline orthogonal radiographs were obtained immediately after surgical closure (Fig. 2).

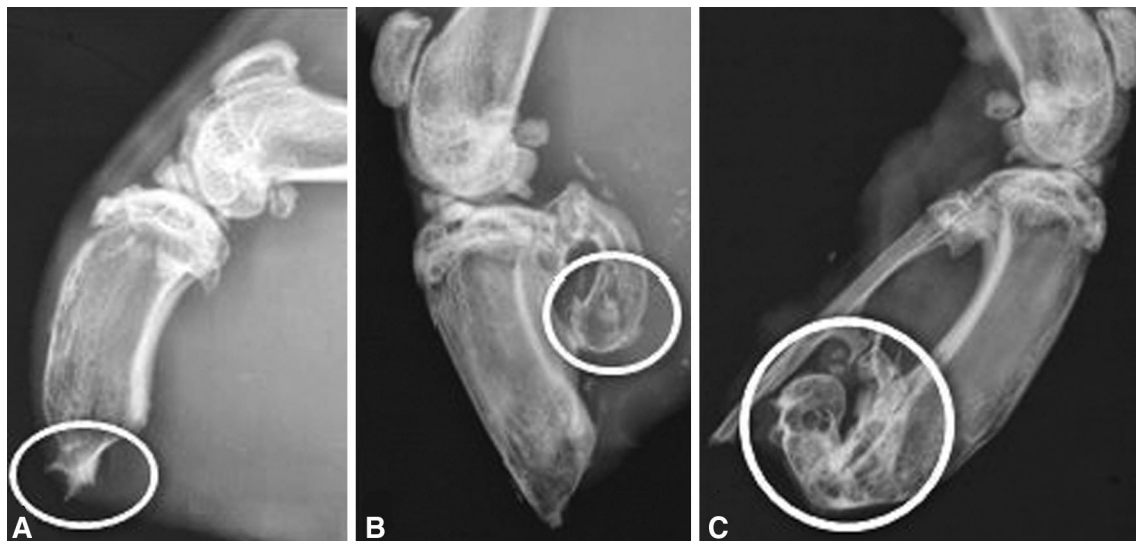
Animals received antibiotics (enrofloxacin, 5 mg/kg administered subcutaneously, twice daily) for 3 days per institutional guidelines. Analgesia was provided with buprenorphine, 0.05 mg/kg subcutaneously every 8 hours for 3 days and then every 12 hours for another 2 days after the procedure. Additional analgesia was available as indicated by physiologic signs of animal discomfort, but was not administered because the animals tolerated the procedure well.

## Animal Complications

One hindlimb amputation in the water-blasted group underwent revision for tibial overgrowth of ectopic bone with puncture through the skin 4 weeks after injury. The revision included minimal shortening of the remaining tibia, gentle irrigation, and reclosure. No signs of gross infection were evident. The animal ultimately had severe HO (Type



**Fig. 2A–B** (A) AP and (B) lateral view radiographs obtained immediately after blast of a residual hindlimb after blast amputation are shown.



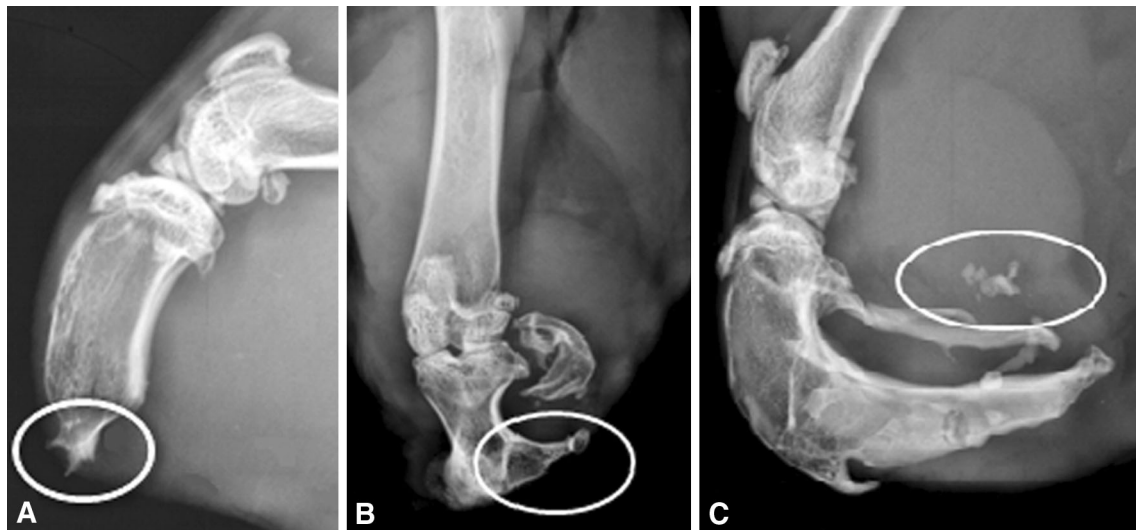
**Fig. 3A–C** The radiographs show examples of (A) mild, (B) moderate, and (C) severe heterotopic ossification in the hindlimbs of blast-injured rats.

3, unanimously graded by all three graders [JB, DEJ, DY]) develop at 24 weeks. Three rats that had undergone sand blasting had postoperative wound infections develop that underwent irrigation, débridement, and immediate reclosure. Two of them had persistent infections and were euthanized at 9 weeks; both had severe Type 3 HO by the time of euthanasia (unanimously graded). The other infection resolved, and the animal was euthanized at 24 weeks with only mild Type 1 HO (unanimously graded). All other animals survived for the planned period of 24 weeks without reoperation or other complications. No statistically significant difference was observed in infection rate between blast amputations made with water and those made with sand (0 of 12 compared with three of 12;  $p = 0.22$ ).

#### Data Collection and Statistical Analysis

After the animals were euthanized at 24 weeks, three independent graders (JB, DEJ, DY) reviewed the series of radiographs and assessed the severity of heterotopic bone as absent, mild, moderate, or severe based on a modification of the scale used by Potter et al. [18, 19] for human amputees. HO was considered to be mild if it measured less than 25% of the width of the tibial plateau on either the AP or lateral view radiograph, moderate if it measured 25% to 50%, and severe if it measured more than 50% (Fig. 3).

The ectopic bone was classified as one of three types. Type 1 was defined as bone growing contiguously with the residual limb while remaining in the normal bony configuration. Type 2 was defined as ectopic bone contiguous



**Fig. 4A–C** The radiographs show examples of (A) Type 1, (B) Type 2, and (C) Type 3 heterotopic ossification in the hindlimbs of blast-injured rats.

with the residual limb skeleton but outside the normal bony envelope. Type 3 was defined as ectopic bone originating in the surrounding soft tissues of the residual limb—not contiguous with the residual bony anatomy (Fig. 4).

The three graders independently evaluated the radiographs of all 24 animals and assessed the severity and type of ectopic bone at three distinct times: 8, 16, and 24 weeks. The graders were blinded to blast medium. Each severity grade of HO was assigned a corresponding numerical value (absent = 0, mild = 1, moderate = 2, severe = 3). When reviewers disagreed, the score assigned with greatest frequency was used. Similarly, Type 3 HO was declared if two of three graders identified a bony island.

Analysis of the data involved calculation of median HO severity and Mann-Whitney U tests to determine significant differences in severity. To statistically analyze type, groups were dichotomized into presence or lack of Type 3 bony islands and were assessed with Fisher's exact test. Significance was assessed at an  $\alpha$  level of 0.05, and all *p* value calculations were two-sided.

The Cronbach  $\alpha$  test was conducted to assess internal consistency among graders. For radiographic heterotopic bone severity, an overall  $\alpha$  statistic of 0.93 indicated excellent internal consistency among three graders at all times evaluated. For type of heterotopic bone (Type 1, 2, or 3), the Cronbach  $\alpha$  statistic was 0.78 (acceptable internal consistency).

## Results

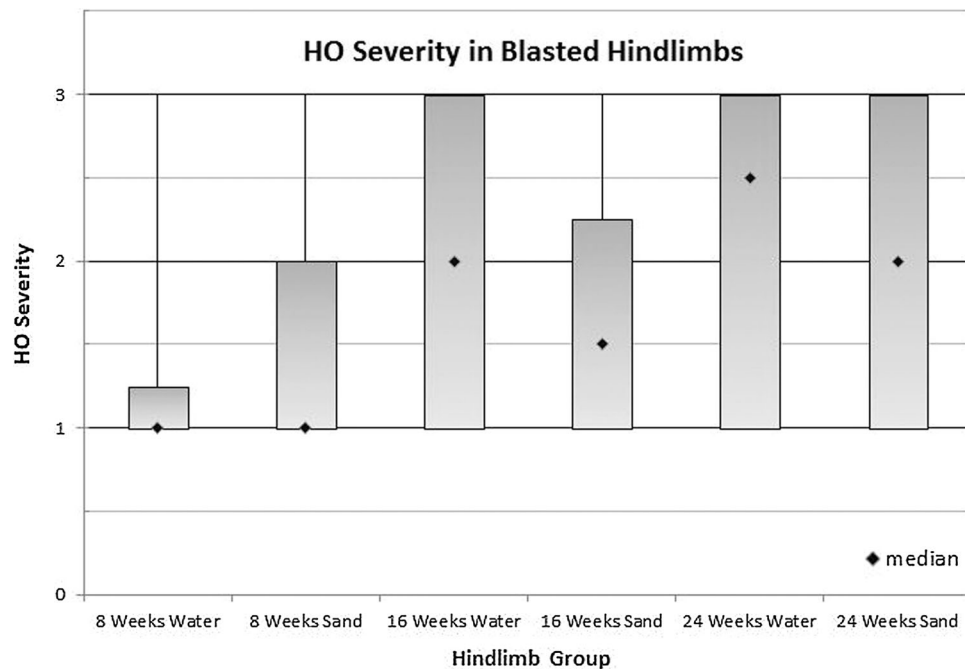
The severity of heterotopic bone formed in the blasted animals progressed with time in each experimental group.

At 8 weeks, animals that had been water blasted and sand blasted had a median severity of 1.0 (range, 1–3; difference of medians, 0;  $p = 0.56$ ). At 16 weeks, animals that had been water blasted had a median severity of 2.0, compared with 1.5 in animals that had been sand blasted (range, 1–3; difference of medians, 0.5;  $p = 0.67$ ) (Fig. 5). Ultimately, at 24 weeks, animals that had been water blasted had median severity of 2.5, compared with 2.0 in animals that had been sand blasted (range, 1–3; difference of medians, 0.5;  $p = 0.67$ ). No difference was observed in HO severity at any time.

Bony islands were observed frequently before euthanasia at 24 weeks regardless of the medium used. At 8, 16, and 24 weeks, there were six, nine, and 10 animals that had been water-blasted that were noted to have Type 3 HO. In animals that were sand blasted, there were seven, 10, and 11 animals with Type 3 HO at each respective time. No difference was observed in HO type at any time (six of 12 versus seven of 12,  $p = 1.00$ ; nine of 12 versus 10 of 12,  $p = 1.00$ ; and 10 of 12 versus 11 of 12,  $p = 1.00$ ).

## Discussion

Between 2001 and 2005, more than 3500 extremity wounds were recorded in the Joint Theater Trauma Registry. The injuries to US service members were evenly distributed between upper and lower extremities, and 75% were the result of explosive munitions [15, 16]. To further explore the phenomenon of ectopic bone formation occurring after blast amputation, we developed an animal model to replicate the process without addition of exogenous osteogenic agents. A previous study showed high survivability after



**Fig. 5** The median heterotopic ossification severity of each group of rats at three different times is shown. A progressive increase in the observed severity of heterotopic ossification occurred with time until euthanasia at 24 weeks. A severity score of 1 corresponds to mild

heterotopic ossification, whereas scores of 2 and 3 represent moderate and severe heterotopic ossification, respectively. The vertical lines depict the range of severity.

controlled blast amputation of a single extremity in a Sprague-Dawley rat model [23]. In the current study, the model showed that the blasted medium had no effect on either the severity or type of heterotopic bone that developed, disproving our hypothesis that sand blasting would result in intensified ectopic bone growth.

The model has some limitations but it consistently creates ectopic bone in the blasted extremity. Although typical amputation management involves extensive débridement of damaged soft tissue, we chose to invert damaged tissue without significant debulking to allow for more experimental consistency. Currently, to our knowledge, no literature exists to validate our model as a representation of HO in humans. However, the model is a realistic model of blast injury endured by service members during combat. Although larger animals (ie, rabbit and sheep models) may be better representatives of human HO formation, previous traumatic models using larger animals have had limited success [14, 22, 26, 27]. This model uses a realistic mechanism of injury and reliably induces heterotopic bone without exogenous growth factors. Current molecular and histologic studies are being conducted to validate this model as a true representation of the pathophysiology involved in human HO. With our severity scale and type classification, good consistency was noted among the graders. We identified some potential reasons for the disagreement that existed among reviewers. Regarding HO

type, the rats' fibulae typically shattered into many pieces, making it difficult to ascertain whether bone in the surrounding soft tissue represented fragments retained from initial injury or newly formed islands of ectopic bone. This limitation was mitigated by obtaining radiographs immediately after the blast. Despite these potential limitations, our radiographic classification scheme was reliably consistent among graders and is suitable for use with future experiments.

No difference in severity of HO was observed among amputated sand-blasted extremities compared with amputated water-blasted extremities. Perhaps with more animals in each group, we might have seen a difference between the two groups; however, pilot work showed that 12 animals are sufficient to detect statistically significant differences in heterotopic bone severity. We expected higher rates of infection and wound complications in the sand-blasted group because of greater contamination with incomplete débridement. We hypothesized that this would result in increased ectopic bone development secondary to general amplification of a local inflammatory response. Muscle injury and inflammation are critical initiators of HO because they induce expression of BMP. Mesenchymal stem cells respond to local BMPs and are induced to differentiate into osteoblasts, leading to new bone formation. The paracrine action of BMPs might account for observed differences in ectopic bone formation after local injury [2,

10, 13]. Despite this proposed mechanism of muscle trauma initiating heterotopic bone, we did not see a significant difference between our two experimental groups. Because we calibrated the force imparted to the limb by adjusting the blast standoff distance, it may be true that the rats' immune systems were not significantly upregulated in the sand-blasted group compared with the water-blasted group. Future biomolecular study is required to determine the cellular initiation of HO in our model.

The results of this study showed that there was no difference in the rate of formation of ectopic bony islands between the two experimental groups. We hypothesized that we would see more bony islands develop in the hindlimb muscle that was injured with sand blasting because of increased contamination and a possible difference in microscopic trauma. As with comparing severity of HO that formed, this proved not to be the case. Perhaps this implies that a systemic response is the key initiator of HO rather than a purely local phenomenon. Future research will be directed at identifying local and systemic factors associated with the formation of bony islands in the soft tissues.

Prophylactic antibiotics was provided to prevent the influence of infection on our data. Per institutional recommendations, 3 days of prophylaxis were provided. Despite this, three wound infections occurred in the sand-blasted group. The infection rate was not statistically greater than in the water-blasted group; however, our study was not powered to detect a threefold increase in infection rate between the two groups (80% power analysis revealed that 78 total animals would have been required to detect such a difference). The aim of our study was not to examine the role of infection on heterotopic bone formation. Despite two of the three infections progressing to rapid development of severe HO, the infections did not statistically contribute to our ultimate conclusion that the media used did not influence the severity or type of ectopic bone formation.

Our study suggests that the mechanism of amputation is the most important predictor of ectopic bone formation in an amputation setting. The medium used did not influence the development of increased ectopic bone. Further study is warranted to elucidate the biomolecular pathophysiology of this disease process. The model can be used in future studies with reliable creation of ectopic bone using available blasting media. We anticipate that future investigations will elucidate similarities between service members' wartime extremity injuries and our animal model. We hope to identify various surgical and medical techniques to reduce heterotopic bone formation, potentially leading to beneficial therapeutic implications.

**Acknowledgment** We thank Dori Kelly MA, University of Maryland School of Medicine, Department of Orthopaedics (Baltimore, MD, USA), for professional manuscript editing and figure formatting.

## References

- Baldwin K, Hosalkar HS, Donegan DJ, Rendon N, Ramsey M, Keenan MA. Surgical resection of heterotopic bone about the elbow: an institutional experience with traumatic and neurologic etiologies. *J Hand Surg Am.* 2011;36:798–803.
- Billings PC, Fiori JL, Bentwood JL, O'Connell MP, Jiao X, Nussbaum B, Caron RJ, Shore EM, Kaplan FS. Dysregulated BMP signaling and enhanced osteogenic differentiation of connective tissue progenitor cells from patients with fibrodysplasia ossificans progressiva (FOP). *J Bone Miner Res.* 2008;23:305–313.
- Brooker AF, Bowerman JW, Robinson RA, Riley LH Jr. Ectopic ossification following total hip replacement: incidence and a method of classification. *J Bone Joint Surg Am.* 1973;55:1629–1632.
- Cipriano CA, Pill SG, Keenan MA. Heterotopic ossification following traumatic brain injury and spinal cord injury. *J Am Acad Orthop Surg.* 2009;17:689–697.
- Covey DC. Blast and fragment injuries of the musculoskeletal system. *J Bone Joint Surg Am.* 2002;84:1221–1234.
- Covey DC. Combat orthopaedics: a view from the trenches. *J Am Acad Orthop Surg.* 2006;14(10 spec no):S10–S17.
- Forsberg JA, Pepek JM, Wagner S, Wilson K, Flint J, Andersen RC, Tadaki D, Gage FA, Stojadinovic A, Elster EA. Heterotopic ossification in high-energy wartime extremity injuries: prevalence and risk factors. *J Bone Joint Surg Am.* 2009;91:1084–1091.
- Genêt F, Jourdan C, Schnitzler A, Lautridou C, Guillemot D, Judet T, Poiraudreau S, Denormandie P. Troublesome heterotopic ossification after central nervous system damage: a survey of 570 surgeries. *PLoS One.* 2011;6:e16632.
- Hofmeister EP, Mazurek M, Ingari J. Injuries sustained to the upper extremity due to modern warfare and the evolution of care. *J Hand Surg Am.* 2007;32:1141–1147.
- Jackson WM, Aragon AB, Bulken-Hoover JD, Nesti LJ, Tuan RS. Putative heterotopic ossification progenitor cells derived from traumatized muscle. *J Orthop Res.* 2009;27:1645–1651.
- Kaplan FS, Glaser DL, Hebel N, Shore EM. Heterotopic ossification. *J Am Acad Orthop Surg.* 2004;12:116–125.
- Leiste UH, Fournay WL, Duff T. Experimental studies to investigate pressure loading on target plates. *Blasting and Fragmentation Journal.* 2013;7:99–126.
- Mavrogenis AF, Soucacos PN, Papagelopoulos PJ. Heterotopic ossification revisited. *Orthopedics.* 2011;34:177.
- Michelsson JE, Granroth G, Andersson LC. Myositis ossificans following forcible manipulation of the leg: a rabbit model for the study of heterotopic bone formation. *J Bone Joint Surg Am.* 1980;62:811–815.
- Murray CK, Hsu JR, Solomkin JS, Keeling JJ, Andersen RC, Ficke JR, Calhoun JH. Prevention and management of infections associated with combat-related extremity injuries. *J Trauma.* 2008;64(3 suppl):S239–251.
- Owens BD, Kragh JF Jr, Macaitis J, Svoboda SJ, Wenke JC. Characterization of extremity wounds in Operation Iraqi Freedom and Operation Enduring Freedom. *J Orthop Trauma.* 2007;21:254–257.
- Pape HC, Marsh S, Morley JR, Krettek C, Giannoudis PV. Current concepts in the development of heterotopic ossification. *J Bone Joint Surg Br.* 2004;86:783–787.
- Potter BK, Burns TC, Lacap AP, Granville RR, Gajewski DA. Heterotopic ossification in the residual limbs of traumatic and combat-related amputees. *J Am Acad Orthop Surg.* 2006;14(10 spec no):S191–197.
- Potter BK, Burns TC, Lacap AP, Granville RR, Gajewski DA. Heterotopic ossification following traumatic and combat-related

- amputations: prevalence, risk factors, and preliminary results of excision. *J Bone Joint Surg Am.* 2007;89:476–486.
20. Rumi MN, Deol GS, Bergandi JA, Singapuri KP, Pellegrini VD Jr. Optimal timing of preoperative radiation for prophylaxis against heterotopic ossification: a rabbit hip model. *J Bone Joint Surg Am.* 2005;87:366–373.
  21. Rumi MN, Deol GS, Singapuri KP, Pellegrini VD Jr. The origin of osteoprogenitor cells responsible for heterotopic ossification following hip surgery: an animal model in the rabbit. *J Orthop Res.* 2005;23:34–40.
  22. Schneider DJ, Moulton MJ, Singapuri K, Chinchilli V, Deol GS, Krenitsky G, Pellegrini VD Jr. The Frank Stinchfield Award: Inhibition of heterotopic ossification with radiation therapy in an animal model. *Clin Orthop Relat Res.* 1998;355:35–46.
  23. Tannous O, Griffith C, O'Toole RV, Pellegrini VD Jr. Heterotopic ossification after extremity blast amputation in a Sprague-Dawley rat animal model. *J Orthop Trauma.* 2011;25:506–510.
  24. Thomas BJ, Amstutz HC. Results of the administration of diphosphonate for the prevention of heterotopic ossification after total hip arthroplasty. *J Bone Joint Surg Am.* 1985;67:400–403.
  25. Vasileiadis GI, Sakellariou VI, Kelekis A, Galanos A, Soucacos PN, Papagelopoulos PJ, Babis GC. Prevention of heterotopic ossification in cases of hypertrophic osteoarthritis submitted to total hip arthroplasty: etidronate or indomethacin? *J Musculoskelet Neuronal Interact.* 2010;10:159–165.
  26. Walton M, Rothwell AG. Reactions of thigh tissues of sheep to blunt trauma. *Clin Orthop Relat Res.* 1983;176:273–281.
  27. Zaccalini PS, Urist MR. Traumatic periosteal proliferations in rabbits: the enigma of experimental myositis ossificans traumatica. *J Trauma.* 1964;4:344–357.

**Failure of Indomethacin and Radiation to Prevent Blast-Induced Heterotopic Ossification:  
An Animal Model in the Sprague Dawley Rat**

Astor D Robertson, MBBS\*, Thao P Nguyen, MD\*, David E Jaffe, MD\*, Robert Homes, MD^, E. Lex Hanna MD^, Juong Rhee, PhD<sup>@</sup>, William B Fourney, PhD<sup>#</sup>, Joseph P. Stains, PhD\*, and Vincent D Pellegrini, Jr, MD^

University of Maryland School of Medicine, Departments of Orthopaedics\* and Radiation Oncology<sup>@</sup>; University of Maryland, Department of Mechanical Engineering<sup>#</sup>; and the Medical University of South Carolina, Department of Orthopaedics^

Work performed at the University of Maryland and the Medical University of South Carolina

This work was supported by a grant from the Department of Defense; Congressionally Directed Medical Research Program, Peer Reviewed Orthopaedic Research Program Contract # WB1XWH-10-1-0975

Corresponding Author  
Vincent D. Pellegrini, Jr, MD  
John A. Siegling Professor and Chair  
Department of Orthopaedics  
Medical University of South Carolina  
96 Jonathan Lucas Street, CSB 708, MSC 622  
Charleston, SC 29425

## ABSTRACT

**Background:** Heterotopic ossification in the residual limb following blast amputation is a known morbidity in soldiers who survive such high-energy trauma. Level 1 clinical studies have demonstrated the efficacy of prophylactic non-steroidal anti-inflammatory drugs and low-dose external beam irradiation to prevent heterotopic ossification following total hip arthroplasty and surgical treatment of acetabular fractures in civilian practice. However, the effectiveness of these prophylactic regimens after high-energy blast amputation has not been assessed. We set out to investigate the effectiveness of indomethacin and external beam irradiation in the prevention of ectopic bone formation after extremity blast amputation in a rat model.

**Methods:** Thirty-six Sprague-Dawley rats underwent hind limb blast amputation via a column of propelled water following detonation of a submerged explosive. All wounds were irrigated with a 40:1 saline to 2% chlorhexidine solution and underwent primary closure. The indomethacin group (n=12) received oral medication at a dose of 3mg/kg for 10 days starting on post-operative day 1. The irradiation group (n=12) received a single dose of 8Gy to the residual limb on post-operative day 3. A third control group (n=12) received neither indomethacin nor irradiation postoperatively. All animals were followed with serial AP and lateral radiographs until planned euthanasia at 24 weeks. Three independent graders evaluated the 24-week radiographs to quantitatively and qualitatively assess ectopic bone formation in the residual limb using a modified Potter scale.

**Results:** The mean heterotopic ossification severity score was 1.5, 1.14, and 1.97 in the control, indomethacin, and irradiation groups, respectively. The qualitative assessment of ectopic bone type was scored as 1.5, 1.47, and 2.12 in the control, indomethacin, and irradiation group respectively. Kruskal-Wallis one-way analysis of variance revealed no significant differences in heterotopic ossification severity or type between either of the treatment groups and controls.

**Conclusion:** While pre-emptively administered indomethacin and external beam radiation have demonstrated efficacy in the prevention of heterotopic ossification after hip surgery in civilian practice, these interventions were not shown to be effective following high-energy blast amputation in a rat model. This observation may suggest a different pathogenesis of heterotopic ossification in this setting, or might rather be indicative of an inciting stimulus of such magnitude that overwhelms conventional prophylactic regimens.

**Clinical Relevance:** Heterotopic ossification following high energy blast amputation in the battle theater will likely require novel approaches to prevention and management compared to those proven to be effective in civilian practice after hip arthroplasty and acetabular fracture repair.

## **INTRODUCTION**

Heterotopic ossification in the residual limb following high energy blast amputation is a known morbidity in soldiers surviving such high energy trauma during recent war conflicts. With the advent of more advanced weaponry and explosives producing increased blast forces, more extensive soft tissue injuries have been observed in combatants of recent military conflicts. Concurrent with the increasing energy delivered by explosives, substantial improvements in body armor and emergent care on the battlefield have been responsible for the increased survival of soldiers following these severe injuries which were previously most often fatal. In recent conflicts, where improvised explosive devices and rocket propelled grenades were the preferred weapons, early 70-80% of service personnel suffered extremity blast injuries.<sup>1-3</sup>

In their analysis of more than 350 traumatic and combat-related amputations treated at military medical centers between 2001 and 2005, Potter et al reported a 63% prevalence of heterotopic ossification in the residual limbs following extremity blast amputations.<sup>1</sup> This observation is both problematic and clinically relevant given that heterotopic ossification may cause considerable residual limb pain in addition to muscle and skin breakdown. Each of these problems may necessitate multiple revision surgeries and severely compromise prosthetic fitting and practical functional use.<sup>4-10</sup> A high energy blast, rather than a projectile or blunt mechanism of injury, and a final amputation level within the initial zone of injury have been identified as risk factors for development of heterotopic ossification. Indeed, 80% of amputees who sustained a blast injury and had final amputation levels within the zone of injury demonstrated clinically meaningful degrees of heterotopic ossification in the residual limb.<sup>1</sup>

Several Level 1 clinical studies have demonstrated the efficacy of pre-emptive administration of non-steroidal anti-inflammatory drugs or low-dose external beam irradiation to prevent heterotopic ossification following total hip arthroplasty and surgical treatment of acetabular fractures.<sup>2,12-18</sup> Both of these regimens have been shown to have comparable efficacy in civilian practice,<sup>16,18</sup> but neither has been studied in the setting of high energy blast trauma in the battlefield.

Previous work has led to the establishment of a blast-amputation animal model which reliably produces heterotopic bone without the addition of any exogenous osteogenic agents.<sup>42</sup> With this model, we aimed to investigate the effect of nonsteroidal anti-inflammatory drugs and external beam radiation on the mitigation of ectopic bone formation in the blast-amputated extremity. We hypothesized that one or both of these prophylactic regimens would optimize wound care protocols in the battlefield and limit or prevent the heterotopic ossification in the residual limb.

## **MATERIALS AND METHODS**

All procedures in this study were performed under a protocol reviewed and approved by the Institutional Animal Care and Use Committee at the University of Maryland School of Medicine

as well as the Animal Care and Use Review Office of the United States Army Medical Research and Materiel Command. This work was funded by the Congressionally Directed Medical Research Program of the Department of Defense under contract # WB1XWH-10-1-0975.

A total of 36 male Sprague-Dawley rats aged sixteen to eighteen weeks old, and weighing approximately 400 g were used in this study. Each animal underwent a left hind limb blast amputation under a well-established experimental protocol. Three groups of 12 animals allowed for systematic study of the specific interventions; Group 1 (N=12) served as controls, Group 2 (N=12) received oral indomethacin; and Group 3 (N=12) underwent radiation treatment after the blast procedure.

### General Animal Preparation

Anesthesia was induced with isoflurane at 4% in an induction chamber, and maintained with 2-3% inhaled isoflurane via a nose cone. Once sedated, an ocular protective lubricant was applied bilaterally. The left hind limb and ipsilateral side of lower back and abdomen were cleared of hair with an electric clipper and cleansed thrice with alternating solutions of betadine scrub and 70% isopropyl alcohol. Buprenorphine (0.05 mg/kg) and enrofloxacin (5 mg/kg) were administered subcutaneously for preemptive analgesia and prophylactic antibacterial coverage, respectively. Preemptive administration of 6 to 10 mL of warmed 0.9% normal saline was provided subcutaneously for volume resuscitation in anticipation of hemorrhage related to the blast amputation trauma.

### Extremity Blast Amputation

Maintaining deep inhalation anesthesia by nose cone, the rat was positioned prone and tightly secured with industrial strength Velcro on a 2-inch-thick aluminum platform that features a 2.5-inch hole in its center. The left hind limb was held across the hole, centered at the desired amputation level through the mid-tibia, with the use of a silk suture and duct tape. The platform was located above a 2 foot by 2 foot by 2 foot steel tank filled with tap water. An explosive (0.75 gram of pentaerythritol tetranitrate) was submerged 0.5 inch below the surface of the water, directly beneath the center of the hole in the platform. (Figure 1) The explosive was detonated using a commercially available detonation box. The resulting chemical reaction creates a large volume of hot, high-pressure gases which act against the surrounding water, and accelerate it upwards at velocities approaching four times the speed of sound in air (Mach 4). These very high velocities were converted into pressure when the propelled water impacted both the plate and the animal's exposed extremity. Pressures on the order of tens of thousands of pounds per square inch were absorbed by the limb, which was quickly and cleanly amputated.

### Post-blast Wound Care

Following amputation, the animals were immediately transferred to an adjacent sterile operating table over an insulated heating pad while maintained on inhaled isoflurane anesthesia via nose cone. Minimal blood loss was observed, presumably due to cauterization of the vessels from the high temperature and pressure of the blast. The traumatic wounds were manually irrigated with 250mL of a 40:1 normal saline: 2% chlorhexidine solution with a 50mL bulb syringe. The amputated bone was examined and sharp edges were filed and beveled or trimmed with a rongeur, as necessary, to facilitate closure. No muscle was debrided. Rather, the muscle in the residual limb was inverted over the edge of the bone and closed with a running 4-0 Vicryl suture in the fascia to ensure adequate soft tissue coverage. The charred skin edges were conservatively but sharply debrided to facilitate primary wound healing. The skin was closed with staples and sealed with Histoacryl tissue adhesive (B. Braun Corporation, Bethlehem, PA).

### Post-Procedural care

Each animal was placed in a separate clean recovery cage with fresh bedding and an isothermal heating pad under the bedding, and closely monitored for signs of distress during emergence from anesthesia. Animals received antibiotics (Enrofloxacin, 5 mg/kg subcutaneously twice a day) for a total of three days, except for the control group which only received one dose at 12 hours post-operatively. Analgesia with Buprenorphine (0.05 mg/kg subcutaneously thrice daily) was provided for five days for the blast animals and three days for the controls. All animals were monitored twice daily for the first three days, then daily for five days, and then at least twice a week until sacrifice for weight changes, general appearance, activity level, breathing patterns and rates, feeding and excretion, ambulation, and incision site changes. Additional analgesia was provided as dictated by physiological signs of animal discomfort.

### Heterotopic Ossification Prophylaxis Interventions

Non-steroidal anti-inflammatory drug: Starting on the first post-operative day, Group 2 animals received a 10 day course of orally administered indomethacin suspension at a dose of 3 mg/kg once daily via syringe feeding (Fig. 2).

External beam irradiation: On post-operative day 3, all animals assigned to Group 3 received external beam radiation. Anesthesia was induced as previously described with isoflurane at 4% in an induction chamber. Thereafter the animals were transferred and secured with tape on a custom fabricated platform, where maintenance anesthesia was administered via a nose cone at 1.5-2.5% isoflurane. The platform served as a customized irradiation apparatus, and was fitted with quarter-inch thick lead and a 1.5 X 1.5 inch aperture to restrict irradiation to only the amputated residual limb. A PANTAX X-ray unit operated at 250kvp was used to deliver a single dose of 8Gy from below the protective metallic shield through the aperture (Fig. 3).

## Outcome Assessment

Modeled after a prior pilot study (Tannous *et al*), the radiographic presence of heterotopic bone in the residual limb was the primary outcome measure. The animals were imaged with orthogonal views on a small animal digital Faxitron radiography machine (Faxitron X-Ray LLC, Lincolnshire, IL) immediately post-op, at 10days, and every 4 weeks thereafter until euthanasia at 6 months. Assessment of heterotopic ossification was modified from the method of Potter et al as originally described in humans<sup>1</sup>. *Severity* of ectopic bone was quantified as absent (0), mild (1), moderate (2), or severe (3). Ectopic bone *type* was qualified as type 1, within the normal bony contour; type 2, contiguous with the residual osseous skeleton but outside the normal bony envelop; or type 3, distinct bony islands.in the soft tissue. Each radiograph at each time point was assessed by three independent graders on three separate occasions in random sequence. (Table 1, Figures 4 and 5).

*Statistics.* Fleiss' kappa statistic was used to evaluate the consistency and reliability of agreement between the three raters' grading of radiographs for ectopic bone type and severity. Kruskal-Wallis one-way analysis of variance was used to assess the statistical significance of the observed differences in ectopic bone formation in the controls and two treatment groups.

## **RESULTS**

Of the 36 animals that underwent left hind limb blast amputation, all survived the procedure without untoward event. The animals typically ambulated in a tripod configuration almost immediately upon recovery from anesthesia, and returned to their pre-injury baseline activities within one week from the procedure. One animal assigned to the irradiation group died two weeks following the procedure of unknown causes and was not replaced.

Five animals, two in each of the treatment intervention groups and one control animal, required at least one surgical wound revision for what appeared clinically to be either wound dehiscence or protrusion of the bony skeleton at approximately four weeks post operatively. In each case, the revision procedure included minimal shortening of the tibia with a rongeur, copious manual irrigation with sterile saline by syringe, and reclosure of the fascial layer with suture and the skin with staples. Appropriate analgesia and prophylactic antibiotic coverage was provided; no wound cultures were suggestive of infection. Of these animals, two developed evidence of marked heterotopic ossification. Additionally, one animal each in the control and indomethacin groups, and two animals in the irradiation group developed persistent fungating granuloma-like lesions in the residual limb; each exhibited radiographic evidence of severe underlying heterotopic ossification. None of these four animals underwent surgical stump revision at any time.

In total, 9 of 35 (25.7%) animals exhibited wound complications four or more weeks after the blast procedure, following removal of the incisional staples at two weeks after wound healing

was clinically apparent. Six of those nine animals demonstrated severe underlying heterotopic ossification in the residual limb on radiographs.

The mean heterotopic ossification *severity* score was 1.5, 1.14, and 1.97 in the control, indomethacin, and irradiations groups, respectively (Fig. 9). The qualitative assessment scores of ectopic bone *type* were 1.5, 1.47, and 2.12 in the control, indomethacin, and irradiation groups, respectively (Fig. 10). Fleiss' kappa statistic for the percent of overall inter-observer agreement of heterotopic ossification scores for *severity* and *type* was calculated as 0.41 and 0.37, respectively. This correlates with a fair to moderate strength of agreement between observers. Kruskal-Wallis one-way analysis of variance revealed no statistical significance in heterotopic ossification scores for *severity* or *type* between either treatment group and controls.

## DISCUSSION

Following traumatic extremity amputation, the military places considerable emphasis on aggressive limb salvage, preservation of residual limb length, and ultimate restoration of function whenever reasonably possible. Heterotopic ossification complicating high-energy blast amputation threatens the speed and completeness of functional recovery following these injuries. Once clinically apparent, treatment options are limited and restricted to surgical excision of the offending bone rather than prevention<sup>11</sup>. Investigation of the effects of blast injury on the musculoskeletal system, specifically the prevention of heterotopic ossification in the residual limb of blast amputees, is a logical priority in the care of war-wounded veterans.

In civilian practice where heterotopic ossification commonly complicates hip surgery, local stem cells are committed to progress down a bone-forming cell line at approximately five days post-injury or surgery. These cells produce ectopic bone within otherwise normal muscle<sup>24-30</sup>. External beam irradiation and non-steroidal anti-inflammatory medications have been shown to be effective in prevention of heterotopic ossification in humans, but critical to their efficacy is initiation of therapy within 5 days of injury, prior to stem cell commitment to osteogenic precursors. Radiation therapy is thought to inhibit proliferation and differentiation of cells that may contribute to heterotopic ossification while non-steroidal anti-inflammatory medications diminish the local and systemic inflammatory response and prevent extracellular matrix mineralization<sup>11</sup>. Administration of single dose of radiation within 24 hours preoperatively or 72 hours postoperatively<sup>31,32</sup>, or indomethacin for two weeks immediately following operation, offer reliable prophylaxis.<sup>33,34</sup> In animals, the minimum effective prophylaxis dose is 700-800cGy or indomethacin 3mg/kg<sup>35-41</sup>; however, these doses were based on animal models that involved hip surgery or exogenous osteogenic agents to induce heterotopic ossification.

Studies in military personnel who sustained high-energy war-time injuries demonstrated significantly more muscle derived connective tissue progenitor cells per gram of tissue than non-injured controls<sup>19</sup>. Despite the increased quantities of progenitor cells committed to the lineage of a connective tissue phenotype, these cells were not preferentially committed to any one single

tissue type.<sup>19</sup> Jackson *et al* confirmed this by demonstrating the pluripotency of muscle-derived progenitor cells present in extremity blast wounds, and their potential to differentiate into osteoblasts, chondrocytes, and adipocytes<sup>20-22</sup>. This finding forms the basis of most research into prevention of ectopic bone formation by diverting this osteogenic capacity in favor of other more favorable mesenchymal phenotypes such as muscle, nerve or fat<sup>23</sup>.

The alarmingly high prevalence of combat-related blast-induced heterotopic ossification has important clinical consequences. Heterotopic bone, once formed, is more commonly meaningful in the residual limb of blast amputees than it is in civilian practice after hip surgery. While active research at military and civilian institutions have led to better insight into trauma-induced heterotopic ossification, our understanding is still rudimentary. Factors thought to significantly contribute to the uniqueness of combat-related ectopic bone formation include dysregulation of the systemic and local inflammatory system, a blast mechanism of injury, delayed wound healing, and bacterial colonization. The absence of any animal studies or human clinical trials evaluating the effectiveness of known methods of prophylaxis of civilian heterotopic ossification in the military setting further challenges the management of blast amputations with this complication.

This study, performed in a well established animal model, provides important but disheartening insight into the clinical management of heterotopic ossification after blast-induced extremity amputation. A strong correlation emerged between the development of chronic granuloma-like lesions (clinically manifest as non-healing ulcers) and the aggressive formation of underlying ectopic bone. Of the four animals with such lesions all developed severe heterotopic ossification. Moreover, the five other animals who underwent revision surgery on the residual limb all did so more than four weeks following the blast procedure after clinical healing of the wound. In aggregate, more than one quarter of animals experienced wound complications and each was associated with severe underlying heterotopic ossification. This lends credence to the observation that delayed wound healing plays an important role in the clinical management of combat-related heterotopic ossification in residual limbs.

Both qualitative and quantitative assessment of heterotopic ossification *severity* and *type* failed to reveal a statistically significant difference between the control and two intervention groups using the Kruskal-Wallis one-way analysis of variance. Neither external beam irradiation nor indomethacin, both proven interventions for the prevention of heterotopic ossification after hip surgery in the civilian setting, demonstrated any hint of mitigation of this bone forming process in the high-energy blast setting. The Fleiss' kappa statistic for the percent of overall inter-observer agreement (Po) for assessment of heterotopic ossification *severity* and *type*, 0.41 and 0.37 respectively, are indicative of fair to moderate agreement. The low inter-observer agreement is likely a reflection of the subjectivity of the grading scale based on plain radiographs.

The primary limitation of this study lies in the subjective grading system used to assess severity and type of heterotopic ossification in the residual limbs. The use of two-dimensional x-rays was

affordable and easily accessible but less than completely reliable. While a more objective quantitative grading system may have potentially eliminated discordant inter-observer grading and revealed a statistical difference between study groups, there were no clinically meaningful differences between groups based on either plain radiographs or observed wound complications. A quantitative measurement system of three-dimensional bone volume for assessing heterotopic ossification based on CT scans is needed for small animal studies<sup>43</sup>.

While indomethacin and external beam radiation administered soon after traumatic insult have demonstrated efficacy in the prevention of heterotopic ossification in civilian practice after hip surgery, these interventions did not alter the development of heterotopic ossification in the setting of blast-induced amputation in an animal model. This result may be indicative of either an inciting stimulus that overwhelms conventional prophylactic interventions or the existence of a different pathway of osteogenesis that is refractory to these modalities, or both. Further research is warranted to elucidate a better understanding of the pathogenesis of blast-induced heterotopic ossification. In the interim, nontraditional methods of treatment, such as sacrifice of limb length and amputation above the zone of injury, may be required to mitigate the process of ectopic bone formation after blast injury in order to facilitate rapid and complete rehabilitation.

## REFERENCES

1. Potter BK, Burns TC, Lacap AP, Granville RR, Gajewski DA. Heterotopic ossification following traumatic and combat-related amputations: prevalence, risk factors, and preliminary results of excision. *J Bone Joint Surg Am.* 2007; 89:476-86.
2. Potter BK, Burns TC, Lacap AP, Granville RR, Gajewski D. Heterotopic ossification in the residual limbs of traumatic and combat-related amputees. *J Am Acad Orthop Surg.* 2006; 14 Suppl 10:S191-7.
3. Ahmed SI, Burns TC, Landt C, Hayda R. Heterotopic ossification in high grade open fractures sustained in combat: risk factors and prevalence. *J Orthop Trauma.* 2013 Mar; 27(3):162-9
4. Henrot P, Stines J, Walter F, et al. Imaging of the painful lower limb stump. *Radiographics.* 2000; 20:S2192S235
5. Salawu A, Middleton C, Gilbertson A, Kodavali K, Neumann V. Stump ulcers and continued prosthetic limb use. *Prosthet Orthot Int.* 2006; 30:279–285.
6. Covey DC. Combat orthopaedics: a view from the trenches. *J Am Acad Orthop Surg.* 2006; 14:S102S17.
7. Owens BD, Wenke JC, Svoboda SJ, et al. Extremity trauma research in the United States Army. *J Am Acad Orthop Surg.* 2006; 14:S372S40.
8. Andersen RC, Frisch HM, Farber GL, et al. Definitive treatment of combat casualties at military medical centers. *J Am Acad Orthop Surg.* 2006;14:S242S31
9. Potter BK, Burns TC, Lacap AP, Granville RR, Gajewski D. Heterotopic ossification in the residual limbs of traumatic and combat-related amputees. *J Am Acad Orthop Surg.* 2006;14 Suppl 10:S191-7.
10. Andersen R, Davis S, Scoville C. Rehabilitation of military amputees: from injury to independence. *Orthopedics.* 2008 Oct;31(10)
11. Pape HC, Marsh S, Morley JR, Krettek C, Giannoudis PV. Current concepts in the development of heterotopic ossification. *J Bone Joint Surg Br.* 2004;86:783-7.
12. Fransen M, Neal B: Non-steroidal anti-inflammatory drugs for preventing heterotopic bone formation after hip arthroplasty. *Cochrane Database Syst Rev* 2004;3:CD001160.
13. Pellegrini VD Jr, Konski AA, Gastel JA, Rubin P, and Evarts CM. Prevention of heterotopic ossification with irradiation after total hip arthroplasty: radiation therapy with a single dose of eight hundred centigray administered to a limited field. *J Bone Joint Surg [Am]* 1992; 74-A:186–200.
14. Gregoritch SJ, Chadha M, Pelligrini VD, Rubin P, Kantorowitz DA: Randomized trial comparing preoperative versus postoperative irradiation for prevention of heterotopic ossification following prosthetic total hip replacement: Preliminary results. *Int J Radiat Oncol Biol Phys* 1994; 30:55-62.

15. Matta JM, Siebenrock KA: Does indomethacin reduce heterotopic bone formation after operations for acetabular fractures? A prospective randomized study. *J Bone Joint Surg Br* 1997; 79:959-963.
16. Moore KD, Goss K, Anglen JO: Indomethacin versus radiation therapy for prophylaxis against heterotopic ossification in acetabular fractures: A randomized, prospective study. *J Bone Joint Surg Br* 1998; 80:259-263.
17. Burd TA, Lowry KJ, Anglen JO: Indomethacin compared with localized irradiation for the prevention of heterotopic ossification following surgical treatment of acetabular fractures. *J Bone Joint Surg Am* 2001; 83:1783-1788.
18. Pakos EE, Ioannidis JP: Radiotherapy vs. nonsteroidal anti-inflammatory drugs for the prevention of heterotopic ossification after major hip procedures: A meta-analysis of randomized trials. *Int J Radiat Oncol Biol Phys* 2004; 60:888-895.
19. Davis TA, O'Brien FP, Anam K, et al. Heterotopic ossification in complex orthopaedic combat wounds: quantification and characterization of osteogenic precursor cell activity in traumatized muscle. *J Bone Joint Surg [Am]* 2011; 93-A:1122-1131.
20. Jackson WM, Aragon AB, Bulken-Hoover JD, Nesti LJ, Tuan RS. Putative heterotopic ossification progenitor cells derived from traumatized muscle. *J Orthop Res* 2009; 27:1645-1651.
21. Jackson WM, Aragon A, Djouad F, et al. Mesenchymal progenitor cells derived from traumatized human muscle. *J Tissue Eng Regen Med* 2009; 3:129-138.
22. Nesti LJ, Jackson WM, Shanti RM, et al. Differentiation potential of multipotent progenitor cells derived from war-traumatized muscle tissue. *J Bone Joint Surg [Am]* 2008; 90-A:2390-2398
23. Alfieri KA, Forsberg JA, Potter BK. Blast injuries and heterotopic ossification. *Bone Joint Res* 2012; 1:174-9
24. Bosch, P., et al. Osteoprogenitor cells within skeletal muscle. *J Orthop Res* 2000; 18(6): 933-44.
25. Cao, B. and Huard, J. Muscle-derived stem cells. *Cell Cycle* 2004; 3(2):104-7.
26. Chalmers J, Gray DH, Rush J. Observations on induction of bone in soft tissues. *J Bone Joint Surg* 1975B; 57:36-45
27. Gazzero, E, Canalis, E. Bone morphogenetic proteins and antagonists. *Rev Endo Met Dis* 2006;7:51-65.
28. Lounev, VY et al. Identification of progenitor cells that contribute to heterotopic skeletogenesis. *J Bone Joint Surg Am* 2009; 91:652-63.
29. Reddi, A.H. Bone morphogenetic proteins, bone marrow stromal cells, and mesenchymal stem cells. Maureen Owen revisited. *Clin Orthop Relat Res* 1995; (313): 115-9.
30. Urist, M.R. Bone: formation by autoinduction. *Science* 1965; 150(698): 893-9
31. Healy WL, Lo TC, DeSimone AA, Rask B, Bernard A: Single-dose irradiation for the prevention of heterotopic ossification after total hip arthroplasty: A comparison of doses

- of five hundred and fifty and seven hundred centigray. *J Bone Joint Surg Am* 1995; 77:590-595.
32. Seegenschmiedt MH, Makoski HB, Micke O, et al: Radiation prophylaxis for heterotopic ossification about the hip joint: A multicenter study. *Int J Radiat Oncol Biol Phys* 2001; 51:756-765.
  33. Kjaersgaard-Andersen P, Nafei A, Teichert G, et al: Indomethacin for prevention of heterotopic ossification: A randomized controlled study in 41 hip arthroplasties. *Acta Orthop Scand* 1993; 64:639-642.
  34. Sell S, Phillips O, and Handel M: Nodifference between two doses of diclofenac in prophylaxis of heterotopic ossifications after total hip arthroplasty. *Acta Orthop Scand* 2004; 75:45-49.
  35. Schneider DJ, Moulton MJ, Singapuri K, Chinchilli V, Deol GS, Krenitsky G, Pellegrini VD Jr. The Frank Stinchfield Award. Inhibition of heterotopic ossification with radiation therapy in an animal model. *Clin Orthop Relat Res.* 1998 Oct; (355):35-46.
  36. Pohl F, Hassel S, Nohe A, Flentje M, Knaus P, Sebald W, Koelbl O. Radiation-induced suppression of the Bmp2 signal transduction pathway in the pluripotent mesenchymal cell line C2C12: an in vitro model for prevention of heterotopic ossification by radiotherapy. *Radiat Res.* 2003 Mar; 159(3):345-50.
  37. Persson PE, Sisask G, Nilsson O. Indomethacin inhibits bone formation in inductive allografts but not in autografts: studies in rat. *Acta Orthop.* 2005 Aug; 76(4):465-9.
  38. Nilsson OS, Persson PE, Ekelund A. Heterotopic new bone formation causes resorption of the inductive bone matrix. *Clin Orthop Relat Res.* 1990 Aug; (257):280-5.
  39. Nilsson OS, Bauer HC, Brosjö O, Törnkvist H. A comparison of indomethacin and diclofenac in the inhibition of experimental heterotopic new bone formation. *Int Orthop.* 1987; 11(3):283-7.
  40. Törnkvist H, Bauer FC, Nilsson OS. Influence of indomethacin on experimental bone metabolism in rats. *Clin Orthop Relat Res.* 1985 Mar; (193):264-70.
  41. Coventry MB, Scanlon PW: The use of radiation to discourage ectopic bone: Anine-year study in surgery about the hip. *J Bone Joint Surg Am* 1981;63:201-208
  42. Tannous O, Griffith C, O'Toole RV, Pellegrini VD. Heterotopic ossification after Extremity blast amputation in a Sprague-Dawley rat animal model. *J Orthop Trauma* 2011; 25:506-510.
  43. Isaacson BM, Stinstra JG, Macleod RS, Pasquina PF, Bloebaum RD. Developing a Quantitative Measurement System for Assessing Heterotopic Ossification and Monitoring the Bioelectric Metrics from Electrically Induced Osseointegration in the Residual Limb of Service Members. *Ann Biomed Eng.* 2010 September; 38(9): 2968–2978.

## Figures

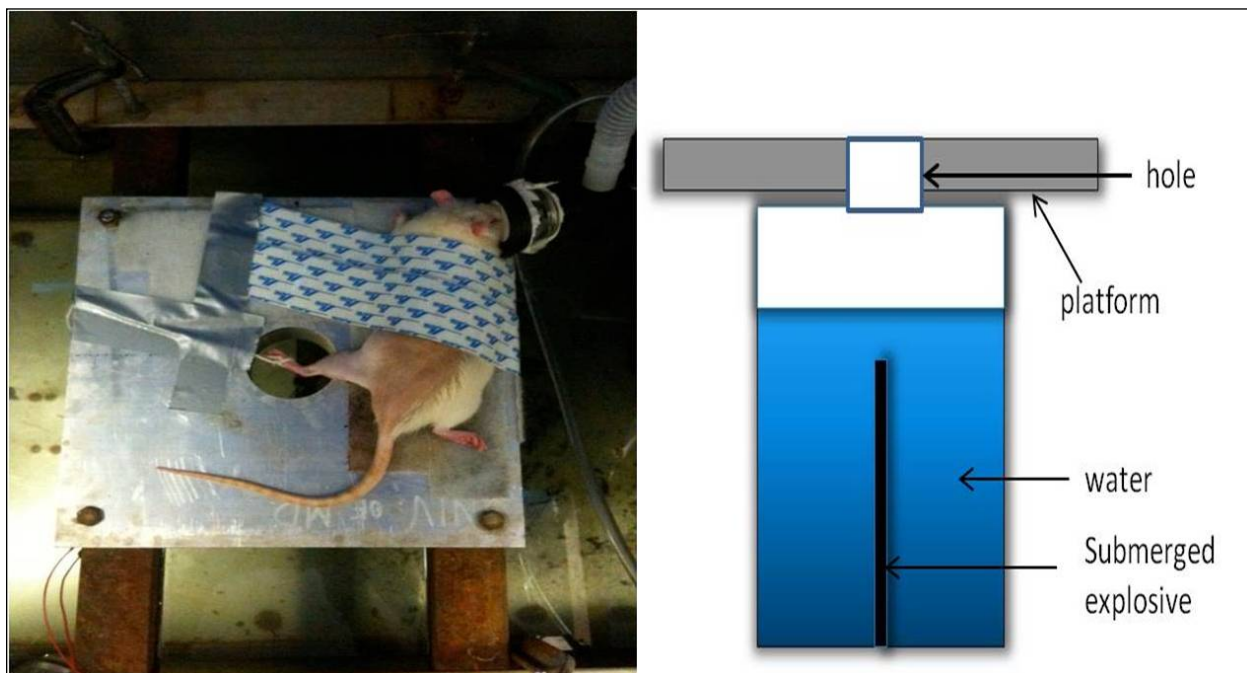


Figure 1. Standard setup for blast amputation of left hind limb of a Sprague-Dawley rat.

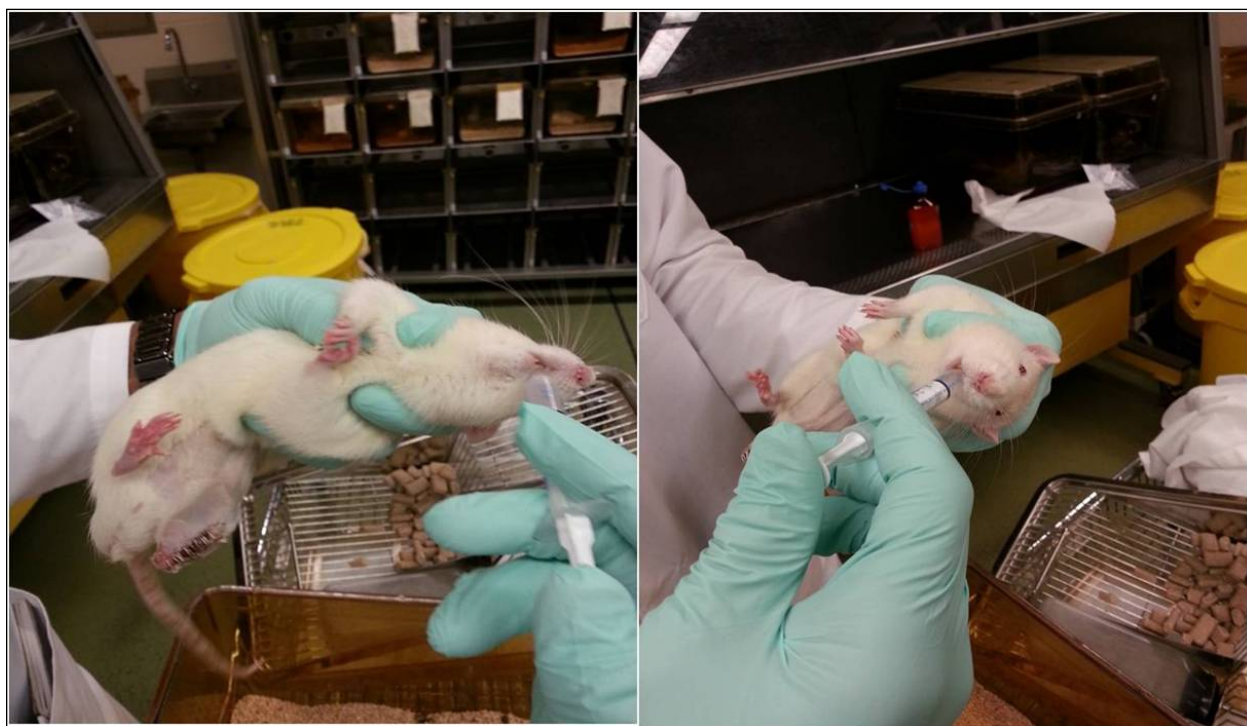


Figure 2. Administration Indomethacin suspension via oral syringe feeding




Figure 3. PANTAX Xray unit used to deliver single dose of 8Gy to the amputated stump on post-operative day 3.

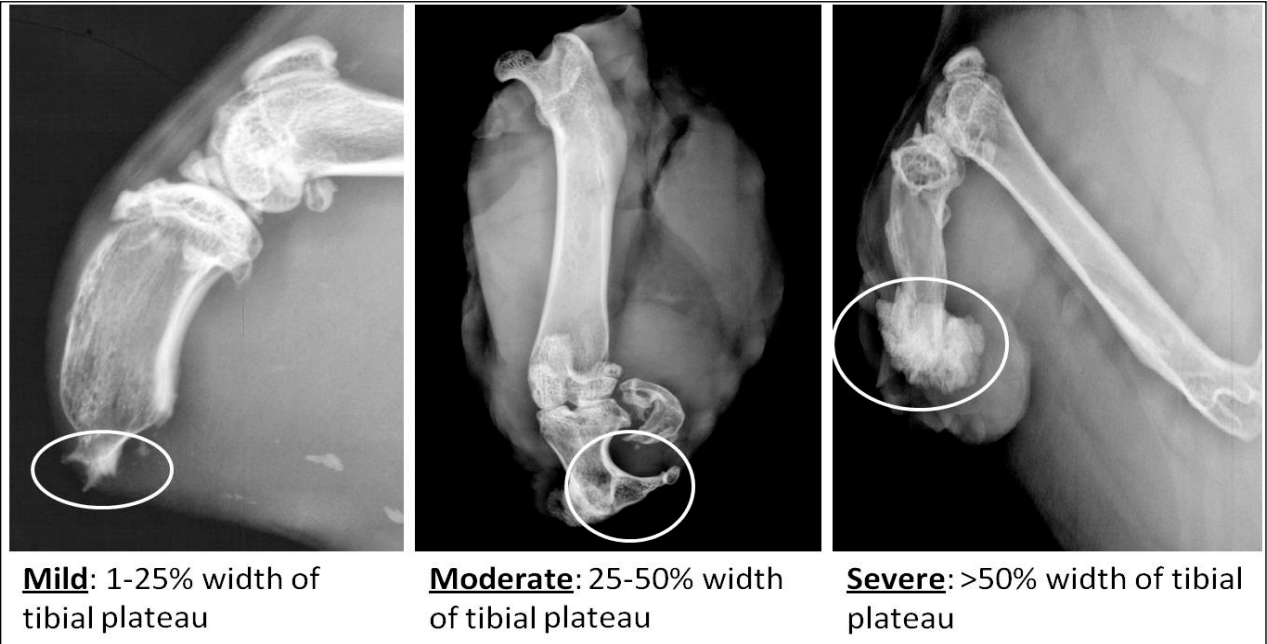


Figure 4. Radiographic key used for grading HO severity.

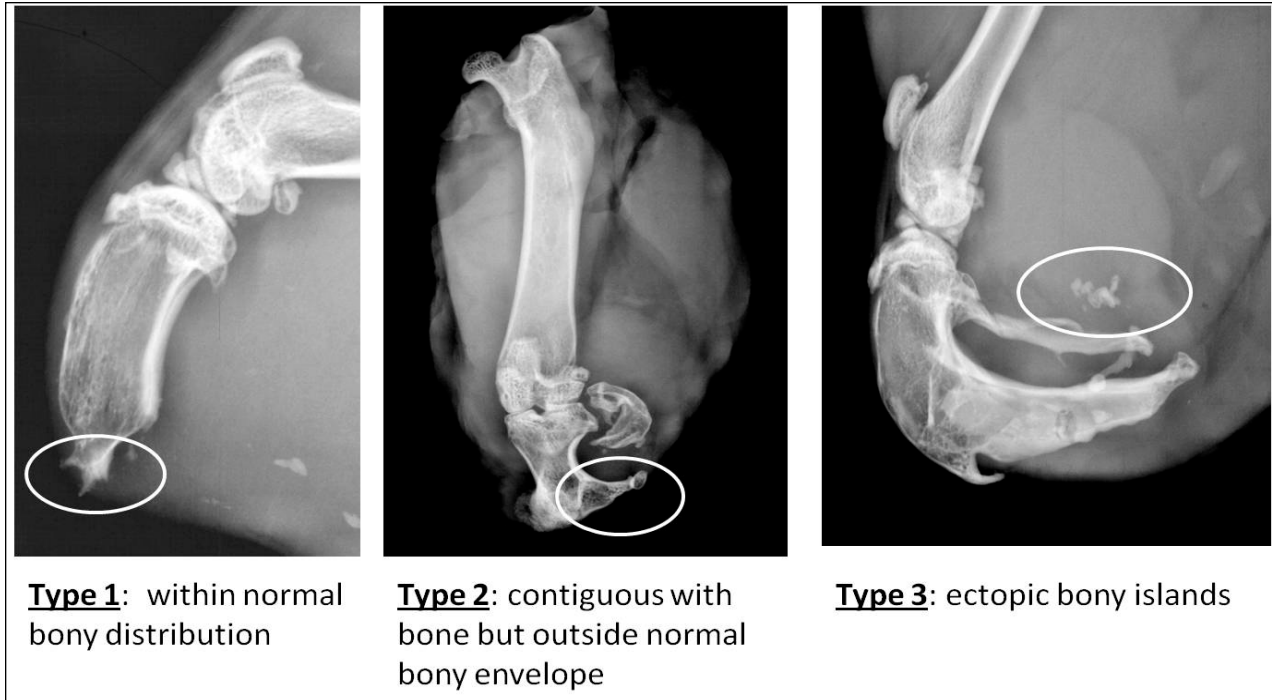


Figure 5. Radiographic key used for grading HO type.

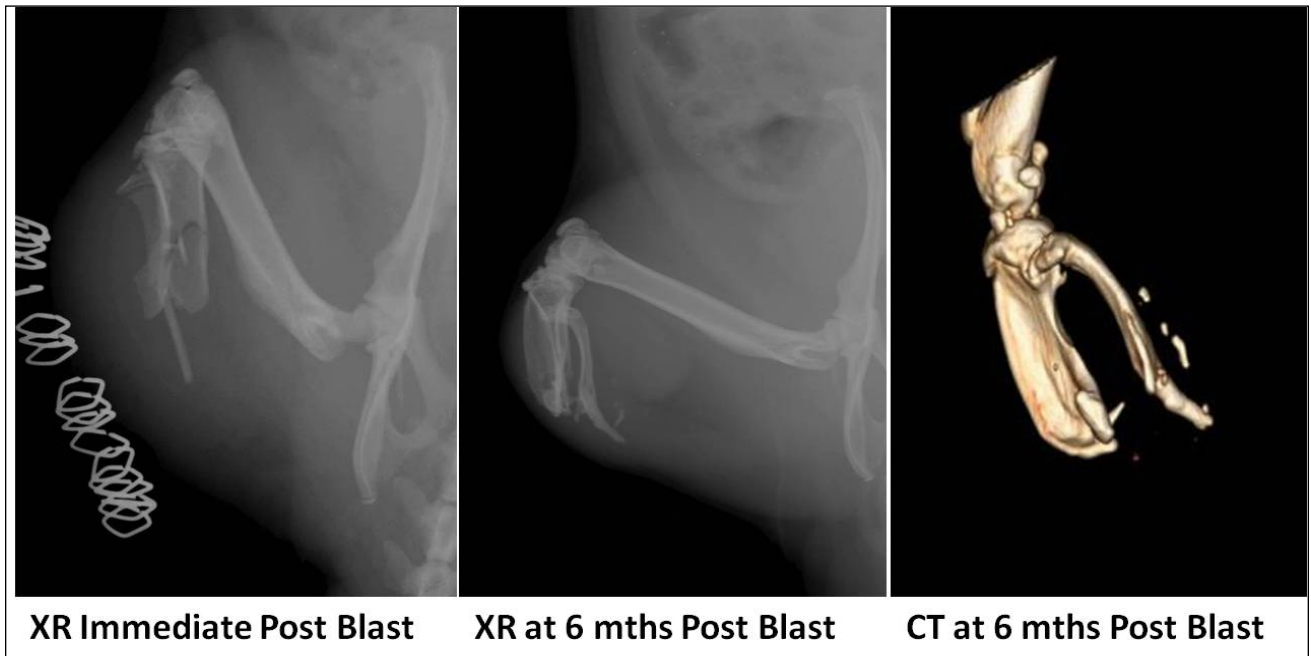


Figure 6. Control group: radiographic evolution of a control animal with severe HO and ectopic bony islands at 6 months post blast amputation.

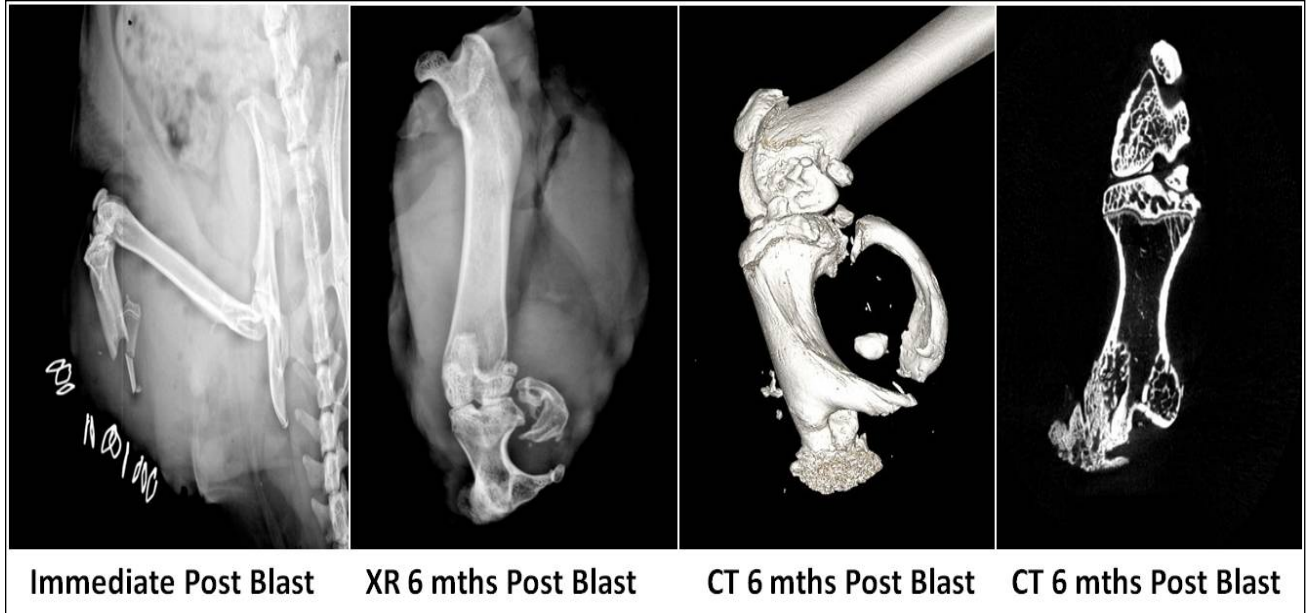


Figure 7. Indomethacin group: Radiographic evolution of HO in one animal demonstrating severe heterotopic ossification in the residual tibia. This animal had chronic granuloma-like lesion.

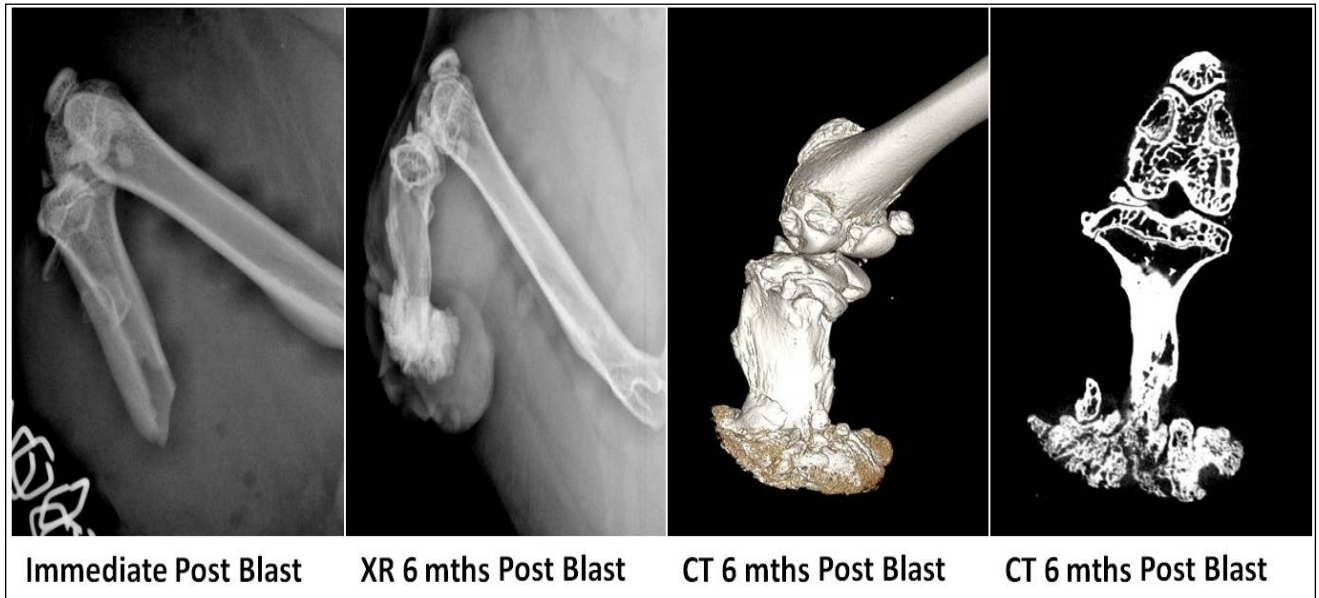
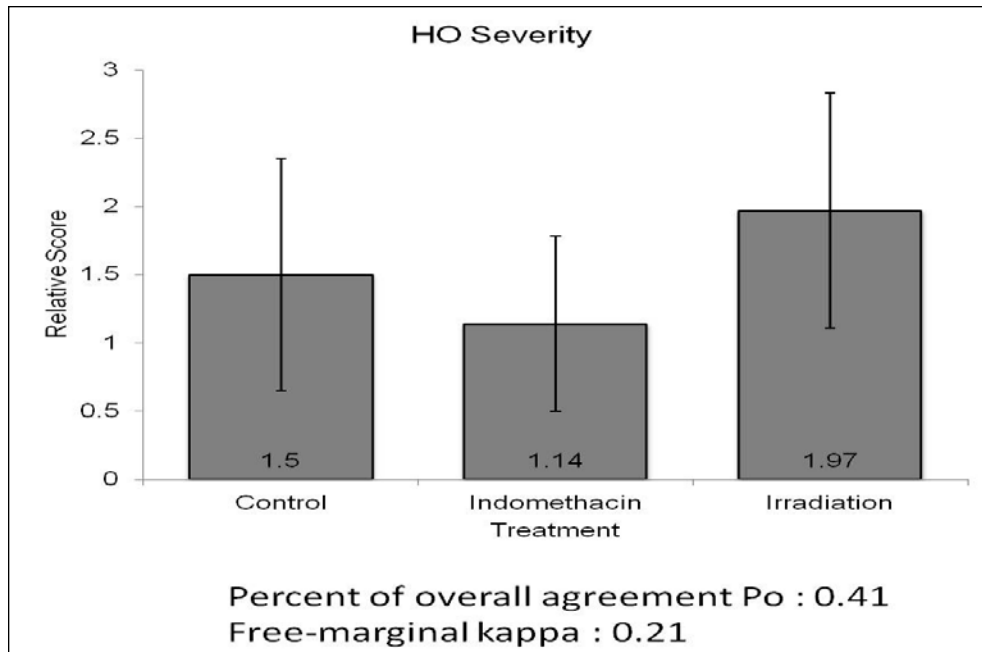
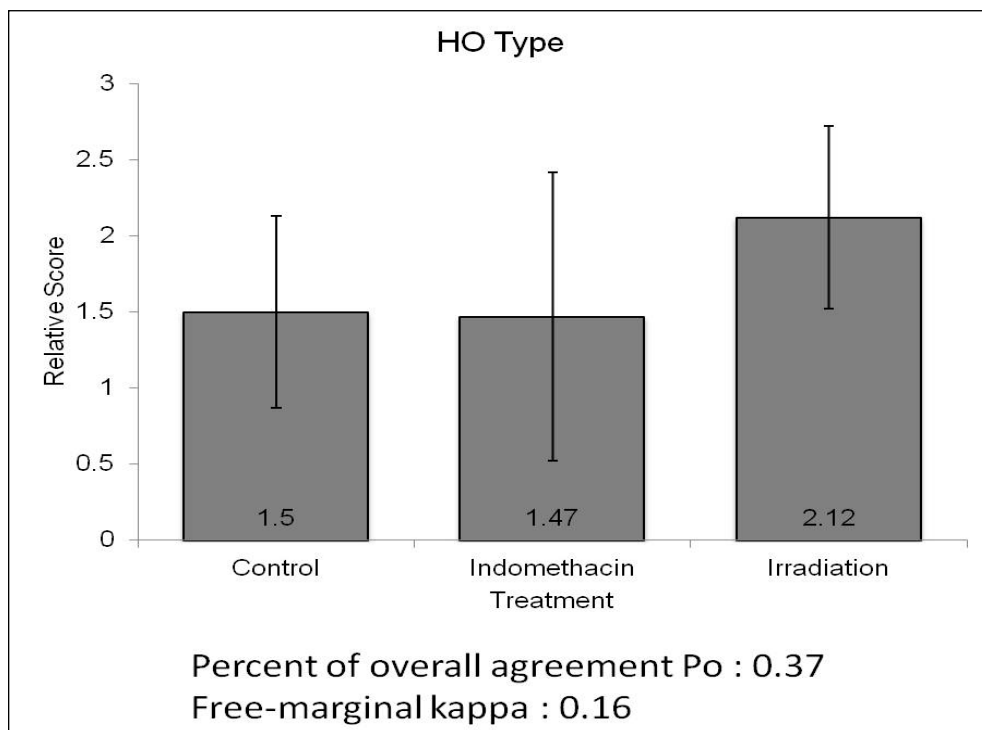


Figure 8. Irradiation group: Radiographic evolution of HO in an animal showing severe HO on the distal aspect of the residual tibia. This animal also had a non-healing granuloma-like lesion.



**Figure 9. Severity of Heterotopic ossification by treatment group (N=12 for all groups except irradiation group where 1 animal died). Scale: Absent (0), Mild (1), Moderate (2), Severe (3)**



**Figure 10. Type of heterotopic ossification by treatment group. Scale: Absent (0), Type 1 (within normal bony distribution), Type 2 (contiguous with bone but outside normal bony envelope), Type 3 (ectopic bony islands).**

**Table 1. Grading scale of HO type and severity modified from that originally devised by Potter *et al***

<b>Severity</b>	<b>Type</b>
0-Absent	0-Absent
1-Mild - <25% of width of tibial plateau of residual limb	1- as bone growing contiguously with the stump while remaining within the normal bony configuration
2-Moderate - 25-50% of width of tibial plateau of residual limb	2- bone contiguous with the bony stump but outside the normal bony Envelope
3-Severe (3)- >50% of width of tibial plateau of residual limb	3- ectopic bone originating within the surrounding soft tissues of the residual limb (not contiguous with the bony stump)

**Pulsatile Lavage of Musculoskeletal Wounds  
Causes Muscle Necrosis and Dystrophic Calcification**

Astor D Robertson, MBBS\*, Thao P Nguyen, MD\*, David E Jaffe, MD\*, Carla Hebert, BS\*,  
E. Lex Hanna, MD<sup>^</sup>, Robert Holmes, MD<sup>^</sup>, William B Fourney, PhD<sup>#</sup>, Joseph Stains,  
PhD\*, and Vincent D Pellegrini, Jr, MD<sup>^</sup>

University of Maryland School of Medicine, Departments of Orthopaedics\* and  
Engineering<sup>#</sup>; and the Medical University of South Carolina Department of Orthopaedics<sup>^</sup>

Work performed at the University of Maryland and the Medical University of South Carolina

This work was supported by a grant from the Department of Defense; Congressionally Directed  
Medical Research Program, Peer Reviewed Orthopaedic Research Program  
Contract # WB1XWH-10-1-0975

Corresponding Author  
Vincent D. Pellegrini, Jr, MD  
John A. Siegling Professor and Chair  
Department of Orthopaedics  
Medical University of South Carolina  
96 Jonathan Lucas Street, CSB 708, MSC 622  
Charleston, SC 29425

## **ABSTRACT**

**Background:** Adequate wound irrigation of open musculoskeletal injuries is widely regarded as standard of care in the prevention of infection by decreasing bacterial load and other contaminants. While the benefit of removal versus the risk of further seeding of debris into host tissue by high-pressure lavage has been the subject of numerous studies, the detrimental effects of irrigation on muscle are infrequently reported. This study aims to assess the relative damage to host muscle by pulsatile lavage versus bulb syringe irrigation.

**Methods:** Twenty-four Sprague-Dawley rats underwent hindlimb blast amputation via a column of propelled water following detonation of a submerged explosive. All wounds were irrigated with a 40:1 saline to 2% chlorhexidine solution and underwent primary closure. Group 1 (n=12) underwent through knee amputation above the zone of injury and bulb syringe irrigation with 250ml of normal saline; Group 2 (n=12) also underwent through-knee amputation above the zone of injury but then had pulsatile lavage irrigation (Waterpik<sup>®</sup>) at 15-20 psi with 1L of saline solution. A third group (n=6) of animals were not subjected to the blast procedure but underwent a 3cm surgical incision on the left thigh into muscle followed by pulsatile lavage of the wound. All animals were followed with serial AP and lateral radiographs monitoring the appearance and evolution of any soft tissue radio-opacities until planned euthanasia at 24 weeks. Xray guided incisional muscle biopsies were done at 8 weeks and post-euthanasia on representative animals from each group. Histologic analysis was performed with hematoxylin and eosin, Alizarin Red, and Von Kossa stains.

**Results:** No blast amputation animals managed with bulb syringe irrigation exhibited any evidence of radiopaque lesions. Conversely, all animals subjected to pulsatile lavage at 20 psi, in both the blast amputation as well as the surgical incision groups, developed soft tissue radio-opacities. Lesions first appeared at approximately 10 days post-operative, increased in density to approximately 16 weeks, and then demonstrated signs of variable regression. Histology revealed evidence of tissue damage with inflammatory cells and dystrophic calcification. There was no histologic evidence of heterotopic ossification in the surgical incision group; in blast amputation animals, pulsatile lavage potentiated heterotopic ossification.

**Conclusions:** Pulsatile lavage used in surgical musculoskeletal wounds can cause incremental insult to muscle tissue resulting in myonecrosis and dystrophic calcification. Additionally, in high energy traumatic blast wounds, pulsatile lavage can potentiate heterotopic ossification.

## INTRODUCTION

Appropriate and timely treatment of musculoskeletal injuries, whether open or closed, is essential for the restoration of normal anatomy and corresponding function in both civilian and military settings. However, high-energy traumatic blast wounds pose an additional challenge with a unique risk of heterotopic ossification along with accompanying risk of infection, protracted rehabilitation, loss of productive work time, and an accumulation of individual emotional and societal costs.

Of the approximately 6 million fractures reported in the United States each year, an estimated 250,000 are open.<sup>1,2</sup> This estimate, coupled with the multitude of unreported cases of open soft tissue injuries, underscores the importance of optimal wound care for the restoration of function in an active and productive population.

Thorough wound toilet is widely accepted as a cornerstone in the management of open fractures and traumatic injuries. Copious irrigation to remove loosely attached cellular and foreign debris, debridement to remove adherent material and devitalized tissue from the wound bed, and appropriate antibiotic coverage comprise the gold-standard of care for open wounds. Together these interventions decrease bacterial counts, remove impediments to the healing process, and create an optimized healing environment.<sup>1, 3, 4</sup>

In the clinical setting, wound irrigation is achieved most commonly through either pulsatile lavage or by simple manual bulb syringe with a saline solution. Pulsatile lavage is the pressurized delivery of an irrigating solution using an electrically powered device, and has gained great popularity in the management of grossly contaminated wounds. Pulsed lavage is considered a high-pressure device compared with the low pressure of a manual bulb syringe. However, accepted definitions classify low pressure as less than 15 psi and high pressure as being greater than 35 psi. High-pressure irrigation has been shown to be more effective in removing particulate debris, necrotic tissue, and bacteria compared with low-pressure irrigation methods, in both *in vitro*<sup>5</sup> and *in vivo*<sup>6-9</sup> studies. However, despite being commonly used for irrigation, pulsatile lavage has been implicated in causing further propagation of bacteria and particulate matter into host tissue, damage to bone and surrounding soft tissue, and even possible impairment of the wound healing process.<sup>5, 10-15</sup> Indeed, the Agency for Health Care Policy and Research has suggested that cleansing with low-pressure lavage (4 to 15 psi) is sufficient to remove surface pathogens and debris without causing additional wound trauma or bacterial spreading.<sup>16</sup>

While macroscopic and microscopic damage to soft tissue by high-pressure lavage has been reported in multiple *in vivo* and *in vitro* studies, its association with dystrophic calcification or relationship to heterotopic ossification has never been reported. Dystrophic calcification refers to the deposition of calcium salts in dead or dying tissues. It occurs principally in areas of coagulative, liquefactive, caseous and/or fat necrosis that persist for rather long periods of time.<sup>17</sup> It is always local, blood levels of calcium and phosphate are normal, and it is thought

to account for 95-98% of all soft tissue calcifications.<sup>18</sup> The process is thought to start in membrane-bound vesicles within cells. When the membrane of a vesicle is damaged, calcium binds to the phospholipid in the membrane. Phosphatases within the membrane add phosphate groups to the calcium, forming calcium phosphate, which precipitates and can be seen on radiographs as cloudy or speckled opacities.<sup>17</sup> Heterotopic ossification, on the other hand, is the process by which woven bone is formed aberrantly within the soft tissues from pluripotent mesenchymal stem cells that are stimulated down an osteogenic cell line. Histologically, in contrast to dystrophic calcification, it is characterized by cellular proliferation and osteoid formation with active osteogenesis rather than cell necrosis. Heterotopic ossification is an aggressive inflammatory process that disrupts normal soft tissue healing and can even result in wound and skin breakdown.

The purpose of this study was to investigate the effects of wound irrigation types on the formation of heterotopic ossification. We will report and characterize unanticipated damage to muscle after wound toilet with pulsed irrigation observed following a high energy blast amputation protocol as well as a controlled surgical incision in the Sprague-Dawley rat.

## **MATERIALS AND METHODS**

All procedures were performed under a protocol reviewed and approved by the Institutional Animal Care and Use Committee at the University of Maryland School of Medicine as well as the Animal Care and Use Review Office of the United States Army Medical Research and Materiel Command. This work was funded by the Congressionally Directed Medical Research Program of the Department of Defense under contract # WB1XWH-10-1-0975.

A total of 30 male Sprague-Dawley rats aged sixteen to eighteen weeks old, and weighing approximately 400 grams, were used in this study. Twenty-four of these animals underwent hind limb blast amputation under a well-established experimental protocol, of which twelve had their open wounds irrigated by pulsatile lavage and the other twelve received bulb syringe irrigation. An additional six animals were not subjected to the blast amputation procedure, but rather underwent a controlled surgical incision through fascia to muscle on the anterolateral left thigh with pulsatile lavage of the wound.

### General Animal Preparation

Anesthesia was induced with isoflurane at 4% in an induction chamber, and maintained with 2-3% inhaled isoflurane via a nose cone. Once sedated, an ocular protective lubricant was applied bilaterally. The left hind limb and ipsilateral side of lower back and abdomen were cleared of hair with an electric clipper and cleansed thrice with alternating solutions of betadine scrub and 70% isopropyl alcohol. Buprenorphine (0.05 mg/kg) and enrofloxacin (5 mg/kg) were administered subcutaneously for preemptive analgesia and prophylactic antibacterial coverage, respectively. Preemptive administration of 6 to 10 mL of warmed

0.9% normal saline was provided subcutaneously for volume resuscitation in anticipation of hemorrhage related to the blast amputation trauma.

### Blast Amputation Group - Traumatic Wound Creation

Maintaining deep inhalation anesthesia by nose cone, the rat was positioned prone on the blast apparatus (Figure 1) and tightly secured with industrial strength Velcro on a 2-inch-thick aluminum platform that features a 2.5-inch hole in its center. The left hind limb was held across the hole, centered at the desired amputation level through the mid-tibia, with the use of a silk suture and duct tape. The platform was located above a 2 foot by 2 foot by 2 foot steel tank filled with tap water. An explosive (0.75 gram of pentaerythritol tetranitrate) was submerged 0.5 inch below the surface of the water, directly beneath the center of the hole in the platform. The explosive was detonated using a commercially available detonation box. The resulting chemical reaction creates a large volume of hot, high-pressure gases which act against the surrounding water, and accelerate it upwards at velocities approaching four times the speed of sound in air (Mach 4). These very high velocities were converted into pressure when the propelled water impacted both the plate and the animal's exposed extremity. Pressures on the order of tens of thousands of pounds per square inch were absorbed by the limb, which was quickly and cleanly amputated.

Following amputation, the animals were immediately transferred to an adjacent sterile operating table over an insulated heating pad while maintained on inhaled isoflurane anesthesia via nose cone. Minimal blood loss was observed, presumably due to cauterization of the vessels from the high temperature and pressure of the blast. A through-knee disarticulation was then performed above the zone of injury to remove the residual bony stump and damaged muscle tissue of all 24 animals. Group 1 animals (N=12) had their wounds irrigated with 250mL of a 40:1 saline: 2% chlorhexidine solution with a 50mL bulb syringe (1 psi). Group 2 animals (N=12) were irrigated with 1L of the same solution delivered via pulsatile lavage set at 20 pounds per square inch using a Waterpik<sup>®</sup> dental jet (Water Pik Technologies, Newport Beach, CA). The muscle around the stump was inverted over the distal femur and myofascial closure was accomplished with a running 4-0 Vicryl suture to ensure adequate soft tissue coverage. The charred skin edges were conservatively but sharply debrided to facilitate primary wound healing. The skin was closed with staples and sealed with Histoacryl tissue adhesive (B. Braun Corporation, Bethlehem, PA).

### Control Group – Surgical Wound Creation

There were six animals in this group. Following standard anesthesia and surgical site preparation as described above, a 3-4 cm skin incision was made on the lateral aspect of the left thigh with sharp dissection down through fascia to expose the underlying muscle. The exposed muscle was then irrigated with 1L of irrigation solution delivered via pulsatile

lavage using a Waterpik® dental jet at 20 psi. The fascia was closed with running 4-0 Vicryl sutures and skin flaps approximated and closed with staples and tissue adhesive as above.

### Post-Procedural care

Each animal was placed in a separate clean recovery cage with fresh bedding and an isothermal heating pad under the bedding, and closely monitored for signs of distress during emergence from anesthesia. Animals received antibiotics (Enrofloxacin, 5 mg/kg subcutaneously twice a day) for a total of three days, except for the control group which only received one dose at 12 hours post-operatively. Analgesia with Buprenorphine (0.05 mg/kg subcutaneously thrice daily) was provided for five days for the blast animals and three days for the controls. All animals were monitored twice daily for the first three days, then daily for five days, and then at least twice a week until sacrifice for weight changes, general appearance, activity level, breathing patterns and rates, feeding and excretion, ambulation, and incision site changes. Additional analgesia was provided as dictated by physiological signs of animal discomfort.

### Outcome Assessment

Radiographic evidence of opacities, and their histologic correlation, in the irrigated soft tissue in the surgical or amputation region was the primary outcome measure of this study. This was further investigated histologically as either an indication of mineralization/calcification of injured or necrotic muscle or the primary process of heterotopic ossification. The animals were imaged with orthogonal views on a small animal digital Faxitron radiography machine (Faxitron X-Ray LLC, Lincolnshire, IL) immediately post-op, at 10days, and every 4 weeks thereafter until euthanasia at 6 months. Three animals from each group with soft tissue radiopacities in the irrigated area underwent an incisional biopsy at the 8-week time point for histological analysis. Histochemical staining was performed using hematoxylin and eosin, Alizarin Red, and Von Kossa stains with the intention of distinguishing between heterotopic ossification and any other process of soft tissue calcification unrelated to HO. The latter two stains are special stains used to identify calcium deposits.

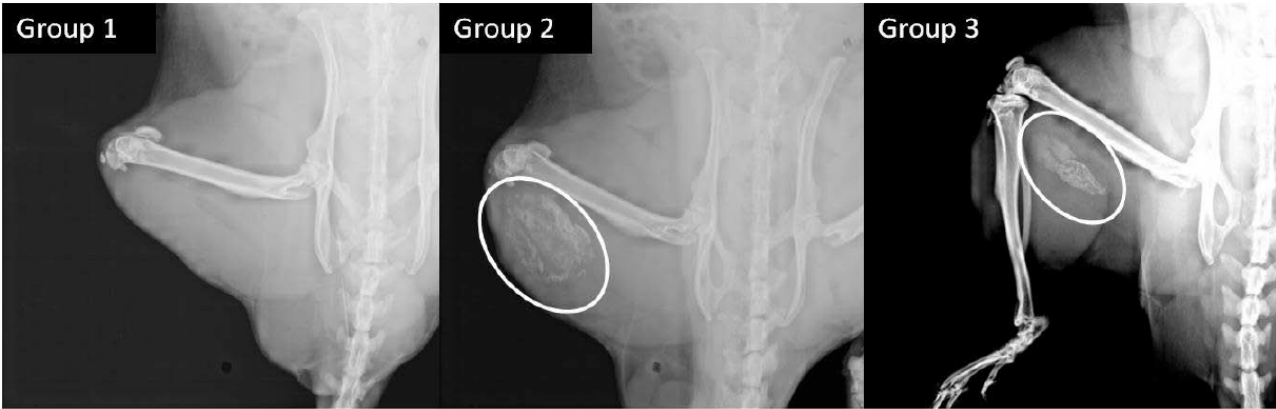
## **RESULTS**

All 24 animals subjected to the left hind limb blast amputation survived the procedure. Three animals in the pulsatile lavage group had wound dehiscence in the immediate postoperative period and healed uneventfully after repeat closure of the incision. Two additional animals in the pulsatile lavage group had wound breakdown without any evidence of infection several weeks after the blast procedure and required secondary closure; each healed uneventfully thereafter without any additional debridement. There were no wound complications in the 12 animals irrigated with the bulb syringe or the 6 control animals.

All animals that underwent blast amputation and were treated with bulb syringe irrigation had a benign radiographic course with no evidence of radiopaque lesions. Conversely, all animals subjected to pulsatile lavage at 20 psi, including both blast amputation and surgical incision groups, developed radio-opacities apparent on imaging. These lesions first appeared at 10 days post-op, increased in density up to 16 weeks, and then showed signs of gradual and variable regression thereafter (Figure 2). Hematoxylin and Eosin, Alizarin Red, and Von Kossa staining all revealed evidence of variable degrees of tissue damage with an abundance of inflammatory cells, extensive areas of edema, myonecrosis, and surrounding reactive fibrous tissue proliferation and calcium deposits within areas of tissue necrosis (Figure 3). Histologic study of tissue harvested after euthanasia also showed evidence of adipocyte edema and destruction with resultant liquefactive necrosis (Figure 4).



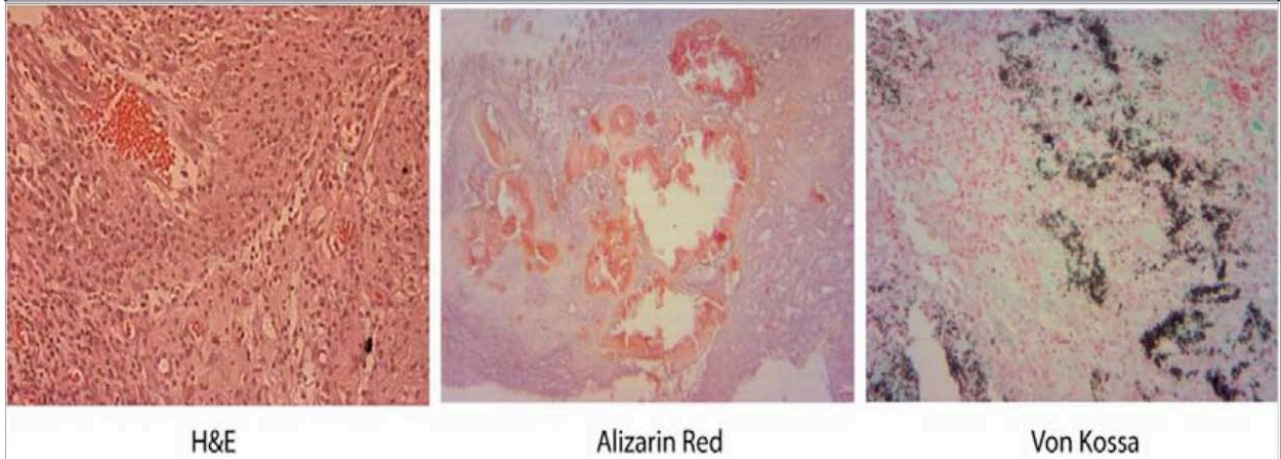
Figure 1. Blast apparatus



Dystrophic calcification is apparent in blast amputation (Group 2) and non-blast (Group 3) limbs following pulsed lavage, and absent in blast amputated limb irrigated with bulb syringe (Group 1)

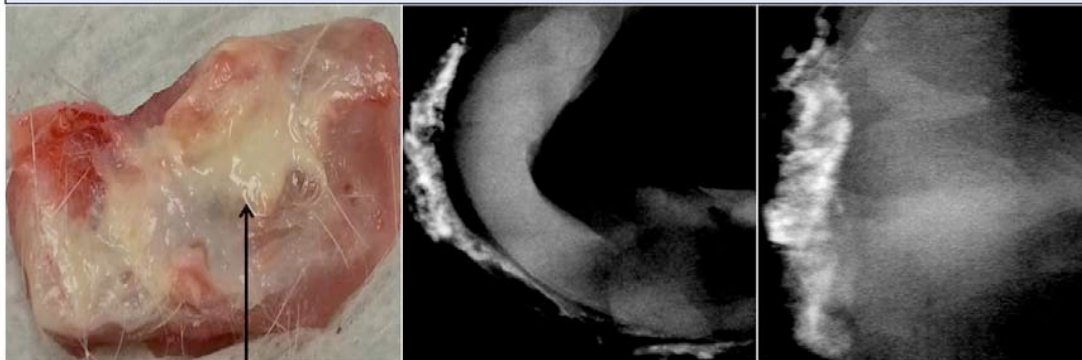
Figure 2. Radiographs at 8 weeks post op.

Histological representations of incisional biopsy specimens at 8 wks post-op



**Figure 3. Histochemical staining with H&E revealing loss of skeletal muscle architecture. Alizarin Red and Von Kossa stains show evidence of calcium deposition with red and black staining respectively.**

Gross image and axial views of excisional biopsies at time of euthanasia



Evidence of liquefactive necrosis

**Figure 4. Gross image demonstrating appearance of liquefactive necrosis in the area of pulsatile lavage. Axial CT views showing area of dystrophic calcification.**

## DISCUSSION

This study was designed to assess the potentially adverse impact of wound irrigation in the management of traumatic high energy musculoskeletal wounds. We utilized a previously established small animal extremity blast amputation model<sup>19</sup> to study the process of heterotopic ossification under conditions of different types of wound irrigation, and a controlled surgical incision for comparison to study the influence of high energy blast trauma on wound toilet. The study was not designed to compare wound cleansing solutions; dilute chlorhexidine was utilized to mitigate the risk of infection, which itself carries a risk of heterotopic ossification in these open wounds.

All wounds subjected to pulsatile lavage irrigation, irrespective of the setting of high-energy blast trauma or a controlled surgical incision, exhibited irrefutable evidence of muscle injury and necrosis manifest as radiographic soft tissue densities and histochemical findings consistent with dystrophic calcification. These findings, seen only in the setting of pulsatile lavage irrigation, were distinctly different radiographically and histologically from the process of heterotopic ossification that occurred within the zone of injury following high energy blast amputation. Importantly, we observed no radiographic or histological evidence of tissue injury associated with use of bulb syringe irrigation.

Many in vitro and in vivo studies have proven that pulsatile lavage irrigation is more effective than bulb syringe irrigation in the removal of particulate matter and decreasing bacterial count in the wound bed. Likewise, deleterious effects of pulsatile lavage have also been suggested, including its propensity to cause visible damage to bone, disruption of healthy soft tissue, and the seeding of intramedullary and soft tissue with bacteria.

The novel finding in this work is that weeks after the use of pulsatile wound irrigation, a phenomenon of dystrophic calcification is evident as a likely marker of irreversible injury to previously normal and healthy tissues incurred during this initial wound cleansing. Dystrophic calcification is a local process that occurs in the setting of prior severe tissue injury or where degeneration or necrosis has occurred. Serum levels of calcium and phosphate in the study animals were not measured, so we are unable to comment on the unlikely systemic nature of this process. It is reasonable to assume that since the radiodense lesions were only visible in the local areas subjected to irrigation, that no systemic abnormalities were present. In humans, dystrophic calcification occurs in the presence of normal levels of serum calcium (approximately 10 mg/100 ml) and in the absence of any derangement in calcium metabolism. Despite being prominent in chronic destructive lesions, it can develop very rapidly in degenerating cells and tissues. Calcium salt deposits may be prominent in acute heart and skeletal muscle lesions. Most commonly, the calcium accumulates in the form of hydroxyapatite. The appearance of radio-opacities in the study animals early as 10 days post op, their subsequent progression and variable regression, and prolonged presence is consistent with this description. One is

left to conclude that pulsatile irrigation can induce muscle injury and cell death in previously normal soft tissues.

Importantly, this study used a pulsatile lavage device which produces pressures comparable to those routinely used in the management of human extremity injuries. The pressure generated from the pulsatile lavage devices commonly used in the operating room is approximately 20 psi, compared with 1 psi for bulb syringe irrigation. The pulsed lavage devices in this experimental protocol were specifically calibrated to deliver irrigation pressures of 20 psi. Extrapolation to actual clinical practice is therefore feasible. It is realistic to conclude that the pathologic process of dystrophic calcification may also occur in humans secondary to unintended soft tissue injury from pulsatile lavage.

While we did not study volume or the specific choice of irrigant in this experiment, it is conceivable that the irrigation composition may play a role in the observed results. Yet, the same solution was used for both irrigation methods so the nature of the solution would not explain the observed differences in tissue response. Normal saline is known to be physiologically compatible and nontoxic to host tissues. Therefore, a 40:1 normal saline: chlorhexidine solution might also be reasonably considered nontoxic.

The clinical importance of these findings is apparent, as they further incriminate pulsatile lavage as being responsible for local adverse soft tissue effects. Indeed, the Agency for Health Care Policy and Research guidelines recommend irrigation pressures ranging from 4 to 15 psi. Specifically, it suggests that irrigation pressures of less than 4 psi may be insufficient to remove surface pathogens and debris, while pressures greater than 15 psi may cause incremental wound trauma and drive bacteria into wounds. While pulsatile lavage is known to be effective in mechanical wound cleansing, maintaining irrigation pressures on the delivery devices to below 15 to 20 psi seems prudent in light of these findings. Indeed, we have discontinued use of high-pressure pulsatile lavage in all but the most grossly contaminated wounds and prefer high volume, low pressure irrigation in the management of most traumatic and surgical wounds in an effort to minimize incremental tissue injury.

## REFERENCES

1. Anglen JO. Wound irrigation in musculoskeletal injury. *J Am Acad Orthop Surg.* 2001; 9: 219- 26.
2. Praemer A, Furner S, Rice DP: Musculoskeletal Conditions in the United States. Park Ridge, Ill: American Academy of Orthopaedic Surgeons, 1992.
3. Gustilo RB, Anderson JT: Prevention of infection in the treatment of one thousand and twenty five open fractures of long bones: Retrospective and prospective analyses. *J Bone Joint Surg* 1976; 58: 453–458.
4. Barr JE. Principles of wound cleansing. *Ostomy Wound Manage* 1995; 41(7A Suppl.):15S–21S; Discussion 22S
5. Bhandari M, Schemitsch EH, Adili A, Lachowski RJ, Shaughnessy SG. High and low pressure pulsatile lavage of contaminated tibial fractures: an in vitro study of bacterial adherence and bone damage. *J Orthop Trauma.* 1999; 13: 526-33.
6. Rodeheaver GT, Pettry D, Thacker JG, Edgerton MT, Edlich RF: Wound cleansing by high pressure irrigation. *Surg Gynecol Obstet* 1975; 141: 357-362.
7. Madden J, Edlich RF, Schauerhamer R, Prusak M, Borner J, Wangenstein OH: Application of principles of fluid dynamics to surgical wound irrigation. *Curr Topics Surg Res* 1971; 3: 85-93.
8. Gross A, Cutright DE, Bhaskar SN: Effectiveness of pulsating water jet lavage in treatment of contaminated crushed wounds. *Am J Surg* 1972; 124: 373-377.
9. Brown LL, Shelton HT, Bornside GH, Cohn I Jr: Evaluation of wound irrigation by pulsatile jet and conventional methods. *Ann Surg* 1978;187: 170-173.
10. Boyd JI 3rd, Wongworawat MD. High-pressure pulsatile lavage causes soft tissue damage. *Clin Orthop Relat Res* 2004; 427:13–7.
11. Wheeler CB, Rodeheaver GT, Thacker JG, Edgerton MT, Edlich RF. Side-effects of high pressure irrigation. *Surg Gynecol Obstet.* 1976; 143: 775-8.
12. Adili A, Bhandari M, Schemitsch EH: The biomechanical effect of high-pressure irrigation on diaphyseal fracture healing in vivo. *J Orthop Trauma* 2002; 16: 413–417.
13. Dirschl DR, Duff GP, Dahners LE, Edin M, Rahn BA, Miclau T. High pressure pulsatile lavage irrigation of intraarticular fractures: effects on fracture healing. *J Orthop Trauma* 1998;12: 460-3.
14. Hassinger SM, Harding G, Wongworawat MD. High-pressure pulsatile lavage propagates bacteria into soft tissue. *Clin Orthop Relat Res.* 2005; 439: 27-31.
15. Park SH, Silva M, Bahk WJ, McKellop H, Lieberman JR. Effect of repeated irrigation and debridement on fracture healing in an animal model. *J Orthop Res.* 2002; 20: 1197-204.
16. Bergstrom N, Bennett MA, Carlson CE. Treatment of pressure ulcers: clinical practice guidelines no. 15. Rockville: US Department of Health and Human Services, Public Health Service, Agency for Health Care Policy and Research, 1994; 6–7,47–53. AHCPR Publication No. 95-0652.
17. Giachelli CM, Ectopic Calcification: Gathering hard facts about soft tissue mineralization. *Am J Pathol.* Mar 1999; 154 (3): 671-675.

18. Banks KP, Bui-Mansfield LT, Chew FS, Collinson F. A compartmental approach to the radiographic evaluation of soft-tissue calcifications. *Semin Roentgenol.* 2005; 40: 391-407.
19. Tannous O, Griffith C, O'Toole RV, Pellegrini VD. Heterotopic ossification after Extremity blast amputation in a Sprague-Dawley rat animal model. *J Orthop Trauma* 2011; 25 506-510.