

Award Number: W81XWH-13-2-0077

TITLE: Preventative Therapeutics for Heterotopic Ossification

PRINCIPAL INVESTIGATOR: Dr. Jonathan Forsberg

CONTRACTING ORGANIZATION: The Geneva Foundation
Tacoma, WA 98402

REPORT DATE: December 2016

TYPE OF REPORT: Final

PREPARED FOR: U.S. Army Medical Research and Materiel Command
Fort Detrick, Maryland 21702-5012

DISTRIBUTION STATEMENT: Approved for Public Release;
Distribution Unlimited

The views, opinions and/or findings contained in this report are those of the author(s) and should not be construed as an official Department of the Army position, policy or decision unless so designated by other documentation.

REPORT DOCUMENTATION PAGE

Form Approved
OMB No. 0704-0188

Public reporting burden for this collection of information is estimated to average 1 hour per response, including the time for reviewing instructions, searching existing data sources, gathering and maintaining the data needed, and completing and reviewing this collection of information. Send comments regarding this burden estimate or any other aspect of this collection of information, including suggestions for reducing this burden to Department of Defense, Washington Headquarters Services, Directorate for Information Operations and Reports (0704-0188), 1215 Jefferson Davis Highway, Suite 1204, Arlington, VA 22202-4302. Respondents should be aware that notwithstanding any other provision of law, no person shall be subject to any penalty for failing to comply with a collection of information if it does not display a currently valid OMB control number. **PLEASE DO NOT RETURN YOUR FORM TO THE ABOVE ADDRESS.**

1. REPORT DATE December 2016		2. REPORT TYPE FINAL		3. DATES COVERED 30 SEP 2013 - 29 SEP 2016	
4. TITLE AND SUBTITLE Preventative Therapeutics for Heterotopic Ossification				5a. CONTRACT NUMBER	
				5b. GRANT NUMBER W81XWH-13-2-0077	
				5c. PROGRAM ELEMENT NUMBER	
6. AUTHOR(S) Dr. Jonathan Forsberg E-Mail: jonathan.a.forsberg.mil@mail.mil				5d. PROJECT NUMBER	
				5e. TASK NUMBER	
				5f. WORK UNIT NUMBER	
7. PERFORMING ORGANIZATION NAME(S) AND ADDRESS(ES) AND ADDRESS(ES) The Geneva Foundation 917 Pacific Ave, Suite 600 Tacoma, WA 98402				8. PERFORMING ORGANIZATION REPORT NUMBER	
9. SPONSORING / MONITORING AGENCY NAME(S) AND ADDRESS(ES) U.S. Army Medical Research and Materiel Command Fort Detrick, Maryland 21702-5012				10. SPONSOR/MONITOR'S ACRONYM(S)	
				11. SPONSOR/MONITOR'S REPORT NUMBER(S)	
12. DISTRIBUTION / AVAILABILITY STATEMENT Approved for Public Release; Distribution Unlimited					
13. SUPPLEMENTARY NOTES					
14. ABSTRACT					
15. SUBJECT TERMS					
16. SECURITY CLASSIFICATION OF:			17. LIMITATION OF ABSTRACT	18. NUMBER OF PAGES	19a. NAME OF RESPONSIBLE PERSON USAMRMC
a. REPORT U	b. ABSTRACT U	c. THIS PAGE U			19b. TELEPHONE NUMBER (include area code)

Standard Form 298 (Rev. 8-98)
Prescribed by ANSI Std. Z39.18

Table of Contents

INTRODUCTION.....	4
KEYWORDS.....	4
OVERALL PROJECT SUMMARY.....	4
KEY RESEARCH ACCOMPLISHMENTS.....	22
CONCLUSION.....	22
PUBLICATIONS, ABSTRACTS, AND PRESENTATIONS:.....	23
Lay Press.....	23
Peer-Reviewed Scientific Journals.....	23
Invited Articles.....	23
Abstracts.....	23
Presentations.....	24
INVENTIONS, PATENTS AND LICENSES.....	26
REPORTABLE OUTCOMES.....	26
OTHER ACHIEVEMENTS.....	26
REFERENCES.....	26
APPENDICES.....	26

INTRODUCTION

In this project we study Heterotopic Ossification (HO) and are a potential novel therapy to cure it. HO consists of formation of extra bone within the muscles, near tendons and ligaments, inside the blood vessels and other places in the body. HO is triggered by trauma, burns, nerve damage, immobilization and other conditions and can also occur in patients undergoing large surgeries such as hip or knee replacement. Because trauma, burns and other severe wounds are regrettably common in our soldiers in the current war theaters and conflicts, HO often affects and afflicts many of them. The consequences of having HO are not minor. Patients with HO can experience loss of normal posture and movement, chronic pain, prosthesis fitting problems, formation of pressure ulcers, deep venous thrombosis and other health problems. Indeed, HO has emerged as the single most important barrier to functional activity and return-to-duty in a recent analysis of wounded active duty service- members. Subsequent infection remains one of the common and significant complications following blast-related severe fracture and amputation with *Acinetobacter Baumannii* and *Methicillin Resistant Staphylococcus Aureus* (MRSA) being the most common isolate from combat wounds. To more precisely identify the cellular and molecular changes associated trauma-induced HO formation and to test the potential in vivo inhibitor effects of an retinoic acid receptor- γ agonist called palovarotene, we will use an established rat model of combat-related extremity injury/amputation that incorporates the critical elements commonly associated with combat injury namely blast injury, femur fracture and amputations, soft tissue injury and bioburden.

KEYWORDS

heterotopic ossification, traumatic injury, ectopic bone, palovarotene, amputation, combat wounds, crush injury, bioburden, osteogenesis, chondrogenesis, gene expression, extremity injuries, and blast overpressure exposure.

OVERALL PROJECT SUMMARY

NMRC-Regenerative Medicine Department Role (SOW) in the Partnership Award

Proposal Specific Aim 3: To determine whether the retinoid agonists block blast- and combat-related HO (months 1-36):

Task 3a. Implement the rat blast-injury model to include bacterial infection and HO (months 1-12).

Objective: To determine the effects of *Acinetobacter Baumannii* and *Methicillin Resistant Staphylococcus Aureus* (MRSA) infection on the rate development and severity of HO formation.

Methods: We subjected (48) Sprague-Dawley adult male rats (450-550g) rats to blast overpressure, femur fracture, soft-tissue crush injury at the fracture site and subsequent immediate trans-femoral amputation through the zone of injury. Wounds were

inoculated beneath the myodesis with vehicle (n=8) or 1×10^6 CFUs of *A. baumannii* (n=20) or MRSA (n=20). Animals were monitored for evidence of wound drainage or dehiscence and debridement was performed when these clinical manifestations of infection were noted. Animals were euthanized if residual limb wound drainage persisted after three debridements or the animal showed overwhelming symptoms of systemic infection. All animals formed HO. Heterotopic ossification was determined by quantitative volumetric measurements of ectopic bone on the 12-week postinjury using micro-CT and qualitative histomorphometry for assessment of new bone formation in the residual limb. Bone marrow and muscle tissue biopsies were collected from the residual limb at 12 weeks to quantitatively measure the bioburden load and to qualitatively determine the species-level identification of the bacterial flora.

Results: . All eight rats in the control group survived until the 12-week micro-CT scan (Figure. 1). Six animals in the MRSA group were euthanized during the fourth and fifth weeks for overwhelming infection. Two of the rats in the *A baumannii* group died on the day of surgery and were excluded. A low level of mortality after surgery was consistent with findings during model development and represents the severe-nature of these multifaceted injuries, particularly given that blast overpressure of 120 ± 7 kPa itself is calibrated for 70% to 90% survivability [1, 7, 26]. In addition, two rats infected with *A baumannii* were euthanized for sustained weight loss greater than 10% during postoperative weeks 2 and 4.

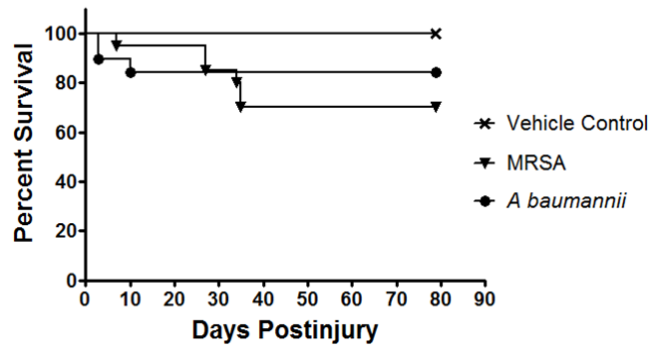


Figure 1. Treatment effects on survival outcome of injured rats wherein the traumatized muscle surrounding the amputation site at the time of closure was infected with either MRSA (1×10^6) or *A baumannii* (1×10^6). Kaplan-Meier survival curves are shown. Animals were euthanized if they demonstrated signs of infection after the third débridement and irrigation of the amputation wound site.

All rats that survived to the end of the study (*A baumannii* [n = 16], MRSA [n = 14], vehicle [n = 8]) demonstrated the formation of ectopic bone on the 12-week micro-CT scan (Figure. 2A-C). Volumetric measurements of ectopic bone formation (Fig. 2D) were more robust in animals inoculated with MRSA (68.0 ± 8.6 mm³; 95% CI, 50.52-85.55) than *A baumannii* (20.9 ± 3.7 mm³; 95% CI, 13.61-28.14; p < 0.001) and vehicle control (16.3 ± 3.2 mm³; 95% CI, 10.06-22.47; p < 0.001). Comparison of vehicle control and *A baumannii*-inoculated groups showed no difference (p = 0.43) with excellent interobserver agreement (ICC = 0.98).

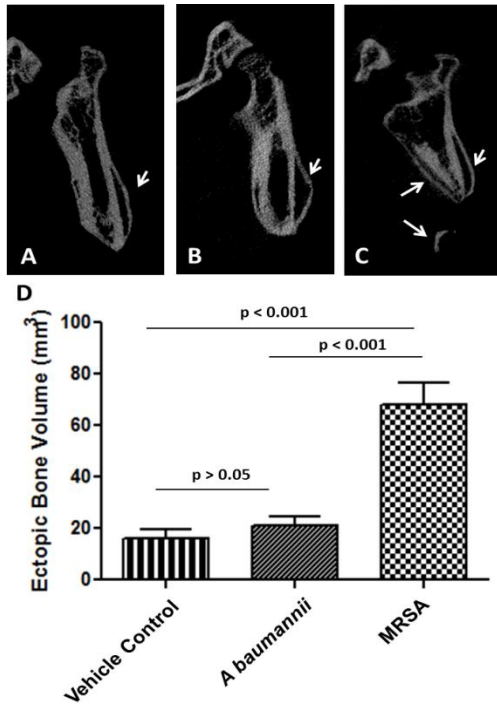


Figure 2A-D MRSA infection increases trauma-induced ectopic bone formation. Representative longitudinal 12-week micro-CT images of the residual femurs of rats inoculated with (A) vehicle control (PBS; noninfected control); (B) *A. baumannii*; and (C) MRSA are shown. The white arrows highlights the areas of ectopic bone formation. (D) The amount of ectopic bone was quantified 12 weeks postinjury from vehicle control (n = 8), *A. baumannii* (n = 16) and MRSA (n = 14) treatment groups. Result expressed are expressed as the mean ± SD.

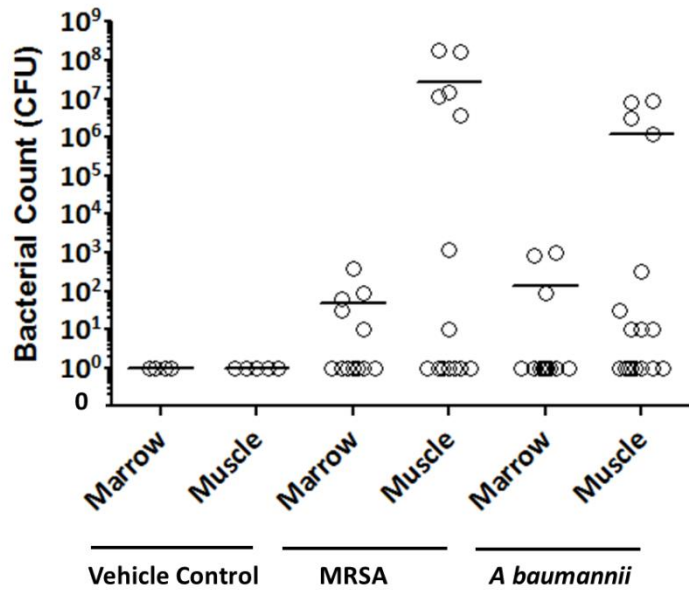


Figure 3. Bacterial titers (in CFUs converted to log scale) in the marrow compartment and soft tissue of rats infected with vehicle control (PBS; noninfected control), MRSA, and *A. baumannii* after 12 weeks. Each data point represents the actual CFU value for each animal in each treatment group, whereas the horizontal bar indicates the mean CFU for each treatment group. All rats inoculated with MRSA tested positive for MRSA, whereas rats inoculated with *A. baumannii* tested positive for other microorganisms as detailed in Table 1.

Figure. 2A-D MRSA infection increases trauma-induced ectopic bone formation. Representative longitudinal 12-week micro-CT images of the residual femurs of rats inoculated with (A) vehicle control (PBS; noninfected control); (B) *A. baumannii*; and (C) MRSA are shown. The white arrows highlights the areas of ectopic bone formation. (D) The amount of ectopic bone was quantified 12 weeks postinjury from vehicle control (n = 8), *A. baumannii* (n = 16) and MRSA (n = 14) treatment groups. Result expressed are expressed as the mean ± SD.

Soft tissue and bone marrow collected from the residual femur from rats inoculated with *A. baumannii* tested negative for *A. baumannii* flora but were positive for other strains of bacteria ($1.33 \times 10^2 \pm 0.89 \times 10^2$; 95% CI, -0.42×10^2 - 3.08×10^2 and $1.24 \times 10^6 \pm 0.69 \times 10^6$; 95% CI, -0.13×10^6 - 2.60×10^6

CFU in bone marrow and muscle tissue, respectively), whereas tissue from MRSA-infected rats contained MRSA only ($4.84 \times 10^1 \pm 3.22 \times 10^1$; 95% CI, -1.47×10^1 - 11.1×10^2 and $2.80 \times 10^7 \pm 1.73 \times 10^7$; 95% CI, -0.60×10^7 - 6.20×10^7) (Table 1). Specifically, bacterial culture results from the surviving MRSA-infected rats showed that in eight of 14 rats the muscle tissue surrounding the amputation site was positive for persistent MRSA infection, whereas five of the 12 bone marrow samples that were available after

Table 1: List of bacteria present in the marrow compartment and soft tissue 12 weeks postinjury.

Tissue	Vehicle control	<i>Acinetobacter baumannii</i>	Methicillin Resistant <i>Staphylococcus aureus</i> (MRSA)
Marrow	Negative	<i>Arcanobacterium haemolyticum</i> ; <i>Enterobacter cloacae</i> and <i>Enterococcus faecalis</i>	<i>Staphylococcus aureus</i>
Muscle	Negative	<i>Arcanobacterium haemolyticum</i> , <i>Streptococcus porcinus</i> , <i>Staphylococcus cohnii</i> ssp <i>urealyticum</i> , <i>Staphylococcus xylosus</i> , <i>Gardnerella vaginalis</i> , <i>Pasteurella multocida</i> , <i>Enterobacter cloacae</i> and <i>Enterococcus faecalis</i>	<i>Staphylococcus aureus</i>

en bloc resection of two animals were MRSA-positive (Figure 3). En bloc resection performed on MRSA rats demonstrated evidence of bacterial microcolonies, increased

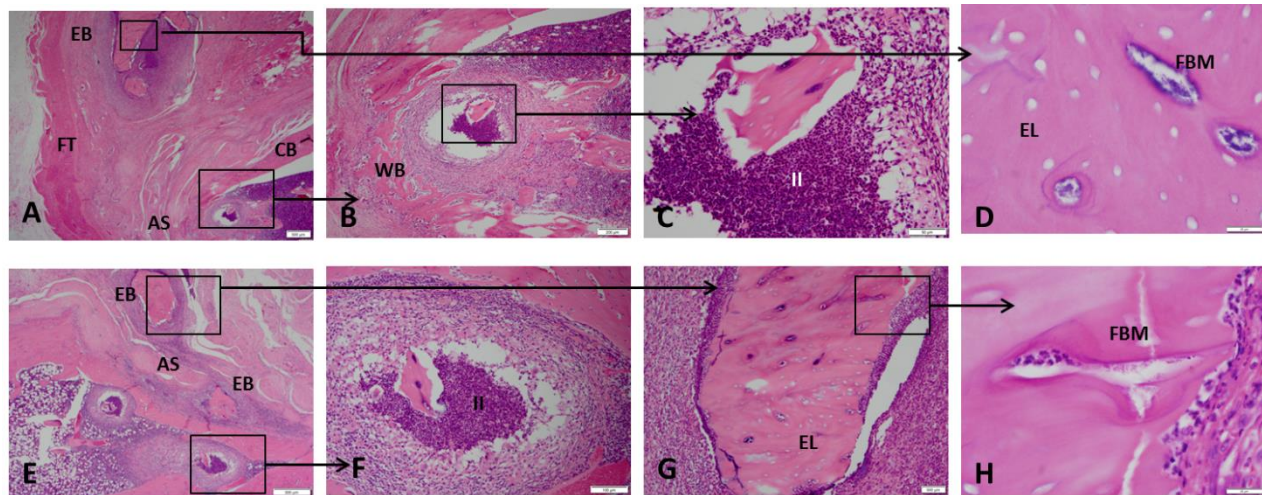


Figure 4A-H The histological features of ectopic bone formation in MRSA-treated rats at 12 weeks is shown in A-H (Stain, hematoxylin and eosin; A (1.25x magnification), B (4x; yellow boxed in region in A), C (20x; black boxed in region in B), D (100x; black boxed in region in A), E (2x), F (10x; yellow boxed in region E), G (10x; black boxed in region E) and H (10x; black boxed in region G)). For detailed evaluation, images of six selected regions at higher magnification are shown. In the medullary space and soft tissue, there is evidence of chronic inflammation, neutrophil infiltration, purulent infection, osteomyelitis, and necrotic ectopic bone as indicative of empty osteocytic lacunae containing bacterial microcolonies. AS = amputation site; CB = cortical bone; EL = empty lacunae; EB = ectopic bone; FBM = foci of bacterial microcolonies; FT = fibroblastic tissue; II = intramedullary infection; WB = woven bone.

neutrophil infiltration, chronic soft tissue infection, and osteomyelitis (foci of bacterial microcolonies, purulent intramedullary infection, and evidence of bone necrosis indicative of empty osteocytic lacunae with islands of necrotic endochondral bone throughout the skeletal muscle; Figure 4). All rats inoculated with *A baumannii* tested negative for the inoculated bacteria in both the soft tissue and bone marrow cultures. However, nine of 16 soft tissue samples and three of the 14 available bone marrow samples had positive cultures at 12 weeks with various bacterial flora species (Figure 3). En bloc resection of *A baumannii* residual limbs sent for histology showed

inflammatory cells indicative of chronic infection (data not shown); however, representative tissue sections (Figure 4) failed to capture the periosteal reaction and ectopic bone formation observed on micro-CT (Figure 2). No bacterial CFUs were detectable in the tissue cultures from vehicle-treated rats.

Conclusion: Our findings demonstrate that persistent infection with MRSA results in a greater volume of ectopic bone formation, which may be the result of chronic soft tissue inflammation, and that early wound colonization may be a key risk factor.

Interventions that mitigate wound contamination and inflammation (such as early débridement, systemic and local antibiotics) may also have a beneficial effect with regard to the mitigation of HO formation and should be evaluated with that potential in mind in future preclinical studies. Specific details regarding these studies and results were published in the scientifically peer-reviewed journal *Clinical Orthopaedics and Related Research* in 2015 (Pavey GJ, Qureshi AT, Hope DN, Pavlicek RL, Potter BK, Forsberg JA and Davis TA. 2015. Bioburden Increases Heterotopic Ossification Formation in an Established Rat Model. *Clinical Orthopaedics and Related Research* 473:2840-2847; Appendix 1).

Task 3b. Test drug effectiveness, regimens and systemic versus local delivery (months 8-30).

A. Early Characterization of Blast-related Heterotopic Ossification in a Rat Model

Objective: In order to optimize the timing of drug-based prophylactic intervention following blast-related combat injury, it is important to define the (1) early histological changes in soft tissue architecture, vascularity, collagen deposition and cartilage development and their correlation with later ectopic bone development following blast-related traumatic injury;(2) the blast-related gene expression patterns in traumatized tissues subsequent to calcium deposition, tissue mineralization and ectopic bone formation and (3) and the expression profile of early chondrogenic and osteogenic gene transcripts in traumatized tissue compare to early known proteomic indicators of ectopic bone development.

Methods: We used our established rat HO model consisting of blast exposure, controlled femur fracture, crush injury, and transfemoral amputation through the zone of injury. Postoperatively, rats were euthanized on Days 3 to 28. We assessed evidence of early ectopic bone formation by micro-CT and histology and performed proteomic and gene expression analysis.

Results: In this physiologic model of combat-related HO, blast exposure in the presence of severe extremity trauma produced μ CT radiographic evidence of HO within the soft tissue surrounding the fracture/amputation site in 100% of the animals within 28 days (Figure 5). We observed no radiographic evidence of neurogenic HO development (around joints and/or in the soft tissue distant from the fracture/amputation site) in our

model or in blast only-treated rats. Foci of proliferative/hypertrophic chondrocytes were observed in tissue surrounding the amputation site (Figure 6A-F) as early as 5 days and certainly by postoperative Day 10. By Day 14, endochondral ossification was evident because the ectopic chondrocyte-rich basophilic hyaline cartilage was replaced with acidophilic bone matrix (osteoid) later followed by the immature woven bone typical of HO arising from the process of endochondral ossification (Figure 2G-I). None of the contralateral limbs from blast-injured rats or limbs from sham-treated rats developed radiographic or histologic evidence of HO.

Genes involved in chondrogenesis (*COL1 α 1*), osteogenesis (*RUNX-2*, *OCN*, *PHEX*, and *POU5F1*), wound healing/tissue repair (*MMP9*, *CSF3*, *FGF-10*, and *HAS1*), and adipogenesis (*ADIPOQ* and *PPARG*) were notably overexpressed (greater than threefold) at the amputation site, whereas all angiogenic targets were unchanged (less than threefold) in comparison to quadriceps muscle tissue collected from the contralateral limb and sham-treated naïve rats (Figure 7). The *in vivo* tissue production of key osteogenic proteins *NOG* (6.78 ± 1.38 ng; 95% confidence interval [CI], 4.06-9.50; $p = 0.04$), *OCN* (6.54 ± 0.56 ng; 95% CI, 7.65-5.43; $p = 0.02$), and *RUNX-2* (7.76 ± 0.94 ng; 95% CI, 9.61-5.92; $p = 0.04$) were elevated at 3 days postinjury relative to normal muscle tissue collected from sham-treated naïve controls (Fig. 4A). In addition, we observed that the amount of the peripherally released neurotransmitter *SP-1* was higher in the injured limb at 3 to 7 days postinjury (0.2 ± 0.04 ng; 95% CI, 0.27-0.10; 0.32 ± 0.10 ng; 95% CI, 0.53-0.10; and 0.4 ± 0.13 ng; 95% CI, 0.67-0.12; per 30 mg of tissue) when compared with sham-treated naïve control muscle ($p = 0.002$, $p = 0.009$, and $p = 0.01$, respectively) and muscle collected from the contralateral leg, which was subjected only to blast-related trauma (Figure 8B). There were no differences observed in concentrations of neurokinin A, *CGRP*, or *BMP-2* (data not shown).

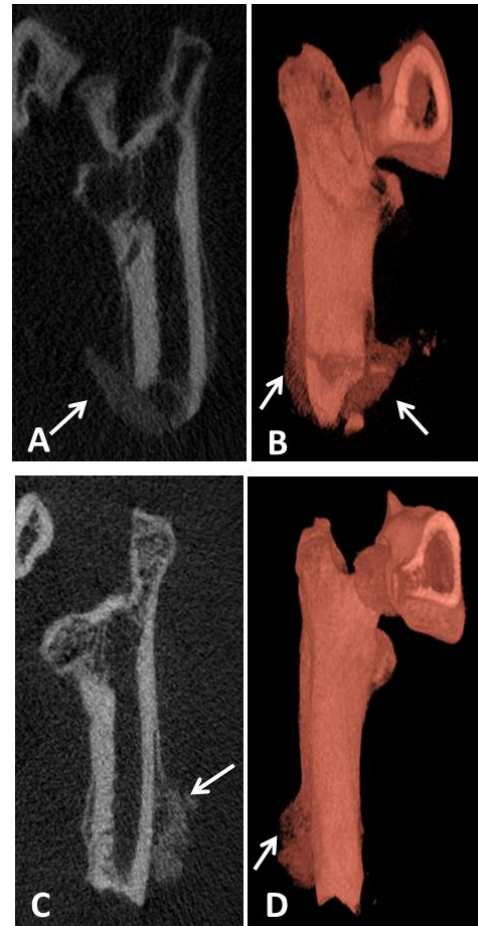


Figure 5A-D Representative μ CT and 3-D reconstructed images of rats euthanized at postinjury Day 21 (A-B) and Day 28 (C-D) are shown. The arrows indicate the formation of ectopic bone.

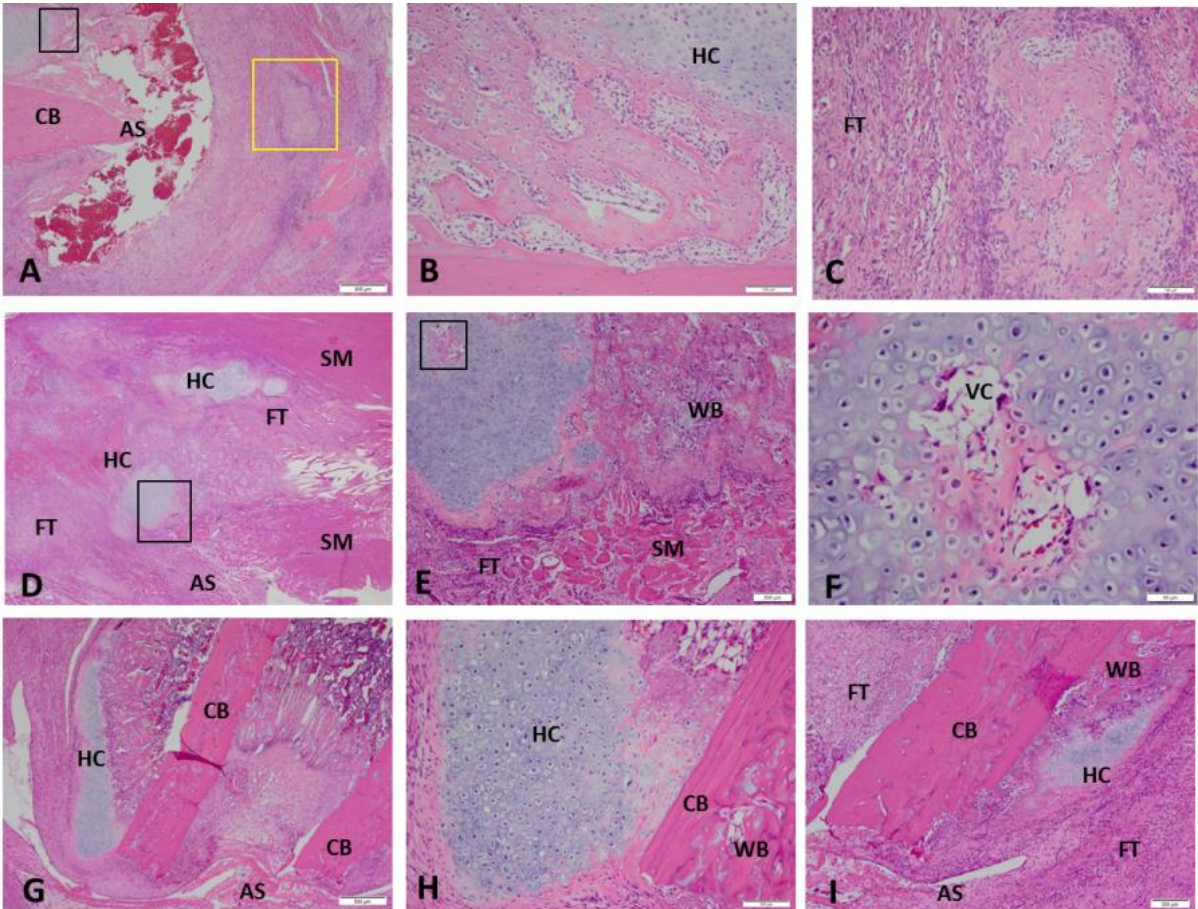


Figure 6A-I These images show the histological evidence of early HO formation at the site of amputation postinjury Day 7 (A-C), Day 10 (D-F), and Day 14 (G-I) (Stain, hematoxylin and eosin). For detailed evaluation, higher magnification images of five selected regions are shown. Panels B and C are high-magnification views of the areas outlined by the black inset box and yellow inset box in panel A, respectively. Panels E, F and H are high-magnification views of the areas outlined the black inset box in panels D, E and G, respectively. Foci of hyaline and vascularized cartilage with woven bone are observed in the soft tissue surrounding the site of amputation at postinjury Days 10 to 14. AS = amputation site; CB = cortical bone; FT = fibroblastic tissue; HC = hyaline cartilage; SM = skeletal muscle; VC = vascularized cartilage; WB = woven bone.

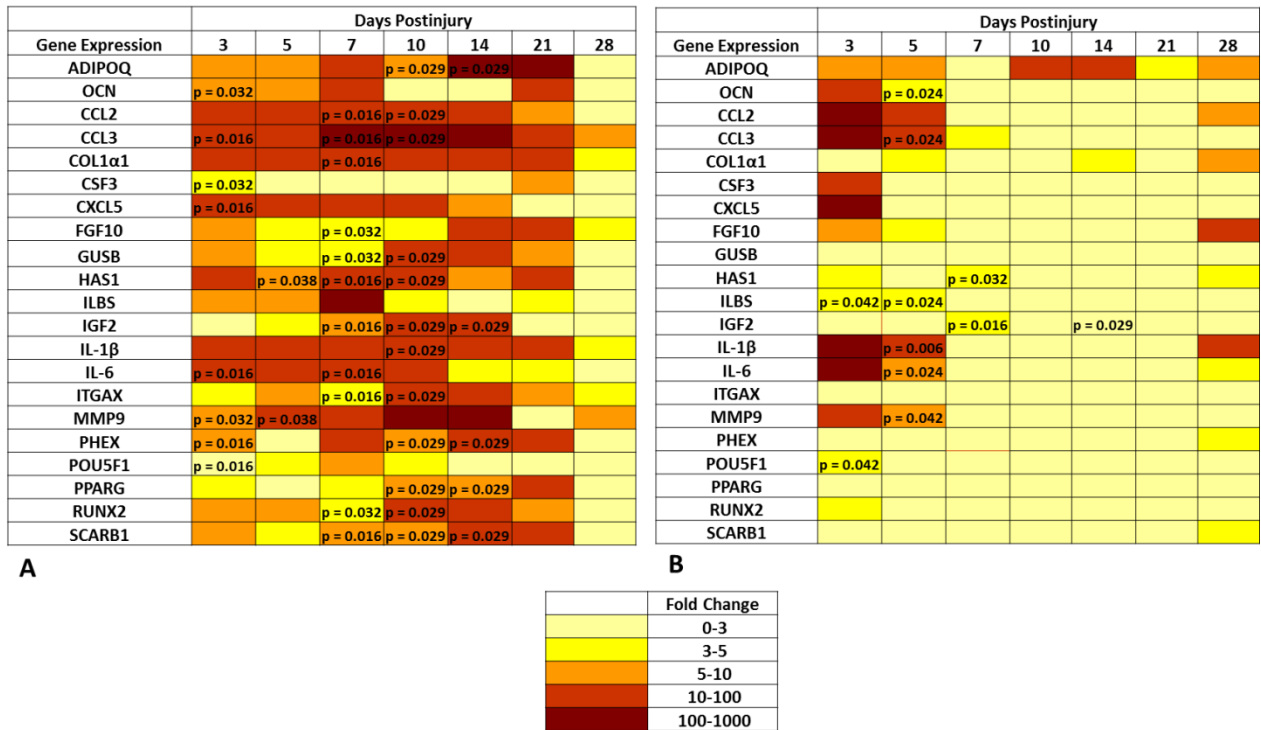


Figure 7A-B A transcript heat map depicting the expression level of the subset of the 83 rat chondrogenic, osteogenic, and angiogenic-related gene targets whose differential expression was greater than threefold compared with the expression level in sham-treated control muscle. (A) Contralateral leg and (B) injured leg and significantly different ($p < 0.05$; Mann-Whitney U-test) compared with sham-treated rats are noted with p values.

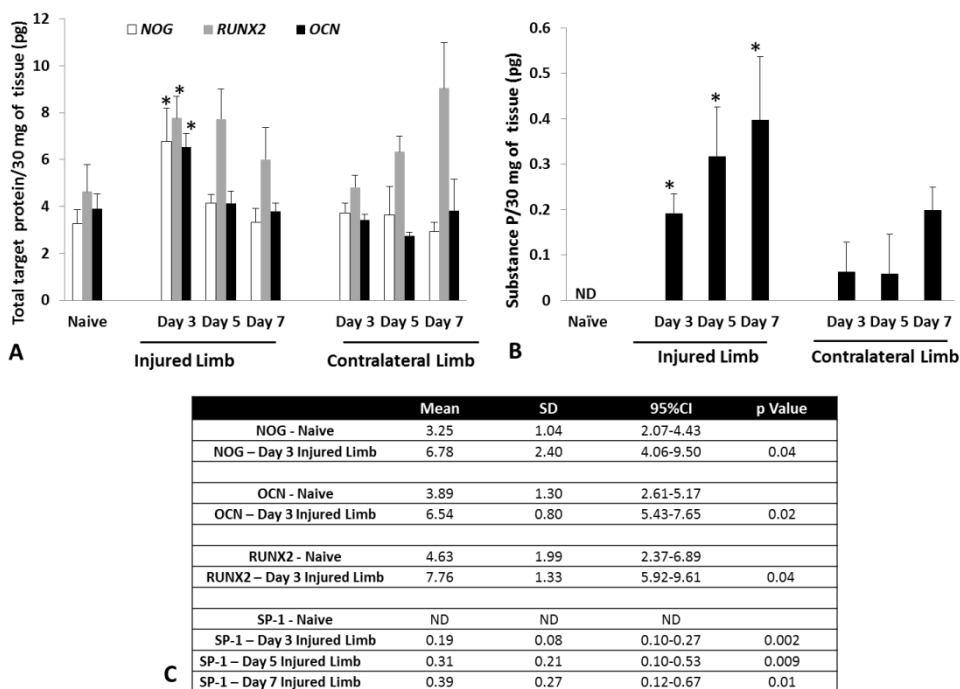


Figure 8A-C The amount of NOG, OCN, and RUNX-2 (A) and SP-1 (B) protein was quantified from tissue samples harvest at the site of amputation. (C) The levels of NOG, OCN, and RUNX-2 are statistically significant from the sham-treated (naïve) rats at 3 days postinjury, whereas the levels of SP-1 are significantly different from the sham-treated (naïve) rats at 3 to 7 days postinjury ($p < 0.05$; Student's t-test).

Conclusions: In these studies, we defined the histologic time course and pertinent molecular signaling patterns in the early stages of HO development using a rat model of combat-related HO that incorporates the critical elements associated with combat injury. Based on these findings, we propose that the initiation of prophylactic therapy targeted at inhibiting the synthesis of ectopic cartilage should start soon after injury in the rat to avoid any adverse effects on physiologic early wound healing processes such as tissue revascularization and granulation tissue development. The ability to correlate molecular events with histologic and morphologic changes will help researchers and clinicians to understand the HO process. In addition, ascertaining how applicable the findings are to the wound healing process in humans will be important in formulating therapeutic interventions that target early chondrogenic, angiogenic, and osteogenic signaling components of ectopic bone development. Specific details regarding these studies and results were published in the scientifically peer-reviewed journal *Clinical Orthopaedics and Related Research* in 2015 (Qureshi AT, Crump EK, Pavey GJ, Hope DN, Forsberg, JA and Davis TA. 2015. Early Characterization of Blast-Related Heterotopic Ossification in a Rat Model. *Clinical Orthopaedics and Related Research* 473:2831-2839: Appendix 2).

B. Effect of Palovarotene prophylactic treatment on preventing trauma-induced heterotopic ossification

Objective: Heterotopic Ossification (HO), which is the abnormal development of bone in nonosseous tissue, has been shown to be prevalent in 65% of blast-related combat extremity wounds involving amputations. Complications can be devastating, including skin ulceration, pain management crises, and prosthetic wear intolerance; all of which deteriorate rehabilitation and often lead to additional surgeries that can be wrought with complications. Furthermore, commonly used civilian prophylactic measures are generally contraindicated in the setting of combat and blast-induced trauma. Our research team has developed a small animal blast-related extremity trauma model that incorporates a combination of critical physiologic injury patterns sustained by combat casualties including blast exposure, extremity fracture, quadriceps crush injury followed by limb amputation through the zone of injury and contamination of the myodesis with a combat wound isolate of methicillin-resistant *Staphylococcus aureus* (MRSA). Using this model, we have demonstrated histologically and molecularly that early cartilage (chondrogenesis) and bone (osteogenesis) formation is established at about 7-10 days following injury. We now have a well-characterized model of HO whereby the timing of treatment and efficacy of prophylactic therapeutics can be rigorously evaluated in a clinically relevant animal model. One such candidate drug, retinoic acid- γ receptor (RAR- γ) agonist (Palovarotene), has been shown to mitigate a BMP-2 induced ectopic endochondral bone formation and inhibit cartilage vascularization in a non-trauma injury model in mice. Expanding on these findings, we sought to evaluate the efficacy and applicability of Palovarotene in preventing ectopic bone formation in our blast-trauma model.

Methods:

A total of 110 young adult pathogen-free male Sprague Dawley rats (*Rattus norvegicus*; 400-600g) were purchased from Taconic Farms (Germantown, NY) and then randomized into experimental and control groups. Exposure to blast and trauma-induced injury was conducted as previously described in the studies discussed above. Briefly, 106 rats were anesthetized with isoflurane (2-4%) and were exposed to blast overpressure (120 ± 7 kPa) via a pneumatically-driven shock tube. They sustained a controlled femoral fracture followed by a one minute soft tissue crush injury, limb amputation through the zone of injury and inoculation of the local soft tissue with 1×10^6 CFU MRSA. Appropriate débridement of devitalized tissue was performed followed by hamstring and quadriceps myoplasty over the exposed residual femur. The incision was closed with 2 interrupted deep subcutaneous 3-0 Vicryl (Ethicon, Somerville, NJ, USA) sutures and a running 4-0 subcuticular Monocryl (Ethicon, Somerville, NJ, USA). The incision was then

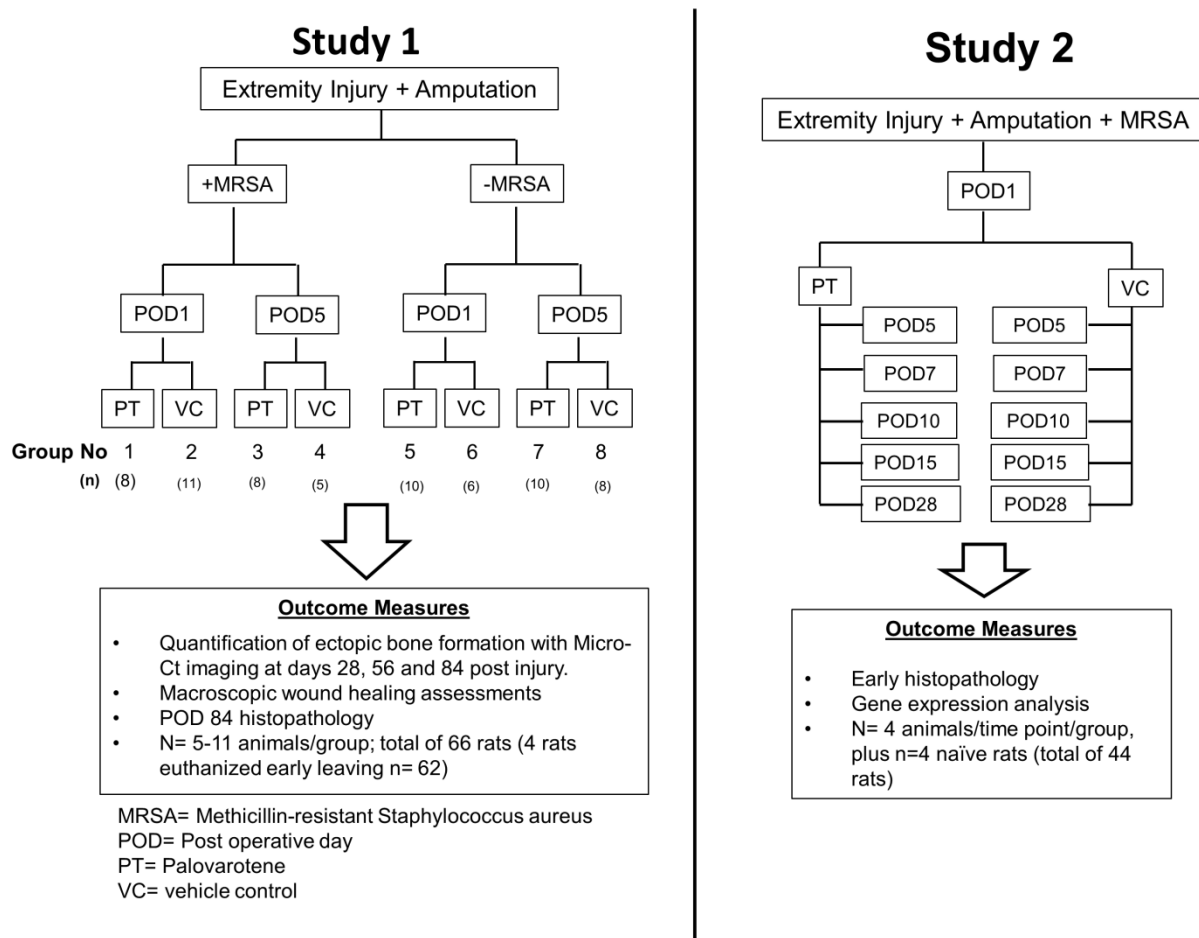


Figure 9: Schematic outline of the experimental studies and outcome measures. The number of rats analyzed in each treatment group is indicated.

covered in Vetbond (3M Animal Care Products, St Paul, MN, USA). Post-surgically, sustained release Buprenorphine (1.2mg/kg) was administered subcutaneously on day of surgery and again on post-operative day 3 for peri-operative pain control. Rats received via oral gavage (100 μ l) either Palovarotene (1.0 mg/kg) or vehicle as control (5% DMSO in corn oil) prepared as previously described [25] every other day for 14 days, starting at postoperative day 1 (POD-1) or POD-5. Rats were euthanized at indicated time points post-injury for ex vivo end point analysis by micro-computed CT (μ CT), histology and RT-PCR gene transcript expression.

Experimental Study 1: To determine the efficacy of Palovarotene in inhibiting ectopic bone formation, 66 rats were randomized into 1 of 8 treatment groups to monitor the development of HO formation longitudinally and non-invasively by μ CT at 28, 56 and 84 days after injury. All rats were subjected to polytraumatic extremity injury \pm MRSA infection. Group-1 received MRSA + Palovarotene treatment starting at POD-1 (n=8); Group-2 received MRSA + vehicle control starting at POD-1 (n=11); Group-3 received MRSA + Palovarotene treatment starting at POD-5 (n=8); Group-4 received MRSA + vehicle control starting at POD-5 (n=5); Group-5 received Palovarotene treatment starting at POD-1 (n=10); Group-6 received vehicle control starting at POD-1(n=6); Group-7 received Palovarotene treatment starting at POD-5 (n=10) and Group-8 received vehicle control starting at POD-5 (n=8). Four rats were sacrificed early, two rats each in Group-5 and Group-7 for losing >15% of their body weight, leaving a total of 62 in the observational study (Figure 9A).

Experimental Study 2: In a follow-on study, an additional 40 blast trauma and extremity injured rats with MRSA contaminated wounds were treated with either Palovarotene or vehicle control beginning on POD-1 (Groups 1-2). Rats from each group were randomly euthanized at days 5, 7, 10, 15, and 28 days post injury (n=4 rats per time point/treatment group) (Figure 9B). Soft tissue surrounding but not attached the distal portion of the residual femur was collected for histological and gene expression analysis. Four rats served as sham-treated, uninjured naïve rats to obtain healthy skeletal muscle tissue for gene expression analysis.

Progression of ectopic bone development at the site of amputation was tracked by imaging the amputated limb on days 28, 56 and 84 post injury using an in vivo high-resolution micro-computed tomography (μ -CT) system (SkyScan 1176; Bruker-MicroCT, Kontich, Belgium) and a standard phantom for normalization. As previously described [13], after the rats were scanned at the mentioned time points, the scanned images from Skyscan software were rendered using NRecon Reconstructions software (Bruker-MicroCT, Kontich, Belgium) to obtain serial flattened longitudinal micro-CT slices. An investigator reviewed all these serial longitudinal micro-CT flattened images at every time point, narrowed the region that encompassed the residual femur and ectopic bone and selected regions of interest (ROI) on every fifth slice to capture all new bone (new bone associated and non-associated with the cortical margins) as well as “soft tissue ectopic bone” (ectopic bone with no association to the cortical bone margins). The three-

dimensional image analysis was performed of all the flattened images with ROI yielding a volumetric measurement of total new ectopic bone and “soft-tissue” ectopic bone based on the selected area of interest.

For histological examination, cohorts of rats at the specified time points were euthanized (Fatal Plus 50 mg/kg IP; Patterson Veterinary, Devens, MA) and disarticulation of the hip was performed to collect the residual limb, which was washed with saline thoroughly then fixed in 10% neutral buffered formalin and subsequently decalcified in 5% formic acid. After complete decalcification, tissues were embedded in paraffin wax, cut into serial 5µm thick longitudinal sections using a microtome and mounted onto glass slides for histology. Sections were used for immunohistochemistry or stained using hematoxylin-eosin (H&E) (Histoserv, Inc., Germantown, MD).

At indicated time points, skeletal muscle tissue collected from the extremity wound, specifically surrounding the amputation site (not set against the bone), and the corresponding distal quadriceps muscle of the contralateral limb were harvested and stored in RNALater (Ambion Inc, Austin, TX, USA) at 4°C. Skeletal muscle samples obtained from age-matched naïve uninjured rats (n=4) served as control tissue. Total RNA was isolated and purified muscle cell lysates using RNeasy columns and DNase-I kits (Qiagen, Valencia, CA, USA) according to the manufacturer’s protocols. RNA was stored at –80°C in nuclease-free water (Bio-Rad, Hercules, CA, USA). Total RNA was quantified spectroscopically by using NanoDrop 1000 (ThermoFisher Scientific, Waltham, MA) and RNA integrity/quality was assessed by microcapillary electrophoresis using an Agilent 2100 Bioanalyzer (Agilent Technologies, Santa Clara, CA). Reverse transcriptase polymerase chain reaction (RT-PCR) was used to convert 1 µg of RNA to cDNA. mRNA transcripts for 83 key genes involved in early chondrogenic, osteogenic and angiogenic signaling pathways (see Supplementary Table 1 for the complete list of genes and their function) were examined by real-time PCR using a custom low density microarray (Bio-Rad Laboratories, Hercules, CA) [16]. Relative gene transcript expression was calculated using the $2^{-\Delta\Delta C_t}$ method and normalized and compared to the gene expression levels of non-injured rat muscle tissue. Gene transcripts values that were significantly differentially expressed between treatment groups are reported.

Results:

A. Palovarotene mitigates post traumatic ectopic bone formation

To test the effectiveness of Palovarotene against blast-induced HO, rats were subjected to whole body blast exposure, femur fracture and crush injury that were followed by amputation of affected limb site and inoculation (or not) of local MRSA. Rats were then

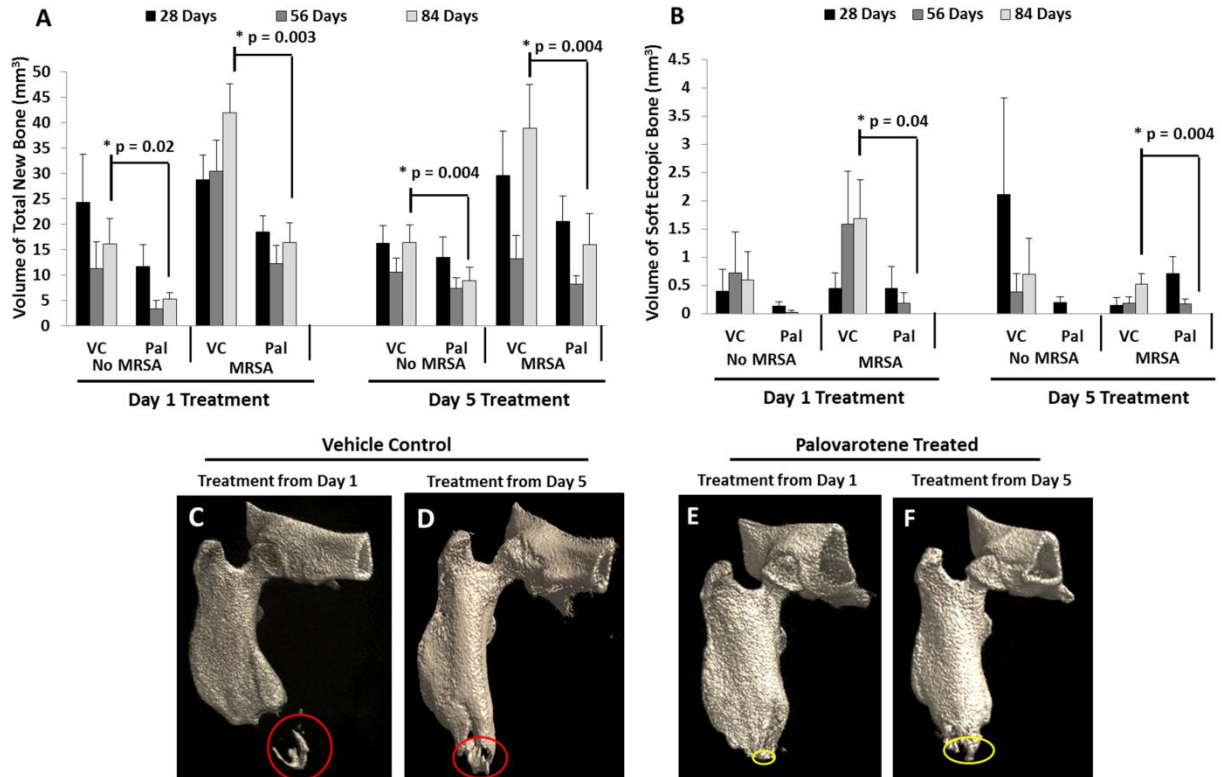


Figure 10: Palovarotene treatment inhibits heterotopic ossification. Analysis and quantification of (A) total new bone and (B) soft tissue ectopic bone volume using the flattened μ -CT images at 28, 56 and 84 days after blast, extremity injury, amputation \pm MRSA (*= $p < 0.05$ using the Welch's two Sample t-test). Representative 3D reconstructed μ CT images of residual amputated limbs from vehicle control (C-D) and Palovarotene (E-F) treated rats at 84 days post injury after blast, extremity injury, and limb amputation with MRSA infection. Red circles indicate soft tissue ectopic bone and yellow circles indicate calcaneal ectopic bone.

administered the drug or vehicle starting every other day for 14 days starting on either postoperative day 1 (POD-1) or POD-5 and were then monitored up to 84 days post-injury. Volumetric assessment of bone formation using μ CT demonstrated significant difference with respect to total new bone volume at the distal end plus ectopic bone outside of cortical margins Figure. 10A) and soft-tissue ectopic bone volume (Figure. 2B) at 84 days (12-weeks) between the vehicle control group and the Palovarotene group. When treatment started at POD-1 in the absence of MRSA, Palovarotene significantly inhibited the formation of trauma-induced total new bone and soft-tissue ectopic bone formation at 84 days post injury from $16.2 \pm 4.9 \text{ mm}^3$ to $5.3 \pm 1.3 \text{ mm}^3$

($p=0.02$; 67% mitigation) and from $0.6 \pm 0.4 \text{ mm}^3$ to no detectable ectopic bone formation ($p=0.04$; 100% inhibition) respectively, as revealed by μ CT imaging and quantification (Figures 10A & 10B). When Palovarotene was administered from POD-5 in the absence of MRSA, it was still effective but less so, causing a decrease of total new bone and soft-tissue ectopic bone from $16.4 \pm 3.4 \text{ mm}^3$ to $8.9 \pm 2.5 \text{ mm}^3$ ($p=0.004$; 46% inhibition) and from $0.7 \pm 0.6 \text{ mm}^3$ to no detectable ectopic bone formation after treatment (100 % inhibition) (Figs. 2A & 2B). MRSA infection is a likely risk factor in combat settings and a known potentiator of trauma-induced HO [13]. In the presence of MRSA infection (Figures. 10B-F) and regardless of when treatment was started, Palovarotene was still able to decrease the volume of total new bone by 84 days post injury by 59-74%. When the Palovarotene treatment initiated at POD-1, the volume of total new bone and soft-tissue ectopic bone decreased from $41.9 \pm 5.6 \text{ mm}^3$ in controls to $16.4 \pm 3.9 \text{ mm}^3$ ($p=0.003$; 61% attenuation) and from $1.68 \pm 0.6 \text{ mm}^3$ to no detectable ectopic bone formation after treatment ($p=0.04$; 100% inhibition), respectively. For the POD-5 treatment, the volume of total new bone and soft-tissue ectopic bone decreased from $38.9 \pm 8.5 \text{ mm}^3$ to $16.0 \pm 6.6 \text{ mm}^3$ ($p=0.004$; 61% attenuation) and from $0.52 \pm 0.19 \text{ mm}^3$ to no detectable ectopic bone formation after treatment ($p=0.004$; 100% inhibition), respectively (Figures 10A & 10B).

B. Palovarotene suppresses post-traumatic chondrogenesis and osteogenesis

Given that the rat blast model causes broader and more encompassing damage and complications compared to the more benign HO mouse models we used previously, it became important to determine the tissue level and phase of HO progression at which Palovarotene was able to inhibit HO in this model. Thus, we collected affected tissues around the amputated area of the limbs at day 15, 28 and 84 from the initial blast injury and processed them for histochemical analyses. In vehicle control samples, the amputated area at days 15 and 28 displayed obvious signs of an ongoing and active endochondral ossification process, with foci of immature and hypertrophying cartilage (Figures 11A-C), numerous surrounding cells exhibiting progenitor characteristics, acidophilic osteoid matrix and immature woven bone (Figures 11D-F). These ectopic tissues were all intimately embedded into surrounding tissues and most clearly, skeletal muscles. At 84 days post injury, masses of mature ectopic bone and marrow were present and often became surrounded by fibrous tissue to form a necrotizing pyogranuloma, a sign of ectopic bone resorption/remodeling (Figures 11G-I). Areas of inflammation with foci of intense bacterial multiplication and necrosis (abscesses) were present in the soft tissue as well. In comparison, specimens obtained from Palovarotene-treated rats showed clear decrease in the amount of detectable immature cartilage and vascularized hypertrophying cartilage at each time point examined (Figures 11J-L). In place of these skeletogenic tissues, we invariably observed the presence of extensive areas of fibrous connective tissues that were particularly obvious at day 28 post injury (Figures 11M-O). At the end of the study at 84 days post injury, histological investigation showed that the medullary cavity was largely filled with similar fibrous connective tissue (Figures 11P-R).

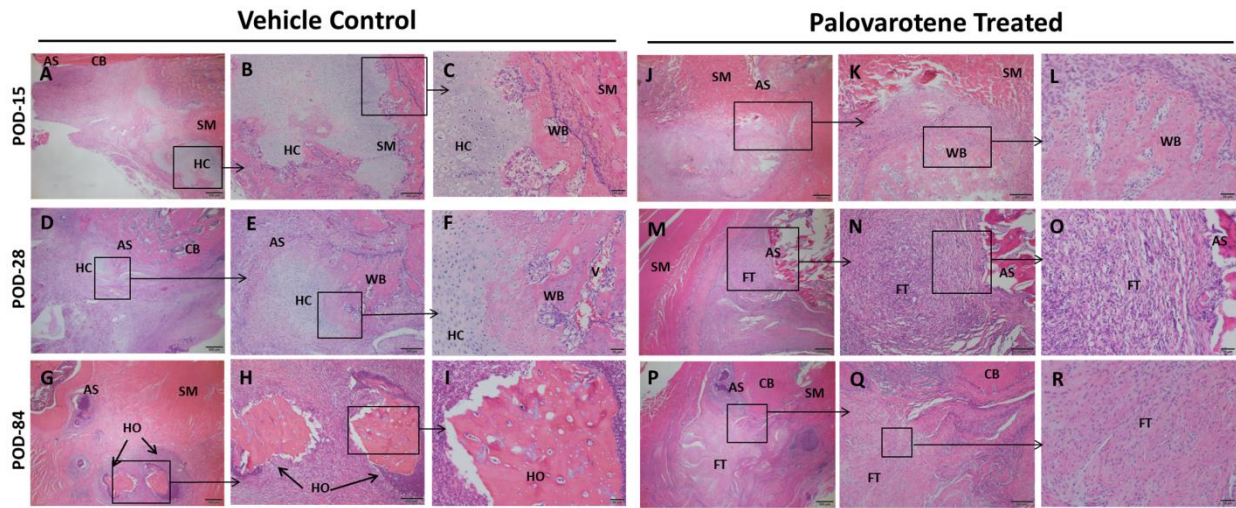


Figure 11: Palovarotene treatment inhibits the initial phases of HO. Histologic and microscopic assessment of HO formation in vehicle- control rats at 15 days (A-C), 28 days (D-F) and 84 days (G-I), and in Palovarotene treated rats at 15 days (J-L), 28 days (M-O) and 84 days (P-R) post injury. CB = cortical bone, AS = amputation site; FT = fibroblastic tissue; HC = immature and hypertrophying cartilage; SM = skeletal muscle; WB = woven bone; V = vascularization and HO = heterotopic ossification. The scale bars in the images (A), (D), (G) (M) and (P) correspond to 500 μ m. Scale bars in images (B), (E), (H), (K), (N) and (Q) corresponds to 200 μ m. Scale bars in images (C), (F), (I), (L), (O) and (R) correspond to 50 μ m.

C. Expression of chondrogenic and osteogenic gene markers is decreased in blast site-tissues from Palovarotene-treated rats

To assess the regulatory levels at which Palovarotene exerted its apparent anti-HO effects, we analyzed the expression of 83 genes associated with early chondrogenic, osteogenic and angiogenic processes related to bone development in blast site-samples collected from vehicle control and Palovarotene-treated rats at day 5, 7, 10, 14 and 28 from injury. As the local skeletal muscles were affected by the blast and were the major site of ectopic bone development; the harvested samples contained soft tissue immediately surrounding the residual femur but not set against the bone. Gene transcript values were normalized to expression levels found in uninjured skeletal muscle obtained from age-matched naïve rats. Samples collected at day 5-14 from injured limbs of vehicle-treated rats displayed significantly higher expression levels of key chondrogenic and osteogenic genes than samples from companion Palovarotene-treated rats (Figure 12). The chondrogenic genes included *SOX9* ($p = 0.01$ on POD-7 and $p = 0.02$ on POD-10) and collagen 2 (*COL2 α 1*, $p = 0.01$ on POD-10) (Figures 12A-B), and the osteogenic genes included osteocalcin (*OCN*, $p = 0.02$ on POD7 and POD-10), *RUNX-2* ($p = 0.003$ on POD-5), osteogenic transcription factors *POU5F1* ($p = 0.01$ on POD-10), Osteopontin (*OPN*, $p = 0.049$ on POD-7), bone morphogenetic protein-2 (*BMP-2*, $p = 0.04$ on POD-7) and bone morphogenetic protein-4 (*BMP-4*, $p = 0.02$ on POD-7) (Figures 12C-H). In contrast to the decreases in chondrogenic and osteogenic genes, the samples from Palovarotene-treated animals displayed significantly higher

expression of matrix metalloproteinase-9 (*MMP9*; $p = 0.02$ on POD-14), an enzyme involved in the degradation of cartilage extracellular matrix (Figure 12I).

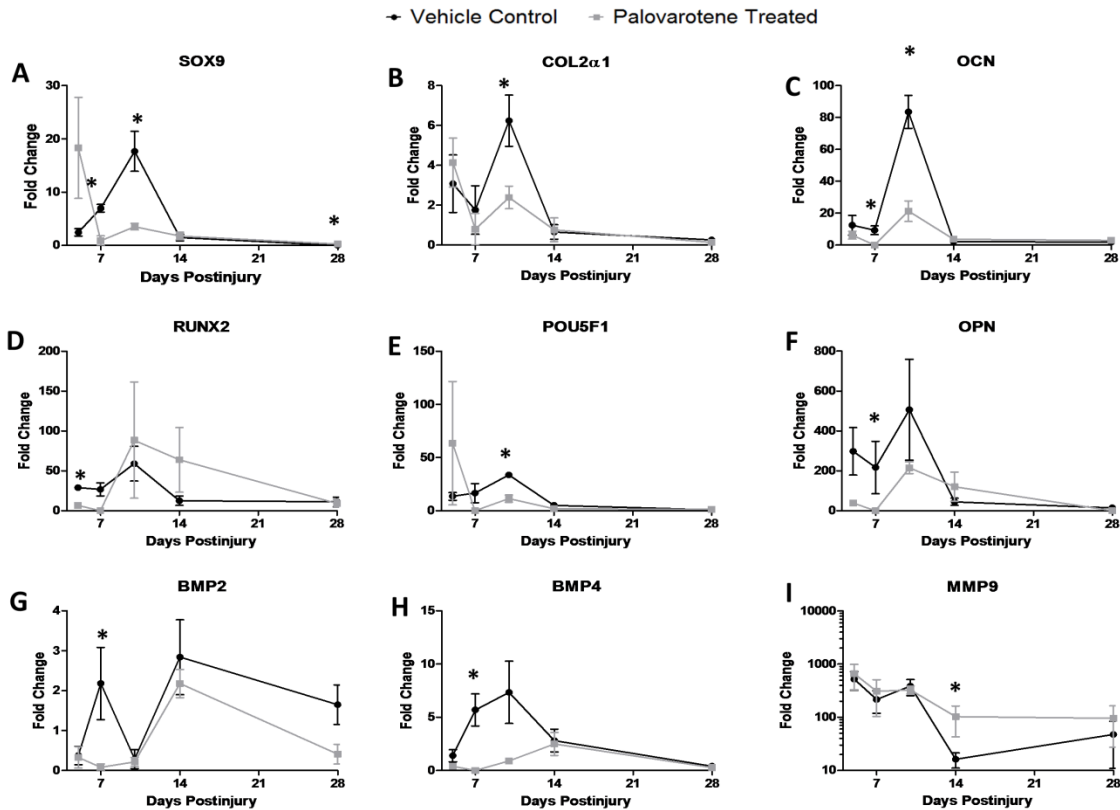


Figure 12. Effects of Palovarotene treatment ($n=4$) and vehicle control ($n=4$) on chondrogenic (A-B) and osteogenic (C-H) related gene targets and matrix metalloproteinase-9 (I) gene expression. The fold change values were calculated by normalizing the values to the samples from non-injured muscle rats. Significantly different changes in gene expression are noted with an asterisk (*) ($p < 0.05$; Mann-Whitney U-test).

Conclusions:

We demonstrate for the first time that Palovarotene is a strong inhibitor of HO in blast-associated rat model of combat-related extremity injury. This model is both severe and encompassing and includes not only the initial blast injury, but also compounding complications often occurring in combat situations, including bacterial infections and/or limb amputation. In each permutation, Palovarotene was able to counteract HO and did

so in a significant manner, with an average of 50 to nearly 70% inhibition. This result is particularly impressive and promising given that Palovarotene was given every other day for 14 days starting on either POD-1 or POD-5 after blast injury, but HO was measured at later time points, which is critical in order to ensure that late recurrence or maturation of HO does not occur following cessation of treatment. Our data indicate that the developmental step of HO mostly affected by Palovarotene is the early chondrogenic phase. This is in line with the fact that retinoid agonists are particularly effective inhibitors of chondrogenesis. Such effect on an early phase of HO can also explain why Palovarotene was so effective against HO; by inhibition chondrogenesis, the drug was able to inhibit the subsequent osteogenic phases of the process. Our data here are also in agreement with our previous analysis of drug-based HO therapy in mouse models.. It is possible that Palovarotene may redirect the commitment and lineage assignment of stem and progenitor cells recruited to the injure blast site, leading them to enter a fibrogenic phenotype to promote and facilitate local tissue healing and regeneration and in turn scar formation. We do detect a robust production of fibrotic connective soft tissue surrounding the amputation site in Palovarotene-treated rats, but it remains unclear whether the drug is able to influence and direct the differentiation of locally-recruited progenitor cells by direct mechanisms or indirect processes and signals occurring within the injured area.

Task 3c. Analyze wound healing and muscle repair (18-36 months)

A. Palovarotene may have moderate inhibitory effects on wound healing

For the Palovarotene studies discussed above daily observational measurements were conducted by veterinary and research staff for clinical evidence of wound complications to include purulent infection, physiological distress, and superficial (not past the dermis, treated with observation) wound or frank (deep, treated with debridement and secondary surgical closure) dehiscence. We specifically quantified

negative effects on wound healing by comparing the proportion of wounds that were not completely healed at 14 days post-injury with

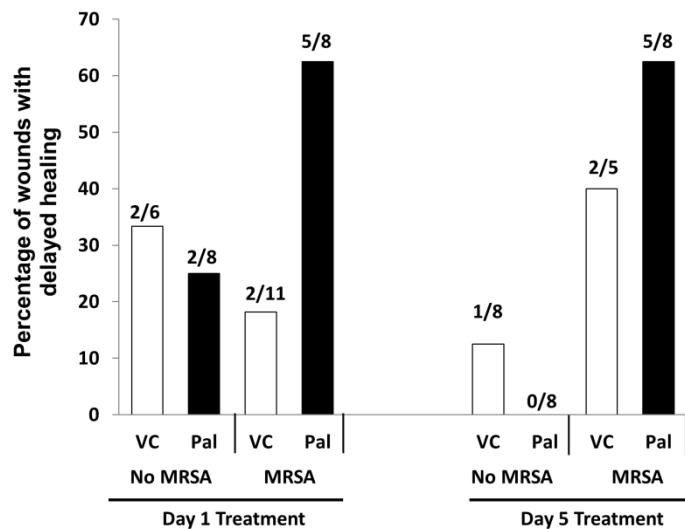


Figure 13: Percentage of wounds that dehisced and were not completely healed by 14 days post-injury. The number of wounds with delayed healing in each treatment group is indicated.

Palovarotene versus vehicle control and treatment timing, with and without MRSA inoculation. Wounds which required repeat surgery were considered to have delayed healing at 14 days even if the suture line was intact at this time point; however, superficially dehisced wounds were considered either healed or delayed based upon the presence or absence of complete epithelialization at 14 days. As indicated above, bacterial infections are common in combat casualties, but wounded service members also suffer from additional injuries including damaged soft tissues and skin. We did not observe overt differences in common macroscopic wound complications such as surgical site bleeding, skin rashes, erosions, necrosis, abscesses, purulent drainage, and wound infection. However, we also quantified delayed wound healing by determining the proportion of wounds that were not completely healed by 14 days post-injury due to either persistent superficial dehiscence or frank dehiscence requiring surgical debridement and secondary closure (Figure 13). Overall, in response to any Palvarotene treatment, irrespective of MRSA contamination, 38% (12/32) of the wounds dehisced versus 23% (7/30) of the wounds in the vehicle control group ($p = 0.28$). However, amongst rats treated with Palovarotene and inoculated with MRSA, 63% (10/16) of rats experienced delayed healing or dehiscence irrespective of treatment timing, whereas 25% (4/16) of MRSA rats treated with vehicle control demonstrated delayed healing or dehiscence ($p = 0.07$).

Conclusions: The safety and tolerability of a candidate HO therapeutic agent must be considered in balance with its clinical efficacy. The ideal agent would not only prevent HO in trauma patients, but would also need to limit its effects on other concomitant injury patterns, such as the early tissue reparative and regenerative processes involved in the healing of complex wounds or fractures. Previous research demonstrates that one potential mode of action of Palovarotene is the dampening of neovascularization during early chondrogenesis. Impaired angiogenesis during the early wound healing process places the healing wound bed at theoretical risk of delayed or incompetent healing, prompting dehiscence. In our study, we observed a trend toward wound complication in the Palovarotene-treated groups, but the difference was not statistically significant. Defining the overall risk-benefit profile for Palovarotene with an in-depth and properly powered study is critical. Wounds that fail to heal often do so in the setting of persistent chronic infection (angiogenesis-dependent processes), which was the case in a large proportion of the MRSA-infected animals in our study. Future work will be directed toward studies assessing whether the therapeutic application of Palovarotene to prevent HO formation might potentially be associated with impaired wound vascularization and tissue repair if given for longer periods of time and/or different doses and frequencies

KEY RESEARCH ACCOMPLISHMENTS

- Characterized the effects of bioburden, specifically *Acinetobacter Baumannii* and Methicillin Resistant *Staphylococcus Aureus* (MRSA) infection, on the rate development and severity of ectopic bone formation (HO).
- Defined the early cellular and molecular signaling development phases of HO development in the blast-related HO model.
- Determined the optimal window for prophylactic therapy
- Based on collective research findings, we have defined the therapeutic window for targeting early chondrogenesis, vasculogenesis and osteogenesis to inhibit the synthesis of cartilage and early ectopic bone formation without adverse effects on physiologic early wound healing processes such as tissue revascularization and granulation tissue development.
- Demonstrated that the administration of palovarotene appears to total inhibit soft-tissue ectopic bone formation when administered orally every other day for 2-weeks starting as late as 5-days post injury.

CONCLUSION Palovarotene administered shortly following trauma may act to preclude the proliferation and further differentiation of chondrocytes during early endochondral ossification. This intervention may therefore represent a promising prophylactic therapy against ectopic bone formation. To our knowledge, this is the first study to demonstrate the applicability of a drug that can mitigate the formation of ectopic bone in a trauma-induced injury model without interfering with wound healing reparative processes; however the effects on bone healing following fracture require further study.

There are several critical questions that the present studies did not address. First, we did not test the effects of Palovarotene on normal healing of long bone fractures, which occurs via endochondral ossification, the known mechanistic target of the drug. The feasibility of using this drug in a model containing concomitant long bone fractures is a focus of an ongoing study. While clarifying the effect on long bone fracture healing is important, we know that there is no ectopic bone attenuation efficacy rebound effect with the use of Palovarotene, and therefore a clinically acceptable treatment plan might include initiation of treatment in the early post-injury period to disrupt HO development, and then to stop treatment prior to definitive fracture fixation to permit unimpeded fracture healing. Temporizing fracture fixation could be initiated to maintain length and stability in the interim and portend a clinically acceptable outcome provided the fractures eventually go on to heal within an acceptable timeframe. Nevertheless, patients with bilateral lower extremity amputations, particularly those without upper extremity or spine

fractures, could represent a specific cohort that would most markedly benefit from early Palovarotene administration. Second, we have not yet identified the mechanism responsible for the alteration of endochondral ossification caused by Palovarotene administration leading to a fibroblastic rather than osteoblastic endstate. Lastly, we need to further refine the dosing regimen of Palovarotene and determine whether the observed efficacy effects were either due to initiating the treatment earlier at POD-1 or selecting a narrow treatment window (14 days post injury) to specifically target endochondral ossification in the development of ectopic bone. With this knowledge, we can refine our treatment window for desired effect for the attenuation of ectopic bone formation in traumatized tissue without prolonging delays in endochondral ossification elsewhere in the body.

PUBLICATIONS, ABSTRACTS, AND PRESENTATIONS:

Lay Press

None

Peer-Reviewed Scientific Journals

- Qureshi AT, Crump EK, Pavey GJ, Hope DN, Forsberg, JA and Davis TA. 2015. Early Characterization of Blast-Related Heterotopic Ossification in a Rat Model. *Clinical Orthopaedics and Related Research* 473:2831-2839.
- Pavey GJ, Qureshi AT, Hope DN, Pavlicek RL, Potter BK, Forsberg JA and Davis TA. 2015. Bioburden Increases Heterotopic Ossification Formation in an Established Rat Model. *Clinical Orthopaedics and Related Research* 473:2840-2847.
- Pavey GJ, Qureshi AT, Tomasino AM, Honnold CL, Bishop DK, Agarwal S, Loder S, Levi B, Pacifici M, Iwamoto M, Potter BK, Davis TA, Forsberg JA. 2016. Targeted stimulation of retinoic acid receptor- γ mitigates the formation of heterotopic ossification in an established blast-related traumatic injury model. *Bone*. 90:159-167.

Invited Articles

Nothing to report.

Abstracts

- Gabriel J. Pavey, Ammar T. Qureshi, Allison Tomasino, Danett Bishop, Maurizio Pacifici, Mashahiro Iwamoto, Benjamin K. Potter, Thomas A. Davis, Jonathan A. Forsberg. Targeted stimulation of retinoic acid receptor signaling mitigates the

formation of heterotopic ossification in an established blast-related traumatic injury model. Oral Presentation- Military Health System Research Symposium (MHSRS) 2015. Oral Presentation.

- Gabriel J. Pavey, Ammar T. Qureshi; Donald N. Hope, Rebecca L. Pavlicek, Benjamin K. Potter, Thomas A. Davis, Jonathan A. Forsberg. Evaluation of Bioburden on the Development of Heterotopic Ossification in an Established Rat Model. Military Health System Research Symposium (MHSRS) 2015. Poster Presentation.
- Gabriel J. Pavey, Ammar T. Qureshi, Allison M. Tomasino, Danett Bishop, Maurizio Pacifici, Mashahiro Iwamoto, Benjamin K. Potter, Thomas A. Davis, Jonathan A. Forsberg. Targeted Stimulation of Retinoic Acid Receptor Signaling Mitigates the Formation of Heterotopic Ossification in an Established Blast-Related Traumatic Injury Model. Orthopedic Trauma Association, San Diego, CA. October 7-10, 2015. (15-112).
- Gabriel J. Pavey, Ammar T. Qureshi, Allison M. Tomasino, Danett Bishop, Maurizio Pacifici, Mashahiro Iwamoto, Benjamin Levi, Carry L. Honnold, Benjamin K. Potter, Thomas A. Davis, Jonathan A. Forsberg. Targeted Stimulation of Retinoic Acid Receptor Signaling Mitigates the Formation of Heterotopic Ossification in an Established Blast-Related Traumatic Injury Model. Orthopaedic Research Society (ORS), Orlando, FL.2016. Invited Poster Presentation. March 5-8, 2016. (16-083).
- Jonathan A. Forsberg, Gabriel J. Pavey, Ammar T. Qureshi, Allison M. Tomasino, Thomas A. Davis, Maurizio Pacifici, Benjamin Levi, Benjamin K. Potter. Does Stimulation of Retinoic Acid Receptor Signaling Mitigate the Formation of Heterotopic Ossification in a Small Animal Model? Association of Bone and Joint Surgeons, Auckland, NZ. April 5-8, 2016. (16-073).
- Gabriel J. Pavey, Ammar T. Qureshi, Allison M. Tomasino, Danett Bishop, Maurizio Pacifici, Mashahiro Iwamoto, Benjamin Levi, Carry L. Honnold, Benjamin K. Potter, Thomas A. Davis, Jonathan A. Forsberg. Targeted Stimulation of Retinoic Acid Receptor Signaling Mitigates the Formation of Heterotopic Ossification in an Established Blast-Related Traumatic Injury Model. First International Symposium on Innovations in Amputation Surgery and Prosthetic Technologies (IASPT), Chicago, IL. May 12-13, 2016. (16-388).

Presentations (* oral presentation)

- *Gabriel J. Pavey, Ammar T. Qureshi, Allison Tomasino, Danett Bishop, Maurizio Pacifici, Mashahiro Iwamoto, Benjamin K. Potter, Thomas A. Davis, Jonathan A. Forsberg. Targeted stimulation of retinoic acid receptor signaling mitigates the

formation of heterotopic ossification in an established blast-related traumatic injury model. Oral Presentation- Military Health System Research Symposium (MHSRS) 2015

- Gabriel J. Pavey, Ammar T. Qureshi; Donald N. Hope, Rebecca L. Pavlicek, Benjamin K. Potter, Thomas A. Davis, Jonathan A. Forsberg. Evaluation of Bioburden on the Development of Heterotopic Ossification in an Established Rat Model. Military Health System Research Symposium (MHSRS) 2015.
- *Ammar T. Qureshi, Gabriel J. Pavey, Donald N. Hope, Rebecca L. Pavlicek, Benjamin K. Potter, Thomas A. Davis, Jonathan A. Forsberg. Evaluation of Bioburden on the Development of Heterotopic Ossification in an Established Rat Model. Southern Orthopedic Association 2015.
- *Gabriel J. Pavey, Ammar T. Qureshi, Allison Tomasino, Danett Bishop, Maurizio Pacifici, Mashahiro Iwamoto, Benjamin K. Potter, Thomas A. Davis, Jonathan A. Forsberg. Targeted stimulation of retinoic acid receptor signaling mitigates the formation of heterotopic ossification in an established blast-related traumatic injury model. Walter Reed Research Day 2015.
- *Gabriel J. Pavey, Ammar T. Qureshi, Allison M. Tomasino, Danett Bishop, Maurizio Pacifici, Mashahiro Iwamoto, Benjamin K. Potter, Thomas A. Davis, Jonathan A. Forsberg. Targeted Stimulation of Retinoic Acid Receptor Signaling Mitigates the Formation of Heterotopic Ossification in an Established Blast-Related Traumatic Injury Model. Orthopedic Trauma Association, San Diego, CA. October 7-10, 2015. (15-112).
- Gabriel J. Pavey, Ammar T. Qureshi, Allison M. Tomasino, Danett Bishop, Maurizio Pacifici, Mashahiro Iwamoto, Benjamin Levi, Carry L. Honnold, Benjamin K. Potter, Thomas A. Davis, Jonathan A. Forsberg. Targeted Stimulation of Retinoic Acid Receptor Signaling Mitigates the Formation of Heterotopic Ossification in an Established Blast-Related Traumatic Injury Model. Orthopaedic Research Society (ORS), Orlando, FL.2016. Invited Poster Presentation. March 5-8, 2016. (16-083).
- Jonathan A. Forsberg, Gabriel J. Pavey, Ammar T. Qureshi, Allison M. Tomasino, Thomas A. Davis, Maurizio Pacifici, Benjamin Levi, Benjamin K. Potter. Does Stimulation of Retinoic Acid Receptor Signaling Mitigate the Formation of Heterotopic Ossification in a Small Animal Model. Association of Bone and Joint Surgeons, Auckland, NZ. April 5-8, 2016. (16-073).
- Gabriel J. Pavey, Ammar T. Qureshi, Allison M. Tomasino, Danett Bishop, Maurizio Pacifici, Mashahiro Iwamoto, Benjamin Levi, Carry L. Honnold, Benjamin K. Potter, Thomas A. Davis, Jonathan A. Forsberg. Targeted Stimulation of Retinoic Acid Receptor Signaling Mitigates the Formation of Heterotopic Ossification in an Established Blast-Related Traumatic Injury Model.

First International Symposium on Innovations in Amputation Surgery and Prosthetic Technologies (IASPT), Chicago, IL. May 12-13, 2016. (16-388)

INVENTIONS, PATENTS AND LICENSES

None to report.

REPORTABLE OUTCOMES

None to report.

OTHER ACHIEVEMENTS

None to report.

REFERENCES

No references cited

APPENDICES

Appendix 1: Pavey GJ, Qureshi AT, Hope DN, Pavlicek RL, Potter BK, Forsberg JA and Davis TA. 2015. Bioburden Increases Heterotopic Ossification Formation in an Established Rat Model. *Clinical Orthopaedics and Related Research* 473:2840-2847.

Appendix 2: Qureshi AT, Crump EK, Pavey GJ, Hope DN, Forsberg, JA and Davis TA. 2015. Early Characterization of Blast-Related Heterotopic Ossification in a Rat Model. *Clinical Orthopaedics and Related Research* 473:2831-2839.

Appendix 3: Pavey GJ, Qureshi AT, Tomasino AM, Honnold CL, Bishop DK, Agarwal S, Loder S, Levi B, Pacifici M, Iwamoto M, Potter BK, Davis TA, Forsberg JA. 2016. Targeted stimulation of retinoic acid receptor- γ mitigates the formation of heterotopic ossification in an established blast-related traumatic injury model. *Bone*. 90:159-167.

Bioburden Increases Heterotopic Ossification Formation in an Established Rat Model

**Gabriel J. Pavey, Ammar T. Qureshi,
Donald N. Hope, Rebecca L. Pavlicek,
Benjamin K. Potter, Jonathan
A. Forsberg & Thomas A. Davis**

**Clinical Orthopaedics and Related
Research®**

ISSN 0009-921X

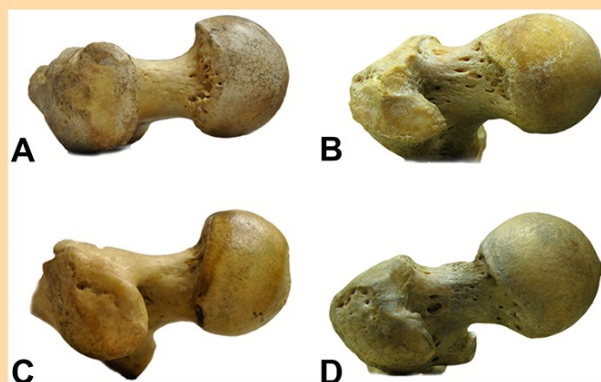
Clin Orthop Relat Res
DOI 10.1007/s11999-015-4272-3

VOLUME 473 • NUMBER 4

**Clinical Orthopaedics
and Related Research®**

PUBLISHED SINCE 1953

www.clinorthop.org



A Publication of
The Association of Bone and Joint Surgeons®
Disseminating Orthopaedic Knowledge



 Springer
11999 • ISSN 0009-921X
473 (4) 1173-1536 (2015)

CORR® goes Mobile!



Your article is protected by copyright and all rights are held exclusively by The Association of Bone and Joint Surgeons®. This e-offprint is for personal use only and shall not be self-archived in electronic repositories. If you wish to self-archive your article, please use the accepted manuscript version for posting on your own website. You may further deposit the accepted manuscript version in any repository, provided it is only made publicly available 12 months after official publication or later and provided acknowledgement is given to the original source of publication and a link is inserted to the published article on Springer's website. The link must be accompanied by the following text: "The final publication is available at link.springer.com".

Bioburden Increases Heterotopic Ossification Formation in an Established Rat Model

Gabriel J. Pavey MD, Ammar T. Qureshi PhD, Donald N. Hope MD, Rebecca L. Pavlicek PhD, Benjamin K. Potter MD, Jonathan A. Forsberg MD, Thomas A. Davis PhD

© The Association of Bone and Joint Surgeons® 2015

Abstract

Background Heterotopic ossification (HO) develops in a majority of combat-related amputations wherein early bacterial colonization has been considered a potential early

risk factor. Our group has recently developed a small animal model of trauma-induced HO that incorporates many of the multifaceted injury patterns of combat trauma in the absence of bacterial contamination and subsequent wound colonization.

This work was supported by USAMRAA BAA #10083004 (Principal Investigator JAF) and USAMRAA PRORP-CDMRP #120056 (Principal Investigator JAF).

All ICMJE Conflict of Interest Forms for authors and *Clinical Orthopaedics and Related Research*® editors and board members are on file with the publication and can be viewed on request.

Clinical Orthopaedics and Related Research® neither advocates nor endorses the use of any treatment, drug, or device. Readers are encouraged to always seek additional information, including FDA-approval status, of any drug or device prior to clinical use.

The authors are employees of the US Government. This work was prepared as part of their official duties. Title 17 USC §105 provides that "Copyright protection under this title is not available for any work of the US Government." Title 17 USC §101 defined a US Government work as a work prepared by a military service member or employees of the US Government as part of that person's official duties. The opinions or assertions contained in this paper are the private views of the authors and are not to be construed as reflecting the views, policy or positions of the Departments of the Navy, Department of Defense nor the US Government.

Each author certifies that his or her institution approved the animal protocol for this investigation and that all investigations were conducted in conformity with ethical principles of research.

This work was performed at the Naval Medical Research Center, Silver Spring, MD, USA.

Questions/purposes We sought to determine if (1) the presence of bioburden (*Acinetobacter baumannii* and methicillin-resistant *Staphylococcus aureus* [MRSA]) increases the magnitude of ectopic bone formation in traumatized muscle after amputation; and (2) what persistent effects bacterial contamination has on late microbial flora within the amputation site.

Methods Using a blast-related HO model, we exposed 48 rats to blast overpressure, femur fracture, crush injury, and subsequent immediate transfemoral amputation through the zone of injury. Control injured rats (n = 8) were inoculated beneath the myodesis with phosphate-buffered saline not containing bacteria (vehicle) and treatment rats were inoculated with 1×10^6 colony-forming units of *A. baumannii* (n = 20) or MRSA (n = 20). All animals formed HO. Heterotopic ossification was determined by quantitative volumetric measurements of ectopic bone at 12-weeks postinjury using micro-CT and qualitative histomorphometry for assessment of new bone formation in the residual limb. Bone marrow and muscle tissue biopsies

G. J. Pavey, A. T. Qureshi, D. N. Hope, B. K. Potter, J. A. Forsberg, T. A. Davis (✉)
Regenerative Medicine Department, Naval Medical Research Center, 503 Robert Grant Avenue, Silver Spring, MD 20910, USA
e-mail: thomas.davis1@med.navy.mil;
thomas.a.davis196.ctr@mail.mil

R. L. Pavlicek
Department of Wound Infections, Naval Medical Research Center, Silver Spring, MD, USA

B. K. Potter, J. A. Forsberg, T. A. Davis
Department of Surgery, Uniformed Services University of the Health Sciences, Bethesda, MD, USA

G. J. Pavey, D. N. Hope, B. K. Potter, J. A. Forsberg
Department of Orthopaedics, Walter Reed National Military Medical Center, Bethesda, MD, USA

were collected from the residual limb at 12 weeks to quantitatively measure the bioburden load and to qualitatively determine the species-level identification of the bacterial flora.

Results At 12 weeks, we observed a greater volume of HO in rats infected with MRSA ($68.9 \pm 8.6 \text{ mm}^3$; 95% confidence interval [CI], 50.52–85.55) when compared with *A baumannii* ($20.9 \pm 3.7 \text{ mm}^3$; 95% CI, 13.61–28.14; $p < 0.001$) or vehicle ($16.3 \pm 3.2 \text{ mm}^3$; 95% CI, 10.06–22.47; $p < 0.001$). Soft tissue and marrow from the residual limb of rats inoculated with *A baumannii* tested negative for *A baumannii* infection but were positive for other strains of bacteria ($1.33 \times 10^2 \pm 0.89 \times 10^2$; 95% CI, -0.42×10^2 – 3.08×10^2 and $1.25 \times 10^6 \pm 0.69 \times 10^6$; 95% CI, -0.13×10^6 – 2.60×10^6 colony-forming units in bone marrow and muscle tissue, respectively), whereas tissue from MRSA-infected rats contained MRSA only ($4.84 \times 10^1 \pm 3.22 \times 10^1$; 95% CI, -1.47×10^1 – 11.1×10^1 and $2.80 \times 10^7 \pm 1.73 \times 10^7$; 95% CI, -0.60×10^7 – 6.20×10^7 in bone marrow and muscle tissue, respectively).

Conclusions Our findings demonstrate that persistent infection with MRSA results in a greater volume of ectopic bone formation, which may be the result of chronic soft tissue inflammation, and that early wound colonization may be a key risk factor.

Clinical Relevance Interventions that mitigate wound contamination and inflammation (such as early débridement, systemic and local antibiotics) may also have a beneficial effect with regard to the mitigation of HO formation and should be evaluated with that potential in mind in future preclinical studies.

Introduction

Blast injuries present formidable surgical, treatment, and rehabilitation challenges. The resulting wounds are multifaceted, often resulting in composite tissue loss, comminuted open fractures, and frequent traumatic amputations. Related wound contamination is ubiquitous, often with multidrug-resistant organisms such as *Acinetobacter baumannii* and methicillin-resistant *Staphylococcus aureus* (MRSA), often calling for protracted treatment regimens that include serial surgical débridements and broad-spectrum antibiotic therapy [2, 3, 6]. A survey of wound infections from Combat Support Hospitals in Iraq from 2003 to 2004 demonstrated a relatively high frequency of MRSA (26%) followed by *Acinetobacter calcoaceticus-baumannii* complex (11%), *Klebsiella pneumoniae* (13%), and *Pseudomonas aeruginosa* (10%) in

combat-related injuries [6]. Wound infection-related complications include wound dehiscence, deep soft tissue infection, biofilm development on orthopaedic implants, and infectious osteomyelitis, often leading to chronic, debilitating infections, further bone and soft tissue destruction, and subsequent limb amputation [2, 20, 22, 23, 33].

Heterotopic ossification (HO) is the formation of mature lamellar bone within soft tissue after severe traumatic injury [10]. It is known to develop in the majority of combat-related amputations, and early bacterial colonization has been considered a potential early risk factor [12, 13]. However, the cellular and early signaling mechanism(s) for combat injury-induced HO formation remain unclear. Recent findings suggest that the heightened and prolonged expression of inflammatory and other reparative mediators may contribute to HO formation [11, 14]. Moreover, the combat wound appears to provide a unique microenvironment conducive to osteogenesis that promotes the skewed differentiation of endogenous tissue-derived progenitor cells toward ectopic bone development within injured and healing soft tissue [10].

We previously developed a rat model of combat-related HO that incorporates the critical elements associated with combat injury, specifically a systemic blast injury, femur fracture with soft tissue crush, and transfemoral amputation through the zone of injury wherein all animals develop radiographic evidence of HO within 2 months postinjury [25]. Expanding on this model, in this study, we sought to evaluate if (1) the presence of bioburden (*A baumannii* and MRSA) increases the magnitude of ectopic bone formation in traumatized muscle after amputation; and (2) what persistent effects bacterial contamination has on late microbial flora within the amputation site.

Materials and Methods

Animals

Forty-eight young adult pathogen-free male Sprague-Dawley rats (*Rattus norvegicus*; 12–14 weeks, 400–500 g) were purchased from Taconic Farms (Germantown, NY, USA). All animals were housed in clean plastic cages and kept on a 12-hour light/dark cycle with unlimited access to food (standard rodent chow) and fresh water ad libitum. The study protocol (12-OUMD-20s) was reviewed and approved by the Walter Reed Army Institute of Research/Naval Medical Research Center Institutional Animal Care and Use Committee in compliance with all applicable Federal regulations governing the protection of animals in research.

Bacteria Culture Conditions

The *A baumannii* (strain 5075) and MRSA (MRSA strain 107261) organisms used in this study are highly virulent, well-characterized clinical specimens isolated from combat wounds from patients treated at the Walter Reed National Military Medical Center. In brief, frozen (-80°C) stock cultures were streaked out on a blood agar plate and left to grow overnight at 37°C and 5% CO_2 . A single bacterial colony was isolated and suspended in 3 mL of Lysogeny broth/Luria-Bertabi medium (Becton, Dickinson and Co, Sparks, MD, USA) and agitated overnight at 37°C and 5% CO_2 . Overnight cultures were diluted 1:50 in 50 mL of fresh prewarmed Luria-Bertabi broth in a 250-mL Erlenmeyer flask and grown to early/midlog phase ($\text{OD}_{600} = 0.2\text{--}0.5$) where cells proliferate in a logarithmic fashion under optimal culture and nutrient conditions resulting in a controlled cell growth rate. Next, 2 mL of the concentrated culture sample was removed. Cells were washed twice using prechilled (4°C) phosphate-buffered saline (PBS), pelleted by centrifugation (5000 rpm for 3 minutes), then resuspended in 1 mL of sterile PBS. The bacterial density was estimated through direct count using a Petroff-Hauser Counting Chamber (Hauser Scientific, Horsham, PA, USA) and confirmed by serial dilution and plating on Luria-Bertabi agar and then diluted to the desired cell concentration, 1×10^7 colony-forming units (CFU)/mL in cold PBS.

Rat Model of Trauma-induced HO and Bacterial Inoculation

A total of 48 rats were exposed to blast overpressure exposure, femur fracture, soft tissue crush injury, and limb amputation as previously described [25]. After quadriceps myoplasty, three muscle sites immediately surrounding the amputation site were inoculated with: (1) vehicle (100 μL of PBS; $n = 8$); (2) *A baumannii* (100 μL of 1×10^7 CFU; $n = 20$); or (3) MRSA (100 μL of 1×10^7 CFU; $n = 20$). Closure of the incision was performed using a 3-0 Vicryl in the deep subcutaneous tissue and a running 4-0 subcuticular Monocryl. Wounds were covered in Vetbond (3M Animal Care Products, St Paul, MN, USA). Postoperatively rats were monitored at least twice daily by animal care staff, research investigators, and veterinarians for animal activity, signs of pain, weight loss, wound dehiscence, or infectious tracts for the duration of the study. Wounds that exhibited signs of infection defined as drainage, progressive marginal erythema, or dehiscence were débrided. Rats were euthanized if they demonstrated signs of infection after a third débridement. We conducted a power analysis based on the effect of a projected 50% increase in ectopic

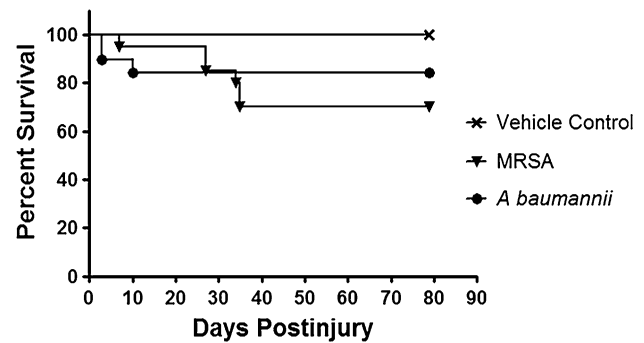


Fig. 1 Treatment effects on survival outcome of injured rats wherein the traumatized muscle surrounding the amputation site at the time of closure was infected with either MRSA (1×10^6) or *A baumannii* (1×10^6). Kaplan-Meier survival curves are shown. Animals were euthanized if they demonstrated signs of infection after the third débridement and irrigation of the amputation wound site.

bone volume within the soft tissue surrounding the amputated femur when the injury site was inoculated with either MRSA or *A baumannii*. Using conservative assumptions and data from our prior studies, the power analysis showed that with eight rats per treatment group and $\alpha = 0.05$, there is 90% power to detect a 50% increase in ectopic bone volume. Thus, it was anticipated that 20 rats in the infected treatment groups would provide adequate statistical power to detect treatment effects of moderate size on the major outcome variable of ectopic bone volume even with attrition of as many as 12 rats per group. All eight rats in the control group survived until the 12-week micro-CT scan (Fig. 1). Six animals in the MRSA group were euthanized during the fourth and fifth weeks for overwhelming infection. Two of the rats in the *A baumannii* group died on the day of surgery and were excluded. A low level of mortality after surgery was consistent with findings during model development and represents the devastation of these multifaceted injuries, particularly given that blast overpressure of 120 ± 7 kPa itself is calibrated for 70% to 90% survivability [1, 7, 25]. In addition, two rats infected with *A baumannii* were euthanized for sustained weight loss greater than 10% during postoperative weeks 2 and 4.

Micro-CT Analysis

Rats anesthetized with isoflurane (2%) were imaged at 12 weeks postinjury using a SkyScan 1176 in vivo high-resolution micro-CT (Bruker-MicroCT, Kontich, Belgium) with the following settings: 89-kV polychromatic xray beam, current of 256 μA , and an exposure time of 81 msec for each of 180 rotational steps. Two investigators (GJP, ATQ) independently reviewed the micro-CT images (170–200 flattened longitudinal micro-CT slices/rat) on a CT-

Analysers (Bruker-MicroCT) and calculated the volume of ectopic bone formation using selected regions of interest on every fifth slice encompassing ectopic bone. The binary selected slices were then used to perform three-dimensional image analysis yielding a total volume of HO in the selected area of interest.

Sample Collection and Culture

After the micro-CT scans were assessed for image quality and clarity, scanning efficiency, and reconstructed for volumetric analysis of ectopic bone formation, rats were euthanized with pentobarbital (Fatal Plus; 390 mg/kg intraperitoneally; Patterson Veterinary, Devens, MA, USA). Muscle tissue adjacent to the amputation site and femur was aseptically excised. Femurs were removed and separated from the soft tissues. Bone marrow from the residual femur was extruded from the medullary canal by flushing using a 10-mL syringe fitted with an 18-gauge needle with 10 mL of sterile PBS after proximal and distal osteotomies. Samples were diluted in PBS out to 10^{-6} , plated on a blood agar plate, and incubated overnight at 37° C, 5% CO₂. Colonies were counted and screened for differing morphology. Isolates were streaked on a blood agar plate for direct bacterial species identification using the BD Phoenix automated microbiology system in accordance with the manufacturer's instructions (BD Diagnostics, Sparks, MD, USA).

Histological Analysis

At the time of euthanasia, two rats from each treatment group received an en bloc resection of the residual limb, which was then fixed in 10% formalin, decalcified in 5% formic acid, paraffin-embedded, cut into 5- μ m longitudinal sections on a microtome, and stained using hematoxylin and eosin stain (Histoserv, Inc, Germantown, MD, USA). Histologic tissue samples were qualitatively analyzed for evidence of soft tissue cartilage formation, inflammation, lamellar bone formation within the soft tissues, the presence of persistent inflammatory cells, or active bacterial infection. The histopathological analysis was conducted by a veterinary pathologist (CH) blinded to the treatment groups.

Statistical Analysis

Kaplan-Meier modeling was performed to assess the survivability patterns of the control and treatment groups over the duration of the study. Intraclass correlation coefficient

(ICC) was calculated to assess the reliability of interobserver measurements of HO formation using the micro-CT analyzing software. Analysis of variance modeling was used to determine whether there was a significant difference in the volume (mm³) of ectopic bone measured among the three groups followed by the Tukey's honestly significant difference test to determine the mean difference among the three groups. All data, including the bacterial CFU counts, were presented as mean \pm SD with 95% confidence interval (CI) unless specified otherwise. Exact p values were stated except when < 0.001 . All statistical analysis described previously was performed using the RStudio, Version 0.98.953 (© 2009–2013 RStudio Inc, Boston, MA, USA).

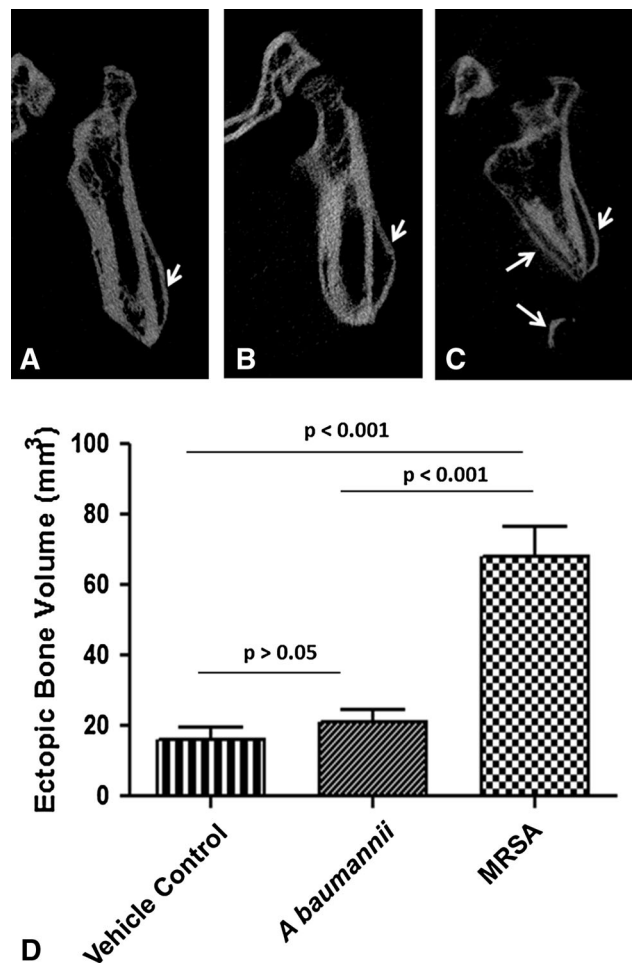


Fig. 2A–D MRSA infection increases trauma-induced ectopic bone formation. Representative longitudinal 12-week micro-CT images of the residual femurs of rats inoculated with (A) vehicle control (PBS; noninfected control); (B) *A. baumannii*; and (C) MRSA are shown. The white arrows highlight the areas of ectopic bone formation. (D) The amount of ectopic bone was quantified 12 weeks postinjury from vehicle control (n = 8), *A. baumannii* (n = 16), and MRSA (n = 14) treatment groups. Result expressed are expressed as the mean \pm SD.

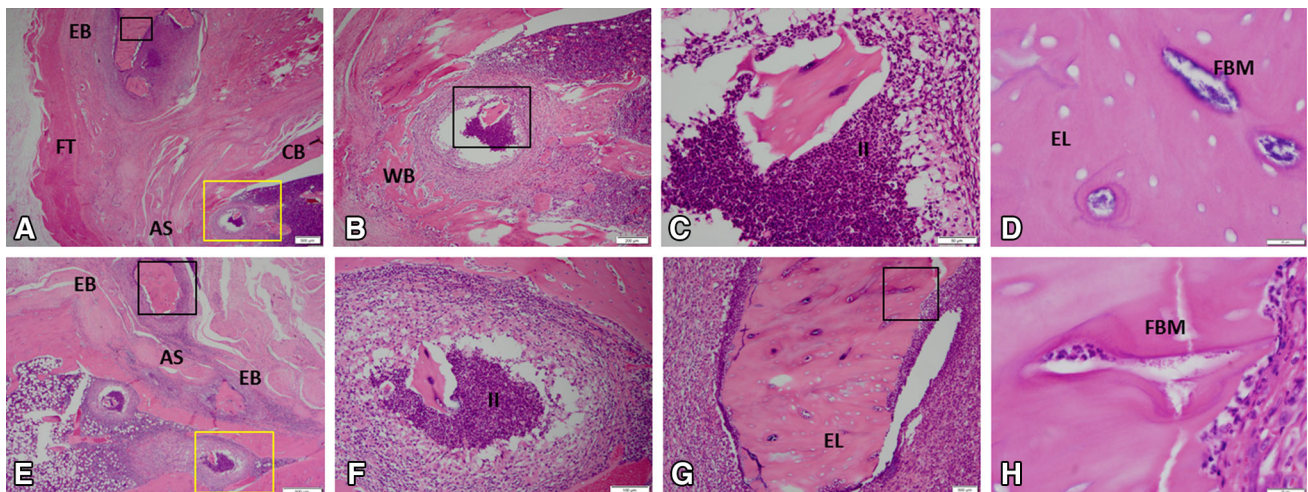


Fig. 4A–H The histological features of ectopic bone formation in MRSA-treated rats at 12 weeks are shown in A–H (A, Stain, hematoxylin and eosin; A original magnification, $\times 1.25$; B, original magnification, $\times 4$, yellow boxed region in A; C, original magnification, $\times 20$, black boxed region in B; D, original magnification, $\times 100$, black boxed region in A; E, original magnification, $\times 2$; F, original magnification, $\times 10$, yellow boxed region in E; G, original magnification, $\times 10$, black boxed region in E; H, original magnification, $\times 10$, black boxed region in G). For detailed evaluation,

images of six selected regions at higher magnification are shown. In the medullary space and soft tissue, there is evidence of chronic inflammation, neutrophil infiltration, purulent infection, osteomyelitis, and necrotic ectopic bone as indicative of empty osteocytic lacunae containing bacterial microcolonies. AS = amputation site; CB = cortical bone; EL = empty lacunae; EB = ectopic bone; FBM = foci of bacterial microcolonies; FT = fibroblastic tissue; II = intramedullary infection; WB = woven bone.

in up to 41% of amputees with HO [30]. As such, considerable focus has been directed toward prevention and mitigation of HO formation; however, understanding factors that exacerbate its development is an important prerequisite. In this effort, we explored, using an established blast-related HO animal model [25], the impact of *A baumannii* or MRSA colonization on the volume of HO formation and identified the characteristics of chronic infection in each setting.

There are several limitations to our study. First, the rat model is not conducive to many of the surgical modalities used in the treatment of traumatic wounds such as serial débridements with negative pressure wound therapy, which are implicated as putative contributors to HO formation [12]. Second, most war wounds are typically colonized by polymicrobial flora [6]. As such, an inoculum of a specific bacterial pathogen (1×10^6 CFU) does not fully address the synergistic role that polymicrobial infection may have in the persistence and virulence of infection plus it limits our ability to assess differences in HO formation or persistence of infection with varied degrees of infection. Preliminary experiments demonstrated that the bacterial concentration of MRSA used in these studies resulted in established persistent infections with high reproducibility and minimal variation in regard to wound complications. Moreover, it has been reported that approximately 50% of combat wounds become clinically infected ($> 1 \times 10^5$ CFU) as opposed to merely contaminated [2, 28]. Notably,

as a limitation in identifying the presence of all persistent microorganisms, only aerobic wound microflora were cultured from soft tissue and bone marrow. With the expressed intent of describing the impact of microbial bioburden on trauma-induced HO, we acknowledge our limited description of other forms of HO such as genetic and neurogenic. Neurogenic HO has been well described in civilian populations [8, 15], whereas the focus in military research has been predominantly in traumatic HO. In the neurogenic form, neurotransmitters such as glutamate, substance P, and catecholamines act to induce osteoblasts to form ectopic bone within a permissive local environment [5, 18, 27]. Therefore, the induction of progenitor cells with varying osteoinductive factors is common in both traumatic and neurogenic; however, the difference lies in the elevated levels of systemic and local inflammatory cytokines in the former and neurotransmitters in the latter [14]. That having been said, the expression and/or production of inflammatory mediators in this current study was not assessed; therefore, inferences regarding the role of local infection on HO development are based only on histopathological changes noted at study termination.

Contamination of residual limbs with MRSA, but not *A baumannii*, contributed to the volume of HO that developed in this rat model. This finding is relevant given that MRSA is the predominant organism in 35% to 50% of clinically infected combat wounds [3, 4]. Often, these wounds demand serial débridements to achieve healthy-appearing and/

or culture-negative tissue. Despite this, approximately one-fourth of amputations develop late infection after closure of a healthy-appearing wound bed [30]. More débridements, five to seven to be exact, are associated with the development of HO, likely resulting from mechanical trauma to the tissue as well as the systemic inflammatory responses that can result from repeated returns to the operating room [7, 19]. In comparison, our MRSA-inoculated rats developed a greater volume of HO with most (11 of 14 analyzed) doing so in the absence of the described serial surgical interventions, further suggesting MRSA involvement. An unexpected finding of our study is the relative lack of effect of *A baumannii* on ectopic bone formation despite the selection of the strain based on its clinical ubiquity and relative virulence [2, 29]. This result may be expected given that *A baumannii*-infected rats cleared their infection. Another explanation involves the signaling of toll-like receptors (TLRs), which are found to be expressed on osteogenic precursor cells [24]. Interestingly, purified lipopolysaccharide, a ligand found on Gram-negative organisms, which has preferential affinity for toll-like receptor 4 (TLR4), demonstrated slow activation of mesenchymal stem cells; however, prolonged exposure to the toxin resulted in decreased expression of TLRs. Alternatively, downregulation of TLRs did not occur with prolonged exposure to the Gram-positive specific cell wall component lipoteichoic acid, perhaps allowing for osteogenic differentiation of mesenchymal stem cells by Gram-positive organisms like MRSA [19, 31]. It may be that infection with Gram-negatives such as *A baumannii* affects HO development indirectly in clinical practice. This organism is not found in wounds at the time of injury but rather is a nosocomial pathogen found in combat theater hospitals. Infection of wounds during aeromedical evacuation or at combat hospitals may “re-infect” wounds, resulting in serial débridements and negative pressure wound therapy, factors that some infer may contribute to HO development [6, 12, 23].

Chronic infection, like persistently symptomatic HO, can delay or regress the rehabilitation of blast- and otherwise war-related amputees. After combat-related lower extremity amputations, 27% require return to the operating room for wound infection [30] at some point during their hospitalization. In a study of 110 service members with severe orthopaedic wounds that subsequently developed osteomyelitis, a retrospective review showed that *A baumannii* accounted for 70% of initial admissions to the hospital; however, these responded well to treatment, making up only 6% of recurrences. By comparison, MRSA, presented as the infecting organism in only 8% of initial diagnoses of osteomyelitis, however, was responsible for 31% of readmissions for osteomyelitis with Gram-positives as a whole accounting for 75% of recurrence [33]. In

addition, modeling of war wounds in a rabbit demonstrated that monobacterial Gram-negative inoculation at a titer of 1×10^5 *A baumannii* failed to produce osteomyelitis, whereas polymicrobial inoculum and/or those containing MRSA demonstrated active, persistent, infection 8 weeks postinoculation [32]. Our findings also support the persistence of Gram-positive infections with 56% and 21% rates of soft tissue contamination and osteomyelitis in our MRSA cohort, the latter occurring despite the bone not being directly inoculated. Conversely, *A baumannii* was not present in any 12-week cultures, but rather other antibiotic-resistant ESKAPE pathogens (*Enterococcus faecium*, *Staphylococcus aureus*, *K pneumoniae*, *A baumannii*, *P aeruginosa*, and *Enterobacter* species) such as enteric organisms *Enterococcus faecium* and *Enterobacter cloacae* as well as various Gram-positive staphylococci, but not *S aureus* were isolated at time of culture (Table 1). Negative culture results for *A baumannii* infection 12 weeks postinoculation are consistent with previous rat studies and may be the result of decreased virulence in bone as compared with other infection sites [9]. Secondary infection with other nosocomial pathogens, particularly Gram-positive organisms, is consistent with clinical findings and suggests that initial infection with *A baumannii* may produce an environment conducive to secondary infection or overgrowth of other nosocomial organisms [17]. Although the synergism between initial *A baumannii* infection and subsequent infection still needs to be studied, this result may be informative for clinical treatment plans.

Our study suggests that of the two most common bacterial isolates of combat-related amputations, MRSA infection results in the development of a several-fold increase in the volume of ectopic bone compared with *A baumannii* and a vehicle control in a rat model. This difference may be related to the microorganisms' persistent colonization and invocation of chronic infection because this difference was shown in our study minus the surgical treatment already known to influence HO formation. Therefore, in addition to drug therapies that target signaling pathways in bone development and/or proinflammatory osteogenic mediators, we further propose that initiation of prophylactic local and/or systemic Gram-positive antimicrobial therapy at the time of injury and continued treatment of sub-clinical infection may help mitigate the formation of ectopic bone; further preclinical work, to include assessment of polymicrobial infections, impact of differential TLR signaling, and the evaluation of systemic and/or local antimicrobial interventions, is necessary to further elucidate this effect.

Acknowledgments We thank Dana Golden, Allison Tomasino, and Erica Crump for assistance with animal care, sample collections, and technical expertise. We also thank Ying Cao for his statistical expertise and assistance. Furthermore, we thank LTC Cary Hannold for his excellent contribution to the histological review of tissue specimens.

References

- Ahlers ST, Vasserman-Stokes E, Shaughnessy MC, Hall AA, Shear DA, Chavko M, McCarron RM, Stone JR. Assessment of the effects of acute and repeated exposure to blast overpressure in rodents: toward a greater understanding of blast and the potential ramifications for injury in humans exposed to blast. *Front Neurol*. 2012;3:32.
- Be NA, Allen JE, Brown TS, Gardner SN, McLoughlin KS, Forsberg JA, Kirkup BC, Chromy BA, Luciw PA, Elster EA, Jaing CJ. Microbial profiling of combat wound infection through detection microarray and next-generation sequencing. *J Clin Microbiol*. 2014;52:2583–2594.
- Brown KV, Dharm-Datta S, Potter BK, Etherington J, Mistlin A, Hsu JR, Clasper JC. Comparison of development of heterotopic ossification in injured US and UK Armed Services personnel with combat-related amputations: preliminary findings and hypotheses regarding causality. *J Trauma Inj Infect Crit Care*. 2010;69:S116–S122.
- Burns TC, Stinner DJ, Mack AW, Potter BK, Beer R, Eckel TT, Possley DR, Beltran MJ, Hayda RA, Andersen RC, Keeling JJ, Frisch HM, Murray CK, Wenke JC, Ficke JR, Hsu JR. Microbiology and injury characteristics in severe open tibia fractures from combat. *J Trauma Acute Care Surg*. 2012;72:1062–1067.
- Cadosch D, Toffoli AM, Gautschi OP, Frey SP, Zellweger R, Skirving AP, Filgueira L. Serum after traumatic brain injury increases proliferation and supports expression of osteoblast markers in muscle cells. *J Bone Joint Surg Am*. 2010;92:645–653.
- Calhoun JH, Murray CK, Manning M. Multidrug-resistant organisms in military wounds from Iraq and Afghanistan. *Clin Orthop Relat Res*. 2008;466:1356–1362.
- Chavko M, Koller WA, Prusaczyk WK, McCarron RM. Measurement of blast wave by a miniature fiber optic pressure transducer in the rat brain. *J Neurosci Methods*. 2007;159:277–281.
- Cipriano CA, Pill SG, Keenan MA. Heterotopic ossification following traumatic brain injury and spinal cord injury. *J Am Acad Orthop Surg*. 2009;17:689–697.
- Collinet-Adler S, Castro CA, Ledonio CGT, Bechtold JE, Tsukayama DT. *Acinetobacter baumannii* is not associated with osteomyelitis in a rat model: a pilot study. *Clin Orthop Relat Res*. 2011;469:274–282.
- Davis TA, Lazdun Y, Potter BK, Forsberg JA. Ectopic bone formation in severely combat-injured orthopedic patients—a hematopoietic niche. *Bone*. 2013;56:119–126.
- Evans KN, Potter BK, Brown TS, Davis TA, Elster EA, Forsberg JA. Osteogenic gene expression correlates with development of heterotopic ossification in war wounds. *Clin Orthop Relat Res*. 2014;472:396–404.
- Forsberg JA, Pepek JM, Wagner S, Wilson K, Flint J, Andersen RC, Tadaki D, Gage FA, Stojadinovic A, Elster EA. Heterotopic ossification in high-energy wartime extremity injuries: prevalence and risk factors. *J Bone Joint Surg Am*. 2009;91:1084–1091.
- Forsberg JA, Potter BK. Heterotopic ossification in wartime wounds. *J Surg Orthop Adv*. 2010;19:54–61.
- Forsberg JA, Potter BK, Polfer EM, Safford SD, Elster EA. Do inflammatory markers portend heterotopic ossification and wound failure in combat wounds? *Clin Orthop Relat Res*. 2014;472:1–10.
- Garland DE. Clinical observations on fractures and heterotopic ossification in the spinal cord and traumatic brain injured populations. *Clin Orthop Relat Res*. 1988;233:86–101.
- Hospenthal DR, Crouch HK, English JF, Leach F, Pool J, Conger NG, Whitman TJ, Wortmann GW, Robertson JL, Murray CK. Multidrug-resistant bacterial colonization of combat-injured personnel at admission to medical centers after evacuation from Afghanistan and Iraq. *J Trauma Inj Infect Crit Care*. 2011;71:S52–S57.
- Johnson EN, Burns TC, Hayda RA, Hospenthal DR, Murray CK. Infectious complications of open type III tibial fractures among combat casualties. *Clin Infect Dis*. 2007;45:409–415.
- Jones KB, Mollano AV, Morcuende JA, Cooper RR, Saltzman CL. Bone and brain: a review of neural, hormonal, and musculoskeletal connections. *Iowa Orthop J*. 2004;24:123.
- Mo IF, Yip KH, Chan WK, Law HK, Lau YL, Chan GC. Prolonged exposure to bacterial toxins downregulated expression of toll-like receptors in mesenchymal stromal cell-derived osteoprogenitors. *BMC Cell Biol*. 2008;9:52.
- Murray CK, Hinkle MK, Yun HC. History of infections associated with combat-related injuries. *J Trauma Inj Infect Crit Care*. 2008;64:S221–S231.
- Murray CK, Hospenthal DR. Treatment of multidrug resistant *Acinetobacter*. *Curr Opin Infect Dis*. 2005;18:502–506.
- Murray CK, Hsu JR, Solomkin JS, Keeling JJ, Andersen RC, Ficke JR, Calhoun JH. Prevention and management of infections associated with combat-related extremity injuries. *J Trauma Inj Infect Crit Care*. 2008;64:S239–S251.
- Murray CK, Roop SA, Hospenthal DR, Dooley DP, Wenner K, Hammock J, Taufen N, Gourdiene E. Bacteriology of war wounds at the time of injury. *Mil Med*. 2006;171:826–829.
- Pevsner-Fischer M, Morad V, Cohen-Sfady M, Rousso-Noori L, Zanin-Zhorov A, Cohen S, Cohen IR, Zipori D. Toll-like receptors and their ligands control mesenchymal stem cell functions. *Blood*. 2007;109:1422–1432.
- Polfer EM, Hope DH, Elster EA, Qureshi AT, Golden DM, Potter BK, Davis TA, Forsberg JA. Development of a rat model for blast-related post-traumatic heterotopic ossification. *Bone Joint J*. 2015;97.
- Potter BK, Burns TC, Lacap AP, Granville RR, Gajewski DA. Heterotopic ossification following traumatic and combat-related amputations. Prevalence, risk factors, and preliminary results of excision. *J Bone Joint Surg Am*. 2007;89:476–486.
- Salisbury EJ, Rodenberg E, Sonnet C, Hipp J, Gannon FH, Vadakkan TJ, Dickinson ME, Olmsted-Davis EA, Davis AR. Sensory nerve induced inflammation contributes to heterotopic ossification. *J Cell Biochem*. 2011;112:2748–2758.
- Sheppard FR, Keiser P, Craft DW, Gage F, Robson M, Brown TS, Petersen K, Sincock S, Kasper M, Hawksworth J. The majority of US combat casualty soft-tissue wounds are not infected or colonized upon arrival or during treatment at a continental US military medical facility. *Am J Surg*. 2010;200:489–495.
- Thompson MG, Black CC, Pavlicek RL, Honnold CL, Wise MC, Alamneh YA, Moon JK, Kessler JL, Si Y, Williams R. Validation of a novel murine wound model of *Acinetobacter baumannii* infection. *Antimicrob Agents Chemother*. 2014;58:1332–1342.
- Tintle SM, Shawen SB, Forsberg JA, Gajewski DA, Keeling JJ, Andersen RC, Potter BK. Reoperation after combat-related major lower extremity amputations. *J Orthop Trauma*. 2014;28:232–237.
- Uematsu S, Akira S. Toll-like receptors (TLRs) and their ligands. In: Bauer GH, ed. *Toll-like Receptors (TLRs) and Innate Immunity. Handbook of Experimental Pharmacology*. Berlin, Heidelberg, Germany: Springer-Verlag; 2008:240.
- Yin LY, Manning MM, Calhoun JH. A rabbit osteomyelitis model to simulate multibacterial war wound infections. *Mil Med*. 2013;178:696–700.
- Yun HC, Branstetter JG, Murray CK. Osteomyelitis in military personnel wounded in Iraq and Afghanistan. *J Trauma Acute Care Surg*. 2008;64:S163–S168.

Early Characterization of Blast-related Heterotopic Ossification in a Rat Model

Ammar T. Qureshi PhD, Erica K. Crump BA, Gabriel J. Pavay MD,
Donald N. Hope MD, Jonathan A. Forsberg MD, Thomas A. Davis PhD

Published online: 10 March 2015

© The Association of Bone and Joint Surgeons® 2015

Abstract

Background Heterotopic ossification (HO) affects the majority of combat-related lower extremity wounds involving severe fracture and amputation. Defining the timing of early osteogenic-related genes may help identify candidate prophylactic agents and guide the timing of prophylactic therapy after blast and other combat-related extremity injuries.

Questions/purposes Using a recently developed animal model of combat-related HO, we sought to determine (1) the timing of early chondrogenesis, cartilage formation, and radiographic ectopic bone development; and (2) the

early cartilage and bone-related gene and protein patterns in traumatized soft tissue.

Methods We used an established rat HO model consisting of blast exposure, controlled femur fracture, crush injury, and transfemoral amputation through the zone of injury. Postoperatively, rats were euthanized on Days 3 to 28. We assessed evidence of early ectopic bone formation by micro-CT and histology and performed proteomic and gene expression analysis.

Results All rats showed radiographic evidence of HO within 28 days. Key chondrogenic (*collagen type I alpha 1 [COL1 α 1]*, $p = 0.016$) and osteogenic-related genes (*Runt-*

This work was supported by CDMRP (W81XWH-14-2-0010; PI-JAF) and BUMED (602115HP.3720.001.A1014; PI-JAF). Some of the authors are employees of the US Government. This work was prepared as part of their official duties. Title 17 U.S.C. §105 provides that “Copyright protection under this title is not available for any work of the United States Government.” Title 17 U.S.C. §101 defined a US Government work as a work prepared by a military service member or employees of the US Government as part of that person’s official duties. The opinions or assertions contained in this paper are the private views of the authors and are not to be construed as reflecting the views, policy or positions of the Department of the Navy, Department of Defense nor the US Government.

All ICMJE Conflict of Interest Forms for authors and *Clinical Orthopaedics and Related Research*® editors and board members are on file with the publication and can be viewed on request. *Clinical Orthopaedics and Related Research*® neither advocates nor endorses the use of any treatment, drug, or device. Readers are encouraged to always seek additional information, including FDA-approval status, of any drug or device prior to clinical use.

Each author certifies that his or her institution approved the animal protocol for this investigation and that all investigations were conducted in conformity with ethical principles of research. This work performed at the Naval Medical Research Center, Silver Spring, MD, USA.

Electronic supplementary material The online version of this article (doi:10.1007/s11999-015-4240-y) contains supplementary material, which is available to authorized users.

A. T. Qureshi, E. K. Crump, G. J. Pavay,
D. N. Hope, J. A. Forsberg, T. A. Davis (✉)
Regenerative Medicine Department, Naval Medical Research
Center, 503 Robert Grant Avenue, Silver Spring, MD 20910, USA
e-mail: thomas.davis1@med.navy.mil;
thomas.a.davis196.ctr@mail.mil

A. T. Qureshi, T. A. Davis
The Henry M. Jackson Foundation for the Advancement of
Military Medicine, Bethesda, MD, USA

E. K. Crump
Columbia University College of Physicians and Surgeons,
New York, NY, USA

G. J. Pavay, D. N. Hope, J. A. Forsberg
Department of Orthopaedics, Walter Reed National Military
Medical Center, Bethesda, MD, USA

J. A. Forsberg, T. A. Davis
Department of Surgery, Uniformed Services University of the
Health Sciences, Bethesda, MD, USA

related transcription factor 2 [RUNX-2], $p = 0.029$; osteocalcin [OCN], $p = 0.032$; phosphate-regulating neutral endopeptidase, X-linked [PHEX], $p = 0.0290$, and POU domain class 5 transcription factor [POU5F], $p = 0.016$) and proteins (Noggin [NOG], $p = 0.04$, OCN, $p = 0.02$, RUNX-2, $p = 0.04$, and substance P-1 [SP-1], $p = 0.01$) in the injured soft tissue, normalized to the contralateral limb and/or sham-treated naïve rats, increased on Days 3 to 14 postinjury. By 14 days, foci of hypertrophic chondrocytes, hyaline cartilage, and woven bone were present in the soft tissue surrounding the amputation site.

Conclusions We found that genes that regulate early chondrogenic and osteogenic signaling and bone development (*COL1 α 1*, *RUNX-2*, *OCN*, *PHEX*, and *POU5F1*) are induced early during the tissue reparative/healing phase in a rat model simulating a combat-related extremity injury. **Clinical Relevance** The ability to correlate molecular events with histologic and morphologic changes will assist researchers and clinicians to understand HO and hence formulate therapeutic interventions.

Introduction

Heterotopic ossification (HO) refers to the abnormal development of bone in nonosseous tissue, most commonly occurring in the setting of orthopaedic trauma, severe burns, neurotrauma, or major surgery [2, 7, 10, 13]. The prevalence of HO in the residual limbs of returning service members with combat-related amputations is reported to be as high 65% [11, 22]. At least 41% of those patients who develop HO require additional excision procedures. Moreover, delayed healing and wound dehiscence are major problems in severely injured patients recovering from survivable severe battlefield blast-related extremity injuries [12]. Studies from our group have established that acute wound failures and subsequent HO formation are related to multiple complex interrelated systemic and local inflammatory responses to traumatic injury [8, 12]. The optimal treatment strategy for HO has not been defined. Surgical excision is the only definitive management option and treatment of symptomatic HO if physical therapy and prosthesis alteration fail to provide adequate relief [31]. Other prophylaxis strategies include treatment with nonsteroidal antiinflammatory drugs or external-beam radiotherapy, but these options are more confined in the civilian setting and are generally contraindicated in the setting of combat and blast-induced trauma given nonsteroidal anti-inflammatory drugs may delay fracture healing and cause unacceptably high rates of bleeding complications while radiotherapy must be administered within 48 hours of injury (difficult if not impossible in the

combat setting) and is known to cause wound- and implant-related complications [11, 22, 23].

A comprehensive assessment of the early histologic and molecular development processes present within blast wounds has not occurred for several reasons. First, clinically relevant animal models have only recently been developed [21, 30]. Second, clinical diagnostic methods are unable to accurately predict the site of HO development [5, 20]. Third, analysis of human tissues obtained early in the débridement process has not been performed. Finally, available human clinical samples, usually collected at the time HO excision, typically contain immature and mature bone. Defining the early development phase of HO in relationship to concurrent wound healing is critical to selection of candidate means of prophylaxis and, importantly, the timing of their administration after high-energy extremity injuries.

We developed a rat model of combat-related HO that incorporates the critical elements associated with combat injury, specifically a blast injury, femur fracture-crush, and transfemoral amputation, through the zone of injury wherein all animals develop radiographic evidence of HO within 2 months postinjury [21]. In this report, we use our model to address (1) the timing of early chondrogenesis, cartilage formation, and radiographic ectopic bone development; and (2) the early cartilage and bone-related gene and protein patterns in traumatized soft tissue subsequent to calcium deposition, tissue mineralization, and ectopic bone formation. It is important to confirm the timing and upregulation of bone-related genes and proteins in our model because some observational clinical studies with soft tissue injury (without fracture or amputation) have shown elevated levels of such genes in a minority of cases [6, 9, 12].

Materials and Methods

Animals

Fifty-four young adult pathogen-free male Sprague-Dawley rats (*Rattus norvegicus*; 400–500 g) were purchased from Taconic Farms (Germantown, NY, USA). All animals were housed in clean plastic cages and kept on a 12-hour light/dark cycle with unlimited access to food (standard chow) and fresh water ad libitum. The study protocol (12-OUMD-20s) was reviewed and approved by the Walter Reed Army Institute of Research/Naval Medical Research Center Institutional Animal Care and Use Committee in compliance with all applicable Federal regulations governing the protection of animals in research. Postoperatively, rats were monitored at a minimum twice daily for animal activity, signs of pain, wound dehiscence, weight loss, and infection

by animal care staff, research staff, and veterinarians. Moribund rats were euthanized.

Rat Heterotopic Ossification Model

Rats were anesthetized with isoflurane (2%–5%) and received full-body blast overpressure (120 ± 7 kPa) exposure, without any shielding to the blast wave, through a pneumatically driven shock tube [1, 4, 29]. Preoperative buprenorphine (0.05 mg/kg) was then administered through intraperitoneal injection and a reproducible comminuted fracture of the right femur was performed using a drop weight apparatus from a height of 88 cm. A crush injury was performed immediately after the fracture by rotating the fracture site between the two support anvils, generating 20 pounds per square inch of pressure for 1 minute [3]. The injured limb was then amputated through the fracture with appropriate hemostasis and débridement of devitalized tissue followed by hamstring and quadriceps myoplasty over the exposed residual femur. Postoperative pain was managed with sustained-release buprenorphine (1.2 mg/kg) administered subcutaneously with repeat dosing after 3 days. Cohorts of four to eight rats per time point were euthanized on postinjury Days 3, 5, 7, 10, 14, 21, and 28 to detect and visualize histologically the early stages of the HO disease process, whereas a cohort of four sham-treated (neither blasted nor injured) naïve rats euthanized on Day 3 served as controls. Two rats were euthanized postoperatively early for self-mutilation of the amputation site and one for consumption and subsequent suffocation as a result of inhalation of the bedding. A surgical team consisting of an orthopaedic surgeon (GJP, EKC or DNH), postdoctorate fellow (ATQ), and two surgical technicians (AMT, DMG) experienced in small animal anesthesia and surgeries conducted the experiments and immediate postoperative care procedures.

Micro-CT for Detection of Ectopic Bone Formation

Postoperatively rats were anesthetized with isoflurane (2%–5%) and the injured leg was imaged using a SkyScan in vivo 1176 high-resolution micro-CT (ICT) x-ray imaging in three dimensions (Bruker-MicroCT, Kontich, Belgium) with the following settings: 89-kV polychromatic x-ray beam, current of 256 μ A, and an exposure time of 81 milliseconds for each of 180 rotational steps. The three-dimensional (3-D) images were rendered to reconstruct tomograms with a commercial package (NRecon; Bruker-MicroCT).

Tissue Collection for Chondrogenic, Osteogenic and Angiogenic Gene Expression and Protein Analysis

After euthanasia, skeletal muscle was aseptically collected from the distal quadriceps of the amputated limb as well as from the distal quadriceps muscle of the contralateral limb. Samples were immediately placed in either RNAlater™ (Ambion Inc, Austin, TX, USA) at 4 °C for 48 hours or snap-frozen in dry ice for gene expression and protein analysis, respectively.

Histological Analysis

The residual injured and contralateral femurs with attached associated muscle tissue were surgically removed and placed in 10% formalin. The femurs were decalcified in 5% formic acid, embedded in paraffin, longitudinal sectioned (5 μ m), and stained with hematoxylin-eosin (Histoserv, Inc, Germantown, MD, USA). Qualitative observations of wound healing and early ectopic endochondral bone development (mesenchymal condensation, chondrocyte differentiation, chondrogenesis, hypertrophic vascularized cartilage, hyaline cartilage development, extracellular maturation, and soft tissue mineralization) were performed by a pathologist (CLH) who was blinded to the study.

RNA Isolation and Gene Expression

Total RNA was isolated from skeletal muscle samples as previously described [9]. A custom-made low-density reverse transcription-polymerase chain reaction (RT-PCR) array consisting of 96 primer sets (including respective forward and reverse primers) for 83 rat-specific osteogenic, chondrogenic, adipogenic, and angiogenic genes as well as six housekeeping and seven quality control genes (SABiosciences, Gaithersburg, MD, USA) was used to assess gene expression (genes and their function listed in Supplemental Table 1 [Supplemental materials are available with the online version of CORR®]). Quantitative RT-PCR and dissociation curve analyses were performed as previously described [9]. Cycle threshold (Ct) measurements per samples were normalized using *GAPDH*. Relative expression between sham-treated naïve rats and the injured limb muscle samples was determined using the comparative Ct method ($2^{-\Delta\Delta Ct}$) [17]. In comparison to sham-treated naïve rats, genes that were differentially expressed at least threefold were depicted using a heat map. Assays with Ct values greater than 35 cycles were considered not expressed and are not reported.

Quantification of Protein Expression

A sample (detailed subsequently) of the differentially expressed genes involved in extracellular matrix remodeling, cartilage deposition and vasculogenesis, and mineralization-ossification were verified by enzyme-linked immunosorbent assay (ELISA) [24]. Protein from skeletal muscle samples (30–32 mg) of the injured and contralateral limbs of rats euthanized 3, 5, and 7 days postinjury was isolated using the Total Protein Extraction Kit (EMD Millipore, Billerica, MA, USA) and total concentrations were determined using the BCA Protein Assay Kit (Pierce, Rockford, IL, USA). Quantification of protein levels of rat substance P (*SP-1*), Neurokinin A, and calcitonin gene-related peptide (*CGRP*) were assayed by enzyme immunoassay (Phoenix Pharmaceuticals, Inc, Burlingame, CA, USA). In addition, levels of noggin (*NOG*), osteocalcin (*OCN*), runt-related transcription factor 2 (*RUNX-2*), and bone morphogenetic protein 2 (*BMP-2*) were assayed by ELISA (MyBioSource, San Diego, CA, USA). For each analyte, samples were equally loaded based on the total protein concentration assayed in duplicate. Absolute tissue sample concentrations of each analyte were calculated from a standard curve of known standards and corrected for protein concentration.

Statistical Analysis

Continuous variables (protein expression) were evaluated with Student's t-test provided the data were normally distributed, whereas noncontinuous data (gene expression) were analyzed with the Mann-Whitney U test. Two-tailed $\alpha < 0.05$ was considered statistically significant. All data are presented as means \pm SD unless otherwise specified.

Results

In this physiologic model of combat-related HO, blast exposure in the presence of severe extremity trauma produced μ CT radiographic evidence of HO within the soft tissue surrounding the fracture/amputation site in 100% of the animals within 28 days (Fig. 1). We observed no radiographic evidence of neurogenic HO development (around joints and/or in the soft tissue distant from the fracture/amputation site) in our model or in blast only-treated rats. Foci of proliferative/hypertrophic chondrocytes were observed in tissue surrounding the amputation site (Fig. 2A–F) as early as 5 days and certainly by postoperative Day 10. By Day 14, endochondral ossification was evident because the ectopic chondrocyte-rich basophilic hyaline cartilage was replaced with acidophilic bone matrix (osteoid) later followed by the

immature woven bone typical of HO arising from the process of endochondral ossification (Fig. 2G–I). None of the contralateral limbs from blast-injured rats or limbs from sham-treated rats developed radiographic or histologic evidence of HO.

Genes involved in chondrogenesis (*COL1 α 1*), osteogenesis (*RUNX-2*, *OCN*, *PHEX*, and *POU5F1*), wound healing/tissue repair (*MMP9*, *CSF3*, *FGF-10*, and *HAS1*), and adipogenesis (*ADIPOQ* and *PPARG*) were notably overexpressed (greater than threefold) at the amputation site, whereas all angiogenic targets were unchanged (less than threefold) in comparison to quadriceps muscle tissue collected from the contralateral limb and sham-treated naïve rats (Fig. 3). The in vivo tissue production of key osteogenic proteins *NOG* (6.78 ± 1.38 ng; 95% confidence interval [CI], 4.06–9.50; $p = 0.04$), *OCN* (6.54 ± 0.56 ng; 95% CI, 5.43–7.65; $p = 0.02$), and *RUNX-2* (7.76 ± 0.94 ng; 95% CI, 5.92–9.61; $p = 0.04$) were elevated at 3 days postinjury relative to normal muscle tissue collected from sham-treated 5.92–9.61 naïve controls (Fig. 4A). In addition, we observed that the amount of the peripherally released neurotransmitter

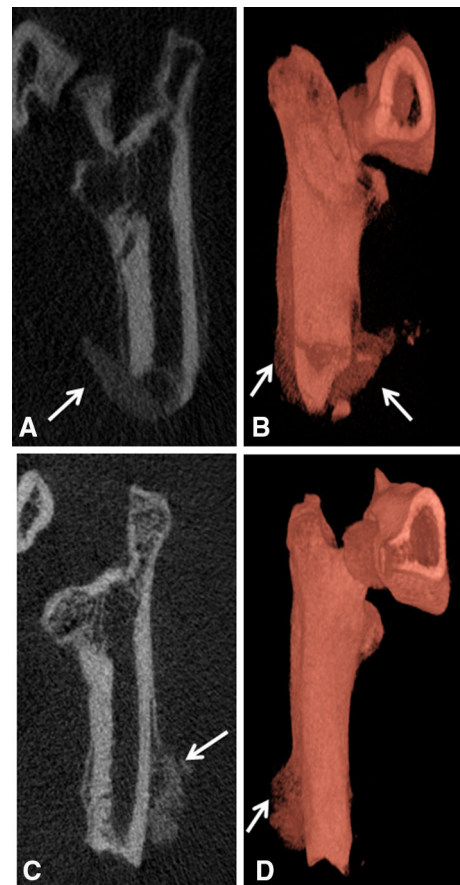


Fig. 1A–D Representative μ CT and 3-D reconstructed images of rats euthanized at postinjury Day 21 (A–B) and Day 28 (C–D) are shown. The arrows indicate the formation of ectopic bone.

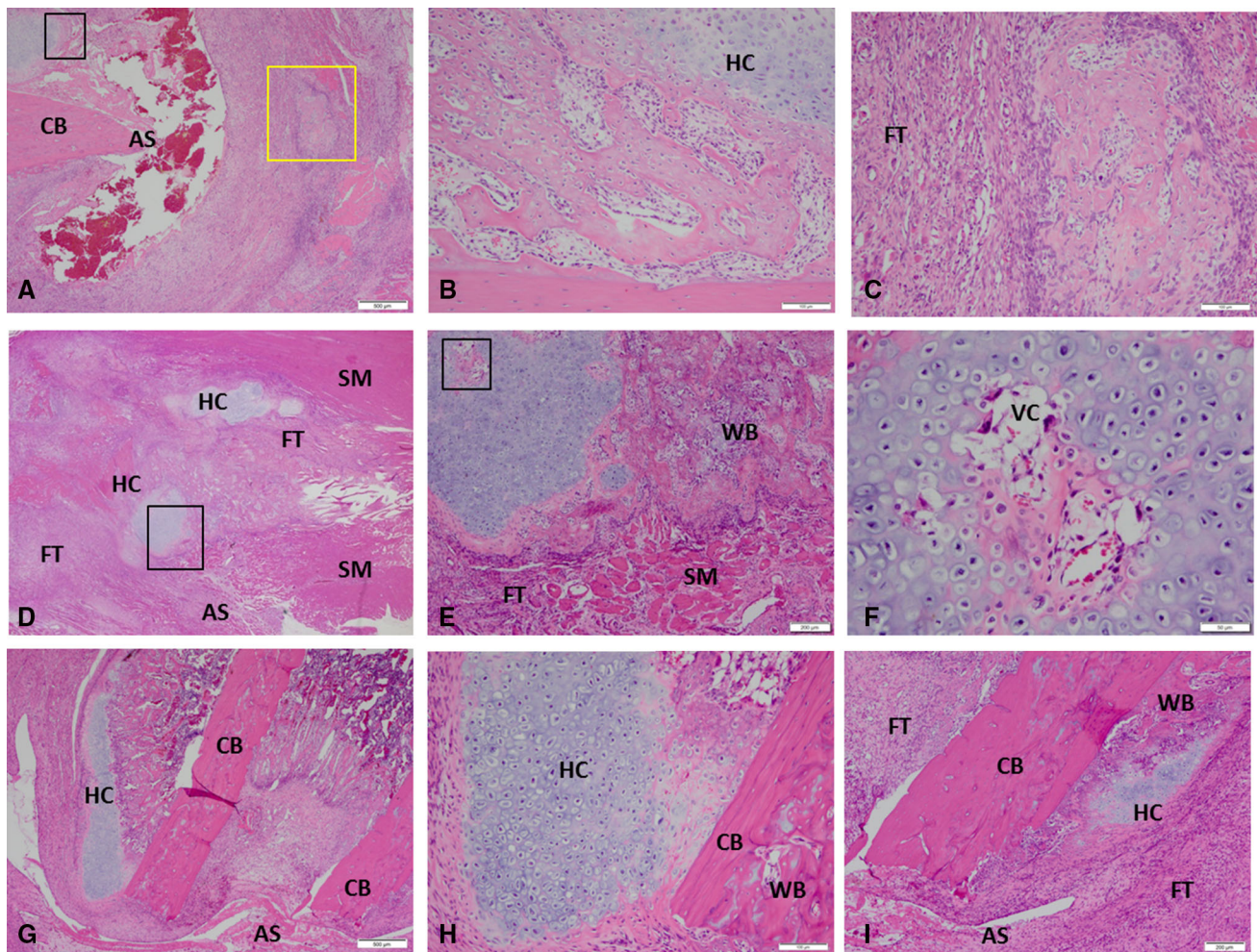


Fig. 2A–I These images show the histological evidence of early HO formation at the site of amputation postinjury Day 7 (A–C), Day 10 (D–F), and Day 14 (G–I) (Stain, hematoxylin and eosin). For detailed evaluation, higher magnification images of five selected regions are shown. (B–C) High-magnification views of the areas are outlined by the black inset box and yellow inset box in A, respectively. (E, F, H) High-magnification views show the areas outlined the black inset box

in D, E, and G, respectively. Foci of hyaline and vascularized cartilage with woven bone are observed in the soft tissue surrounding the site of amputation at postinjury Days 10 to 14. AS = amputation site; CB = cortical bone; FT = fibroblastic tissue; HC = hyaline cartilage; SM = skeletal muscle; VC = vascularized cartilage; WB = woven bone.

SP-1 was higher in the injured limb at 3 to 7 days postinjury (0.2 ± 0.04 ng; 95% CI, 0.10–0.27; 0.32 ± 0.10 ng; 95% CI, 0.10–0.53; and 0.4 ± 0.13 ng; 95% CI, 0.12–0.67; per 30 mg of tissue) when compared with sham-treated naïve control muscle ($p = 0.002$, $p = 0.009$, and $p = 0.01$, respectively) and muscle collected from the contralateral leg, which was subjected only to blast-related trauma (Fig. 4B). There were no differences observed in concentrations of neurokinin A, *CGRP*, or *BMP-2* (data not shown).

Discussion

High-energy blast exposure to the extremities results in extensive soft tissue, muscle, vascular, nerve, and bone

destruction often resulting in limb amputations, which collectively pose formidable surgical, postoperative treatment, and rehabilitation challenges. The prevalence of ectopic bone development in the residual limbs of patients with combat-related amputations is reported to be as high 65% [22]. Advances in combat casualty care-related wound healing are limited by an incomplete understanding of fundamental cellular and molecular mechanisms driving normal healing processes versus the dysregulated wound healing responses. In this study, we described the histology and local microenvironment during the early differentiation phase of stem cells/progenitor cells in a rat model of combat-related HO that integrates some of the key injury patterns seen in our blast-wounded service members. Using our established and highly reproducible animal model of trauma-induced HO, we provide definitive evidence that

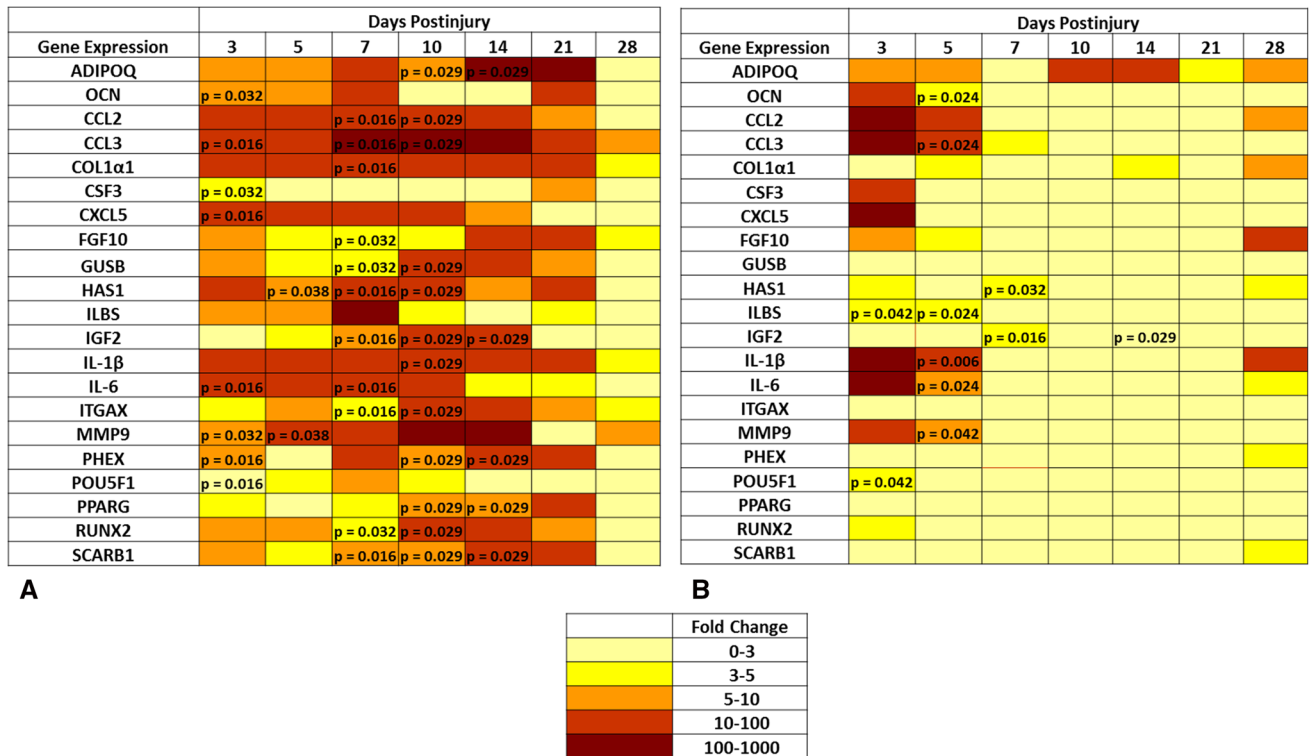


Fig. 3A–B A transcript heat map depicting the expression level of the subset of the 83 rat chondrogenic, osteogenic, and angiogenic-related gene targets whose differential expression was greater than threefold compared with the expression level in sham-treated control

muscle. (A) Injured leg and (B) contralateral leg and significantly different ($p < 0.05$; Mann-Whitney U test) compared with sham-treated rats are noted with p values.

the pathophysiological process of ectopic bone formation is through endochondral ossification, replacement of cartilage by bone. Results from these studies that recapitulate the clinical disease process will be most useful in advancing our understanding of early underlying molecular signaling pathways and cell development stages involved in formation of extraskeletal bone formation and facilitate the identification of targeted novel therapeutic strategies.

Several limitations to our study are noteworthy. The primary limitation is that the work was only conducted on one animal species. It is possible that a large animal model (swine or nonhuman primate), similar in size and physiology to humans, may more closely mimic the trauma-induced local and systemic responses exhibited by combat casualties. In addition, larger animal models may allow for the incorporation of other postoperative surgical and treatment variables such as serial débridement procedures and negative pressure wound therapy, which is difficult to use in a small animal model. Second, factors that influence the development of HO may prove to be the actual biological mechanism accounting for the extent and severity of injury. Unlike on the battlefield, the multifaceted injury patterns, limb amputation, and surgical repair/wound closure in this model were all made in sequence and within hours of injury

rather than days to weeks postinjury after serial débridement procedures, as seen in the clinical setting. Third, we assessed the combinatorial effects of the critical elements associated with combat injury, which results in 100% radiographic evidence of ectopic bone formation. In regard to early histological changes and gene expression signaling, it may be worthwhile to evaluate the importance of each injury pattern alone and in various combinations. Lastly, we evaluated the time course of gene expression for a small subset of genes at given times wherein regulation may have occurred earlier than 3 days postinjury and/or expression of some genes may be highly temporal in regulation during early ectopic bone development. Furthermore, it is likely that the same mediators that promote normal wound healing also support ectopic bone development; however, we believe the nature and severity of the injury involving blast exposure in conjunction with a heightened and prolonged local and systemic immune response plays a major role in ectopic bone formation/wound dehiscence versus normal healing in combat-wounded patients.

Micro-CT scans showed an increase in ectopic bone development at 3 to 4 weeks within the soft tissue surrounding the site of amputation. These findings are consistent with those of radiographic studies detecting

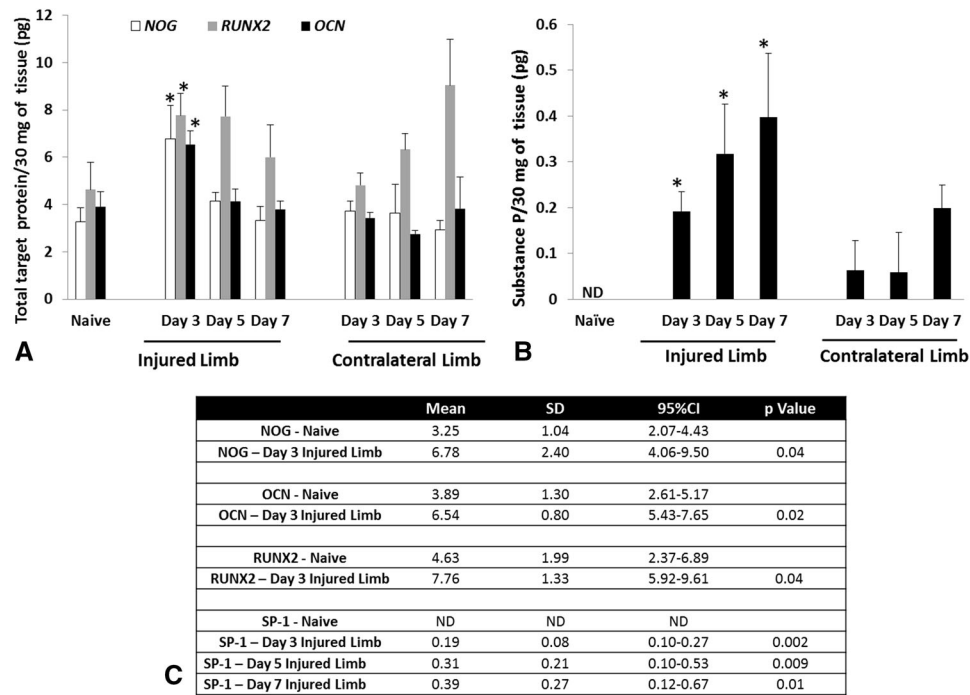


Fig. 4A–C The amount of *NOG*, *RUNX-2* and *OCN* (A) and *SP-1* (B) protein was quantified from tissue samples harvest at the site of amputation. (C) The levels of *NOG*, *OCN*, and *RUNX-2* are statistically significant from the sham-treated (naïve) rats at 3 days

postinjury, whereas the levels of *SP-1* are significantly different from the sham-treated (naïve) rats at 3 to 7 days postinjury (* $p < 0.05$; Student's t-test).

early evidence of soft tissue mineralization and bone deposition in combat-wounded patients [23]. At Day 7 to 10 postinjury, abundant foci of hypertrophic chondrocytes and vascularized hyaline cartilage were present. By Days 10 to 14, the soft tissue contained abundant hyaline cartilage with hypertrophic chondrocytes with evidence of subsequent mineralization and osteoprogenitor cell migration as denoted by zones of primary woven bone (immature endochondral bone formation). By Day 28, qualitative analysis of ectopic bone formation using 3-D high-resolution μ CT showed a peak in the size of radiographically detectable bone in the soft tissue, which was supported by clear histological evidence of woven bone. This is similar to the results observed in another animal model of post-traumatic HO [30].

Gene expression during endochondral bone formation is regulated by a series of chondrogenic and osteogenic inductive cell signaling, proliferation, and differentiation events at the undifferentiated mesenchymal stem/progenitor cell stage involving extracellular matrix remodeling, cartilage deposition and vasculogenesis, mineralization ossification, and subsequent replacement with bone [15, 24]. A cohort of gene transcripts and key osteogenic-related proteins (*RUNX-2*, *OCN*, *NOG*, *SP-1*) were identified that correlate to the early histological response and development of ectopic bone. *RUNX-2* is the

early master regulator of osteogenic/osteoblast differentiation [16], and *OCN* is a prime marker of bone development produced by osteoblasts [18]. *SP-1* is a neuroinflammatory peptide that has been reported to promote the mobilization, proliferation, and osteogenic differentiation of mesenchymal stem cells at sensory nerve structures [25, 26]. We showed here that the expression of *SP-1* is induced systemically in our trauma-induced model, providing a connection between blast injury and increased formation of ectopic bone. Consistent with previous studies examining endochondral bone development and early ossification, we observed that HO is coupled with an early increase in the expression of transcripts necessary for synthesis of a cartilaginous matrix (*COL1 α 1*), bone and osteoblast mineralization (*RUNX-2*, *OCN*, *PHEX*, and *POU5F1*), tissue remodeling (*MMP9*, *CSF3*, *FGF-10*, and *HAS1*), and inflammatory cytokines (*IL-6*, *IL1 β* , *CCL2*, *CCL3*, and *CXCL5*) within the first 14 days postinjury [14].

Recently, Peterson et al. [19] demonstrated in a murine Achilles tenotomy plus partial-thickness dorsum burn injury model that injured mice develop endochondral ectopic bone and functional joint contractures through BMP-mediated canonical small “mothers against” decapentaplegic (SMAD) signaling. Moreover, they report that these orthopaedic disease processes can be attenuated/modulated by targeting adenosine triphosphate (ATP) hydrolysis and

SMAD1/5/8 phosphorylation at the burn site using apyrase [19]. Interestingly, it has been reported that focused extracorporeal shockwave therapy (ESWT; low-density shockwaves administered orders of magnitude below blast overpressure conditions used in the study) has been shown to induce osteogenic differentiation of marrow-derived mesenchymal stem cells through ATP release and downstream transcriptional signaling events resulting in activation of P2X7 receptors [28]. Consistent with the finding of Peterson et al., removal of ATP using apyrase inhibited ESWT-induced osteogenic differentiation. ESWT has been used in treatment of bone and soft tissue disorders and shown to stimulate soft tissue expression of osteogenic factors (BMPs, OC, OPN, TGF β 1) but also angiogenic factors (VEGF, FGF) [27, 32]. Therefore, it is not surprising that many of the genes induced in the musculature of the injured limb show parallel, albeit reduced, levels of change in the contralateral limb.

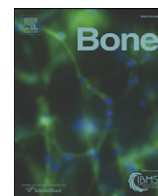
In this study, we defined the histologic time course and pertinent molecular signaling patterns in the early stages of HO development using a rat model of combat-related HO that incorporates the critical elements associated with combat injury. Based on these findings, we propose that the initiation of prophylactic therapy targeted at inhibiting the synthesis of ectopic cartilage should start soon after injury in the rat to avoid any adverse effects on physiologic early wound healing processes such as tissue revascularization and granulation tissue development. The ability to correlate molecular events with histologic and morphologic changes will help researchers and clinicians to understand the HO process. In addition, ascertaining how applicable the findings are to the wound healing process in humans will be important in formulating therapeutic interventions that target early chondrogenic, angiogenic, and osteogenic signaling components of ectopic bone development.

Acknowledgments We thank Dana M. Golden and Allison M. Tomasino for assistance with animal care, sample collections, and technical expertise; Dr Matthew Wagner for his statistical analysis; and LTC Cary L. Hannold for his detailed histological review of specimens.

References

- Ahlers ST, Vasserman-Stokes E, Shaughnessy MC, Hall AA, Shear DA, Chavko M, McCarron RM, Stone JR. Assessment of the effects of acute and repeated exposure to blast overpressure in rodents: toward a greater understanding of blast and the potential ramifications for injury in humans exposed to blast. *Front Neurol*. 2012;3:32.
- Ahrengart L. Periarticular heterotopic ossification after total hip arthroplasty: risk factors and consequences. *Clin Orthop Relat Res*. 1991;263:49–58.
- Bonnarens F, Einhorn TA. Production of a standard closed fracture in laboratory animal bone. *J Orthop Res*. 1984;2:97–101.
- Chavko M, Koller WA, Prusaczyk WK, McCarron RM. Measurement of blast wave by a miniature fiber optic pressure transducer in the rat brain. *J Neurosci Methods*. 2007;159:277–281.
- Crane NJ, Polfer E, Elster EA, Potter BK, Forsberg JA. Raman spectroscopic analysis of combat-related heterotopic ossification development. *Bone*. 2013;57:335–342.
- Davis TA, O'Brien FP, Anam K, Grijalva S, Potter BK, Elster EA. Heterotopic ossification in complex orthopaedic combat wounds: quantification and characterization of osteogenic precursor cell activity in traumatized muscle. *J Bone Joint Surg Am*. 2011;93:1122–1131.
- Evans EB. Heterotopic bone formation in thermal burns. *Clin Orthop Relat Res*. 1991;263:94–101.
- Evans KN, Forsberg JA, Potter BK, Hawksworth JS, Brown TS, Andersen R, Dunne JR, Tadaki D, Elster EA. Inflammatory cytokine and chemokine expression is associated with heterotopic ossification in high-energy penetrating war injuries. *J Orthop Trauma*. 2012;26:e204–e213.
- Evans KN, Potter BK, Brown TS, Davis TA, Elster EA, Forsberg JA. Osteogenic gene expression correlates with development of heterotopic ossification in war wounds. *Clin Orthop Relat Res*. 2014;472:396–404.
- Forsberg JA, Davis TA, Elster EA, Gimble JM. Burned to the bone. *Sci Transl Med*. 2014;6:255fs237.
- Forsberg JA, Pepek JM, Wagner S, Wilson K, Flint J, Andersen RC, Tadaki D, Gage FA, Stojadinovic A, Elster EA. Heterotopic ossification in high-energy wartime extremity injuries: prevalence and risk factors. *J Bone Joint Surg Am*. 2009;91:1084–1091.
- Forsberg JA, Potter BK, Polfer EM, Safford SD, Elster EA. Do inflammatory markers portend heterotopic ossification and wound failure in combat wounds? *Clin Orthop Relat Res*. 2014;472:2845–2854.
- Garland DE. A clinical perspective on common forms of acquired heterotopic ossification. *Clin Orthop Relat Res*. 1991;263:13–29.
- James CG, Stanton L-A, Agoston H, Ulici V, Underhill TM, Beier F. Genome-wide analyses of gene expression during mouse endochondral ossification. *PLoS One*. 2010;5:e8693.
- Kaplan FS, Glaser DL, Hebela N, Shore EM. Heterotopic ossification. *J Am Acad Orthop Surg*. 2004;12:116–125.
- Kirkham G, Cartmell S. *Genes and Proteins Involved in the Regulation of Osteogenesis*. London, UK: Hindawi Publishers; 2007.
- Livak KJ, Schmittgen TD. Analysis of relative gene expression data using real-time quantitative PCR and the 2^{(-Delta Delta C(T))} method. *Methods*. 2001;25:402–408.
- Nakamura A, Dohi Y, Akahane M, Ohgushi H, Nakajima H, Funaoka H, Takakura Y. Osteocalcin secretion as an early marker of in vitro osteogenic differentiation of rat mesenchymal stem cells. *Tissue Eng Part C Methods*. 2009;15:169–180.
- Peterson JR, De La Rosa S, Eboda O, Cilwa KE, Agarwal S, Buchman SR, Cederna PS, Xi C, Morris MD, Herndon DN. Treatment of heterotopic ossification through remote ATP hydrolysis. *Sci Transl Med*. 2014;6:255ra132.
- Peterson JR, Okagbare PI, De La Rosa S, Cilwa KE, Perosky JE, Eboda ON, Donneys A, Su GL, Buchman SR, Cederna PS, Wang SC, Kozloff KM, Morris MD, Levi B. Early detection of burn induced heterotopic ossification using transcutaneous Raman spectroscopy. *Bone*. 2013;54:28–34.
- Polfer EM, Hope DH, Elster EA, Qureshi AT, Golden DM, Potter BK, Davis TA, Forsberg JA. Development of a rat model for blast-related post-traumatic heterotopic ossification. *Bone Joint J*. 2015;97.
- Potter BK, Burns TC, Lacap AP, Granville RR, Gajewski DA. Heterotopic ossification following traumatic and combat-related amputations. Prevalence, risk factors, and preliminary results of excision. *J Bone Joint Surg Am*. 2007;89:476–486.

23. Potter MBK, Forsberg LJA, Davis TA, Evans CKN, Hawksworth MJS, Tadaki D, Brown TS, Crane NJ, Burns MTC, O'Brien CFP. Heterotopic ossification following combat-related trauma. *J Bone Joint Surg Am.* 2010;92:74–89.
24. Provot S, Schipani E. Molecular mechanisms of endochondral bone development. *Biochem Biophys Res Commun.* 2005;328:658–665.
25. Salisbury E, Rodenberg E, Sonnet C, Hipp J, Gannon FH, Vadakkan TJ, Dickinson ME, Olmsted-Davis EA, Davis AR. Sensory nerve induced inflammation contributes to heterotopic ossification. *J Cell Biochem.* 2011;112:2748–2758.
26. Salisbury E, Sonnet C, Heggeness M, Davis AR, Olmsted-Davis E. Heterotopic ossification has some nerve. *Crit Rev Eukaryot Gene Expr.* 2010;20:313–324.
27. Stojadinovic A, Elster EA, Anam K, Tadaki D, Amare M, Zins S, Davis TA. Angiogenic response to extracorporeal shock wave treatment in murine skin isografts. *Angiogenesis.* 2008;11:369–380.
28. Sun D, Junger WG, Yuan C, Zhang W, Bao Y, Qin D, Wang C, Tan L, Qi B, Zhu D. Shockwaves induce osteogenic differentiation of human mesenchymal stem cells through ATP release and activation of P2X7 receptors. *Stem Cells.* 2013;31:1170–1180.
29. Svetlov SI, Prima V, Glushakova O, Svetlov A, Kirk DR, Gutierrez H, Serebruany VL, Curley KC, Wang KK, Hayes RL. Neuro-glial and systemic mechanisms of pathological responses in rat models of primary blast overpressure compared to 'composite' blast. *Front Neurol.* 2012;3:15.
30. Tannous O, Griffith C, O'Toole RV, Pellegrini VD Jr. Heterotopic ossification after extremity blast amputation in a Sprague-Dawley rat animal model. *J Orthop Trauma.* 2011;25:506–510.
31. Tintle LSM, Baechler LMF, Nanos CGP, Forsberg LJA, Potter MBK. Reoperations following combat-related upper-extremity amputations. *J Bone Joint Surg Am.* 2012;94:e119.111–116.
32. Wang C-J. Extracorporeal shockwave therapy in musculoskeletal disorders. *J Orthop Surg Res.* 2012;7:1–8.



Full Length Article

Targeted stimulation of retinoic acid receptor- γ mitigates the formation of heterotopic ossification in an established blast-related traumatic injury model[☆]



Gabriel J. Pavey^{a,f,1}, Ammar T. Qureshi^{a,1}, Allison M. Tomasino^a, Cary L. Honnold^b, Danett K. Bishop^c, Shailesh Agarwal^d, Shawn Loder^d, Benjamin Levi^d, Maurizio Pacifici^e, Masahiro Iwamoto^e, Benjamin K. Potter^{a,f}, Thomas A. Davis^{a,f,*}, Jonathan A. Forsberg^{a,f}

^a Regenerative Medicine Department, Naval Medical Research Center, Silver Spring, MD, United States

^b Department of Pathology, Naval Medical Research Center, Silver Spring, MD, United States

^c Department of Wound Infections, Naval Medical Research Center, Silver Spring, MD, United States

^d Department of Surgery, University of Michigan Health System, Ann Arbor, MI, United States

^e Division of Orthopaedic Surgery, The Children's Hospital of Philadelphia, PA, United States

^f USU-Walter Reed Surgery, Walter Reed National Military Medical Center, Bethesda, MD, United States

ARTICLE INFO

Article history:

Received 7 March 2016

Revised 24 May 2016

Accepted 26 June 2016

Available online 28 June 2016

Keywords:

Heterotopic ossification

Prophylaxis

Animal model

Retinoic acid receptor- γ agonist

Endochondral ossification

Traumatic extremity injury

Blast overpressure exposure

Bioburden

ABSTRACT

Heterotopic ossification (HO) involves formation of endochondral bone at non-skeletal sites, is prevalent in severely wounded service members, and causes significant complications and delayed rehabilitation. As common prophylactic treatments such as anti-inflammatory drugs and irradiation cannot be used after multi-system combat trauma, there is an urgent need for new remedies. Previously, we showed that the retinoic acid receptor γ agonist Palovarotene inhibited subcutaneous and intramuscular HO in mice, but those models do not mimic complex combat injury. Thus, we tested Palovarotene in our validated rat trauma-induced HO model that involves blast-related limb injury, femoral fracture, quadriceps crush injury, amputation and infection with methicillin-resistant *Staphylococcus aureus* from combat wound infections. Palovarotene was given orally for 14 days at 1 mg/kg/day starting on post-operative day (POD) 1 or POD-5, and HO amount, wound dehiscence and related processes were monitored for up to 84 days post injury. Compared to vehicle-control animals, Palovarotene significantly decreased HO by 50 to 60% regardless of when the treatment started and if infection was present. Histological analyses showed that Palovarotene reduced ectopic chondrogenesis, osteogenesis and angiogenesis forming at the injury site over time, while fibrotic tissue was often present in place of ectopic bone. Custom gene array data verified that while expression of key chondrogenic and osteogenic genes was decreased within soft tissues of residual limb in Palovarotene-treated rats, expression of cartilage catabolic genes was increased, including matrix metalloproteinase-9. Importantly, Palovarotene seemed to exert moderate inhibitory effects on wound healing, raising potential safety concerns related to dosing and timing. Our data show for the first time that Palovarotene significantly inhibits HO triggered by blast injury and associated complications, strongly indicating that it may prevent HO in patients at high risk such as those sustaining combat injuries and other forms of blast trauma.

Published by Elsevier Inc.

Abbreviations: BMP, Bone morphogenetic proteins; CFU, Colony forming unit; COL1 α 1, Collagen type 1 alpha 1; COL2 α 1, Collagen type 2 alpha 1; DMSO, Dimethylsulfoxide; FGF1, Fibroblast Growth Factor-1; FGF10, Fibroblast Growth Factor-10; H&E, hematoxylin-Eosin; HO, Heterotopic ossification; IP, Intraperitoneal; mCT, Micro-computed tomography; MMP9, Matrix metalloproteinase 9; MRSA, Methicillin-resistant *Staphylococcus aureus*; NSAIDs, Nonsteroidal anti-inflammatory drugs; OCN, Osteocalcin; POU5F1, POU domain class 5 transcription factor; RAR, Retinoic acid receptor; RT-PCR, Reverse transcription polymerase chain reaction; RUNX2, Runt-related transcription factor 2; SOX2, (Sex Determining Region Y)-Box2; ROI, Regions of interest.

[☆] Some of the authors are employees of the US Government. This work was prepared as part of their official duties. Title 17 U.S.C. §105 provides that "Copyright protection under this title is not available for any work of the United States Government." Title 17 U.S.C. §101 defined a US Government work as a work prepared by a military service member or employees of the US Government as part of that person's official duties. The opinions or assertions contained in this paper are the private views of the authors and are not to be construed as reflecting the views, policy or positions of the Department of the Navy, Department of Defense nor the US Government. Each author certifies that his or her institution approved the animal protocol for this investigation and that all investigations were conducted in conformity with ethical principles of research. This work performed at the Naval Medical Research Center, Silver Spring, MD, USA.

* Corresponding author at: Regenerative Medicine Department, Naval Medical Research Center, 503 Robert Grant Ave, Silver Spring, MD 20910, United States.

E-mail address: thomas.a.davis196.ctr@mail.mil (T.A. Davis).

¹ These authors contributed equally.

1. Introduction

Heterotopic ossification (HO) consists of ectopic bone formation within non-skeletal tissues and sites and can be classified as genetic, neurogenic or traumatic in origin [1–5]. Post-traumatic HO is most commonly encountered following high-energy trauma, spinal cord and brain injury, severe burns, [6,7] and in orthopaedic practice following hip or elbow surgery [8,9]. Recent studies have revealed that HO is actually most prevalent in severe combat-related extremity wounds and within residual limbs after combat-related amputations [3,10–12]. Blast and other severe polytraumatic injuries elicit complex and often dysregulated inflammatory and physiological responses, and the pathological interactions amongst diverse tissues, cell types, inflammatory mediators and local and systemic signaling pathways provide fertile ground for HO development. The clinical complications of HO include activity-limiting pain, primary (ankylosis) and secondary (muscle-tendon tethering) joint stiffness, skin ulceration and poor tolerance of prosthesis wear, wherein conservative interventions such as multi-modal pain regimens, physiotherapy and prosthetic modification fail to alleviate symptoms in up to 41% of patients [10]. Surgical excision of HO, although the standard of care, often fails to relieve the underlying joint contractures [13], can be fraught with complications and, even when successful, can further delay rehabilitation because of its invasive nature; in some cases, it can even lead to recurrent HO [3,11,14]. Surgical excision is also unable to address the chronic symptoms associated with HO including joint contracture, chronic pain, and non-healing wounds. In addition, current prophylaxis strategies used in the general population –such as administration of non-steroidal anti-inflammatory drugs (NSAIDs) and external beam radiotherapy– are generally contraindicated in the setting of multi-system combat trauma because they have deleterious systemic and local side effects and may not be logistically feasible in forward deployed war settings [15]. Furthermore, it is not clear how effective these strategies actually are given that penetration and severity of HO in the general population vary significantly. Thus, it would be highly desirable to have a simple, effective and safe prophylactic pharmacologic therapy that could be easily administered systemically post-injury, would avoid adverse complications and outcomes, and would minimize treatment duration. Such treatment would have immense impact on the burden of HO disease and resulting pathogenic sequelae, and the search for such novel and non-invasive means of primary HO prevention continues to attract substantial interest and effort.

Heterotopic ossification, when triggered by traumatic injury or other major insults most often arises via endochondral ossification, one of the two essential processes by which the native skeleton forms and grows during embryogenesis and early postnatal life [16–19]. Skeletal elements including long bones, ribs and vertebrae are initially laid down as entirely cartilaginous structures in early embryogenesis. The cartilaginous tissue then undergoes a process of maturation and hypertrophy, and the resulting hypertrophic cartilage is invaded by vascular and osteopotent cells and is replaced by endochondral bone and marrow. This complex series of events and differentiation steps is governed by equally complex mechanisms that include local and systemic hormones and cytokines, transcription factors and multiple signaling proteins including members of the bone morphogenetic protein (BMP) family. Experimental prophylactic therapies targeting the BMP signaling pathway and its regulatory networks have shown some degree of efficacy against HO in murine models [20,21]. However, it is not known how effective and safe these treatments would be in patients and in particular those suffering from combat injuries and whether they would have unwanted side effects because of the multiple roles BMPs and BMP signaling have in body physiology and function.

The retinoid signaling pathway and nuclear retinoic acid receptors (RARs) are important regulators of skeletal development and growth [22]. In particular, chondrogenesis was shown to require a steep decrease in endogenous retinoid action during skeletogenesis [23], and

exogenous retinoid agonists were in fact found to strongly inhibit chondrogenesis and skeletal development [22,24]. Because of their ability to block condensation of skeletal progenitor cells and their differentiation into chondrocytes that represent the initial stages of HO, we previously asked whether synthetic retinoid agonists could block HO. We used mouse models of skeletogenic protein- or genetic mutation-induced HO and found that the RAR- γ agonist Palovarotene was amongst the most potent anti-HO agents [25,26]. Analysis of mechanisms showed that this and other retinoids did, in fact, act by significantly decreasing chondrogenesis and in turn osteogenesis and vascularization. At the cellular level, the drugs dampened canonical BMP signaling –an effect involving ubiquitination and proteasome degradation of Smad proteins– and concurrently increased Wnt β -catenin signaling, a potent endogenous inhibitor of chondrogenesis [27,28]. While the above studies are quite promising, it remains unclear whether a retinoid-based strategy would be equally effective in the far more complex setting of HO developing after combat injuries in which the affected site is usually large, the wounds are extremely severe, multiple tissues are damaged, and bacterial infections are common.

We recently developed a rat model that incorporates the multiple pathogenic insults sustained by combat casualties with severe orthopaedic extremity injuries which we believe is significantly more representative than non-physiologic models of excess BMP ligand administration or genetic mutations. These insults include exposure to blast overpressure, femur fracture, quadriceps crush injury followed by limb amputation through the zone of injury, and finally inoculation of the myodesis with a highly virulent isolate of methicillin-resistant *Staphylococcus aureus* (MRSA) obtained from combat wound infections [13,29]. Previously, we reported on the timing and kinetics of ectopic bone development in this trauma induced HO model. Using molecular and histological tools, we found that chondrogenesis became apparent approximately 3 days following injury and was subsequently followed by cartilage hypertrophy and endochondral bone formation within soft tissues surrounding the amputation site starting around post-injury day 10 [16]. Understanding the timing of these key developmental phases and events was quite important as it now provides a window for prophylactic administration of candidate therapies that could target mechanisms and pathways involved in endochondral ossification. Herein, we sought to determine whether and how Palovarotene may be able to inhibit trauma-induced endochondral HO formation in our rat blast model. To evaluate possible unwanted side effects, we monitored and assessed wound healing as well.

2. Materials and methods

2.1. Animals

A total of 110 young adult pathogen-free male Sprague Dawley rats (*Rattus norvegicus*; 400–600 g) were purchased from Taconic Farms (Germantown, NY). All animals were housed individually in plastic cages and kept on a 12-hour light/dark cycle with unlimited access to food (standard rodent chow) and fresh water ad libitum. They were acclimated for at least one week before experimentation. Prior to experimentation, animals were randomized into experimental and control groups. The study protocol (12-OUMD-20S) was reviewed and approved by the Walter Reed Army Institute of Research/Naval Medical Research Center Institutional Animal Care and Use Committee in compliance with all applicable Federal regulations governing the protection of animals in research.

2.2. Rat HO model and surgical procedures

Exposure to blast and trauma-induced injury was conducted as previously described [12,22]. Briefly, 106 rats were anesthetized with isoflurane (2–4%) and were exposed to blast overpressure (120 ± 7 kPa) via a pneumatically-driven shock tube. They sustained a

controlled femoral fracture followed by a 1 min soft tissue crush injury, limb amputation through the zone of injury and inoculation of the local soft tissue with 1×10^6 CFU MRSA. Appropriate débridement of devitalized tissue was performed followed by hamstring and quadriceps myoplasty over the exposed residual femur. The incision was closed with 2 interrupted deep subcutaneous 3-0 Vicryl (Ethicon, Somerville, NJ, USA) sutures and a running 4-0 subcuticular Monocryl (Ethicon, Somerville, NJ, USA). The incision was then covered in Vetbond (3M Animal Care Products, St Paul, MN, USA). Post-surgically, sustained release Buprenorphine (1.2 mg/kg) was administered subcutaneously on day of surgery and again on post-operative day 3 for peri-operative pain control. Rats received via oral gavage (100 μ l) either Palovarotene (1.0 mg/kg) or vehicle as control (5% DMSO in corn oil) prepared as previously described [25] every other day for 14 days, starting at postoperative day 1 (POD-1) or POD-5. Rats were euthanized at indicated time points post-injury for *ex vivo* end point analysis by micro-computed CT (μ CT), histology and RT-PCR gene transcript expression.

2.3. Experimental study groups

Study 1: To determine the efficacy of Palovarotene in inhibiting ectopic bone formation, 66 rats were randomized into 1 of 8 treatment groups to monitor the development of HO formation longitudinally and non-invasively by μ CT at 28, 56 and 84 days after injury. All rats were subjected to polytraumatic extremity injury \pm MRSA infection. Group-1 received MRSA + Palovarotene treatment starting at POD-1 ($n = 8$); Group-2 received MRSA + vehicle control starting at POD-1 ($n = 11$); Group-3 received MRSA + Palovarotene treatment starting at POD-5 ($n = 8$); Group-4 received MRSA + vehicle control starting at POD-5 ($n = 5$); Group-5 received Palovarotene treatment starting at POD-1 ($n = 10$); Group-6 received vehicle control starting at POD-1 ($n = 6$); Group-7 received Palovarotene treatment starting at POD-5 ($n = 10$) and Group-8 received vehicle control starting at POD-5 ($n = 8$). Four rats were sacrificed early, two rats each in Group-5 and Group-7 for losing $>15\%$ of their body weight, leaving a total of 62 in the observational study (Fig. 1A).

Study 2: In a follow-on study, an additional 40 blast trauma and extremity injured rats with MRSA contaminated wounds were treated with either Palovarotene or vehicle control beginning on POD-1 (Groups 1–2). Rats from each group were randomly euthanized at days 5, 7, 10, 15, and 28 days post injury ($n = 4$ rats per time point/treatment group) (Fig. 1B). Soft tissue surrounding but not attached to the distal portion of the residual femur was collected for histological and gene expression analysis. Four rats served as sham-treated, uninjured naïve rats to obtain healthy skeletal muscle tissue for gene expression analysis.

2.4. Micro-computed tomography imaging

Progression of ectopic bone development at the site of amputation was tracked by imaging the amputated limb on days 28, 56 and 84 post injury using an *in vivo* high-resolution micro-computed tomography (μ -CT) system (SkyScan 1176; Bruker-MicroCT, Kontich, Belgium) and a standard phantom for normalization. As previously described [13], after the rats were scanned at the mentioned time points, the scanned images from Skyscan software were rendered using NRecon Reconstructions software (Bruker-MicroCT, Kontich, Belgium) to obtain serial flattened longitudinal micro-CT slices. An investigator reviewed all these serial longitudinal micro-CT flattened images at every time point, narrowed the region that encompassed the residual femur and ectopic bone and selected regions of interest (ROI) on every fifth slice to capture all new bone (new bone associated and non-associated with the cortical margins) as well as “soft tissue ectopic bone” (ectopic bone with no association to the cortical bone margins). The three-dimensional image analysis was performed of all the flattened images with ROI yielding a volumetric measurement of total new ectopic bone (Fig. 2A) and “soft-tissue” ectopic bone (Fig. 2B) based on the selected area of interest.

2.5. Histological analysis

For histological examination, cohorts of rats at the specified time points were euthanized (Fatal Plus 50 mg/kg IP; Patterson Veterinary,

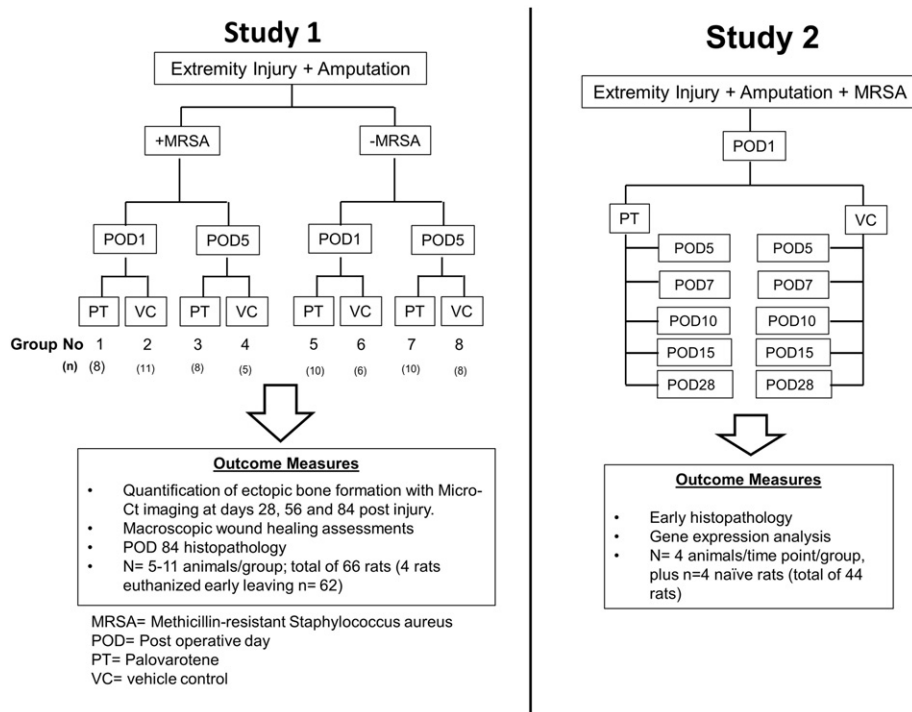


Fig. 1. Schematic outline of the experimental studies and outcome measures. The number of rats analyzed in each treatment group is indicated.

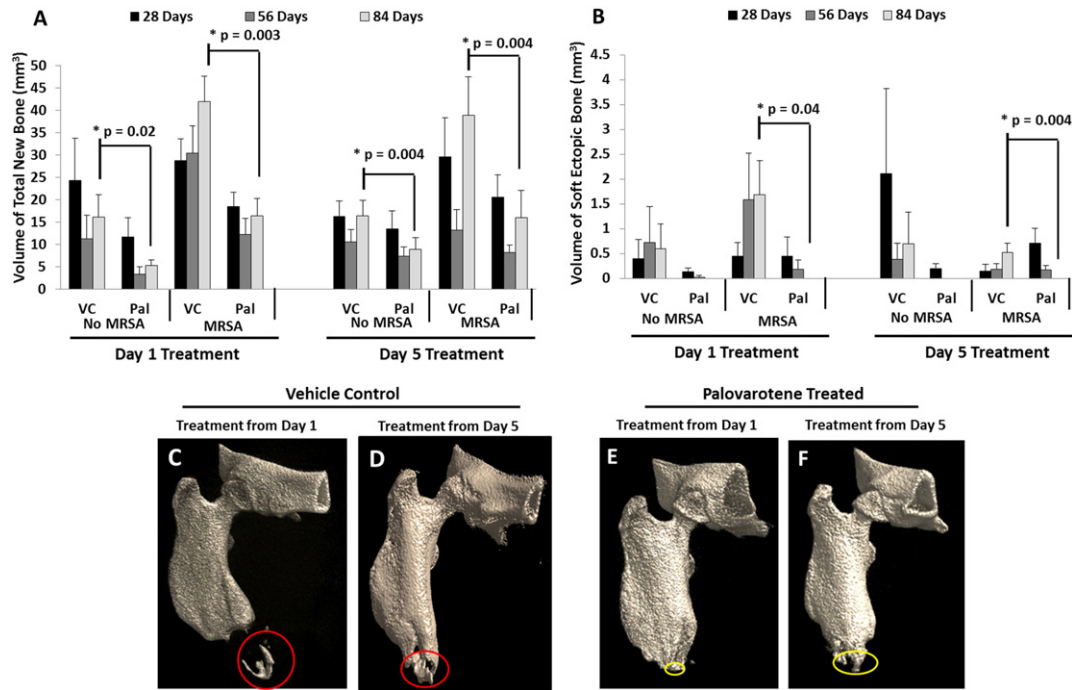


Fig. 2. Palovarotene treatment inhibits heterotopic ossification. Analysis and quantification of (A) total new bone and (B) soft tissue ectopic bone volume using the flattened μ -CT images at 28, 56 and 84 days after blast, extremity injury, amputation \pm MRSA (* = $p < 0.05$ using the Welch's two Sample t -test). Representative 3D reconstructed μ CT images of residual amputated limbs from vehicle control (C–D) and Palovarotene (E–F) treated rats at 84 days post injury after blast, extremity injury, and limb amputation with MRSA infection. Red circles indicate soft tissue ectopic bone and yellow circles indicate calcaneal ectopic bone.

Devens, MA) and disarticulation of the hip was performed to collect the residual limb, which was washed with saline thoroughly then fixed in 10% neutral buffered formalin and subsequently decalcified in 5% formic acid. After complete decalcification, tissues were embedded in paraffin wax, cut into serial 5 μ m thick longitudinal sections using a microtome and mounted onto glass slides for histology. Sections were used for immunohistochemistry or stained using hematoxylin-eosin (H&E) (Histoserv, Inc., Germantown, MD) [16].

2.6. RNA isolation and gene expression

At indicated time points, skeletal muscle tissue collected from the extremity wound, specifically surrounding the amputation site (not set against the bone), and the corresponding distal quadriceps muscle of the contralateral limb were harvested and stored in RNALater (Ambion Inc., Austin, TX, USA) at 4 °C. Skeletal muscle samples obtained from age-matched naïve uninjured rats ($n = 4$) served as control tissue. Total RNA was isolated and purified muscle cell lysates using RNeasy columns and DNase-I kits (Qiagen, Valencia, CA, USA) according to the manufacturer's protocols. RNA was stored at -80 °C in nuclease-free water (Bio-Rad, Hercules, CA, USA). Total RNA was quantified spectroscopically by using NanoDrop 1000 (ThermoFisher Scientific, Waltham, MA) and RNA integrity/quality was assessed by microcapillary electrophoresis using an Agilent 2100 Bioanalyzer (Agilent Technologies, Santa Clara, CA). Reverse transcriptase polymerase chain reaction (RT-PCR) was used to convert 1 μ g of RNA to cDNA. mRNA transcripts for 83 key genes involved in early chondrogenic, osteogenic and angiogenic signaling pathways (see Supplementary Table 1 for the complete list of genes and their function) were examined by real-time PCR using a custom low density microarray (Bio-Rad Laboratories, Hercules, CA) [16]. Relative gene transcript expression was calculated using the $2^{-\Delta\Delta C_t}$ method and normalized and compared to the gene expression levels of non-injured rat muscle tissue. Gene transcripts values that were significantly differentially expressed between treatment groups are reported.

2.7. Assessment of wound healing

Animals were observed daily by veterinary and research staff for clinical evidence of wound complications to include purulent infection, physiological distress, and superficial (not past the dermis, treated with observation) wound or frank (deep, treated with debridement and secondary surgical closure) dehiscence. We specifically quantified negative effects on wound healing by comparing the proportion of wounds that were not completely healed at 14 days post-injury with Palovarotene versus vehicle control and treatment timing, with and without MRSA inoculation. Wounds which required repeat surgery were considered to have delayed healing at 14 days even if the suture line was intact at this time point; however, superficially dehisced wounds were considered either healed or delayed based upon the presence or absence of complete epithelialization at 14 days.

2.8. Statistical analyses

Non-continuous gene expression data was analyzed with the Mann-Whitney U test and two-tailed $\alpha < 0.05$ was considered statistically significant. The reliability of the volumetric measurement of ectopic bone by μ CT images was assessed using the Intraclass correlation coefficient (ICC). The Welch's two Sample t -test and Fisher exact test were used to determine the statistical differences in ectopic bone volume (mm^3) and by correlating the incidence of postoperative wound dehiscence between the vehicle control and Palovarotene treated rats, respectively, with a statistical significance level of $p < 0.05$. All data are presented as mean \pm the standard error of the mean (SEM) unless otherwise specified.

3. Results

3.1. Palovarotene mitigates post traumatic ectopic bone formation

To test the effectiveness of Palovarotene against blast-induced HO, rats were subjected to whole body blast exposure, femur fracture and

crush injury that were followed by amputation of affected limb site and inoculation (or not) of local MRSA. Rats were then administered the drug or vehicle starting every other day for 14 days starting on either postoperative day 1 (POD-1) or POD-5 and were then monitored up to 84 days post-injury. Volumetric assessment of bone formation using μ CT demonstrated significant difference with respect to total new bone volume at the distal end plus ectopic bone outside of cortical margins (Fig. 2A) and soft-tissue ectopic bone volume (Fig. 2B) at 84 days (12-weeks) between the vehicle control group and the Palovarotene group. When treatment started at POD-1 in the absence of MRSA, Palovarotene significantly inhibited the formation of trauma-induced total new bone and soft-tissue ectopic bone formation at 84 days post injury from $16.2 \pm 4.9 \text{ mm}^3$ to $5.3 \pm 1.3 \text{ mm}^3$ ($p = 0.02$; 67% mitigation) and from $0.6 \pm 0.4 \text{ mm}^3$ to no detectable ectopic bone formation ($p = 0.04$; 100% inhibition) respectively, as revealed by μ CT imaging and quantification (Figs. 2A & 2B). When Palovarotene was administered from POD-5 in the absence of MRSA, it was still effective but less so, causing a decrease of total new bone and soft-tissue ectopic bone from $16.4 \pm 3.4 \text{ mm}^3$ to $8.9 \pm 2.5 \text{ mm}^3$ ($p = 0.004$; 46% inhibition) and from $0.7 \pm 0.6 \text{ mm}^3$ to no detectable ectopic bone formation after treatment (100% inhibition) (Figs. 2A & 2B). MRSA infection is a likely risk factor in combat settings and a known potentiator of trauma-induced HO [13]. In the presence of MRSA infection (Figs. 2B–F) and regardless of when treatment was started, Palovarotene was still able to decrease the volume of total new bone by 84 days post injury by 59–74%. When the Palovarotene treatment initiated at POD-1, the volume of total new bone and soft-tissue ectopic bone decreased from $41.9 \pm 5.6 \text{ mm}^3$ in controls to $16.4 \pm 3.9 \text{ mm}^3$ ($p = 0.003$; 61% attenuation) and from $1.68 \pm 0.6 \text{ mm}^3$ to no detectable ectopic bone formation after treatment ($p = 0.04$; 100% inhibition), respectively. For the POD-5 treatment, the volume of total new bone and soft-tissue ectopic bone decreased from $38.9 \pm 8.5 \text{ mm}^3$ to $16.0 \pm 6.6 \text{ mm}^3$ ($p = 0.004$; 61% attenuation) and from $0.52 \pm 0.19 \text{ mm}^3$ to no detectable ectopic bone formation after treatment ($p = 0.004$; 100% inhibition), respectively (Figs. 2A & 2B).

3.2. Palovarotene suppresses post-traumatic chondrogenesis and osteogenesis

Given that the rat blast model causes broader and more encompassing damage and complications compared to the more benign HO mouse models we used previously, it became important to determine the tissue level and phase of HO progression at which Palovarotene was able to inhibit HO in this model. Thus, we collected affected tissues around the amputated area of the limbs at day 15, 28 and 84 from the initial blast injury and processed them for histochemical analyses. In vehicle control samples, the amputated area at days 15 and 28 displayed obvious signs of an ongoing and active endochondral ossification process, with foci of immature and hypertrophying cartilage (Fig. 3A–C), numerous surrounding cells exhibiting progenitor characteristics, acidophilic osteoid matrix and immature woven bone (Fig. 3D–F). These ectopic tissues were all intimately embedded into surrounding tissues and most clearly, skeletal muscles. At 84 days post injury, masses of mature ectopic bone and marrow were present and often became surrounded by fibrous tissue to form a necrotizing pyogranuloma, a sign of ectopic bone resorption/remodeling (Fig. 3G–I). Areas of inflammation with foci of intense bacterial multiplication and necrosis (abscesses) were present in the soft tissue as well. In comparison, specimens obtained from Palovarotene-treated rats showed clear decrease in the amount of detectable immature cartilage and vascularized hypertrophying cartilage at each time point examined (Fig. 3J–L). In place of these skeletogenic tissues, we invariably observed the presence of extensive areas of fibrous connective tissues that were particularly obvious at day 28 post injury (Fig. 3M–O). At the end of the study at 84 days post injury, histological investigation showed that

the medullary cavity was largely filled with similar fibrous connective tissue (Fig. 3P–R).

3.3. Expression of chondrogenic and osteogenic gene markers is decreased in blast site-tissues from Palovarotene-treated rats

To assess the regulatory levels at which Palovarotene exerted its apparent anti-HO effects, we analyzed the expression of 83 genes associated with early chondrogenic, osteogenic and angiogenic processes related to bone development in blast site-samples collected from vehicle control and Palovarotene-treated rats at day 5, 7, 10, 14 and 28 from injury. As the local skeletal muscles were affected by the blast and were the major site of ectopic bone development; the harvested samples contained soft tissue immediately surrounding the residual femur but not set against the bone. Gene transcript values were normalized to expression levels found in uninjured skeletal muscle obtained from age-matched naïve rats. Samples collected at day 5–14 from injured limbs of vehicle-treated rats displayed significantly higher expression levels of key chondrogenic and osteogenic genes than samples from companion Palovarotene-treated rats (Fig. 4). The chondrogenic genes included SOX9 ($p = 0.01$ on POD-7 and $p = 0.02$ on POD-10) and collagen 2 (*COL2 α 1*, $p = 0.01$ on POD-10) (Fig. 4A–B), and the osteogenic genes included osteocalcin (*OCN*, $p = 0.02$ on POD7 and POD-10), *RUNX-2* ($p = 0.003$ on POD-5), osteogenic transcription factors *POU5F1* ($p = 0.01$ on POD-10), Osteopontin (*OPN*, $p = 0.049$ on POD-7), bone morphogenetic protein-2 (*BMP-2*, $p = 0.04$ on POD-7) and bone morphogenetic protein-4 (*BMP-4*, $p = 0.02$ on POD-7) (Fig. 4C–H). In contrast to the decreases in chondrogenic and osteogenic genes, the samples from Palovarotene-treated animals displayed significantly higher expression of matrix metalloproteinase-9 (*MMP9*; $p = 0.02$ on POD-14), an enzyme involved in the degradation of cartilage extracellular matrix (Fig. 4I) [30].

3.4. Palovarotene may have moderate inhibitory effects on wound healing

As indicated above, bacterial infections are common in combat casualties, but wounded service members also suffer from additional injuries including damaged soft tissues and skin. We did not observe overt differences in common macroscopic wound complications such as surgical site bleeding, skin rashes, erosions, necrosis, abscesses, purulent drainage, and wound infection. However, we also quantified delayed wound healing by determining the proportion of wounds that were not completely healed by 14 days post-injury due to either persistent superficial dehiscence or frank dehiscence requiring surgical debridement and secondary closure (Fig. 5). Overall, in response to any Palovarotene treatment, irrespective of MRSA contamination, 38% (12/32) of the wounds dehiscenced versus 23% (7/30) of the wounds in the vehicle control group ($p = 0.28$). However, amongst rats treated with Palovarotene and inoculated with MRSA, 63% (10/16) of rats experienced delayed healing or dehiscence irrespective of treatment timing, whereas 25% (4/16) of MRSA rats treated with vehicle control demonstrated delayed healing or dehiscence ($p = 0.07$).

4. Discussion

Herein, we report for the first time that Palovarotene is a strong inhibitor of HO in blast-associated rat model of combat-related extremity injury. This model is both severe and encompassing and includes not only the initial blast injury, but also compounding complications often occurring in combat situations, including bacterial infections and/or limb amputation. In each permutation, Palovarotene was able to counteract HO and did so in a significant manner, with an average of 50 to nearly 100% inhibition. This result is particularly impressive and promising given that Palovarotene was given every other day for 14 days starting on either POD-1 or POD-5 after blast injury, but HO was measured at later time points, which is critical in order to ensure that late

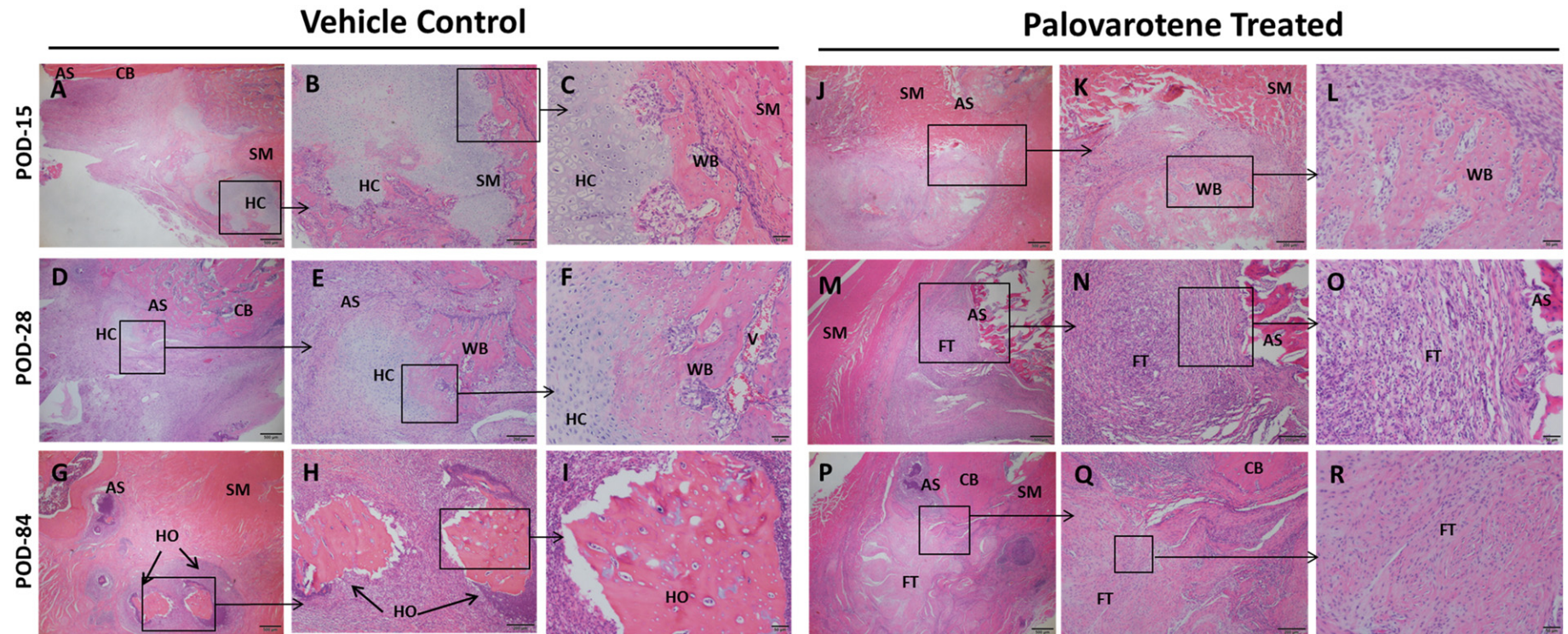


Fig. 3. Palovarotene treatment inhibits the initial phases of HO. Histologic and microscopic assessment of HO formation in vehicle- control rats at 15 days (A–C), 28 days (D–F) and 84 days (G–I), and in Palovarotene treated rats at 15 days (J–L), 28 days (M–O) and 84 days (P–R) post injury. CB = cortical bone, AS = amputation site; FT = fibroblastic tissue; HC = immature and hypertrophying cartilage; SM = skeletal muscle; WB = woven bone; V = vascularization and HO = heterotopic ossification. The scale bars in the images (A), (D), (G) (M) and (P) correspond to 500 μ m. Scale bars in images (B), (E), (H), (K), (N) and (Q) corresponds to 200 μ m. Scale bars in images (C), (F), (I), (L), (O) and (R) correspond to 50 μ m.

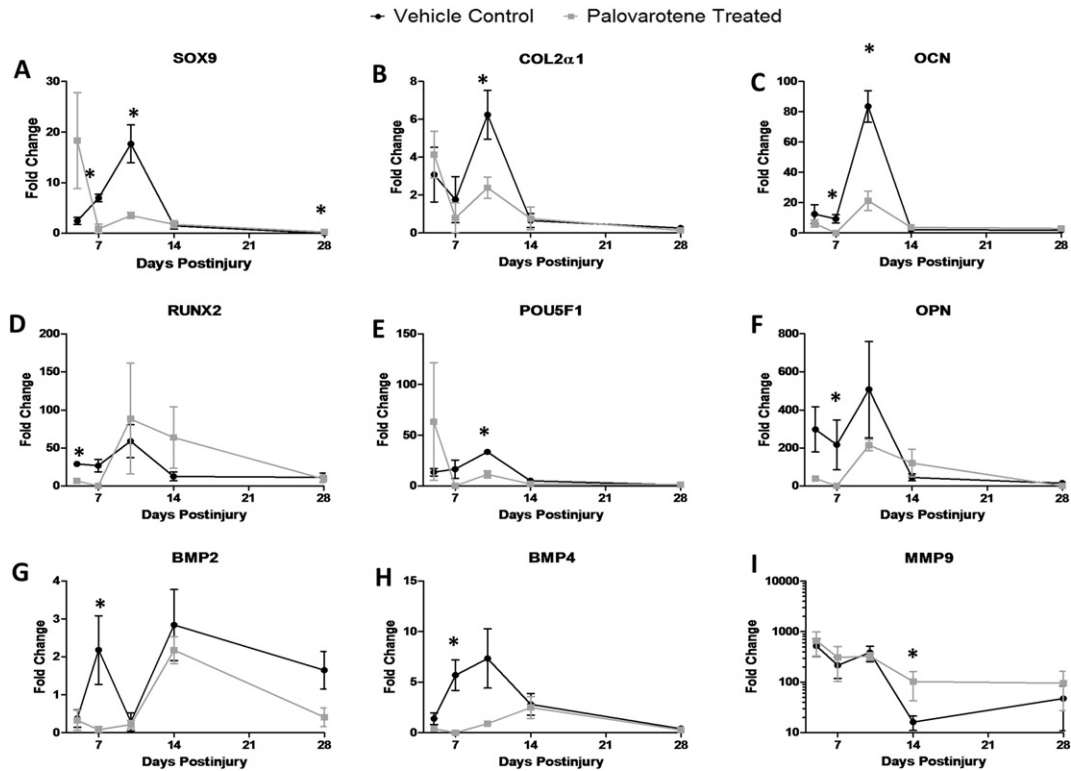


Fig. 4. Effects of Palovarotene treatment ($n = 4$) and vehicle control ($n = 4$) on chondrogenic (A–B) and osteogenic (C–H) related gene targets and matrix metalloproteinase-9 (I) gene expression. The fold change values were calculated by normalizing the values to the samples from non-injured muscle rats. Significantly different changes in gene expression are noted with an asterisk (*) ($p < 0.05$; Mann-Whitney U test).

recurrence or maturation of HO does not occur following cessation of treatment. Our data indicate that the developmental step of HO mostly affected by Palovarotene is the early chondrogenic phase. This is in line with the fact that retinoid agonists are particularly effective inhibitors of chondrogenesis [24,31]. Such effect on an early phase of HO can also explain why Palovarotene was so effective against HO; by inhibition chondrogenesis, the drug was able to inhibit the subsequent osteogenic phases of the process. Our data here are also in agreement with our previous analysis of drug-based HO therapy in mouse models [25,26]. It is

possible that Palovarotene may redirect the commitment and lineage assignment of stem and progenitor cells recruited to the injury site, leading them to enter a fibrogenic phenotype to promote and facilitate local tissue healing and regeneration and in turn scar formation. We do detect a robust production of fibrotic connective soft tissue surrounding the amputation site in Palovarotene-treated rats, but it remains unclear whether the drug is able to influence and direct the differentiation of locally-recruited progenitor cells by direct mechanisms or indirect processes and signals occurring within the injured area.

The etiology, pathophysiology and exact mechanism(s) orchestrating trauma-induced HO remain poorly understood, although dysregulated immunological-neuro inflammation, production of local soluble osteogenic mediators, hypoxia and various risk factors have been identified as possible culprits [16,19,32]. Induction of chronic bacterial-induced inflammation and ostensibly, indolent infection of the residual limb and surrounding soft tissue are known clinical risk factors and are reported to be potentiators of ectopic bone formation [13]. Non-steroidal anti-inflammatory agents (NSAIDs) are often used to decrease this inflammatory component - specifically inflammatory prostaglandin-E₂ - and the ensuing decrease in inflammation may reduce HO formation as well [33]. Our data indicate that the bioburden resulting from MRSA infection does not hamper appreciably the ability of Palovarotene to inhibit HO. This effect was obvious not only by histological inspection, but was also revealed by decreased expression of key chondrogenic (*SOX9* and *COL2 α 1*) and osteogenic (*OCN*, *OPN*, *BMP-2*, *BMP-4*, *POU5FL* and *RUNX2*) genes and by increased expression of an important cartilage matrix catabolism gene (*MMP9*) [30].

The safety and tolerability of a candidate HO therapeutic agent must be considered in balance with its clinical efficacy. The ideal agent would not only prevent HO in trauma patients, but would also need to limit its effects on other concomitant injury patterns, such as the early tissue reparative and regenerative processes involved in the healing of complex

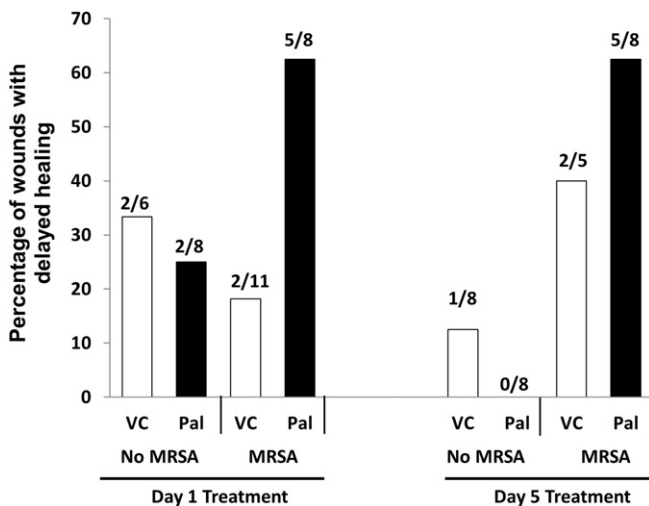


Fig. 5. Percentage of wounds that dehisced and were not completely healed by 14 days post-injury. The number of wounds with delayed healing in each treatment group is indicated.

wounds or fractures. Previous research demonstrates that one potential mode of action of Palovarotene is the dampening of neovascularization during early chondrogenesis [25,26]. Impaired angiogenesis during the early wound healing process places the healing wound bed at theoretical risk of delayed or incompetent healing, prompting dehiscence. In our study, we observed a trend toward wound complication in the Palovarotene-treated groups, but the difference was not statistically significant. Defining the overall risk-benefit profile for Palovarotene with an in-depth and properly powered study is critical. Wounds that fail to heal often do so in the setting of persistent chronic infection (angiogenesis-dependent processes) [34,35], which was the case in a large proportion of the MRSA-infected animals in our study. Future work will be directed toward studies assessing whether the therapeutic application of Palovarotene to prevent HO formation might potentially be associated with impaired wound vascularization and tissue repair if given for longer periods of time and/or different doses and frequencies.

There are several questions that the present study did not address. First, we did not test the effects of Palovarotene on the muscle injury or normal healing of long bone fractures, which occurs via endochondral ossification, the known mechanistic target of the drug. The feasibility of using this drug in a model containing concomitant long bone fractures is a focus of an ongoing study. While clarifying the effect on long bone fracture healing is important, we know that there is no ectopic bone attenuation efficacy rebound effect with the use of Palovarotene [25], and therefore a clinically acceptable treatment plan might include initiation of treatment in the early post-injury period to disrupt HO development, and then to stop treatment prior to definitive fracture fixation to permit unimpeded fracture healing. Temporizing fracture fixation could be initiated to maintain length and stability in the interim and portend a clinically acceptable outcome provided the fractures eventually go on to heal within an acceptable timeframe. Nevertheless, patients with bilateral lower extremity amputations, particularly those without upper extremity or spine fractures, could represent a specific cohort that would most markedly benefit from early Palovarotene administration. Second, we have not yet identified the mechanism responsible for the alteration of endochondral ossification caused by Palovarotene administration leading to a fibroblastic rather than osteoblastic endstate. Lastly, we need to further refine the dosing regimen of Palovarotene and determine whether the observed efficacy effects were either due to initiating the treatment earlier at POD-1 or selecting a narrow treatment window (14 days post injury) to specifically target endochondral ossification in the development of ectopic bone. With this knowledge, we can refine our treatment window for desired effect for the attenuation of ectopic bone formation in traumatized tissue without prolonging delays in endochondral ossification elsewhere in the body.

Supplementary data to this article can be found online at <http://dx.doi.org/10.1016/j.bone.2016.06.014>.

Conflict of interest

M.P., M.I., and J.F. are consultants for Clementia Pharmaceuticals. The other authors have no financial or personal conflicts of interest to disclose.

Acknowledgments

We like to thank Dr. Matthew Wagner, Dr. John Tra and Mr. Ying Cao for their assistance with statistical analysis. This work was supported by CDMRP grant W81XWH-13-2-0077 (to JAF) and grant H81XWH-13-2-0076 (to MP). B.L. received funding from NIH/NIGMS - K08GM109105-0, Plastic Surgery Foundation National Endowment Award, the Association for Academic Surgery Roslyn Award American Association for the Surgery of Trauma Research & Education Foundation Scholarship, and American Association of Plastic Surgery Research Fellowship. SJL funded by a Howard Hughes

Medical Institute research fellowship. SA funded by the NIH LRP, Colter Society, and Plastic Surgery Foundation.

References

- [1] C.A. Cipriano, S.G. Pill, M.A. Keenan, Heterotopic ossification following traumatic brain injury and spinal cord injury, *J. Am. Acad. Orthop. Surg.* 17 (11) (2009) 689–697.
- [2] D.E. Garland, Clinical observations on fractures and heterotopic ossification in the spinal cord and traumatic brain injured populations, *Clin. Orthop. Relat. Res.* 233 (1988) 86–101.
- [3] B.K. Potter, et al., Heterotopic ossification following traumatic and combat-related amputations. Prevalence, risk factors, and preliminary results of excision, *J. Bone Joint Surg. Am.* 89 (3) (2007) 476–486.
- [4] F.S. Kaplan, et al., Heterotopic ossification, *J. Am. Acad. Orthop. Surg.* 12 (2) (2004) 116–125.
- [5] T.F. Lanchoney, et al., Characterization of bone morphogenetic protein 4 receptor in fibrodysplasia ossificans progressiva, *Clin. Orthop. Relat. Res.* 346 (1998) 38–45.
- [6] A. Medina, et al., Characterization of heterotopic ossification in burn patients, *J. Burn Care Res.* 35 (3) (2014) 251–256.
- [7] B. Levi, et al., Risk factors for the development of heterotopic ossification in seriously burned adults: A national institute on disability, independent living and rehabilitation research burn model system database analysis, *J. Trauma Acute Care Surg.* 79 (5) (2015) 870–876.
- [8] D.E. Garland, R.M. O'Hollaren, Fractures and dislocations about the elbow in the head-injured adult, *Clin. Orthop. Relat. Res.* 168 (1982) 38–41.
- [9] D.E. Garland, C.E. Blum, R. Waters, Periarticular heterotopic ossification in head-injured adults. Incidence and location, *J. Bone Joint Surg.* 62 (7) (1980) 1143–1146.
- [10] S.M. Tintle, et al., Reoperation after combat-related major lower extremity amputations, *J. Orthop. Trauma* 28 (4) (2014) 232–237.
- [11] J.A. Forsberg, et al., Heterotopic ossification in high-energy wartime extremity injuries: prevalence and risk factors, *J. Bone Joint Surg.* 91 (5) (2009) 1084–1091.
- [12] K.V. Brown, et al., Comparison of development of heterotopic ossification in injured US and UK Armed Services personnel with combat-related amputations: preliminary findings and hypotheses regarding causality, *Journal of Trauma-Injury, Infection, and Critical Care* 69 (1) (2010) S116–S122.
- [13] G.J. Pavey, et al., Effect of bioburden on heterotopic ossification formation in an established rat model, *Clin. Orthop. Relat. Res.* 473 (9) (2015) 2840–2847.
- [14] G.J. Pavey, P.E. K. Nappo, S.M. Tintle, J.A. Forsberg, B.K. Potter, What risk factors predict recurrence of heterotopic ossification after excision in combat-related amputations? *Clin. Orthop. Relat. Res.* 473 (9) (2015) 2814–2824.
- [15] J.A. Forsberg, B.K. Potter, Heterotopic ossification in wartime wounds, *J. Surg. Orthop. Adv.* 19 (1) (2010) 54–61.
- [16] A.T. Qureshi, et al., Early Characterization of Blast-related Heterotopic Ossification in a Rat Model, *Clin. Orthop. Relat. Res.* 479 (9) (2015) 2831–2839.
- [17] J.R. Peterson, et al., Early detection of burn induced heterotopic ossification using transcutaneous Raman spectroscopy, *Bone* 54 (1) (2013) 28–34.
- [18] T.A. Davis, et al., Ectopic bone formation in severely combat-injured orthopedic patients—A hematopoietic niche, *Bone* 56 (1) (2013) 119–126.
- [19] T.A. Davis, et al., Heterotopic ossification in complex orthopaedic combat wounds: quantification and characterization of osteogenic precursor cell activity in traumatized muscle, *J. Bone Joint Surg. Am.* 93 (12) (2011) 1122–1131.
- [20] A.H. Mohedas, et al., Development of an ALK2-biased BMP type I receptor kinase inhibitor, *ACS Chem. Biol.* 8 (6) (2013) 1291–1302.
- [21] J.R. Peterson, et al., Treatment of heterotopic ossification through remote ATP hydrolysis, *Sci. Transl. Med.* 6 (255) (2014) 255ra132.
- [22] J.A. Williams, et al., Retinoic acid receptors are required for skeletal growth, matrix homeostasis and growth plate function in postnatal mouse, *Dev. Biol.* 328 (2) (2009) 315–327.
- [23] L.M. Hoffman, et al., BMP action in skeletogenesis involves attenuation of retinoid signaling, *J. Cell Biol.* 174 (1) (2006) 101–113.
- [24] M. Pacifici, et al., Vitamin A inhibits chondrogenesis but not myogenesis, *Exp. Cell Res.* 129 (2) (1980) 469–474.
- [25] K. Shimono, et al., Potent inhibition of heterotopic ossification by nuclear retinoic acid receptor-gamma agonists, *Nat. Med.* 17 (4) (2011) 454–460.
- [26] K. Shimono, et al., Inhibition of ectopic bone formation by a selective retinoic acid receptor α -agonist: A new therapy for heterotopic ossification? *J. Orthop. Res.* 28 (2) (2010) 271–277.
- [27] E. Koyama, et al., Retinoid signaling is required for chondrocyte maturation and endochondral bone formation during limb skeletogenesis, *Dev. Biol.* 208 (2) (1999) 375–391.
- [28] A.D. Weston, et al., Requirement for RAR-mediated gene repression in skeletal progenitor differentiation, *J. Cell Biol.* 158 (1) (2002) 39–51.
- [29] E.M. Polfer, et al., The development of a rat model to investigate the formation of blast-related post-traumatic heterotopic ossification, *The Bone and Joint Journal* 97 (4) (2015).
- [30] P. Lu, et al., Extracellular matrix degradation and remodeling in development and disease, *Cold Spring Harb. Perspect. Biol.* 3 (12) (2011) a005058.
- [31] J.R. Hassell, J.P. Pennypacker, C.A. Lewis, Chondrogenesis and cell proliferation in limb bud cell cultures treated with cytosine arabinoside and vitamin A, *Exp. Cell Res.* 112 (2) (1978) 409–417.
- [32] J.A. Forsberg, et al., Do inflammatory markers portend heterotopic ossification and wound failure in combat wounds? *Clin. Orthop. Relat. Res.* (2014) 1–10.
- [33] A. Nauth, et al., Heterotopic ossification in orthopaedic trauma, *J. Orthop. Trauma* 26 (12) (2012) 684.

- [34] T.N. Demidova-Rice, M.R. Hamblin, I.M. Herman, Acute and impaired wound healing: pathophysiology and current methods for drug delivery, part 1: normal and chronic wounds: biology, causes, and approaches to care, *Adv. Skin Wound Care* 25 (7) (2012) 304.
- [35] T.N. Demidova-Rice, M.R. Hamblin, I.M. Herman, Acute and impaired wound healing: pathophysiology and current methods for drug delivery, part 2: role of growth factors in normal and pathological wound healing: therapeutic potential and methods of delivery, *Adv. Skin Wound Care* 25 (8) (2012) 349.