

14. ABSTRACT

With current combat operations there is high incidence of infection and a continuing need for innovative approaches to wound healing and tissue regeneration. The early and aggressive administration of antimicrobial treatment starting with intervention on the battlefield has resulted in improved patient outcomes and is considered standard of care. Unfortunately, while previous research in the development of effective antimicrobial agents, none has the ideal formulation for the treatment of battlefield wounds. Therefore, effective agents that are more appropriate for use on combat wounds must be developed. In order to address this problem, we will develop new treatment protocols, drug delivery systems and tissue engineered biologics to reduce wound-related infections and accelerate wound healing using a military relevant infected burn/debridement model. This will be accomplished by developing a novel biodegradable gel based antimicrobial dressing for battlefield administration to minimize post injury complications and infection. This gel will provide local delivery of antibacterial to the site of injury, prevent colonization of bacteria and reduce dependence on high doses of systemic antibiotics. The result will be a sterilized prepackaged biodegradable gel that will allow optimal handling and placement that inhibits infection and promotes tissue revascularization. Second, for those soldiers who have been evacuated from the battlefield, we will use the gel in combination with autologous stem cells. This tissue engineering based strategy will provide the surgically debrided wound a matrix for neovascularization and tissue regeneration to limit the loss of life and limb.

Table of Contents

	Page
Introduction.....	3
Body.....	5
Key Research Accomplishments.....	6
Reportable Outcomes.....	22
Conclusion.....	24
References.....	25
Appendices.....	26

Introduction

One of the most frequent complications in combat burn victims is infection, which requires immediate treatment to reduce the possibility of further complications, yet it remains one of the leading causes of mortality among burn patients [1-3]. The most prevalent infections of military burn patients are caused by the pathogenic microbes *Pseudomonas aeruginosa* and *Staphylococcus aureus*. Infections caused by these bacteria cause exudation at the wound site [4], which affects the healing process by reducing the oxygen tension, degrading extracellular matrix proteins and various growth factors, delaying re-epithelialization and preventing wound closure [5]. Addressing control of infection is the primary problem to improve wound healing. The best-identified topical antibacterial agent to control infections experimentally and clinically is silver sulphadiazine (SSD) [6-7]. SSD possesses a broad spectrum of activity against gram-positive and gram-negative bacteria as well as fungi [8-10]. The ability of silver sulfadiazine to be effective even at low concentration in reducing invasive early burn wound sepsis has made it a drug of choice for burn wound injuries [11]. After initial antimicrobial treatment it will be desirable to use active polymers that can act as a platform to induce functional recruitment of host cells for wound healing. A major cause of concern during usage of SSD cream is absorption of silver ions, which remain at a certain level in the body for some time after dissociation [12]. Moreover, optimal dose and mode of deployment of currently available SSD cream in burn wound therapy have not been fully defined. Alternative systems have been developed to overcome the aforementioned problems [13-14]. But these systems lack the ability to control the release of SSD in such a way that drug concentration in serum does not exceed toxic levels when used for *in vivo* application. A possible method of controlling the delivery of SSD is by entrapping it in a polymer matrix. In our first phase of the project we developed a controlled release formulation for delivering SSD from chitosan microspheres (SSD-CSM). The SSD-CSM microspheres were successfully evaluated for their *in vitro* release and antibacterial efficiency [15].

Most wound dressings are primarily designed to address infection, with less focus on the quality of healing [16]. To develop more than a simple antimicrobial wound cover, it is desirable for a wound dressing to provide a viable environment for the host cells to granulate and to provide a scaffold for better wound regeneration. Studies have shown that hydrogel-based polymers can improve healing by initiating early cellular and molecular events during wound healing [17]. More importantly, infiltration of mesenchymal stem cells to the wound site is currently thought to be a crucial early event in the tissue regeneration process [18]. Mesenchymal stem cells residing in the tissue may also be recruited to the wound site to initiate the reparative process. Few reports show that exogenously delivered mesenchymal stem cells from adipose tissue can hasten wound healing with the aid of a provisional matrix [19]. We have recently shown that a polyethylene glycol-based fibrin gel (PEGylated fibrin gel) induces vasculogenesis both *in vitro* and *in vivo* [20]. To exploit the inherent ability of fibrin as a substitute for a three-dimensional provisional matrix and as a carrier to control the release of SSD we designed a fibrin-based wound dressing. This dressing primarily controls infection and further aid in neovascularization when applied to an infected wound. Adipose derived stem cells (ASC), when embedded within PEGylated fibrin gels form vascular-like structures *in vitro* and exhibit enhanced vasculogenesis *in vivo* [21]. In phase 2 of our study we have shown that the PEGylated fibrin impregnated SSD-CSM at a concentration of 50 $\mu\text{g/ml}$ allows active tube formation by ASCs *in vitro* and at the same time were capable of eliciting antimicrobial activity *in vitro*. The morphology of the tube-like structures formed *in vitro* is comparable with the gels without SSD-CSM. Moreover, the tube-like structures exhibited phenotypic characteristics of

pericytes (NG2⁺ and PDGFRβ⁺), which are considered to be vital for further endothelial cell infiltration during neo-vascularization [22]. Therefore, it is anticipated that when applied in vivo SSD–CSM–PEGylated fibrin gels may act as an active platform inducing vasculogenesis in an infected wound environment.

In phase 3 of our study we evaluated the effect of SSD loaded microspheres within the PEGylated fibrin gel in infected rat burn wound. A third degree burn was created in rat's dorsum and infected with a challenging inoculum of 10⁷ cfu *Pseudomonas aeruginosa*. The efficiency of SSD-CSM–PEGylated fibrin against microbial challenge was assessed by observing the wound healing pattern in treated rats, in comparison with their respective controls. Within four days, rats treated with SSD hydrogel showed control of infections (≤ initial inoculum count) and a significant decrease in cfu (from 2- 3×10⁷ cfu to < 1000 cfu). Following the observations in the rat burn wounds we assessed the efficiency of SSD-CSM–PEGylated fibrin in a full thickness infected excision wounds in a porcine model. Wounds treated with the SSD-CSM–PEGylated fibrin gels, 24 hours after inoculation had the least amount of *Pseudomonas aeruginosa* PA 09-010 when recovered on days 5, 7 and 11 (6.79±0.35, 5.46±0.45 and 1.77±0.88 Log cfu/g, respectively). After 11 days wounds treated with SSD-CSM–PEGylated fibrin gels showed the largest reduction (5.29±0.80 Log cfu/g) of *P. aeruginosa*. This value corresponds with the largest percentage of reduction 99.99% of *P. aeruginosa* as compared to untreated wounds.

The aim of our final phase (current report) of the project was to evaluate a combination treatment of SSD-CSM–PEGylated fibrin gels and ASCs-PEGylated fibrin gels in an infected burn wounds. The objective of this phase is to develop wound injury treatments for military personnel using combination products containing hydrogel biomaterials, tunable topical release of antimicrobial/antibiotics and autologous stem cells for inducing active tissue regeneration. As a part of our first specific aim of this project we used an infected rat burn wound model and treated them with SSD-CSM–PEGylated fibrin gels for seven days. After the subsidence of infection, day 9, the wounds were treated with ASCs-PEGylated fibrin gels. The infected rat injury is intended to provide a simple model for optimization of material and delivery formulation. The wound healing was assessed for 28 days using morphometric measures like reduction in bacterial counts in wounds, wound closure and using histological techniques on wound biopsies taken at different days of treatment. To further support initial results obtained from infected full thick excision model in pig we repeated this to obtain statistically reportable results on the effectiveness of SSD-CSM–PEGylated fibrin gels based dressing. In our final aim the efficiency of ASCs–PEGylated fibrin gels was evaluated in a porcine deep partial thickness burn wound model. The porcine burn wound establishes an experimental host that mimics the altered physiological and immunological conditions in severely injured human.

Within the context of this investigation in this report period, and within the overall objective, we carried our experiments pertinent to following specific aims,

- a. Evaluate the synergistic effects of SSD-CSM–PEGylated fibrin gels followed by ASCs–PEGylated fibrin gels in an infected rat burn wound model.
- b. Evaluate the effectiveness of SSD-CSM–PEGylated fibrin gels based dressing in a full thickness porcine excision wound model to obtain statistically reportable results.
- c. Develop a deep partial thickness porcine burn injury model
- d. Determine the effect of ASCs–PEGylated fibrin gels in a porcine deep partial thickness burn wound model.

Body

- **Specific Aim #1:** Design and develop a fibrin based wound dressing (SCD-1) for initial chemoprophylaxis in burn wound.
 - A. Preparation of antibacterial drug (silver sulfadiazine) loaded microspheres.
 - B. Evaluation of efficiency of drug loaded microspheres – release kinetics, efficiency of drug, optimization of dosage, morphological analysis.
 - C. Development and analysis of drug loaded microspheres embedded PEGylated fibrin gel
- **Specific Aim #2:** Development of fibrin based composite tissue engineered scaffold (SCD-2) for accelerated healing.
 - A. Isolation and characterization of adipose derived stem cells (ASC) from rat.
 - B. Preparation of tissue engineered fibrin-ASC scaffold.
 - C. Preparation of microsphere impregnated wound cover (using collagen).
 - D. Preparation of a composite tissue engineered scaffold: Fibrin-ASC sandwiched with microsphere impregnated wound cover.
- **Specific Aim #3:** Develop a full thickness infected burn wound model in Lewis rats and optimize the fibrin based wound dressing (SCD-1) to induce wound healing by limiting infection. Following optimization in rats, a pig full thickness infected burn wound model will be used to determine the efficiency of SCD-1.
- **Specific Aim #4:** Evaluate the efficiency of the dressing regime, SCD-1 followed by SCD-2 in infected rat and pig full thickness burn wound models. The dressing change will be carried out considering the fact that severe burn injuries requires a biomaterial capable of replacing tissue loss as well as to limit infection. Infection will also be considered as a predisposing factor to impair the healing process by shifting the normal phase of healing. The synergistic effects of SCD-1 and SCD-2 on healing is envisioned to limit infection, modulate the balance of the inflammatory and remodeling phases and assist accelerated healing by inducing angiogenesis through a guided tissue regeneration process facilitated by adipose-derived, autologous stem cells.

Specific Aim # 1: Effectiveness of Silver Sulfadiazine Loaded Chitosan Microspheres Impregnated in Polyethylene Glycol Fibrin Gels (SSD-CSM-PEGylated fibrin gels) and Adipose Derived Stem Cells embedded (ASC-PEGylated fibrin gels) in Rat (*Rattus norvegicus*) Infected Contact Burn Wounds

Rationale: A combination treatment with silver sulfadiazine (SSD) and adipose derived stem cells (ASC) using a PEGylated fibrin based scaffold will help to mitigate infection and promote angiogenesis during the burn wound healing.

Experimental Method: Preceding any *in vivo* experiments, evaluation of treatments; SSD-CSM-PEGylated fibrin gels and ASC-PEGylated fibrin gels was done *in vitro*. The *in vitro* experimental antibacterial values of SSD were used as a reference to calculate the effective treatment dose for the *in vivo* studies. The biocompatibility of PEGylated fibrin gels, as well as ASCs adhesion and viability within the PEGylated fibrin gel was also evaluated. From these *in vitro* experiments, the most relevant treatment regime, PEGylated fibrin gel or combination will be chosen and evaluated for its performance *in vivo*. In this experiment the optimal treatment was evaluated over time to determine how they are effecting the different phases of wound healing. This was determined by assessing the morphometric, microbiological and histological properties at each respective time point.

A. Infected burn wound and Treatment: We used our previously developed and tested deep-partial thickness thermal injury wound model. Briefly, the animals were anesthetized and the dorsal skin was shaved and disinfected. The circular disc was heated to 85 °C and allowed to stabilize for 20 minutes. The external contacting surface of the circular iron/brass disc (17mm diameter) was then placed on the shaved dorsal side of the rat for 10 seconds without exerting any external pressure. The resulting burn wound was approximately 226.8 mm². Twelve hours after injury the wounds were infected with *Pseudomonas aeruginosa* (10⁷cfu/100μL of saline, Day -1). The bacterial suspension was injected underneath the eschar between the subcutaneous skin and paraspinus muscular layer and left overnight (12 - 14 hours) to establish the infection [23-24]. Positive bacterial colonization was established with our previous model development studies, which showed that wound biopsies (0.25-1cm²) of depth up to the panniculus adiposus (a layer of fat underlying dermis) contained a positive challenging concentration of *Pseudomonas aeruginosa* ($\geq 10^6$ cfu, assessed quantitatively by spread plate method). Twelve hours after bacterial infection the eschar was removed and treated with SSD-CSM-PEGylated fibrin gel (Day 0; figure 1). On day 9 wound were treated with ASC-PEGylated fibrin gel. Animals were euthanized on Days 1, 4, 7, 14 and 28 and wound biopsies were taken and assessed for the healing outcomes.

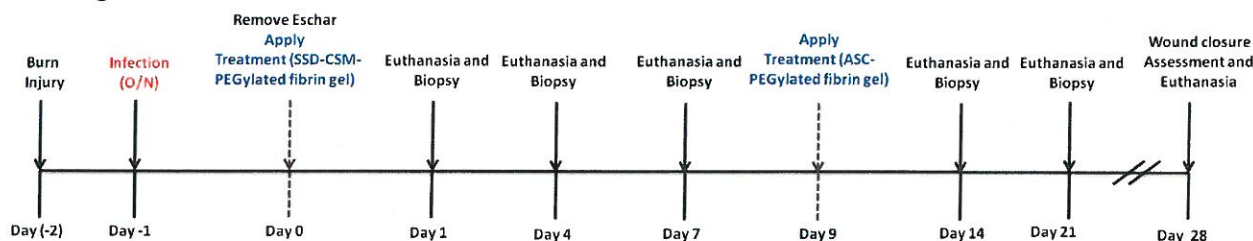


Figure 1: Experimental Time Course

B. Treatments:

SSD-CSM-PEGylated fibrin gels: PEGylated fibrinogen was prepared as previously described [20-21]. Briefly, succinimidylglutarate polyethylene glycol (SG-PEGSG, 3400 Da) was added to fibrinogen in a 6-well plate at molar ratio of 10:1 (SG-PEG-SG:fibrinogen) in Tris-buffered saline, pH 7.8, and incubated for 20 min at 37 °C. An equal volume of thrombin in 40 mM calcium chloride (final concentration 12.5 U/ ml) was then added and incubated for 10 min at room temperature. The resulting gels were then rinsed twice with Hank's balanced salt solution (HBSS), pH 7.8, to remove unbound SG-PEG-SG. To prepare SSD–CSM–PEGylated fibrin, SSD–CSM particles (25 mg) were added to the SG-PEG-SG:fibrinogen mixture followed by gelation with thrombin. A 2ml gel was used for treatment and consisted of 50mg of SSD loaded microspheres.

ASC-PEGylated fibrin gels: Rat ASCs were isolated from perirenal and epididymal adipose tissue as previously described [25-26]. Briefly, Perirenal and epididymal adipose tissue was collected and washed with sterile Hanks buffered balance solution (HBBS), minced, and centrifuged (500×g at room temperature for 10 min). The free floating adipose tissue layer was collected, collagenase digested (200U/mL) for 45 min at 37°C in an orbital shaker. The digested tissue was then filtered through 100 and 70 mm nylon mesh filter, centrifuged for 10 min at 500×g at room temperature, and washed twice with sterile HBBS. The cell pellet was re-suspended in MesenPRO RS. Cells were cultured on T75 flasks and maintained in a 5% CO₂ humidified incubator at 37°C. Passage 2–4 ASC were used for all experiments.

To prepare ASC-PEGylated fibrin gels, 5×10⁴ cells/ml were mixed to the fibrinogen-PEG solution mixture before initiating the gelation process using thrombin. ASC-PEGylated firbin gels were incubated in a 5% CO₂ humidified incubator at 37°C until used for the treatment.

Results:

1. Influence of SSD-CSM-PEGylated fibrin gel treatment on infection:

Untreated control On day 1, showed a significant increase in cfu (from 2 -3 ×10⁷ cfu to 10⁹ cfu/g), whereas SSD-CSM-PEGylated fibrin gel treated treated rats started to show a slight decrease in microbial count from initial inoculums (from 2 -3 ×10⁷ cfu to ~5 ×10⁵ cfu /g) (Figure 2), which constantly reduced on post-burn days. On day 7 there was a significant decrease in microbial load from initial inoculums (< 1000cfu/g, 99.9% decrease by day 7, but untreated showed a saturated infected in wound biopsies (>10⁹ cfu/g).

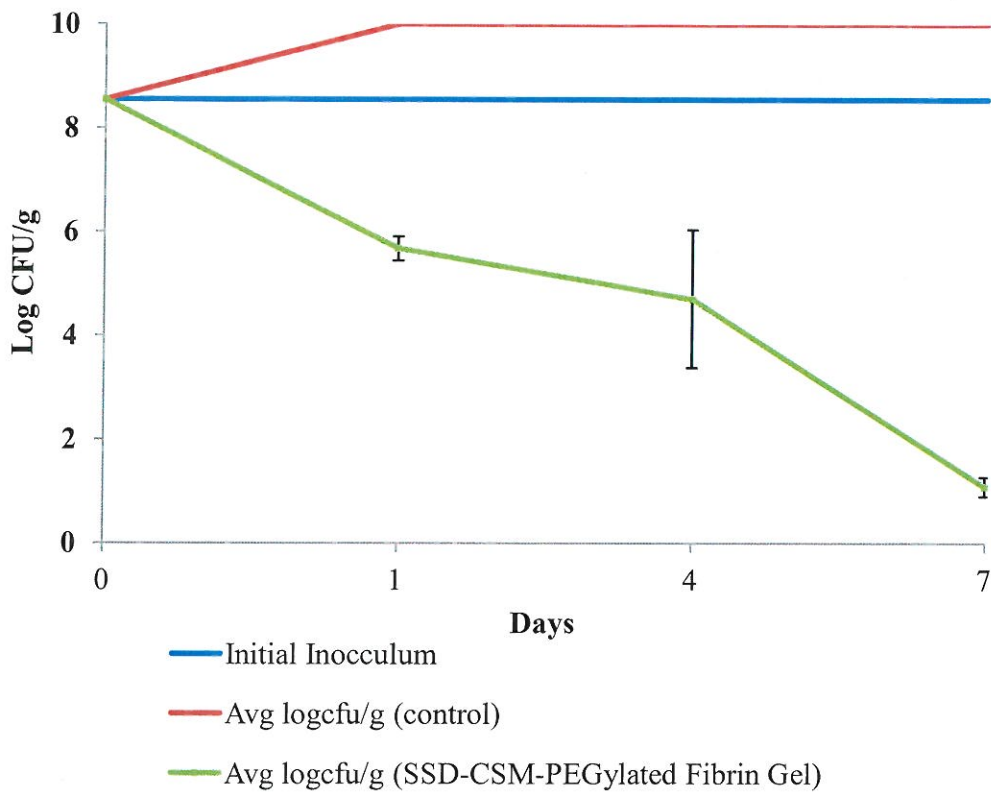


Figure 2: Reduction of *P. aeruginosa* cfu observed in SSD-CSM-PEGylated Fibrin gel treated rats in comparison with infected controls

- Wound closure:** The wound closure pattern of SSD–CSM–PEGylated fibrin gels and the combination treatment of SSD–CSM and ASC-PEGylated fibrin gels against microbial challenge were assessed in comparison to untreated infected control controls. All the treatment and no treatment burn wound showed an increase in wound surface area, after eschar removal, during early assessment time (24 hours post burn and infection). The infected group and the non-infected treatment control still exhibited a larger area from their initial burn size four days post injury. Whereas, non-infected rats treated with either PEGylated fibrin gel or SSD-CSM-PEGylated fibrin gels showed a 10-20% reduction in their wound size. Infected wounds in rats treated with SSD-CSM-PEGylated gel had reduced to their initial day burn size during this time (day 4). After 7 days a positive healing was noted in all the groups. Though significant differences in percentage closures was not observed between the groups, it is at the same time the SSD treatment cleared the bacterial load on the infected wounds. By day 14 all the groups started to heal with significant increase in wound closure. The non-infected groups (control and PEGylated fibrin gel +/- SSD-CSM) showed 80% reduction in their wound size in comparison to 60-65% observed in infected control and treated groups. After 21 days post burn wound in all the groups approached 90% closure

irrespective of infection status and by 28 days all the groups showed complete closure of the wounds (Figure 3).

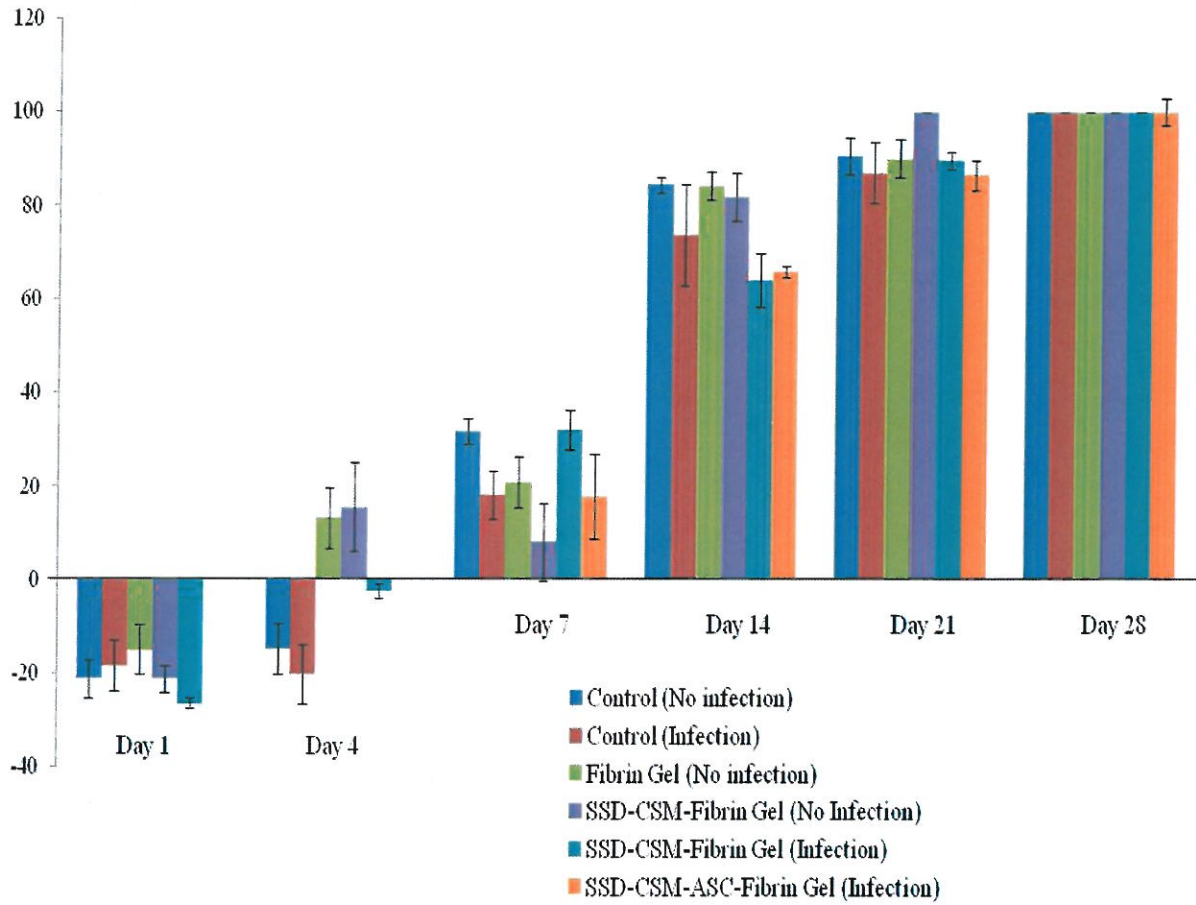


Figure 3: Percentage wound closure observed over 28 days in both infected and non-infected groups treated with SSDM-CSM PEGylated fibrin gel with or without ASCs.

3. Histological Analysis:

Histological analysis was performed on ~7- μ m sections of formalin-fixed paraffin embedded granulation tissue and normal skin tissue surrounding the wound collected from the wound bed of the rats at different days (day 7, 14, 21 and 28). The sections were stained with either Masson's trichrome or Movatt's pentachrome stain and examined under light microscopy to assess the overall wound healing pattern in the rat tissue. Masson's trichrome stained sections of SSD-CSM-PEGylated fibrin gels against microbial challenge were assessed in comparison to untreated controls.

Masson's trichrome stain was helpful to evaluate the collagen deposition and organization during healing (Figure 4). In both the groups treated with SSD-CSM PEGylated fibrin gel with and without ASCs show no bacterial infiltration after day 7. The chitosan microspheres were clearly seen embedded with the wound bed found wide spread on scab region found on top of the granulating wound bed. This was evident from the pentachrome staining with bright red stained microspheres (Figure 5). The microspheres were still found within the re-organizing dermal wound bed on day 14 in both the groups. In both the groups the surround tissue were minimally infiltrated with macrophages or with less inflammatory cells (Figure 6 A and B) which indicates the controlled release of SSD treatment to be compatible in treating these wounds. The PEGylated fibrin matrix in both treatment groups were indistinguishable after day 14 and mostly replaced by host granulation tissue component. In comparison rats treated with SSD-CSM PEGylated firbin gel and ASCs showed increased amount of dermal collagen matrix deposition in comparison to the SSD-CSM PEGylated fibrin gel treatment without ASCs (Figure 6C and D). Further, the wound bed of rats treated with ASCs started to show more defined dermal-epithelial boundary with remnant of sloughing scab on top of the wound bed (Figure 6 E). The rats treated with SSD-CSM PEGylated firbin gel alone showed a less organized dermal layer with associated bed of unorganized granulation tissue and an absence of any re-epithelialization (Figure 6 F). The neo-synthesized collagen could be clearly visualized (stained blue) in wound treated with SSD-CSM PEGylated firbin gel and ASCs. Also, our initial analysis exhibited a better vascularization than the untreated control and deserves an in-depth analysis comparing the groups treated with PEGylated firbrin gel groups with and with ASCs.

After 21 days ASCs treatment groups showed a defined epithelial layer advancing towards the center underneath the adnexial scab layer progressing towards complete closure (Figure 7A). Whereas the SSD-CSM PEGylated firbin gel alone treatment group still showed remodeling dermis associated with unorganized granulation tissue with significant amount of scab tissue (Figure 7B). Though the leading epidermal edge could be seen, still the distinct epithelial-dermal demarcation was not evident. By day 28 wounds of both the treatment groups showed complete re-epithelialization and prominent remodeling of the dermal layer. Although both the hydrogel-treated groups showed comparably similar re-epithelialization, the groups treated with ASCs showed well organized dermal and epithelial layers with a significantly better re-epithelializing wound margin and minimal scab adhering to the wound bed. In addition the dermal layer of rats treated with SSD-CSM PEGylated fibrin gel were still undergoing evident remodeling along with associated epithelial layer.

Conclusions

Overall this study showed the treatment of infected wounds with SSD-CSM-PEGylated gels were effective in controlling the infection and also improved wound healing. Adding ASCs to

the treatment regiment would significantly improve the quality of healing. Especially this may have direct implications on infected large surface area burn wound regeneration.

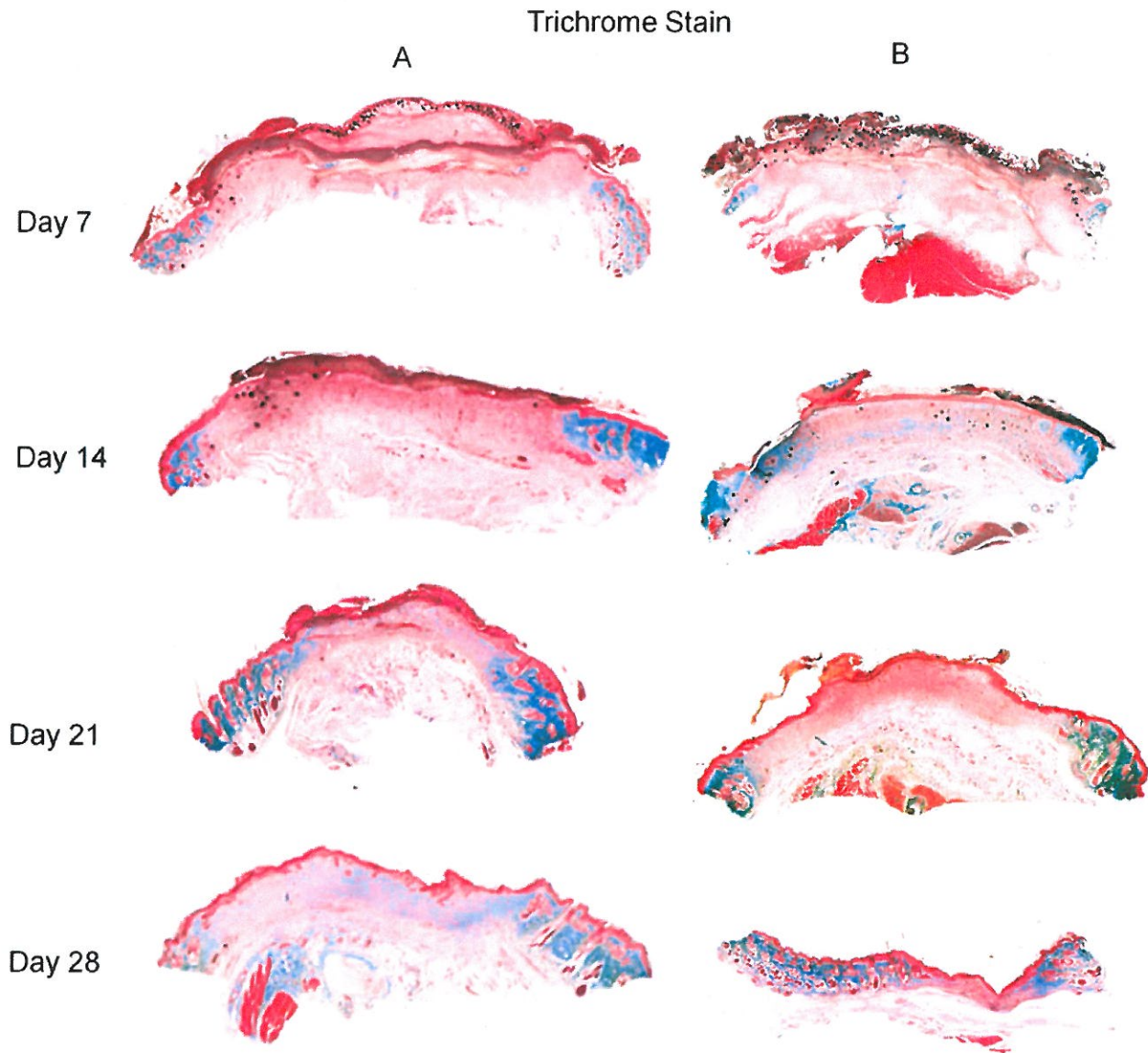


Figure 4: Masson's trichrome stained tissue sections of wounds treated with SSDM-CSM PEGylated fibrin gel with or without ASCs.

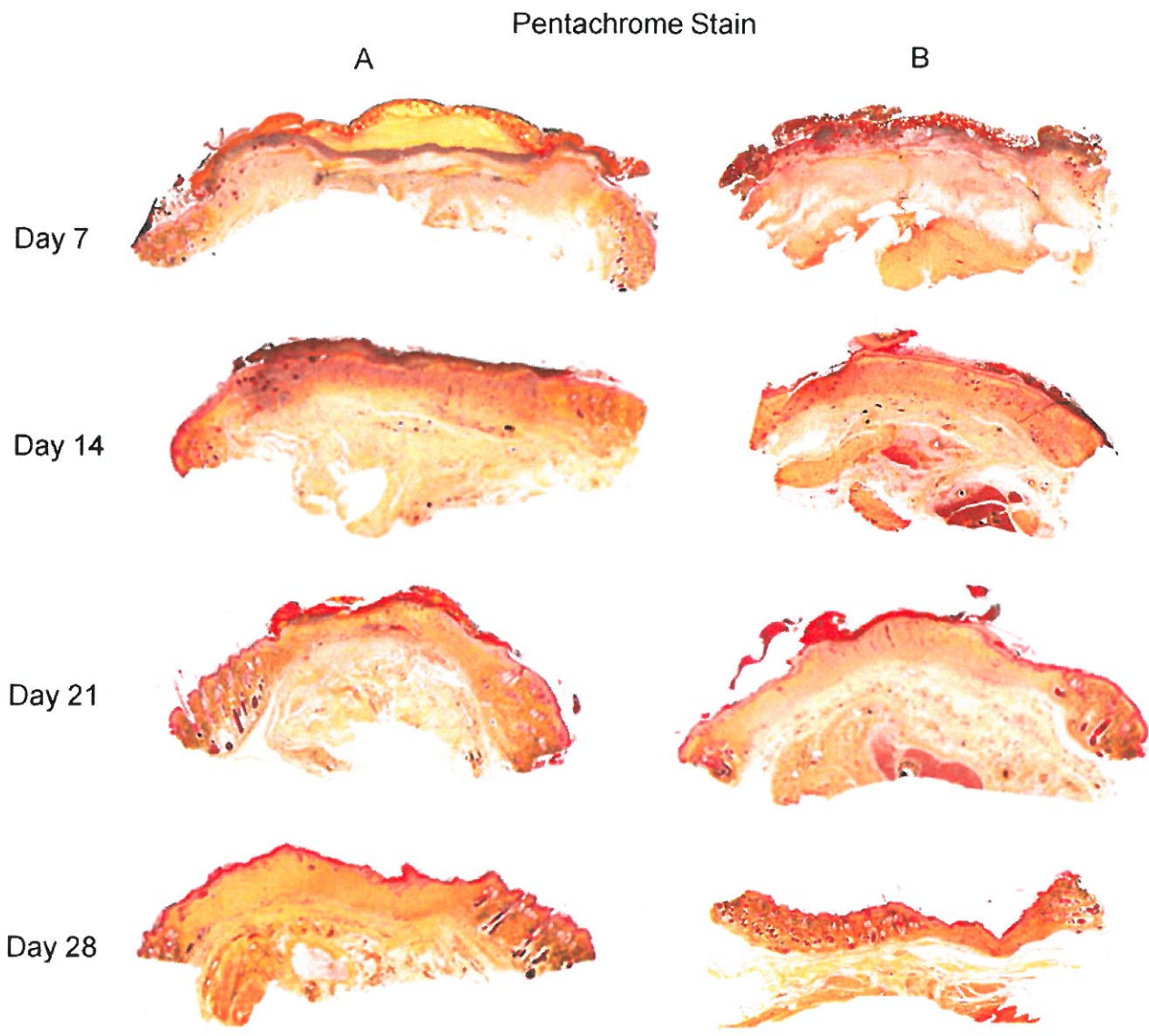


Figure 5: Movatt's pentachrome stained tissue sections of wounds treated with SSDM-CSM PEGylated fibrin gel with or without ASCs.

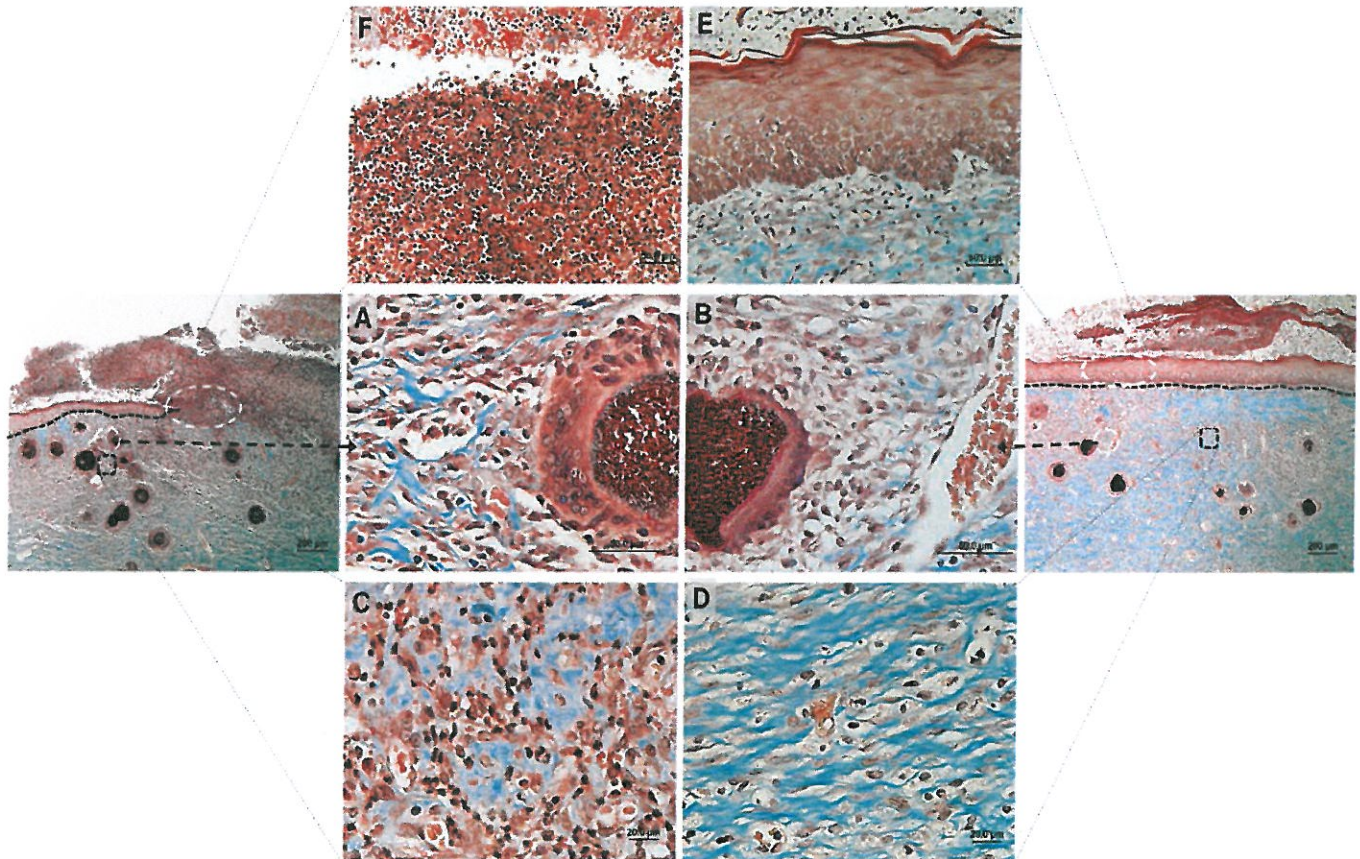


Figure 6: Masson's trichrome stained tissue sections of wounds treated with SSDM-CSM PEGylated fibrin gel with or without ASCs on day 14.

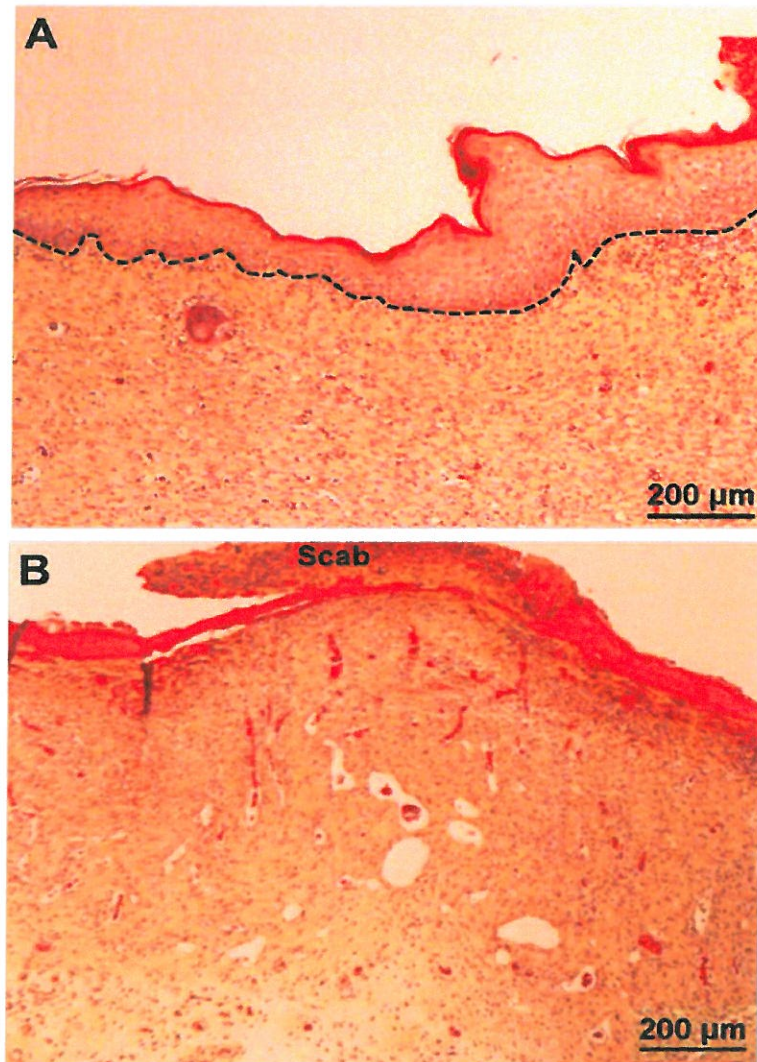


Figure 7: Movats pentachrome stained tissue sections of wounds treated with SSDM-CSM PEGylated fibrin gel with or without ASCs on day 21.

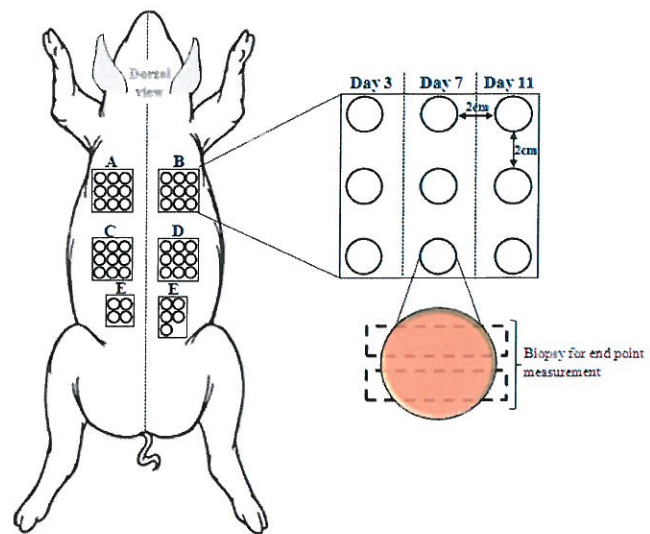
Specific Aim # 2: Effectiveness of SSD-CSM–PEGylated fibrin gels based dressing in a porcine full thickness infected excision wound model

We used a porcine full thickness infected excision wound model as similar to explained in our previous report (W81XWH-09-1-0607 PI Christy Annual Report Sep 2012). To obtain a statistical significance we repeated this study using two more animals. The animal model and treatment strategies are briefed below.

Porcine full thickness infected excision wound:

Young female specific pathogen free (SPF: Loper Farms, North Carolina) pig weighing 35-40 kg were used in this study. The animal was sedated with Telazol HCl, Xylazine and Atropine I.M. and anaesthetized using isoflurane: oxygen combination during preparation, wounding, and treatment.

Dorsal hair was clipped and skin surface was cleaned by washing with a non-antibiotic soap (Neutrogena Soap Bar; Johnson and Johnson, Los Angeles, CA) and sterile water. The animal was blotted dry with sterile gauze. Forty five (45) full thickness wounds were made on the paravertebral and thoracic area with a 10mm punch biopsy. The wounds were separated from one another by 15 mm of unwounded skin. Treatment groups (5) were randomly assigned to different anatomical areas on the pig. Nine (9) wounds were assigned to each treatment group according to the experimental design shown in figure 8. Immediately after wounding, the wounds were inoculated with *Pseudomonas aeruginosa* 09-010 (PA09-010 is military bacteria wound isolated) as described in the “Wound Inoculation” section below and then were covered with polyurethane film dressing (Tegaderm; 3M, St. Paul, MN).



- A: Chitosan microspheres Ag + Gel*
- B: Chitosan microspheres Ag + w/o Gel*
- C: Chitosan microspheres Ag + Gel*
- D: Chitosan microspheres w/o Ag *
- E: Tegaderm Control*
- (Chitosan microspheres 40 mg)

Figure 8: Schematic Representation of excision wound location and treatment groups

Wound Inoculation

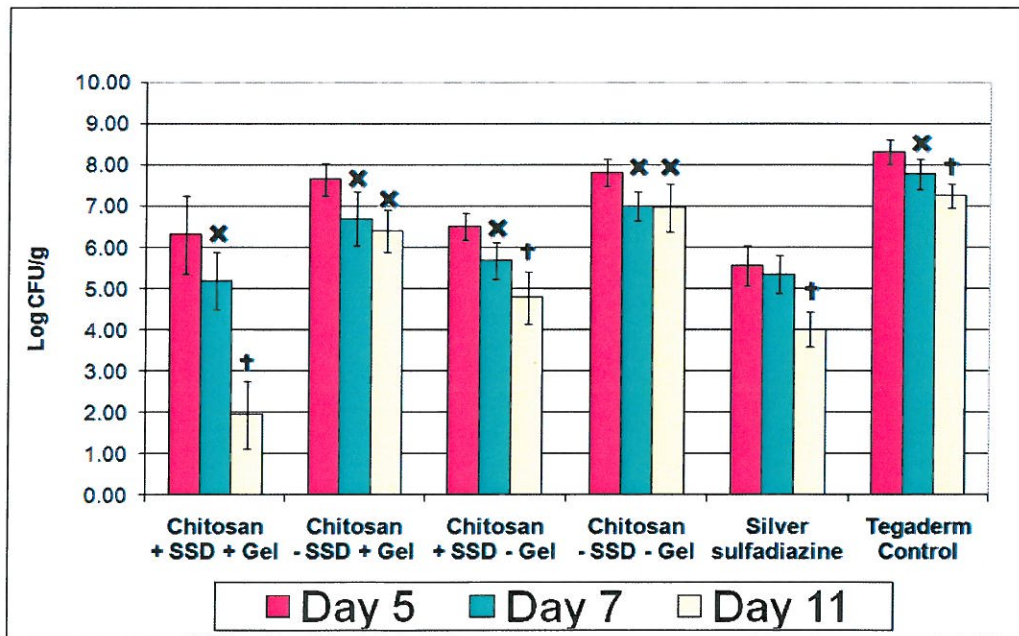
The pathogenic strain of *Pseudomonas aeruginosa* PA 09-010 was used in this study. The challenge inoculum suspension was prepared by scraping the overnight growth from a culture plate into 5 ml of normal saline (see below). This resulted in a suspension concentration of approximately 10^{10} colony forming units/ml (CFU/ml). Serial dilutions were made until a concentration of 10^6 CFU/ml was achieved. In addition, serial dilutions of the suspension were plated onto culture media to quantify the exact concentration of viable organisms used for this experiment. The inoculum suspension was used directly to inoculate each wound by pipeting a 25 μ l aliquot in the center of each wound site. All wounds were covered with a polyurethane film dressing (Tegaderm Transparent Dressing; 3M Health Care, St. Paul, MN USA). All sites were secured with surgical tape and the entire animal loosely wrapped with Coban self-adhesive

elastic wrap (3M, St. Paul MN). The dressings were left in place for 24 hours to allow formation of a challenging inoculum in the wounds. After 24 hours, the dressings were removed and all wounds were treated with the appropriate treatment, and redressed appropriately.

Microbiology Assessment

Three wounds were biopsied (6mm punch biopsy and an incisional wedge biopsy which included normal skin on both sides) per group on days 5, 7 and 11 post treatment application. The punch biopsy (6mm) was taken from the center of the wound and weighed then immediately placed in 1 ml of All Purpose Neutralizing Solution. The sample was combined with an additional 2 ml of Neutralizing Solution and homogenized in a sterile homogenization tube (Tenbroeck Tissue Grinder). Serial dilutions were made and plated in a *Pseudomonas* Agar-base with CN supplementation. After plating, all samples were incubated aerobically for 24 hours at 37° C. After the incubation period, colonies on the plates were counted and the CFU/g calculated.

Results:



†p<0.05 compared to Day 5 and Day 7 *p<0.05 compared to Day 5

CSM + SSD + FPEG				CSM - SSD + FPEG				CSM + SSD - FPEG			
* p<0.05 statistical significance				* p<0.05 statistical significance				* p<0.05 statistical significance			
Treatment	Day 5	Day 7	Day 11	Treatment	Day 5	Day 7	Day 11	Treatment	Day 5	Day 7	Day 11
Day 5		0.033*	0.000*	Day 5		0.005*	0.000*	Day 5		0.007*	0.000*
Day 7	0.033*		0.000*	Day 7	0.005*		0.503	Day 7	0.007*		0.004*
Day 11	0.000*	0.000*		Day 11	0.000*	0.503		Day 11	0.000*	0.004*	

CSM - SSD - FPEG				SSD (Silver sulfadiazine)				Tegaderm Control			
* p<0.05 statistical significance				* p<0.05 statistical significance				* p<0.05 statistical significance			
Treatment	Day 5	Day 7	Day 11	Treatment	Day 5	Day 7	Day 11	Treatment	Day 5	Day 7	Day 11
Day 5		0.004*	0.003*	Day 5		0.601	0.000*	Day 5		0.008*	0.000*
Day 7	0.004*		0.985	Day 7	0.601		0.000*	Day 7	0.008*		0.010*
Day 11	0.003*	0.985		Day 11	0.000*	0.000*		Day 11	0.000*	0.010*	

Figure 9: Combined bacterial count of *Pseudomonas aeruginosa* for each assessment

The mean of the Log (CFU/g) and standard deviations were calculated for each time and treatment. The data was then combined with the previous study's results and analyzed for significance using ANOVA which analyzed the mean Log CFU/g for the combined animal data. On the first assessment day, five (5) days post inoculation, the Silver Sulfadiazine control eliminated the greatest amount of *P. aeruginosa* and yielded a 2.75 ± 0.19 Log CFU/g reduction compared to the Tegaderm treated wounds. The wounds treated with SSD exhibited a 99.82% reduction compared to the Tegaderm control and reduced the bacteria significantly ($p < 0.05$) compared to every treatment group except for Chitosan + SSD + Gel of which there was no significant difference between the treatments on this day (figure 3). The Chitosan + SSD + Gel was the next best treatment in reducing *PA* which yielded a 99.01% (2.00 ± 0.64 Log CFU/g) reduction compared to the Tegaderm control wounds. The Chitosan + SSD – Gel treated wounds showed the third greatest reduction of *PA* as compared to the tegaderm control (1.81 ± 0.02 Log CFU/g; 98.44% reduction). The results on the initial assessment day demonstrate the efficiency of the treatment modality with all of the active ingredients present as well as the positive control. As expected the Tegaderm (negative) control reduced the least amount of bacteria on this day and harbored 8.32 ± 0.30 Log CFU/g of bacteria compared to the SSD treated wounds which harbored a total of 5.57 ± 0.49 Log CFU/g of *PA*.

Overall, both the Chitosan + SSD + Gel and Chitosan + SSD – Gel treatment modalities significantly reduced ($p < 0.05$) *PA* compared to the other CSM without SSD treatment groups on day 5. The CSM + SSD + Gel treatment group exhibited reduction values of 1.34 ± 0.55 and 1.50 ± 0.61 Log CFU/g with reduction percentages of 95.41% and 96.82%, respectively, when compared to CSM – SSD with and without FPEG gel. The CSM + SSD – Gel treatment group demonstrated reduction amounts of 1.14 ± 0.07 and 1.30 ± 0.01 Log CFU/g corresponding to percentage values of 92.78% and 95.01%, respectively, compared to wounds treated with CSM – SSD with and without gel on day 5 (Figure 9).

On day 7, the Chitosan + SSD + Gel treatment surpassed the SSD's reduction potency and eliminated the greatest amount of *PA* (99.74% reduction value) out of all the treatment groups when compared to the Tegaderm control and exhibited a 2.59 ± 0.34 Log CFU/g reduction of *PA*. These results demonstrated the significance of controlled release of SSD from the Chitosan Microspheres impregnated within the PEGylated fibrin gel matrix. Also accounts for the fact that the treatment exhibited a significant *PA* reduction compared to the CSM – SSD With and Without Gel treatment groups (1.51 ± 0.05 and 1.82 ± 0.34 Log CFU/g, respectively). These values represent a 96.90% and 98.49% reduction of *PA* respectively. The SSD treated wounds eliminated the second greatest amount of bacteria compared to the Tegaderm treated wounds on day 7 by reducing 2.44 ± 0.10 Log CFU/g (99.63%) of *PA*. Both the SSD and CSM + SSD + Gel treatments resulted in significantly reducing *PA* counts ($p < 0.05$) when compared to the CSM lacking SSD treatments and the Tegaderm treated wounds. The Chitosan + SSD – Gel also demonstrated its ability to significantly reduce the bacteria counts ($p < 0.05$) compared to the CSM – SSD With and Without Gel treatments (1.02 ± 0.22 and 1.33 ± 0.08 Log CFU/g) as well as the Tegaderm control (2.10 ± 0.07 Log CFU/g) on this day corresponding to reduction values of 90.45%, 95.36% and 99.21%, respectively.

On day 11, the Chitosan + SSD + Gel significantly reduced ($p < 0.05$) the bacterial counts compared to all other treatment group represented and exhibited a 99.99% reduction compared to both CSM lacking SSD treatments and the Tegaderm control group. Similarly, the Chitosan + SSD – Gel treatment was able to significantly reduce ($p < 0.05$) the counts of *PA* colonies compared to both CSM – SSD With and Without Gel treatment groups and the Tegaderm control treatment on this day with reduction values of 97.54%, 99.35% and 99.66%, respectively.

When comparing the various treatments reductive abilities across the assessment days, it was apparent that the Chitosan + SSD + Gel eliminated the greatest amount of *PA* from day 5 to day 11 by significantly ($p < 0.05$) reducing the bacterial counts by 99.99% (4.37 ± 0.32 Log CFU/g). Overall, the Chitosan + SSD – Gel treatment was the second most effective treatment in reducing *PA* counts from day 5 to day 11 out of all the treatment groups and reduced 98.11% (1.72 ± 0.31 Log CFU/g) of bacteria from the wounds in this treatment group. Similar to the CSM + SSD + Gel treatment, this treatment also demonstrated a significant degree ($p < 0.05$) of reducing capabilities within these wounds between each set of assessment days (5-7 and 7-11) and exhibited reduction values of 85.36% (0.83 ± 0.12 Log CFU/g) and 87.10% (0.89 ± 0.19 Log CFU/g) from assessment day 5 to 7 and from day 7 to 11, respectively.

Conclusions

After examination of the statistical data, it was apparent that the Chitosan + SSD + Gel was the most effective treatment modality of all the treatments (A, B, C, D, E and F) when considering the prolonged persistency of the treatment's efficacy up to 11 days post inoculation. A total of 99.99% of *PA* was reduced by the Chitosan + SSD + Gel compared to the Chitosan – SSD + Gel, the Chitosan – SSD – Gel and the tegaderm control treatment reducing the bacteria by 4.45 ± 0.32 , 5.03 ± 0.24 and 5.31 ± 0.53 Log CFU/g, respectively.

The one-time Chitosan SSD application formulation demonstrated superior *PA* kill than daily application of SSD cream showing the importance of a sustained release vehicle. It is possible if additional application of the Chitosan SSD treatment was implemented that even larger reductions in *PA* could be seen.

Specific Aim # 3: Development of a deep partial thickness porcine burn injury model

Experimental methods: On the day before surgery, the animal was given a 100mcg patch of fentanyl citrate along with optional preoperative analgesic (hydromorphone, 0.2mg/kg IM). The pig was then intubated and anesthesia using 1% to 3% isoflurane in 100% oxygen.

Hair on the dorsum and flanks were trimmed and shaved after the animal was anesthetized. The area was disinfected with chlorohexidine and/or alcohol. Tattoo markings were made just before the burn procedure using an electric tattoo machine, while the animal is under anesthesia. Tattoo marks were used to monitor the amount of skin contraction and wound surface measurements.

Burn wounds were inflicted on the dorsum of the pig, at least 2 cm from the spine, within the tattoo marking and location of the burn wounds is shown in **Figure 10**. Brass cylinders (3cm diameter) were heated in a dry bath incubator at 100°C for 27 seconds after which the external contacting surface of the cylinder was placed to induce burns (**Figure 11A**).

Histological results from our model development studies, 24 hours post-burn, have found that burns that are 23 seconds in duration are superficial, 24-28 seconds create a deep-partial thickness burn wound, while 30 seconds of contact time results in third degree burns. Therefore, we created a deep-partial thickness burn using 27 second contact time (**Figure 10B**). A row of 6 wounds were placed at least 1.5cm from the spine, on either side of the dorsum. Additionally, if necessary, a row of burn wounds may be placed with similar spacing on the flank of the animal. Burn wounds were debrided (surgical removal of dead or damaged tissue) on day 4 post-burn and further treated with PEGylated fibrin, collagen based hydrogels. Wound biopsies were taken on days 7, 10, 14, and 28/42. Follow ups were performed by first removing the existing dressing. Photographs of wounds were taken, on various post-burn days and followed up to 42 days post-burn.

Results:

Gross macroscopic and H and E histology images of burns 24 hours post-injury shows that burns of 26 (**Figure 11C**), 28 (**Figure 11D**), and 30 (**Figure 11E**) seconds all appear pale with pronounced zones of stasis. Depth of collagen coagulation can be quantified and determined histologically. Probe contact time correlates negatively with total skin thickness and positively with the percentage of dermal collagen coagulated (i.e. burn depth). Burn that initially created damage in the form of collagen degeneration to the mid dermis ultimately spread to become deep partial thickness wounds.

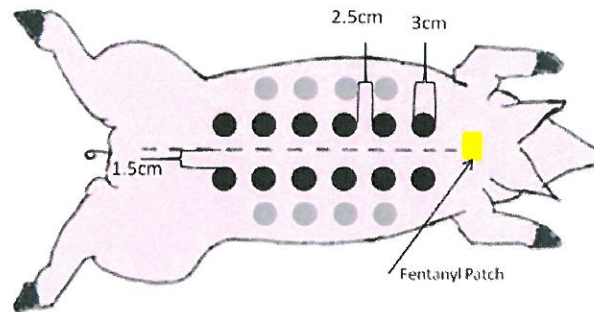


Figure 10: Schematic showing burn dimensions and locations on the back of the animal.

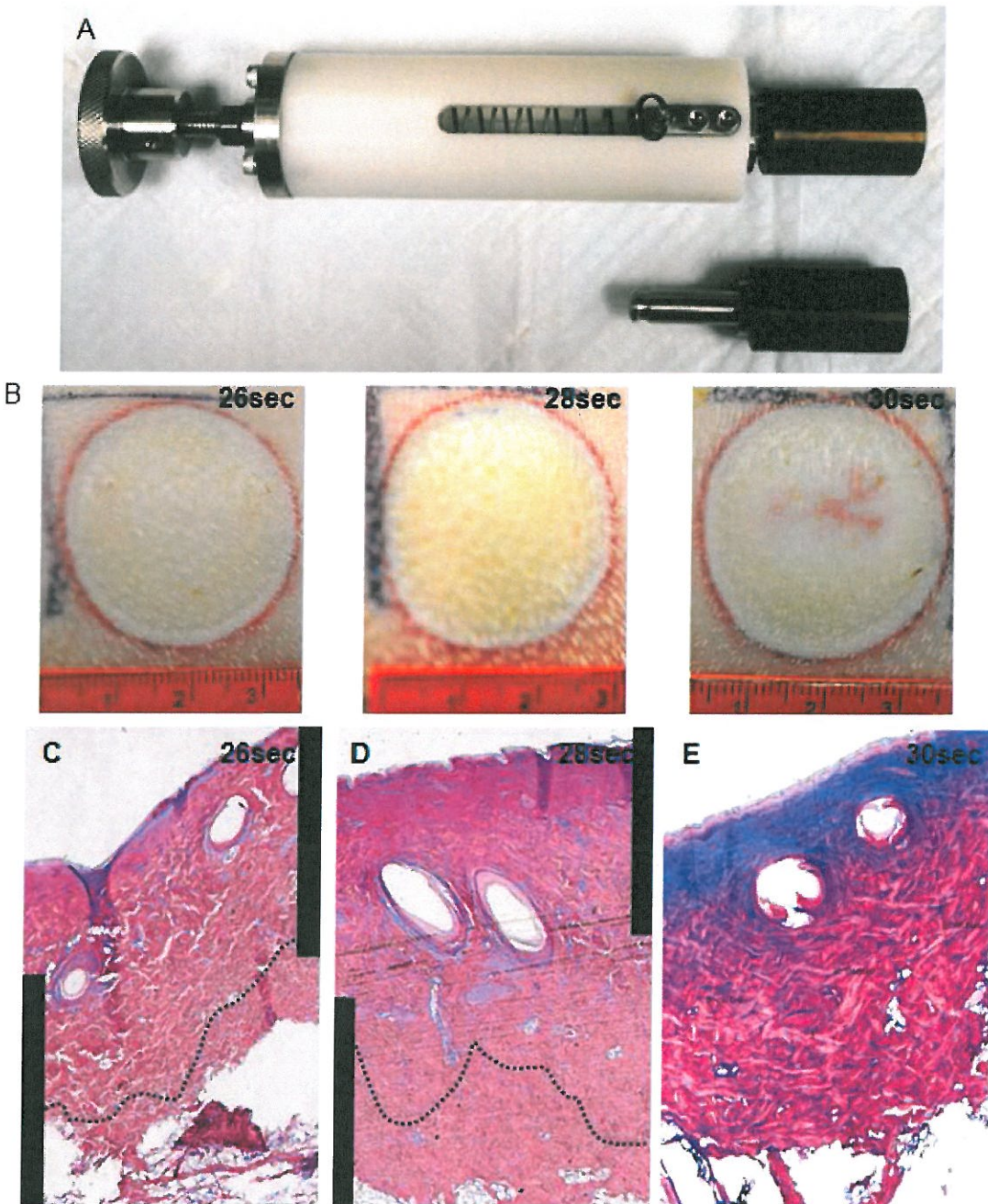


Figure 11: Macroscopic and Hematoxylin and Eosin histology images of burns 24 hours post-injury

Specific Aim # 4: Determine the effect of ASCs–PEGylated fibrin gels in a porcine deep partial thickness burn wound model

The final phase of the current project focuses on the use of PEGylated fibrin gel and ASCs for regeneration of burn wound. In the previous report we provided experimental evidences for either culture expanded ASCs or freshly isolated stromal vascular fraction (SVF) in combination with PEGylated fibrin gel to influence angiogenic response and showed relatively better epithelial coverage and epithelial maturation in comparison to the fibrin gel alone. Following these observations, we further tested ASCs embedded within the fibrin gel in a deep partial thickness porcine burn wound model (detailed above).

Treatment groups

Treatments comprised of PEGylated fibrin gels, collagen hydrogels, and controls) with or without stem cells. To provide a successful wound healing/tissue engineering construct and to simulate the point-of-care clinical situation, fibrin gels were formed in situ on top of the debrided burn wound by mixing the PEG-fibrinogen liquid mixture with a known concentration of thrombin using a dual syringe applicator. This type of treatment provides the development of conditions that closely mimic the *in vivo* microenvironment.

Results:

We were able to successfully able to form fibrin gels in situ. The gels adhered to wound surface and the contours of the debrided surfaces within the wound bed. From our pilot study experiments we found by applying a topical chemoprophylactic antibiotic ointment around the wound post-burn and gel application provided appropriate protection against secondary infection. Though in our project we proposed to use SSD-chitosan microsphere impregnated within a collagen sheet as a secondary wound coverage, in our current study we were able prevent secondary infection using a bacitracin ointment.

We are currently completing the final analysis of the histological and biochemical results of this study which will be included in a future manuscript.

Reportable Outcomes

Abstracts and Presentations:

1. **Determining the Effects of Chitosan, Silver Sulfadiazine with Fibrin Gels on *Pseudomonas aeruginosa* Biofilms using a Porcine Full Thickness Wound Model.** Stephen Davis, Shanmugasundaram Natesan, Joel Gil, Ryan Treu, Jose Valdes, Andrew Harding, Michael Solis, Robert Christy. Poster Presented at the Wound Healing Society, Denver, CO, April 2013.

Abstract:

Silver Sulfadiazine (SSD) remains to be a routinely used antimicrobial agent especially for eliminating gram negative bacteria in wounds.^{1,2} In order for any antimicrobial to be effective, an optimal sustained delivery system is needed. The following study evaluated the antimicrobial and wound healing efficacy of Chitosan Microspheres (CM) impregnated with SSD in conjunction with Fibrin Polyethylene Glycol (FPEG) hydrogels on full-thickness wounds infected with *Pseudomonas aeruginosa*. Using a well-established porcine model,^{3, 4, 5} one-hundred and forty-four (144) punch biopsy (10 mm) wounds were made and then inoculated with PA. After 24 hours, the wounds were treated with one of the following; (1) CM+SSD+FPEG*, (2) CM-SSD+FPEG*, (3) CM+SSD-FPEG*, (4) CM-SSD-FPEG*, (5) SSD and (6) polyurethane film control. Wounds from all treatments were treated only once except for SSD which was treated once daily. One wedge biopsy (histological assessment) and one 4 mm punch biopsy (microbiological assessment) were taken from each wound on days 5, 7 and 11 post treatment application. By day 11, the CM+SSD+FPEG treatment significantly reduced ($P<0.05$) PA counts compared to every other treatment group and exhibited a 5.31 ± 0.53 Log CFU/g reduction (99%) compared to the polyurethane control group. Furthermore, on day 11, the wounds treated with CM+SSD+FPEG had no difference in healing as compared to control wounds. Overall, the CM+SSD+FPEG eliminated the most PA was found not be detrimental to the healing process. The use of a sustained delivery system of SSD may have important clinical implications.

2. **Development of a Porcine Contact Burn which Progresses to Deep Partial Thickness.** David M. Burmeister, Daniel Roy, Bridget Ford, Shanmugasundaram Natesan, and Robert J. Christ. **Poster Presented at MHSRS, Tampa, FL, August 2013.**

Abstract:

Due to the recent increase in the use of improvised explosive devices, burns are the primary injury in ~5% of evacuated military personnel. Average evacuation time is 7 days from the combat zone to rehabilitative care in the U.S, which makes the fact that burns are dynamic injuries troublesome. The zone of ischemia that surrounds the coagulated, necrotic tissue may also become compromised within 3 days post-injury. As such, we sought to develop a contact burn model in a pig that progresses to a deep partial thickness wound. Three cm² brass probes were heated to 100°C and applied to the dorsum of Yorkshire pigs for 14-30 seconds. Biopsies of wounds were excised between 1-28 days post-injury for routine histopathology. The application time of the probe positively correlated with the percent of dermis coagulated and negatively correlated with total dermal thickness. Application of the probe for 27 seconds led to a central

zone of coagulation that initially comprised ~60-70% of the dermis 24 hours post-injury. This area of damage spread to the dermal-hypodermal junction by 7 days post-injury. Histological examination 28 days after injury revealed significant granulation tissue deposition that spanned the majority of the thickness of the dermis. Thus, we have developed a model of porcine contact burn that recapitulates the timecourse of burn wound progression. This model can be used as a platform for testing existing and new tissue engineered products that may mitigate the spread of thermal injury and stimulate wound healing.

3. **Development of a Third-Degree Burn Wound Model to Evaluate Scarring.** Davis SC, Waibel JS, Christy RJ, Schulman CI, Gil J, Ford, BM, Natesan S, Valdes J, Treu R, Solis M, Salgado M, Rodriguez-Menocal L, Shabbir A, Badiavas EV. **Poster Presented at MHSRS, Tampa, FL, August 2013.**

Abstract:

Despite advances in the acute management of burn injury, scarring with subsequent contractures remains a major problem. Long after the initial injury, burn scars result in substantial functional impairment restricting return to service and can impact a veteran's adjustment to civilian life. Treatments designed to mitigate the effects of hypertrophic scarring including scar massage, topical treatments, steroid injections, and compression garments have met with only limited success. The development of an *in-vivo* model to assess potential treatments to reduce scar formation as well as evaluate therapies for the treatment of existing scars may have significant clinical impact. In collaboration between USAISR and the University of Miami, a scar model was developed to assess laser treatment. Third degree burns were created on Red Duroc pigs using a branding iron; scars were allowed to develop and then treated with a fractional CO₂ or Erbium-YAG laser. Biopsies were taken after laser treatment for histologic evaluation and cell culture. Differences in collagen bundle, epidermal thickness and fibroblast cell growth were noted between control and lasers. Results have shown that the Red Duroc pigs formed scars similar to those observed in humans and that laser therapy can modulate the scar response. This model can be used to determine if the efficacy of new scar therapies which may have significant impact on both military personnel and civilian who suffer from burns.

4. Manuscript (in Preparation)
Determining the Effects of Silver Sulfadiazine Containing Chitosan Microspheres in Fibrin Gels on Pseudomonas aeruginosa Biofilms in Full Thickness Wounds.
Shanmugasundaram Natesan, Stephen Davis, Joel Gil, Ryan Treu, Robert Christy.

Conclusion

Invasive infection remains the most common cause of morbidity and mortality in patients with extensive burn injuries. Recent guidelines from the tactical combat casualty care (TCCC) committee recommend the use of SSD or mafenide acetate formulations as the primary standard of care for preventing infection. Novel combinations of antimicrobials/antibiotics, biomaterials/scaffolds, and stem cells will prevent infection and improve one or more stages of the wound healing process. Also, battle field related infected burn wounds require an antibacterial drug delivery system which can control and arrest infection for prolonged time without frequent dressing change. In the last decade, fibrin hydrogels have been widely used for promoting angiogenesis in a variety of tissue engineering applications. Further, fibrin has been used clinically as an FDA-approved hemostatic agent and as a sealant in a variety of clinical applications. The currently developed SSD-CSM-PEGylated fibrin wound dressing delivers SSD in a controlled manner within a defined bactericidal concentration for a period of 3 days. The coupled systematic approach of controlling drug release in a biocompatible polymer and angiogenic gel has implications in the treatment of infected burn wounds. From this study ASCs seem to modulate the skin wound healing process, including collagen synthesis and re-epithelialization. The wound healing effects of ASC verified with our *in vivo* study in rats, demonstrated that ASC significantly reduced wound size and accelerated re-epithelialization. In this study we have the efficacy of silver sulphadiazine-chitosan microspheres (SSD-CSM) impregnated in polyethylene glycol-fibrin gels (PEGylated fibrin gels) with ASC on healing an infected burn wound. The ability of the dressing to support tubular network formation by ASCs (shown in our previous report) has significantly shown to improve infected burn wound healing. Current results indicate that our SSD-fibrin based dressings have the potential to combat infection in wounds and significantly improve healing and wound repair.

References:

1. Church, D., et al., *Burn wound infections*. Clin Microbiol Rev, 2006. 19(2): p. 403-34.
2. D'Avignon, L.C., et al., *Prevention and management of infections associated with burns in the combat casualty*. J Trauma, 2008. 64(3 Suppl): p. S277-86.
3. Keen, E.F., 3rd, et al., *Incidence and bacteriology of burn infections at a military burn center*. Burns, 2010. 36(4): p. 461-8.
4. Kennedy, P., S. Brammah, and E. Wills, *Burns, biofilm and a new appraisal of burn wound sepsis*. Burns, 2010. 36(1): p. 49-56.
5. Guo, S. and L.A. Dipietro, *Factors affecting wound healing*. J Dent Res, 2010. 89(3): p. 219-29.
6. Fox, C.L., Jr., *Silver sulfadiazine--a new topical therapy for Pseudomonas in burns. Therapy of Pseudomonas infection in burns*. Arch Surg, 1968. 96(2): p. 184-8.
7. Ollstein, R.N., et al., *Alternate case study of topical sulfamylon and silver sulfadiazine in burns*. Plast Reconstr Surg, 1971. 48(4): p. 311-7.
8. Coward, J.E., H.S. Carr, and H.S. Rosenkranz, *Silver sulfadiazine: effect on the growth and ultrastructure of Staphylococci*. Chemotherapy, 1973. 19(6): p. 348-53.
9. Rosenkranz, H.S. and H.S. Carr, *The determination of the susceptibility of bacterial isolates to silver sulfadiazine*. Chemotherapy, 1978. 24(3): p. 143-5.
10. Wlodkowski, T.J. and H.S. Rosenkranz, *Antifungal activity of silver sulphadiazine*. Lancet, 1973. 2(7831): p. 739-40.
11. Harrison, H.N., *Pharmacology of sulfadiazine silver. Its attachment to burned human and rat skin and studies of gastrointestinal absorption and extension*. Arch Surg, 1979. 114(3): p. 281-5.
12. Sano, S., et al., *Absorption, excretion and tissue distribution of silver sulphadiazine*. Burns Incl Therm Inj, 1982. 8(4): p. 278-85.
13. Gear, A.J., et al., *A new silver sulfadiazine water soluble gel*. Burns, 1997. 23(5): p. 387-91.
14. Kawai, K., et al., *Development of an artificial dermis preparation capable of silver sulfadiazine release*. J Biomed Mater Res, 2001. 57(3): p. 346-56.
15. Seetharaman, S., et al., *A PEGylated fibrin-based wound dressing with antimicrobial and angiogenic activity*. Acta Biomater, 2011. 7(7): p. 2787-96.
16. Baghel, P.S., et al., *A comparative study to evaluate the effect of honey dressing and silver sulfadiazine dressing on wound healing in burn patients*. Indian J Plast Surg, 2009. 42(2): p. 176-81.
17. Guo, X., et al., *Repair of osteochondral defects with biodegradable hydrogel composites encapsulating marrow mesenchymal stem cells in a rabbit model*. Acta Biomater, 2010. 6(1): p. 39-47.
18. Lim, S.M., et al., *Dual growth factor-releasing nanoparticle/hydrogel system for cartilage tissue engineering*. J Mater Sci Mater Med, 2010. 21(9): p. 2593-600.
19. Jackson, W.M., L.J. Nesti, and R.S. Tuan, *Potential therapeutic applications of muscle-derived mesenchymal stem and progenitor cells*. Expert Opin Biol Ther, 2010. 10(4): p. 505-17.
20. Zhang, G., et al., *A PEGylated fibrin patch for mesenchymal stem cell delivery*. Tissue Eng, 2006. 12(1): p. 9-19.
21. Zhang, G., et al., *Vascular differentiation of bone marrow stem cells is directed by a tunable three-dimensional matrix*. Acta Biomater, 2010. 6(9): p. 3395-403.

22. Ozerdem, U. and W.B. Stallcup, *Early contribution of pericytes to angiogenic sprouting and tube formation*. *Angiogenesis*, 2003. 6(3): p. 241-9.
23. Grzybowski, J., et al., *New cytokine dressings. II. Stimulation of oxidative burst in leucocytes in vitro and reduction of viable bacteria within an infected wound*. *Int J Pharm*, 1999. 184(2): p. 179-87.
24. Shanmugasundaram, N., et al., *Efficiency of controlled topical delivery of silver sulfadiazine in infected burn wounds*. *J Biomed Mater Res A*, 2009. 89(2): p. 472-82.
25. Zuk, P.A., et al., *Human adipose tissue is a source of multipotent stem cells*. *Mol Biol Cell*, 2002. 13(12): p. 4279-95.
26. Zuk, P.A., et al., *Multilineage cells from human adipose tissue: implications for cell-based therapies*. *Tissue Eng*, 2001. 7(2): p. 211-28.

Appendices:
None