

AWARD NUMBER: W81XWH-13-2-0057

TITLE: Positioning Vascularized Composite Allotransplantation within the Spectrum of Transplantation

PRINCIPAL INVESTIGATOR: Christina L. Kaufman PhD

CONTRACTING ORGANIZATION: Christine M. Kleinert Institute for Hand and Microsurgery  
Louisville, KY 40202-1882

REPORT DATE: October 2016

TYPE OF REPORT: Annual

PREPARED FOR: U.S. Army Medical Research and Materiel Command  
Fort Detrick, Maryland 21702-5012

DISTRIBUTION STATEMENT: Approved for Public Release;  
Distribution Unlimited

The views, opinions and/or findings contained in this report are those of the author(s) and should not be construed as an official Department of the Army position, policy or decision unless so designated by other documentation.

<b>REPORT DOCUMENTATION PAGE</b>		<i>Form Approved</i> OMB No. 0704-0188
Public reporting burden for this collection of information is estimated to average 1 hour per response, including the time for reviewing instructions, searching existing data sources, gathering and maintaining the data needed, and completing and reviewing this collection of information. Send comments regarding this burden estimate or any other aspect of this collection of information, including suggestions for reducing this burden to Department of Defense, Washington Headquarters Services, Directorate for Information Operations and Reports (0704-0188), 1215 Jefferson Davis Highway, Suite 1204, Arlington, VA 22202-4302. Respondents should be aware that notwithstanding any other provision of law, no person shall be subject to any penalty for failing to comply with a collection of information if it does not display a currently valid OMB control number. <b>PLEASE DO NOT RETURN YOUR FORM TO THE ABOVE ADDRESS.</b>		
<b>1. REPORT DATE (DD-MM-YYYY)</b> October 2016	<b>2. REPORT TYPE</b> Annual	<b>3. DATES COVERED (From - To)</b> 15 Sep 2015 - 14 Sep 2016
<b>4. TITLE AND SUBTITLE</b> Positioning Vascularized Composite Allotransplantation within the Spectrum of Transplantation		<b>5a. CONTRACT NUMBER</b> W81XWH-13-2-0057
		<b>5b. GRANT NUMBER</b> MR120023P2
		<b>5c. PROGRAM ELEMENT NUMBER</b>
<b>6. AUTHOR(S)</b> Christina L. Kaufman PhD  Email: ckaufman@cmki.org		<b>5d. PROJECT NUMBER</b>
		<b>5e. TASK NUMBER</b>
		<b>5f. WORK UNIT NUMBER</b>
<b>7. PERFORMING ORGANIZATION NAME(S) AND ADDRESS(ES)</b> Christine M. Kleinert Institute for Hand and Microsurgery 225 Abraham Flexner Way, Louisville, KY 40202		<b>8. PERFORMING ORGANIZATION REPORT NUMBER</b>
<b>9. SPONSORING / MONITORING AGENCY NAME(S) AND ADDRESS(ES)</b> U.S. Army Medical Research and Materiel Command Fort Detrick, Maryland 21702-5012		<b>10. SPONSOR/MONITOR'S ACRONYM(S)</b>
		<b>11. SPONSOR/MONITOR'S REPORT NUMBER(S)</b>
<b>12. DISTRIBUTION / AVAILABILITY STATEMENT</b>		
<b>13. SUPPLEMENTARY NOTES</b>		

**14. ABSTRACT**

The purpose of this project is to enable more patients to access VCA transplantation. The work in Louisville will focus on using non-invasive imaging techniques that can be used to monitor vessels and nerves in VCA recipients (Aim 6). The goal is to identify changes while there is still time to intervene. Studies are initiated using infrared imaging of ICG dye to study blood perfusion and lymphatic drainage in our hand transplant patients. We are extending our studies of vessel wall thickness using very high resolution ultrasound, and including non-invasive studies of nerve anatomy. In Aim 7 we established a rodent model to study VCA vasculopathy, both with respect to imaging modalities and what factors initiate or exacerbate graft vasculopathy. Initial IR-ICG imaging studies of graft perfusion correlate well with acute graft rejection in our animals. Finally in Aim 8 we will develop standardization of protocols and clinical monitoring and treatment for VCA targeting vascular health. We propose to serve as the central site for the standardization of bioimaging assessment of vasculopathies in hand and face allotransplants. The ultimate goal is to expand the available options for individuals with combat-related injuries in need of complex tissue reconstruction by elevating VCA to the level of an established therapy for use in appropriately selected personnel with severe traumatic tissue loss.

**15. SUBJECT TERMS** VCA, vasculopathy, animal model, high resolution ultrasound, Fluorescence angiography, immune monitoring, graft rejection, histology, standardization, hand transplant, face transplant

**16. SECURITY CLASSIFICATION OF:**

<b>a. REPORT</b> U		<b>17. LIMITATION OF ABSTRACT</b> UU	<b>18. NUMBER OF PAGES</b>  26	<b>19a. NAME OF RESPONSIBLE PERSON</b> USAMRMC
	<b>b. ABSTRACT</b> U	<b>c. THIS PAGE</b> U		<b>19b. TELEPHONE NUMBER</b> (include area code)

**Standard Form 298 (Rev. 8-98)**

Prescribed by ANSI Std. Z39.18

# Table of Contents

	<u>Page</u>
<b>INTRODUCTION</b> .....	5
<b>KEYWORDS</b> .....	5
<b>ACCOMPLISHMENTS</b> .....	5
<b>IMPACT</b> .....	19
<b>CHANGES/PROBLEMS</b> .....	20
<b>PRODUCTS</b> .....	21
<b>PARTICIPANTS &amp; OTHER COLLABORATING ORGANIZATIONS</b> .....	23
<b>SPECIAL REPORTING REQUIREMENTS</b> .....	26
<b>APPENDICES</b> .....	26

**INTRODUCTION:** The principal objective of this project is to hone vascularized composite allotransplantation (VCA) into a useful therapeutic option for patients in need of advanced tissue reconstruction and replacement. This is a multi-institutional and multi-disciplinary project between the Louisville VCA Program, which is composed of four different institutions in Louisville, the University of Pennsylvania, the University of Maryland, and at this point, Duke University. The work in Louisville is focused on aims 6,7 and 8 of the Statement of work. Specifically in Aim 6 we will evaluate less invasive bio-imaging modalities with standard of care biopsy and peripheral blood analysis to assess vasculopathies associated with VCA in patients. In Aim 7 we will establish disease mechanisms associated with vasculopathy in pre-clinical models of VCA. Finally in Aim 8 we will develop standardization of protocols and clinical monitoring and treatment for VCA targeting vascular health. We propose to serve as the central site for the standardization of bioimaging assessment of vasculopathies in hand and face allotransplants. The ultimate goal is to expand the available options for individuals with combat-related injuries in need of complex tissue reconstruction by elevating VCA to the level of an established therapy for use in appropriately selected personnel with severe traumatic tissue loss.

**KEYWORDS:** VCA, vasculopathy, animal model, high resolution ultrasound, Fluorescence angiography, immune monitoring, graft rejection, histology, standardization, hand transplant, face transplant

### **ACCOMPLISHMENTS:**

The major goals of this project are focused on Aim 6, 7 and 8 of the Statement of work, which are as follows:

**Aim 6. To evaluate less invasive bio-imaging modalities with standard of care biopsy and peripheral blood analysis to assess vasculopathies associated with VCA in patients.**

Hypothesis: Vascular events associated with VCA can be identified and the therapeutic intervention efficacy can be assessed using minimally invasive, bioactive contrast imaging of the transplant vasculature. To test the hypothesis, we will perform vascular assessments in existing and new VCA patients in the Consortium using our bioimaging modalities. Image findings will be correlated with

clinical course, rejection activity, biopsy results (including genomic analysis), and blood-based measurements including flow cytometric and cytokine analyses, with specific emphasis on humoral immune responses.

**Performing Institution:** Louisville

**Task 1.** To establish and maintain a database of imaging data and clinical follow-up including immune monitoring assays.

**Task 2.** To perform imaging clinical and immune monitoring of subjects as well as historical controls for comparison of rejection episodes, humoral immune status and mature lineage and cytokine analysis of peripheral blood Regulatory review and approval process (months 1-4).

**Subtask 2.1.** To collect data regarding non-histologic indices of rejection such as hand volume (edema), presence of rash or erythema, and level of involvement, i.e. localized or generalized involving a named (i.e. 25%) percentage of the allograft dorsal or ventral surface.

**Subtask 2.1.** To perform immune monitoring assays on peripheral blood lymphocytes at rejection and following resolution.

**Aim 7. To establish disease mechanisms associated with vasculopathy in pre-clinical models**

**of VCA.** Hypothesis: VCA-associated macro- and microvasculopathies are due to chronic and multiple acute rejection activities, and can be exacerbated to confluent aggressive vasculopathy by non-alloimmune triggers. We will perform vascular imaging assessments utilizing mouse preclinical models of VCA in experiments with defined rejection regimens. In addition, we will use vascularized composite autograft models to evaluate the effects of inflammation and antirejection medications in the absence of active rejection. Our evaluations will include molecular and histologic analyses in combination with imaging-based measurements, including those utilizing already developed and tested targeted bioactive contrast agents for use in assessing vascular status.

**Performing Institution:** Louisville (in collaboration with Penn, Emory and Maryland)

**Task 1:** To perform osteomyocutaneous (hindlimb) allogeneic VCA in rodents (Regulatory review and approval process.

**Task 2:** To establish baseline and experimental imaging standards in rodent model

**Subtask 2a:** To transplant groups of animals and follow and image over a 28-90 day period

**Subtask 2b:** To perform immunologic and histologic analysis of VCA recipients

**Task 3:** To perform murine transplants involving pharmacological and genetic perturbations to allo-rejection

**Subtask 3.1:** To transplant groups of animals evaluating experimental interventions with imaging

**Aim 8– To develop standardization of protocols and clinical monitoring and treatment for VCA targeting vascular health.** We propose to serve as the central site for the standardization of (a) bioimaging assessment of vasculopathies in hand and face allotransplants, and (b) Collaborate with consortium members in submission of biorepository samples and digitization of existing Hematoxylin and Eosin slides of clinical VCA biopsies.

**Focus areas:** Clinical Monitoring of Composite Tissue allotransplant recipients, and Established Practice and Protocol

**Performing Institution:** All sites

**Task 1:** To establish reproducible and HIPAA compliant protocols for UBM, MLDI and SPY imaging in VCA recipients (Regulatory review and approval process (1-4). Data collection

**Task 2:** To implement and maintain database and data sharing protocols for clinical and experimental animal data with consortium members

**Task 3:** To participate with consortium members in submission of historical and prospective VCA patient histological slides and biopsy samples for digitization using the Aperio system.

### **What was accomplished under these goals?**

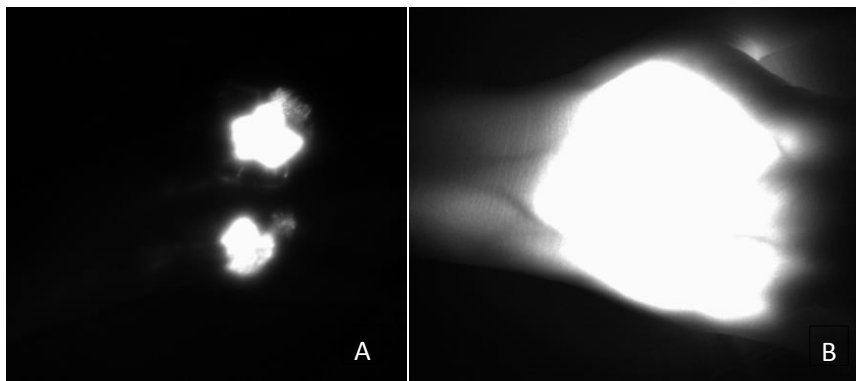
In the third year of this grant, we made significant progress using our rat osteomyocutaneous flap model to study the effect of rejection on vasculopathy and also initiated our protocol of whole body vibration to establish the role of external and environmental influences on rejection in VCA grafts. In the third year of the grant we also received approval for, and implemented our studies of lymphatic function via subdermal injections of indocyanine green, in both normal controls and in our hand transplant recipients. Both of these projects have resulted in manuscripts which should be submitted in the first quarter of year 4. We have also made significant progress in using the Vevo 2100 in imaging vasculopathy in the rat model, as well as improving and expanding our collection of digitized slides of skin biopsies from our hand transplant recipients and our archive of blood, plasma and DNA from clinical and experimental models for future studies.

In the third year of the grant we finalized and signed the material transfer and data use agreement with the VCAci consortium, which is located at Duke University.

In the third year of the grant we applied for and received approval from both our local IRB as well as HRPO to perform intradermal injections of indocyanine green (ICG) and infrared camera imaging using the LUNA fluorescence angiography unit. After the initial pilot study in one of our hand transplant recipients, it became clear that we needed to characterize and standardize intradermal injections of ICG in normal recipients so that we could define normal or abnormal flow in transplant recipients. A review of the literature showed that much of the ICG imaging of the upper extremity was performed in patients following oncologic surgery, primarily mastectomy/lumpectomies for breast cancer. We found no publications describing the movement of ICG dye in the lymphatics of normal subjects.

After receiving IRB approval, in the third year of the grant we performed studies to determine the best dye concentration and location of injection in our normal control subjects. We started with the dye concentration recommended by the manufacturer for intra-venous dye injection of 2.5 mg/ml. As shown in Figure 1, this resulted in significant “blooming” of dye at the injection site, to the point

Figure 1: Initial studies using 250 µg per injection of 100 µl intradermally into each of the 2<sup>nd</sup> and 4<sup>th</sup> dorsal web spaces. Example of excessive dye “blooming” in hand dorsum of normal control subject 5 minutes (A) and 1 hour (B) after injections.



drainage patterns were obstructed. We tested a series of dilutions, and are now using a dose of 10ug of dye

diluted in 100 ul of saline at each injection site. After imaging injections at various sites on the dorsal and volar sides of the hand we settled on two injections at the second and fourth webspace on the dorsal side of the hand. This allows us to view the superficial and larger draining lymphatics that are close to the surface on the dorsal side of the hand, traveling laterally to the ventral side of the

forearm and to and antecubital space and the axillary lymph nodes. Again, after several pilot runs, look at dye movement up to one week later, we settled on a protocol of imaging dye at the time of injection, and then at 15 minute intervals for a minimum of one hour. Images were collected at the site of injection, the dorsum of the hand and the volar side of the wrist and forearm, the antecubital space and up to the axillary area in some patients. Table 1 shows the demographics of the thirteen subjected enrolled in the study by Sept 15, 2016. We also obtained the subjects blood pressure at the start of the study.

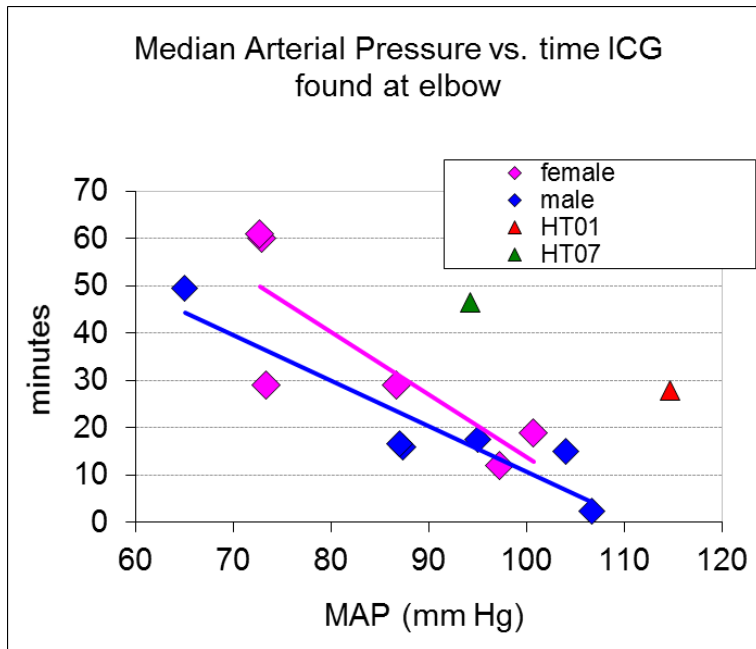
**Table 1: Normal Control Subjects enrolled in the ICG subdermal lymphatic fluorescence study**

	<b>M</b>	<b>F</b>
<b>n</b>	8	5
<b>Age</b>		
<b>Range</b>	37-64	21-54
<b>mean ± SD</b>	40.3 ± 11.1	38.6 ± 15.3
<b>BP</b>		
<b>range (S/D)</b>	95/50 -140/90	90/62 - 126/88
<b>mean</b>	118/76 (± 15/14)	108/73 (± 15/10)

The normal controls were injected and we measured the amount of time it took the dye to move from the injection site to the antecubital space (elbow). Figure 2 graphs the minutes to the elbow (Y axis) vs. the mean arterial pressure of the subjects. In addition, we are showing data from two of our hand transplant recipients. In the images, linear patterns were found in all the control individuals at the hand, forearm, medial elbow and mid arm. The ICG can be visualized around the elbow, or cubital lymph node area, in a linear pattern between 5 to 15 minutes after injection and cubital appearance occurred within 30 minutes. We also found that cubital appearance time is inversely related with the subjects mean arterial blood pressure (MAP). In general, the higher the arterial pressure, the faster the dye moves through the lymphatic vessels.

In addition to the normal controls, by September 15, 2016 we were able to perform ICG injections in

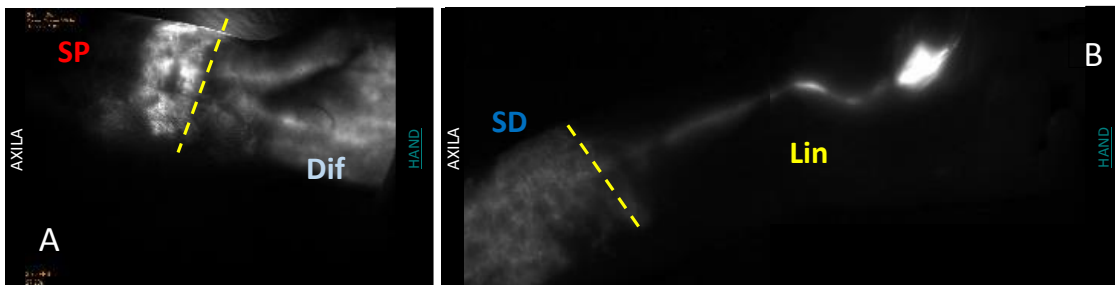
Figure 2: Speed of dye movement vs. MAP for normal controls and two hand transplant recipients Htx03 and Htx07



3 our hand transplant recipients. In the patient with chronic edema (male, 7.6 years post-transplant at mid-forearm level), the movement of ICG was mixture of stardust, linear and splash patterns within the hand that initially cleared at the wrist but then appeared at the border between graft and native tissue (Figure 4A). However, this span over the wrist showed a linear movement between site of injection and the graft/recipient border approximately 20 minutes after injection. Accumulation of ICG showed a stardust-like pattern and was on the donor side of

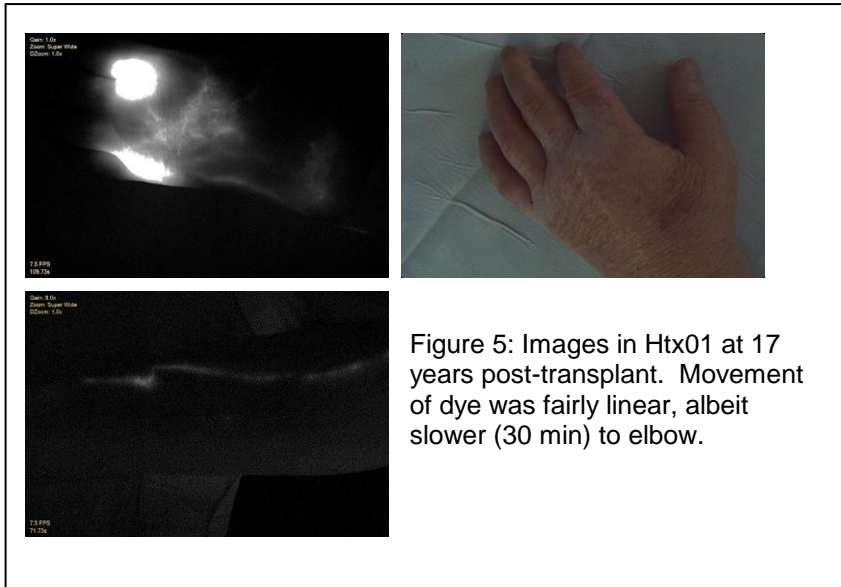
donor/recipient skin junction. This pattern suggests movement through deep lymphatic vessels (or deep venous system [commitans veins]) that came with the graft, with movement to superficial lymphatics at the transition from donor to host skin. (Figure 4A). Two other long-term VCA hand

Figure 4: ICG LUNA images of hand transplant recipients Htx03 (A) (nine years post tx) and Htx07 (B)(four years post tx). Note the linear patterns (Lin) of larger lymphatics similar to control patients, as well as stardust (SD) and splash (SP) patterns seen near the donor/recipient boarder for both recipients. Subject Htx03, who has chronic edema, demonstrates a diffuse pattern (Dif) within the graft as well. The dotted line indicates the level of the transplant as evident on at the skin level for both subjects



transplant recipients were also imaged for lymphatic drainage. Neither patient had signs of edema at the time of assessment but both exhibited mixed patterns of ICG drainage. The ICG movement occurred in a linear fashion, highlighting the lymphatic vessel between the hand and the cubital

lymph node area, similar to normal controls, on the ulnar side. The second VCA recipient imaged was a 41.5 year old, male, unilateral hand transplant at 4 years post-transplant. Immediate drainage after ICG injection was linear and in distinct packets within the graft moving toward the wrist. Initial movement was strikingly similar to controls (figure 4B). Similar to the first patient, the linear pattern of flow changed to a more superficial stardust pattern at the donor/recipient skin interface.



The third VCA recipient imaged by 9/15/16 is a 55 year old male, unilateral hand transplant, at 17 years post-transplant (Figure 5).. The ICG movement occurred in a linear fashion, highlighting the lymphatic vessel between the hand and the cubital lymph node area, similar to normal controls, on the ulnar side. Interestingly, there was a distinct right angle turn in the ICG highlighted vessel near the border between graft and

native tissue, likely indicating the path of growth that particular graft lymphatic vessel made in order to establish connection with the lymphatic vasculature of the recipient. In addition to this linear clearance pattern, ICG also exhibited a stardust pattern (SD) of accumulation in the superficial area between graft and native tissue. We will continue to collect data on these patients as well as our other patients in Year 4 of this project.

Although outside the funding of the current grant, an important part of our study is our success in enrolling and transplanting VCA recipients. We are putting significant effort into finding and screening potential candidates. To date, the majority of candidates who approach our program have failed our screening procedures. However, those programs with active clinical VCA programs understand how critical the screening process is to achieving good outcomes. Strict adherence to our inclusion and exclusion criteria are paramount to the success of this project as well.

The current working summary of potential and pending candidates for hand transplantation is as follows:

Male age 31, excellent candidate, approved for listing, waiting on workman's comp settlement. Workman's comp has denied twice in the last quarter. Patient is now seeking legal assistance to obtain Workman's compensation coverage for immunosuppression.

Male age 32, excellent candidate, family situation changed, subject still interested in transplant once family issues are more manageable.

Female age 68: Currently listed for bilateral hand transplant, 8% PRA (**Patient was transplanted on 9/17/16 and will be discussed in the first quarterly report in year 4 of the project**).

Female age 39: Cleared medically, financially and socially for transplant, but will not be listed until BMI is reduced from 43 to 34.

#### Analysis of previously collected Vevo 2100 data

In year 3 of the project we continue to collect Vevo 2100 data at protocol time points or as clinical course indicates. With the new VevoVasc software we are now acquiring 300 frames/sec vs 100 frames/sec and continue to re-analyze historical data using the new VevoVasc software. We have over 200 timepoints from hand transplant recipients, candidates and normal controls to reanalyze, most with measurements of the radial, ulnar, palmar arch and thumb and ring finger digital arteries. We will analyze with respect to intimal medial layer thickness, and intermittently compare patient and control data to determine the usefulness of lumen diameter, and vessel wall elasticity and stiffness. This data is being compiled into a manuscript evaluating vasculopathy over time that we expect to submit in the 2<sup>nd</sup> or 3<sup>rd</sup> quarter of year 4 of the project.

#### Implementation of Aperio digitalization of biopsy histology

In year 3 of the proposal we continue to scan H&E as well as slides stained for C4d of skin and tissue biopsies from our hand transplant recipients as well as experimental models on the Aperio Digital Slide Scanner. The system allows us to log on to the system and access images for sharing with our collaborators at Duke, U Penn and U Maryland. Dr. Chilton has scanned the first set of slides. Using a Leica Aperio Imaging microscope, we are now in the process of digitizing the biopsy slides from our hand transplant patients. Each slide received from the pathology lab has 2-5 serial tissue slices stained for cellular infiltrate analysis using hematoxylin and eosin dyes (H&E). Some of these tissue

sections are in better physical shape than others, therefore, the best three (if available) sections per slide are acquired as individual digital images at 40X magnification. The pathology department's slide label is used as the file name followed by "#n" where the n=the individual section being scanned from that slide. The system also compiles the following data: patient initials, date of sampling, specific tissue and location sampled (i.e left dorsal hand, skin or muscle), type of staining (thus far, only H&E), and clinical score (Banff rejection score). This information is compiled into a database and is accessed via Spectrum software on a secure server. With these images digitized and available to us, we then retrieve them and analyze and save as TIF files for sharing with the consortium. As of 9/15/16 there were over 400 clinical transplant biopsy timepoints, with multiple slides per timepoint to scan, as well as selected slides of the rat hind-limb project that are designated for scanning and sharing with the consortium members. The list below does not include the multiple pre-transplant biopsy samples taken from the donor of our 10<sup>th</sup> recipient who was transplanted on 9/17/16. The status of clinical slides scanned as of 9/15/16 is shown below:

Recip #	scanned biopsies	remaining biopsies	% finished	#scans
HTx01	19	49	27.9	95
HTx02	20	46	30.3	96
HTx03	70	36	66.0	455
HTx04	0	32	0.0	0
HTx05	14	44	24.1	94
HTx06	0	19	0.0	0
HTx07	0	30	0.0	0
HTx08	0	15	0.0	0
HTx09	0	2	0.0	0
HTx10	0	8	0	0
totals	126	281	31.0	740

## Hand transplant recipient specimen archive and immunomonitoring

In year 3 of the protocol we continued to perform flow cytometric analysis of circulating peripheral blood populations and archiving of extra cells, serum, plasma and RNA Paxgene samples on hand transplant recipients at their annual visit, and as clinical course indicates.

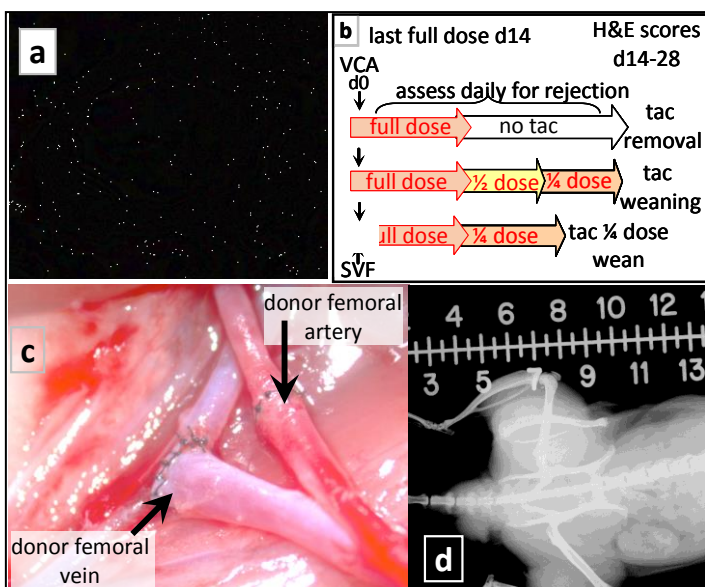
In addition to studies focused on improving and standardizing monitoring of VCA recipients in Aim 6 and 8, Aim 7 will address the hypothesis that VCA-associated macro- and microvasculopathies are due to chronic and multiple acute rejection activities, and can be exacerbated to confluent aggressive vasculopathy by non-alloimmune triggers. In year 3 of the project we performed vascular imaging assessments utilizing rodent preclinical models of VCA in experiments with defined rejection regimens. In addition, we are using vascularized composite autograft models to evaluate the effects of inflammation and antirejection medications in the absence of active rejection. The work in this Aim is guided by 3 tasks, all of which are relevant to this year 3 annual report.

**Task 1:** To perform osteomyocutaneous (hindlimb) allogeneic VCA in a rodent model

**Task 2:** To establish baseline and experimental imaging standards in rat model

**Task 3:** To perform rat transplants involving perturbations to allo-rejection

### **Task 1: To perform osteomyocutaneous (hindlimb) allogeneic VCA in rat.**

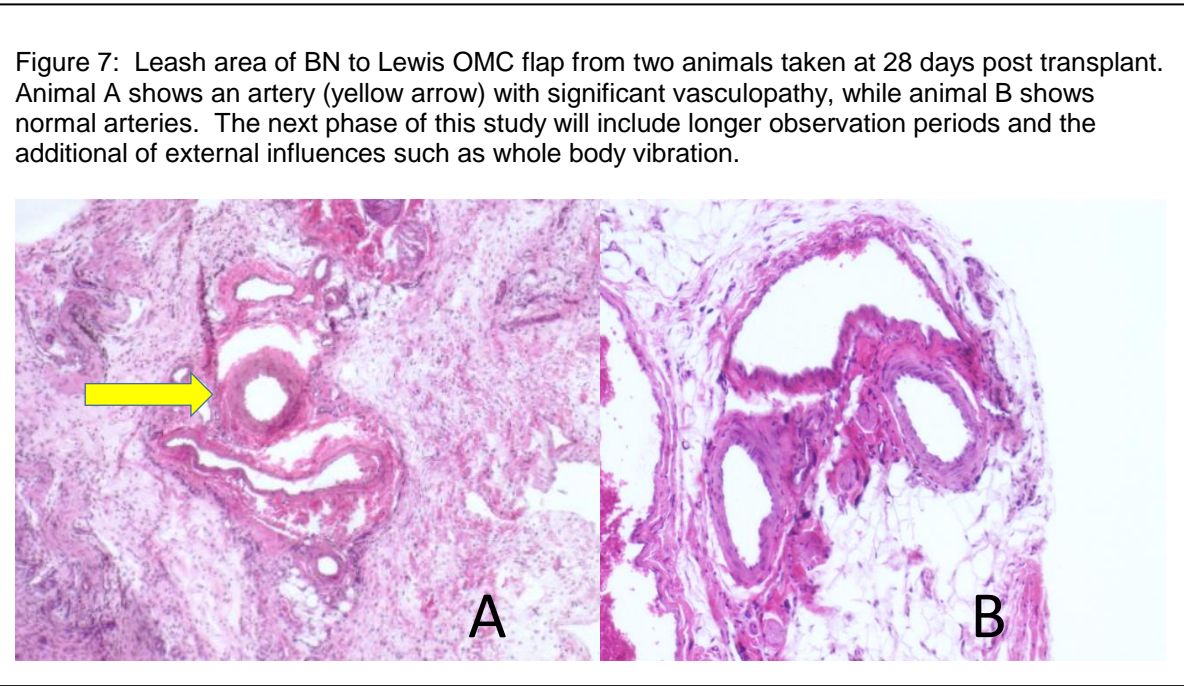


**Figure 6 OMC model in BN to Lewis Rat Model**

In the third year of the grant we have made significant progress on our rat model of VCA. In preparation of the graft, a vascular leash containing both the femoral artery/vein pair and distal iliac artery/vein regions is isolated. We are targeting our studies on vasculopathy on these vessels, as we can image them easily with the Vevo 2100. Care is taken in preparing the graft to preserve artery perforators supporting skin perfusion. The graft is transplanted in the inguinal pocket of the recipient with the distal end of the

tibia/fibula pointing anterior The femoral artery of the donor was attached to the femoral artery of the recipient via an end-end anastomosis. While the vein anastomosis involved an end (donor)-side (recipient) arrangement. We have previously reported on our progress with the model. Year 3 was interrupted when our microsurgeon left and we had to train Ms. Young to take over this responsibility.

**Task 2: To establish baseline and experimental imaging standards in rat VCA model.** We have shown that we can image and obtain Doppler flow patterns on the leash of the OMC flap shown in figure 6. In addition we have demonstrated that we can obtain intimal medial thickness readings on



our rat images. We have also previously reported on our ability to obtain ICG and Moor Laser Doppler images of blood flow in our grafts.

**Task 3: To perform rat**


transplants involving perturbations to allo-rejection

In year three, we have focused on a less aggressive form of rejection, and will be combining that with whole body vibration as a means to determine the effect of external trauma on vasculopathy. As previously described, there is a “leash” of artery and veins that supplies blood to the pedicle flap of bone muscle and skin used in our model. In year 3 of this project we identified vasculopathy of the “leash” artery by 28 days post-transplant using immunosuppression that allows significant allograft rejection. In figure 7 we show one rat with minimal vasculopathy at the end of the study (Figure 7A) compared with an animal that shows the beginning of vessel wall thickening in the artery at 28 days post transplant (Figure 7B). We have extended this model with additional, but sub-optimal immunosuppression, and for a longer time period (60 days) than the first group. Additionally we are

now collecting ultra high resolution ultrasound images of the leash at multiple timepoints, so we can correlate the onset of vasculopathy with what we image with the Vevo 2100.

Because the goal is to evaluate vasculopathies in VCA, including the consequences of rejection on vascular integrity, we employed an initial immune-suppression protocol designed to provide baseline information of vascular function during graft healing without rejection, vascular function post-healing without rejection, and vascular function with rejection. In year 3 of the study we focused on a model which gives a full dose of tacrolimus for the first two weeks, followed by maintenance on a  $\frac{1}{4}$  (0.5 mg dose). Assessment of graft health occurs during this entire time course. As shown in figure 7, we were able to demonstrate vasculopathy in some of the leashes from animals that were allowed to undergo fairly severe graft rejection. We are hypothesizing that using a model with mild to moderate rejection, we will be able to study the development of vasculopathy in the context of factors in addition to rejection. In addition to the imaging in year 3 of the project, we established a flow crossmatch to detect donor specific antibody production in our rats. Positive controls were created by immunizing rats with irradiated splenocytes. Plasma was tested from the animals that had undergone acute rejection in 28 days. We did not detect development of IgM or IgG antibodies against BN MHC antigens in a flow crossmatch assay.

In year 3 of the project we requested, and were granted permission, to purchase some equipment that would allow us to administer whole body vibration (WBV) to multiple rats at a time. This device called the Theraplate, is shown in figure 8. Stimulation motors transduce a orbital motion and vibration at known frequencies to the animal or person standing on the device. Initially we had focused on stopping immunosuppression at day 14 and allowing rejection to occur. This resulted in a very fast and strong rejection, which would not be as useful in studies of vasculopathy. After testing various doses of tacrolimus, we found a regimen of full dose (2mg/kg) followed by  $\frac{1}{4}$  dose, (0.5 mg/kg) produces a model with rejection, but with a time course over weeks, not days. We will use this model in conjunction with 20 min/day five days a week of whole body vibration, comparing 30Hz with 50Hz. We hypothesize that the 50Hz dose will routinely result in vasculopathy in the leash and other vessels of our OMC flap. Native vessels as well as transplanted vessels will be examined. The Theraplate device is 3x4 feet, and we are able to place 4 rat cages at a time on the device. However we found that rats must be trained to the



**Figure 8: TheraPlate:** We hypothesize the whole body vibration at 50 Hz will accelerate vasculopathy in an rat allogeneic OMC flap model with minimal rejection

device in order to avoid a high stress response from the rats. After some trials we developed a regimen of training the animals prior to transplantation. As shown in figure 13, the bedding was removed from the cages and replaced with a soft rubber mat that the animals could grip. Animals



were then acclimated with ten minutes sessions with vibration of the unit at 10% of maximum, followed on subsequent days with three 10 minute sessions starting with low levels of 10% of the maximum vibration, followed by 10 minutes at 20%, and then 30%. In this manner we found that animals

**Figure 9: Lewis rats being acclimatized to whole body vibration on the TheraPlate.**

responded well, and tolerated future Theraplate sessions. In this model, we are waiting a minimum of 14 days after the flap procedure to ensure adequate healing prior to exposing the animals to WBV.

**Table II : Experimental plan of vasculopathy experiments in the rat.** Groups labeled in green have been transplanted and followed.

	Group	N	Strain Comb	FK506	Vevo/LUNA imaging	Biopsy	Biopsy stains
1	Standard tx	3	Lew > Lew	2mg/kg - 12 days/ 0.5 mg/kg - 16 days**	Day 14, 28	Day 14, 28	H&E,LEC, Treg, MHC
2	strip leash	3	Lew > Lew	-	Day 14, 28	Day of euthanasi a	H&E,LEC, Treg, MHC
3	strip leash	3	Lew > Lew	-	Day 14, 28	Day 7, 14, 28	H&E,LEC, Treg, MHC
4	Standard tx	4	BN > Lew	2mg/kg - 12 days/ 0.5 mg/kg - 16 days**	Day 14, 28	Day 14, 28	H&E,LEC, Treg, MHC
5	Standard tx	4	BN > Lew	2mg/kg - 12 days/ 1 mg/kg weekdays 18 days/.75 mg/kg weekdays 30 days	Day 14, 28, 60	Day 14, 28, 60	H&E,LEC, Treg, MHC
6	Standard tx	4	BN > Lew	2mg/kg - 12 days/ 1 mg/kg weekdays 18 days/.75 mg/kg weekdays 30 days	Day 14, 28, 60	Biopsy on day of euthanasi a	H&E,LEC, Treg, MHC
7	strip leash	4	BN > Lew	2mg/kg - 12 days/ 1 mg/kg weekdays 18 days/.75 mg/kg weekdays 30 days	Day 14, 28, 60	Day 14, 28, 60	H&E,LEC, Treg, MHC
8	Theraplate vibration 30Hz****	4	BN > Lew	2mg/kg - 12 days/ 1 mg/kg weekdays 18 days/.75 mg/kg weekdays 30 days	Day 14, 28, 60	Day 14, 28, 60	H&E,LEC, Treg, MHC
9	Theraplate vibration 50Hz****	4	BN > Lew	2mg/kg - 12 days/ 1 mg/kg weekdays 18 days/.75 mg/kg weekdays 30 days	Day 14, 28, 60	Day 14, 28, 60	H&E,LEC, Treg, MHC

### **What opportunities for training and professional development has the project provided?**

Our hand surgery fellows have had the opportunity to observe our hand transplant recipients, obtain biopsies, participate in surgical planning meetings and practice sessions on cadavers in the fresh tissue lab. Additionally our fellows have gained experience using the Vevo 2100 and LUNA fluorescence angiography systems.

Importantly, we are excited by some potential collaborations between our group and the collaborating center at Philadelphia which includes Dr. Wayne Hancock and Dr. Scott Levin. In the fourth year of this grant we look forward to collaboration and getting Dr. Hancock's expertise in our rat model as well as Dr. Levin's input on our lymphatic and clinical monitoring.

### **How were the results disseminated to communities of interest?**

We have had abstracts accepted to local, national and international meetings including the Tri-state Hand Surgery meetings including the American Society of Reconstructive Microsurgery, the Banff Histology Meetings, the Chinese Orthopedic Association and the International Hand and Composite Allotransplantation Society, and the International Histology Workshop. Additionally we share our results in ongoing collaborations with many of the active VCA centers in the United States as well as our colleagues overseas.

### **What do you plan to do during the next reporting period to accomplish the goals?**

In the next quarter we plan on continuing to acquire data. Our 10<sup>th</sup> hand transplant recipient was transplanted on 9/17/16, in the first days of quarter 1 of year 4. We will follow this patient closely. . We have multiple manuscripts in preparation, including a manuscript on therapy in hand transplant recipients, monitoring of vasculopathy and chronic rejection, and characterization of donor derived T cells in the skin of VCA grafts. We also have two separate manuscripts describing the use of ICG dye in defining lymphatic function in normal controls as well as our hand transplant recipients.

### **IMPACT:**

**What was the impact on the development of the principal discipline(s) of the project?**

Our initial studies in monitoring subjects using IR-ICG techniques (using the LUNA fluorescence angiography unit) suggest that there may be a distinct difference in how the lymphatics drain in transplant recipients vs. normal controls. If we can define these differences, and determine a way to normalize or optimize drainage in transplant recipients, we expect that functional outcomes will be improved. Additionally the ability to monitor nerve function by an anatomic measurement (counting the nerve bundles) may be an important tool to gauge progress in these patients. We plan to extend these studies in the next quarter and publish our findings.

The immunomonitoring studies, especially on our patient who is exhibiting signs of chronic rejection in the skin may result in a better understanding of the immune cell populations that are associated with chronic rejection in VCA.

The Vevo 2100 studies will have significant impact on the monitoring of VCA recipients as well as any patients population suffering from vascular disease.

#### **What was the impact on other disciplines?**

While the target population of this proposal is VCA recipients, we expect that significantly larger patient populations will also benefit. Cancer patients, especially breast cancer patients will benefit from a better understanding of lymphatic drainage in the upper extremity. In addition, thousands of patients a year have traumatic severing of the digital, medial and ulnar nerves. A technique to monitor recovery would be very helpful in testing interventions to improve nerve recovery in these patients as well.

#### **What was the impact on technology transfer?**

These studies have the potential to improve utilization of both fluorescence angiography and high resolution ultrasound through novel applications to understand vessel perfusion, lymphatic drainage and recovery of nerve bundles in ligated and repaired peripheral nerves.

#### **What was the impact on society beyond science and technology?**

The goal of this proposal is to improve the quality of life of persons who receive a VCA transplant for the treatment of catastrophic tissue loss. While we are striving to measure, improve and standardize

this treatment modality, the ultimate judgment of whether the lives of these patients are restored are made by the patients and their families. If we can play some role in restoring the limbs or face of a soldier to as “normal” as possible, and allow them the best opportunity to integrate back in society, our goal will be achieved.

## **CHANGES/PROBLEMS:**

### **Changes in approach and reasons for change.**

We requested and received approval to implement whole body vibration as a means to induce vasculopathy in our rat model.

### **Actual or anticipated problems or delays and actions or plans to resolve them**

The major delay in these studies will be the accrual of VCA recipients. We cannot control the number of patients transplanted. In our clinical trial of hand transplantation (funded outside the current grant) we are aggressively screening candidates and listing them for transplantation as they are approved. The tenth transplant in Sept of 2016 is doing well and will be carefully monitored.

### **Changes that had a significant impact on expenditures**

The most significant impact on expenditures have been changes in personnel, and the approved requests to spend funds on equipment required for the proposed studies.

**Significant changes in use or care of human subjects** – None to report

**Significant changes in use or care of vertebrate animals.** – None to report

**Significant changes in use of biohazards and/or select agents** – N/A

## **PRODUCTS:**

"Nothing to Report."

### **Publications, conference papers, and presentations**

Manuscript	Kaufman CL, The Sum of the parts: Understanding how skin allografts are rejected. Transplantation 2016, 100(10)2020-2021.
Manuscript	CL. Kaufman, MR. Marvin, PM. Chilton, JB. Hoying, SK. Williams, H Tien , T Ozyurekoglu and R Ouseph. Immunobiology of VCA, Transplant International, 2016. 29(6): 644-654.
Manuscript	M Carmen Cirstea, I Choi, P Lee, H Peng, C Kaufman, and S Frey Magnetic resonance spectroscopy of current hand amputees reveals evidence for neuronal-level changes in former sensorimotor Cortex. J. Neurophysiology (accepted)
Presentation	HY Tien and C. Kaufman. Clinical Outcomes of Hand Transplantation, 10 <sup>th</sup> International Congress of the Chinese Orthopaedic Association, November 19-22, 2015, Chongqing, China
Poster	CL Kaufman, R. Ouseph , T. Ozyurekoglu, HY Tien, E. Galvis, Y Manon Matos, M. Palazzo and MR Marvin. Graft rejection in hand transplant recipients with grade 0 skin biopsy histology. October 2015 Banff-CST Joint Scientific Meeting, Vancouver, BC
Presentation	CL Kaufman, Chronic Rejection in VCA, American Society of Reconstructive Microsurgery 2016 Annual Meeting, January 16-19, 2016 Scottsdale, AZ
Presentation	CM Jones and C Kaufman. Examples of skin biopsy histology in the Louisville VCA Program, International workshop on VCA histopathology, May 21, 2016 Durham, NC

**Website(s) or other Internet site(s) – None to report**

**Technologies or techniques – None**

**Inventions, patent applications, and/or licenses – None to report**

**Other Products – None to report**

## **PARTICIPANTS & OTHER COLLABORATING ORGANIZATIONS**

### **What individuals have worked on the project?**

Provide the following information for: (1) PDs/PIs; and (2) each person who has worked at least one person month per year on the project during the reporting period, regardless of the source of compensation (a person month equals approximately 160 hours of effort). If information is unchanged from a previous submission, provide the name only and indicate "no change."

*Name:* Christina Kaufman PhD

*Project Role:* Primary Investigator

*Researcher Identifier (e.g. ORCID ID):*

*Nearest person month worked:* 12 months @ 10% effort

Dr. Kaufman has met on a consistent basis with local grant co-investigators and initiated studies on the LUNA IR/ICG unit as well as the Vevo 2100. She also oversees the day to day administration of the grant and the hand transplant protocol with the Louisville VCA Program.

*Name:* Jay Hoying PhD

*Project Role:* Co-Investigator

*Researcher Identifier (e.g. ORCID ID):*

*Nearest person month worked:* 12 months @ 8% effort

Dr. Hoying has met on a consistent basis with local grant co-investigators and obtained approval for the IACUC protocol through the U of L IRB. Dr. Hoying also initiated discussions with the JH/CHI IT department. Dr. Hoying also works with the microsurgeon on the project in performing the rat VCA flaps, and the imaging studies in the experimental model.

*Name:* Chris Jones MD

*Project Role:* Co-Investigator

*Researcher Identifier (e.g. ORCID ID):*

*Nearest person month worked:* 4 months @ 5% effort

Dr. Jones has met on a consistent basis with local grant co-investigators to discuss details of the clinical monitoring protocols.

*Name:* Michael R. Marvin MD

*Project Role:* Co-Investigator

*Researcher Identifier (e.g. ORCID ID):*

*Nearest person month worked:* 4 months @ 2% effort

Dr. Marvin has met on a consistent basis with local grant co-investigators to discuss details of the clinical monitoring protocols. Dr. Marvin accepted another position and left the Program in January of 2016.

*Name:* Tuna Ozyrekoglu MD

*Project Role:* Co-Investigator

*Researcher Identifier (e.g. ORCID ID):*

*Nearest person month worked:* 4 months @ 5% effort

Dr. Ozyrekoglu has met on a consistent basis with local grant co-investigators to discuss details of the clinical monitoring protocols. Dr. Ozyrekoglu has replaced Dr. Kutz, who retired in March of 2016, on this study.

*Name:* Stuart K. Williams PhD

*Project Role:* Co-Investigator

*Researcher Identifier (e.g. ORCID ID):*

*Nearest person month worked:* 12 months at 8% effort

Dr. Williams has met on a consistent basis with local grant co-investigators to discuss details of the clinical monitoring protocols as well as the IACUC protocols and the imaging studies in the experimental model.

*Name:* Donna Stacy RN

*Project Role:* Research Nurse

*Researcher Identifier (e.g. ORCID ID):*

*Nearest person month worked:* 12 months at 10% effort

Ms. Stacy has been working on establishing protocols and methods for IRB and working with Drs. Kaufman and Marvin on protocols and patient follow up.

*Name:* Paula Chilton PhD

*Project Role:* Research Scientist

*Researcher Identifier (e.g. ORCID ID):*

*Nearest person month worked:* 12 months at 100% effort

Dr. Chilton joined the project in June of 2015, replacing Dr. Stephen Mathis. Dr. Chilton has established several new flow cytometric assays, and assists the microsurgeon in the follow up of the transplanted rats and imaging of the animals post transplant. She is also working with Dr. Kaufman on the ICG imaging of lymphatics on the normal controls and hand transplant recipients.

*Name:* Robert Reed

*Project Role:* Technician

*Researcher Identifier (e.g. ORCID ID):*

*Nearest person month worked:* 4 months at 30% effort

Mr. Reed has been working on establishing protocols and methods for IACUC project and working with Drs. Hoying and Williams on preparation of protocols. He has established and mastered the microsurgical techniques of the rat VCA model with Dr. Hoying. Mr. Reed left the program to work with another group at the University of Louisville.

*Name:* Ashley Young

*Project Role:* Technician

*Researcher Identifier (e.g. ORCID ID):*

*Nearest person month worked:* 8 months at 100% effort

Ms Young was hired and trained to perform the rat OMC flap in the BN to Lewis model. She mastered the microsurgical techniques of the rat VCA model with Dr. Hoying, and is transplanting two animals per week as well as performing monitoring studies and administering immunosuppression and other animal husbandry duties.

**Has there been a change in the active other support of the PD/PI(s) or senior/key personnel since the last reporting period?**

No significant changes in active support other than the personnel leaving or joining the program as described above.

**What other organizations were involved as partners?**

Provide the following information for each partnership:

Organization Name: Jewish Hospital Foundation (JHF) and Jewish Hospital (Part of KentuckyOne Health)

Location of Organization: Louisville, KY

Partner's contribution to the project – JHF and JH have provided \$1.5 million in funding to cover cost of screening, transplanting and patient follow up for hand transplant recipients that are not covered by insurance.

Organization Name: Kleinert Kutz Hand Care Center

Location of Organization: Louisville, KY

Partner's contribution to the project – The Kleinert Kutz Hand Care Center supplies all of the surgeons which perform the actual hand transplants and help to follow the patients post transplant. In addition, KKHCC staff also participate in the screening of potential hand transplant candidates. The surgeons do not charge for these efforts.

**SPECIAL REPORTING REQUIREMENTS** – None to report

**APPENDICES** – None to report