

**Volumetric Changes in Edentulous Alveolar Ridge Sites Utilizing Guided Bone
Regeneration and a Custom Titanium Ridge Augmentation Matrix (CTRAM).**

by

Jared Cameron Beck, DMD
Lieutenant Commander, Dental Corps
United States Navy

A Thesis submitted to the Faculty of the
Periodontics Graduate Program
Naval Postgraduate Dental School
Uniformed Services University of the Health Sciences
in partial fulfillment of the requirements for the degree of
Master of Science
in Oral Biology

June 2016

Naval Postgraduate Dental School
Uniformed Services University of the Health
Sciences

Bethesda,
Maryland

CERTIFICATE OF APPROVAL


MASTER'S
THESIS


This is to certify that the Master's thesis of


Jared Cameron Beck


has been approved by the Examining Committee for the thesis requirement for the
Master of Science degree in Oral Biology at the June 2016 graduation.

Thesis Committee:


Peter M. Bertrand, DDS
CAPT(Ret), DC, USN, Professor, Dental Research
Thesis Supervisor


Ivan Roman, DDS, MS
CAPT, DC, USN
Chairman, NPDS Periodontics


Thu P. Getka, DDS, MS
CAPT(Ret), DC, USN



Jeffrey R. Wessel, DDS, MS
CDR, DC, USN

COPYRIGHT STATEMENT

The author hereby certifies that the use of any copyrighted material in the thesis manuscript entitled:

“Volumetric Changes in Edentulous Alveolar Ridge Sites Utilizing Guided Bone Regeneration and a Custom Titanium Ridge Augmentation Matrix (CTRAM)”

is appropriately acknowledged and, beyond brief excerpts, is with the permission of the copyright owner.

A handwritten signature in black ink, reading "Jared Cameron Beck", written over a horizontal line.

Jared Cameron Beck
Periodontics Graduate Program
Naval Postgraduate Dental School
June 2016

DISCLAIMER

The views presented here are those of the author and are not to be construed as official or reflecting the views of the Uniformed Services University of the Health Sciences, the Department of Defense or the U.S. Government.

ABSTRACT

Volumetric Changes in Edentulous Alveolar Ridge Sites Utilizing Guided Bone Regeneration and a Custom Titanium Ridge Augmentation Matrix (CTRAM).

Jared Cameron Beck, DMD
Periodontics, 2016

Thesis directed by: Peter M. Bertrand, DDS
CAPT (Ret), DC, USN
Professor
Naval Postgraduate Dental School

Introduction:

Patients with missing teeth often lack sufficient bone to receive a dental implant and require bone augmentation (grafting). This can be accomplished using a custom titanium ridge augmentation matrix (CTRAM). The matrix is designed via 3D computer aided design (CAD) software using a virtual jaw model derived from pre-surgical cone beam computerized tomography (CBCT). The matrix is then printed in titanium alloy and sterilized. The CTRAM is surgically fixated to the deficient alveolar ridge, filled with freeze-dried bone allograft (FDBA), and covered with a resorbable collagen membrane. In this prospective observational study, up to 14 patients treatment planned to receive one or more dental implants will be consented for evaluation of the clinical outcome of bone augmentation using CTRAM. The changes in their alveolar ridge dimensions will be assessed by three methods.

Methods:

First: A second CBCT will be taken 7 months following CTRAM placement and bone grafting. Using 3D modeling, the second CBCT accounts for change in jaw morphology afforded by grafting, allows precise implant placement at approximately 8 months, and comparison to the pre-surgical CBCT to quantify volumetric change. Second: Periodontal probe measurements to the alveolar ridge below the CTRAM will be recorded: 1) At initial fixation, and 2) at 8 months (prior to CTRAM removal and implant placement) for comparison. Third: Impressions will be made of the alveolar ridge before CTRAM placement, at 2-4 weeks and 4 months following implant placement. Stone models will be digitally scanned and compared using computer software to assess dimensional alveolar ridge changes.

Conclusion:

It is anticipated that the measurements recorded from the CBCT and stone model scans will correlate with the clinical measurements to demonstrate complete bone fill utilizing the CTRAM ridge augmentation technique. The data from this IRB approved study may show that CTRAM predictably produces complete ridge regeneration, such that a second post-graft CBCT may not be necessary when implant therapy is planned.

TABLE OF CONTENTS

	Page
LIST OF FIGURES	vi
LIST OF ABBREVIATIONS.....	vii
CHAPTER	
I. INTRODUCTION	1
II. REVIEW OF THE LITERATURE	4
III. MATERIALS AND METHODS	20
IV. CONCLUSION	29
APPENDIX	
A. CTRAM PROSPECTIVE STUDY FLOW CHART	32
B. PERIODONTAL SURGICAL PROCEDURES	33
C. ONE PAGE STUDY BRIEF	38
D. PERIODONTAL PROBE MEASUREMENT MAP	40
E. DATA COLLECTION SHEETS	41
REFERENCES	45

LIST OF FIGURES

Figure	Page
1. Deficient alveolar ridge.....	2
1A. Flap elevated.....	2
1B. CTRAM fixated.....	2
1C. Graft placed.....	2
1D. Resorbable membrane placed.....	2
1E. Flap sutured.....	2
1F. CTRAM removed.....	3
1G. Implant.....	3
2. Implant on deficient ridge.....	4
3. Purulence due to peri-implantitis.....	5
4. CBCT slice of deficient ridge.....	17
5. CBCT slice after CTRAM with bone.....	17
6. Custom titanium matrix.....	17
7. Periodontal Probing.....	22
8. Probe measurement.....	22
9. Digital scan of stone model.....	24

LIST OF ABBREVIATIONS

AAOMR	American Academy of Oral and Maxillofacial Radiology
CAD	Computer Aided Design
CAM	Computer Aided Milling
CBCT	Cone Beam Computed Tomography
CT	Computed Tomography
CTRAM	Custom Titanium Ridge Augmentation Matrix
DMLS	Direct Metal Laser Sintering
EBM	Electron Beam Melting
EMD	Enamel Matrix Derivative
e-PTFE	Expanded Polytetrafluoroethylene
FDDBA	Freeze-Dried Bone Allograft
GBR	Guided Bone Regeneration
mg	Milligram
mm	Millimeter
NSAIDS	Non-steroidal Anti-Inflammatory Drugs
PACS	Picture Archiving and Communication System
q6h	Every 6 Hours
q8h	Every 8 Hours
stl	Stereolithography
TBSP	Tablespoon
WRNMMC	Walter Reed National Medical Military Center

CHAPTER I: INTRODUCTION

Bone grafting at the time of tooth extraction helps prevent alveolar ridge atrophy. In its absence, ridge deficiency is likely and can be problematic when a fixed restorative option, afforded by a dental implant, is eventually desired. Bone grafting using a fixed, rigid material that will maintain space to stabilize the bone graft placed at the edentulous site is desired for a predictable augmentation outcome.

Off the shelf titanium mesh (or matrix) is not a new technique and has been used to achieve good clinical results in horizontal, and in some cases, vertical bone growth (Louis, 2008).

The downsides to commercial titanium mesh are (Jensen, 2014; Louis 2008):

1. The time required to trim the material increases duration of surgery.
2. Potentially sharp points on the trimmed mesh may protrude the tissue flap.
3. The inability to precisely form fit the mesh to create ideal bone contours.

Now computer aided design (CAD) and 3D modeling allow fabrication of a thin custom titanium ridge augmentation matrix (CTRAM) that defines ideal ridge dimension, reduces the surgical time to fixate the mesh, enables easy placement of particulate freeze-dried bone allograft (FDBA), and appears to achieve ideal restoration of lost jaw bone. The CTRAM approach eliminates harvesting autogenous bone causing an additional surgical site, and negates the need to resort to block grafts that are prone to significant resorption during healing.

Figure 1 shows how the loss of the molar teeth results in a deficient alveolar ridge. Figure 1A reveals the patient's ridge after a surgical flap has been reflected. Figure 1B depicts the CTRAM fixated to the ridge and the periodontal probe illustrates at one point, the

difference between what is considered ideal bone dimension (determined by 3D technology that enables design and printing of the custom mesh) and the patient's clinical condition. In Figure 1C particulate FDBA has been placed into the space provided by the CTRAM. The round openings are then covered by a resorbable membrane as shown in Figure 1D. The flap is then sutured (tension free) to completely cover the CTRAM (Figure 1E). Figure 1F depicts the ideal dimension of the restored bone at 8 months when the CTRAM was removed and the implant was placed, as shown in Figure 1G. These results appear ideal but quantification of bone gain with this procedure needs to be documented.

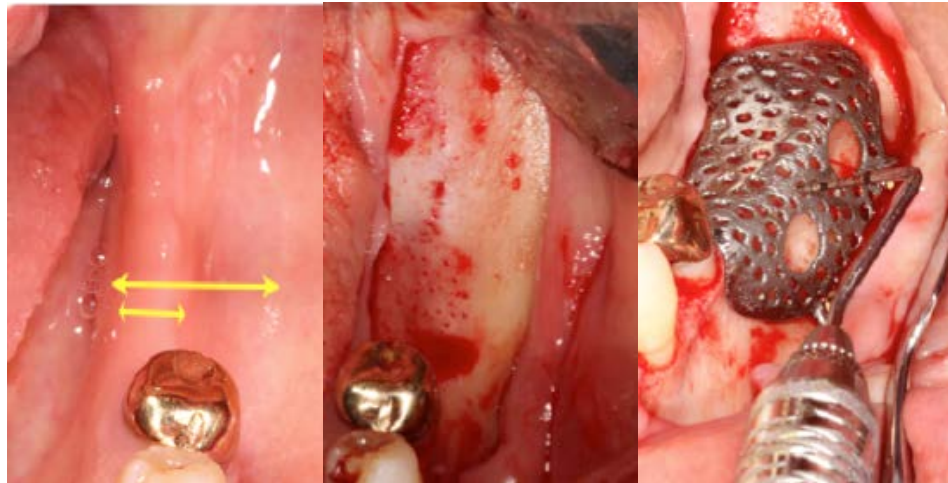


Figure 1

Figure 1A

Figure 1B

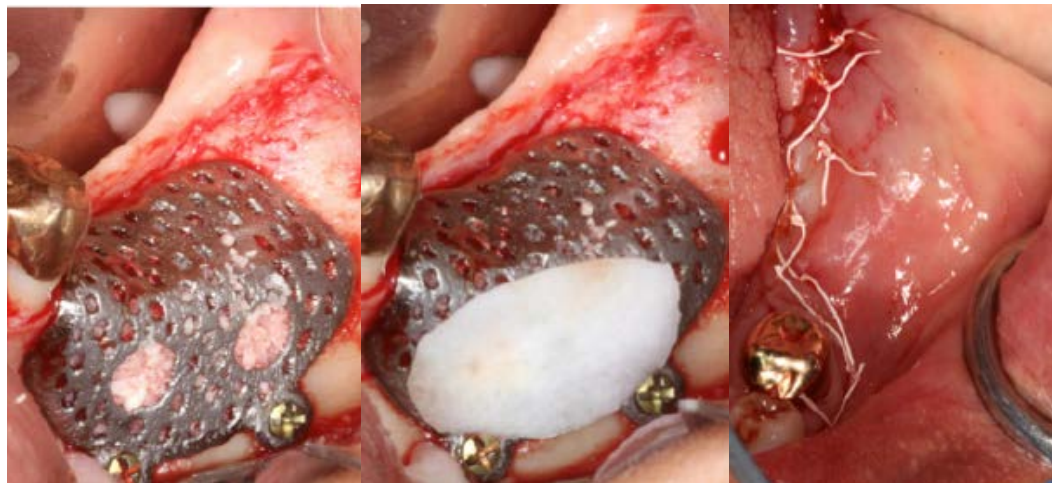


Figure 1C

Figure 1D

Figure 1E

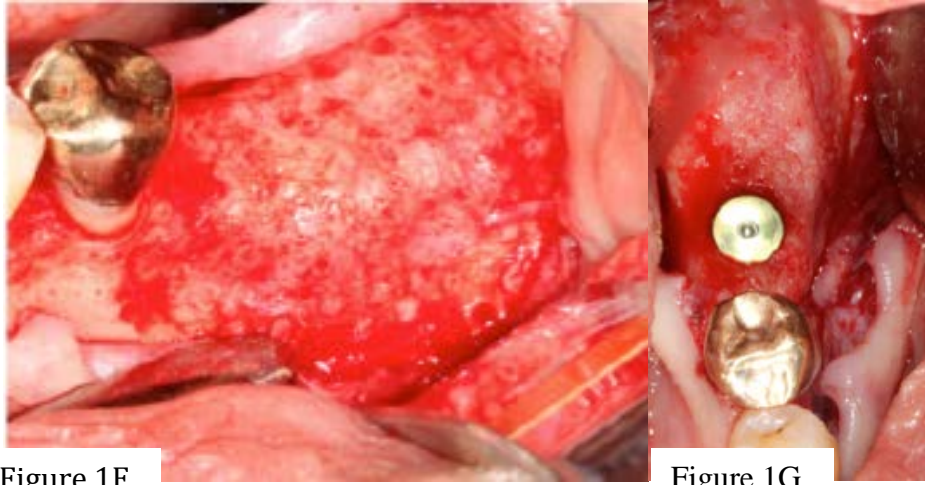


Figure 1F

Figure 1G

At this time no studies have reported the volumetric change gained when utilizing a custom titanium matrix (CTRAM) with bone grafting to augment an edentulous ridge for dental implant placement.

The observed, non-quantified, results for ridge augmentation provided with CTRAM appear to completely restore deficient ridges to ideal dimension. Additionally, if the data in this prospective study indeed show predictable complete augmentation then it may be feasible to consider eliminating a second CBCT recommended by the American Academy of Oral and Maxillofacial Radiology (AAOMR) to assess success of regeneration (Tyndall, 2012).

CHAPTER II: REVIEW OF THE LITERATURE

Successful restoration of dental function and health in an edentulous area utilizing dental implants requires several considerations. Of major importance is adequate width and height of alveolar bone for implant placement. A study of forty-six patients (Schropp, 2003) utilizing linear and subtraction radiography techniques, along with stone models found once a tooth is extracted, the height and width of the alveolar bone is reduced. Their findings quantified the loss to be approximately 50% of the width of the alveolar ridge after one year—two thirds of which was lost in the first three months. Figure 1 (Introduction section) illustrates how thin the alveolar ridge becomes after teeth are extracted. The solid line shows the width of the alveolar crest while the dashed line approximates the width prior to molar extraction. Without intervention at the time of extraction, a large portion of the bone that retained the tooth will atrophy following tooth extraction.

If a patient desires a restoration utilizing an implant, a significant reduction in the volume of bone at the site intended for implant placement creates a surgical dilemma. If an

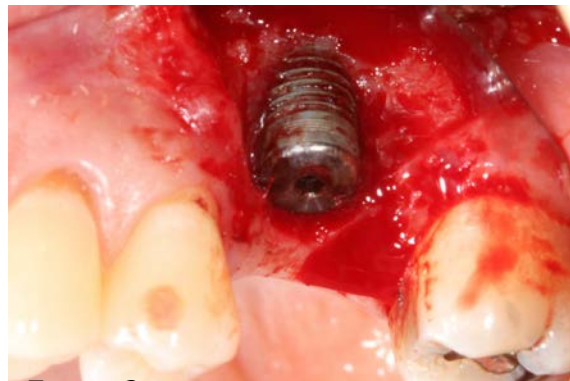


Figure 2

implant is placed at a location deficient in bone, then implant threads, as shown in Figure 2, likely will not be covered by bone. These threads provide a niche that is very difficult to clean, and allows bacterial plaque retention that can lead to localized infection and bone loss around an implant called peri-implantitis (AAP Position Paper, 2013).

Figure 3 shows the implant in Figure 2 before flap reflection and depicts peri-implantitis. Purulence is evident as it exudes through the gingiva surrounding an implant.

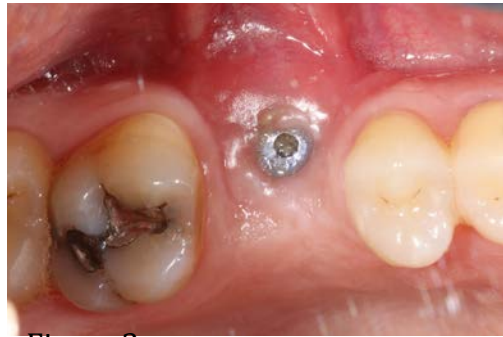

Figure 3

A bone graft procedure to maximize alveolar ridge dimension would have reduced the potential for incomplete coverage of the implant threads with bone. Such a surgical result threatens long-term stability of the implant, and indicates that augmentation of the alveolar bone prior to implant placement would be preferred.

Evidence that alveolar bone resorbs following extraction of teeth, raises the question of how best to preserve alveolar bone—or regenerate bone that has been lost over time at the location where the tooth or teeth were removed. Maintaining alveolar ridge dimension after extraction or augmenting bone in clinical presentations, as in Figure 1 and Figure 2, is necessary to insure healthy long-term restoration with dental implants.

Guided Bone Regeneration

According to the AAP Glossary of Terms (2001), Guided Bone Regeneration (GBR) refers to augmenting lost jaw bone using a bone graft, covered by a barrier membrane, which aims to exclude epithelial cells and gingival fibroblasts from invading the location where bone augmentation is targeted. Exclusion of epithelial cells and gingival fibroblasts provides slower growing bone cells a better opportunity to differentiate into mature bone. The concept of GBR was introduced in 1959 (Hurley,

1959) using occlusive membranes to cover bone grafts during spinal fusion procedures on dogs. Buser (1993) developed a surgical technique to augment jaw bone employing a fixated membrane to achieve GBR. The authors describe a staged approach to ridge augmentation where the site was left to heal over approximately nine months. After the nine months passed, the membrane and fixation screws were removed and implants were then placed in the area of regenerated bone. Four critical principles were stated in the article to ensure GBR technique success: 1) obtain primary closure of the tissue flap, 2) utilize a barrier membrane to prevent epithelial and gingival cell migration into the graft site, 3) stabilize the membrane, and 4) maintain space under the membrane for bone regeneration. McAllister (2007) discussed the four concepts related to GBR success, the use of resorbable and non-resorbable membranes, as well as with available bone graft materials which are explained in further detail in the “Membranes” and “Bone Graft Materials” sections to follow.

Membranes

Resorbable membranes are derived from sources such as bovine or porcine collagen, human amnion chorion, or synthetic polymers which resorb over time beneath the tissue flap and therefore do not require removal. However, if exposed to the oral cavity, they rapidly degrade and the exposure may compromise bone regeneration even though tissue generally heals over the exposed area quickly. These membranes are often used in combination with a bone graft material to maintain the desired space. Another potential problem with resorbable membranes is their potential to collapse or move at the bone graft site—resulting in a loss of space reducing the amount of new bone that can be formed.

Non-resorbable membranes are traditionally made from an expanded-polytetrafluoroethylene (e-PTFE) material and are completely occlusive to invasion by epithelial cells. If they maintain the intended bone graft space, the underlying blood clot remains undisturbed—creating an environment that allows initial immature woven bone to be subsequently replaced by lamellar bone during the bone healing/remodeling process. To ensure space preservation at the graft site these membranes are sometimes reinforced with titanium. However, titanium reinforced membranes may induce perforations of tissue flap that expose the graft site to the oral environment which can compromise the healing process.

Bone Graft Materials

Several sources of bone material are available for grafting. They are: 1) Autografts (one's own bone), 2) allografts (from another human), 3) alloplasts (synthetic material) and 4) xenografts (from another species).

Autograft bone is harvested from the patient from areas such as the iliac crest, mandibular ramus, mandibular symphysis and from tori or an exostosis. Since the donor site is a second surgical site, autografts are associated with the possibility of an increased level of morbidity and recovery time for the patient. Additionally, since there may be a limited amount of bone that can be harvested from the donor site, autografts may not provide sufficient bone for GBR.

Allograft material is human bone from a source other than the patient. It has been used for decades in dental and orthopedic surgery, both in small particle or block form. In dentistry, allograft bone is used to regenerate bone in periodontal defects around teeth,

preserve bone dimensions at dental extraction sites and augment deficient alveolar ridges. As opposed to autogenous bone, allograft bone is available in essentially limitless quantities and eliminates the need for a second surgical site for harvesting.

Two main forms of particulate allograft are currently utilized in GBR: Freeze-Dried Bone Allograft (FDBA) and Demineralized Freeze Dried Bone Allograft (DFDBA). These have been shown to have similar results when used with augmentation for implant site development. In a study of 72 FDBA grafted sites and 21 DFDBA grafted sites in 93 patients receiving ridge augmentation, the mean percentages of new bone formed were 41.89% for FDBA and 41.74% for DFDBA (Cammack, 2005). A statistical difference between the two graft materials was not found regardless of where the graft was used in this particular study. A different study suggested that dental implants placed and loaded in bone regenerated from DFDBA, FDBA or autogenous sources had success rates similar to “native” bone. A total of 526 implants were placed in 352 patients who were followed from six to seventy-four months. Only 8 implants (all in the maxilla) were lost, yielding a 97.5% implant survival rate (Nevins, 1998).

Block autografts and allografts have also been used to augment deficient alveolar ridges. As mentioned previously, autogenous blocks require a second surgical site to harvest the graft and are associated with some morbidity including the potential for traumatization or de-vitalization of adjacent nerves. Resorption of block grafts after placement is also a concern that several studies have assessed.

Fifty block autografts from human symphysis or ramus locations were followed through a 4-6 month healing time end point. Although a 100% survival rate was achieved, resorption of these autograft blocks ranged from 0 - 25% (Misch, 1997).

Keith (2004) studied mineralized block allografts in partially edentulous patients. No resorption was observed in 69% (52/75) of subjects and 0.5 - 2.0 mm of localized resorption around block fixation screws or around the blocks themselves occurred in 31% (23/75) of subjects. In a case report, freeze-dried cancellous block allografts covered by a membrane were placed at five deficient sites that were re-entered after 6 months healing time. A gain of 2.0 - 4.0 mm in ridge width was achieved with these grafts however, despite the increase in ridge width, 1.0 - 2.0 mm of surface resorption was recorded at three of the five grafted areas (Lyford, 2003). These studies point to the fact that autogenous or allograft blocks can increase width of deficient ridges but are prone to resorption, which can affect the predictability of the bone augmentation and ultimately implant placement.

Synthetic graft materials known as alloplasts have been utilized in augmentation for over 100 years. Calcium phosphate and calcium sulfate are compounds that have shown some biologic success in regard to biocompatibility and additionally are readily available in regard to supply and cost. However, because alloplasts are not completely remodeled into natural bone, they are less suitable for future implant placement.

Xenograft materials have been implemented in association with GBR techniques for many years. These materials may come from equine or bovine sources and have been noted to be quite effective in space maintenance at the graft site due to a long resorptive and remodeling period. They have been heavily utilized in sinus augmentation procedures where they maintain the desired space for implant placement. Wallace (1996) reported that after taking histologic samples of sinuses grafted with xenograft (80%) and autogenous bone (20%), a 12 - 20 month period was needed in order to see the graft

remodel to “vital bone”.

Membranes, as stated earlier, have been utilized to contain the bone material at the grafted site, exclude epithelial cell and gingival fibroblast migration into the graft site and attempt to maintain the space necessary for the graft to remain undisturbed.

Resorbable and non-resorbable membranes are currently used in a number of regenerative periodontal procedures. A potential problem with a flexible membrane is the potential for collapse. This loss of space over the course of regeneration directly affects the amount of new bone that can be formed, and has prompted efforts to develop membranes which are better able to maintain space.

Titanium Mesh in Cranioplasty

Neurosurgeons have employed titanium mesh or plates as biocompatible space maintainers following cranioplasty. Gundeslioglu (2013) submitted a case report of a 58-year-old patient who had a titanium mesh cranial implant, which became exposed, shortly after placement. Eight years later the patient presented for treatment due to odor and “discharge” from the area. When the titanium mesh implant was removed, significant osteogenesis had occurred underneath the mesh and had dramatically decreased the bone defect in the skull. Pathological analysis revealed that the odor and discharge were due to chronic inflammatory responses attributed to “reactions against the inverted scalp” and not the titanium mesh material. This report demonstrates the biocompatibility of titanium even in the event of exposure.

Wiggins (2013) examined the results of custom titanium mesh or plates used in cranioplasty over a 14-year period. Eighteen of 113 patients (16%) developed infections

that occurred approximately 120 days after placement. It was found that “the only variable that significantly influenced the risk of infection was the size of the titanium cranioplasty.” The authors noted that most infections stemmed from either exposure to microbes (mainly *S. aureus*) in a hospital environment, or from problems related to residual effects of previous infections associated with flap procedures that had failed. The larger the original cranial defects exposed to the open environment, the higher the incidence of infection.

Titanium Mesh in Dental Surgery

Titanium mesh has been used in dental surgery to overcome flexible membrane deformation (collapse) and create solid structural support that allows optimal space maintenance and stabilization for bone growth. Titanium mesh ridge augmentation was outlined in a case report (Sumi, 2000). Bone defects were measured and the titanium mesh was trimmed by hand. Autogenous bone grafts were placed to fill approximately 50% of the space between the mesh and crestal bone. Corticotomies (small holes through the cortical plate) were made at the recipient site to allow blood vessels to grow into the graft from medullary bone. The mesh was fixated into place with screws and primary closure was achieved. Six to nine months later, the mesh and screws were removed and a 3.5 mm mean gain in alveolar crest width was recorded. Implants in all three patients were stable at 6 - 18 months following placement.

Von Arx (1998) assessed the clinical outcome of 10 dental implants placed in 6 patients who needed autogenous bone harvested from the symphysis or ramus, and grafted over the implants at the time of implant placement. Despite pre-surgical CT

scans to assess bone morphology, these surgical sites had deficient alveolar ridges that caused implant surface exposures (4-10 mm) upon implant placement. After the implants were placed, titanium mesh was adapted over the exposed implant threads and bone defect to contain the autogenous bone graft and fixated with screws for stability. During 6 - 9 months of healing, no complications—including mesh exposures, were reported. The mesh and screws were retrieved and all sites were found to have >90% of the grafted bone remaining over the implants.

Alveolar ridge defects were treated using titanium mesh in a prospective study (Pieri, 2008). Sixteen subjects with 19 alveolar ridge bony defects were treated. Commercially available titanium mesh was trimmed and fixated over the graft composed of autogenous and bovine bone. Of the 19 sites treated, 18 (94.7%) had uneventful healing. One site had a mesh exposure at 2 months. The mesh exposure, however, did not interfere with subsequent implant placement. After 8 - 9 months, the mesh at all sites was removed and 44 implants were placed. Post healing CT imaging was compared to a baseline scan and revealed a 3.71 mm average gain in vertical bone growth and 4.16 mm mean horizontal gain. Following 2 years of functional loading, all implants were retained. A 93.2% success rate and a 100% survival rate were observed. Success was determined by absence of pain, suppuration, radiolucency, mobility and bone loss <1.5 mm within one year, and <0.2 mm each subsequent year (Albrektsson, 1986). Survival was defined as the absence of pain, suppuration, radiolucency and mobility with the additional criteria that implants demonstrated bone loss that exceeded the parameters designated for success.

A review of six articles by Ricci (2013) assessed 79 patients who received 82 titanium grids (meshes) and bone grafts for various alveolar bone deficiencies. Eighteen patients (22.78%) had grid exposures between 5 and 12 weeks after surgery and 9 patients required grid removal. Following 4 - 10 months of bone graft healing time, and despite the aforementioned findings, 141 implants were placed in the 79 patients. All 141 implants survived. Success and survival were determined according to similar criterion used by Pieri (2008). The overall success rate of bone grafting utilizing titanium grids was greater than 98%. Only one site out of the 82 grids had complete loss of the graft resulting in bone graft failure rate of 1.21%.

Louis (2008) retrospectively studied titanium mesh ridge augmentation in 44 patients who underwent maxillary or mandibular rehabilitation. Findings after 7 months of healing showed a 97.7% bone grafting success rate that allowed placement of 174 implants. Twenty-three patients (52%) experienced some degree of mesh exposure. Seven patients had exposures related to localized infection that required mesh removal. However, the authors stated that sharp mesh edges created by trimming the mesh to fit the defects might have contributed more to the large incidence of mesh exposure than did infection. After 17 months of follow up, only one patient lost implants (3 total) due to local infection.

Another retrospective study (Her, 2012) evaluated 26 patients for complications associated with titanium mesh used for ridge augmentation by bone grafting. Twenty-seven sites were treated with titanium mesh and various bone grafting materials. At these sites, 69 implants were placed after 4 - 11 months of bone graft healing time. A 26% mesh exposure rate (7 sites) was reported. Mesh exposures were treated by smoothing

the protruding surface with a diamond bur and healing of these sites ensued within a few weeks. No mesh required removal, and only slight resorption of grafted bone seemed to occur at exposed areas. The mesh exposures did not prevent implant placement.

Titanium mesh has been demonstrated to be a biocompatible material that preserves needed space for alveolar ridge bone regeneration. A disadvantage to using commercially prefabricated titanium mesh is the time required during surgery to manually cut the material and adapt it to the graft site. Additionally, regardless of the ability of the surgeon to shape the mesh to the site, there will always be some areas where the interface between the mesh and bone will be less than ideal. There is also potential for sharp edges that may irritate the soft tissue flap.

Customizing Titanium Mesh Using 3D Technology

Joffe (1999) reported findings using 3D generated images from CT to fabricate titanium plates for 148 patients undergoing cranioplasty for skull injuries. Ninety-seven percent of the fabricated plates “fit passively over the defect” or had the border of the plate within 2 mm of the bone margin. The authors also noted that 96% of cases only required 30 minutes to fixate. In 57% of patients no symptoms were reported post operatively, while 31% reported mild headache, dizziness or pain. Significant discomfort (7%), localized pain (2.5%) and severe headaches (2.5%) were reported by the remaining 12% of patients. Only one case involved the removal of a plate due to infection. Computer-aided design/computer-aided manufacturing (CAD/CAM) of customized titanium plates in the treatment of skull defects was efficacious, demonstrated a high level of precision, reduced operative time (as the plates did not need to be adapted by

hand to the site) and resulted in minimal post-operative symptoms. Titanium was also shown to lower the rate of infection versus other materials, such as acrylic, where infection rate has been reported as high as 10%.

In an article by Hou (2011), seven patients had CT's of bilateral mandibular defects. These were reconstructed with the aid of CAD/CAM rapid prototyping using the CT information to fabricate pre-operative 3D jaw models upon which commercial, off the shelf, 0.5 mm thick titanium mesh frameworks were manually adapted. No complications were reported for these 7 patients who were followed from 11 months to 3 years. This combination of CT and CAD/CAM technologies allowed for reduced intraoperative time required and improved the accuracy of mesh placement.

A case report by Ciocca (2011) showed how the integration of CT and CAD/CAM data could be used by Direct Metal Laser Sintering (DMLS) to create custom titanium mesh to reconstruct a deficient maxillary alveolar anterior ridge. A pre-operative CT was taken of the patient and linked with implant planning software to calculate placement parameters and volume of required bone. The mesh was designed with a 0.6 mm thickness and square 1.0 mm pores. Using titanium alloy (Ti6AlV4), DMLS created the customized grid. A 3D resin model was produced and a trial fit was conducted to verify satisfactory adaptation. The mesh was sterilized. Particulate bone graft material was placed within the mesh, and then the mesh was implanted at the site. No fixation screws were utilized, as the mesh was reportedly non-mobile via bony undercuts. A CT was taken after 8 months when the mesh was removed. A mean increase of 2.57 mm in bone height and 3.41 mm in width was reported, allowing for placement of four pre-planned dental implants.

In a report by Jensen (2014), Electron Beam Melting (EBM) by Arcam™ was used in conjunction with CT imaging and CAD technology to fabricate a titanium “shell” that outlined the desired shape and volume of bone for augmentation of a mandibular anterior deficient ridge. The design of the titanium “shell” was packaged as a stereolithography (stl) file, which could then be sent to the EBM for printing. The EBM melts titanium powder alloy (Ti6Al4V) to produce a mesh one layer at a time—precisely following the CT and CAD image data. In this study the titanium printed thickness was 0.8 mm with 1 mm diameter pores spaced at approximately 0.3 mm apart. No outcome data was reported—however, a transverse CT image after titanium shell placement was included in the paper. This method of ridge augmentation showed high accuracy, stability, and shorter procedure time with greater ease. Disadvantages included cost and limited access to the expertise needed to produce a printed titanium mesh. Unlike the use of resorbable membranes used in bone augmentation, titanium mesh is removed after graft maturation when the alveolar ridge is prepared for surgical implant placement.

Custom Titanium Ridge Augmentation Matrix (CTRAM) at NPDS

CBCT imaging imparts less radiation dose than CT (White and Pharoah, 2009) and is recommended by the American Academy of Oral and Maxillofacial Radiology (AAOMR) as the method of choice for cross-sectional imaging in that it provides the greatest diagnostic yield at an acceptable radiation dose risk (Tyndall, 2012). A CBCT scan is standard pre-surgical clinical procedure used to assess jaw dimensions and plan implant placement. It is also recommended by the AAOMR to use CBCT to assess the success of bone augmentation procedures aimed at increasing jaw bone dimension prior to implant placement (Tyndall, 2012). CBCT helps avoid impingement on nerve and

vascular pathways and enables positioning of the implant in the most functional and bone supported location.

Recently, NPDS clinicians (Connors, 2016) have improved the fit of titanium mesh and reduced intraoperative time by utilizing information digitally obtained from CBCT scans (stl files) to produce a CTRAM. Figure 4 is a 0.18 mm thick slice from a patient's CBCT that shows there is insufficient bone to hold

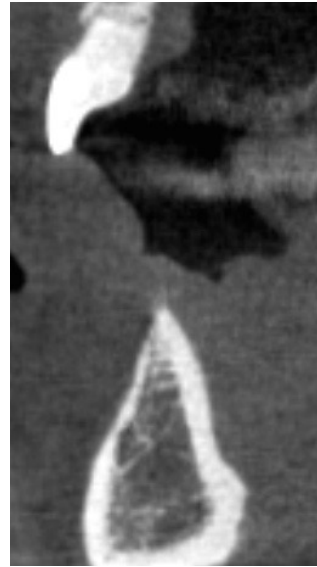

Figure 4

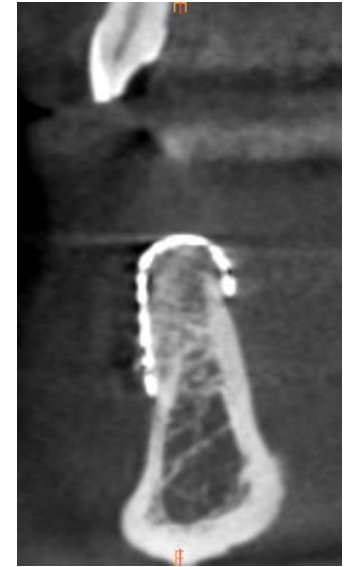

Figure 5

an implant. Figure 5 shows the bone fill beneath the fixated CTRAM at 7 months following CTRAM fixation and bone graft placement. The image suggests restoration of most of the original width and height of alveolar bone prior to loss of the lower front tooth.

Using the CBCT information with CAD/CAM capabilities allows practitioners to pre-surgically create a precise virtual model of the jaw upon which ideal bone dimension can be established. Then the thin, exact fitting CTRAM can be fabricated. Figure 6, shows the virtual jaw model created from the pre-surgical CBCT

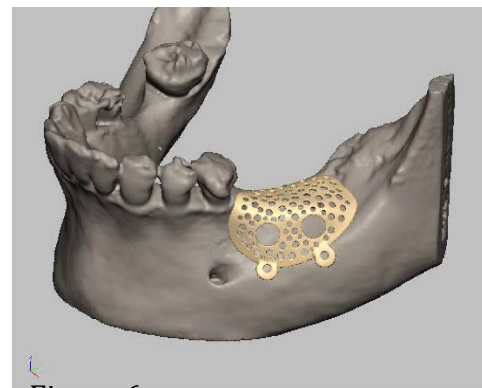


Figure 6

and the designed CTRAM for clinical use. An EBM machine by Arcam™ then prints the actual CTRAM that is used by clinicians at NPDS.

This combination of CT imaging and CAD/CAM technology to create CTRAM from virtual 3D models of the jaw provides many advantages when augmenting deficient alveolar ridges with bone grafting. When dental implants are desired but the jaw site has an alveolar bone defect, this technology allows for precise pre-surgical planning that allows ideal restoration of the patient's defect. This technology enables 1) determination of the ideal amount of required bone for ridge augmentation for implants, 2) reduction of intraoperative time, and 3) application of the critical principle of rigid space maintenance. To date, quantification of the change in bone volume at deficient alveolar ridges accomplished by bone grafting using this technology has not been reported.

Assessing Volumetric Change Using Digital Scanning

One method that can assess volumetric change utilizes a digital scanner to acquire images. This method is non-invasive and patients are not exposed to radiation. Presently, digital intraoral scans of jaws and teeth are directly used in dental offices and dental laboratories to fabricate crowns and other fixed prosthetic restorations for patients. Akyalcin (2013) demonstrated the accuracy of this technology in comparing changes in volume over time using a Cadent iTero™ scanner to scan 60 dry skulls and converted the images into stl files. These stl files were used to compare digital scanning measurements of three teeth in each arch to measurements made via CBCT images and hand held calipers. Teeth were measured in three dimensions—apical-coronal, mesio-distal and bucco-lingual. Intra-class correlation analysis (ICC) was conducted for the three

measurement techniques. Caliper measurements versus a digital intraoral scanner yielded high ICC values ranging from 0.92-0.99. CBCT compared with calipers yielded ICC values ranging from 0.88 to 0.98. A mean difference of 0.16 mm was found between the caliper method versus digital scanner and a 0.28 mm difference between caliper and CBCT. This study demonstrates the high level of accuracy that can be achieved using digital capture methods for documenting the dimensions of intra-oral anatomy.

Rebele (2014) recently demonstrated the ability to document changes in the volume of soft tissue with a digital scanning device. Six patients, from a pool of 24 study participants, were followed for 12 months after receiving root coverage flap surgery. Digital scans using the Imetric D103™ scanner were made on dental stone models obtained from impressions of the treated sites at baseline, 1, 2, 3, 6 and 12 months post-operatively. The digital images were superimposed (registered) on one another by orienting images to a specific site on the buccal surface of treated teeth. This registration allowed quantification of tissue volume changes. Volume in mm³ was converted into a percentage for convenience in comparing changes over time. Digital measurement of volume change over time permits precise comparisons between the original and augmented sites.

CHAPTER III: MATERIALS AND METHODS

This will be a prospective pilot study of 14 subjects to document the volumetric changes in the alveolar ridge which occur when utilizing the CTRAM technique for guided bone regeneration. Bone dimension, using different techniques, will be assessed at 1) baseline, 2) at 7 and 8 months post bone grafting with CTRAM and 3) at 2 - 4 weeks and 4 months post implant placement.

The study's flow chart, titled "CTRAM Prospective Study Flow Chart" (Appendix A), outlines how procedures (marked by superscript numbers) for research measurement are sequenced within the normal clinical and laboratory procedures for treatment of deficient alveolar ridges using CTRAM. The superscript numbers are indicated in the specific aims below.

Specific Aim 1

Compare stereolithography (stl) files of the pre-surgical CBCT¹ of the deficient alveolar ridge with a) the virtual jaw model to show how much added bone is ideal, and b) with the post-bone graft CBCT⁵ at 7 months to determine actual volumetric gain. Differences between ideal bone and actual bone gain will be recorded in cubic mm.

- Additionally, stl files will be used to compare location of the CTRAM on the virtual jaw model to its actual location after fixation to the jaw.

Specific Aim 2

Measure bone fill achieved by CTRAM by comparing periodontal probe measurements to the bone under CTRAM at baseline before bone grafting and

at 8 months:

- At CTRAM design on the virtual jaw model, a digital image of the CTRAM design (Appendix D: “Periodontal Probe Measurement Map”) will be made that designates exactly which pores (small openings) and windows (large openings) investigators will measure space below the CTRAM just before bone grafting and 8 months later.
 - At the two large windows, ridge width measurements will be made at the noon, 3, 6 and 9 o’clock positions.
 - Please note: Since the CTRAM is custom made, each participant’s mapping that designates which windows and pores will be used for measurement with the periodontal probe will also be unique. Each data collection sheet (Appendix E) for probing bone levels will reflect the custom nature of each CTRAM design.
- Measure space under CTRAM after fixation using marked windows on buccal surface (horizontal)³ and pores on ridge crest (vertical)⁴.
 - This will be accomplished using a UNC 15 periodontal probe fitted with a rubber stopper (Figure 7) and measured with a ruler marked at 0.5 mm increments. The depth will be recorded to the nearest 0.5 mm (Figure 8).

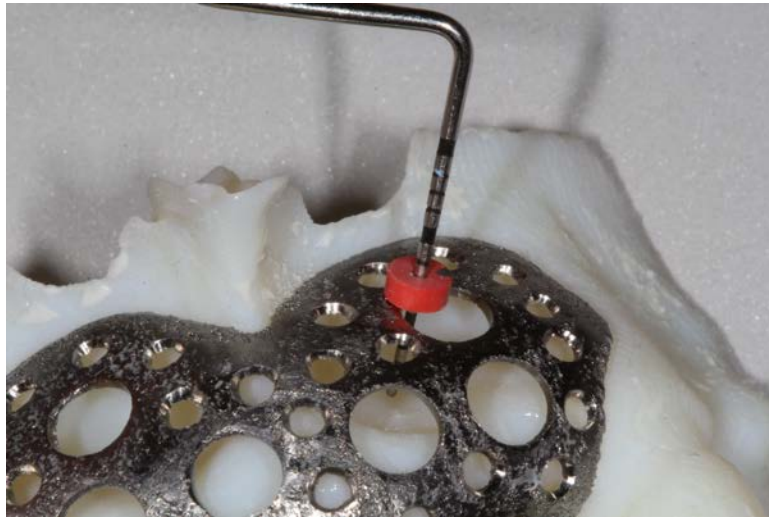

Figure 7




Figure 8

- Measure space under CTRAM at same locations^{3*,4*} for bone fill at 8 months following bone graft surgery just before the CTRAM is removed and the implant is placed.

Specific Aim 3

Compare stl files of the digital scans of the stone models made from impressions made pre-surgically², 2-4 weeks (after any post-surgical swelling has abated) after the implant is placed⁶, and at 4 months after implant

placement⁷ to note volume changes on models. Differences in volume will be recorded in cubic mm.

- Comparison of stl files will be made for the surgical site and at another location on the models where teeth are intact and no surgery was performed. The comparison of stl files at a non-surgical site where no tissue dimension changes are anticipated is being performed to assess reliability of the stl file comparison on study models.

Before Study: Initial Clinical Sequence with Screening and Consent:

1. Patients are referred to Naval Postgraduate Dental School, Department of Periodontics for alveolar ridge augmentation and subsequent implant therapy.
2. A treatment plan (based on the clinical exam, diagnostic stone models and CBCT) may be developed for ridge augmentation using CTRAM with GBR leading to implant placement.
3. Patients for whom CTRAM with GBR is treatment planned will be asked by their provider if they would like to read a one page brief (Appendix C) that describes the study that is measuring how well CTRAM works to regenerate bone.
4. If the patient is not interested in hearing more about the study the provider begins the CTRAM treatment process.

5. If the patient expresses interest in study participation after reading the one page brief, an investigator will be asked to meet with the patient to fully discuss the study.
 - a. If the patient does not consent to be in the study, therapy will continue as planned by the patient's surgeon, but measurements of volumetric bone changes will not be made as described in this study.
 - b. If the patient consents to be in the study, the therapy under the research protocol will continue as stated below.

Following Consent:

1. Baseline digital scan:
 - a. A digital scan of the patient's pre-surgical jaw stone model, capturing the teeth and the edentulous alveolar ridge at the site to be treated will be made via the Degree of Freedom Scanner (see Figure 9 below).

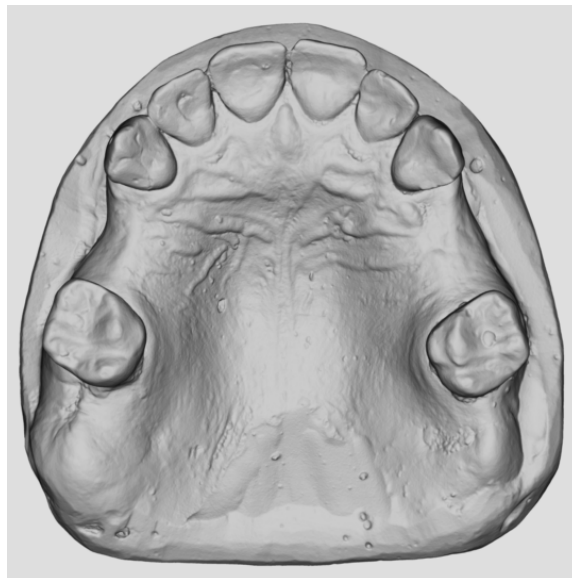


Figure 9

- i. The image will be saved as an stl file under the patient's study number and date the image was taken on a removable storage device that only stores digital scans and is not connected to the web. The device will be locked by the PI in a secure office drawer at NPDS.
 - ii. The baseline stl file² image will be compared to digital images that will be taken at time points (stl files^{6, 7}) listed in the methods protocol (See Appendix A). The 3 stl digital image files will be transferred to a secure computer in 3D Medical Applications Department for comparison. (See Appendix A).
2. The 3D virtual model of the ridge defect will be created (stl file):
 - a. Using the software in the 3D Medical Applications Department the patient's CBCT images (stored on the WRNMMC Radiology Picture Archiving and Communication System (PACS) for radiology) will be uploaded and used to create a virtual model of the teeth and the deficient ridge to plan the augmentation of the ridge.
 - b. A virtual 3D model of deficient ridge is produced.
3. 3D Medical Applications will design a CTRAM using the computer generated model to virtually augment the ridge to ideal bone contours, and determine bone volume from the underside of the CTRAM to the surface of the edentulous ridge (stl file). Following the CTRAM design phase, it is printed (see Chapter II, Figure 6).

4. Once the CTRAM has been printed, the cameo and intaglio surfaces will be polished and the peripheral edges smoothed to a “feather edge” with slow speed polishing burs.
5. The CTRAM is then sterilized for surgery. (Please see Appendix B: Surgical Protocol for details concerning the surgical treatment phase of the study.)
6. 3D Medical Applications will make a photo image (mapping – see Appendix D) of the CTRAM on which markings will be made to show investigators where measurements are made using the periodontal probe at CTRAM fixation and at 8 months just before the CTRAM is removed.
7. The surgical protocol will be followed (Appendix B) to insert the CTRAM, take clinical measurements and remove the CTRAM at the end of 8 months, prior to implant placement.

Data Analysis Plan

This study is a pilot study with 12 anticipated subjects (plus 2 additional enrollees in case some subjects are exited from the study). Thus, the results presented from this study will primarily be descriptive, with means and 95% confidence intervals (or medians and ranges) presented to summarize continuous data and counts and percentages for categorical data.

1. A patient flow diagram will present the number of subjects recruited, consented, and the number of subjects at each follow up time point.
2. A table will present demographic and clinical characteristics of the subjects. The pattern of any adverse events or loss to follow-up over the duration of the study will be described.

3. Specific Aim 1: For each subject, the hypothetical ideal volume of bone augmentation will be calculated and summarized by comparing the pre-surgical CBCT of the deficient alveolar ridge with the virtual model created for fabrication of the CTRAM.
4. Specific Aim 1: The post-graft CBCT (taken at 7 months) will be compared with the pre-surgical CBCT to measure actual bone growth. The differences between actual bone growth and hypothetical bone growth will be calculated for each patient and summarized. Paired comparisons (Wilcoxon signed-rank tests or paired t-tests) will be done to evaluate the statistical significance of bone growth as assessed by the CBCT.
5. Specific Aim 1: STL files will be used to compare the actual and ideal placement of the CTRAM. The distance between the actual placement and the ideal placement will be calculated and summarized.
6. Specific Aim 2: Mean space between the CTRAM and *the alveolar ridge* at initial placement will be measured using a periodontal probe and summarized for each subject on both the vertical and horizontal extent. The same locations will be re-sampled immediately prior to CTRAM removal. Paired comparisons (Wilcoxon signed-rank tests or paired t-tests) will be done to evaluate the statistical significance of bone growth as assessed by the periodontal probe.
7. Specific Aim 3: Volumetric measurements taken from STL files of digital scans of stone models will be summarized and compared across three time points: pre-surgically, 2-4 post surgically, and 4 months after implant

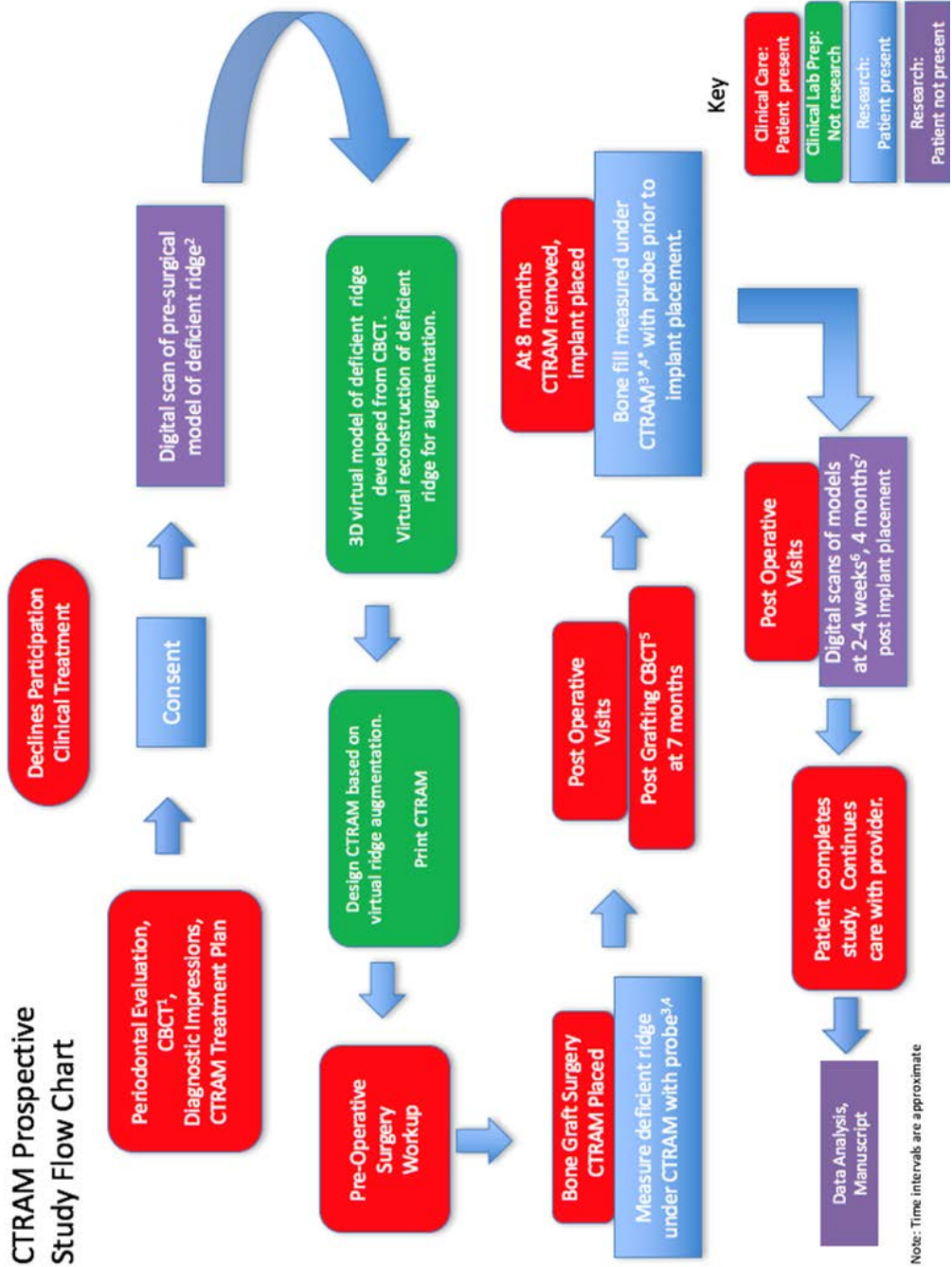
placement. Paired comparisons (Wilcoxon signed-rank tests or paired t-tests) will be done to assess change at each time point, with significance levels adjusted for three comparisons.

8. Specific Aim 3: For each patient, a region of approximately equivalent size contralateral to the surgical site will be identified for use as a split-mouth, paired control region. A paired test (Wilcoxon signed-rank tests or paired t-tests) will be used to compare volumetric change from baseline in the surgical site versus the control site over the two time points.

CHAPTER IV: CONCLUSION

It is anticipated that the measurements recorded from the CBCT and stone model scans will correlate with the clinical measurements to demonstrate complete bone fill utilizing the CTRAM ridge augmentation technique. The data from this IRB approved study may show that CTRAM predictably produces complete ridge regeneration, such that a second post-graft CBCT may not be necessary when implant therapy is planned.

APPENDIX A: CTRAM PROSPECTIVE STUDY FLOW CHART



APPENDIX B: PERIODONTAL SURGICAL PROCEDURES

Phase I CTRAM Surgical Procedure:

Females of childbearing age will be asked to complete a HCG urinalysis prior to the surgical procedure. If the results of the HCG test are positive, the surgery will be deferred until after pregnancy and thus the subject will be exited from the study.

Prior to surgical procedure, in line with standard procedure at the Periodontics Department, participants will be offered the option of having the surgery performed using: 1) Only local anesthesia, or 2) a combination of oral anxiolysis with Triazolam and local anesthesia, or 3) a combination of IV moderate sedation with Versed and Fentanyl and local anesthesia. The use of sedation will not affect the surgical procedure.

1. All surgical providers will be briefed in the protocol. All surgeries will follow the same steps listed below:
 - a. Surgical set-up is standardized for all surgeries done at the Naval Postgraduate Dental School Periodontics Department.
 - b. Surgical Procedure Steps:
 - i. Administration of oral anxiolysis or IV moderate sedation if patient desires and such treatment is indicated
 - ii. Administration of IV Dexamethasone if considered needed
 - iii. Administration of topical and local anesthetic with any combination of 2% Lidocaine with 1:100K epinephrine, 4% Articaine with 1:100K epinephrine, and 0.5% Marcaine with 1:200K epinephrine

- iv. Sulcular incision around teeth adjacent to the edentulous site, connected via a crestal or paracrestal incision along the edentulous ridge. Vertical releasing incisions may be made for surgical access.
- v. Full thickness flaps will be reflected to expose the deficient ridge.
- vi. The CTRAM will be tried in at the site and examined for correct fit. If fit is appropriate, corticotomies will be made into the bone to induce bleeding and the CTRAM will be fixated with the required number of surgical fixation screws for proper stability—ensuring that there is no movement.
- vii. A periodontal probe fitted with a rubber stopper will record the space from the surface of the CTRAM to the alveolar ridge through specific pores as shown in Appendix D. The distance will be measured via an endodontic style ruler marked at 0.5 mm increments. At the same pores, a second set of measurements will be made 8 months later just before the CTRAM is removed and the implant is placed.
- viii. FDBA will be hydrated with sterile saline as per the manufacturer's instructions, or enamel matrix derivative (EMD) and placed into the alveolar defect—level with the pores and access port(s) of the titanium matrix (see Figure 1C).
- ix. A resorbable collagen membrane will be placed over the access port(s) on the external aspect of the matrix.

- x. If needed, a periosteal releasing incision will be made in the buccal and/or lingual flap to allow for primary closure.
 - xi. The area of the flap directly covering the matrix will be sutured with a monofilament, non-resorbable suture material. Areas which do not directly cover the matrix may employ this same suture type, or may require a resorbable suture instead.
2. Standard post-operative care will be provided: (See next section: Post-operative Care below)

Post-operative Care:

1. All participants receive the following post-operative regimen:
 - a. Pain medication consisting of any of the following alone or in combination:
 - i. Ibuprofen 800 mg , Take 1 tab PO q6-8h for moderate pain OR
 - ii. Hydrocodone/Acetaminophen 5/325 mg, Take 1-2 tab PO q6h prn severe/breakthrough pain OR
 - iii. Oxycodone/Acetaminophen 5/325mg, Take 1-2 tab PO q6h prn severe/breakthrough pain
 - b. Pain medication for patients who cannot take NSAIDS will be prescribed any of the following alone or in combinations:
 - i. Acetaminophen 325 mg, Take 1-2 tabs PO q4h for moderate pain
 - ii. Oxycodone 5mg, Take 1 tab PO q4h prn severe/breakthrough pain

- c. Antibiotics consisting of either of the following:
 - i. Amoxicillin 500mg, Take 1 tab PO q8h for 10 days
 - ii. Clindamycin 300 mg, Take 1 tab PO q8h for 10 days
 - d. 0. 12% Chlorhexidine, 1 bottle, Rinse and spit bid with 1 TBSP as directed on the bottle
 - e. Medrol 4 mg Dosepak if needed. Use as directed on package.
3. All patients are provided with the standard post-operative instructions. Patients will be evaluated at weeks 1, 2, 4 and 8 weeks and then at 3, 5 and 7 months for routine post-operative care.

At 7 months post-insertion of the CTRAM device, the patient has a second CBCT taken to assess the grafted site and plan for the second stage of surgery involving CTRAM and fixation screw removal and placement of the dental implant(s) at the grafted site.

Phase II Surgical Procedure at Approximately 8 Months:

1. Surgical steps will be completed as outlined in the Phase I surgical procedure section up until step “v”.
2. Measurements with a UNC-15 periodontal probe will be taken at the augmented site using the access port(s) and pores of the CTRAM to assess bone fill as described in the specific aims.
3. The fixation screw(s) and the CTRAM device will be removed.
4. The implant(s) will be placed based upon the manufacturer’s guidelines. A cover screw or healing abutment will be hand tightened and a peri-apical radiograph will be taken to ensure proper seating contact between implant and cover screw or healing abutment.

5. Standard post-operative care will be provided at weeks 1, 2, 4 and 8 and at 4 months.
 - a. During a postoperative visit 2 - 4 weeks when any post-surgical edema has abated, an impression of the surgical site will be made and a digital scan of the stone model will be made.
 - b. At approximately 4 months post-operatively the patient will have another jaw impression made and a final digital scan of the model will be made.
6. This completes the subject's participation in this prospective case series. Patients will be exited from the study and followed by their periodontist and primary care dentist for subsequent maintenance therapy and implant restoration.

APPENDIX C: ONE PAGE STUDY BRIEF

You and your doctor have decided that you are going to have a bone graft placed under a custom titanium mesh where a tooth was removed and your jawbone shape decreased in size. This procedure is called guided bone regeneration. It can restore the jawbone contours needed to place a dental implant. Although custom titanium mesh technique appears to work great, how much new bone is actually restored has not been scientifically measured.

The Periodontics Department is conducting a research study to measure how much new jawbone is restored when a custom titanium mesh is used to hold a bone graft. If you choose to enroll in the study you will have the same number of appointments, and receive the same treatment as patients who do not enroll in the study. The only differences are that we are asking study volunteers to let us make 3 measurements and take 2 extra jaw impressions.

Normal clinical treatment with a custom titanium mesh needs a pre-surgical 3D x-ray scan of the missing tooth area and a post grafting 3D x-ray scan to see the bone growth. *Measurement #1* in this study will compare these x-rays on a computer to determine how much new bone is gained.

The custom titanium mesh and bone graft are placed in your jaw during the first surgery. The mesh is removed and the implant is placed in the second surgery 8 months later. *Measurement #2* uses a periodontal probe to measure the space under your mesh to your jawbone before the bone graft is placed, and 8 months later before the matrix is removed.

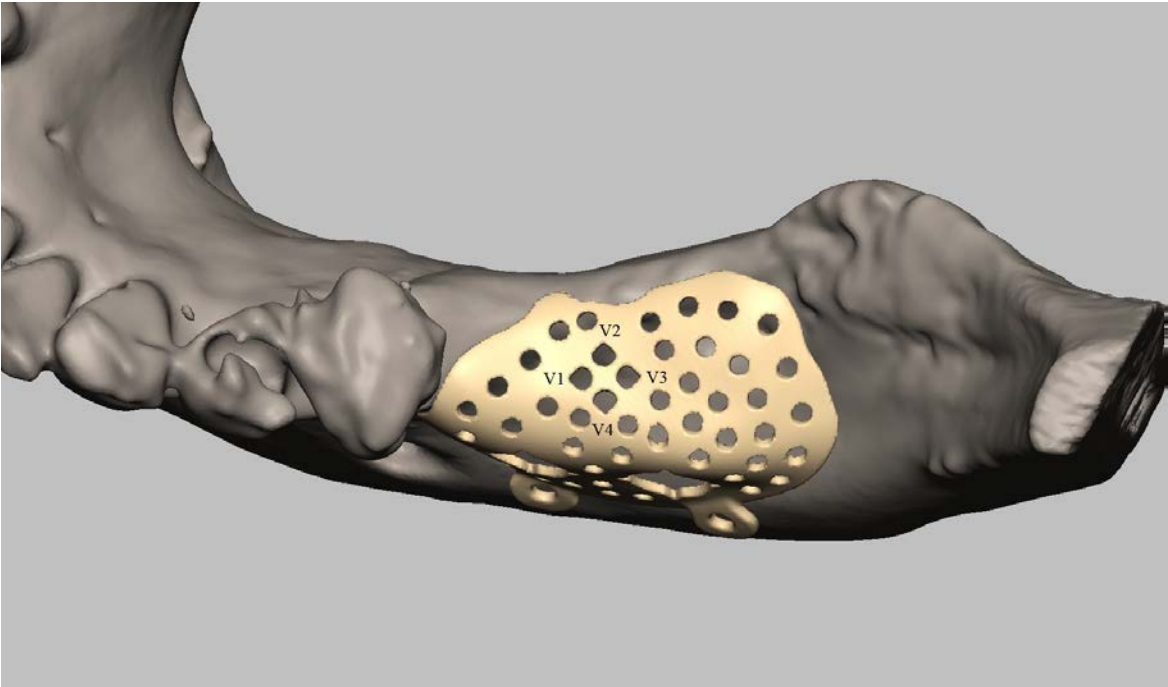
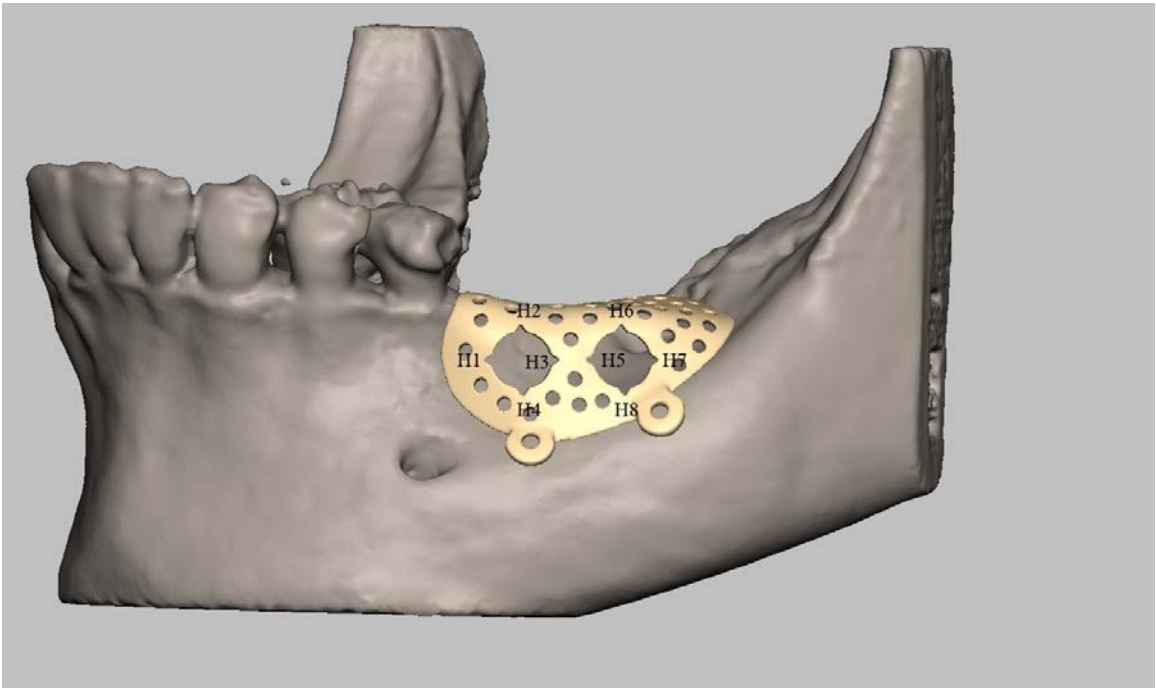
An impression for a model of your teeth and jaw is made before surgery. For the study we are asking you to let us take an impression for jaw models at 2 to 4 weeks and at 4 months after implant placement. *Measurement #3* uses digital photo scans of these 3 jaw models and compares them on a computer to measure how jaw contours change.

If you are interested in being in this study to help us document how bone volume changes using the custom titanium mesh, tell your doctor. He or she will have an investigator come over to discuss the study.

Speaking with an investigator does not obligate you to be in the study. If you are not interested, that is okay and you will start your treatment with your doctor as a non-study patient.

Thank you for your consideration.

APPENDIX D: PERIODONTAL PROBE MEASUREMENT MAP



APPENDIX E: DATA COLLECTION SHEETS


Data Collection Sheet 1 CBCT Volumetric Measurement (in mm³)

For Specific Aim 1


Protocol: Volumetric Changes in Edentulous Alveolar Ridge Sites Utilizing Guided Bone Regeneration and a Custom Titanium Ridge Augmentation Matrix (CTRAM)

Subject ID #: _____
 Date Enrolled: _____
 Gender: _____
 Age: _____
 Tooth/Site #: _____


CBCT Volumetric Measurement (in mm³)



Baseline



Virtual Model Increase



7 Months Post
Grafting and
CTRAM Placement

Location of CTRAM on virtual model using baseline CBCT.

Location of CTRAM in mouth using 7 months CBCT.

Linear distance between fixed points in mm.

Fixed points determined after CTRAM Design.
 Fixed points on CTRAM (1-4). Anatomical fixed points on teeth A-D.

	Point 1 - A	Point 2 - B	Point 3 - C	Point 4 - D
Virtual Model				
In Mouth				
Difference in mm				

Data Collection Sheet 2


Digital Scan of Stone Model: Volumetric Measurement (in mm³)

For Specific Aim 3


Protocol: Volumetric Changes in Edentulous Alveolar Ridge Sites Utilizing Guided Bone Regeneration and a Custom Titanium Ridge Augmentation Matrix (CTRAM)

Subject ID #: _____
Date Enrolled: _____
Gender: _____
Age: _____
Tooth/Site #: _____

Digital Scans of Stone Models: Volumetric Measurement (in mm³) at graft site



Baseline




2-4 Week Time Point




4 Month Time Point


Digital Scans of Stone Models: Volumetric Measurement (in mm³) at contralateral site



Baseline



2-4 Week Time Point



4 Month Time Point

Data Collection Sheet 3
Periodontal Probe Measurements to Bone under CTRAM at Baseline

Pre-grafting Measurement

For Specific Aim 2

Please note: Each data sheet to record probe measurements is customized because each CTRAM has a unique custom design. This example is how individual data collection sheets will be designed.

Protocol: Volumetric Changes in Edentulous Alveolar Ridge Sites Utilizing Guided Bone Regeneration and a Custom Titanium Ridge Augmentation Matrix (CTRAM)

Subject ID #: _____
 Date Enrolled: _____
 Gender: _____
 Age: _____
 Tooth/Site #: _____

Pre-Grafting: Vertical Probing Measurements of Bone with CTRAM in mm's Locations individualized per subject based on mapping of CTRAM indicating where to measure			
V ₁ Mesial site	V ₂ Lingual/Palatal site	V ₃ Distal site	V ₄ Buccal site

Pre-Grafting: Horizontal Probing Measurements of Bone with CTRAM in mm's Locations individualized per subject based on mapping of CTRAM indicating where to measure			
H ₁ Mesial site	H ₂ Coronal site	H ₃ Distal site	H ₄ Apical site

*****IF TWO PORTS ARE PRESENT, INCLUDE SECOND SET OF MEASUREMENTS**

Pre-Grafting: Horizontal Probing Measurements of Bone with CTRAM in mm's Locations individualized per subject based on mapping of CTRAM indicating where to measure			
H ₅ Mesial site	H ₆ Coronal site	H ₇ Distal site	H ₈ Buccal site

Data Collection Sheet 4
Periodontal Probe Measurements to Bone under CTRAM at 8 months

Post-grafting Measurements

For Specific Aim 2

Please note: Each data sheet to record probe measurements is customized because each CTRAM has a unique custom design. This example is how individual data collection sheets will be designed.

Protocol: Volumetric Changes in Edentulous Alveolar Ridge Sites Utilizing Guided Bone Regeneration and a Custom Titanium Ridge Augmentation Matrix (CTRAM)

Subject ID #: _____
 Date Enrolled: _____
 Gender: _____
 Age: _____
 Tooth/Site #: _____

Post-Grafting: Vertical Probing Measurements of Bone with CTRAM in mm's Locations individualized per subject based on mapping of CTRAM indicating where to measure			
V ₁ Mesial site	V ₂ Lingual/Palatal site	V ₃ Distal site	V ₄ Buccal site

Post-Grafting: Horizontal Probing Measurements of Bone with CTRAM in mm's Locations individualized per subject based on mapping of CTRAM indicating where to measure			
H ₁ Mesial site	H ₂ Coronal site	H ₃ Distal site	H ₄ Apical site

*****IF TWO PORTS ARE PRESENT, INCLUDE SECOND SET OF MEASUREMENTS**

Post-Grafting: Horizontal Probing Measurements of Bone with CTRAM in mm's Locations individualized per subject based on mapping of CTRAM indicating where to measure			
H ₅ Mesial site	H ₆ Coronal site	H ₇ Distal site	H ₈ Buccal site

REFERENCES

Albrektsson T, Zarb G, Worthington P, Eriksson AR. The Long-Term Efficacy of Currently Used Dental Implants: A Review and Proposed Criteria of Success. *Int J Oral Maxillofac Implants* 1986; 1(1):11-25.

American Academy of Periodontology Glossary of Periodontal Terms, 4th Edition, 2001, Chicago, Illinois 60611-2690

American Academy of Periodontology Position Paper. Peri-Implant Mucositis and Peri-Implantitis: A Current Understanding of Their Diagnoses and Clinical Implications. *J Periodontol* 2013; 84(4):436-443.

Akyalcin S, Cozad BE, English JD, Colville CD, Laman S. Diagnostic Accuracy of Impression-Free Digital Models. *Am J Orthod Dentofacial Orthop* 2013; 144:916-22.

Buser D, Dula K, Belser U, Hirt H, Berthold H. Localized Ridge Augmentation Using Guided Bone Regeneration. I. Surgical Procedure in the Maxilla. *Int J Periodont Rest Dent* 1993; 13:29-45.

Cammack GV, Nevins M, Clem DS, Hatch JP, Mellonig JT. Histologic Evaluation of Mineralized and Demineralized Freeze-Dried Bone Allograft for Ridge and Sinus Augmentations. *Int J Periodont Rest Dent* 2005; 25:231-237.

Ciocca L, Fantini M, De Crescenzo F, Corinaldesi G, Scotti R. Direct Metal Laser Sintering (DMLS) of a Customized Titanium Mesh for Prosthetically Guided Bone Regeneration of Atrophic Maxillary Arches. *Med Biol Eng Comput* 2011; 49:1347-1352.

Connors CA, Liacouras PC, Grant GT. Custom Titanium Ridge Augmentation Matrix (CTRAM). *Int J Periodont Rest Dent* 2016; (in press).

Gundeslioglu OA. Exposed Titanium Mesh and Dura Persisting for 8 Years After Cranioplasty. *J Craniofac Surg* 2013; 24(2):655-656.

Her S, Taeheon K, Fien M. Titanium Mesh as an Alternative to a Membrane for Ridge Augmentation. *J Oral and Maxillofac Surg* 2012; 70:803-810.

Hou J, Chen M, Pan C, Tao Q, Wang J, Wang C, Zhang B, Huang H. Immediate Reconstruction of Bilateral Mandibular Defects: Management Based on Computer-Aided Design/Computer-Aided Manufacturing Rapid Prototyping Technology in Combination with Vascularized Fibular Osteomyocutaneous Flap. *J Oral Maxillofac Surg* 2011; 69:1792-1797.

Hurley LA, Stinchfield FE, et al. The role of soft tissues in osteogenesis. An experimental study of canine spine fusions. *J Bone Joint Surg Am* 1959;41A: 1243-54.

Jensen OT, Lehman H, Ringeman JL, Casap N. Fabrication of Printed Titanium Shells for Containment of BMP-2 Composite Graft Materials for Alveolar Bone Reconstruction. *J Oral Maxillofac Implants* 2014; 29e103-e105.

Joffe J, Harris M, Kahugu F, Nicoll S, Linney A, Richards R. A Prospective Study of Computer-Aided Design and Manufacture of Titanium Plate for Cranioplasty and its Clinical Outcome. *Br J Neurosurg* 1999; 13(6):576-580.

Keith JD Jr, Petrungaro P, Leonetti JA, Elwell CW, Zeren KJ, Caputo C, Nikitakis NG, Schöpf C, Warner MM. Clinical and histologic evaluation of a mineralized block allograft: results from the developmental period (2001-2004). *Int J Periodontics Restorative Dent* 2006; Aug;26(4):321-7.

Louis P, Gutta R, Said-Al-Naief N, Bartolucci AA. Reconstruction of the Maxilla and Mandible with Particulate Bone Graft and Titanium Mesh for Implant Placement. *J Oral Maxillofac Surg* 2008; 66:235-245.

Lyford RH, Mills MP, Knapp CL, Scheyer ET, Mellonig JT. Clinical evaluation of freeze-dried block allografts for alveolar ridge augmentation: a case series. *Int J Periodontics Restorative Dent* 2003; Oct;23(5):417-25.

McAllister BS, Haghghat K. Bone Augmentation Techniques. *J Periodontol* 2007; 78(3): 377-396.

Misch C. Comparison of Intraoral Donor Sites for Onlay Grafting Prior to Implant Placement. *Int J Oral Maxillofac Implants* 1997; 12:767-776.

Nevins M, Mellonig JT, Clem DS, Reiser GM, Buser DA. Implants in Regenerated Bone: Long-Term Survival. *Int J Periodont Rest Dent* 1998; 18:35-45.

Pieri F, Corinaldesi G, Fini M, Aldini NN, Giardino R, Marchetti C. Alveolar Ridge Augmentation with Titanium Mesh and a Combination of Autogenous Bone and Anorganic Bovine Bone: A 2-Year Prospective Study. *J Periodont* 2008; 79:2093-2103.

Rebele SF, Zuhr O, Schneider D, Jung RE, Hurzeler MB. Tunnel Technique with Connective Tissue Graft Versus Coronally Advanced Flap with Enamel Matrix Derivative for Root Coverage: A RCT using 3D Digital Measuring Methods. Part II. Volumetric Studies on Healing Dynamics and Gingival Dimensions. *J Clin Periodontol* 2014; 41: 593-603.

Ricci L, Perrotti V, Ravera L, Scarano A, Piattelli A, Iezzi G. Rehabilitation of Deficient Alveolar Ridges Using Titanium Grids Before and Simultaneously with Implant Placement: A Systematic Review. *J Periodontol* 2013; 84:1234-1242.

Schropp L, Wenzel A, Kostopoulos L, Karring T. Bone Healing and Soft Tissue Contour Changes Following Single-Tooth Extraction: A Clinical and Radiographic 12-Month Prospective Study. *Int J Periodontics Restorative Dent* 2003; 23:313-323.

Sumi Y, Miyaishi O, Tohnai I, Ueda M. Alveolar Ridge Augmentation with Titanium Mesh and Autogenous Bone. *Oral Surg Oral Med Oral Pathol Oral Radio Endod* 2000; 89:268-70.

Tyndall DA, Price JB, Tetradis S, Ganz SD, Hildebolt C, Scarfe WC. Position statement of the American Academy of Oral and Maxillofacial Radiology on Selection Criteria for the Use of Radiology in Dental Implantology with Emphasis on Cone Beam Computed Tomography. *Oral Surg Oral Med Oral Pathol Oral Radiol* 2012;113:817-826.

von Arx T, Kurt B. Implant Placement and Simultaneous Peri-Implant Bone Grafting Using a Micro Titanium Mesh for Graft Stabilization. *Int J Periodont Rest Dent* 1998; 18:117-127.

Wallace SS, Froum SJ, Tarnow DP. Histologic evaluation of a sinus elevation procedure: a clinical report. *Int J Periodont Rest Dent* 1996; Feb:16(1):46-51.

White SC and Pharoah MJ. *Oral Radiology: Principles and Interpretation*. 7th Edition. 2009.

Wiggins A, Austerberry R, Morrison D, Ho KM, Honeybul S. Cranioplasty With Custom-Made Titanium Plates—14 Years Experience. *Neurosurgery* 2013; 72:248-256.