

REPORT DOCUMENTATION PAGE

*Form Approved
OMB No. 0704-0188*

The public reporting burden for this collection of information is estimated to average 1 hour per response, including the time for reviewing instructions, searching existing data sources, gathering and maintaining the data needed, and completing and reviewing the collection of information. Send comments regarding this burden estimate or any other aspect of this collection of information, including suggestions for reducing the burden, to the Department of Defense, Executive Service Directorate (0704-0188). Respondents should be aware that notwithstanding any other provision of law, no person shall be subject to any penalty for failing to comply with a collection of information if it does not display a currently valid OMB control number.

PLEASE DO NOT RETURN YOUR FORM TO THE ABOVE ORGANIZATION.

1. REPORT DATE (DD-MM-YYYY) 10/20/2017		2. REPORT TYPE Poster		3. DATES COVERED (From - To) 10/20/2017-10/24/2017	
4. TITLE AND SUBTITLE Penetrating Facial Trauma Causing Unexpected Massive Blood Loss				5a. CONTRACT NUMBER	
				5b. GRANT NUMBER	
				5c. PROGRAM ELEMENT NUMBER	
6. AUTHOR(S) Capt Caleb S Baxter				5d. PROJECT NUMBER	
				5e. TASK NUMBER	
				5f. WORK UNIT NUMBER	
7. PERFORMING ORGANIZATION NAME(S) AND ADDRESS(ES) 59th Clinical Research Division 1100 Willford Hall Loop, Bldg 4430 JBSA-Lackland, TX 78236-9908 210-292-7141				8. PERFORMING ORGANIZATION REPORT NUMBER 17414	
9. SPONSORING/MONITORING AGENCY NAME(S) AND ADDRESS(ES) 59th Clinical Research Division 1100 Willford Hall Loop, Bldg 4430 JBSA-Lackland, TX 78236-9908 210-292-7141				10. SPONSOR/MONITOR'S ACRONYM(S)	
				11. SPONSOR/MONITOR'S REPORT NUMBER(S)	
12. DISTRIBUTION/AVAILABILITY STATEMENT Approved for public release. Distribution is unlimited.					
13. SUPPLEMENTARY NOTES					
14. ABSTRACT					
15. SUBJECT TERMS					
16. SECURITY CLASSIFICATION OF:			17. LIMITATION OF ABSTRACT	18. NUMBER OF PAGES	19a. NAME OF RESPONSIBLE PERSON Clarice Longoria
a. REPORT	b. ABSTRACT	c. THIS PAGE			19b. TELEPHONE NUMBER (Include area code) 210-292-7141



Penetrating Facial Trauma Causing Unexpected Massive Blood Loss

Caleb Baxter, D.O., Angelica Mancone, M.D., Kurt Bolin, M.D.
San Antonio Uniformed Services Health Education Consortium Anesthesiology Program

Introduction:

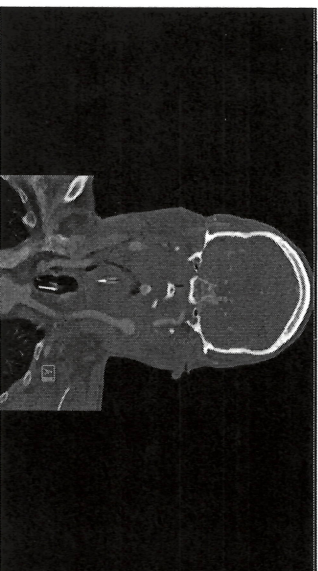
In spite of years of collective experience and continued improvements in trauma resuscitation, mortality remains high. The most common cause of preventable mortality in penetrating trauma is uncontrolled hemorrhage⁵. The ability for the trauma anesthesiologist to rapidly analyze the patient's condition and initiate appropriate resuscitation remains critical. It is important for the clinician to keep in mind that occult blood loss may complicate the initial assessment.

Case Presentation:

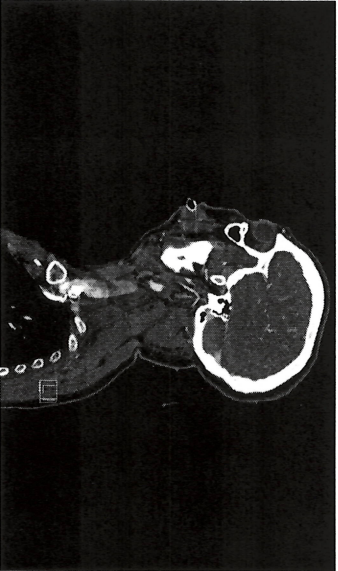
36 year old male with no significant prior medical history presented to the EID following a gunshot wound to the face with entry wound to left cheek, exit wound to right anterior neck with notable oral trauma to teeth and tongue.

Management:

On arrival to the ER the patient was agitated but alert and responsive with significant bleeding from the mouth. Initial vitals revealed mild tachycardia but were otherwise within normal limits. PIV access was established and blood products started. He was breathing spontaneously on initial assessment but given the location of his injuries and continued bleeding the trauma surgeon decided to take him emergently to the OR to secure his airway. He had two episodes of bloody emesis during transfer but continued to breath spontaneously and respond to questioning. He became more agitated on arrival to the OR and his PIV was dislodged. Non-invasive blood pressure monitoring was unable to be obtained due to his agitation, however he continued to remain active, requesting to be "put to sleep". HR ranged from 110-140 with SpO₂ >94%. Large bore PIV access was obtained and his airway was immediately secured via RSI and direct laryngoscopy. An arterial line was placed after intubation and initial blood gas revealed a pH of 6.8, BE: -24, H/H 10/29, and lactate 15. OG suctioning returned 300cc of blood. After intubation and initial resuscitation he underwent CT and CT angiography revealing injuries which included right internal carotid artery injury with active extravasation. He was immediately returned to the OR for further surgical management which included neck exploration and internal carotid artery ligation. MAP goals were discussed with surgeons who felt that low/normal MAPs were appropriate given reconstruction of his distal ICA via the anterior communicating artery. He required further resuscitation and intermittent vasopressors to maintain MAPs >65.



Occlusive dissection versus transection of the proximal right cervical internal carotid artery



References:

1. Sorenson J, Davis S. Foreign and/or airway: Penetrating Injuries. *Emergency Medical Services*. 2011;28(2):120-123.
2. Bergner A, Hovno A. Traumatic Brain Injuries: Trauma in Trauma: Hemorrhage. *Book Abstracts*. 2013;3(1):106-110.
3. Bergner A, Hovno A. Traumatic Brain Injuries: Trauma in Trauma: Hemorrhage. *Book Abstracts*. 2013;3(1):106-110.
4. Sorenson J, Davis S. Foreign and/or airway: Penetrating Injuries. *Emergency Medical Services*. 2011;28(2):120-123.
5. Sorenson J, Davis S. Foreign and/or airway: Penetrating Injuries. *Emergency Medical Services*. 2011;28(2):120-123.

Declaration: The views expressed herein are those of the authors and do not reflect the official policy or position of San Antonio Uniformed Services Health Education Consortium, the U.S. Air Force, the U.S. Army, the Department of Defense, or the U.S. Government.

Total resuscitation between the EID and OR included 7u PRBC, 6u FFP, 2u platelets and 4650ml crystalloid. After a 15 day hospitalization which included multiple surgical procedures the patient was discharged home able to perform activities of daily living.

Discussion:

The leading cause of death within the first six hours following penetrating trauma is blood loss⁵. The most effective treatment remains early source control and restoration of circulating blood volume. Massive blood loss is often readily apparent on initial evaluation however there are times, such as this case in which occult bleeding may obscure the severity of injury and delay resuscitation. Primary survey must be completed early while remembering that young, healthy patients may be appear stable with minimal changes in vital signs even in the face of severe blood loss up until cardiovascular collapse. Factors like anxiety, stress and pain can also confound initial vital signs. In this case the nature of his neck injury apparently led to ingestion of blood, obscuring the severity of hemorrhage. If patients are hemodynamically unstable early resuscitation must be initiated to temporize until source control is obtained. Tools to recognize internal bleeding such as the FAST ultrasound exam are readily accessible but limited in scope. CT angiography is more sensitive and specific for internal bleeding but requires time and a stable patient. Trauma care requires rapid assessment and integration of multiple clinical factors. The trauma anesthesiologist should maintain a high index of suspicion for occult injury and hemorrhage to avoid delays in intervention and resuscitation.

Classification of Hemorrhage

% Blood Loss	Exam Findings
Class I < 15%	Often no changes to vital signs, no resuscitation necessary
Class II 15-30%	Tachycardia, narrowed pulse pressure, pale/diaphoretic skin, behavioral changes. IVF necessary
Class III 30-40%	Decreased BP, decreased capillary refill, worsened mental status. Blood transfusion usually necessary.
Class IV > 40%	Cardiovascular collapse. Massive transfusion required.