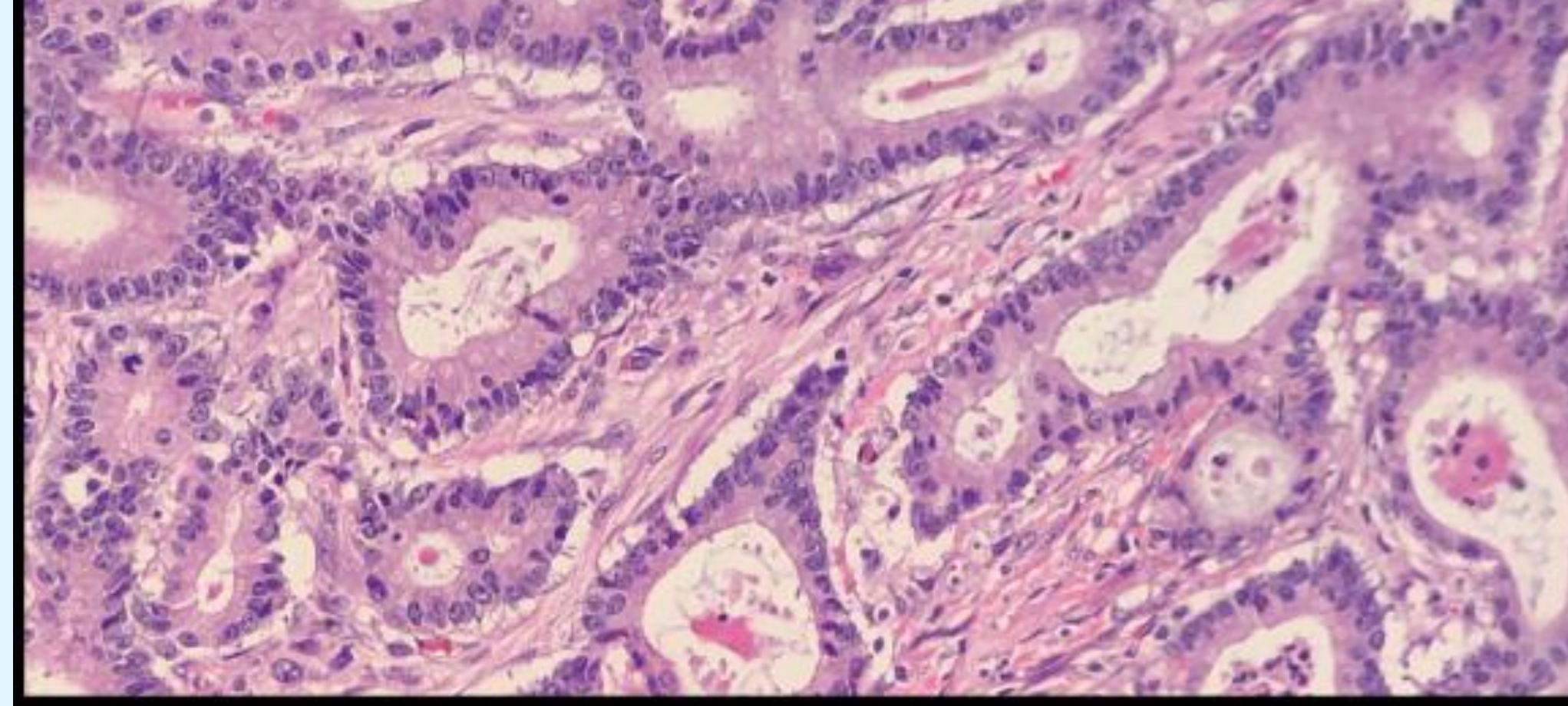


## Background

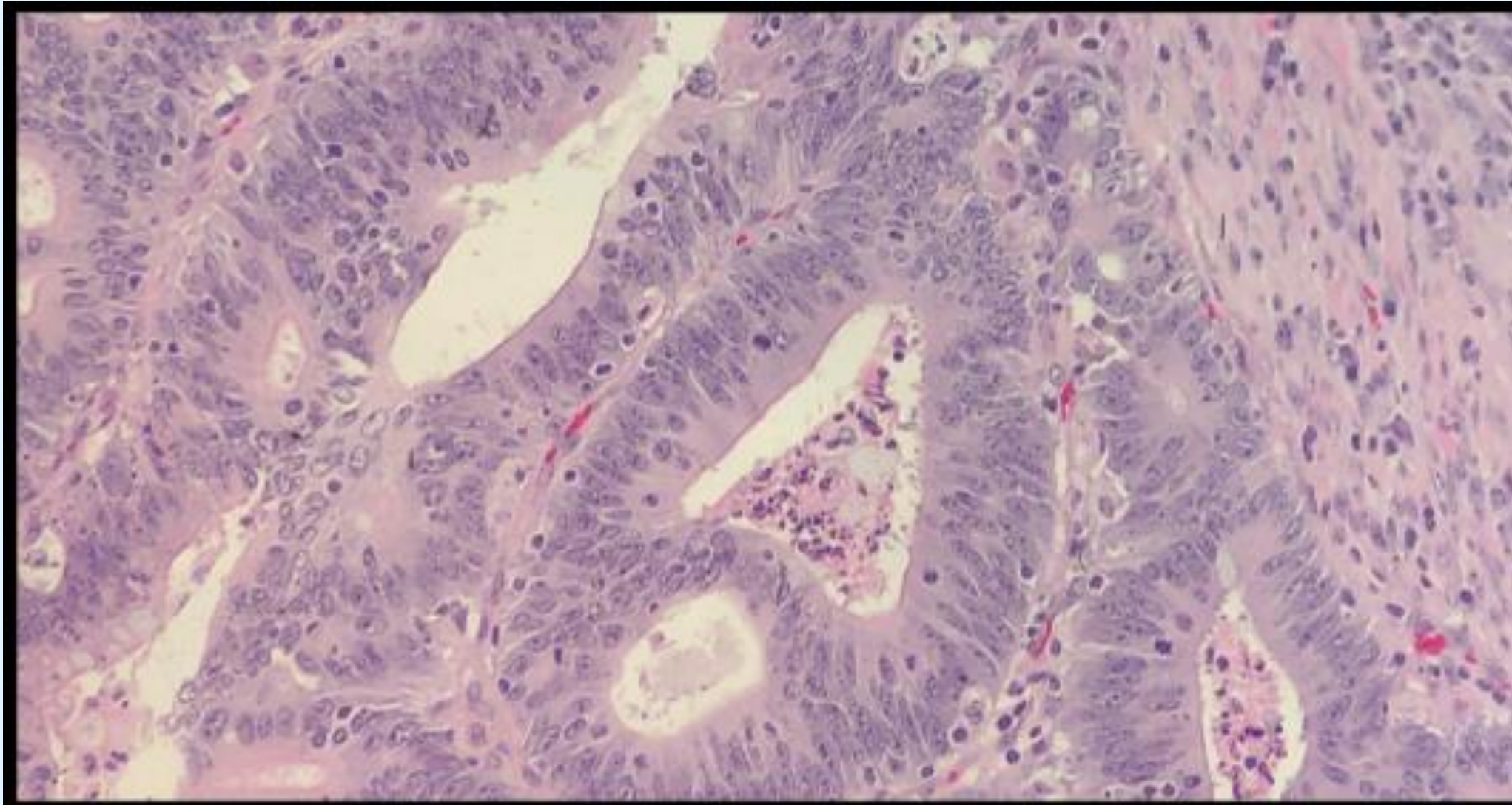
- PD-L1 immunohistochemical staining is becoming increasingly important in the oncological treatment of various neoplasms.
- Interestingly, colonic adenocarcinomas show PD-L1-dependent morphological changes (medullary phenotype and increased tumor-infiltrating lymphocytes) rendering them potentially amenable to analysis by a Convolutional Neural Network (CNN).
- Previously, we have shown that CNNs have the potential to reduce costs and turnaround time associated with immunohistochemical (IHC) staining.
- Herein, we demonstrate that a fine-tuned InceptionV3 CNN architecture is able to accurately and confidently determine PD-L1 status from H&E images.

## Design

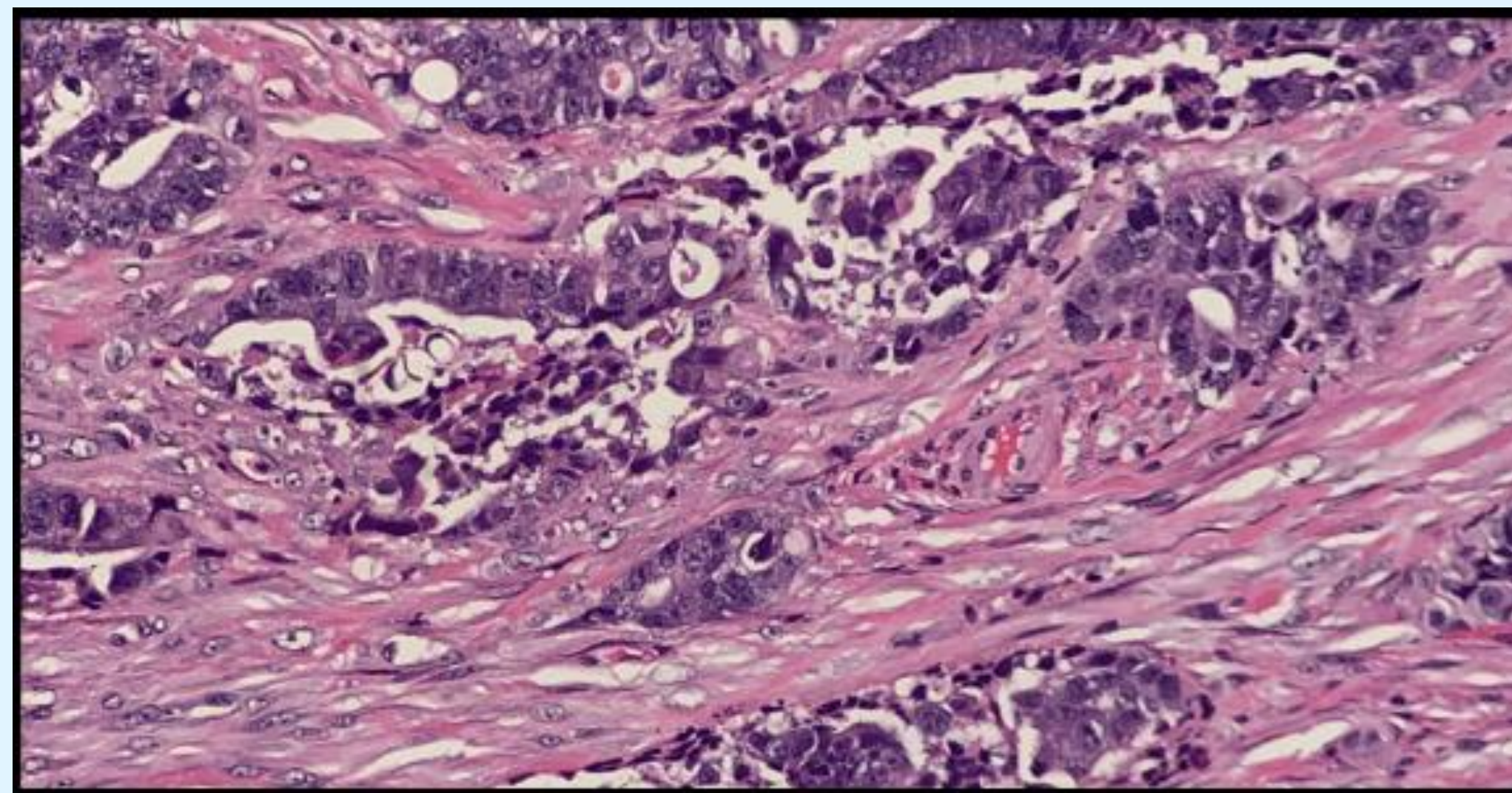
- A total of 1915 H&E images were acquired from 107 (68 PD-L1 negative, 39 PD-L1 positive) archived colonic adenocarcinoma cases.
- Cases were randomly partitioned into 1532 training (80%) and 383 test images (20%) without individual case overlap between the training and test sets.
- The training set was used to fine-tune a customized fully-connected layer on top of the InceptionV3 CNN architecture utilizing pre-trained ImageNet convolutional layer weights. The customized FC layer contained a single 256-unit hidden layer and 2 final output units with softmax activation to output a probability distribution over two classes (PD-L1 positive and PD-L1 negative).
- A ROC curve was used to determine the probability with the highest specificity.



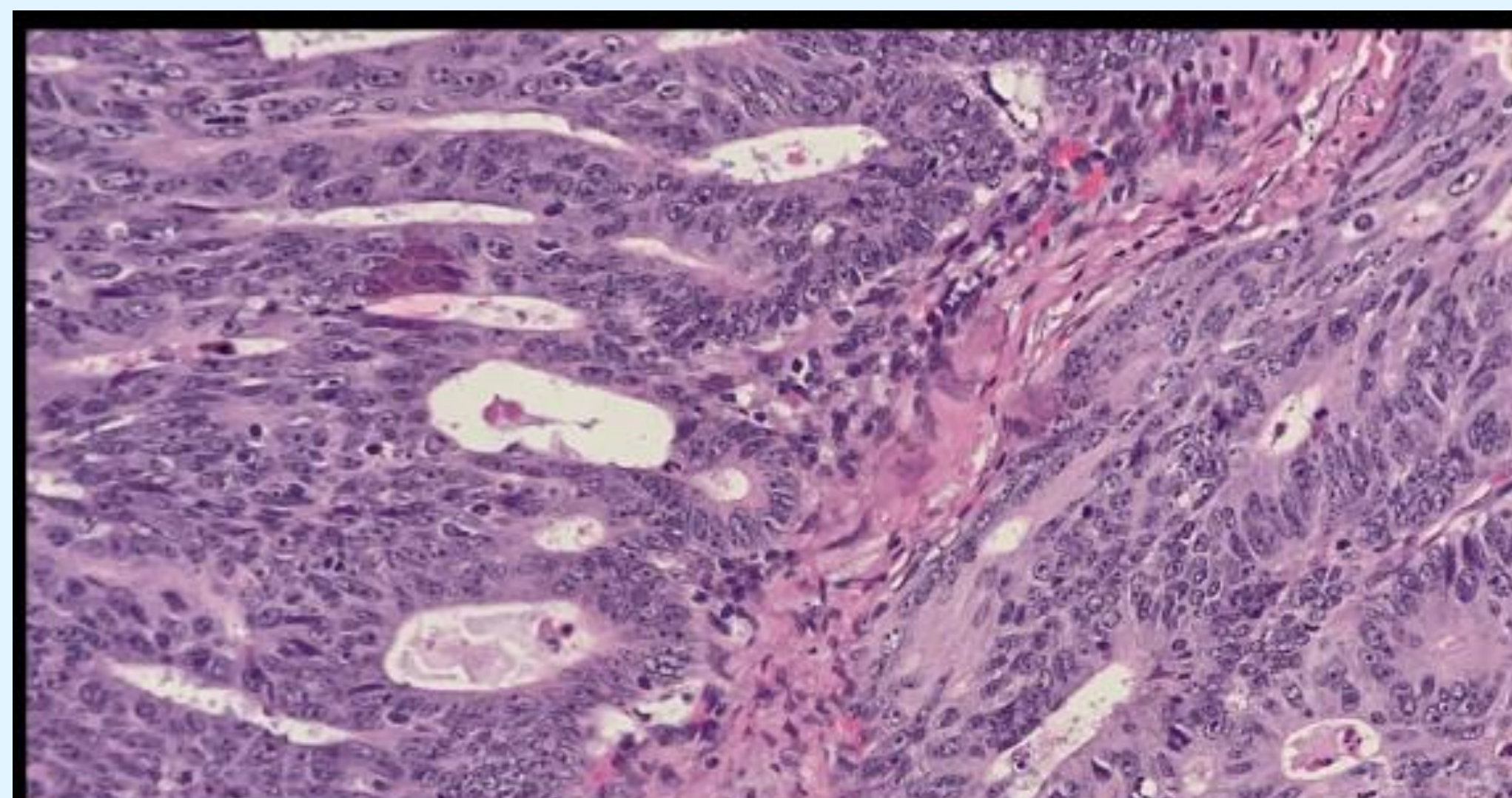
PD-L1 positive predicted correctly;  
Confident prediction (0.9957)



PD-L1 positive predicted correctly;  
Equivocal prediction (0.6679)



PD-L1 negative predicted correctly;  
Confident prediction (0.9919)



PD-L1 negative predicted incorrectly;  
Equivocal prediction (0.5918)

## Results

- The CNN showed 81.2% overall predicted probability of the true status. The entire test set was 0.772 with a specificity of 0.299.
- Of 383 test images, 196 (51.2%) had a class probability of  $> 0.95$  (“Confident Prediction”) while 187 (48.8%) had a probability of  $< 0.95$  (“Equivocal Prediction”).
- The specificities with “confident predictions” were 88.1% and 88.1% for PD-L1 positive and negative, respectively, with IHC utilization with only “equivocal predictions” would result in 51.2% less IHC utilization.
- Additionally, 51 cumulative days of IHC time and up to \$2550 worth of IHC reagents were reduced per 100 cases.
- Images (left) illustrate predicted PD-L1 status at various colonic adenocarcinoma magnifications.

## Conclusion

- A fine-tuned InceptionV3 architecture is an accurate and confident CNN for determining PD-L1 status.
- We predict even further increases in accuracy with additional training images and validation on future intra- and interdepartmental cases.