

SUCCESSFUL RE-ATTACHMENT OF DESCMET'S MEMBRANE AFTER CATARACT SURGERY WITH PNEUMATIC DESCMETOPEXY AND SHORT-TERM GAS FILL: A CASE REPORT

SAMUEL D. HOBBS, NIKHIL J. GODBOLE, AND ANTHONY J. JOHNSON

NO FINANCIAL DISCLOSURES

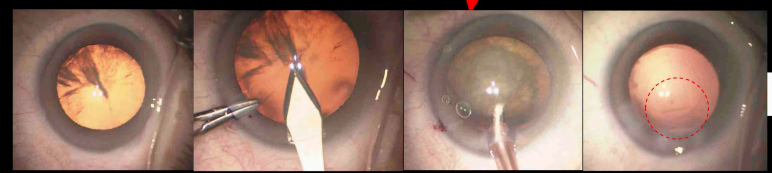
NO FINANCIAL DISCLOSURES. THE VIEW(S) EXPRESSED HEREIN ARE THOSE OF THE AUTHOR(S) AND DO NOT REFLECT THE OFFICIAL POLICY OR POSITION OF BROOKS ARMY MEDICAL CENTER, WILFORD HALL AMBULATORY SURGICAL CENTER, THE U.S. ARMY MEDICAL DEPARTMENT, THE U.S. ARMY OFFICE OF THE SURGEON GENERAL, THE DEPARTMENT OF THE ARMY, THE DEPARTMENT OF THE AIR FORCE AND DEPARTMENT OF DEFENSE, OR THE U.S. GOVERNMENT.

BACKGROUND

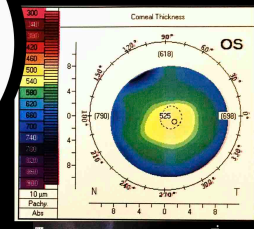
DESCMET'S MEMBRANE DETACHMENT (DMD) IS A RARE COMPLICATION THAT MAY OCCUR AFTER CATARACT SURGERY. I WILL DESCRIBE A CASE OF EXTENSIVE, VISUALLY SIGNIFICANT DESCMET'S DETACHMENT AFTER CATARACT SURGERY THAT WAS TREATED SUCCESSFULLY WITH PNEUMATIC DESCMETOPEXY AND SHORT-TERM GAS FILL.



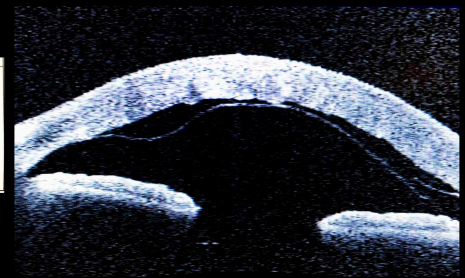
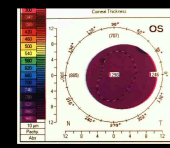
CASE PRESENTATION



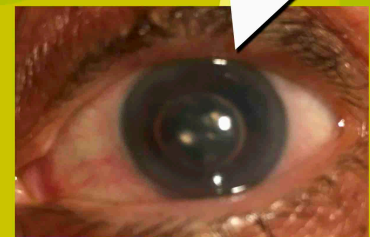CEIOL OS COMPLICATED BY DESCMET'S TEAR




POD#1	POW#1
20/15-1	20/CF@6"
+K	+DIFFUSE K
EDEMA/D-FOLDS, MOSTLY D-TEAR, COMPLETE TEMPORAL, WITH FOCAL D-TEAR (ATTACHED)	EDEMA, TEMPORAL D-DETACHMENT TO SCHWALBE'S LINE



POM#3
20/20
CLEAR CORNEA WITH TEMPORAL D-FOLD



PNEUMATIC DESCMETOPEXY WITH AIR - UNSUCCESSFUL



PNEUMATIC DESCMETOPEXY WITH SF6
IOP 49, SO PARACENTESIS BURPED
SF6 FILL LEFT FOR <24 HOURS

CONCLUSION

ANTERIOR SEGMENT OCT IS AN EFFECTIVE METHOD OF IDENTIFYING A DESCMET'S DETACHMENT AFTER CATARACT SURGERY.

SUCCESSFUL RE-ATTACHMENT OF DESCMET'S MEMBRANE MAY BE ACHIEVED WITH GOOD VISUAL RECOVERY UTILIZING PNEUMATIC DESCMETOPEXY AND SHORT-TERM GAS FILL.