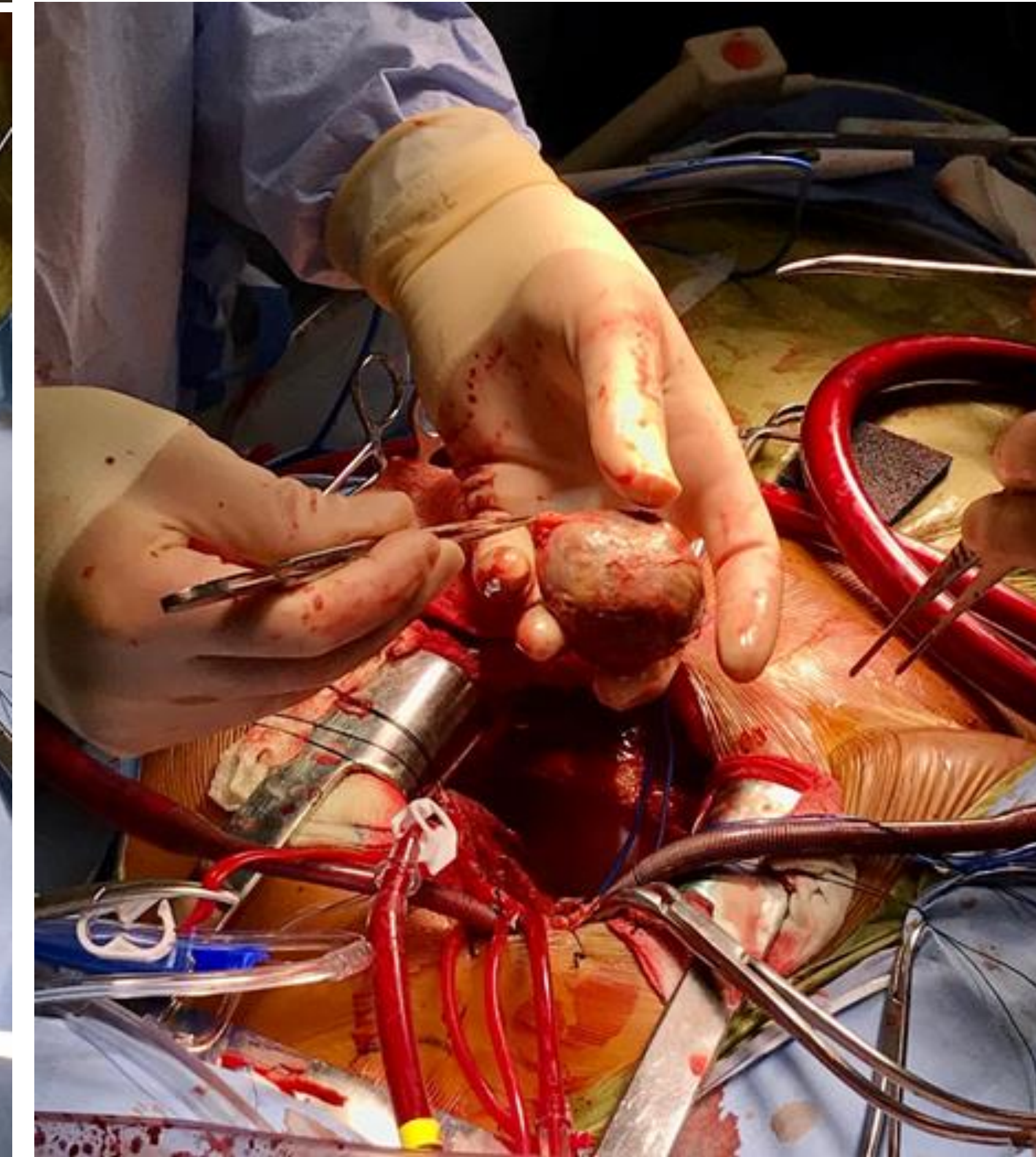
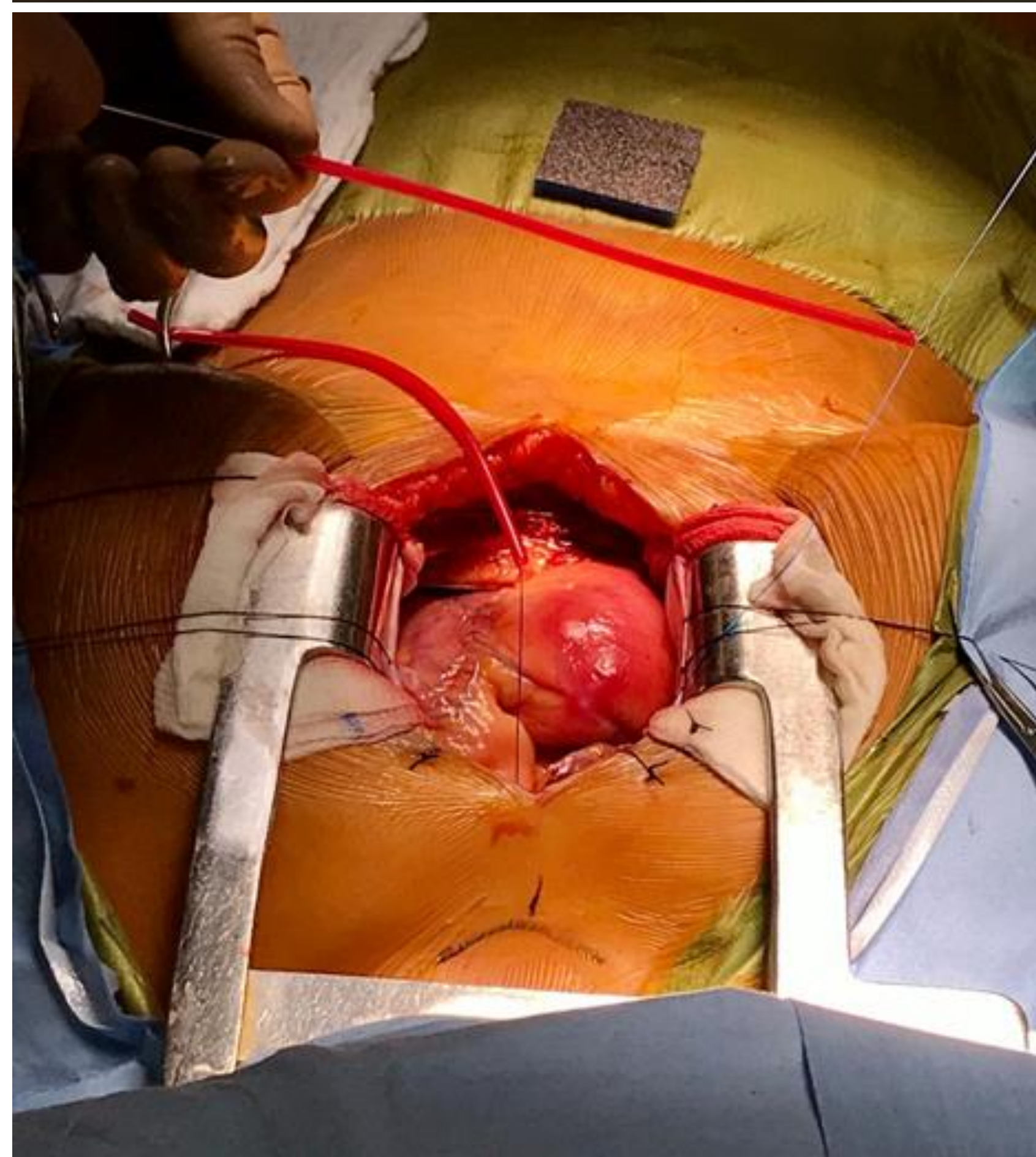
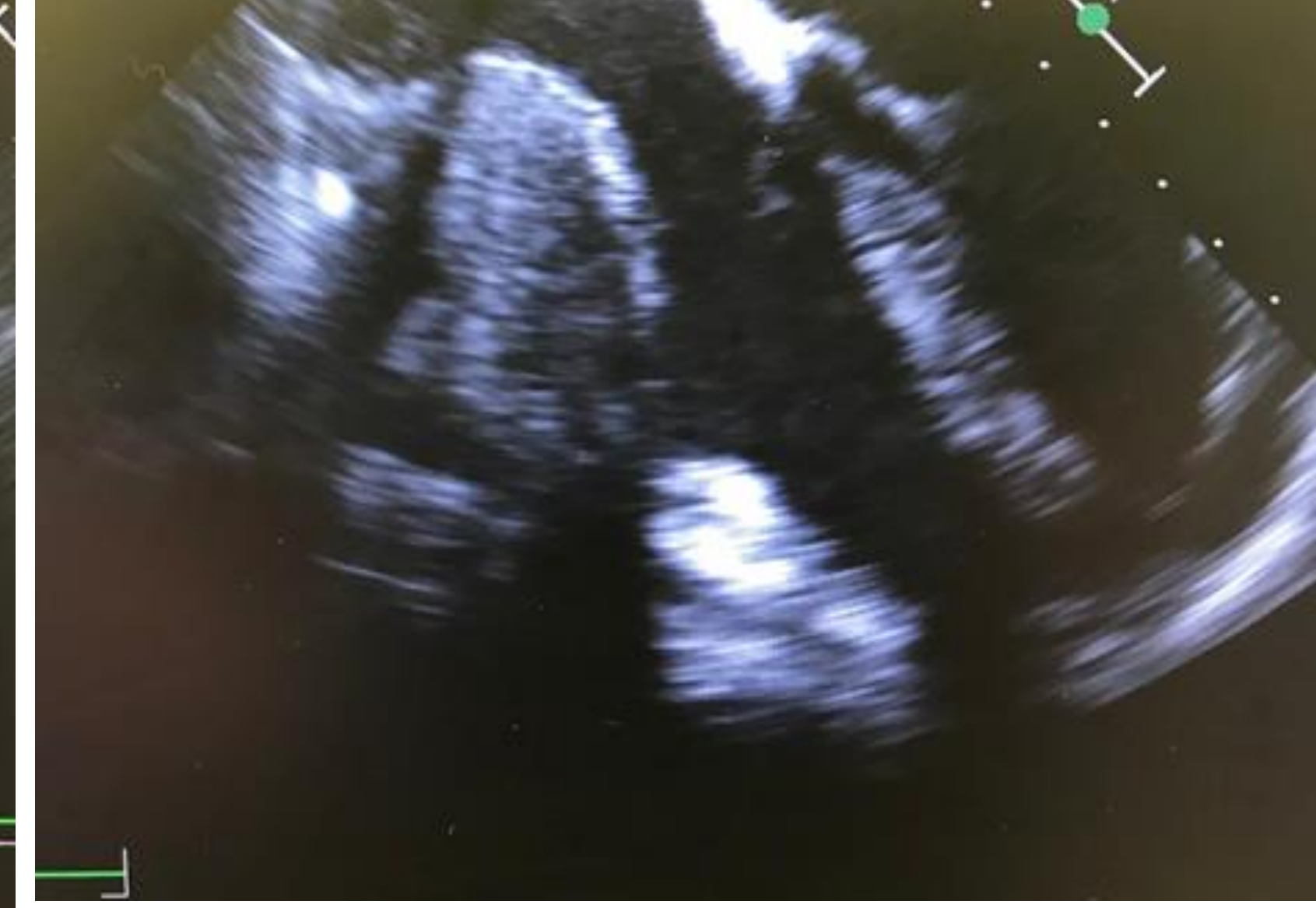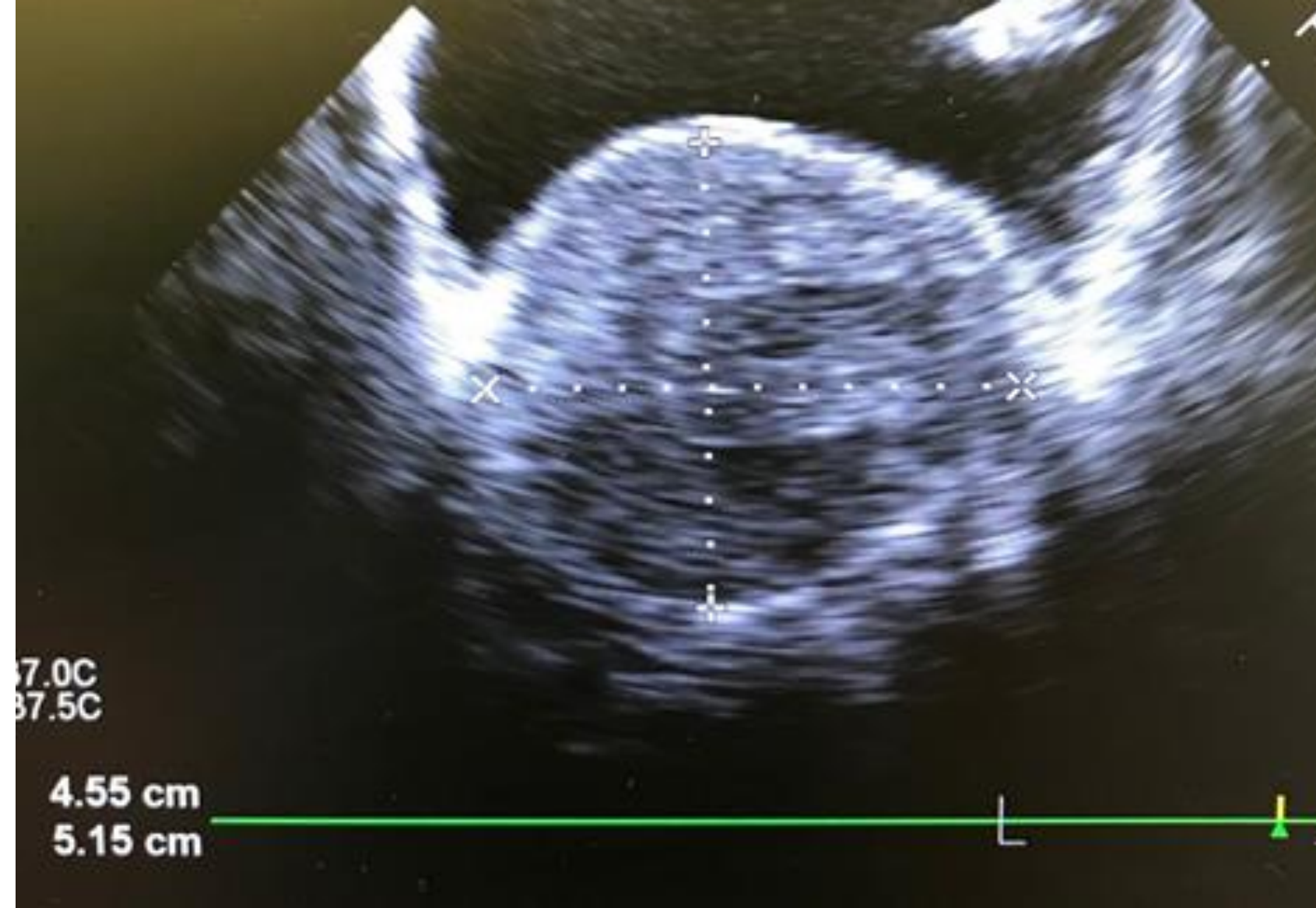


- Giant coronary artery aneurysms (CAA) compose a small subset of this pathology, with a reported prevalence of 0.1 – 0.2%.
- No universally accepted definition of giant CAA, though diameters of 20, 40, and 50mm have been proposed.
- Aneurysms > 50mm in diameter carry a prevalence of 0.02%.
- Right CAAs occur more commonly than left.
- CAA formation arises from wall defects in the media, predisposing atherosclerotic vessels to elastic compromise and eventually to aneurysm formation.
- Associated conditions include:
  - Congenital heart disease
  - Connective tissue diseases (Ehlers-Danlos, Marfan syndrome)
  - Vasculitides
  - Autoimmune disease (SLE)
  - Fibromuscular dysplasia
  - Iatrogenic formation (as a complication of PCI)
- Most CAAs are asymptomatic, though patients may present with angina, CHF, MI, tamponade, or sudden death.
- Giant CAAs may present with SVC syndrome or as a misdiagnosed mediastinal mass or cardiac tumor.
- Sequelae include thromboembolic disease, fistula formation, and rupture.

## REFERENCES

1. Crawley PD, Mahlow WJ, Huntsinger DR, Afiniwala S, Wortham DC. *Giant coronary artery aneurysms: review and update.* Tex Heart Inst J. 2014 Dec 1;41(6):603-608.
2. Naraen A, Reddy P, Notarstefano C, Kudavali M. *Giant Coronary Artery Aneurysm in a Middle- Aged Woman.* Ann Thorac Surg. 2017 Apr;103(4):313-315.



**Figures 1-2:** Intraoperative TEE showing giant right CAA measuring 52mm x 46mm (Fig 1) with extensive intraluminal thrombus and extracardiac compression of the RA, base of the RV, and tricuspid annulus (Fig 2).

**Figures 3-4:** Surgical approach. Once excised, the aneurysm was measured at 50mm x 80mm in the largest dimension.

- After initial...
- remained a...
- In early 20...
- and was re...
- General an...
- stable hem...
- Intraopera...
- The aneury...
- graft, and t...
- Following s...
- Her postop...
- postoperat...

## DISCUSS

- Induction o...
- patient wit...
- like sympto...
- A detailed l...
- however a...
- hemodynam...
- Reviewing...
- ventricular...
- Surgical ma...
- however so...
- Options inc...
- CABG, aneu...
- Percutaneo...
- In the abse...
- anticoagula...