

A CLINICAL EVALUATION OF CONE BEAM COMPUTED TOMOGRAPHY: IMPLICATIONS FOR
ENDODONTIC MICROSURGERY

by

Molly E. Kopacz, DDS
Lieutenant Commander, Dental Corps
United States Navy

A thesis submitted to the Faculty of the
Endodontic Graduate Program
Naval Postgraduate Dental School
Uniformed Services University of the Health Sciences
in partial fulfillment of the requirements for the degree of
Master of Science
in Oral Biology

June 2019

Distribution Statement

Distribution A: Public Release.

The views presented here are those of the author and are not to be construed as official or reflecting the views of the Uniformed Services University of the Health Sciences, the Department of Defense or the U.S. Government.

Naval Postgraduate Dental School
Uniformed Services University of the Health Sciences
Bethesda, Maryland

CERTIFICATE OF APPROVAL


MASTER'S THESIS

This is to certify that the Master's thesis of

Molly E. Kopacz

has been approved by the Examining Committee for the thesis requirement
for the Master of Science degree in Oral Biology at the June 2019 graduation.


Thesis Committee:



CDR Calvin Suffridge, D.D.S., M.S.
Chairman, Endodontics



CDR Jeff Neal, D.D.S., M.S.
Thesis Supervisor




Dr. Imamura, D.D.S., M.S.
Research Mentor

The author hereby certifies that the use of any copyrighted material in the thesis manuscript titled:

“A CLINICAL EVALUATION OF CONE BEAM COMPUTED TOMOGRAPHY:
IMPLICATIONS FOR ENDODONTIC MICROSURGERY”

is appropriately acknowledged and, beyond brief excerpts, is with the permission of the copyright owner.



Molly E. Kopacz
Endodontic Graduate Program
Naval Postgraduate Dental School
30 June 2019

NAVAL POSTGRADUATE DENTAL SCHOOL
MOLLY E. KOPACZ

2019

This thesis may not be re-printed without the expressed written permission of the author.

ABSTRACT

A CLINICAL EVALUATION OF CONE BEAM COMPUTED TOMOGRAPHY: IMPLICATIONS FOR ENDODONTIC MICROSURGERY

MOLLY E. KOPACZ
D.D.S., ENDODONTICS, 2019

Directed by: CDR CALVIN SUFFRIDGE, D.D.S., M.S.
Naval Postgraduate Dental School

Introduction: Cone-Beam Computed Tomography (CBCT) has become a valuable diagnostic tool for endodontics. Although the literature generally supports the accuracy of this imaging modality, some studies report that CBCT images may have limitations in representing the true clinical presentation. **Purpose:** This prospective, in vivo study compared limited field of view (LFOV) CBCT measurements to clinical measurements made during endodontic surgery.

Methods: Patients requiring endodontic surgery with a LFOV CBCT were asked to enroll in the study. Data collection, during the surgical and radiographic assessment, involved answering standardized questions evaluating multiple factors including the presence and dimensions of bony defects. During surgery, clinical data was collected and photographically documented. During the radiographic assessment, CBCT scans were evaluated by three calibrated, board certified specialists; two endodontists and one oral and maxillofacial radiologist. The clinical data was compared to data from CBCT interpretations and statistically analyzed. **Results:** The sample size of 83 teeth included 58 maxillary and 25 mandibular teeth from 77 subjects: 20 females and 57 males with an average age of 41 years old. The CBCT evaluators correctly identified the presence or absence of buccal plate fenestrations 92.2% of the time and had a kappa value of 0.84. The area of buccal plate fenestrations had to be at least 20.5 mm² in order to be visible on CBCT at least 90% of the time. This data was most reliable when the interval between scan and surgery is less than 100 days. **Conclusion:** Though useful in endodontic surgical treatment planning, based on the findings of this study, the LFOV CBCT overestimates the presence of bone and underestimates the size of fenestrations.

TABLE OF CONTENTS

CHAPTER		Page
I.	INTRODUCTION	7
II.	MATERIALS AND METHODS.....	9
III.	RESULTS	13
IV.	DISCUSSION.....	18
V.	CONCLUSIONS.....	22
REFERENCES	23

LIST OF FIGURES AND TABLES

Figure		Page
1.	CLINICAL DATA COLLECTION SHEET	10
2.	CLINICAL MEASUREMENTS ILLUSTRATION	10
3.	CLINICAL MEASUREMENTS EXAMPLE	11
4.	CLINICAL FINDINGS EXAMPLE	11
5.	LINEAR REGRESSION MODELS FOR FENESTRATION AREA	15
6.	LINEAR REGRESSION MODEL FOR MARGINAL BONE HEIGHT..	16
7.	FENESTRATION PRESENCE VS ABSCENSE AREA THRESHOLD .	16
8.	SMOOTHED DENSTIRY PLOT FOR LAG TIME.....	17
9.	FENESTRATION ACCURACY AND PRECISION	17

Table		Page
1.	CHACTERISTICS OF SUBJECTS	14
2.	FENESTRATION PRESCENSE VS ABSCENSE.....	14

I. INTRODUCTION

Endodontic microsurgery techniques have made many advancements in the past couple of decades to include use of the microscope, ultrasonic retro prep, bioceramic materials, and cone-beam computed tomography (CBCT) in order to become a minimally invasive procedure that results in faster

SIGNIFICANCE: When planning for endodontic microsurgery, CBCT should be used to help identify presence of fenestrations and fenestration area but limitations exist. These measurements are most reliable if time between scan and surgery is less than 100 days.

healing and improved outcomes. (1-4) The three-dimensional information gathered from CBCT is of particular relevance in endodontics and endodontic microsurgical planning as it helps the surgeon be prepared and achieve the best clinical outcome possible. In a recent study by Mota de Almeida et al, CBCT changed the endodontic diagnosis for 37% of the teeth and 42% of the patients in their study. (5) CBCT technology continues to improve but still has limitations such as scatter and beam hardening caused by high density neighboring structures. (6)

In 2001, NewTom introduced the first cone beam scanner for dental use. These devices employed the same controls found in conventional dental radiography units, such as tube voltage (kV), tube current (mA), and exposure time (s), but at a much lower radiation dose compared to medical CT. (6) In a recent systematic review, limited field of view (LFOV) 5x5cm or smaller CBCT median effective dose was 28.5 μ Sv compared to a 5.1-10.0cm or larger than 10cm, 69.9 μ Sv and 114 μ Sv respectively. (7) Conventional medical multi-slice computed tomography (MSCT) effective dose of the mandible or full head was around 500 μ Sv or 1000 μ Sv respectively, far above those of CBCT imaging. (8) Other advantages of CBCT over MSCT include the ability to capture a sharper image

and the CBCT field of view can be further collimated to increase resolution and decrease the area of exposure (large, medium, or focused). (9) A focused or LFOV CBCT, which covers an area of 5x5 cm or less, is sufficient for most endodontic purposes in order to best view small anatomical structures such as trabecular bone, periodontal ligament space, and root canal space. (10)

When treatment planning for endodontic surgery, a thorough understanding of the surgical site is essential. This may include the presence or absence of apical bony lesions, alveolar bone defects, perforation of cortical bone, missed root canals, presence of root fractures, adjacent anatomical structures, and previous procedural complications (i.e. fractured instrument, root perforation or extruded material). Traditional radiographic imaging modalities provide a two-dimensional representation of a three-dimensional surgical site, and thus hinder the clinician's ability to visualize all structures due to superimposition. This limitation can lead to misinterpretation during the treatment planning phase. (11, 12) The advent of CBCT has helped eliminate many of the limitations inherent to two-dimensional imaging modalities.

CBCT use in dentistry has been widely studied and is generally accepted as an accurate digital representation of the clinical scenario. Many investigations using simulated apical lesions in human cadaver models have shown that CBCT can accurately measure the volume of the lesions. (13-16) Similar studies have also established the accuracy of CBCT measurements of apical lesions in animal models. (17, 18) Despite multiple studies supporting the use of CBCT to detect apical lesions, Tsai et al. also noted that limitations exist when lesions are less than 1.4 mm in diameter.(16)

Likewise, many studies have used human cadaver models to determine the accuracy of CBCT in measuring the distance to adjacent anatomical structures, such as the maxillary sinus or the mandibular canal. (19-21) Other human cadaver models have used artificial landmarks to determine its accuracy.(22) Al-Ekrish et al. suggested that CBCT was limited in this regard, as its accuracy is operator dependent. (23)

To date, no human-use studies exist that compare LFOV CBCT measurements to clinical measurements documented during endodontic microsurgery. Understanding the accuracy of measurements obtained from LFOV CBCT interpretations can be of value to the clinician, particularly when determining the size of the periapical lesion, height of alveolar bone, and proximity to adjacent anatomic structures. The purpose of this prospective, *in vivo* study was to compare measurements from LFOV CBCT interpretations to clinical measurements taken intraoperatively during endodontic surgery.

II. MATERIALS AND METHODS

This Walter Reed National Military Medical Center IRB approved study (protocol #383684) was divided into four phases: diagnostic, surgical, radiographic interpretation, and data analysis.

Diagnostic Phase

All patients received a comprehensive endodontic evaluation following established clinical guidelines prior to receiving treatment. In cases where endodontic surgery was indicated, a LFOV CBCT was obtained in accordance with the 2015 AAЕ/AAOMR guidelines for CBCT use in endodontics. Patients were invited to participate in this study if they met the following inclusion criteria: eighteen years of age

A CLINICAL EVALUATION OF CONE BEAM COMPUTED TOMOGRAPHY

REGISTRY PATIENT # _____
Surgeon _____
Date _____
CBCT TAKEN _____
TOOTH # _____

Vertical bone height _____ mm. Take photo with perio probe _____
(Measured mid-buccal from CEJ) or crown margin to crestal bone)

Perforation of cortical plate? Yes / No Take photo with perio probe _____
Measurement: width _____ X height _____ mm.

Communication with sinus or other structures? (IA canal, mental foramen, infraorbital canal) Yes / No
_____ Take photo _____

Dimensions of lesion width _____ X height _____ X depth _____ mm.

Fracture? Yes / No **Type:** _____ Take photo _____

Untreated canal(s) located? Yes / No
_____ canal Take photo _____

Other findings
(fractured instruments, extruded material, root perforation, etc.) Take photo _____

FIGURE 1: clinical and radiographic data collection sheet

questions relevant to the procedure. All clinical measurements were made using a #15 UNC color-coded periodontal probe (Hu-Friedy LLC, Chicago, IL) to the nearest 0.5mm (Figure 2). All clinical measurements and other findings were photographed for documentation.

Immediately following flap reflection, the marginal bone height of the tooth receiving treatment was measured. This was defined as the distance between the cemento-enamel junction (CEJ) and the alveolar bone crest on the mid-facial surface of the tooth. In teeth restored with a crown, the measurement was taken from the restoration margin to the bone crest. If a submarginal flap was utilized, this data point

or older, required endodontic surgery, and a LFOV CBCT of the surgical area was acquired.

Surgical Phase

The surgical procedures were completed utilizing currently accepted microsurgical techniques. Clinical data were identified only by subject number and documented on a data collection sheet composed of 7 standardized questions (Figure 1). Clinical data varied from case to case and was collected only on those

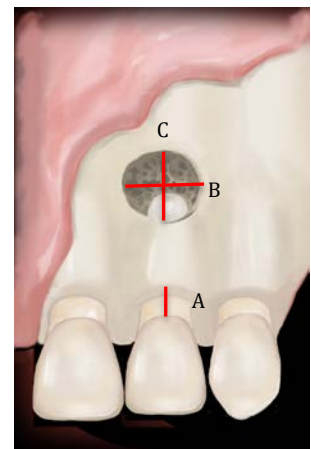


FIGURE 2: measurements a) vertical bone height b) fenestration width c) fenestration height

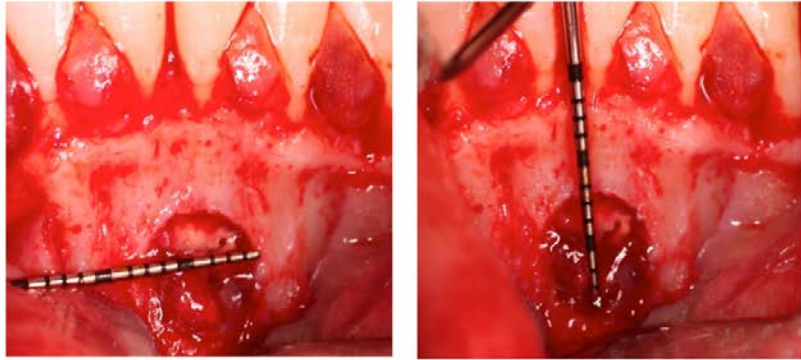


FIGURE 3: Clinical Photographs buccal bone perforation size (width and height)

was not recorded. No differentiation was made between vertical bone height and demonstrated dehiscence if one was present.

The presence or absence of a buccal cortical plate perforation located anywhere below the alveolar crest was identified and documented as a fenestration. A perforation was defined as an opening on the surface of the bone large enough to permit insertion of the periodontal probe. If a perforation was present, the height (coronal-apical) and width (mesial-distal) were measured at the points of greatest dimensions (Figure 3).

Several other data points were collected including communication with sinus or other structures; lesion height, width, and depth; fracture presence and type; untreated canals and location (Figure 4).

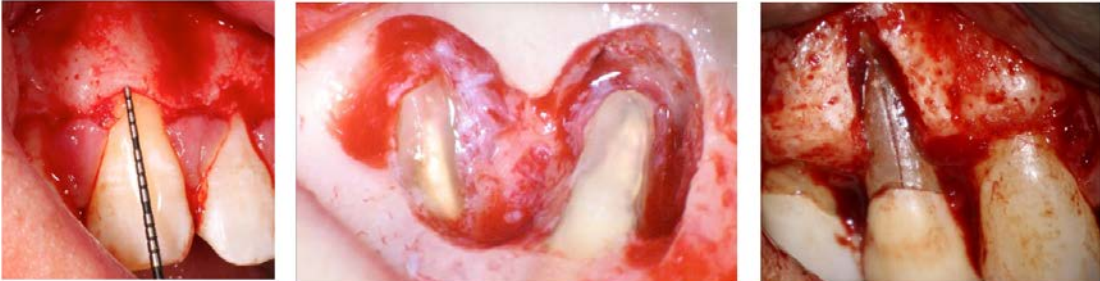

FIGURE 4: Clinical Photographs vertical bone height , communication with anatomic structures, and root fracture

Radiographic Interpretation Phase

All CBCT scans were taken with the Carestream 9300 (Carestream Dental LLC, Atlanta, GA) using the following exposure parameters: 85kV, 8 mA (females) of 10 mA (males), 10.8-20 seconds, field of view was 5cm x 5cm, 90 μ m voxel size. Each scan was anonymized and copied to a HP EliteBook Folio 1040 G3 Notebook PC (Hewlett Packard Enterprise, Palo Alto, CA) and then reviewed with CS 3D Imaging Software (Carestream Dental LLC, Atlanta, GA).

Two board certified endodontists and one board certified oral and maxillofacial radiologist evaluated the scans and provided radiographic interpretation of the data. Each examiner was calibrated individually and provided written instructions for use of the CS 3D software to collect the CBCT data.

Following the calibration, the examiners independently viewed the 77 CBCT scans. The orthogonal planes were aligned to each subject tooth so the axial plane was perpendicular, while the coronal and sagittal planes were parallel to the long axis so as to avoid any parallaxing errors. Measurements involving height (marginal bone height, perforation height, lesion height) were taken in the sagittal plane for anterior teeth and coronal plane for posterior teeth. Measurements involving width (perforation width, lesion width) and depth (lesion depth) were taken in the axial plane. The examiners were directed to scroll through the three planes when assessing for presence of root fractures or communication with adjacent anatomic structures. Measurements and other findings described in the calibration were recorded on separate radiographic interpretation data

sheets identified with the corresponding subject number and tooth. The radiographic data collected was then organized for statistical analysis.

Data Analysis Phase

During the data analysis phase, the clinical data and corresponding radiographic interpretation data were analyzed using R Core Team Software (R Foundation for Statistical Computing, Vienna, Austria, 2015). Categorical data in this study included: the presence of a buccal bone perforation, the presence of a root fracture, and communication with other structures (i.e. maxillary sinus or inferior alveolar nerve canal). These were analyzed for accuracy, sensitivity and specificity; and inter-rater agreement was represented with a kappa value. Continuous data included: buccal bone perforation size, lesion size, and marginal bone height. These were analyzed via linear regression models with intraclass correlation coefficients (ICC) calculated to represent inter-rater agreement. Lesion area was not included in this data analysis. A power analysis was performed and established the need for one hundred eleven (111) enrolled subjects.

III. RESULTS

Characteristics	No. of teeth
Age(y)	
18-30	23
31-40	16
41-50	22
51-60	7
>60	9
Sex	
Male	57
Female	20
Tooth Position	
Maxillary, anterior	29
Premolar	10
Molar	19
Mandibular, anterior	3
Premolar	4
Molar	18
Total	83

TABLE 1: Characteristics of subjects

77 subjects were prospectively consented and enrolled prior to endodontic surgery, 11 subjects were retrospectively enrolled but their data were not used for this analysis. 75 root-end endodontic microsurgeries and two surgical root resorption repair procedures were analyzed in this cohort. This included a total of 83 teeth; 58 of which were maxillary and 25 were mandibular. A total of 41 subjects involved buccal bone fenestrations, there were 83

marginal bone height measurements, and 11 vertical root fractures. Characteristics of the group are included in Table 1.

When evaluating for the detection of buccal bone fenestrations on CBCT (Table 2), there was a 92.2% accuracy, with 88% sensitivity (the ability to detect a perforation when

present) and 97% specificity (the ability to detect the absence of a perforation). The kappa score for this measurement was 0.84,

		Clinical		
		Absent	Present	
CBCT	Absent	35	5	40
	Present	1	36	37
		36	41	77

TABLE 2: Fenestration presence vs absence

indicating high agreement between the evaluators. Presence or absence of fenestration among the CBCT reviewers was determined by force consensus.

For the both buccal bone perforation area, the relationship between the CBCT evaluators' measurements and clinical measurements was plotted via linear regression models (Figure 5).

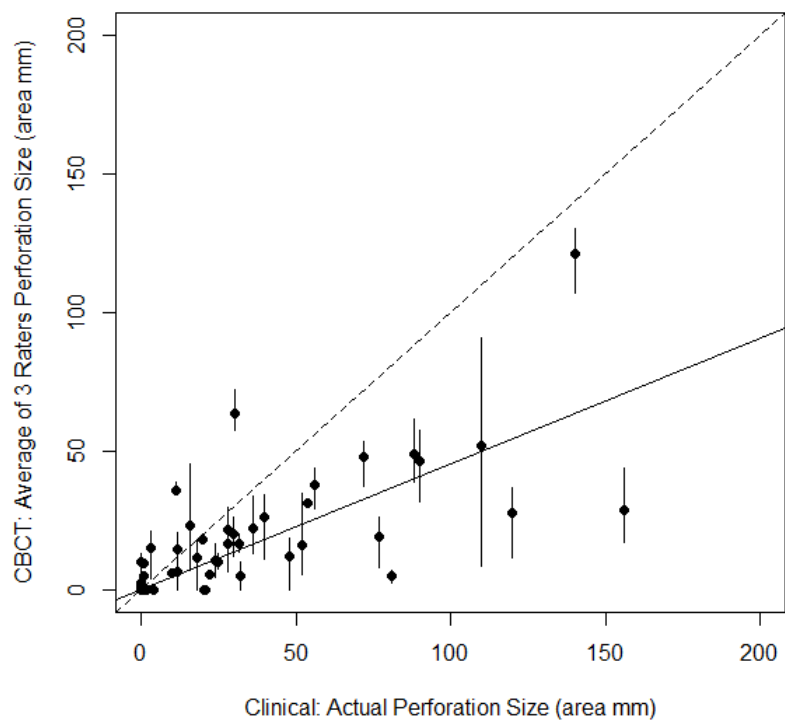
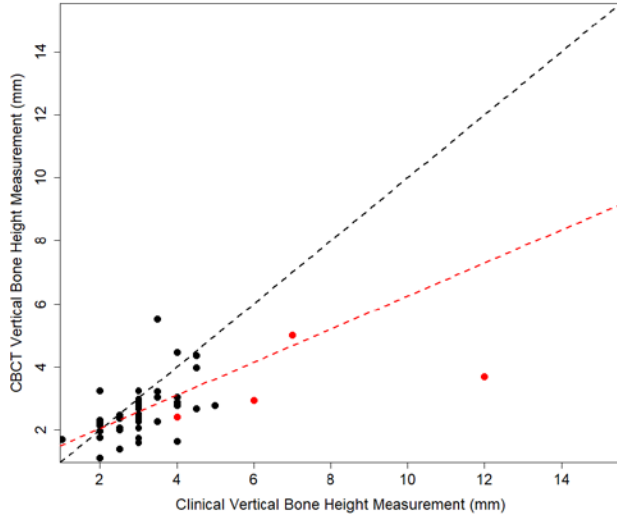


Figure 5 : Fenestration Area. Data points represent the average of the interpreters and the bars represent the deviations of the three interpreters.

The black dots represent the average of all three evaluators for a given measurement. As a reference, the black dashed line represents perfect agreement between the clinical and CBCT measurements; while the solid line represents the linear regression

drawn from the evaluators' interpretations. The evaluators had an intraclass correlation coefficient, or ICC, of 0.82 [.72-.89] $P < .0001$; which indicated strong agreement.



A linear regression model for vertical bone height (Figure 6) demonstrated CBCT measurements underestimated vertical bone loss versus the clinical measurements. As the slope of the linear regression for actual data fell below the ideal slope of one.

Figure 6: Vertical bone height measurements. Black data points represent average of the three interpreters. Red data points represent presence of dehiscence that was not detected by the interpreters when reading the CBCT. The black dashed line represents ideal slope of 1. Red dashed line represents the clinical data measurements adjust after removal of the 4 dehiscence data points.

When looking at a plot of the presence or absence of the fenestration vs the consensus on the CBCT finding, the size of the fenestration had to be at least 9.7 mm^2 (or about $3 \times 3 \text{ mm}$) in order for the fenestration to be visible on CBCT at least 50% of the time. To be accurate 90% of the time, the fenestration had to be at least 20.5 mm^2 (or about $4 \times 5 \text{ mm}$).

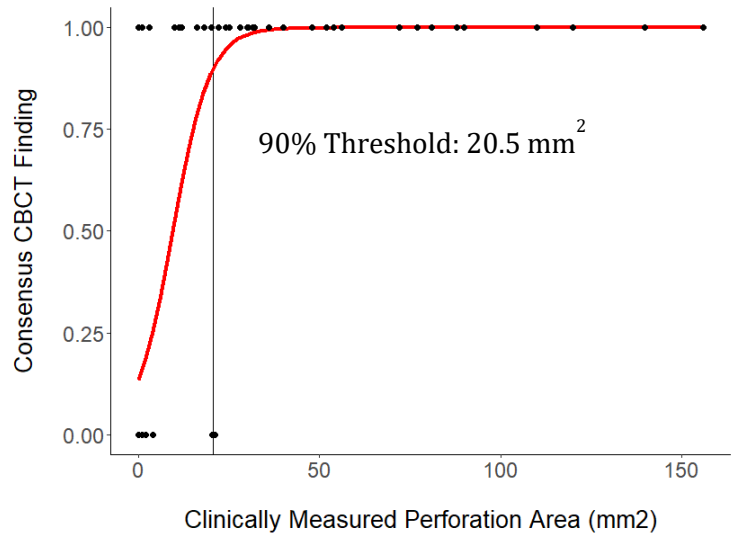


Figure 7: Fenestration presence vs absence. 90% threshold: 20.5 mm^2 . 50% threshold- 9.7 mm^2 .

A smoothed density plot showing the amount of lag time (in days) between the CBCT and the actual surgery versus the density or frequency of the number of cases. A CBCT and Surgery that occurred on exactly the same day are represented on the left side of the plot and 300 or more days between CBCT and surgery are on the right side. Most of the surgeries were performed within 100 days of the CBCT scan but there were some outliers with delays between CBCT and surgery of over 300 days. The calculated median lag time between scan and surgery was 55 days.

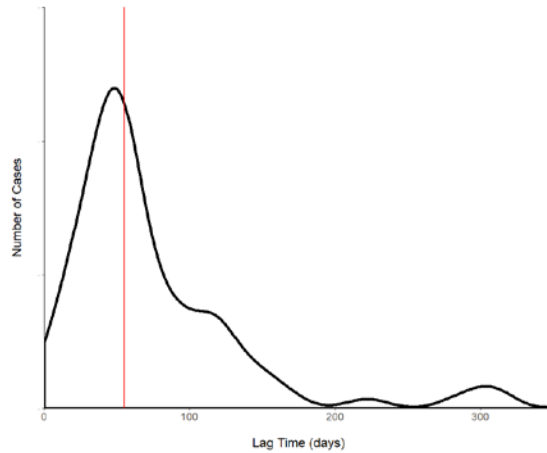


Figure 8: Lag time between scan and surgery. Red vertical line represents median lag time of 55 days.

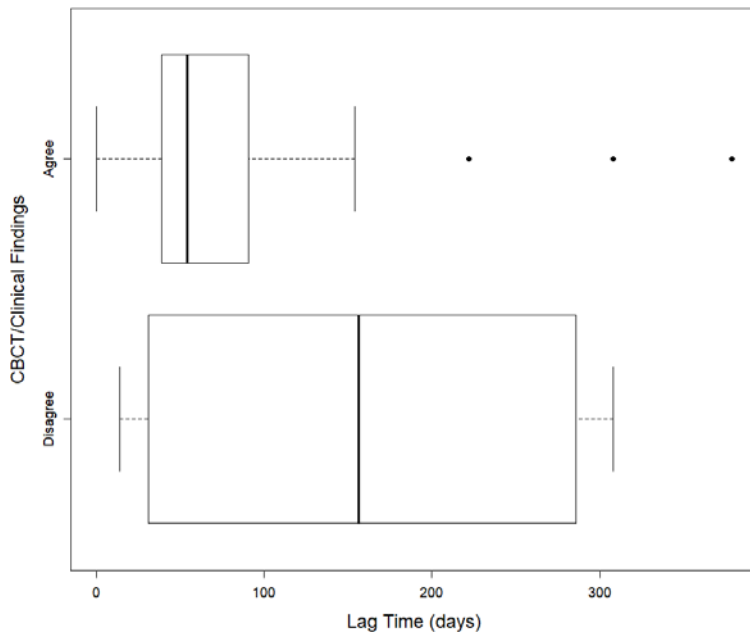


Figure 9: Fenestration accuracy and precision. Agreement represents true negatives and true positives. Disagreement represents false negatives and false positives.

A box and whisker plot helps us visualize the CBCT accuracy and reliability as it relates to lag time between CBCT scan and surgery. In the 71 cases that the surgical scenario agreed with interpretation of the CBCT scan, the data was precise and accurate. In the 6 cases that the surgical scenario

did not agree with the interpretation of the CBCT scan, the data was neither precise nor accurate as represented by the wide distribution of the red box. This suggests decreasing lag time between scan and surgery will increase accuracy of the scan.

For detection of root fractures, the sensitivity was determined to be 0%, indicating evaluators could not detect root fractures when one was clinically present. However, a high specificity was noted at 100%, which represented the ability to detect the absence of a root fracture. A kappa score of 0 indicated no agreement among evaluators.

Only 2 clinical cases presented with communication with other structures, one involving the maxillary sinus and one involving the inferior alveolar nerve canal. There were 6 cases where at least one evaluator interpreted a communication with another anatomic structure when one was not present clinically. For the sake of this interim analysis, these data points were not analyzed with the hope that similar cases will present and allow for better analysis as the study continues to enroll subjects.

IV. DISCUSSION

Endodontic surgery requires an appreciation of regional anatomy to avoid adverse outcomes, such as damage to adjacent teeth and other vital structures. To aid in treatment planning, LFOV CBCT is often utilized to visualize the surgical site in three dimensions and provide more accurate measurements than two-dimensional imaging.(6) The imaging modality also allows the practitioner enhanced preparedness by providing a more in-depth view of the bony architecture.

All of the factors listed above were observed in this study; more specifically, the presence or absence of buccal bone fenestrations and their area, vertical bone height, the

presence or absence of root fractures, and communication with adjacent anatomical structures (such as the maxillary sinus or inferior alveolar nerve canal).

The accuracy of CBCT in representing alveolar bone defects has also been widely studied with mixed results, utilizing both human cadaver and animal models. Timock et al. determined the modality to be accurate when measuring the height and thickness of alveolar bone. (24) When detecting the presence of a fenestration or dehiscence in a dry human skull model for orthodontic purposes, Leung et al. found CBCT to have a very low positive predictive value of 0.25, (presence of fenestration) and a high negative predictive value of 0.98, the probability that a negative test result (absence of fenestration) was truly negative. The positive predictive value for dehiscence was only 0.51 and the negative predictive value was 0.93. (25)

Very few *in vivo* studies have compared CBCT measurements with intraoperative findings. Behnia et al. compared buccal bone thickness during surgical extraction of maxillary anterior teeth and found that CBCT's accuracy was limited when the bone is thinner than 1mm. (26) Banodkar et al. compared periodontal bone defects on CBCT with intraoperative findings and found CBCT to be highly accurate in identifying and quantifying periodontal bone loss for both horizontal and vertical defects. (27) In a similar periodontal study evaluating bone height by Grimard et al., CBCT measurements underestimated the surgical measurements by 0.9 +/- 0.8 mm.(28) In a recent meta-analysis and systematic review by Haas et al., the mean difference between CBCT and in situ evaluation for the measurement of alveolar bone loss was -0.10 [-0.39, 0.19] with a 95% confidence interval, a clinically irrelevant measurement. (29) A prospective, surgical study that compared bone thinner than 0.5mm in cystic-space to CBCT with

large FOV in an oral surgery model found CBCT imaging to be unreliable in showing thin bony structures. (30)

The findings in this study compared favorably with the findings of Haas et al., in that CBCT was accurate when measuring marginal bone height and Misch et al. who found that CBCT tended to over-estimate the amount of alveolar bone present.(29, 31) This study found that LFOV CBCT underestimated the actual size of fenestration.

Agreement between radiographic interpretation is an important factor in this data analysis and helps a clinician's confidence in their reliability when interpreting CBCTs. Two board certified Endodontists and one board certified Oral and Maxillofacial radiologist interpreted the data for this research. During the data collection portion of this study, the Oral Radiologist consistently gave a more detailed interpretation of the CBCT than the endodontists as is reflected in each's training. Most Oral Radiology training programs include two years of training to perform and interpret CBCT, MRI, and medical CT with opportunities for interdisciplinary collaboration with Oral Medicine, Oral Surgery, and Neuroradiology. Categorical data such as yes/no questions or communication with anatomic structures (maxillary sinus, IAN canal, nasopalatine duct) is analyzed with the kappa statistic, whereas continuous data is analyzed with the ICC.

The Oral Radiologist was the only radiographic interpreter that was truly blinded when collecting data as the two endodontic interpreters were also involved in a number of the surgical procedures and therefore may have seen the cases clinically before being asked to radiographically interpret what was seen on the CBCT.

LFOV CBCT also has inherent limitations that must be considered. This includes artifacts, which can obscure portions of the image and make analysis difficult or

impossible; and parallax which causes objects to appear different when viewed from different angles. The effects of parallax were minimized in the calibration process by ensuring that each evaluator was viewing the respective object in the same plane. Partial volume averaging must also be considered as its effects can lead to misrepresentation of hard tissue such as periodontal bone support. (32, 33) Misinterpretation of LFOV CBCT, in this regard, may lead the practitioner to think a given tooth lacks sufficient bone support and unnecessarily give the tooth an unfavorable prognosis. Understanding LFOV CBCT's limitations may help preserve teeth that may otherwise be extracted.

In this study, LFOV CBCT was able to accurately detect the presence or absence of buccal bone perforations. This is of particular importance to the endodontist during root-end surgical procedures, as locating the end of the root may prove challenging if buccal bone is intact. LFOV CBCT offers the surgeon greater foresight in cases like these and helps preserve bone and tooth structure that may otherwise be unnecessarily removed.

This study included various cases of periapical lesions including multiple teeth whose lesions communicated with each other or other possible anatomic structures such as the maxillary sinus, inferior alveolar canal, or nasopalatine canal. Additionally, numerous operators were involved in the clinical data collection which weakens the data by introducing error between operators. In an effort to control error, operators were calibrated to take measurements of the largest part of the lesions. Photo documentation was used to compare measurement techniques at time of data collection. Often times, exact dimensions of the bone defects during surgical procedures cannot be done without first disturbing the lesion by enlarging the osteotomy. Therefore, the clinical

measurements were not necessarily representative of the true size of the periapical lesions as was the case for similarly designed studies such as Song et al and von Arx et al (34, 35). For these reasons, we did not include analysis of the size of periapical lesions for the purposes of this study.

V. CONCLUSIONS

The presence or absence of buccal bone perforations was accurately assessed by the LFOV CBCT evaluators in this study, however, their interpretations demonstrated that LFOV CBCT misrepresented the amount of bone in a number of diagnostic situations by overestimating the actual amount of bone present and underestimating the size of fenestrations. Fenestration size of 20.5 mm² was needed to be visible on CBCT 90% of the time. CBCT is most reliable when the interval between scan and surgery is less than 100 days. Based on these inconsistencies, CBCT should only be used as an adjunct to clinical findings when treatment planning for endodontic surgery. In summary, limited field of view cone beam computed tomography should not be considered the “gold standard” as this could lead to faulty diagnosis and prognosis, but understanding its limitations can help providers better understand the surgical field prior to surgery.

Future *in vivo* studies should measure bone thickness as it relates to fenestrations and CBCT accuracy.

References

1. Floratos S, Kim S. Modern Endodontic Microsurgery Concepts: A Clinical Update. *Dent Clin North Am* 2017;61(1):81-91.
2. Kim S, Kratchman S. Modern endodontic surgery concepts and practice: a review. *Journal of endodontics* 2006;32(7):601-623.
3. Cotton TP, Geisler TM, Holden DT, Schwartz SA, Schindler WG. Endodontic applications of cone-beam volumetric tomography. *Journal of endodontics* 2007;33(9):1121-1132.
4. Tsesis I, Rosen E, Taschieri S, Telishevsky Strauss Y, Ceresoli V, Del Fabbro M. Outcomes of surgical endodontic treatment performed by a modern technique: an updated meta-analysis of the literature. *Journal of endodontics* 2013;39(3):332-339.
5. Mota de Almeida FJ, Knutsson K, Flygare L. The impact of cone beam computed tomography on the choice of endodontic diagnosis. *Int Endod J* 2015;48(6):564-572.
6. Patel S. New dimensions in endodontic imaging: Part 2. Cone beam computed tomography. *Int Endod J* 2009;42(6):463-475.
7. Al-Okshi A, Lindh C, Sale H, Gunnarsson M, Rohlin M. Effective dose of cone beam CT (CBCT) of the facial skeleton: a systematic review. *Br J Radiol* 2015;88(1045):20140658.
8. Loubele M, Bogaerts R, Van Dijck E, Pauwels R, Vanheusden S, Suetens P, et al. Comparison between effective radiation dose of CBCT and MSCT scanners for dentomaxillofacial applications. *Eur J Radiol* 2009;71(3):461-468.
9. Patel S, Dawood A, Whaites E, Pitt Ford T. New dimensions in endodontic imaging: part 1. Conventional and alternative radiographic systems. *Int Endod J* 2009;42(6):447-462.
10. Hassan BA, Payam J, Juyanda B, van der Stelt P, Wesselink PR. Influence of scan setting selections on root canal visibility with cone beam CT. *Dentomaxillofac Radiol* 2012;41(8):645-648.
11. Low KM, Dula K, Burgin W, von Arx T. Comparison of periapical radiography and limited cone-beam tomography in posterior maxillary teeth referred for apical surgery. *Journal of endodontics* 2008;34(5):557-562.
12. Bornstein MM, Lauber R, Sendi P, von Arx T. Comparison of periapical radiography and limited cone-beam computed tomography in mandibular molars for analysis of anatomical landmarks before apical surgery. *Journal of endodontics* 2011;37(2):151-157.
13. Patel S, Dawood A, Mannocci F, Wilson R, Pitt Ford T. Detection of periapical bone defects in human jaws using cone beam computed tomography and intraoral radiography. *Int Endod J* 2009;42(6):507-515.
14. Kamburoglu K, Kilic C, Ozen T, Horasan S. Accuracy of chemically created periapical lesion measurements using limited cone beam computed tomography. *Dentomaxillofac Radiol* 2010;39(2):95-99.
15. Liang YH, Jiang L, Gao XJ, Shemesh H, Wesselink PR, Wu MK. Detection and measurement of artificial periapical lesions by cone-beam computed tomography. *Int Endod J* 2014;47(4):332-338.
16. Tsai P, Torabinejad M, Rice D, Azevedo B. Accuracy of cone-beam computed tomography and periapical radiography in detecting small periapical lesions. *Journal of endodontics* 2012;38(7):965-970.
17. Ahlowalia MS, Patel S, Anwar HM, Cama G, Austin RS, Wilson R, et al. Accuracy of CBCT for volumetric measurement of simulated periapical lesions. *Int Endod J* 2013;46(6):538-546.
18. Esposito SA, Huybrechts B, Slagmolen P, Cotti E, Coucke W, Pauwels R, et al. A novel method to estimate the volume of bone defects using cone-beam computed tomography: an in vitro study. *Journal of endodontics* 2013;39(9):1111-1115.

19. Howe RB. First molar radicular bone near the maxillary sinus: a comparison of CBCT analysis and gross anatomic dissection for small bony measurement. *Oral Surg Oral Med Oral Pathol Oral Radiol Endod* 2009;108(2):264-269.
20. Kim TS, Caruso JM, Christensen H, Torabinejad M. A comparison of cone-beam computed tomography and direct measurement in the examination of the mandibular canal and adjacent structures. *Journal of endodontics* 2010;36(7):1191-1194.
21. Adibi S, Paknahad M. Comparison of cone-beam computed tomography and osteometric examination in preoperative assessment of the proximity of the mandibular canal to the apices of the teeth. *Br J Oral Maxillofac Surg* 2017;55(3):246-250.
22. Moshfeghi M, Tavakoli MA, Hosseini ET, Hosseini AT, Hosseini IT. Analysis of linear measurement accuracy obtained by cone beam computed tomography (CBCT-NewTom VG). *Dent Res J (Isfahan)* 2012;9(Suppl 1):S57-62.
23. Al-Ekrish AA, Ekram M. A comparative study of the accuracy and reliability of multidetector computed tomography and cone beam computed tomography in the assessment of dental implant site dimensions. *Dentomaxillofac Radiol* 2011;40(2):67-75.
24. Timock AM, Cook V, McDonald T, Leo MC, Crowe J, Benninger BL, et al. Accuracy and reliability of buccal bone height and thickness measurements from cone-beam computed tomography imaging. *Am J Orthod Dentofacial Orthop* 2011;140(5):734-744.
25. Leung CC, Palomo L, Griffith R, Hans MG. Accuracy and reliability of cone-beam computed tomography for measuring alveolar bone height and detecting bony dehiscences and fenestrations. *Am J Orthod Dentofacial Orthop* 2010;137(4 Suppl):S109-119.
26. Behnia H, Motamedian SR, Kiani MT, Morad G, Khojasteh A. Accuracy and reliability of cone beam computed tomographic measurements of the bone labial and palatal to the maxillary anterior teeth. *Int J Oral Maxillofac Implants* 2015;30(6):1249-1255.
27. Banodkar AB, Gaikwad RP, Gunjekar TU, Lobo TA. Evaluation of accuracy of cone beam computed tomography for measurement of periodontal defects: A clinical study. *J Indian Soc Periodontol* 2015;19(3):285-289.
28. Grimard BA, Hoidal MJ, Mills MP, Mellonig JT, Nummikoski PV, Mealey BL. Comparison of clinical, periapical radiograph, and cone-beam volume tomography measurement techniques for assessing bone level changes following regenerative periodontal therapy. *Journal of periodontology* 2009;80(1):48-55.
29. Haas LF, Zimmermann GS, De Luca Canto G, Flores-Mir C, Correa M. Precision of cone beam CT to assess periodontal bone defects: a systematic review and meta-analysis. *Dentomaxillofac Radiol* 2018;47(2):20170084.
30. Thonissen P, Ermer MA, Schmelzeisen R, Gutwald R, Metzger MC, Bittermann G. Sensitivity and specificity of cone beam computed tomography in thin bony structures in maxillofacial surgery - A clinical trial. *Journal of cranio-maxillo-facial surgery : official publication of the European Association for Cranio-Maxillo-Facial Surgery* 2015;43(7):1284-1288.
31. Misch KA, Yi ES, Sarment DP. Accuracy of cone beam computed tomography for periodontal defect measurements. *Journal of periodontology* 2006;77(7):1261-1266.
32. Molen AD. Considerations in the use of cone-beam computed tomography for buccal bone measurements. *Am J Orthod Dentofacial Orthop* 2010;137(4 Suppl):S130-135.
33. Sun Z, Smith T, Kortam S, Kim DG, Tee BC, Fields H. Effect of bone thickness on alveolar bone-height measurements from cone-beam computed tomography images. *Am J Orthod Dentofacial Orthop* 2011;139(2):e117-127.
34. Song M, Kim SG, Shin SJ, Kim HC, Kim E. The influence of bone tissue deficiency on the outcome of endodontic microsurgery: a prospective study. *Journal of endodontics* 2013;39(11):1341-1345.

35. von Arx T, Hanni S, Jensen SS. Correlation of bone defect dimensions with healing outcome one year after apical surgery. *Journal of endodontics* 2007;33(9):1044-1048.