



# Enhancing Early Nerve Regeneration from Reconstruction of Segmental Nerve Injury with Polyethylene Glycol



Alejandro Bernal, MD<sup>1</sup>, Casey Sabbag, MD<sup>1</sup>, Julia AV Nuelle, MD<sup>2</sup>, Cody Hinshaw, BS<sup>1</sup>, Jennifer Hinshaw, BS<sup>1</sup>, Cathy Yang, PhD<sup>3</sup>, Margaux M Salas, PhD<sup>1</sup>, Wensheng Zhang, MD, PhD<sup>1</sup>, George Bittner, PhD<sup>3</sup>, Jaimie Shores, MD<sup>4</sup>, Erik K. Weitzel, MD<sup>1</sup>, Joseph F. Alderete, MD<sup>1</sup>

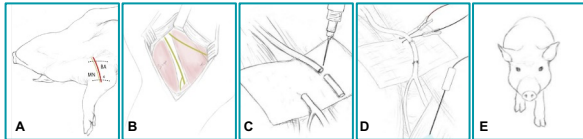
(1) RESTOR-FUSE Nerve Reconstruction Consortium, US Army Institute of Surgical Research & 59th MDW, San Antonio, TX (2) University of Missouri, Columbia, MO (3) University of Texas at Austin, Austin, TX (4) Johns Hopkins University, Baltimore, MD

## BACKGROUND

- Restoration of lost motor and sensory functions remain poor using current methods and conventional techniques, especially for segmental-loss peripheral nerve injuries (PNIs) despite advancements in modern medicine.
- Our previous nerve repair studies using polyethylene glycol (PEG) have shown promise in successive small animal models.
- In this study, we sought to further optimize the PEG fusion-based therapies for large-gap PNIs using a porcine model of median nerve allotransplantation.
- Standardization of peripheral nerve allograft procedures, nerve reconstructive treatment and functional assessment in the larger porcine model will enhance transition of PEG technologies to clinical trials.

## METHODS

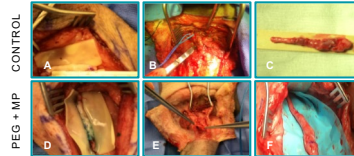
- 15 donor median peripheral nerve allografts (PNA) procured and preserved in calcium free hypotonic solution.
- 15 other Yucatan swine (randomly divided into 4 groups) undergo neurorrhaphy using a preserved median PNA.
- Treatment (Rx) groups compared with a control group.
- Rx groups: (1) PEG; (2) PEG + MP; (3) 72hr preserved PNA.
- PNA ed 2 weeks post-op for histopathologic analysis.



**Simplified Procedure.** (A) Positioning and marking; (B) target nerve isolation; (C) Neurorrhaphy with or without methylene blue (MB), PEG, and methylprednisolone (MP) depending on group; (D) Set up for electrodiagnostic compound muscle action potential (receiver placed within flexor carpi radialis; FCR); (E) gait analysis with 2 cameras in front to view frontal plane and on right side of animal to view sagittal plane.

## RESULTS

### REDUCED POST-OP INFLAMMATION IN PEG-TREATED MP GROUP



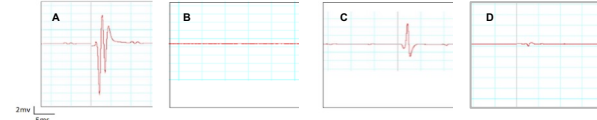
**Gross Comparison.** (A) Post neurorrhaphy; (B) EOS mod-severe inflammation and fibrosis; (C) EOS allograft mod-severe inflammatory/hemorrhagic injury with undistinguishable nerve-fibrotic layers. (D) Post neurorrhaphy; (E) EOS mild inflammation and fibrosis; (F) EOS allograft demonstrating mild inflammation with distinguishable separation between nerve-fibrotic layers.

### REDUCED HOOF INVERSION IN PEG-TREATED GROUPS



**Gait Comparison.** (A) Pig without PEG demonstrating moderate-severe medial hoof inversion (B) Pig with PEG (-MP) demonstrating mild medial hoof inversion (C) Pig with PEG (+MP) demonstrating lack of hoof deviation

### SUPERIOR CMAP RESPONSE IN PEG-TREATED MP GROUP

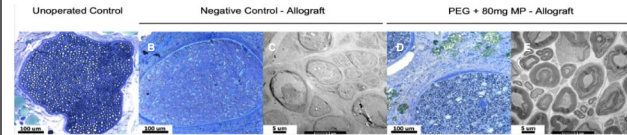


**Morphologic Comparison.** (A)(B) Pre-neurorrhaphy & post-transected median nerve, respectively; (C) PEG + MP, 2 wk CMAP; vs (D) Control, 2 wk CMAP.

## RESULTS

- Quality of stimulated FCR muscle contraction, at end of study, best demonstrated in PEG-treated compared to control group.
- Hoof inversion not witnessed in PEG + MP group.
- Baseline changes regarding time to- and max angle- flexion most reduced in PEG + MP group.
- Prevalence of donor PNA axonal survival and distal host median n. survival best illustrated in PEG-treated compared to control.

### INCREASED AXON SURVIVAL IN PEG-TREATED GROUP



**Histological PNA Comparison.** (A) Transected nerve without neurorrhaphy used for baseline; (B & C) Control group; (D & E) PEG + MP group. Representative images of TEM analysis.

## CONCLUSION

- Preliminary data indicate the potential success of PEG fusion protocols to enhance recovery from segmental-loss PNIs, with superior results shown in PEG+MP group.
- This translational porcine model provides a procedural outline for PEG fusion-PNA reconstruction as well as a framework for assessment of nerve regeneration and functional restoration.

## DISCLAIMER

The views expressed are those of the author(s) and do not reflect the official views or policy of the Department of Defense or its Components. The experiments reported herein were conducted according to the principles set forth in the National Institute of Health Publication No.80-23, Guide for the Care and Use of Laboratory Animals and the Animal Welfare Act of 1966, as amended before the Background.

**Author Disclosure Information:** Authors have no conflicts of interest to disclose.