

AD-A033 601

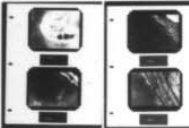
ARMY INST OF DENTAL RESEARCH WASHINGTON D C
CHONDROMA OF THE TONGUE. (U)
DEC 76 C E DEL RIO

F/G, 6/5

UNCLASSIFIED

NL

1 OF 1
AD
A033601



END

DATE

FILMED

2-77

ADA033601

REPORT DOCUMENTATION PAGE		READ INSTRUCTIONS BEFORE COMPLETING FORM
1. REPORT NUMBER	2. GOVT ACCESSION NO. DA OH 6030	3. RECIPIENT'S CATALOG NUMBER
4. TITLE (and Subtitle) 6 Chondroma of the Tongue	1	5. TYPE OF REPORT & PERIOD COVERED Manuscript for publication June 75 - December 76
AUTHOR(s) 10 Carlos E./del Rio		6. PERFORMING ORG. REPORT NUMBER
PERFORMING ORGANIZATION NAME AND ADDRESS JS Army Institute of Dental Research Walter Reed ARmy Medical Center Washington, D. C. 20012		8. CONTRACT OR GRANT NUMBER(s) 16
CONTROLLING OFFICE NAME AND ADDRESS 9 Rept. for Jun 75 - Dec 76		10. PROGRAM ELEMENT, PROJECT, TASK AREA & WORK UNIT NUMBERS 62775A, 35762775A825 Task Area 80 Work Unit 004
4. NUMBER OF PAGES 12 14p.	11	12. REPORT DATE 3 December 1976
		13. NUMBER OF PAGES 9
		15. SECURITY CLASS. (of this report) Unclassified
		15a. DECLASSIFICATION/DOWNGRADING SCHEDULE
6. DISTRIBUTION STATEMENT (of this Report) This document has been approved for public release and sale; its distribution is unlimited.		
17. DISTRIBUTION STATEMENT (of the abstract entered in Block 20, if different from Report)		
18. SUPPLEMENTARY NOTES		
19. KEY WORDS (Continue on reverse side if necessary and identify by block number) Chondroma; Tongue; Diagnosis 1 This paper reports a		
20. ABSTRACT (Continue on reverse side if necessary and identify by block number) A rare case is reported of chondroma in the right, posterior, ventral surface of the tongue. Possible etiology is discussed, and the method of treatment described. A		

DDC
RECEIVED
DEC 16 1976
RECEIVED
A

038670-
AB

CHONDROMA OF THE TONGUE:

A CASE REPORT

**Carlos E. del Rio, BS, DDS, Colonel U. S. Army
Chief, Division of Clinical Research
Director of Endodontic Residency
U.S. Army Institute of Dental Research
Washington, D.C. 20012**

101
102
103
104
105
106
107
108
109
110
111
112
113
114
115
116
117
118
119
120

A

1

A rare case is reported of chondroma in the right, posterior, ventral surface of the tongue. Possible etiology is discussed, and the method of treatment described.

✓ Chondroma is a benign neoplasm of cartilage which occurs rarely in the oral cavity. It is so uncommon in the tongue that only sixteen cases have been reported in the literature. → (cont on p 1473A)

Pless reviewed the literature up to 1934, and reported a case of a chondroma localized at the tip of the tongue.⁽¹⁾ His review included the cases from: Berry, who in 1892 reported a chondroma of five years duration in the lateral border of the tongue of a forty-nine year old male; Lang, who in 1892 described a sessile cartilaginous tumor of twenty years duration in the tongue of a twenty-two year old female; Routier, who in 1905 reported a chondroma of four years duration in the right border of the tongue of a twenty-one year old female; Capus and Ertzbeschoff, also in 1905, who reported a case of a 3cm by 2cm chondroma in the right anterior border of the tongue; Huie, who in 1927 described a tumor measuring 13cm by 10cm which provoked catarrhal symptoms, dysphonia, and dysphagia in a female, and Gentscheff, in 1934, who reported various cartilaginous nodules of the tongue.⁽²⁾ & ⁽⁶⁾

Johns reported in 1942 a twenty year asymptomatic cartilaginous nodule in the right lingual border of the tongue.⁽²⁾ Bruce and McDonald, in 1953 reported a 5mm asymptomatic pale, hard nodule in the anterior portion close to the right border of the dorsum of the tongue, in a fifty-two year old white male and a small nodule, 3mm in diameter in the middle third of the dorsum of the tongue in a forty-three year old white female.⁽¹⁾ In 1961, Rosen reported the case of a thirty-six year old white male who had a hard, movable, 2 by 1.5cm mass, in the left lateral border of the tongue. The lesion had been present for twenty years.⁽³⁾

Yoel and Pundyk, in 1965, described a hard, painless, fairly adherent growth, measuring 4.5cm by 1.0cm between the middle and posterior thirds of the dorsum of the tongue, anterior to the lingual "V" and spreading upward to the right border. This lesion had existed for eight years in a thirty-six year old male. (2) Two smooth rounded masses, 1cm in diameter in the right middle third of the dorsum and the lateral margin of the tongue, occurring in a 10 year old female were reported in 1968 by Ramachandran and Viswanathan. (5) Vilglioglia and Stirparo, in 1970, described a hard bi-lobular lesion, 3cm in diameter, at the junction of the medial and posterior thirds of the dorsum of the tongue, occurring in a pregnant 26 year old female. (6) Samant and Gupta, in 1971 reported a chondroma in a 16 year old boy, which presented as an almond-size, painless swelling of 6 years duration on the dorsum of the right posterior third of the tongue. (7)

The most recent report, by Gutmann, et al, in 1974, describes a 1.5cm lesion of 18 months duration in a 42-year-old female. (8) Table 1.

It is recognized that chondroma of the tongue is a very rare lesion, and for this reason the following report of a case is presented.

CASE REPORT

A twenty-one year old white male in no acute distress was seen for a routine dental examination. Complete dental examination revealed a well-developed, well-nourished male with multiple caries and a 0.5cm, round hard, white movable nodule on the right posterior ventral surface of the tongue. (Figure 1). The lesion was asymptomatic and of unknown duration. An excisional biopsy was performed under local anesthesia and the specimen forwarded for pathologic examination.

Microscopically, the section showed a strip of oral mucosa. The covering epithelium and superficial lamina propia were essentially normal. The deeper zone of lamina propia contained a well-circumscribed nodule of cartilage measuring about 4mm in its greatest diameter. The cartilage was hyaline in nature, with relatively few chondrocytes noted. There was no apparent inflammatory reaction in the surrounding connective tissue or striated muscle. (Figure 2, 3 and 4). The diagnosis was benign chondroma of the tongue.

The patient was observed one year post-operatively. The biopsy site was normal with no apparent scar formation.

DISCUSSION

Chondromas may occur in organs or tissues in which cartilage is normally absent, for instance, the tonsils, kidneys, thyroid, tongue and the mammary glands.⁽⁴⁾ To explain the origin of these chondromas, two theories have evolved. The "embryonal theory" proposes that the tumor originates from remnants of displaced fetal cartilagenous tissue which lie dormant in an abnormal habitat until proper stimulation for growth occurs. The "cellular metaplasia" theory suggests that the tumor has its origin in the pluripotential mesenchymal cells which, due to some type of unknown stimulation, possibly trauma, will differentiate into chondrocytes, forming the nidus for chondroma.⁽¹⁾ Although both theories are feasible, the complexity of proving etiology is beyond the scope of this report.

Because of its hardness and white color, this benign neoplasm can be easily differentiated from fibromas, lipomas, angiomas, angiofibromas, and lymphoepithelial cysts. It is differentiated from osteomas of the tongue by histological examination.

Cartilage is essentially an embryonal and transitory tissue, and is readily subjected to metaplastic changes. It is possible, therefore, that some reported osteomas of the tongue have developed from chondromas of the tongue.⁽⁹⁾

Since chondrosarcomas may develop from these benign lesions, the treatment of choice is complete excision.⁽⁴⁾

ILLUSTRATIONS

- Fig. 1 View of the clinical lesion on the right posterior ventral surface of the tongue.
- Fig. 2 Low power photomicrograph of the cartilagenous mass; note the sparsity of chondrocytes.
- Fig. 3 High power photomicrograph showing some of the chondrocytes
- Fig. 4 High power photomicrograph showing the homogenous mass which displaces surrounding striated muscle.

REFERENCES

1. Bruce, K. W., and McDonald, J.R.: Chondroma of the Tongue, Oral Surg., 6:1281-1283, 1953.
2. Yoel, J., and Pundyk, C.: Chondroma of the Tongue, Oral Surg., 20:578-582, 1965.
3. Rosen, M. D.: Chondroma of the Tongue: Report of a Case: J. Oral Surg., Anesth. and Hosp. D. Serv. 19:157-159, 1961
4. Thoma, K. H., and Goldman, H.: Oral Pathology, ed. 5, St. Louis, 1960, The C. V. Mosby Company, pp. 1255-1258.
5. Ramachandran, K. and Viswanathan, R.: Chondroma of the Tongue: Report of a case, Oral Surg., 25:487-490, 1968.
6. Viglioglia, P., and Stirparo, M.: Chondroma of the Tongue, Oral Surg., 29:820-826, 1970.
7. Samant, H. C., and Gupta, O. P.: Chondroma of the Tongue, Oral Surg., 32:450-452, 1971.
8. Gutmann, J., Cifuentes, C., Balzarini, M. A., Sobarzo, V. and Vicuna, R.: Chondroma of the Tongue, Oral Surg., 37:75-77, 1974.
9. Ewing, J.: Neoplastic Diseases: A Treatise on Tumors, ed. 4, Philadel., 1940, W. B. Saunders Company, p. 205.

The author acknowledges the assistance of Drs. C. A. Waldron and W. C. Lail in the preparation of this article.

Reprint requests to:

Col. C. E. del Rio
U. S. Army Institute of Dental Research
Walter Reed Army Medical Center
Washington, D. C. 20012

TABLE 1. SUMMARY OF CASES OF CHONDROMA OF THE TONGUE.

AUTHOR	PATIENT AGE	SEX	DURATION (Year)	LINGUAL LOCATION	SIZE
1. Berry (1892)	49	M	5	Lateral Border	
2. Lang (1892)	22	F	20		
3. Routier (1905)	21	F	4	Right edge	
4. Canus and Ertzbeschoff (1905)				Right anterior edge	3 x 2 cm
5. Huie (1927)		F			13 x 10 cm
6. Gentscheff (1934)				Multiple nodules	
7. Pless (1936)				Tip	
8. Johns (1942)		M	20	Right border	
9. Bruce and McDonald (1953)	52	M	2	Anterior portion of dorsum	5 mm in diameter
10. Bruce and McDonald (1953)	43	F	1	Middle third of dorsum	3 mm in diameter
11. Rosen (1961)	36	M	20	Dorsum and left border	2 x 1.5 cm

AUTHOR	PATIENT AGE	SEX	DURATION (Year)	LINGUAL LOCATION	SIZE
12. Yoe1 and Pundyk (1965)	36	M	8	Between middle and posterior thirds of right dorsum	4.5 x 1 cm
13. Ramachandran and Viswanathan (1968)	10	F	2	Middle third of dorsum and lateral margin	1 cm in dia.
14. Viglioglia and Stirpara (1970)	26	F	0.5	Dorsum at the junction of medial and posterior thirds	3 cm in dia.
15. Samant and Gupta (1971)	16	M	6	Dorsum of the right posterior third	Almond-size 2.5 x 1 cm
16. Gutmann, Cifuentes, Balzarini, Sobarzo and Vicuna (1974)	42	F	1.5	Middle third of dorsum	13 x 7 mm
17. del Rio (1976)	21	M	Unknown	Right posterior ventral sur-face	.5 cm

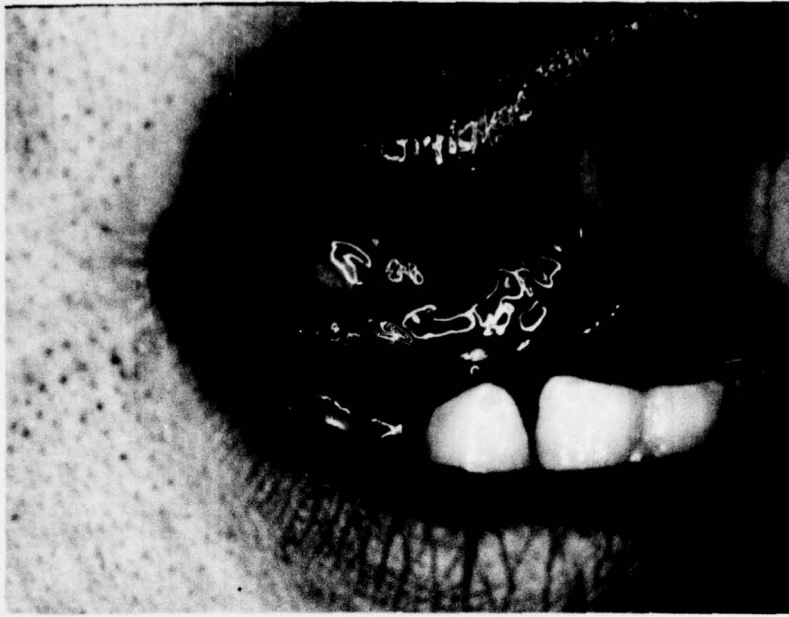
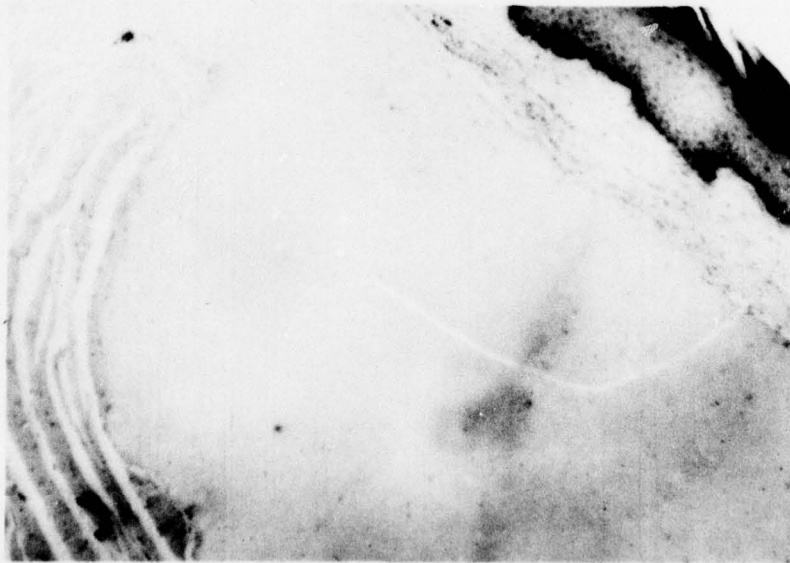


FIGURE 1



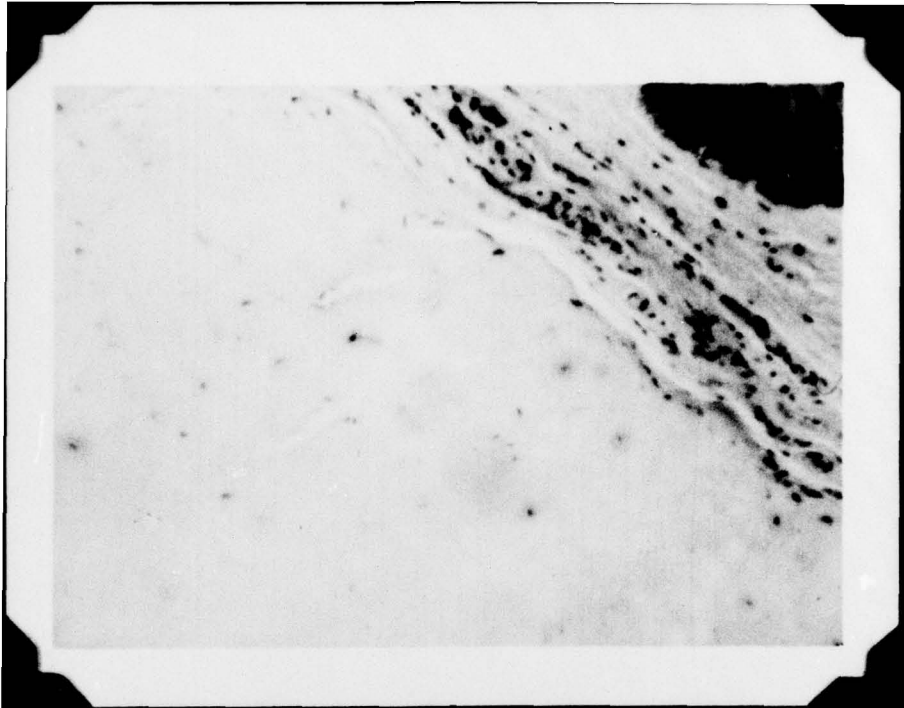


FIGURE 3

