

AD-A035 238

SCHOOL OF AVIATION MEDICINE RANDOLPH AFB TEX
IMPROVED PHONETICS IN ARTIFICIAL DENTURE CONSTRUCTION, (U)
DEC 58 L R ALLEN
59-10

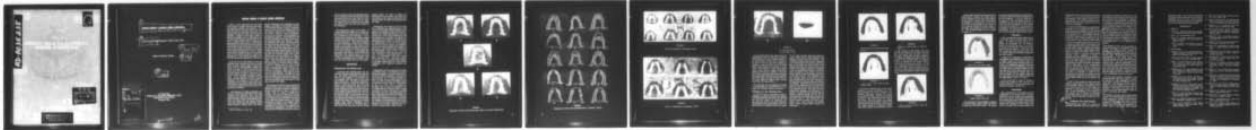
F/G 6/5

UNCLASSIFIED

NL

1 of 1

AD
A035238



END

DATE
FILMED
3-77

AD-A035238

0



DDC
RECEIVED
FEB 7 1977
D

DISTRIBUTION STATEMENT A
Approved for public release;
Distribution Unlimited

②
IMPROVED PHONETICS IN ARTIFICIAL DENTURE CONSTRUCTION

⑩
LESLIE R. ALLEN Lieutenant Colonel, USAF (DC)

⑪ Dec 58

Research Dentistry Division

⑫ 13p.

⑭
59-10

ACCESSION for	
DTIC	White Section <input checked="" type="checkbox"/>
DDC	Buff Section <input type="checkbox"/>
ANNOUNCEMENTS	<input type="checkbox"/>
IDENTIFICATION	
Per Hrs. on file	
BY _____	
REGISTRATION/AVAILABILITY CODES	
DISC. _____	
SPECIAL _____	
A	

Air University
SCHOOL OF AVIATION MEDICINE, USAF
RANDOLPH AFB, TEXAS
December 1958

317100

JP

IMPROVED PHONETICS IN ARTIFICIAL DENTURE CONSTRUCTION

Landa (1) has aptly stated that the three major factors in complete denture construction are mechanics, esthetics, and phonetics. Considerable progress has been made in the last few decades in improving mechanics and esthetics, but little has been done to improve phonetics. Neglect of this major factor in denture construction may be attributed to the fact that most edentulous patients tend to return to normal speech after a postinsertion practice period of several days to several weeks. Various kinds of oral inaccuracies occur during this practice period, but by far the most common, as well as the most difficult to overcome, is the mispronunciation of the *s* and *sh*. While faulty speech is tolerated as part of "getting used to" the artificial denture, it causes embarrassment to the patient and adds to his burden of physiologic adaptation to the denture.

In the Air Force, faulty speech is not to be tolerated when it concerns the flyer or control tower operator, because failure to speak distinctly over the communication system could result in danger for both aircraft and crew. Flyers and control operators are not immune to dental disease, and some of them lose a sufficient number of teeth to warrant replacement. In the prosthetic treatment for this group, phonetics becomes an acute problem. Therefore, the objective of the present investigation was to develop a procedure in artificial denture construction which would enable the patient to speak clearly at the time of insertion of the denture.

The literature in dental prosthetics was reviewed, and previous methods for improving phonetics were evaluated. Snow (2), after observing many casts of the natural dentition, pointed out that a tracing which started at the vault and passed over the lingual alveolar area to the incisal edge of the maxillary incisor always formed a reverse curve. He recom-

mended thickening and contouring the area lingual to the collars of the maxillary incisors of the artificial denture in order to reproduce this reverse curve, and he maintained that this reproduction facilitated the pronunciation of the *s* and *sh*. Landa (1) uses the labiodentals (*f* and *v*) as an adjunct to the arrangement of the maxillary anteriors. He believes the teeth should be arranged so that these fricatives can be pronounced easily and naturally. Landa also maintains that proper vertical dimension is the key to proper pronunciation of the *s* and *sh*. Sears (3) reports that clearer *s* pronunciation will result from fashioning the area of the anterior median ridge according to the type of tongue. He recommends making a groove in this area for the broad tongue with a slight median sulcus, and the building of a ridge in this area for the tongue with a deep median sulcus. Sears also advocates taking a palatogram on cases in which the median sulcus of the tongue does not coincide with the midline. Pound (4) believes that the entire lingual aspect of the maxillary denture should be contoured to simulate the normal, if proper phonetics is to be attained. Many authors recommend the reproduction of the rugae as an adjunct to proper phonetics. Probably the oldest and most widely used procedure for improving speech is the thinning of the entire lingual surface of the maxillary denture in order to create more room for the tongue.

The literature in phonetics was perused, with special attention given to tongue positions in phonation. A moment's reflection of elementary physics recalls that all that is required to produce sound is a source of energy and a vibrator. The source of energy for the voice is expired air from the lungs, and the vibrator is the margins of the vocal folds in the larynx. As air passes the highly sensitive vocal folds, appropriate portions of the margins vibrate to produce the desired sound. This sound is modulated by the larynx, the laryngeal pharynx and the nasopharynx, the nose, and the oral cavity, all of which act as cavity resonators

to give resonance to the voice. Further modulation is brought about by the articulation which takes place between the vocal folds, the velum and the pharynx, the tongue and the velum, the tongue and the hard palate, the tongue and teeth, the lips and teeth, and finally the lips themselves.

The tongue plays a major role in speech. It changes position and shape for the pronunciation of each of the vowels, and it is the principal articulator for the consonants. In pronouncing the consonants, the tongue contacts various portions of the teeth, the alveolar ridge, and the hard palate. Since these structures are either replaced or covered by the artificial denture, it was basic to the study to know exactly which portions of these structures are normally contacted by the tongue in pronouncing a given consonant. To accomplish this, palatograms were made on a group of dentulous individuals with normal speech, who were chosen so as to incorporate a maximum variety of tooth arrangement, tooth occlusion, arch form, arch size, vault form, and vault depth.

PROCEDURE

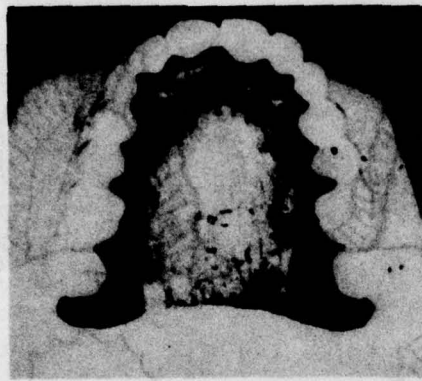
Palatograms for the dentulous group

A uniformly thin artificial palate was constructed of methyl methacrylate for each subject. The palate was inserted and tested for retention and adaptation. The subject practiced speaking with the palate in place until speech became clear. Trial tests for the palatogram were made by having the subject pronounce a given sound and open his mouth without again contacting the palate with his tongue. The palate was then removed, thoroughly dried, dusted with nonscented talcum powder, and carefully inserted in the mouth. The subject was then asked to pronounce the previously practiced sound, and the palate was carefully removed and examined. The moist tongue removed the powder from the area of contact, leaving a clear tracing (palatogram) on the artificial palate (fig. 1). However, after a short period, this area dried and the tracing

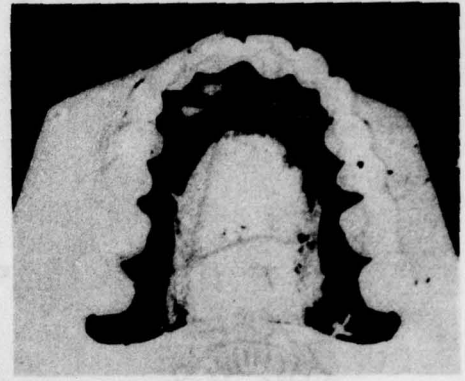
became obscure. In order to preserve the palatogram for future study, the contact area was outlined with a glass-marking pencil immediately after the palate was removed from the mouth.

Palatograms were made for all the vowels, and in studying and comparing these, it was found that the tongue contacts portions of the palate in pronouncing all the vowels except *o*. Therefore, in making palatograms of the consonants, the *o* was used in combination with the consonant to be studied even though the combination did not result in a standard word. Consonants alone could not be used, because the pronunciation of any of the consonants involves two or more sounds, and therefore, two or more tongue positions; for example, to pronounce *s*, the *e* sound is made, followed by the characteristic "s-s-s" of the *s*. One has only to pronounce *s* slowly to prove this to be true. The same *e* sound precedes the *f*, *l*, *m*, and *n*. In pronouncing *t*, the "tuh" is made first, followed by the *e*. The same *e* follows *b*, *c*, *d*, *g*, *p*, *v*, and *z*. In order to avoid primary or secondary contact then, the *o* was used in combination with whatever consonant was studied.

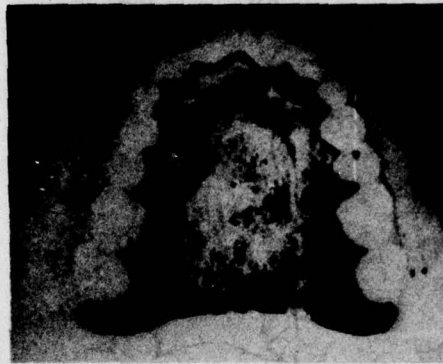
Palatograms of all the consonants were made and filed for study. In studying and comparing the palatograms of the same consonant pronounced by different members of the group, it was found that no two persons contacted exactly the same area in pronouncing the consonant, but that a sufficient similarity existed to constitute a pattern (fig. 2). The patterns for the *t*, *d*, *n*, and *l* were not distinct individually (that is, it was not possible to look at a palatogram and determine which of these consonants had been pronounced in making the tracing); however, the group pattern for these consonants was sufficiently distinct to be certain that either the *t*, *d*, *n*, or *l*, had been pronounced in making the tracing. A comparative analysis of the palatograms of the *s* and *sh* was of particular interest, because each of these presented an individual similarity and constituted a distinct pattern (figs. 3 and 4).



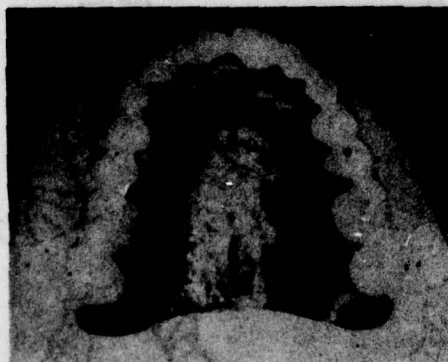T



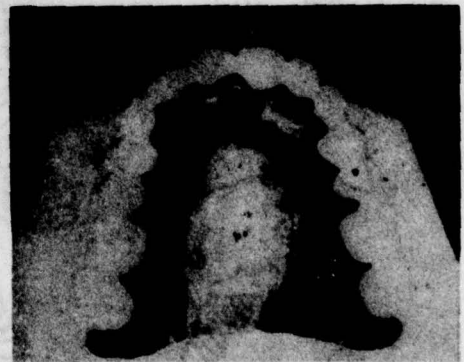D



A



E



U

FIGURE 1.

Palatograms of various sounds showing tongue contact on a powdered artificial palate.

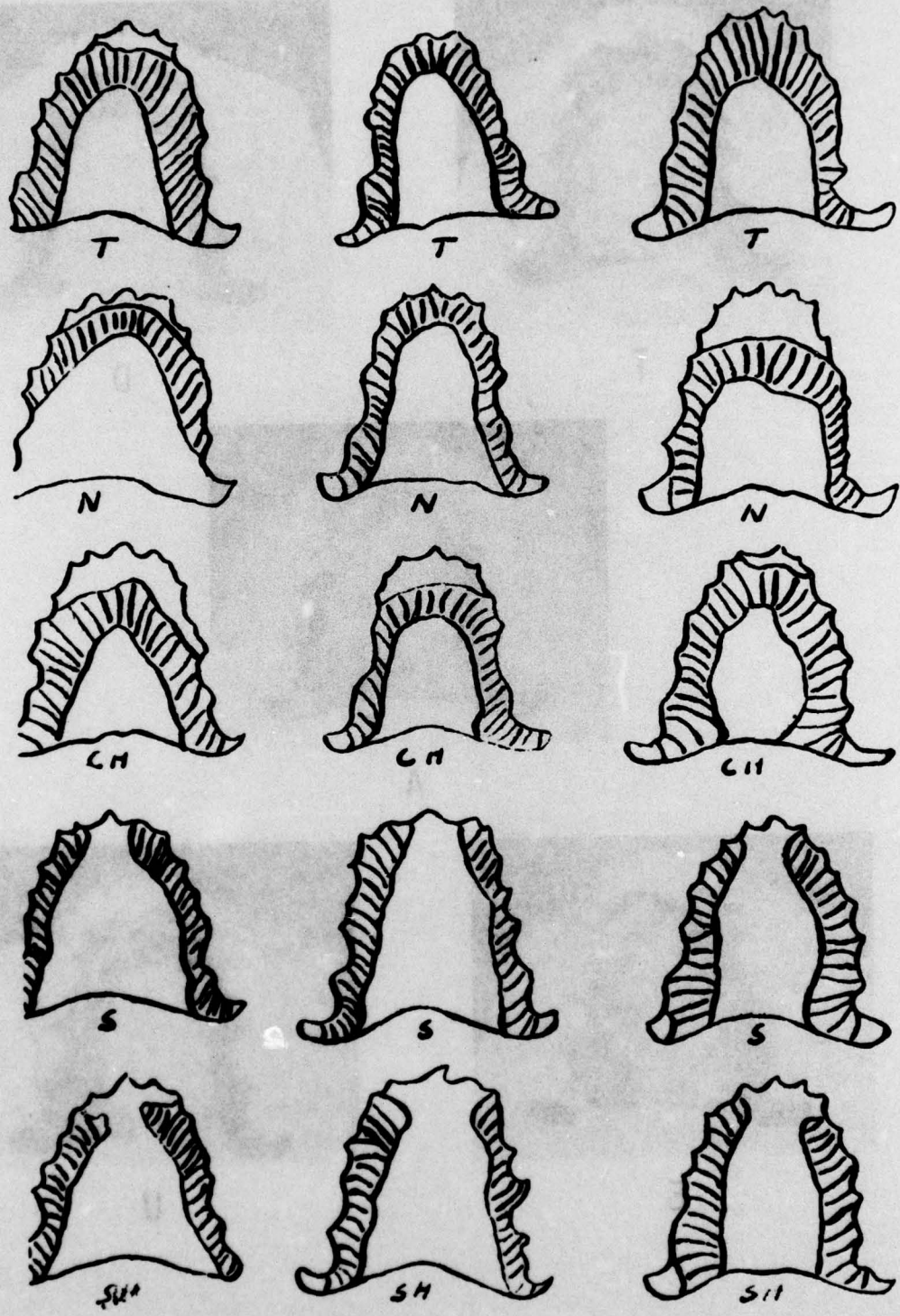


FIGURE 2.

Palmprints of various people, sufficiently similar to constitute a pattern.

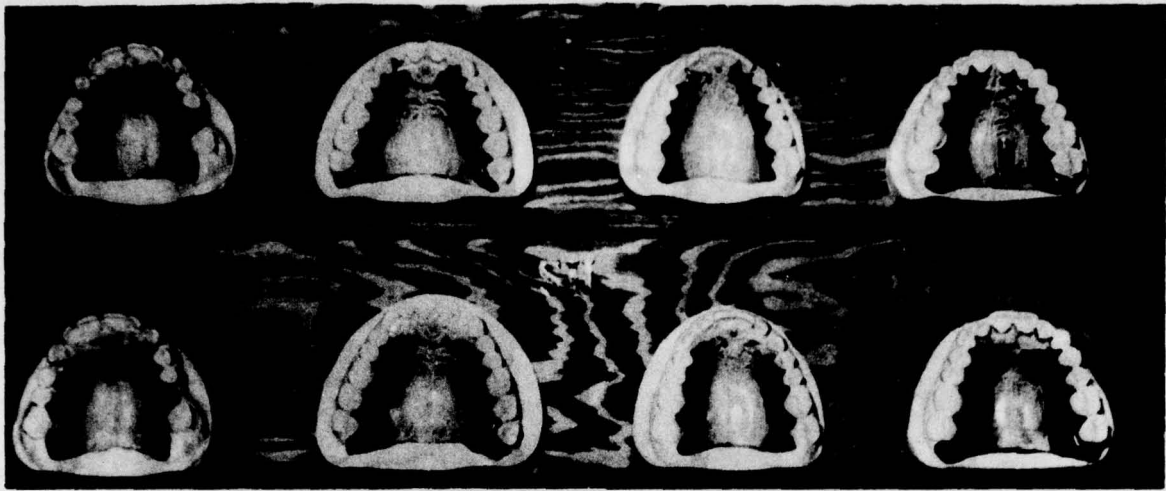


FIGURE 3.

Patterns in palatograms in pronouncing s and sh.

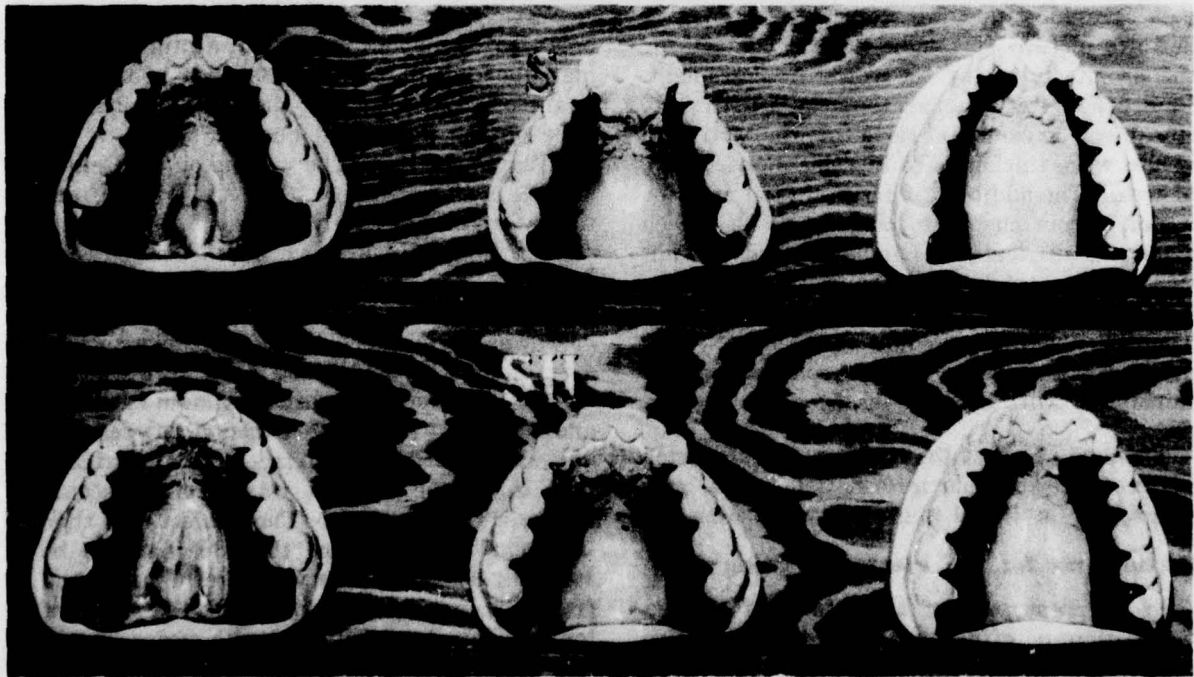
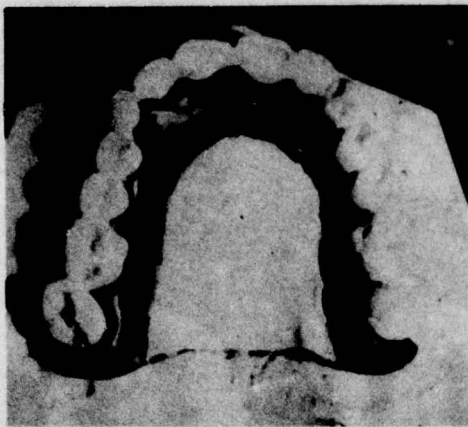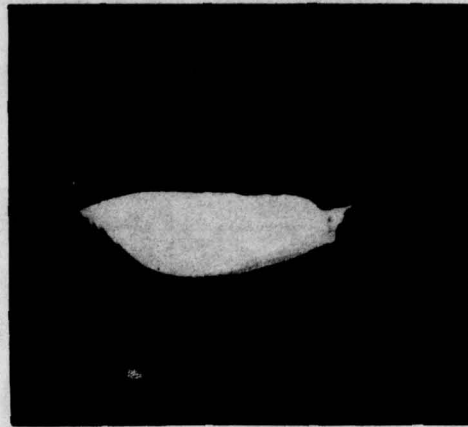


FIGURE 4.

Patterns in palatograms in pronouncing s and sh.



A



B

FIGURE 5.

A, Vault area waxed.

B, Cross section of wax.

Over 500 palatograms were made, and by the palatographic study, we were able to obtain a definite picture of tongue palatal contact for the pronunciation of the vowel or consonant. In order to test the areas most sensitive to thickness, various portions of the artificial palate were thickened in increments of 1 mm. of wax. The addition of 1 mm. in the anterior region (from cuspid to cuspid) made speech awkward, difficult, and indistinct. The addition of 1 mm. thickness in the posterior alveolar area made speech awkward but not indistinct. The entire vault area could be filled with wax up to the outline of tongue contact without interfering with speech (fig. 5).

The next phase of the investigation consisted of incorporating this information into a procedure for artificial denture construction.

Palatograms for the edentulous group

In the first part of this phase of the investigation, no effort was made to be selective in choosing subjects for the study. The criterion was that the subject be edentulous and physiologically ready for prosthetic treatment. The application of the palatographic study was started while the dentures were in the waxed,

"try-in" stage, and after satisfactory esthetics, correct centric, proper vertical dimension, and balanced occlusion had been attained. The mandibular trial base was waxed to completion in the usual manner, and the final waxing was done on the labial and buccal aspects of the maxillary trial base. The waxing on the lingual surface of the maxillary trial base was confined to the area immediately adjacent to the teeth, with a minimum of wax added to assure a smooth surface between baseplate and collars of the teeth (fig. 6). The mandibular trial base was then placed in the subject's mouth, after adhesive powder had been sprinkled on the tissue surface to insure maximum retention and stability. Nonscented talcum powder was dusted on the lingual surface of the maxillary trial base, and the base was carefully seated in the subject's mouth. The subject was then instructed to pronounce the consonant to be studied. The trial base was carefully removed from the patient's mouth, and the area of tongue contact was outlined with a glass-marking pencil (fig. 7). The outlined area was waxed, contoured, redusted, and another palatogram made. This procedure was repeated until a normal tongue palatal contact was established.

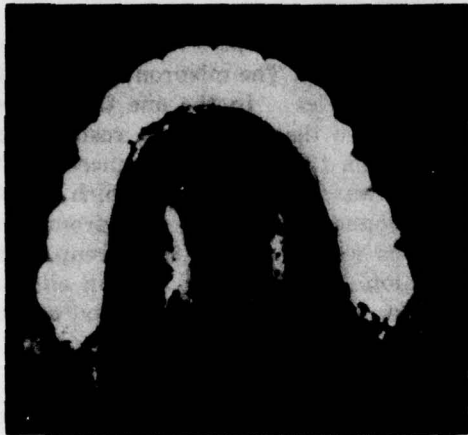

FIGURE 6.

Waxed surface between baseplate and collars of teeth.

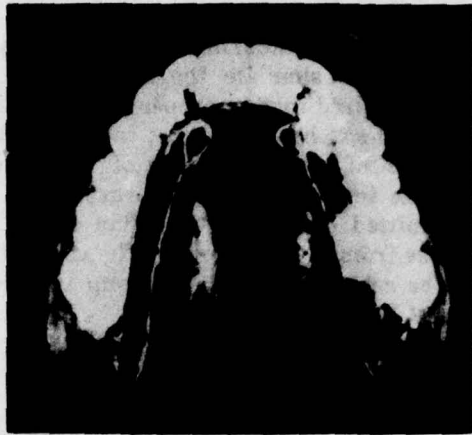


FIGURE 8.

Waxed area between collar of tooth and pencil line.



FIGURE 7.

Area of tongue contact outlined in glass-marking pencil.

To develop a normal pattern, it was always necessary to thicken the outlined area. Sufficient thickness was usually obtained by the following procedures: Waxing was started around the first molar; enough wax was added to create a 1 mm. margin around the collar of this tooth. The area between this margin and the pencil line on the palate was then filled with wax and smoothed (fig. 8). Next, enough wax was added around the delineated anterior teeth (those included in the tracing) to allow a

$\frac{1}{2}$ mm. margin at the collars. The area between this margin and the anterior palatal line was waxed and smoothed (fig. 9). Waxing of the bicuspid area was accomplished by adding wax between the palate line and the collars of the bicuspid teeth in sufficient quantity to present an even contour between the anterior and molar waxed areas. Waxing was completed by adding sufficient wax between the palatal line and second molar to present an even contour between the waxed first molar and posterior border of the baseplate.

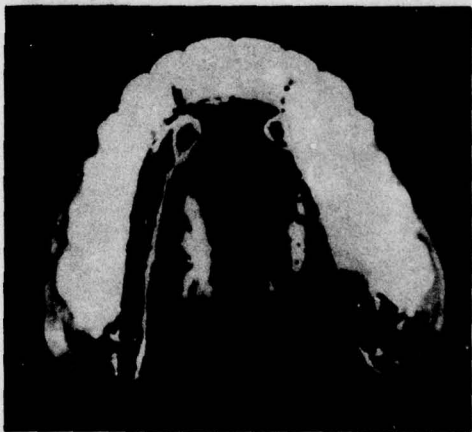

FIGURE 9.

Waxed area between collar of tooth and anterior palatal line.

In some cases, contouring the tongue palatal contact area to simulate the normal was all that was required for the proper pronunciation of the *s* and *sh*; however, most cases required the addition of a small amount of wax in the area of the incisive papilla to prevent the jet of air emitted through the median sulcus of the tongue from escaping toward the vault (fig. 10). The completed lingual wax-up is shown in figure 11.

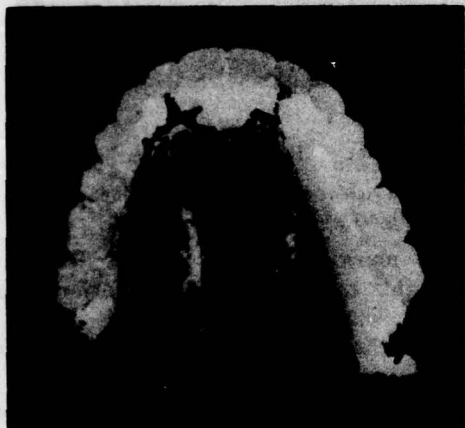

FIGURE 10.

Waxed area of the incisive papilla.

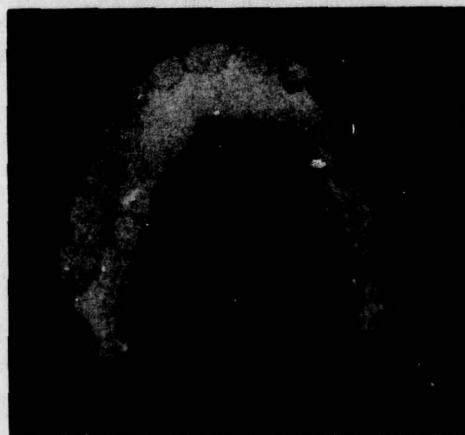

FIGURE 11.

Complete lingual waxed area.

The final phase of the investigation consisted of studying tongue palatal contact of denture wearers who had faulty speech. The speech

inaccuracy in all these cases was mispronunciation of the *s* and *sh*. The mispronunciations fell into two categories: In the one there was a continuous *s*, so that the speech resulted in a whistling when the *s* was pronounced; in the other, there was an indistinct *s*, which resulted in the *sh* sound when the *s* was pronounced. Palatograms were made on this group in the usual fashion. It was found that in all cases there was an abnormal tongue palatal contact.

FINDINGS

A thin, well-adapted artificial palate (about 1 mm. thick) does not greatly impair normal speech. In making the speech test prior to making the palatograms for the dentulous group, it was found that only a few minutes of practice were required by most of the subjects to enunciate properly. It was also noted that during this short practice period, the *t*, *d*, *n*, and *l* were more awkward to pronounce than the *s* and *sh*.

A study of the palatograms showed that in pronouncing the consonants, the primary area of tongue contact is the alveolar area, and that only a small portion of the hard palate is involved. In a comparative analysis of the *s* and *sh* palatography, it was interesting to note that the rugae area was contacted slightly in some cases and not at all in others, but that in all cases the entire posterior alveolar area was always contacted. It was further noted that the rugae area was only slightly involved in the pronunciation of the *t*, *d*, *n*, and *l*.

It was found that in order to develop a normal tongue pattern for the *s* and *sh* in the maxillary denture, it was always necessary to thicken the posterior alveolar area.

DISCUSSION

Many clinicians have successfully used the reproduction of the reverse curve, as recommended by Snow (2), to improve the pronunciation of the *s* and *sh*. Experiments showed that this procedure has merit in that it prevents the jet of air emitted by the median sulcus of the tongue from escaping toward the vault; however, it was found that in some instances, the

reproduction interfered with the pronunciation of the *t*, *d*, *n*, and *l*, and occasionally interfered with anterior lateral tongue contact in pronouncing the *s*. To avoid these possible interferences, thickening was confined to the area of the incisive papilla.

The use of the labiodentals, as recommended by Landa (1), is a prudent procedure for arriving at proper arrangement of the anterior teeth, and the proper vertical dimension which he recommends for *s* pronunciation certainly is important; however, all too often, after arriving at proper vertical dimension, faulty pronunciation of this consonant is still evident.

Sears's (3) method of grooving the area of the anterior median raphe for the tongue with a slight median sulcus was found to be helpful in some cases; however, thickening the lateral alveolar area to produce normal tongue contact tends to increase the median sulcus of the tongue and allows a jet of air to be emitted normally. Sears's suggestion of taking a palatogram on cases in which the median sulcus does not coincide with the midline is excellent and is an added reason for the use of the palatography to improve phonetics in complete denture construction. In the palatographic study of the dentulous group, it was found that the median sulcus and the midline did not coincide in 20 percent of the cases studied. The lack of coincidence is greater in the edentulous cases, because, for esthetic reasons, the maxillary centrals are set according to the facial midline rather than to the palatal midline.

Pound (4) was successful in improving phonetics by contouring the entire lingual aspect of the maxillary denture to simulate the normal; however, most of us do not possess the dexterity to approximate Pound's craftsmanship. In this investigation, it was found that good results could be attained by thickening the necessary areas to produce normal tongue contact without meticulous carving and contouring.

SUMMARY AND CONCLUSIONS

Palatograms were made on a group of dentulous individuals who had normal speech

and presented a variety of problems as to tooth arrangement, tooth occlusion, arch form, arch size, vault form, and vault height. A comparative analysis of the palatograms indicated that no two persons contacted exactly the same area in pronouncing a given consonant, but that sufficient similarity existed to constitute a pattern. The patterns for the *t*, *d*, *n*, and *l* were not distinct; that is, it was not possible to look at a palatogram and determine which of these consonants had been pronounced in making the tracing; however, the pattern for these consonants as a group was distinct, so that it was possible to look at a palatogram and be certain that either *t*, *d*, *n*, or *l* had been pronounced.

The patterns for the *s* and *sh* presented an individual similarity and constituted a distinct pattern. The pattern for the *s* begins approximately in the region of the lateral incisors, and bilaterally includes most of the posterior alveolar region. The pattern for the *sh* begins approximately in the cuspid region, and bilaterally includes all of the posterior alveolar area and some of the vault. In a comparative analysis of the *s* and *sh* palatography, it was found that the rugae area was contacted slightly in some cases and not at all in others, but that in all cases, the entire posterior alveolar area was always contacted. It was also found that the rugae area was only slightly involved in the pronunciation of the *t*, *d*, *n*, and *l*.

The area most sensitive to thickness is the anterior alveolar area from cuspid to cuspid. An addition of 1 mm. thickness in this area made speech awkward and indistinct, and an additional 1 mm. thickness in the posterior alveolar area made speech awkward but not indistinct. The entire vault area could be thickened up to the tongue palatal tracing line without interfering with speech.

To develop a normal *s* and *sh* tongue palatal pattern in the waxed maxillary trial base, it is usually necessary to thicken the area outlined by the palatogram. In most cases, it is also necessary to thicken the area of the incisive papilla to prevent the jet of air emitted by the median sulcus of the tongue from escaping

START

toward the vault. It was found that building the tongue palatal contact area to normal and thickening the area of the incisive papilla facilitates proper enunciation and eliminates much of the postinsertion practice period.

BIBLIOGRAPHY

A. References

1. Landa, J. F. Importance of phonetics in full denture prosthesis. *Dental Digest* 41:154-160 (1935).
2. Snow, G. B. Dental advertiser, 1899.
3. Sears, V. H. Principles and technics for complete denture construction. St. Louis: The C. V. Mosby Co., 1949.
4. Pound, E. Aesthetics and phonetics in full denture construction. *D. J. Australia* 23:126-134 (1951).

B. General reading

1. Anthony, L. P., et al. The American textbook of prosthetic dentistry, 7th ed., pp. 332-336. Philadelphia: Lea and Febiger, 1942.
2. Black, N. H., and H. N. Davis. Practical physics, pp. 427-462. New York: Macmillan, 1926.
3. Brash, J. C., and E. B. Jamieson. (eds.) Cunningham's manual of practical anatomy, 10th ed., vol. 3, pp. 274-336. New York: Oxford University Press, 1940.
4. Darlington, C.G., et al. Speech defects and related oral anomalies. The 1938 Year Book of Dentistry, pp. 605-608. Chicago: Year Book Publishers, 1938.
5. Darlington, C. G., et al. Speech — Its relation to dental appliances and oral anomalies. The 1939 Year Book of Dentistry, pp. 644-646. Chicago: Year Book Publishers, 1939.
6. Darlington, C. G., et al. Some phases of full denture construction and treatment of malocclusion and loss of retention in full dentures. The 1940 Year Book of Dentistry, pp. 365-367. Chicago: Year Book Publishers, 1940.
7. Dresch, I. J. The construction of vulcanite dentures to facilitate clear speech. *Dental Digest* 21:751-758 (Dec. 1915).
8. Duff, A. W. Textbook of physics, 4th ed., pp. 517-551. Philadelphia: Blakiston, 1916.
9. Grant, J. C. B. In Schaeffer, J. (ed.) Morris' human anatomy, 10th ed., pp. 377-581. Philadelphia, Blakiston, 1942.
10. Gray, G. W., and C. M. Wise. The bases of speech. New York: Harper, 1946.
11. Gray, H. In Lewis, W. H. (ed.) Anatomy of the human body, 22d ed., pp. 400-418; 1065-1094; 1104-1138. Philadelphia: Lea and Febiger, 1930.
12. Elphinstone, J. L. Vocalization and the bite. *Dental Cosmos* 77:740-743 (Aug. 1935).
13. Jackson, C. M., and R. F. Blount. In Schaeffer, J. (ed.) Morris' human anatomy, 10th ed., pp. 1246-1248; 1250-1257; 1262-1288. Philadelphia: Blakiston, 1942.
14. Kimball, H. D., and J. H. Muyskens. Speech reconstruction after prosthesis. *J.A.D.A.* 24:1158-1168 (July 1937).
15. Knudsen, V. O. Sound waves and rhythms. *Scientific Monthly* 67:430-435 (Dec. 1948).
16. Moses, E. R. Palatography and speech improvement. *J. Speech Disorders* 4:103-114 (June 1939).
17. Parmenter, C. E., and S. N. Trevino. Vowel positions as shown by x-ray. *Quart. J. Speech* 18: 351-369 (June 1932).
18. Prendergast, W. K. Phonetics and speech defects in prosthetic dentistry. *Canad. Dent. A. J.* 1:295-308 (July 1935).
19. Proctor, H. H. Phonetics in relation to dental prosthesis. The 1949 Year Book of Dentistry, pp. 162-165. Chicago: Year Book Publishers, 1949.
20. Schaeffer, J. P. (ed.) Morris' human anatomy, 10th ed., pp. 1360-1420. Philadelphia: Blakiston, 1942.
21. Schlosser, R. O. Checking the phonetics of testing the patient's ability to speak clearly with model dentures. In Complete denture prosthesis, 2d ed., pp. 284-291. Philadelphia: W. B. Saunders Co., 1946.
22. Shohara, H. H., and C. Hanson. Palatography as an aid to the improvement of articulatory movements. *J. Speech Disorders* 6:115-124 (Sept. 1941).
23. Shohara, H. H. Abstract of thesis. *Quart. J. Speech* 21:343-348 (June 1935).
24. Swenson, M. G. Complete dentures, pp. 432-434. St. Louis: C. V. Mosby Co., 1940.
25. Taffel, A. Visualized physics, pp. 154-169. New York: Oxford Book Co., 1947.
26. Tench, R. W. Influence of speech habits on the design of full artificial dentures. *J.A.D.A.* 14: 644-648 (Apr. 1927).

27. Terry, R. J. /n Schaeffer, J. (ed.) Morris' human anatomy, 10th ed., pp. 88-91; 174-181; 186. Philadelphia: Blakiston, 1942.
28. Weir, F. S. Relating tooth positions in full dentures to the oral vestibule to obtain accuracy of speech, esthetics, and anatomic function.

J.A.D.A. 19:1706-1714 (Oct. 1932).

29. West, R., L. Kennedy, and A. Carr. Rehabilitation of speech. New York: Harper, 1947.
30. Westerman, K. N. Emergent voice, pp. 43-66. Ann Arbor, Mich.: Privately Printed, 1947.