

AD-A035 705

ARMY INST OF DENTAL RESEARCH WASHINGTON D C
PANORAMIC FINDINGS IN DENTISTS HEALTH SCREENING PROGRAM, 1975 A--ETC(U)
JAN 77 P J TSAKNIS, T F PAYNE, J F NELSON

F/6 6/5

UNCLASSIFIED

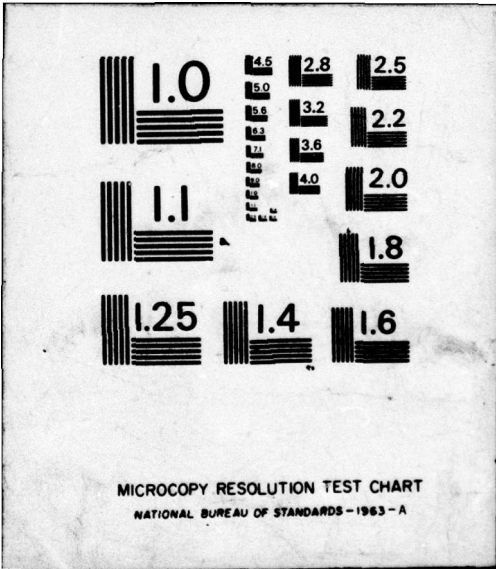
NL

| OF |
AD
A035705



END

DATE
FILMED
3-77



Unclassified

SECURITY CLASSIFICATION OF THIS PAGE (When Data Entered)

REPORT DOCUMENTATION PAGE

READ INSTRUCTIONS BEFORE COMPLETING FORM

ADA 035705

1. REPORT NUMBER 0		2. JOVT ACCESSION NO.		3. RECIPIENT'S CATALOG NUMBER	
4. TITLE (and Subtitle) PANORAMIC FINDINGS IN DENTISTS HEALTH SCREENING PROGRAM, 1975 ADA-FDI MEETING				5. TYPE OF REPORT & PERIOD COVERED Manuscript for publication	
7. AUTHOR(s) Colonel Peter J. Tsaknis Major Thomas F. Payne Lieutenant Colonel John F. Nelson Colonel James C. Adrian				8. CONTRACT OR GRANT NUMBER(s)	
9. PERFORMING ORGANIZATION NAME AND ADDRESS U.S. Army Institute of Dental Research Walter Reed Army Medical Center Washington, D.C. 20012				10. PROGRAM ELEMENT, PROJECT, TASK AREA & WORK UNIT NUMBERS 61101A 3A161101A91C 00 360	
11. CONTROLLING OFFICE NAME AND ADDRESS U.S. Army Med. Research & Development Cmd HQDA (SGRD-RP) Washington, D.C. 20314				12. REPORT DATE 27 Jan 1977	
14. MONITORING AGENCY NAME & ADDRESS (if different from Controlling Office) 12 19p.				15. SECURITY CLASS. (of this report) Unclassified	
16. DISTRIBUTION STATEMENT (of this Report) This document has been approved for public release and sale; its distribution is unlimited.					
17. DISTRIBUTION STATEMENT (of the abstract entered in Block 20, if different from Report)					
18. SUPPLEMENTARY NOTES COPY AVAILABLE TO DDC DOES NOT PERMIT FULLY LEGIBLE PRODUCTION					
19. KEY WORDS (Continue on reverse side if necessary and identify by block number) 1. Panoramic survey 2. ADA-FDI 3. Oral findings COPY AVAILABLE TO DDC DOES NOT PERMIT FULLY LEGIBLE PRODUCTION					
20. ABSTRACT (Continue on reverse side if necessary and identify by block number) A panoramic radiographic examination of 1,239 dentists attending the 115th Annual meeting of the American Dental Association was performed as part of the Health Screening Program. Analysis of the radiographs revealed that 68% of those surveyed had less than 28 natural teeth, 34% had one or more endodontically treated teeth and 25% were judged to have moderate to severe bone loss related to periodontal disease.					

038670

13

PANORAMIC FINDINGS IN DENTISTS
HEALTH SCREENING PROGRAM, 1975 ADA-FDI MEETING

Peter J. Tsaknis, LTC, DC
Thomas F. Payne, MAJ, DC
John F. Nelson, LTC, DC
James C. Adrian, COL, DC

ACCESSION FOR	
NTIS	White Section <input checked="" type="checkbox"/>
DDC	Pink Section <input type="checkbox"/>
UNANNOUNCED	
JUSTIFICATION	
BY	
DISTRIBUTION/AVAILABILITY CODES	
Dist.	AVAIL. and/or SPECIAL
A	

Division of Pathology
U.S. Army Institute of Dental Research
Walter Reed Army Medical Center
Washington, D.C. 20012

The views and opinions expressed herein are those of the authors and are not to be interpreted as official or as representing the Department of Defense.

ABSTRACT

A panoramic radiographic examination of 1,239 dentists attending the 115th Annual meeting of the American Dental Association was performed as part of the Health Screening Program. Analysis of the radiographs revealed that 68 percent of those surveyed had less than 28 natural teeth, 34 percent had one or more endodontically treated teeth and 25 percent were judged to have moderate to severe bone loss related to periodontal disease.

As part of the ADA-sponsored Health Screening Program, conducted at the 115th annual meeting of the ADA, 1,239 Panorex* radiographs were taken. A number of the participants represented the twenty-two member countries of the Federation Dentaire International which met in joint session with the American Dental Association. No attempt was made in this study to differentiate the panographs of American dentists from their FDI counterparts. The radiographs were analyzed to determine the prevalence of pathological conditions relating to the osseous structures. Similar previously published studies¹⁻⁴ have been sponsored and conducted by the ADA providing a spectrum of data for comparative purposes; however, this is the first report of an international sampling of the oral health status of dentists.

Material and Methods

All processed radiographs were interpreted by four oral pathologists from the Division of Pathology, US Army Institute of Dental Research. An overhead projector was used to project the x-rays onto a screen for evaluation. The frequencies of observed pathoses were classified into the following categories: (a) missing teeth; (b) impactions; (c) endodontic procedures; (d) retained root tips; (e) dental caries; (f) periodontal disease; and (g) miscellaneous findings.

All radiographs examined were of excellent quality. The criterion for determining missing teeth, impactions, endodontic procedures and retained root tips were objective and self-evident. The determination of dental caries and periodontal disease was considered to be subjective and was classified on a conservative basis according to the following criteria. A positive caries determination required obvious destruction of enamel and dentin with no evidence of a restorative procedure or gross destruction adjacent to an existing restoration. To be classified as exhibiting radiographic evidence of periodontal disease, obvious bone resorption in

*S.S. White Co., Philadelphia, Pa. 19102

relation to the crestal alveolar bone height was necessary. Those films falling in the range of 3 to 4 on an arbitrary scale of 0 to 4 were classified as exhibiting significant osseous involvement.

Results

The age distribution is presented in Table I. Approximately 75 percent of the dentists were quite equally distributed between 30 and 60 years of age. The incidence of missing teeth, impacted teeth, retained root tips, endodontic procedures, periodontal disease and dental caries is presented in Table II.

Missing Teeth

Of the 8,516 missing teeth, the maxillary and mandibular third molars accounted for 56 percent. The teeth in order of increasing frequency of loss were the mandibular cuspids (8), maxillary cuspids (26), mandibular anteriors (61), maxillary anteriors (184), mandibular bicuspid (420), maxillary bicuspid (609), maxillary 1st and 2nd molars (762), mandibular 1st and 2nd molars (1214), mandibular 3rd molars (2,223) and maxillary 3rd molars (2,506). Eight dentists were completely edentulous, 11 were edentulous in the maxilla only and one was edentulous in the mandible only. Complete dentitions were noted in 65 instances (.05%), however, 581 dentists (42.3%) had 28 to 31 teeth.

Impacted Teeth

Twenty percent of the dentists surveyed had at least one impacted tooth. Maxillary and mandibular third molars together accounted for 495 (96.5%) of all impacted, unerupted or embedded teeth. Examples of impacted incisors of maxillary 1st and 2nd molars were not noted; neither were any unerupted teeth observed in the edentulous jaws. Two instances of impacted supernumerary maxillary molars were seen and

these represented the only findings of excessive teeth in this study. A full complement of four impacted third molars was observed in 29 dentists. A number of radiographs revealed the unilateral presence of maxillary and mandibular third molars with contralaterally missing third molars.

Endodontics

Endodontically treated root canals were noted in the following order of frequency: mandibular cuspids (15), maxillary cuspids (30), mandibular anterior (45), mandibular bicuspid (112), maxillary molars (142), mandibular molars (116), maxillary anterior (239), maxillary bicuspid (300). Periapical radiolucencies less than one centimeter in diameter were noted in 7.1 percent (74) of endodontically treated teeth. Ten mandibular and two maxillary molars had a concurrent root amputation. Thirty-four percent of the dentists surveyed had at least one endodontically treated tooth.

Root Tips

One or more retained root tips were observed in seven individuals. The mandibular molar area was the most common location followed by the anterior maxilla.

Dental Caries

Obvious cavitation was evident in 9 percent (112) of the examined films. These lesions represented extensive destruction of dental structures which was readily apparent on a panograph.

Periodontal Disease

Significant osseous involvement was noted in 25 percent (315) of the radiographs. The loss of crestal bone height was accompanied in most

cases by radiographically observable calculus.

Miscellaneous Findings

Among the miscellaneous findings were the following: elongated stylohyoid processes with evidence of ligament calcification (33), antral mucocele (27), foreign bodies (10) and Stafne mandibular salivary gland depressions (6). A number of malformed teeth were noted in addition to several nondiagnostic ill-defined radiopacities. None of the radiographs exhibited features suggestive of a central boney lesion.

Discussion

The findings of this survey may be interpreted as an indicator of the general attitude of dentists toward various dental procedures. This is particularly evident in the area of endodontics with over one-third of the dentists having at least one endodontically treated tooth. The number of dentists with unerupted teeth (20 percent) is interesting when compared with a survey of 2,486 patients by Johnson⁵ who found only a 9% incidence in a Veteran's Administration Hospital. Twenty-five percent of the patients in Johnson's study were edentulous as compared to 0.01 percent in the present study. The prevalence and severity of the osseous destruction attributed to periodontal disease was somewhat alarming. The authors feel that this is perhaps a reflection of the motivational problems association with periodontics. It is a distinct credit to the surveyed population that no radiographic findings pathognomic of intraboney neoplasms were found.

Summary and Conclusions

Twelve hundred and thirty-nine panoramic radiographs were evaluated. The following conclusions were drawn from a tabulation of the results:

1. 25 percent of the radiographs exhibited moderate to severe periodontal bone loss.

2. 20 percent exhibited unerupted teeth.
3. 9 percent exhibited gross caries.
4. 33 percent of the dentists surveyed had at least one endodontically treated tooth.
5. No definitive radiographic evidence of cyst formation or central boney tumors was noted.

<u>Age Range</u>	<u>Number</u>	<u>Percent of Total</u>
20-29	134	10.8
30-39	298	24.2
40-49	326	26.4
50-59	305	24.8
60-69	134	10.8
70-79	31	2.5
Unknown	<u>8</u>	<u>0.6</u>
	1239	100.0

Table I - Age by Decades of Examined Dentists.

	Missing	Impacted	Root Tips	Root Canals	Periodontal Bone Loss	Caries
Total Number	8,516	513	8	1049	818	112
Number of Dentists	1190	251	7	419	818	112
Percent of Total	96.04	20.25	0.01	33.82	66.02	9.04

Table II - Data from Radiographic Survey of 1239 Dentists.

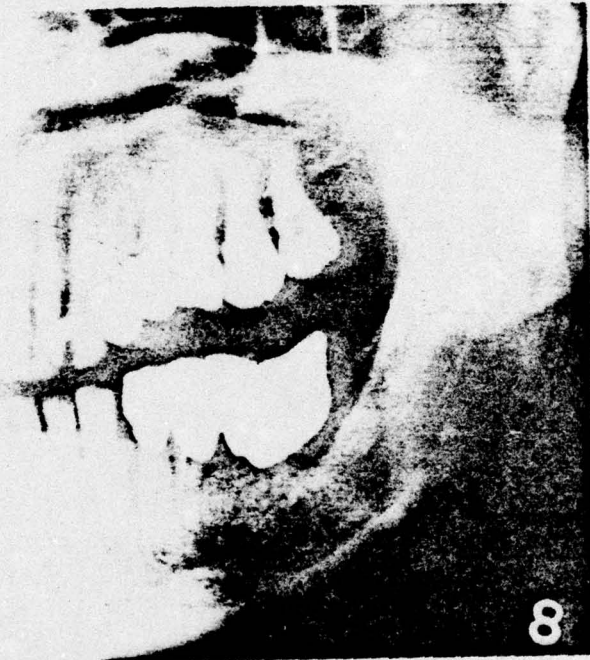BIBLIOGRAPHY

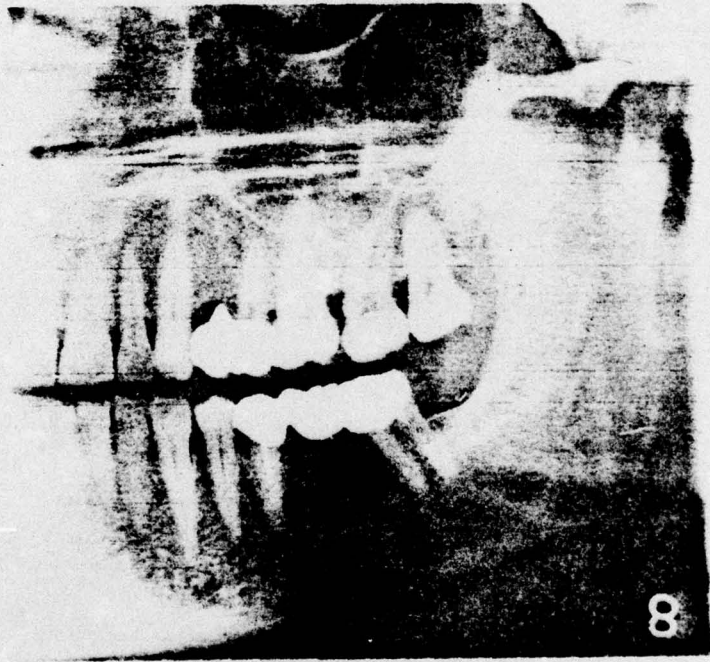
1. Lilly, G.E., Steiner, M., Irby, W.B. Oral Health Evaluation: Analysis of Radiographic Findings JADA 71:635 Sept., 1965.
2. Lilly, G.E., Steiner, M., Alling, C.C., Tiecke, R.W. Oral Health Of Dentists: Analysis of Panoramic Radiographs J Oral Med 22:23 Jan., 1967.
3. Christen, A.G., Meffert, R.M., Cornyn, J., Tiecke, R.W. Oral Health Of Dentists: Analysis of Panoramic Radiographic Survey JADA 75:1167 Nov., 1967.
4. Cuttino, C.L., Pogozielski, D.S., Richard, G.R., Tiecke, R.W. Panoramic Radiographic Survey of Dentists: Interpretation of Findings JADA 79:1179 Nov., 1969.
5. Johnson, C.C. Analysis of Panoramic Survey JADA 81:151 Jul., 1970.

The authors wish to acknowledge Dr. Roger H. Scholle, Asst. Secretary of the Council of Dental Therapeutics ADA and Mr. Ronald D. Newman of Penwalt Corporation for their invaluable assistance in this project.

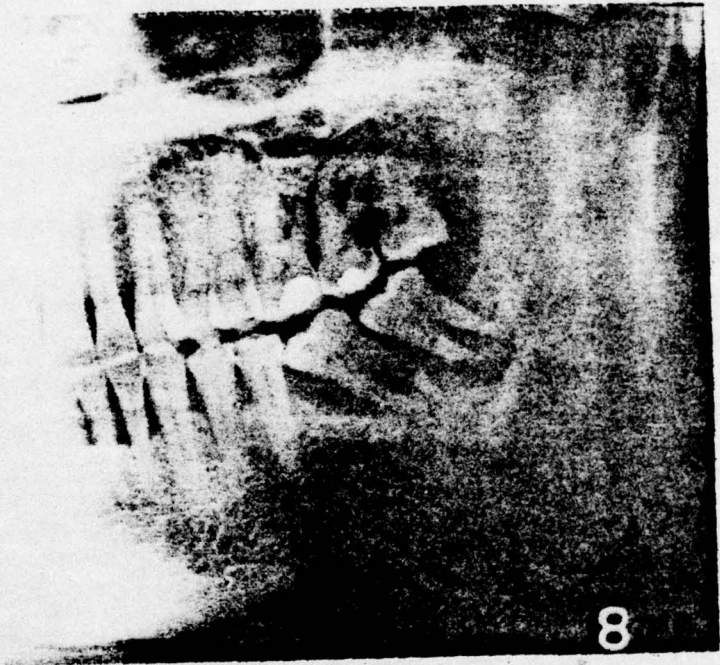
LEGEND

- Figure 1 Severe periodontal involvement of the osseous tissues in the molar areas is radiographically apparent.
- Figure 2 This radiograph exhibits moderate periodontal involvement of the maxillary molar region. A retained root tip is noted below the mandibular molar pontic.
- Figure 3 Caries and severe periodontal disease is exhibited in this radiograph.
- Figure 4 Numerous root tips and several periapical radiolucencies are observable in this panograph.
- Figure 5 A foreign object, possibly a broken instrument, presumably lodged in the body of the mandible is readily apparent.
- Figure 6 This radiograph demonstrates bilateral impaction of mandibular bicuspids.
- Figure 7 This radiograph illustrates a complete dentition except for a missing maxillary third molar. However, loss of crestal bone with calculus formation in the maxillary anterior area is obvious.





8



8

