

AD-A040 775

ARMY INST OF DENTAL RESEARCH WASHINGTON D C  
SUBMERGENCE OF ROOTS FOR ALVEOLAR BONE PRESERVATION. II. REIMPL--ETC(U)  
MAY 77 T GOUND, R B O'NEAL, C E DEL RIO

F/G 6/5

UNCLASSIFIED

NL

| of |  
ADA040775



R L D w/ photo

REPORT DOCUMENTATION PAGE

READ INSTRUCTIONS BEFORE COMPLETING FORM

AD A 040775

1. REPORT NUMBER <b>6</b>		2. GOVT ACCESSION NO.	3. RECIPIENT'S CATALOG NUMBER
4. TITLE (and Subtitle) Submergence of Roots for Alveolar Bone Preservation, II. Reimplanted Endodontically-Treated Roots		5. TYPE OF REPORT & PERIOD COVERED Submission of Paper. Sep 75 - May 77	
7. AUTHOR(s) Tom/Gound, Robert B./O'Neal, Carlos E. del RIO and Marvin P./Levin		8. CONTRACT OR GRANT NUMBER(s) <b>12</b>	
9. PERFORMING ORGANIZATION NAME AND ADDRESS US Army Institute of Dental Research Walter Reed Army Medical Center Washington, DC 20012		10. PROGRAM ELEMENT, PROJECT, TASK AREA & WORK UNIT NUMBERS Program Element 62110A Project No. 3A162110A825 Task Area No 00-Work Unit No.	
11. CONTROLLING OFFICE NAME AND ADDRESS US Army Medical Research and Development Command ATTN: (SGRD-RP) Washington, DC 20012		12. REPORT DATE 10 May 1977	
14. MONITORING AGENCY NAME & ADDRESS (if different from Controlling Office) <b>9) Rept. for Sep 75 - May 77</b>		13. NUMBER OF PAGES 18 <b>12 pp</b>	
		15. SECURITY CLASS. (of this report)	
		15a. DECLASSIFICATION/DOWNGRADING SCHEDULE	

16. DISTRIBUTION STATEMENT (of this Report)

"This document has been approved for public release and sale; its distribution is unlimited."  
**12 2pp**

17. DISTRIBUTION STATEMENT (of the abstract entered in Block 20, if different from Report)

DDC  
JUN 21 1977  
C

18. SUPPLEMENTARY NOTES

19. KEY WORDS (Continue on reverse side if necessary and identify by block number)

Mandibular premolars, investigation, histology, endodontically, root canal, extracted, contoured, reimplanted, submerged, resorption, sealer

20. ABSTRACT (Continue on reverse side if necessary and identify by block number)

Root canal therapy was accomplished on the mandibular premolars of four dogs. These premolars were then extracted, contoured, reimplanted and submerged. Resorption occurred up to 60 days; healing progressed satisfactorily with some evidence of coronal osseous regeneration.

AU NO. DDC FILE COPY

038 670

ACCESSION		White Section	<input checked="" type="checkbox"/>
NTIS		Both Section	<input type="checkbox"/>
DDC			
UNANNOUNCED			
IDENTIFICATION			
BY			
DISTRIBUTION / AVAILABILITY CODES			
U.S.	AVAIL.	REG.	SPECIAL
A			

## SUBMERGENCE OF ROOTS FOR ALVEOLAR BONE PRESERVATION

### II. REIMPLANTED ENDODONTICALLY-TREATED ROOTS

- \*TOM GOUND, D.D.S., M.S.
- \*\*ROBERT B. O'NEAL D.M.D., M.A., M.S.
- \*\*\*CARLOS E. del RIO, B.S., D.D.S.
- \*\*\*\*MARVIN P. LEVIN, B.S., D.D.S.

- MAJ, DC Endodontic Resident, US Air Force, US Army Institute of Dental Research, Walter Reed Army Medical Center, Washington, DC 20012
- MAJ, DC Periodontic Resident, US Army Institute of Dental Research, Walter Reed Army Medical Center, Washington, DC 20012
- COL, DC Chief, Division of Clinical Research; Director, Endodontic Residency, US Army Institute of Dental Research, Walter Reed Army Medical Center, Washington, DC 20012
- COL, DC Chief, Dept. of Clinical Specialties; Director, Periodontic Residency, US Army Institute of Dental Research, Walter Reed Army Medical Center, Washington, DC 20012

In conducting research described in this report, the investigators adhered to the "Guide for the Care and Use of Laboratory Animals," as promulgated by the Committee on the Revision of the Guide for Laboratory Animal Facilities and Care of the Institute of Laboratory Animal Resources, National Research Council.

ABSTRACT

Root canal therapy was accomplished on the mandibular premolars of four dogs. These premolars were then extracted, contoured, reimplanted and submerged. Resorption occurred up to 60 days; healing progressed satisfactorily with some evidence of coronal osseous regeneration.

In the first of a two part series a study was described which indicated the feasibility of submerging root segments that were first treated endodontically (1). This second report investigates another approach to maintaining the alveolar ridge of denture patients.

In an attempt to develop a procedure that was both practical and economical, Simon and Kimura had devised a technique in which human teeth were extracted, crowns were removed, the roots were endodontically treated, contoured, and then submerged. After 18 months the radiographic findings indicated that no bone formed coronal to the roots and that many of the roots were resorbing. However, clinically some of the roots appeared to be maintaining bone in various amounts (2).

The purpose of the present study is to histologically investigate roots that are endodontically treated, extracted and contoured, and then reimplanted and submerged.

#### MATERIALS AND METHODS

Four healthy mongrel dogs approximately three years old and weighing about 40 pounds each were used. The dogs were premedicated with Innovar, 1 cc per 20 pounds of body weight. Surgery was performed under general anesthesia using sodium pentothal, 1 cc per 50 pounds of body weight in conjunction with nitrous oxide at 50% concentration.

The four mandibular premolars were used in this study with the single rooted first premolars serving as controls. Sixteen roots of the premolar teeth were selected at random to be used in this study. Both the control and the experimental teeth were treated endodontically. Following biomechanical preparation, the canals and pulp

chambers were filled with gutta percha using the lateral condensation technique. Kerr Tubli-Seal\* cement was utilized as the sealer.

A local anesthetic was administered (xylocaine 2% with 1/100,000 epinephrine) for hemorrhage control. Full thickness mucoperiosteal flaps were reflected on the buccal and lingual of the mandible. Inverse bevel incisions were used so creviclectomy could be accomplished. All excess soft tissue around the teeth was removed with curets. The first premolars received no treatment other than reflection of the flaps. The endodontically treated double rooted experimental teeth were sectioned using a high speed bur and water spray. Each root was extracted and the coronal part reduced so that when reimplanted it would be 2 to 3 millimeters below the crest of the alveolar bone. Reduction was done while holding the roots in a saline soaked 2 x 2 gauze. The roots were contoured into a dome shaped form with a fine flare diamond bur using a water spray. The sockets were irrigated, suctioned and the roots were reimplanted. Roots were out of the alveolar socket approximately three minutes.

Releasing incisions were made in the periosteum at the base of the buccal flap. Primary closure was obtained using a mattress suture technique. Each animal received 600,000 units of benzathine penicillin G suspension and 600,000 units of Procaine G immediately after the procedure. Sutures were removed seven days postoperatively.

The animals were sacrificed in a sequence that provided two specimens and a control at the following postoperative times; 30, 40,

---

\*Kerr Sybron Corp., Romulus, Michigan

45, 55, 60, 90 and 120 days. The two 40 days specimens were lost in tissue preparation. The resulting histological specimens were evaluated for inflammation, resorption and bone regeneration.

Inflammation. The specimens were graded for inflammation coronal to the root segment and in the periapical area according to the following scale:

- 0 No evidence of inflammation.
- 1 Minimal reaction, characterized by a diffuse scattering of inflammatory cells in a prescribed area.
- 2 Moderate reaction--a mixed inflammatory infiltrate, not well localized.
- 3 Severe reaction characterized by a heavy infiltrate, possibly accompanied by resorption of bone.

Root Resorption. Two categories were considered:

Category 1: Root resorption in the coronal half of the segment.

Category 2: Root resorption in the apical half of the segment.

A score was given for each root segment according to the following scale:

- 0 No evidence of root resorption.
- 1 Surface resorption of cementum only and the defect was replaced.
- 2 Resorption of both cementum and dentin and the defect was replaced by calcified tissue; no active resorption apparent.
- 3 Active resorption in cementum only.
- 4 Active resorption of cementum and dentin.
- 5 Rampant resorption of the root segment in toto.

Bone regeneration coronal to the root segment was graded according to the following scale:

- 0 No evidence of regeneration.
- 1 Minimal bone regeneration.
- 2 Bone regeneration covering at least half the root segment.
- 3 Bone regeneration covering the entire root segment.

#### RESULTS

Primary closure of the flaps resulted in rapid healing of all surgical sites. Clinically the ridge contours were normal and none of the submerged root segments could be perceived.

Histological examination revealed all roots which had been extracted and reimplanted exhibited some degree of root resorption. Root canal sealer could be seen expressed from the coronal portion of all roots.

Figures 1, 2, 3 and 4 illustrate specimens in different stages of resorption and repair. Active resorption occurred up to 60 days; after that, none of the experimentally treated roots revealed active resorption. In addition, none of the roots showed evidence of destructive inflammatory type resorption. Parts of the root surfaces could be described as showing surface resorption (Figures 1 & 2). However, most of the roots showed replacement resorption with resulting ankylosis.<sup>(3)</sup> Scalloped areas of resorption into cementum and dentin indicated various stages of replacement by bone (Figures 3 & 4).

\* From the radiographs at the time of sacrifice it was difficult to interpret the resorption which was present histologically (Figure 5).

The inflammation which was associated with the roots appeared to be primarily a response to the excess root canal sealer that was expressed coronally and periapically. Inflammation was evident in all specimens up to 90 days (Figure 3) but absent in the 120 day specimens (Figure 4). The cellular reaction was predominately a chronic inflammatory response which walled off the excess root canal sealing material. The scores for inflammation and coronal apposition are shown in Tables 1 and 2.

Thirty-six percent of the reimplanted roots had new bone formation which extended over more than 50% of the coronal surface. Complete osseous coverage of the root segment was noted as early as 45 days (Figure 6).

None of the control teeth exhibited root resorption or apical inflammation. Lateral and mesio-distal radiographs did not show new alveolar bone over these roots although new bone was readily observable on histological examination (Figures 5 & 7).

#### DISCUSSION

In this study the resorption proceeded to penetrate through the cementum and into the dentin to a maximum depth of 0.5 mm. The reason for more resorption in the apical third is unclear but could have resulted from trapped blood elements or excess pressure exerted from the implanted root.

The reimplantation procedure has two advantages. The coronal portion of the root can be contoured without removing alveolar bone and chair time is minimized at the surgery appointment.

Completing the endodontic procedure prior to extraction probably decreases the amount of resorption (4) but increases the chair time and difficulty of the procedure. In their study Simon and Kimura completed the

endodontic procedures extraorally. Seven of the eighteen roots after 18 months demonstrated coronal resorption radiographically<sup>(2)</sup>. In the present study there was some evidence of resorption radiographically and this was readily evident histologically (Figures 5 and 7).

The resorption that occurred was not considered a disadvantage in this model because it became inactive after 60 days. Resulting ankylosis could conceivably be an advantage by preventing future eruption and loss of the remaining alveolar ridge.

If the sealer had not been expressed from the coronal portion of the roots more coronal bone may have formed. It was our impression while reading the histological specimens that the root canal cement may have prevented bone formation coronal to the root segments. The amount of inflammation surrounding the root canal sealer could have been decreased by placing an amalgam filling in the canal orifice or by staging the procedure in two steps to allow the sealer to harden. Even in spite of the presence of inflammation new bone formed coronally to the root in some cases (Figure 6).

As a result of this study it appears that submerging reimplanted roots will shorten the clinical operative time but will introduce resorptive processes into the procedure. Although the resorptive processes stop at 60 days in our dog model, it cannot be recommended for humans because of the unpredictable resorptive results of reimplantation in humans.

#### SUMMARY

\* Root canal therapy was accomplished on the mandibular premolars of four dogs. These premolars were then extracted, contoured,

reimplanted and submerged. Resorption occurred up to 60 days; healing progressed satisfactorily with some evidence of coronal osseous regeneration. Root canal sealer was expressed out the coronal orifice after the roots were submerged. This sealer appeared to affect normal healing over the coronal surface of the roots.

REPRINT REQUESTS

COL Carlos E. del RIO  
Director, Endodontic Residency  
Chief, Division of Clinical Research  
US Army Institute of Dental Research  
Washington, DC 20012

TABLE I

New Bone Formation Over Endodontically Treated Reimplanted Roots

	<u>0</u>	<u>1</u>	<u>2</u>	<u>3</u>
14 roots read	2	7	4	1

9 showed apposition

TABLE II

Inflammation With Reimplanted Endodontically Treated Roots

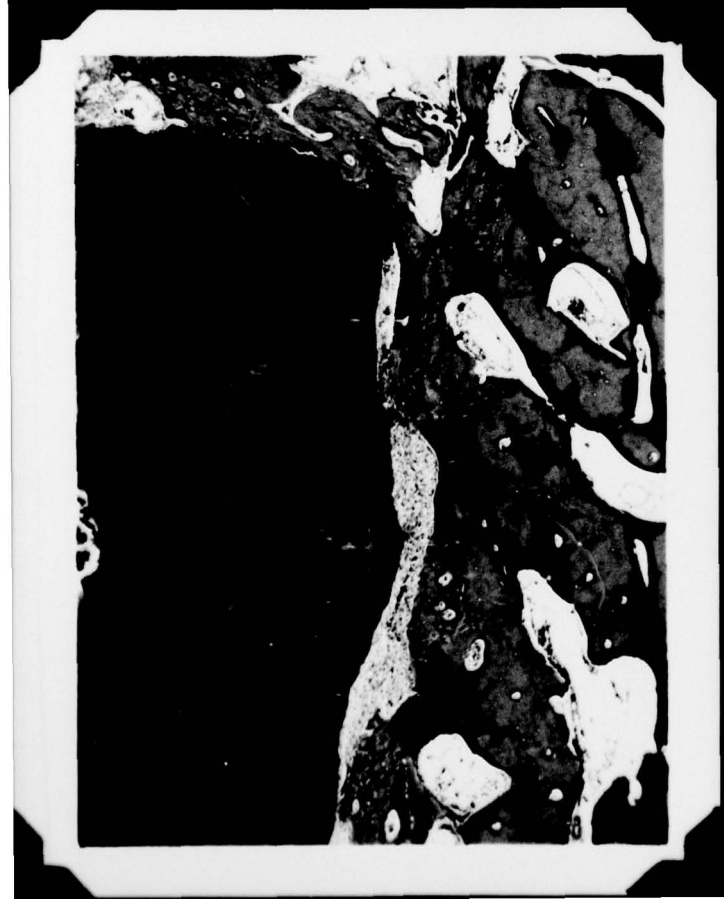	<u>Scale</u>	0	1	2	3
Periapical		9	3	1	1
Pericoronal		3	8	2	1

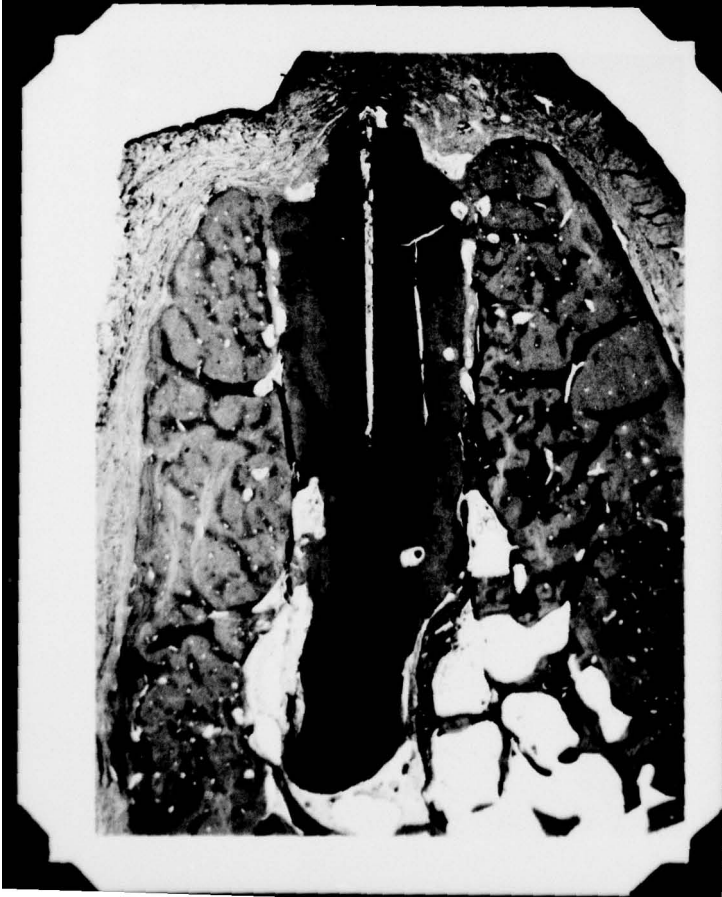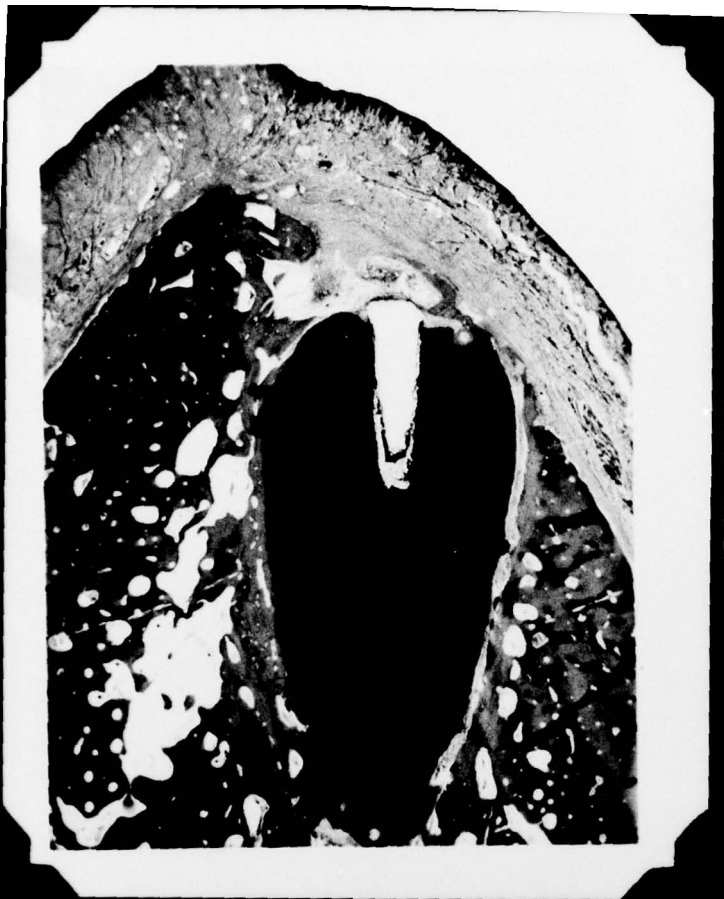## REFERENCES

1. O'Neal, R. B., Gound, T., Levin, M. and del Rio, C.:  
Submergence of roots for alveolar preservation, Part I.  
endodontically treated teeth, Oral Surg.,
2. Simon, J. and Kimura, J.: Maintenance of alveolar bone by the  
intentional reimplantation of roots, Oral Surg., 37:936-944,  
1974.
3. Andreasen, J.: Replantation of extracted molars, a radiographic  
and histologic study, Acta Odont Scand., 44:328-345, 1966.
4. Andreason, J. O. and Hjørting-Hansen, E.: Reimplantation of  
teeth. I. Radiographic and clinical study of 110 human teeth  
replanted after accidental loss, Acta Odont. Scand., 24:263-  
286, 1966.

- Figure 1. Thirty-day specimen with active surface resorption (arrow) of cementum and dentin. (40X)
- Figure 2. Photomicrograph of a fifty-five day specimen with active surface resorption of cementum (c) and dentin (d) and replaced by calcified tissue (t) and area of connective tissue interface (ct). Coronal dentin is ankylosed by new coronal bone (a). (40X)
- Figure 3. Ninety-day specimen illustrating both surface resorption (arrow) and replacement resorption (\*). Due to elastic recoil the gutta percha point extruded from the canal. Inflammation (i) is evident coronal to extruded gutta percha. (10X)  
Lingual (L); Buccal (B).
- Figure 4. One-hundred-twenty-day specimen with scalloped areas of resorption into dentin with replacement by bone (\*) in the coronal half. The apical half exhibits surface resorption with replacement by connective tissue (arrow). (10X)
- Figure 5. Radiograph of one-hundred-twenty-day specimen.
- Figure 6. Photomicrograph of 45-day specimen with new bone (b) formed coronally in spite of the presence of inflammation. (32X)

Figure 7. Mesial-distal radiograph showing the relative position of the root in relation to the buccal (B) and lingual (L) cortical plates.





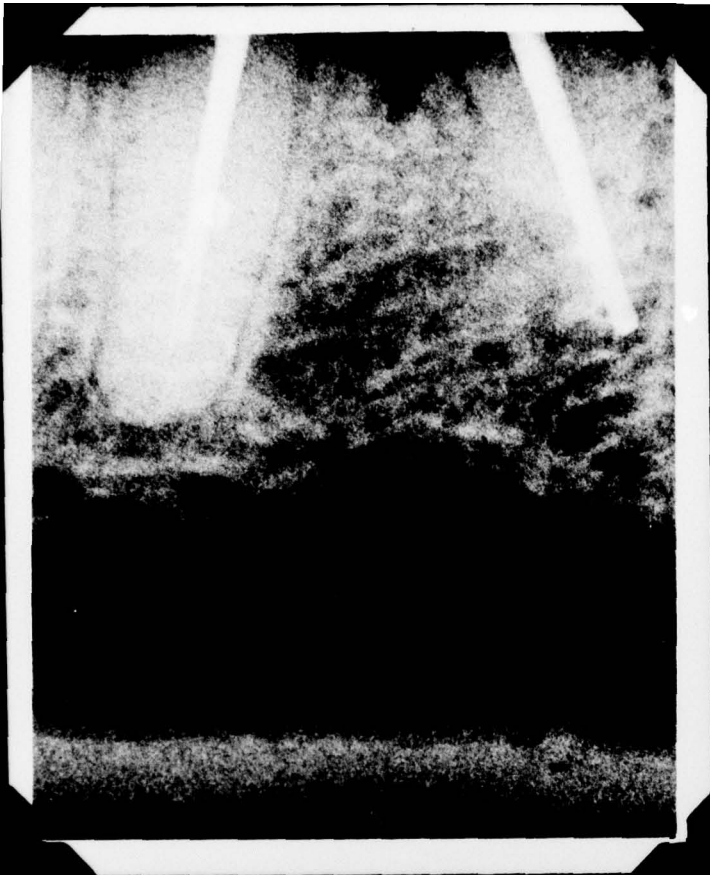


FIGURE 5



FIGURE 6

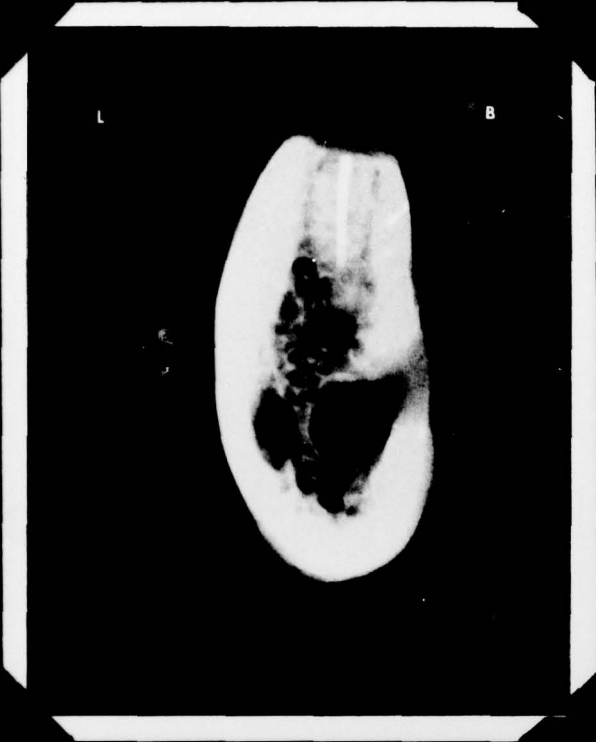

FIGURE 7