

AD-A044 996

ARMY MEDICAL RESEARCH INST OF INFECTIOUS DISEASES FR--ETC F/G 6/5
ALTERATIONS OF BODY FLUID COMPARTMENTS AND DISTRIBUTION OF TISS--ETC(U)
SEP 77 C T LIU, D E HILMAS, M J GRIFFIN

UNCLASSIFIED


NL

1 of 1
ADA044996



The microfiche contains 33 frames of data, arranged in three rows. The first row has 12 frames of text. The second row has 12 frames, including several tables and graphs. The third row has 9 frames, including several graphs and tables. The data is presented in a structured, scientific format.

END
DATE
FILMED
11-77
DDC



MICROCOPY RESOLUTION TEST CHART
NATIONAL BUREAU OF STANDARDS 1963-A

AD A 044996

6 Alterations of Body Fluid Compartments and Distribution of Tissue Water and Electrolytes in Monkeys during Rocky Mountain Spotted Fever.

10 C. T./Liu, D. E./Hilmas, M. J./Griffin,
C. E./Pedersen, Jr. C. L./Hadick, Jr., and W. R./Beisel

DDC
OCT 11 1977
PUBLIC

16 3M762776A841 17 pp 9 Interim rept.
From the U. S. Army Medical Research Institute of Infectious Diseases,
Fort Detrick, Frederick, Maryland 21701 11 23 Sep 77

21 Report on
Running Head: ROCKY MOUNTAIN SPOTTED FEVER IN MONKEYS. 13 3 pp.

A portion of this work was published as an abstract in Proc. Inter. Union Physiol. Sci. (Paris) 13:451, 1977.

In conducting the research described in this report, the investigators adhered to the "Guide for the Care and Use of Laboratory Animals," as promulgated by the Committee on the Revision of the Guide for Laboratory Animal Facilities and Care of the Institute of Laboratory Animal Resources, National Research Council. The facilities are fully accredited by the American Association for Accreditation of Laboratory Animal Care.

The views of the author do not purport to reflect the positions of the Department of the Army or the Department of Defense.

Please send proofs to: C. T. Liu, Ph.D., Research Physiologist, Animal Assessment Division, U. S. Army Medical Research Institute of Infectious Diseases, Fort Detrick, Frederick, Maryland 21701

Approved for public release; distribution unlimited

23 Sep 77

405 039

mt

AD No. _____
DDC FILE COPY

Alterations of Body Fluid Compartments and Distribution of Tissue Water
and Electrolytes in Monkeys during Rocky Mountain Spotted Fever

C. T. Liu, D. E. Hilmas, M. J. Griffin,
C. E. Pedersen, Jr., C. L. Hadick, Jr., and W. R. Beisel

From the U. S. Army Medical Research Institute of Infectious Diseases,
Fort Detrick, Frederick, Maryland 21701

Running Head: ROCKY MOUNTAIN SPOTTED FEVER IN MONKEYS

A portion of this work was published as an abstract in Proc. Inter.
Union Physiol. Sci. (Paris) 13:451, 1977.

In conducting the research described in this report, the investigators adhered to the "Guide for the Care and Use of Laboratory Animals," as promulgated by the Committee on the Revision of the Guide for Laboratory Animal Facilities and Care of the Institute of Laboratory Animal Resources, National Research Council. The facilities are fully accredited by the American Association for Accreditation of Laboratory Animal Care.

The views of the author do not purport to reflect the positions of the Department of the Army or the Department of Defense.

Please send proofs to: C. T. Liu, Ph.D., Research Physiologist, Animal Assessment Division, U. S. Army Medical Research Institute of Infectious Diseases, Fort Detrick, Frederick, Maryland 21701

ABSTRACT

Chair-restrained rhesus monkeys were inoculated subcutaneously with 10^{2-3} plaque forming units of virulent Rickettsia rickettsii. The latent period for fever and rickettsemia was found to be 3-4 days and death occurred within 6-8 days postinfection. Total circulatory electrolytes and fluid volumes including plasma, red blood cell, true circulatory blood, and extracellular fluid increased during Rocky Mountain spotted fever. The expansion of the extracellular and plasma volumes resembled the findings reported to occur during severe RMSF infections in man, guinea pigs and rabbits. Liver total water content also increased. Intracellular K^+ , as well as total Na^+ and K^+ decreased in the diaphragm. Both the lung and medulla oblongata showed increased intracellular Na^+ and water with simultaneously decreased extracellular Na^+ and water. It is suggested that intracellular overhydration of the medulla oblongata may contribute to death as a result of depression of the cardiovascular and respiratory centers. Based on the findings in monkeys the intravenous infusion of fluids and electrolytes during clinical therapy of severe rickettsial infections should be considered as extremely dangerous.

100 to 1000

VERSION for	
W IS	White Section <input checked="" type="checkbox"/>
DDC	Buff Section <input type="checkbox"/>
UNANNOUNCED	<input type="checkbox"/>
JUSTIFICATION _____	
BY _____	
DISTRIBUTION/AVAILABILITY CODES	
SPECIAL	
A	

Rocky Mountain Spotted Fever (RMSF) remains a disease of considerable importance during the spring and early summer throughout rural areas of eastern and midwestern United States [1-4]. Biting ticks, infected with Rickettsia rickettsii generally transmit the infection to man, but the rickettsiae may also be transmitted directly via the airborne route in laboratory accidents [5,6].

Ricketts was the first to isolate the causative organism from patients with RMSF in 1909 [7]. Forty years later, Harrell [8], and Harrell and Aikawa [9] described several RMSF-induced physiological changes in children and adults. Extracellular fluid volume expansion, systemic edema, vasculitis [10], skin rash, headache and certain neurological syndromes [11-13] characterized the infection. Although selected antibiotics including tetracyclines and chloramphenicol have proven to be excellent in the treatment of RMSF [14,15], patients may still die if specific therapy is not initiated during the early phase of the disease. Delayed treatment of RMSF may result from incorrect diagnosis or late admission to a medical facility. Since the specific cause of death in RMSF infections remains to be determined, the objectives of this study were to study RMSF-induced pathophysiologic changes in a subhuman primate model (rhesus monkey), (2) to examine alterations of body fluid compartments and distribution of tissue water and electrolytes, and (3) to extrapolate physiologic information from monkeys to improve clinical guidelines and supportive treatment in patients.

In order to compare values between control and infected monkeys, base-line values of total water content and electrolyte levels, as well as their distributions across cell membranes in various tissues were also determined.

Methods and Materials

The entire study was performed in facilities designed to permit a Class III level of microbiological containment.¹ Sixteen healthy, male, conscious, rhesus monkeys weighing 3-5 kg were adapted to chair restraint for 6 days prior to initiation of the study. Monkey chow and water were provided ad libitum. Ten monkeys were inoculated subcutaneously (sc) with 10^{2-3} plaque forming units (pfu) of chick yolk sac-grown R. rickettsii (Sheila Smith strain). Six control monkeys were inoculated similarly, with sterile chick yolk sac material. Rectal temperature and body weight were measured daily. A 3-5-ml blood sample was collected from each monkey by direct venipuncture before placement in primate restraint chairs and prior to inoculation. After inoculation, blood samples were taken every 2 days until death. Rickettsemia [16], hematocrit, plasma concentrations of protein and electrolytes, and plasma osmolality were determined in these blood samples. Five days after inoculation, the femoral artery and vein of each monkey were cannulated under ketamine anesthesia (10 mg/kg) to measure arterial blood pressure and to inject indicators for fluid compartment measurements. On the basis of clinical indications of overwhelming infection, i.e., a sudden decrease in rectal temperature from peak fever and deteriorating clinical appearance, body fluid compartments were determined in each infected monkey from 6 and 8 days postinoculation [17]. However, the body fluids of all control monkeys were determined on day 8. Body fluid compartments were determined by the dilution principle. A total of 5 hr were required to complete the fluid volume measurements. Evans blue, ^{51}Cr -labeled red blood cell (RBC), Na thiocyanate, and tritiated water were used as indicators.

Upon completion of body fluid determinations, all monkeys were

anesthetized with ketamine (40 mg/kg) and killed by opening the chest and removing the beating heart [18,19]. Fourteen different tissues of each monkey including skin, skeletal muscle (gastrocnemius), cardiac muscle (left ventricular), lung, diaphragm, liver, renal cortex, renal outer medulla, renal inner medulla, cerebral cortex (predominantly grey matter), cerebellum, thalamus and hypothalamus complex, medulla oblongata, and spinal cord were taken within 10 min of death to determine their content of water, electrolytes, and total lipid. Water content was determined by drying a small tissue sample (0.2-0.5 g) at 100 C for 48 hr to a constant weight by a method previously described [18,19]. Electrolytes (Na^+ and K^+) were extracted with 10% trichloroacetic acid (1:10, wt/vol) after homogenization, and determined on a flame photometer [18,20]. Tissue Cl^- was extracted with distilled water and analyzed with a chloridometer [21]. For the calculation of electrolyte concentration in terms of fat-free tissue, total lipids of each tissue were extracted with 2:1 (vol/vol) chloroform-methanol by a standard method [22]. For each gram of tissue, 20 ml of the mixed solvent was added for extraction. The tissue extract was further purified with distilled water and its lipid content was determined gravimetrically. Intracellular and extracellular water and electrolyte distributions were calculated according to equations reported by Benson et al. [23]. A Donnan factor 0.98 was used for the cardiac muscle, while a factor of 0.95 was utilized for all other tissues. All data were analyzed statistically. When control vs. illness values for the same monkey were compared, the paired t test was employed. When comparison was made between control and infected groups, the differences were analyzed using an independent t test. The null hypothesis was rejected at the 5% level.

Results

Fever and rickettsemia. A significant increase in the rectal temperature was observed within 3 days after inoculation (figure 1). The rectal temperature reached a plateau value of approximately 40.3 C about day 5; fever then remained at high levels for 2-3 additional days but began to fall rapidly when the disease became agonal. During the febrile period, high titer rickettsemia (70-370 pfu/ml) was present.

Body fluid compartments and total circulatory electrolytes. Although no change was found in the total body water of infected monkeys, there was a shift of intracellular water to the extracellular space (figure 2). Further, extracellular water increased significantly as compared to control monkeys. The increased extracellular fluid volume during late infection resulted primarily from an increase in plasma volume without a significant change in the interstitial fluid. Further, RBC and true circulatory blood volumes were also markedly increased (figure 3) without appreciable changes in either hematocrit or the F cell ratio. Although plasma concentration of Na^+ , K^+ , and Cl^- were not altered during this rickettsial infection, total amounts of circulatory electrolytes were significantly increased ($P < 0.05$) due to the increased plasma volume in infected as compared with control monkeys (figure 4).

Changes in tissue water and electrolytes. Among the 14 different tissues analyzed in monkeys infected with RMSF, only liver, lung, diaphragm and medulla oblongata showed significant changes in either water content, electrolyte concentrations, or both when compared to control values (tables 1-4). The following tissue changes were significant during infection when compared to control values: (1) total water content of the liver was increased; (2) total and intracellular Na^+ concentrations

were decreased and total K^+ levels were increased in the diaphragm (tables 1-2); and (3) intracellular water content and total Na^+ values were increased in the medulla oblongata, while extracellular Na^+ , K^+ , and water, and intracellular K^+ concentrations were all decreased in the same tissue (tables 3-4). Water and electrolyte changes in the lung were similar to those of the medulla oblongata, except that an increased trend of intracellular Na^+ was observed in the lung (tables 1-2).

Cardiovascular responses and plasma changes. During RMSF, monkeys showed few changes in mean arterial blood pressure and heart rate until shortly before death. Other plasma variables such as water content, protein concentration, osmolality, and electrolyte concentrations (Na^+ , K^+ and Cl^-) did not reveal significant changes during the infection.

Body weight changes. Mean body weight of monkeys decreased significantly from 4.9 to 4.6 kg during the first day after placement in restraint chairs. Mean body weights of both groups remained at this value for 5 days prior to inoculation and throughout the course of study in all monkeys until death.

Discussion

The rhesus monkey has been shown to be quite susceptible to infection with R. rickettsii [24-26]. Clinical signs of RMSF infection in monkeys are similar to those in man as described by Feigin et al. [5], Sanders and Smithson [27] and others [8-10, 28-32]. However, with this laboratory model, the time course for RMSF in rhesus monkeys is shorter than that observed in most human patients. Further, the mean times to death for infected monkeys housed in standard primate restraint cages are longer (7-12 days) than mean death time for chair restrained

monkeys (6-8 days) [24].

The pathophysiologic responses to RMSF in humans is characterized by peripheral vascular collapse, capillary dilatation and pooling of blood induced during the early phase of RMSF [8,9,29,32]. As proliferative and thrombotic lesions develop in small vessels, anoxia occurs in areas supplied by the impaired circulation. Tissue necrosis and increased capillary permeability ensue.

A significant increase in "thiocyanate space" and a slight expansion of plasma volume were observed during the peak illness of RMSF in man [9,29]. Slow return of increased extracellular fluid volume toward normal levels coincided with recovery from the disease. Similar increases in the "thiocyanate space" in rabbits [33] and tissue "radiosodium space" in guinea pigs [34] were also reported during RMSF. In the present study, increases of plasma, RBC, and true circulatory blood volumes were observed near the terminal stage of RMSF in monkeys. The design of the present study did not allow us to determine the time of onset of volume expansion. Increases in plasma volume values may be induced by the accumulation of electrolytes in the circulation of the terminally ill monkey. Plasma levels of antidiuretic hormone and aldosterone are known to increase during this rickettsial infection in man (personal communication with Dr. R. D. Feigin); a combination of these endocrine effects may explain renal retention of Na^+ , Cl^- , and water in monkeys during RMSF. Because rickettsiae actively penetrate body cells [35,36] and can alter functions of cell membranes, a cellular release of K^+ may explain the fact that plasma circulating K^+ failed to decrease in the presence of increased aldosterone levels. It is also possible that the increase in RBC volume after infection was due to bone marrow stimulation, or to

increased RBC releases from storage sites, such as the spleen and liver.

A review of the literature failed to reveal any data concerning the tissue water or electrolyte content in healthy young adult rhesus monkeys. Because of the importance of fluid and electrolyte overloading in patients with severe RMSF, it was essential to generate normal base-line values for 14 different tissues in the control group of chair-restrained monkeys as well as data concerning total, intracellular and extracellular distributions of water and electrolytes. Measurements of body fluid compartments were made using accepted methods, as previously reported in healthy conscious rhesus monkey studied in this laboratory [17]. The reproducibility of the applied methodology was confirmed by data from the control group of monkeys used here.

Body weight of both groups of monkeys decreased significantly on the first day after chairing and remained constant for 5 days prior to inoculation and subsequently. The initial loss of body weight in both groups under conditions of chair restraint may be attributed to decreased food and water intake or to an increased rate of metabolism. The fact that body weight then remained constant between the time of inoculation and death is consistent with the finding that total body water was not altered significantly in infected monkeys. It appears that the increased extracellular fluid volume, including plasma volume, occurred due to a shift of intracellular water or from accumulation of extracellular electrolytes, or both. The decrease in intracellular water of 20.5 ml/kg could account for 83% of the net gain in extracellular fluid volume (24.7 ml/kg). Since net plasma volume was increased to 11.3 ml/kg without simultaneous changes in plasma total protein or electrolyte concentrations, water content or osmolality during infection, it seems

unlikely that the capillary permeability was significantly increased in monkeys with RMSF.

The expansion of extracellular fluid volume and the infectious processes in monkeys selectively altered water and electrolyte content or distribution in the liver, diaphragm, lung and medulla oblongata. The expected differences between the skeletal muscle of diaphragm and gastrocnemius in control monkeys, i.e., higher intracellular Na^+ and water; lower extracellular Na^+ and water, could be explained by the continuing respiratory work performed by the diaphragm in chaired monkeys. During RMSF, total and intracellular Na^+ were decreased, while total K^+ was increased in the diaphragm.

One of the unique findings is that among five portions of the brain studied, only the medulla oblongata showed significant changes in water and electrolyte distributions. Intracellular overhydration in the medulla of the brain occurred in infected monkeys as shown by increased intracellular water and Na^+ . Local swelling of nerve cells at the medulla oblongata could depress both the cardiovascular and respiratory centers, and lead to circulatory shock and respiratory arrest. The evidence for CNS overhydration in these monkeys appears to be compatible with some of the clinical signs and symptoms indicative of CNS involvement in man.

Evidence of neurologic dysfunction may be overlooked during severe RMSF in man [13] despite the apparent frequency and severity of CNS involvement [12]. Frontal or generalized headaches of extreme severity often typify severe RMSF and are not easily relieved. An abnormal mental status with lethargy, confusion, delirium, euphoria, coma or stupor was observed in more than half of the patients included

in a recently published large series [13]. Signs of meningeal irritation may occur early in infants and children with RMSF and contribute to diagnostic uncertainty [11]. Focal neurological signs may occur to suggest cranial nerve or corticospinal pathway lesions; seizures of either a generalized or focal variety may occur. Neurological, intellectual, and work-performance sequelae may persist following recovery [37-39].

The clinical manifestations of CNS dysfunction during RMSF have been ascribed to the presence of destructive or proliferative thrombovasculitic lesions in the small blood vessels of the brain and meninges [11-13, 37]. The possibility that the CNS effects may also be due, in part, to localized or generalized imbalances of fluids and electrolytes is supported by the occasional clinical findings of papilledema [11], increases of spinal fluid pressure [12], and the findings of the present study.

A recent report from the Center for Disease Control in Georgia presented two cases of RMSF [6]. The patients showed clinical pictures similar to the infected rhesus monkey. The duration of illness was short (4-5 days) and a rash was not noted on either patient.

It may be concluded that extracellular fluid expansion with retention of electrolytes occur during RMSF in monkeys. This finding is consistent with systemic edema observed in patients with severe RMSF. Local disturbances of water and electrolyte metabolism in the medulla oblongata may be associated with some of the neurological symptoms and the cardio-respiratory depression. Because a fluid overload may already be present in the vascular bed and CNS tissues of patients with severe, advanced RMSF, extreme caution must be observed if intravenous

infusions of fluids and electrolytes are contemplated during the clinical management of the patient with RMSF. The danger of intravenous fluid administration would appear to be greatest in infants and young children [5].

ACKNOWLEDGEMENTS

The authors thank Dr. R. H. Kenyon for providing R. rickettsii, SP5 D. R. Dufault, Mr. R. D. DeLauter, and Mr. G. E. Crone for technical assistance, Mrs. Phebe W. Summers for editorial assistance, Miss Linda Stup and PFC J. A. Kennard for typing, and Mrs. Regina E. Staley for secretarial aid.

Footnotes

¹Classification of Etiologic Agents on the Basis of Hazard. U. S. Dept. of Health, Education and Welfare. Public Health Service, Center for Disease Control, Office of Biosafety, Atlanta, Georgia 30333, September 1976. pp. 1-13.

References

1. Hattwick, M. A. W. Rocky Mountain spotted fever in the United States, 1920-1970. *J. Infect. Dis.* 124:112-114, 1971.
2. Hattwick, M. A. W., O'Brien, R. J., Hanson, B. F. Rocky Mountain spotted fever: epidemiology of an increasing problem. *Ann. Intern. Med.* 84:732-739, 1976.
3. Hattwick, M. A. W., Peters, A. H., Gregg, M. B. Hanson, B. Surveillance of Rocky Mountain spotted fever. *J. Am. Med. Assoc.* 225:1338-1343, 1973.
4. Pedersen, C. E., Jr. Rocky Mountain spotted fever: A disease that must be recognized. *J. Am. Med. Technol.* 36:190-198, 1977.
5. Feigin, R. D., Kissane, J. M., Eisenberg, C. S., Kahn, L. I. Rocky Mountain spotted fever. Successful application of new insights into physiologic changes during acute infections to successful management of a severely-ill patient. *Clin. Pediatr.* 8:331-343, 1969.
6. Center for Disease Control. Fatal Rocky Mountain spotted fever-- Georgia. *Morbidity and Mortality Weekly Report.* 26:84, 1977.
7. Woodward, T. E. A historical account of the rickettsial diseases with a discussion of unsolved problems. *J. Infect. Dis.* 127:583-594, 1973.
8. Harrell, G. T. Rocky Mountain spotted fever. *Medicine* 28:333-370, 1949.
9. Harrell, G. T., Aikawa, J. K. Pathogenesis of circulatory failure in Rocky Mountain spotted fever. Alterations in the blood volume and the thiocyanate space at various stages of the disease. *Arch. Intern. Med.* 83:331-347, 1949.

10. Hand, W. L., Miller, J. B., Reinartz, J. A., Sanford, J. P.
Rocky Mountain spotted fever. A vascular disease. Arch.
Intern. Med. 125:879-882, 1970.
11. Bell, W. E., Lascari, A. D. Rocky Mountain spotted fever.
Neurological symptoms in the acute phase. Neurology 20:841-
847, 1970.
12. Harrell, G. T. Rickettsial involvement of the nervous system.
Med. Clin. North Am. 37:395-422, 1953.
13. Miller, J. O., Price, T. R. Involvement of the brain in Rocky
Mountain spotted fever. South Med. J. 65:437-439, 1972.
14. Parker, R. T., Bauer, R. E., Lister, L. M., Woodward, T. E.,
Hall, H. E. Further experience in the treatment of Rocky
Mountain spotted fever with chloramphenicol. Am. J. Med.
9:308-314, 1950.
15. Szalay, G. C. Tick-borne disease. Am. J. Dis. Child. 127:909,
1974.
16. Wike, D. A., Burgdorfer, W. Plaque formation in tissue cultures
by Rickettsia rickettsii isolated directly from whole blood and
tick hemolymph. Infect. Immun. 6:736-738, 1972.
17. Liu, C. T., Griffin, M. J., Faulkner, R. T. Effect of
staphylococcal enterotoxin B on body fluid compartments in
conscious rhesus monkeys. J. Med. Primatol. 5:336-344, 1976.
18. Liu, C. T., Overman, R. R. Responses of x-irradiated dogs to
induced muscular contraction in vivo. Radiat. Res. 24:452-472,
1965.

19. Liu, C. T., Overman, R. R. Changes in tissue electrolytes, lipids, and glycogen during hypocalcemic tetany in dogs. *Texas Rep. Biol. Med.* 27:93-100, 1969.
20. Overman, R. R., Davis, A. K. Application of flame photometry to sodium and potassium determinations in biological fluids. *J. Biol. Chem.* 168:641-649, 1947.
21. Cotlove, E., Trantham, H. V., Bowman, R. L. An instrument and method for automatic, rapid, accurate, and sensitive titration of chloride in biologic samples. *J. Lab. Clin. Med.* 51:461-468, 1958.
22. Folch, J., Less, M., Sloane Stanley, G. H. A simple method for the isolation and purification of total lipides from animal tissues. *J. Biol. Chem.* 226:497-509, 1957.
23. Benson, E. S., Freier, E. F., Hallaway, B. E., Johnson, M. J. Distribution of fluid and electrolytes and concentration of actomyocin and other proteins in the myocardium of dogs with chronic congestive heart failure. *Am. J. Physiol.* 187:483-492, 1956.
24. Sammons, L. S., Kenyon, R. H., Burger, G. T., Pedersen, Jr., C. E., Spertzel, R. O. Changes in blood serum constituents and hematologic values in Macaca mulatta with Rocky Mountain spotted fever. *Am. J. Vet. Res.* 37:725-730, 1976.
25. Saslaw, S., Carlisle, H. N., Wolf, G. L., Cole, C. R. Rocky Mountain spotted fever: clinical and laboratory observations of monkeys after respiratory exposure. *J. Infect. Dis.* 116:243-255, 1966.

26. Wolf, G. L., Cole, C. R., Carlisle, H. N., Saslaw, S. The pathogenesis of Rocky Mountain spotted fever in monkeys. Infected by inhalation. Arch. Pathol. 84:486-494, 1967.
27. Sanders, D. Y., Smithson, W. A. Rocky Mountain spotted fever in three brothers. N. C. Med. J. 34:276-278, 1973.
28. Baker, G. E. Rocky Mountain spotted fever. Med. Clin. North Am. 35:907-930, 1951.
29. Harrell, G. T. Physiologic alterations in patients with spotted fever. In: Symposium on the Spotted Fever Group of Rickettsiae, edited by C. L. Wisseman (Med. Sci. Pub. No. 7, Walter Reed Army Institute of Research) U. S. Government Printing Office, Washington D. C. 1960, p. 23-38.
30. Haynes, R. E., Sanders, D. Y., Gramblett, H. G. Rocky Mountain spotted fever in children. J. Pediatr. 76:685-693, 1970.
31. Laycob, L. M., Garin, E., Lerner, W. Rocky Mountain spotted fever in children. Mo. Med. 70:303-306, 1973.
32. Harrell, G. T., Aikawa, J. K. Alterations in the permeability of membranes during infection. J. Am. Med. Assoc. 147:232-238, 1951.
33. Aikawa, J. K., Harrell, G. T. Isotopic studies of fluid and electrolyte changes in domestic rabbits with Rocky Mountain spotted fever. J. Infect. Dis. 93:222-225, 1953.
34. Aikawa, J. K., Harrell, G. T. Changes in the tissue radiosodium space associated with experimental Rocky Mountain spotted fever in guinea pigs. J. Infect. Dis. 93:263-265, 1953.

35. Burgdorfer, W., Anacker, R. L., Bird, R. G., Bertram, D. S.
Intranuclear growth of Rickettsia rickettsii. J. Bacteriol.
96:1415-1418, 1968.
36. Smadel, J. E. Intracellular infection and the carrier state.
The path of clinical investigation leads from bench to bed and
back again. Science 140:153-160, 1963.
37. Rosenblum, M. J., Masland, R. L., Harrell, G. T. Residual
effects of rickettsial disease on the central nervous system.
Arch. Intern. Med. 90:444-455, 1952.
38. Thomas, M. H., Berlin, L. Neurologic sequelae of Rocky Mountain
spotted fever. Arch. Neurol. Psychiatry 60:574-584, 1948.
39. Wright, L. Intellectual sequelae of Rocky Mountain spotted fever.
J. Abnorm. Psychol. 80:315-316, 1972.

FIGURE LEGENDS

- Fig. 1. Changes in rectal temperature and presence of rickettsemia in monkeys with Rocky Mountain spotted fever.
- Fig. 2. Changes in total body, extracellular, and intracellular water in monkeys with Rocky Mountain spotted fever.
- Fig. 3. Changes in plasma, red blood cell, and true circulatory blood volumes in monkeys with Rocky Mountain spotted fever.
- Fig. 4. Increases in total amount of circulatory electrolytes in monkeys with Rocky Mountain spotted fever.

Table 1. Changes in water content in various tissues of monkeys with Rocky Mountain spotted fever (RMSF)

Tissue	Group (n = 6)	H ₂ O Content (g/kg FFWT* ± SE)		
		Total	Extracellular	Intracellular
Heart	Control	794 ± 15	197 ± 25	597 ± 26
	RMSF	820 ± 7	173 ± 24	647 ± 28
Lung	Control	826 ± 6	455 ± 49	371 ± 52
	RMSF	837 ± 11	284 ± 57 [†]	553 ± 59 [†]
Liver	Control	772 ± 12	238 ± 11	534 ± 12
	RMSF	802 ± 5 [†]	208 ± 28	594 ± 30
Renal cortex	Control	827 ± 7	305 ± 48	522 ± 50
	RMSF	839 ± 2	235 ± 33	604 ± 32
Renal outer medulla	Control	823 ± 3	153 ± 17	670 ± 18
	RMSF (n = 2)	864	160	704
Renal inner medulla	Control	836 ± 8	599 ± 29	237 ± 24
	RMSF (n = 2)	882	105	777
Diaphragm	Control	764 ± 9	108 ± 16	656 ± 15
	RMSF	760 ± 13	152 ± 59	608 ± 64
Skeletal muscle	Control	791 ± 10	161 ± 13	630 ± 11
	RMSF	816 ± 13	172 ± 39	644 ± 31
Skin	Control	758 ± 12	506 ± 79	252 ± 87
	RMSF	781 ± 27	459 ± 34	322 ± 42

* FFWT = Fat-free wet tissue.

[†] $P < 0.05$, compared to controls.

Table 2. Changes in Na⁺, K⁺ and Cl⁻ concentrations in various tissues of monkeys with Rocky Mountain

Tissue	Group (n = 6)	Mean ± SE*					
		(Na) _T (mEq/kg FFWT)	(Na) _T (mEq/kg FFDT)	(Na) _E (mEq/kg FFWT)	[Na] _I (mEq/kg H ₂ O)	(K) _T mEq/kg FFWT	(K) _T mEq/kg FFDT
Heart	Control	43.5 ± 3.1	218 ± 22	29.1 ± 3.5	24.1 ± 2.5	71.4 ± 6.2	351 ± 28
	RMSF	44.9 ± 4.5	253 ± 29	20.1 ± 4.0	28.1 ± 6.6	72.5 ± 5.4	407 ± 34
Lung	Control	87.1 ± 2.2	505 ± 15	65.1 ± 7.4	50.5 ± 14	52.3 ± 0.8	304 ± 14
	RMSF	76.9 ± 2.8 [†]	485 ± 49	31.6 ± 7.6 [†]	75.1 ± 9	49.6 ± 1.7	314 ± 38
Liver	Control	42.2 ± 2.1	186 ± 9	30.2 ± 3.8	21.7 ± 5.8	78.2 ± 1.9	349 ± 23
	RMSF	43.9 ± 2.8	223 ± 20	25.5 ± 3.6	29.5 ± 5.3	76.8 ± 2.4	388 ± 10
Renal cortex	Control	58.4 ± 1.3	340 ± 15	34.8 ± 7.1	40.6 ± 9.0	65.2 ± 1.6	378 ± 10
	RMSF	59.5 ± 1.9	369 ± 16	27.5 ± 5.0	53.2 ± 9.0	61.3 ± 2.4	381 ± 19
Renal outer medulla	Control (n = 5)	70.1 ± 7.5	394 ± 38	23.6 ± 0.9	71.5 ± 11.5	63.0 ± 3.8	355 ± 22
	RMSF (n = 2)	66.3	490	36.0	56.3	63.0	470
Renal inner medulla	Control (n = 5)	95.6 ± 5.2	585 ± 25	75.7 ± 11.6	76.8 ± 5.7	59.4 ± 2.5	367 ± 28
	RMSF (n = 2)	83.6	704	14.8	64.4	61.5	519
Diaphragm	Control	49.1 ± 4.4	208 ± 16	12.9 ± 2.6	53.6 ± 7.5	69.6 ± 4.1	298 ± 24
	RMSF	37.3 ± 2.5	156 ± 11 [†]	21.5 ± 8.6	23.9 ± 7.8 [†]	84.9 ± 3.0 [†]	357 ± 22
Skeletal muscle	Control	39.2 ± 2.6	190 ± 16	20.3 ± 2.8	32.1 ± 8.2	84.5 ± 4.6	405 ± 16
	RMSF	46.0 ± 3.0	256 ± 25	24.7 ± 5.8	31.2 ± 9.4	74.4 ± 3.0	414 ± 33
Skin	Control	104 ± 10	431 ± 40	68.3 ± 13	102 ± 7	24.7 ± 1.2	105 ± 8
	RMSF	88 ± 9	433 ± 87	63.0 ± 5	66.3 ± 30	23.5 ± 4	113 ± 23

FFWT = Fat-free wet tissue, FFDT = Fat-free dry tissue, T = Total, E = Extracellular, I = Intracellular

ions in various tissues of monkeys with Rocky Mountain spotted fever (RMSF)

Mean \pm SE*							
(Na) _E	[Na] _I	(K) _T	(K) _T	(K) _E	(K) _I	(Cl) _T	(Cl) _T
mg FFWT)	(mEq/kg H ₂ O)	mEq/kg FFWT	mEq/kg FFDI	mEq/kg FFWT	mEq/kg H ₂ O	mEq/kg FFWT	mEq/kg FFDI
+ 3.5	24.1 \pm 2.5	71.4 \pm 6.2	351 \pm 28	0.743 \pm 0.108	120 \pm 13	26.7 \pm 3.2	132 \pm 20
\pm 4.0	28.1 \pm 6.6	72.5 \pm 5.4	407 \pm 34	0.572 \pm 0.101	112 \pm 10	22.4 \pm 2.4	125 \pm 12
+ 7.4	50.5 \pm 14	52.3 \pm 0.8	304 \pm 14	1.64 \pm 0.18	151 \pm 22	57.6 \pm 5.5	333 \pm 31
\pm 7.6 [†]	75.1 \pm 9	49.6 \pm 1.7	314 \pm 38	0.96 \pm 0.18 [†]	84 \pm 6 [†]	35.4 \pm 5.9 [†]	222 \pm 40
+ 3.8	21.7 \pm 5.8	78.2 \pm 1.9	349 \pm 23	0.863 \pm 0.065	144 \pm 6	31.5 \pm 1.6	142 \pm 11
\pm 3.6	29.5 \pm 5.3	76.8 \pm 2.4	388 \pm 10	0.712 \pm 0.118	126 \pm 7	26.9 \pm 3.3	136 \pm 16
+ 7.1	40.6 \pm 9.0	65.2 \pm 1.6	378 \pm 10	1.220 \pm 0.210	128 \pm 10	39.6 \pm 6.0	229 \pm 34
\pm 5.0	53.2 \pm 9.0	61.3 \pm 2.4	381 \pm 19	0.915 \pm 0.315	102 \pm 8	30.2 \pm 3.8	188 \pm 24
+ 0.9	71.5 \pm 11.5	63.0 \pm 3.8	355 \pm 22	0.588 \pm 0.037	95 \pm 6	21.2 \pm 1.9	120 \pm 11
	56.3	63.0	470	0.933	99	21.7	166
+ 11.6	76.8 \pm 5.7	59.4 \pm 2.5	367 \pm 28	1.940 \pm 0.270	231 \pm 48	74.9 \pm 2.4	465 \pm 41
	64.4	61.5	519	0.383	79	16.0	135
+ 2.6	53.6 \pm 7.5	69.6 \pm 4.1	298 \pm 24	0.503 \pm 0.162	132 \pm 9	15.5 \pm 2.0	61 \pm 9
\pm 8.6	23.9 \pm 7.8 [†]	84.9 \pm 3.0 [†]	357 \pm 22	0.596 \pm 0.244	143 \pm 13	20.9 \pm 7.2	87 \pm 31
+ 2.8	32.1 \pm 8.2	84.5 \pm 4.6	405 \pm 16	0.527 \pm 0.091	132 \pm 9	22.2 \pm 1.7	108 \pm 11
\pm 5.8	31.2 \pm 9.4	74.4 \pm 3.0	414 \pm 33	0.677 \pm 0.158	116 \pm 9	23.0 \pm 4.5	133 \pm 31
+ 13	102 \pm 7	24.7 \pm 1.2	105 \pm 8	1.49 \pm 0.35	105 \pm 42	64.3 \pm 10.2	279 \pm 52
\pm 5	66.3 \pm 30	23.5 \pm 4	113 \pm 23	1.75 \pm 0.07	70 \pm 15	56.0 \pm 4.4	270 \pm 44

e, T = Total, E = Extracellular, I = Intracellular, [†]P < 0.05, compared to controls.

2-

TABLE 3. Changes in water content in various portions of the brain and spinal cord in monkeys with Rocky Mountain spotted fever (RMSF)

Tissue	Group	H ₂ O Content (g/kg FFWT*)		
		Total	Extracellular	Intracellular
Cerebral cortex	Control (n = 6)	859 ± 4	280 ± 37	579 ± 35
	RMSF (n = 4)	861 ± 6	191 ± 15	670 ± 15
Cerebellum	Control	835 ± 10	175 ± 25	660 ± 32
	RMSF	858 ± 7	186 ± 6	672 ± 12
Thalamus, hypo- thalamus	Control	857 ± 14	154 ± 44	703 ± 35
	RMSF	836 ± 19	181 ± 30	655 ± 43
Medulla oblongata	Control	868 ± 11	230 ± 23	638 ± 19
	RMSF	847 ± 12	87 ± 8 [†]	760 ± 12 [†]
Spinal cord	Control	831 ± 23	184 ± 40	647 ± 61
	RMSF	816 ± 12	134 ± 42	682 ± 41

* FFWT = Fat-free wet tissue, [†]P < 0.05 compared to controls.

Table 4. Changes in Na⁺, K⁺ and Cl⁻ concentrations in various portions of the brain and spinal cord in spotted fever (RMSF)

Tissue	Group	Mean ± SE*					
		(Na) _T mEq/kg FFWT	(Na) _T mEq/kg FFDT	(Na) _E mEq/kg FFWT	[Na] _I mEq/kg H ₂ O	(K) _T mEq/kg FFWT	(K) _T mEq/kg FFDT
Cerebral cortex	Control (n = 6)	57.8 ± 3.2	411 ± 24	38.2 ± 5.1	29.7 ± 5.9	94.8 ± 11	678 ± 85
	RMSF (n = 4)	56.8 ± 3.8	384 ± 25	26.3 ± 2.4	45.6 ± 5.6	92.5 ± 1.1	696 ± 49
Cerebellum	Control	51.9 ± 2.6	310 ± 25	24.9 ± 3.2	37.7 ± 6.6	95.1 ± 2.1	577 ± 28
	RMSF	48.3 ± 2.7	352 ± 24	25.6 ± 0.6	36.8 ± 6.4	92.4 ± 3.1	653 ± 38
Thalamus, hypo-thalamus	Control	59.2 ± 1.7	438 ± 50	21.6 ± 5.9	52.6 ± 5.5	94.3 ± 2.9	691 ± 66
	RMSF	61.5 ± 2.1	395 ± 60	24.8 ± 4.1	79.4 ± 21	88.7 ± 2.1	559 ± 53
Medulla oblongata	Control	54.5 ± 2.0	423 ± 27	32.6 ± 2.9	33.5 ± 6.7	103 ± 4.0	803 ± 54
	RMSF	61.4 ± 2.6	408 ± 39	9.87 ± 2.57 [†]	67.6 ± 5.4 [†]	91.0 ± 3.9	598 ± 25 [†]
Spinal cord	Control	79.3 ± 3.1	462 ± 51	25.9 ± 5.6	82.1 ± 4.8	82.3 ± 6.1	516 ± 75
	RMSF	68.7 ± 4.6	373 ± 16	18.8 ± 6.0	73.2 ± 7.8	87.0 ± 8.4	484 ± 72

FFWT = Fat-free wet tissue, FFDT = Fat-free dry tissue, [†]P < 0.05, Control vs. RMSF, * T = Total, E = Extracellular

1

ions in various portions of the brain and spinal cord in monkeys with Rocky Mountain

Mean \pm SE*							
(Na) _E	[Na] _I	(K) _T	(K) _T	(K) _E	[K] _I	(Cl) _T	(Cl) _T
/kg FFWT	mEq/kg H ₂ O	mEq/kg FFWT	mEq/kg FFDT	mEq/kg FFWT	mEq/kg H ₂ O	mEq/kg FFWT	mEq/kg FFDT
2 \pm 5.1	29.7 \pm 5.9	94.8 \pm 11	678 \pm 85	1.020 \pm 0.140	161 \pm 19	37.0 \pm 4.6	266 \pm 36
3 \pm 2.4	45.6 \pm 5.6	92.5 \pm 1.1	696 \pm 49	0.741 \pm 0.092	137 \pm 5	25.4 \pm 1.9	184 \pm 15
9 \pm 3.2	37.7 \pm 6.6	95.1 \pm 2.1	577 \pm 28	0.646 \pm 0.097	143 \pm 9	25.7 \pm 2.8	147 \pm 17
5 \pm 0.6	36.8 \pm 6.4	92.4 \pm 3.1	653 \pm 38	0.718 \pm 0.051	137 \pm 5	24.8 \pm 0.4	175 \pm 8
5 \pm 5.9	52.6 \pm 5.5	94.3 \pm 2.9	691 \pm 66	0.535 \pm 0.135	135 \pm 8	21.3 \pm 5.0	172 \pm 52
8 \pm 4.1	79.4 \pm 21	88.7 \pm 2.1	559 \pm 53	0.714 \pm 0.154	162 \pm 34	24.0 \pm 3.5	148 \pm 18
5 \pm 2.9	33.5 \pm 6.7	103 \pm 4.0	803 \pm 54	0.831 \pm 0.083	162 \pm 9	30.8 \pm 2.6	245 \pm 33
7 \pm 2.57 [†]	67.6 \pm 5.4 [†]	91.0 \pm 3.9	598 \pm 25 [†]	0.332 \pm 0.029 [†]	119 \pm 6 [†]	13.3 \pm 1.2 [†]	89.3 \pm 12 [†]
9 \pm 5.6	82.1 \pm 4.8	82.3 \pm 6.1	516 \pm 75	0.698 \pm 0.173	132 \pm 19	23.6 \pm 5.4	124 \pm 18
3 \pm 6.0	73.2 \pm 7.8	87.0 \pm 8.4	484 \pm 72	0.530 \pm 0.189	128 \pm 13	18.8 \pm 5.1	104 \pm 28

[†] P < 0.05, Control vs. RMSF, * T = Total, E = Extracellular, I = Intracellular.

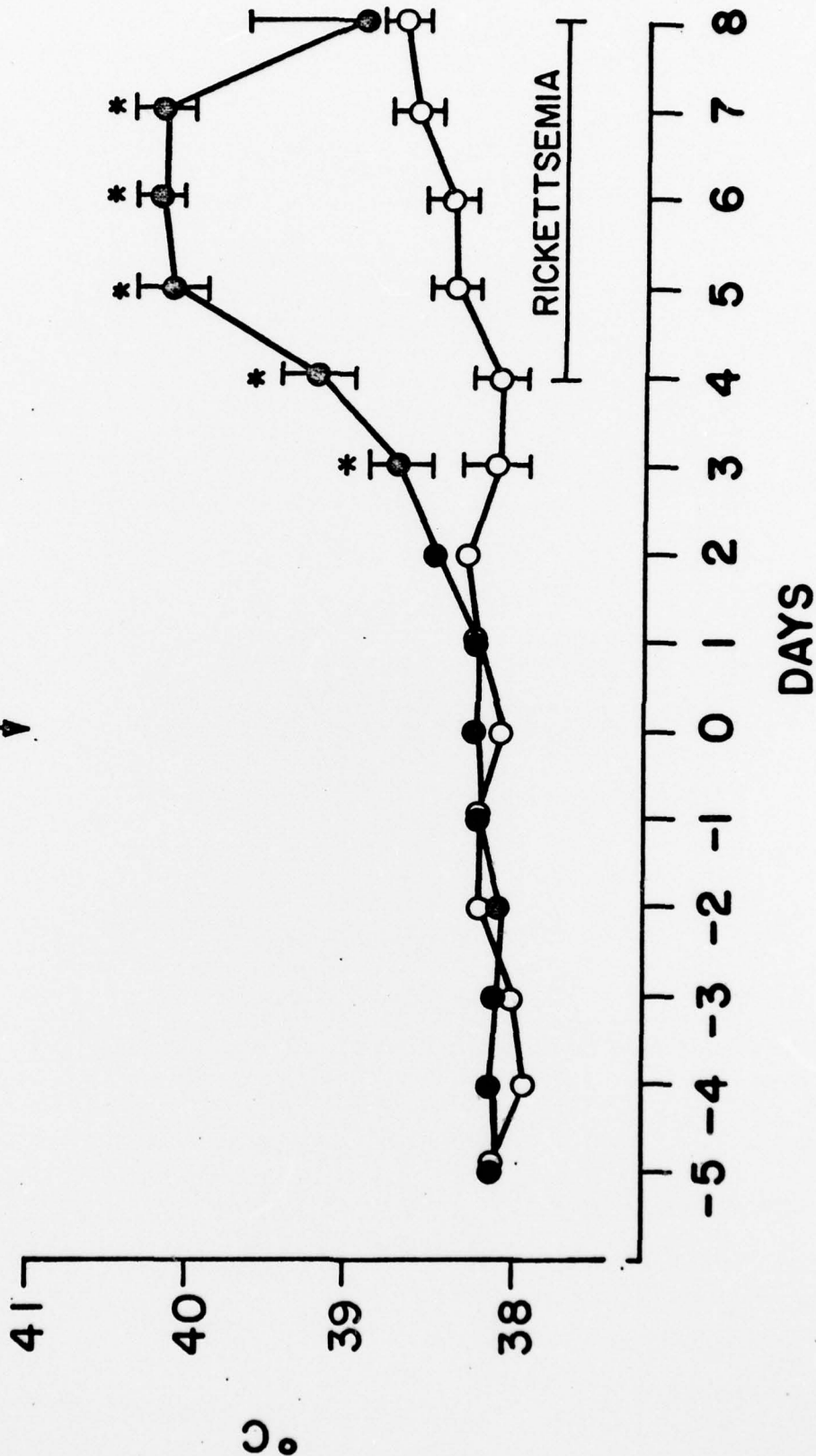
2

* P < 0.05

○ CONTROL (N=6)

● INFECTED (N=10)

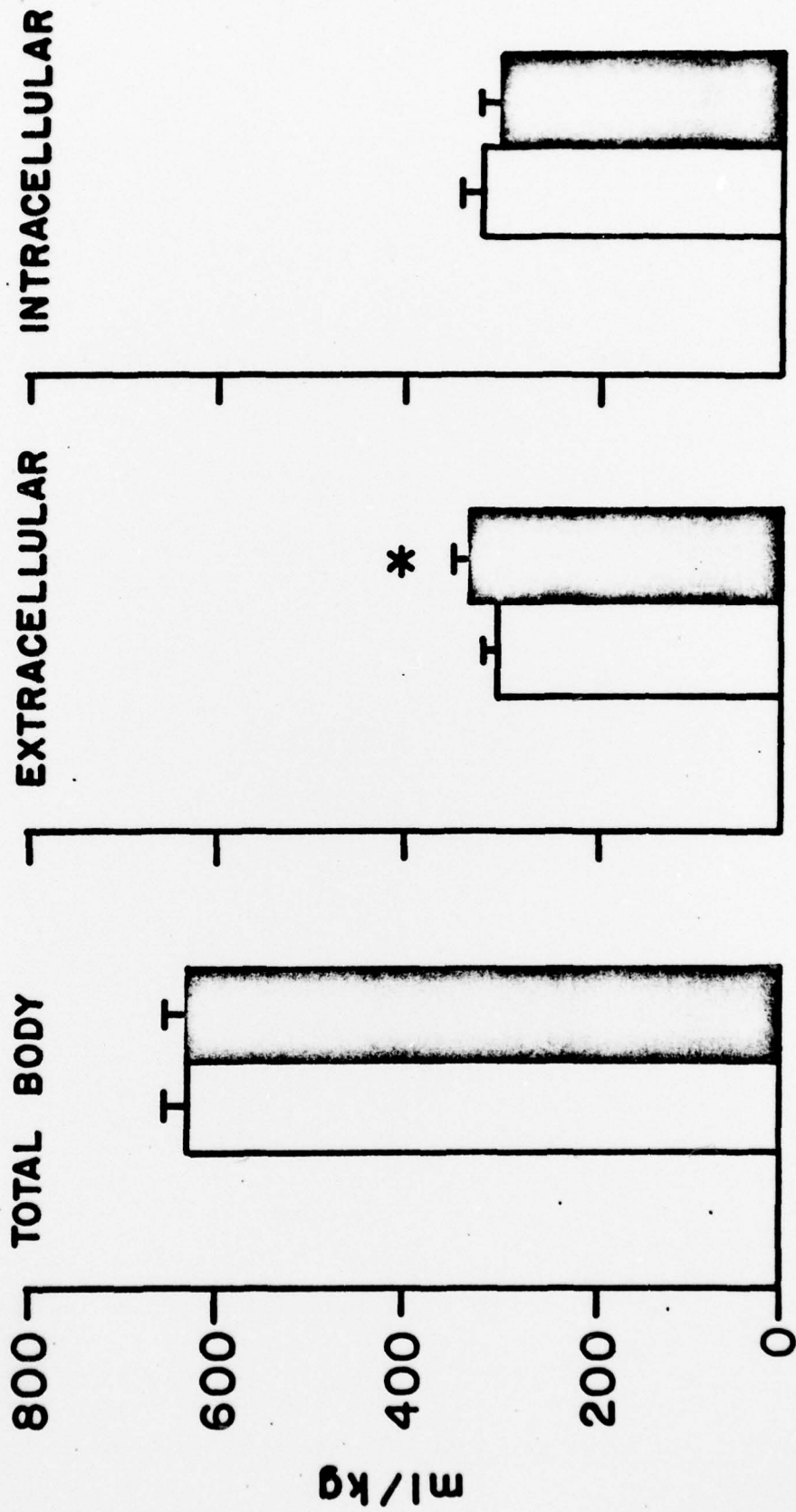
SC INOCULATION
↓

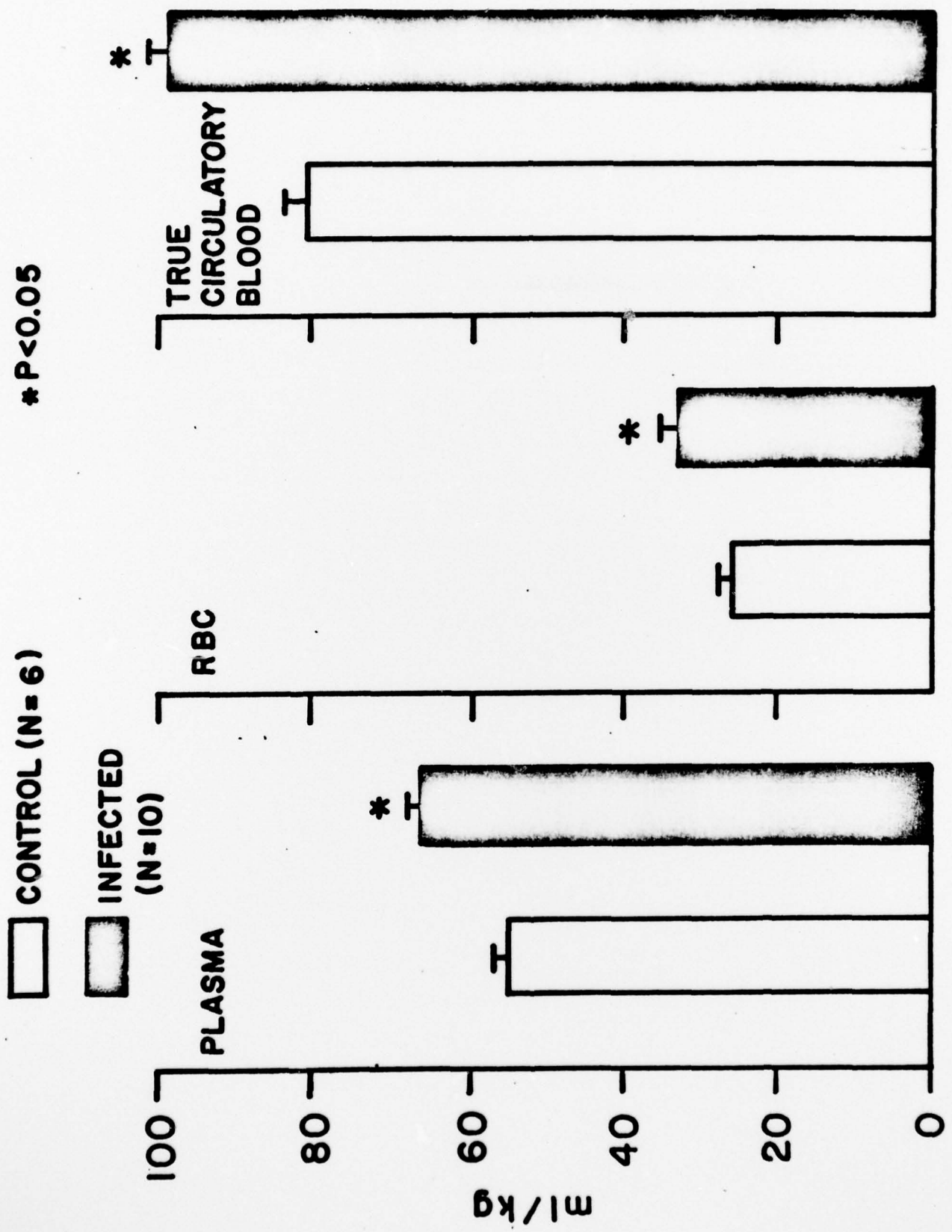


□ CONTROL (N=6)

■ INFECTED (N=10)

* P < 0.05

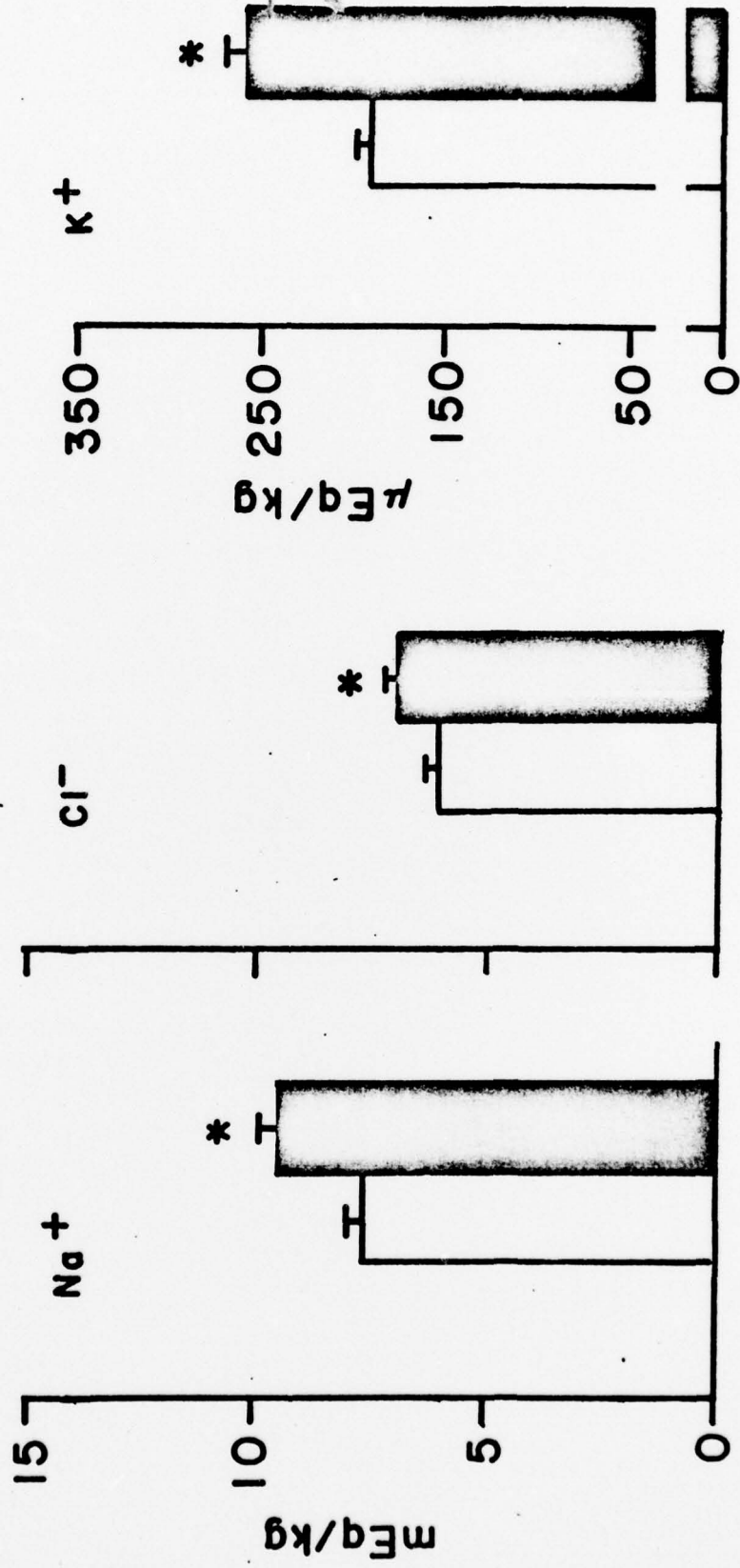




CONTROL N=6

INFECTED N=10

* P<0.05



REPORT DOCUMENTATION PAGE		READ INSTRUCTIONS BEFORE COMPLETING FORM	
1. REPORT NUMBER	2. GOVT ACCESSION NO.	3. RECIPIENT'S CATALOG NUMBER	
4. TITLE (and Subtitle) Alterations of Body Fluid Compartments and Distribution of Tissue Water and Electrolytes in Monkeys During Rocky Mountain Spotted Fever		5. TYPE OF REPORT & PERIOD COVERED Interim	
7. AUTHOR(s) C. T. Liu, D. E. Hilmas, M. J. Griffin, C. E. Pedersen, Jr., C. L. Hadick, Jr., and W. R. Beisel.		6. PERFORMING ORG. REPORT NUMBER	
9. PERFORMING ORGANIZATION NAME AND ADDRESS U.S. Army Medical Research Institute of Infectious Diseases SGRD-UIA-A Fort Detrick, Frederick, Maryland 21701		8. CONTRACT OR GRANT NUMBER(s)	
11. CONTROLLING OFFICE NAME AND ADDRESS		10. PROGRAM ELEMENT, PROJECT, TASK AREA & WORK UNIT NUMBERS 62776A 3M762776A841 00 030	
14. MONITORING AGENCY NAME & ADDRESS (if different from Controlling Office)		12. REPORT DATE 23 Sep 77	
		13. NUMBER OF PAGES 28	
		15. SECURITY CLASS. (of this report) UNCLASSIFIED	
16. DISTRIBUTION STATEMENT (of this Report) Approved for public release; distribution unlimited		15a. DECLASSIFICATION/DOWNGRADING SCHEDULE	
17. DISTRIBUTION STATEMENT (of the abstract entered in Block 20, if different from Report)		DDC APPROVED OCT 11 1977 REGISTERED C	
18. SUPPLEMENTARY NOTES Reprints bearing assigned AD number will be forwarded upon receipt. To be submitted for publication in the Journal of Infectious Diseases.			
19. KEY WORDS (Continue on reverse side if necessary and identify by block number) Body fluid compartments Tissue water Tissue electrolytes Brain Rhesus monkeys			
20. ABSTRACT (Continue on reverse side if necessary and identify by block number) Chair-restrained rhesus monkeys were inoculated subcutaneously with 10 ²⁻³ plaque forming units of virulent <i>Rickettsia rickettsii</i> . The latent period for fever and rickettsemia was found to be 3-4 days and death occurred within 6-8 days postinfection. Total circulatory electrolytes and fluid volumes including plasma, red blood cell, true circulatory blood, and extracellular fluid increased during Rocky Mountain spotted fever. The expansion of the extracellular and plasma volumes resembled the findings reported to occur during severe RMSF in- fections in man, guinea pigs and rabbits. Liver total water content (cont'd)			

DD FORM 1473

EDITION OF 1 NOV 65 IS OBSOLETE

405 039

UNCLASSIFIED

SECURITY CLASSIFICATION OF THIS PAGE (When Data Entered) mt

also increased. Intracellular K^+ , as well as total Na^+ and K^+ decreased in the diaphragm. Both the lung and medulla oblongata showed increased intracellular Na^+ and water with simultaneously decreased extracellular Na^+ and water. It is suggested that intracellular overhydration of the medulla oblongata may contribute to death as a result of depression of the cardiovascular and respiratory centers. Based on the findings in monkeys the intravenous infusion of fluids and electrolytes during clinical therapy of severe rickettsial infections should be considered as extremely dangerous.

UNCLASSIFIED