

AD-A072 747

ARMY INST OF DENTAL RESEARCH WASHINGTON D C  
THE MAXILLARY AMELOBLASTOMA: AN ANALYSIS OF TWENTY-FOUR CASES. (U)  
1978 P J TSAKNIS, J F NELSON

F/G 6/5


UNCLASSIFIED

NL

1 OF 1  
AD  
A072747



END  
DATE  
FILMED  
9-79  
DDC



MICROCOPY RESOLUTION TEST CHART  
 NATIONAL BUREAU OF STANDARDS-1963-A

# LEVEL

6  
P.S.

SECURITY CLASSIFICATION OF THIS PAGE (When Data Entered)

### REPORT DOCUMENTATION PAGE

READ INSTRUCTIONS  
BEFORE COMPLETING FORM

1. REPORT NUMBER		2. GOVT ACCESSION NO.	3. RECIPIENT'S CATALOG NUMBER
4. TITLE (and Subtitle) The Maxillary Ameloblastoma: An Analysis of Twenty-Four Cases. (Maxillary Ameloblastoma)		5. TYPE OF REPORT & PERIOD COVERED Manuscript for Publication June 1976 - Jan 1979	
7. AUTHOR(s) Peter J. Tsaknis and John F. Nelson		6. PERFORMING ORG. REPORT NUMBER	
9. PERFORMING ORGANIZATION NAME AND ADDRESS U. S. Army Institute of Dental Research Walter Reed Army Medical Center Washington, DC 20012		8. CONTRACT OR GRANT NUMBER(s)	
11. CONTROLLING OFFICE NAME AND ADDRESS U. S. Army Medical Research & Development Command HQDA-IS Fort Detrick, Maryland 21701		10. PROGRAM ELEMENT, PROJECT, TASK AREA & WORK UNIT NUMBERS	
14. MONITORING AGENCY NAME & ADDRESS (if different from Controlling Office)		12. REPORT DATE	
		13. NUMBER OF PAGES	
		15. SECURITY CLASS. (of this report)  UNCLASSIFIED	
		15a. DECLASSIFICATION/DOWNGRADING SCHEDULE	
16. DISTRIBUTION STATEMENT (of this Report) This document has been approved for public release and sale; its distribution is unlimited.			
17. DISTRIBUTION STATEMENT (of the abstract entered in Block 20, if different from Report)			
18. SUPPLEMENTARY NOTES None			
19. KEY WORDS (Continue on reverse side if necessary and identify by block number)			
20. ABSTRACT (Continue on reverse side if necessary and identify by block number) The maxillary ameloblastoma presents clinically as a potentially more dangerous lesion than its mandibular counterpart. The microscopic appearance of this locally aggressive neoplasm challenges the diagnostic acumen of the pathologist and its variable biologic behavior dictates a radical therapeutic approach by the surgeon. Therapy should consist of either surgical excision or hemimaxillectomy. The surgeon must carefully weigh the potential danger of the neoplasm against the deformity and disability caused by the surgical procedure.			

AD A 072747

DDC FILE COPY.

DDC  
RECEIVED  
AUG 14 1979  
REGISTRY  
C

9 Rept. for Jun 76-Jan 79

6 THE MAXILLARY AMELOBLASTOMA:  
AN ANALYSIS OF TWENTY-FOUR CASES.

12 30 p.

10 Peter J. Tsaknis, D.D.S., M.S., M.Ed.  
Division of Oral Biology  
John F. Nelson, D.D.S., M.Ed.  
Division of Oral Pathology

11 1978

U. S. Army Institute of Dental Research  
Walter Reed Army Medical Center  
Washington, D. C. 20012

038 670

slf

## SUMMARY

Twenty-four cases of maxillary ameloblastoma were reviewed from the files of the Dental and Oral Division of the Armed Forces Institute of Pathology and the U. S. Army Institute of Dental Research. Clinical findings demonstrate an average age of 45.6 years, a male/female ratio of 2.4:1, and an equal racial distribution between whites and blacks. Eighty-eight percent of the tumors occurred distal to the maxillary cuspid. A slowly enlarging mass was the primary clinical sign in over 90% of the cases. Recurrences were noted in eight of the sixteen cases on which follow-up information was received. The majority of the tumors demonstrated a mixed follicular histologic pattern. Therapy should consist of either surgical excision or hemimaxillectomy. The surgeon must carefully weigh the potential danger of the neoplasm against the deformity and disability caused by the surgical procedure.

## INTRODUCTION

The ameloblastoma was the first recognized tumor arising from the odontogenic apparatus. It is an uncommon tumor of the odontognathic regions occurring most often in the mandibular molar area, less often in the maxilla and rarely in the oral soft tissues. An extensive store of literature exists describing its epidemiology, highly variable histology, biological behavior, and treatment modalities.

Controversy exists concerning the precise cell of origin of the ameloblastoma. Transmission electron microscopy findings have offered

Section for	<input checked="" type="checkbox"/>	<input type="checkbox"/>	<input type="checkbox"/>
IS G4441			
J TAB			
announced			
stification			
tribution/			
availability Codes			
Avail and/or			
at special			
			<b>A</b>

little assistance in resolving this question. The dilemma has resulted in the genesis of over fifty different names in the literature, each one testifying to the descriptive accuracy of its logic. The latest appeal was made by Baden<sup>1</sup> for the term odontogenic epithelioma, which closely echoes Malassez<sup>1,2</sup> original adamantine epithelioma of almost 100 years ago.

The two most widely accepted terms for this tumor are adamantinoma and ameloblastoma. The former term predominates in Europe, and the latter in North America. Both terms, however, are misnomers since the enamel elaborating cells (ameloblasts) need not be present and enamel is never produced. The ameloblastoma is a characteristic epithelial tumor which may arise from (1) the epithelial lining of a dentigerous or follicular cyst (25-30% according to Bhaskar<sup>3</sup>); (2) the remnants of the dental lamina; (3) the enamel organ; (4) the basal layer of adjacent oral mucous membrane; or (5) heterotopic embryonic enamel organ epithelium in other locations of the body<sup>4</sup>; an example of which is the dreaded craniopharyngioma in the pituitary gland.

In 1937 Robinson<sup>5</sup> reviewed the literature and reported 295 cases of ameloblastoma, of which 247 (84%) were mandibular and 48 cases (16%) were maxillary. Included in his study was the only reported case of simultaneously occurring ameloblastomas in each jaw. Also discussed was one of the largest ameloblastomas ever reported, which weighed 1.5 kg and protruded inferiorly to the level of the second rib. Another massive tumor was reported by Schumtziger<sup>6</sup> in 1930 which equaled the size of the patient's head. Two of Robinson's cases had a duration

of over fifty years, testifying to the slow but relentless growth of this neoplasm.

The average age of diagnosis is within the fourth decade but reports exist of tumor occurrence in patients as young as two months,<sup>7</sup> and as old as Klinar and McMannis' case arising in an octogenarian.<sup>8</sup>

It has generally been accepted that there is no sex or race predilection. However, Kegel<sup>9</sup> found a black to white ratio of 11:1. Slavin and Cameron<sup>10</sup> also believed that some racial differences may exist between East Africans of Tanzania and Uganda, and Europeans.

In searching for etiological factors, Main<sup>11</sup> in 1969, used the polyoma virus (PV) to induce ameloblastomas in mice. Cahn and Tietze<sup>12</sup> felt that trauma and inflammation may be a precursor in tumor development. Of 157 jaw tumors reported by Chung *et al.*<sup>13</sup> 20 were ameloblastomas, only one of which involved the maxilla. Potdar<sup>14</sup> contributed 58 cases from Bombay, India; 51 from the mandible and 7 from the maxilla. The latter study demonstrated an interesting 3:1 male to female ratio.

Bernier<sup>15</sup> and Small and Waldron<sup>16</sup> confirmed earlier statistical data and further concluded that about 1% of all tumors and cysts found in and around the maxilla and mandible to be ameloblastomas. Bhaskar,<sup>17</sup> however, assigned the ameloblastoma a much higher (18.18%) occurrence rate among odontogenic tumors. In the 18 year interim from the publication of Robinson's statistics to Small and Waldron's, the ameloblastoma's apparent duration decreased dramatically from an average of

8.5 years to 5.8 years with 32% of the neoplasms having a duration of less than two years. The authors attributed this reduction to increased efforts in public education by the health professions as well as better diagnostic techniques in dentistry and medicine.<sup>16</sup>

Although the ameloblastoma is generally considered to be a painless, slow growing, and benign neoplasm it may cause extensive local destruction and even death by direct invasion into vital structures. On this basis it is often referred to as being locally malignant. Kyriasis<sup>18</sup> cited a maxillary ameloblastoma with wide-spread involvement of the base of the skull and extensive infiltration into the brain. Bailey<sup>19</sup> reported a mandibular tumor which progressed unimpeded through the sphenomandibular bone and into the cranial vault. Metastatic spread of ameloblastoma has been documented which weakens, but does not fully refute the argument that the apparent malignancy arose primarily as an aspiration metastasis into the lung. A case metastasizing to the lumbar vertebrae<sup>20</sup> and another case which metastasized to the cervical vertebrae<sup>21</sup> have been reported. Both of these cases and 13 others were reviewed and accepted as being truly metastatic by Ikemura, et al.<sup>22</sup> in 1971, who suggested that truly malignant ameloblastomas may be more common in Japan.

A significant feature of this tumor is its high rate of recurrence. Robinson<sup>5</sup> reported 199 recurrences of 295 ameloblastomas. Gardner<sup>23</sup> cited 15 instances of recurrence in 21 cases and commented that the cystic type of ameloblastoma recurred most commonly. Other authors have disagreed with this observation.<sup>24</sup>

Treatment for the ameloblastoma has included radiation, chemotherapy, electrocautery, conservative curettage, and radical block excision.<sup>25</sup> The use of radiation as a treatment modality is generally discouraged since the ameloblastoma is widely agreed to be radioresistant. However, some authors have reported successful treatment results with radiotherapy.<sup>26,27,28</sup> Smith<sup>29</sup> emphatically opposes both irradiation and conservative curettage. Becker and Pertl<sup>30</sup> noted 42% recurrences following radiotherapy and a 25% occurrence in irradiated patients of eventually fatal postradiation sarcoma. A 5% solution of sodium psylliate was successfully used to block the blood supply in an otherwise inoperable tumor by Schultz and Vazirani.<sup>31</sup> In 89 patients treated by radical surgery, less than 5% recurred, whereas, in another group treated with conservative curettage or simple enucleation, almost 60% recurred. Other workers also reported high recurrence rates with curettage.<sup>28,32</sup> Waldron<sup>33</sup> concluded that the smaller, well-localized tumor is best treated by block excision, with preservation of the continuity of the jaw.

#### MATERIALS AND METHODS

The computerized files of the Dental and Oral Division of the Armed Forces Institute of Pathology and the U. S. Army Institute of Dental Research were systematically searched for all cases coded as ameloblastoma of the maxillae. Synonymous terms were used to obtain additional cases. The material included cases from the military, Veterans Administration, and civilian sources. Only those tumors which met the histopathologic criteria of ameloblastoma were retrieved. Tumors of questionable diagnosis were not

used in this study.

Twenty-four cases of histologically verified maxillary ameloblastoma were obtained and follow-up information was received on a total of sixteen from various treatment centers. A questionnaire was used in each case to ascertain age, sex, race, anatomic site, treatment modality, and recurrence. Patient records were supplemented when available with radiographs, clinical photographs, and tissue specimens. The tissue was processed by standard paraffin embedded block technique and stained with hematoxylin and eosin.

Clinical Findings:

Age: The diagnosis age ranged from 5 to 75 years with a mean of 45.6 years for all patients. The age distribution for patients with recurrences ranged from 30 to 74 years with a mean of 54.4 years. No recurrences were noted in the third and seventh decades. Because of insufficient follow-up data, it was impossible to ascertain recurrence on eight patients.

Sex: There was a total of 17 males and 7 females among these patients, resulting in a male preponderance of 2.4:1.

Race: The race was unknown in five cases. In the remaining 19 cases whites and blacks were represented with about equal occurrence. Blacks had a recurrence rate of 67% as opposed to 42% for whites.

Anatomic Location: The ameloblastomas in this study were located predominantly in the posterior maxilla, with only two cases occurring anteriorly (Figure 1). The maxillary antrum was involved in 12 of the 24 patients. Six of eight (75%) of the neoplasms that recurred showed

sinus involvement. The two patients who died as a direct result of their tumor demonstrated sinus involvement. One of these metastasized bilaterally to the lungs and also invaded the pituitary gland. The other patient expired due to an aggressive expansile intracerebral neoplasm.

Signs and Symptoms: Localized enlargement ranks as the most common of the presenting signs and symptoms with 20 of 22 patients (91%) listing this as their chief complaint (Figure 2). Three recurrences (37.5%) presented as enlargements. Six patients (25%) displayed an ulcerating lesion in the oral cavity (Figure 3). Fifty percent of the group experiencing recurrence demonstrated intraoral or extraoral ulceration. In only one case was pain mentioned as a presenting clinical symptom and this involved a recurrence. Draining sinuses were reported in three cases and nasal obstruction was noted to occur in an equal number. Migrating teeth, ill-fitting dentures, slow-healing extraction sockets, and malocclusion occurred in seven patients. One recurrence which had invaded the orbit caused a loss of visual acuity. The two patients who died as the result of pituitary involvement experienced high fever, dizziness, edema, tinnitus, hearing loss, hypercalcemia, and subsequent progressive deep coma followed by death.

Duration: Maxillary ameloblastomas demonstrated a median duration of five months between the time the patient became aware of the growth and the time of the initial diagnosis. However, long-standing lesions of a year or more were reported in seven of eighteen cases (39%). Four of eight recurrences were diagnosed within a year following initial treatment.

Radiographic Features: Since the ameloblastoma almost never produces a mineralized component, the lesions are osteolytic.<sup>34</sup> Generally, the maxillary tumors displayed uniform unilocular or multilocular, soap-bubble-like appearance. Figure 4 demonstrates these features. Several lesions revealed destruction of the maxillary antral walls as well as cloudiness and a thickening of the lining membrane. Similar characteristics were attributed to both primary and recurrent neoplasms. No specific features were evident which distinctly set the maxillary ameloblastoma radiographically apart from other locally aggressive disease processes of the jaws.

Macroscopic and Microscopic Features: The gross appearance of the ameloblastoma varied from solid to cystic (Figure 5). The larger tumors of greater duration tended to be of the latter type. Eight (33%) of the primary lesions were described as being mixed, whereas three (37.5%) of the recurrences were entirely of the cystic type. A soft, gelatinous material and fluid was contained within some cystic spaces while others were described as being empty or hollow.

Size varied, but the largest tumors were those infringing upon the maxillary antrum. The range of tumor size based on available surgical specimen measurements was 0.5 cm to 16 cm in the greatest dimension, with an average of 4.2 cm. Worthy of note was the fact that recurrent tumors represented both the smallest and largest lesions.

Microscopically, the tumors were classified according to the five generally accepted categories including the acanthomatous, plexiform, follicular, granular cell, and basal cell types. Prominent squamous

metaplasia of the stellate reticulum-like cells within the epithelial follicles differentiated the acanthomatous category (Figure 6). In this series no tumor differentiated to the point of producing calcifications.

Plexiform ameloblastomas demonstrated tumor epithelium arranged in irregular masses or as a network of strands. These strands were bounded by a layer of tall cuboidal or columnar cells and included tissue resembling the stellate reticulum of the dental lamina (Figure 7).

The follicular variant consisted of tumor epithelium in the form of more or less discrete follicles surrounded by a loose fibrous connective tissue stroma. The intrafollicular areas resembling stellate reticulum often demonstrated cystic breakdown.

Histopathologic material was available for 14 of the 24 tumors and four of the eight recurrences. Four primary tumors were plexiform, two were follicular, six had mixed features of both and two were acanthomatous. The recurrences consisted of one plexiform, two mixed and one acanthomatous type. No examples of the granular cell or basal cell type were seen in this series. Two tumors were initially misdiagnosed as carcinomas.

#### Treatment:

Most tumors were surgically managed. The modalities included curettage, excision, and partial maxillectomy. Radiation was used in conjunction with excision in one recurrent case, and chemotherapy plus hemimaxillectomy in another.

Table 1 indicates the various surgical procedures and the number of patients treated by each method.

Only two patients initially treated by curettage resulted in a full cure. One is still free of tumor eleven years after the operation and the other died of unrelated causes without evidence of recurrence four years postoperatively. The remaining five cases undergoing curettage resulted in recurrences within four years following treatment. The earliest recurrence was noted five months after surgery.

One recurrence was treated by another curettage, after which the patient refused further treatment. Subsequent diagnosis at autopsy nine years later was an ameloblastoma which was fixed to the undersurface of the tentorium and extended extradurally into the middle cranial fossae.

Of the twelve patients undergoing surgical excision, three had recurrences within five years. The remaining nine were symptom-free for seven to thirty-four years.

Excision was used in the treatment of six recurrences. Four patients are well and living without further recurrence, up to twenty years after treatment. One patient died of unrelated causes but was free of recurrent ameloblastoma. The remaining patient died as the result of local recurrence, bilateral pulmonary metastasis and destruction of the pituitary gland by tumor.

Hemimaxillectomy proved effective as initial treatment for one primary lesion and one recurrence. Both patients were living without recurrence six and eight years respectively.

#### DISCUSSION

The ameloblastoma comprises approximately one-fifth of all neoplasms arising from the embryonic odontogenic apparatus and about 1%

of all jaw tumors.<sup>3,4,8</sup> The mandibular ameloblastoma accounts for 80% of these tumors and has been discussed extensively in the literature.<sup>14,15,23</sup> Maxillary ameloblastomas are rare and much less extensively reported, resulting in a paucity of information available for study.

The clinical findings of this study are at some variance with previous reports concerning age and sex.<sup>5,10,16</sup> The latter can be explained by the biased sample of male patients serviced by the Armed Forces Institute of Pathology and the U. S. Army Institute of Dental Research. The mean patient age in this series, however, was 45.6 years. This represents an age differential of more than six to eleven years compared to other investigations.<sup>5,16</sup> The findings in this study, therefore, indicate that the maxillary ameloblastoma may arise later in life.

Although only occasionally reported in children, three cases (13%) in this study were in patients with ages of five to twelve years. Earlier reports indicated a 4% occurrence rate in children 0-9 years of age.<sup>7</sup>

The anatomic location within the maxilla indicates a propensity for maxillary sinus involvement. This is especially true when the lesion arises posterior to the canine area. Apparently the lack of thick, confining cortical plates as seen in the mandible allow for a more rapid dissemination into other parts of the skull. The more abundant blood supply of the maxilla may aid in local hematogenous spread of the neoplasm.

The clinical features of slow enlargement when coupled with lack of pain and a unilocular to multilocular radiolucency should alert the diagnostician to the possibility of ameloblastoma.

Previous investigators have shown that the ameloblastoma manifests diverse gross and histologic patterns.<sup>5,16,24</sup> Electronmicroscopic, histochemical, and tissue culture studies have failed to provide definitive proof that the peripheral columnar cells are really ameloblasts.<sup>11,35,36</sup> However, certain essential characteristics remain common to all histologic types. These include palisading and hyperchromatism with polarization of the basal cell nuclei of the epithelium. Both features were apparent in all lesions in this series. The occurrence of a mixed plexiform and follicular pattern in many of the ameloblastomas suggested a potential for the epithelium to undergo architectural transformation.

Etiologically, the site of ameloblastoma links it to the dental lamina. The morphologic similarity between the two indicate a causal relationship. The acanthomatous, plexiform, and follicular arrangements seen in this study could reflect an embryonic cellular spectrum with junctional tendencies. This may mimic the surface epithelium from which the lamina derives, the lamina itself, or the dental organ which its terminal cells are destined to produce.

The aggressive nature of ameloblastoma can be related to the similarity of behavioral characteristics between it and its parent dental lamina. Both have the inherent ability to invade adjacent connective tissue. The multiple finger-like columns of proliferating cells of the dental lamina are highly reminiscent of the peripheral invasive expansion seen in association with ameloblastomatous growth.

The findings of this study indicate no difference in biologic

behavior or predictability among the various histopathologic varieties. The issue is further clouded by the fact that the majority of recurrent tumors were mixed follicular and plexiform types. No granular or basal cell types were found within the maxilla.

One case in this study involved bilateral metastasis to the lungs. This feature has been cited as not representing a true metastasis since the tumor detritus allegedly reached the lung via aspiration during surgical removal. No other locally aggressive tumor such as the calcifying epithelial odontogenic tumor or the odontogenic myxoma has ever been reported as being seeded in the pulmonary areas. This certainly suggests an unusual ability of the ameloblastoma to find a "fertile soil" in lung tissue.

The one finding of an intraluminal ameloblastoma lends further support to the concept of the dentigerous cyst being a potential precursor of neoplastic transformation.<sup>3,4</sup>

Several factors brought out in this study reinforce the absolute necessity for long-term follow up of all diagnosed ameloblastomas. The extremely high recurrence rate (50%) and two subsequent deaths testify to the insidious unrelenting nature of this tumor.

Opponents of curettage as a treatment modality are supported by the failure of this procedure to provide a cure in six of eight (75%) cases. Other authors have indicated an even higher recurrence rate following curettement.<sup>29</sup> It has been used in many instances because of the difficulty in performing surgery in the maxilla as compared to

the more readily accessible mandible.

Excision appears to be the most desired method of successfully eradicating the tumor, short of extensive osseous removal as encompassed in a partial maxillectomy. Present results show 14 of 18 patients (78%) obtaining acceptable results with excision. Hemimaxillectomy, while apparently successful in two cases, presents serious problems relating to disfigurement and rehabilitation.

The use of radiation in one case and methotrexate infusion in another failed to bring about tumor elimination even when coupled with surgery. These findings support the fact that the ameloblastoma does not respond to these methods of therapy.<sup>25,27,28,30</sup> Recent studies with well-documented follow-ups by Sehdev, et al.<sup>38</sup> further emphasize the need for complete surgical resection, especially when the ameloblastoma occurs in the maxilla. An excellent report by Mehlich, et al.<sup>39</sup> states that depending upon the tumor size, electrocautery coupled with excision or resection offers the best results. Huffman and Thatcher,<sup>40</sup> however, argue for conservative curettage plus electrocautery, providing the tumor is small and the patients are reliably available for recall. In their four cases Crawley and Levin also support conservative treatment and proper follow-up as acceptable methods of initial treatment.<sup>41</sup>

Selection of the most effective means of treating the maxillary ameloblastoma requires the weighing of many factors by the surgeon. These include the patient's general health, specific anatomical location, extent of the lesion, and esthetic considerations.

MILITARY DISCLAIMER

Commercial materials and equipment are identified in this report to specify the investigative procedures. Such identification does not imply recommendation or endorsement or that the materials and equipment are necessarily the best available for the purpose. Furthermore, the opinions expressed herein are those of the authors and are not to be construed as those of the U. S. Army Medical Department.

## REPRINT REQUESTS TO:

Peter J. Tsaknis, LTC, DC  
Division of Oral Biology  
U. S. Army Institute of Dental Research  
Walter Reed Army Medical Center  
Washington, D. C. 20012

TABLE 1.

<u>Surgical Treatment of Primary Tumor</u>	<u>Number of Patients</u>	<u>Number of Recurrences</u>	<u>Died of Tumor</u>
Curettage	7	5	0
Excision	12	3	0
Hemimaxillectomy	1	0	0
Unknown	4	-	-
 <u>Surgical Treatment of Recurrent Tumor</u>			
Curettage	1	1	1*
Excision	6	1	1†
Hemimaxillectomy	1	0	0

\* Combined with radiation.

† Combined with methotrexate infusion.

#### REFERENCES

1. Baden, F.: Terminology of the Ameloblastoma; History and Current Usage. J. Oral Surg., 23:40-49, 1965.
2. Mallassez, L.: Sur le Rol des Debris Epitheliaux Paradentaires. Arch. Physiol. Norm. Pathol. 5:379-449, 1885.
3. Bhaskar, S.N.: Synopsis of Oral Pathology, 4th Ed., St. Louis, C.V. Mosby Co., p. 239, 1973.
4. Shafer, W.G., Hine, M.K. and Levy, B.M.: Oral Pathology, 3rd Ed., Philadelphia, W.B. Saunders Co., p. 252, 1974.
5. Robinson, H.B.G.: Ameloblastoma, Survey of 379 Cases from the Literature. Arch. Path. 23:831-843, 1937.
6. Schmutziger, P.: Uber Zentrale Unterkiefertumoren Odontogenen Ursprungs. Schweizerische Monatsschrift fur Zahnheilkunde 40:309-370, 1930.
7. Young, R.H.: Ameloblastomas in Children. Oral Surg. 15:1155-1162.
8. Klinar, K.L. and McManis, J.C.: Soft Tissue Ameloblastoma. Oral Surg. 28:266-272, 1969.
9. Kegel, R.: Adamantine Epithelioma. Arch. Surg. 25:498-528, 1932.
10. Slavin, G. and Cameron, H.: Ameloblastoma in Africans from Tanzania and Uganda. A Report of 56 Cases. Brit. J. Cancer 23:31-38, 1969.
11. Main, J.H.: Transformation of Odontogenic Epithelium by Polyoma Virus *In Vitro*. J. Dent. Res. (Suppl) 48:738-744, 1969.
12. Cahn, R.L. and Tiecke, R.W.: Odontogenic Tumors in Oral Pathology. Tiecke, R.W., Ed. New York, McGraw-Hill Book Co., 1965.
13. Chung, D.H., Kinnman, J.E., and Lee, B.C.: Tumors of Jaws in Korea. Oral Surg. 27:716-723, 1969.

14. Potdar, G.G.: Ameloblastoma of the Jaw in Bombay, India. Oral Surg. 28:297-303, 1969.
15. Bernier, J.L.: Ameloblastoma: Report of 34 Cases. J. Dent. Res. 21:529, 1942.
16. Small, I.A. and Waldron, C.A.: Ameloblastoma of Jaws. Oral Surg. 8:281-297, 1955.
17. Bhaskar, S.N.: Oral Pathology in the Dental Office: Survey of 20,575 Biopsy Specimens. J. Am. Dent. Assoc. 76:761, 1968.
18. Kyriazis, A.P., Karkazis, G.C., and Kyriazis, A.A.: Maxillary Ameloblastoma with Intracerebral Extension. Report of A Case. J. Oral Surg. 32:582-587, 1971.
19. Bailey, I.C.: Case Report. Brit. J. Cancer 55:455-457, 1966.
20. Sugimura, M., Yamauchi, T. and Yashikawa, K.: Malignant Ameloblastoma with Metastasis to the Lumbar Vertebrae. J. Oral Surg. 27:350-357, 1969.
21. Hoke, H.F. and Harrelson, A.B.: Granular Cell Ameloblastoma with Metastasis to the Cervical Vertebrae. Cancer, 20:991-999, 1967.
22. Ikemura, K., Tashior, H. and Hiroshi, F.: Metastatic Ameloblastoma of Mandible. Cancer 29:930-940, 1972.
23. Gardner, A.F., Apter, M.B. and Axelrod, J.H.: A Study of 21 Instances of Ameloblastoma. A Tumor of Odontogenic Origin. J. Oral Surg. 21:230-237, 1963.
24. Richenbach, E. and Schneider, G.: Betrachtungen zur Therapie der Adamantinoma. Oest. Z. Stomat. 57:3-10, 1960.
25. Brandenburg, J.H., Finch, W.W., Kirkham, W.R.: Malignant Ameloblastoma of the Maxilla. Trans. Am. Acad. Ophthalmol. Otolaryngol. 82:576-578, 1976.

26. Baclesse, F.: Les Ameloblastomes des Maxillaires. Rev. Belge. Med. Dent. 47-54, 1964.
27. Hair, J.A.: Radiosensitive Adamantinoma. Brit. Med. J. 105-106, 1963.
28. Hertz, J.: Adamantinoma: Studies in Histopathology and Prognosis. Acta Med. Scand. (Suppl) 142:529-556, 1952.
29. Smith, J.F.: Ameloblastoma, Report of 30 Cases. Oral Surg. 13:253-257, 1960.
30. Becker, R. and Pertl, A.: Zur Therapie des Ameloblastoma. Deutsch Zahn Mund Kieferheilk 49:423-436, 1967.
31. Schultz, L.W. and Vazirani, S.J.: Use of Sclerosing Solution in the Treatment of Ameloblastoma. Oral Surg. 13:150-156, 1960.
32. Hickey, M.J., Ballantyne, L.W., MacDonald, J.A., and Rankow, R.M.: Surgical Treatment of Adamantinoma, Further Report. Am. J. Surg. 92:852-856, 1956.
33. Waldron, C.A.: Ameloblastoma in Perspective. J. Oral Surg. 24:331-333, 1966.
34. Pindborg, J.J. and Weinmann, J.P.: Squamous Cell Metaplasia Within Ameloblastomas. Acta Pathol. Microbiol. Scand. (A) 44:247-252, 1958.
35. Moe, H., Clausen, F., and Philipsen, H.P.: The Ultrastructure of the Simple Ameloblastoma. Acta Pathol. Microbiol. Scand. (A) 52:140-154, 1961.
36. Masahiko, Mori and Okamoto, Y.: Enzymatic Histochemical Demonstration of Ameloblastoma. Oral Surg. 17:235-250, 1964.
37. Hartman, K.: Granular Cell Ameloblastoma. Oral Surg. 38:241-253, 1974.
38. Sehdev, M.K., Huvos, A.G., Strong, E.W., Gerald, F.P., and Willis, G.W.: Ameloblastoma of the Maxilla and Mandible. Cancer 33:324-333, 1974.
39. Mehlisch, D.R., Dahlin, D.C., Mason, J.K.: Ameloblastoma: A Clinico-pathologic Report. J. Oral Surg. 30:9-22, 1972.

40. Huffman, G.G. and Thatcher, J.W.: Ameloblastoma - The Conservative Surgical Approach to Treatment: Report of Four Cases. J. Oral Surg. 32:850-854, 1974.
41. Crawley, W.A. and Levin, S.L.: Treatment of the Ameloblastoma - A Controversy. Cancer 42:357-363, 1978.

### LEGENDS

- FIGURE 1. Anatomical location of 23 maxillary ameloblastomas.
- FIGURE 2. Frontal view of a patient with a maxillary tumescence. Although previously treated by excision at 5 years of age, lesion recurred with bilateral pulmonary metastasis, pituitary invasion and subsequent death. Note surgical scar and hypertropia.
- FIGURE 3. Intraoral enlargement of anterior maxilla with surface ulceration in 62 year old male. No recurrence following treatment by hemimaxillectomy.
- FIGURE 4. Multilocular soap-bubble radiolucency of lesion seen in Figure 3 with involvement of maxillary sinus.
- FIGURE 5. Surgical specimens of maxillary solid and cystic ameloblastomas. Cystic spaces are filled with a transparent fluid.
- FIGURE 6. Microscopically prominent squamous metaplasia (arrows) demonstrated within the stellate reticulum of an acanthomatous ameloblastoma noted in the upper surgical specimen of Figure 5. (Magnification 100X)
- FIGURE 7. Photomicrograph of a plexiform ameloblastoma from the lower surgical specimen in Figure 5 showing a network of strands and cords lined by ameloblastic tumor cells. (Magnification 100X)

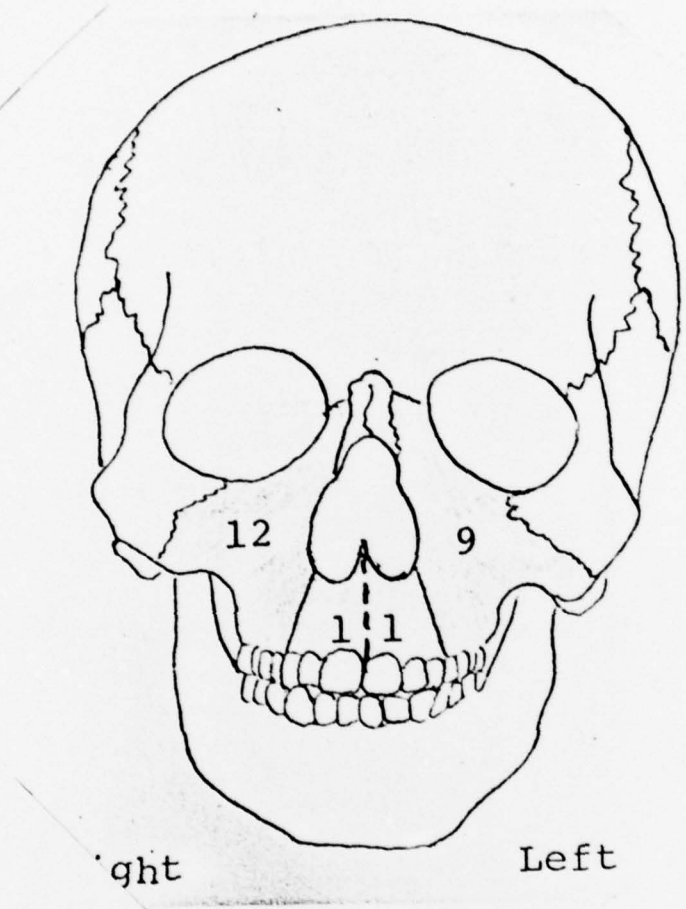


FIGURE 1 Anatomical location of 23 maxillary ameloblastomas

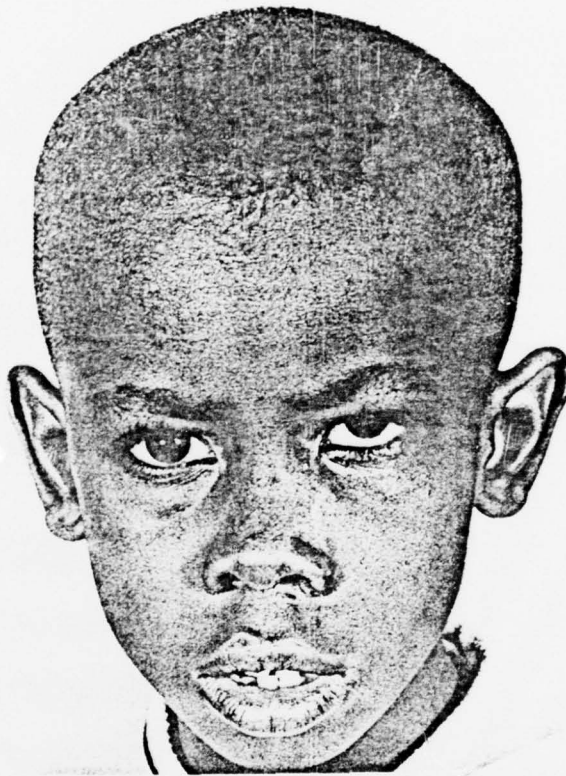


FIGURE 2 Frontal view of a patient with a maxillary tumescence. Although previously treated by excision at 5 years of age, lesion recurred with bilateral pulmonary metastasis, pituitary invasion and subsequent death. Note surgical scar and hypertropia.

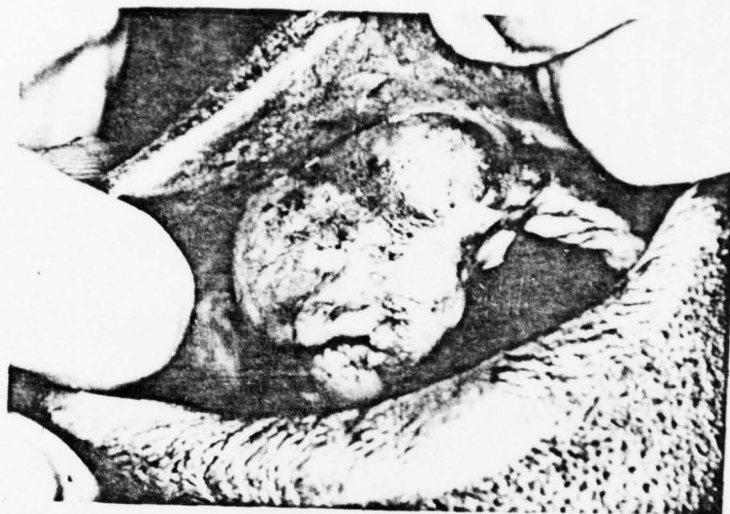

FIGURE 3 Intraoral enlargement of anterior maxilla with surface ulceration in 62 year old male. No recurrence following treatment by hemimaxillectomy.

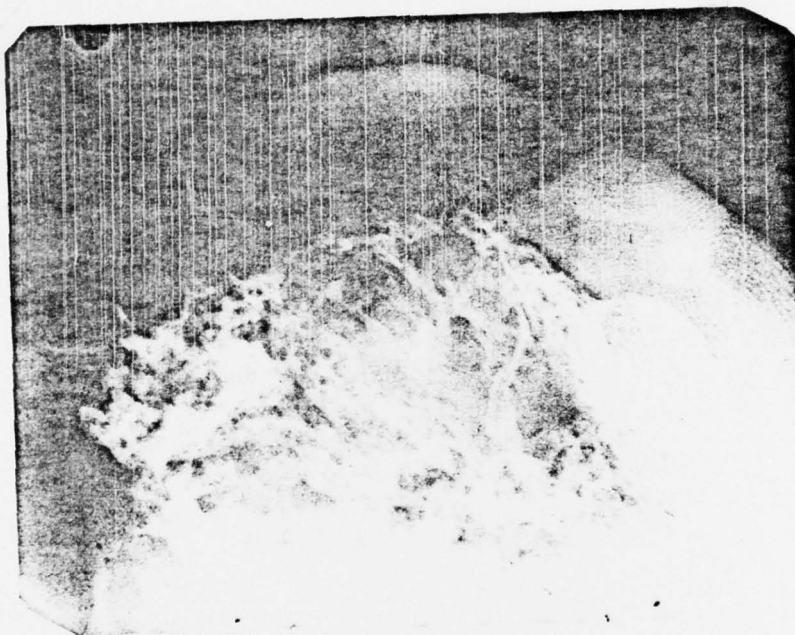
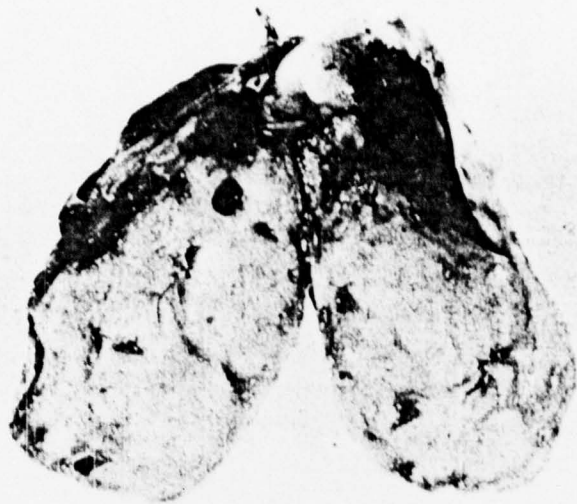
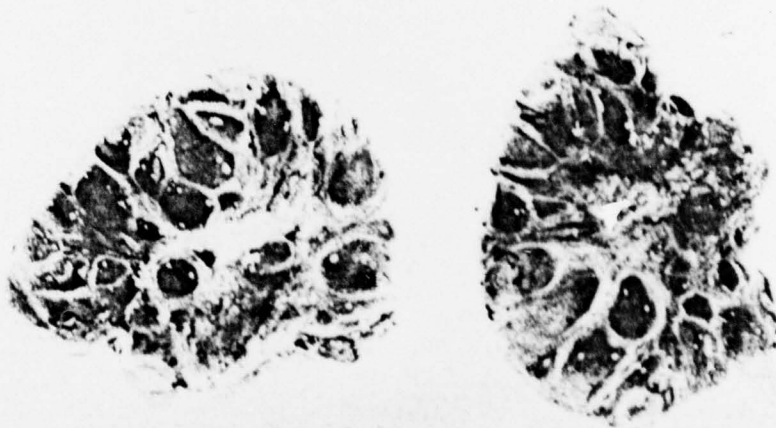


FIGURE 4 Multilocular soap-bubble radiolucency of lesion seen in Figure 3 with involvement of maxillary sinus.



OPS  
248-61



S - 1365 - 61  
USAF HOSP LAFB

5 CM

Figure 5 Surgical specimens of maxillary solid and cystic ameloblastomas. Cystic spaces are filled with a transparent fluid.

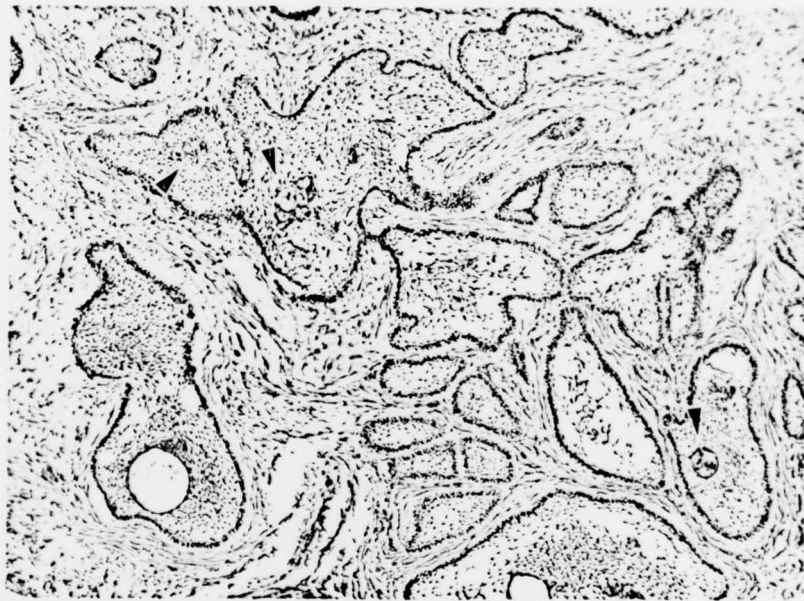

FIGURE 6 Microscopically prominent squamous metaplasia (arrows) demonstrated within the stellate reticulum of an acanthomatous ameloblastoma noted in the upper surgical specimen of Figure 5. (Magnification 100X)

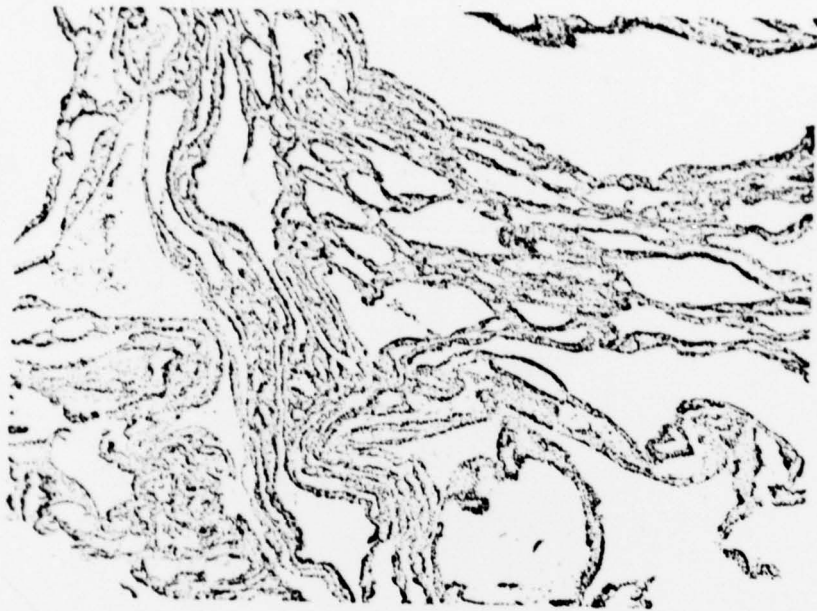


FIGURE 7 Photomicrograph of a plexiform ameloblastoma from the lower surgical specimen in Figure 5 showing a network of strands and cords lined by ameloblastic tumor cells. (Magnification 100X)