

AD-A078 608

ARMY INST OF DENTAL RESEARCH WASHINGTON D C
MOLLUSCUM CONTAGIOSUM OF THE LOWER LIP: REPORT OF A CASE, (U)
DEC 79 J F NELSON , P J TSAKNIS

F/G 6/5


UNCLASSIFIED

| OF |
AD
A078608



NI

END
DATE
FILMED
- 80
DDC



MICROCOPY RESOLUTION TEST CHART
NATIONAL BUREAU OF STANDARDS-1963-A

UNCLASSIFIED

SECURITY CLASSIFICATION OF THIS PAGE (When Data Entered)

12

REPORT DOCUMENTATION PAGE

READ INSTRUCTIONS BEFORE COMPLETING FORM

1. REPORT NUMBER	2. GOVT ACCESSION NO.	3. RECIPIENT'S CATALOG NUMBER
4. TITLE (and Subtitle) Molluscum Contagiosum of the Lower Lip: Report of a Case		5. TYPE OF REPORT & PERIOD COVERED Manuscript
7. AUTHOR(s) John F. Nelson COL DC and Peter J. Tsaknis COL DC		8. CONTRACT OR GRANT NUMBER(s) 12 11
9. PERFORMING ORGANIZATION NAME AND ADDRESS U.S. Army Institute of Dental Research Washington, D.C. 20012		10. PROGRAM ELEMENT, PROJECT, TASK AREA & WORK UNIT NUMBERS OH-6030 00-004
11. CONTROLLING OFFICE NAME AND ADDRESS U.S. Medical Research and Development Command Attn: (SGRD RP) Fort Detrick, Md 21701		12. REPORT DATE 6 December 1979
14. MONITORING AGENCY NAME & ADDRESS (if different from Controlling Office)		13. NUMBER OF PAGES
LEVEL		15. SECURITY CLASS. (of this report) Unclassified
		15a. DECLASSIFICATION/DOWNGRADING SCHEDULE
16. DISTRIBUTION STATEMENT (of this Report) This document has been approved for public release and sale; its distribution is unlimited.		
17. DISTRIBUTION STATEMENT (of the abstract entered in Block 20, if different from Report)		
18. SUPPLEMENTARY NOTES To be published in the Journal of Oral Medicine		
19. KEY WORDS (Continue on reverse side if necessary and identify by block number) Molluscum contagiosum, viral bodies, lower lip		
20. ABSTRACT (Continue on reverse side if necessary and identify by block number) A rare case of molluscum contagiosum of the lower lip is presented. Its clinical and microscopic features are discussed and a differential diagnosis is suggested. K		

DDC
RECEIVED
DEC 26 1979
E

79 12 18 150

ADA 078608

DDC FILE COPY

038 670

JOB

Molluscum Contagiosum of the Lower Lip: Report of a Case

J.F. Nelson, D.D.S., M.Ed.*, and
P.J. Tsaknis D.D.S., M.S., M.Ed.**

INTRODUCTION

Molluscum contagiosum is a viral disease of the skin seen primarily in children.¹ The causative organism is a pox virus of the same grouping as smallpox, cowpox and others.²

The disease was first described by Bateman in 1814 although a clear account of it appeared nearly 20 years prior to that time in a notebook belonging to Edward Jenner. Interestingly, these original handwritten pages are still on display in the library of the Royal College of Physicians in England.³

The viral nature of the disease was established in 1905 although the consistent failure to replicate in tissue culture has somewhat clouded the issue.⁴ It has, however, been characterized by light and electron microscopy.⁵

The lesions of molluscum contagiosum are commonly seen in the anogenital area and in adults a venereal transmission is considered highly likely.⁶⁻⁷ Lesions have also been reported on the trunk, thighs, arms, neck, face and scalp.^{6,8} Occurrence in the eyelid and periocular areas is quite common and may in some instances result in ophthalmological complications.⁹ Eruptions have been reported following systemic administration of corticosteroids and antimetabolites.¹⁰

Typical lesions present as raised, pearly papules with an umbilicated

* Chief Division of Pathology, U.S. Army Institute of Dental Research,
Washington, D.C. 20012

** Chief Department of Biophysics, U.S. Army Institute of Dental Research,
Washington, D.C. 20012

central area. Bidigital manipulation will usually result in the extrusion of a semisolid, caseous material which consists of degenerated keratin and epithelial cells containing the viral inclusion bodies known as Lipschutz granules.⁶

Treatment usually consists of curretment or excision. Cryotherapy, trichloroacetic acid and podophyllin administration have also been successfully utilized.¹¹

The present case is considered to be of interest due to its occurrence on the lower lip, the differential diagnostic problem and the paucity of information in the dental literature relating to molluscum contagiosum.

CASE REPORT:

A 25-year-old caucasian male presented for a dental examination and evaluation of a lesion located on the junction of the vermillion surface and skin in the midline of the lower lip. The lesion was raised, firm, round, normal to pearly in color and measured approximately .7 cm. across its surface (Fig 1). The patient related that it had been present for approximately two months and was presently of a stable size. His past medical history was within normal limits and no similar lesions were noted on the face or elsewhere. He denied the possibility of orogenital sexual transmission and self-inoculation was ruled out on the basis of a negative history. An excisional biopsy was performed in November of 1978. Histologic examination revealed a lesion covered on its superior surface by stratified squamous epithelium. Extending from the external surface into the underlying connective tissue were epithelial lobules containing in their central areas tightly packed squamous cells containing large, intracytoplasmic inclusion bodies which had largely displaced the cell nuclei (Fig 2). The outermost cells of the lobules were in the process of being exfoliated.

Deep to the lobules the epithelial cells did not display viral inclusions. Staining characteristics of the viral inclusion bodies varied from eosinophilia in the deeper epithelium to basophilia in the superficial cells. Little inflammation was noted. One large pseudocyst was present which was filled with exfoliated cellular and viral debris (Fig 3): Diagnosis: molluscum contagiosum of the lip.

Electron microscopic evaluation revealed in detail the honeycomb pattern of the molluscum bodies. These inclusion bodies most likely represent a degenerative keratinaceous product of the stratified squamous epithelium induced by the presence of the Poxviridae virus.

Further support for this concept was noted by the appearance of a keratin-like layering within the empty lacunae of several molluscum bodies. (Fig 4).

DISCUSSION:

Molluscum contagiosum is a viral disease of the skin felt to be contagious in nature and occurring most commonly in the anogenital area of children. This case is of interest due to the rare occurrence on the lip in an adult with no other lesions or history of contact.

The DNA which contains the virus of molluscum contagiosum resides within the rounded hyaline masses or Henderson-Paterson bodies found predominately within cells of the stratum spinosum segment of the epithelium. These molluscum bodies measure approximately 35 microns in diameter. The tenant virus itself has dimensions of approximately 300 X 200mm. Its morphology strongly resembles the "brick-shaped" capsule of the variola, vaccinia, and cowpox viruses of the family Poxviridae.

A clinical differential diagnosis might include such entities as fibroma, neuroma, nevus, minor salivary gland tumor, mucocele, xanthoma and many others including the basal cell carcinoma and keratoacanthoma. The diagnosis of molluscum contagiosum was a distinct surprise. To our knowledge only one

other such lesion of the perioral or intraoral area has been reported in the dental literature.¹³

The patient did not suffer recurrence following excision and his experience can presumably be considered an isolated incident.

SUMMARY

A rare case of molluscum contagiosum of the lower lip is presented. Its clinical and microscopic features are discussed and a differential diagnosis is suggested.

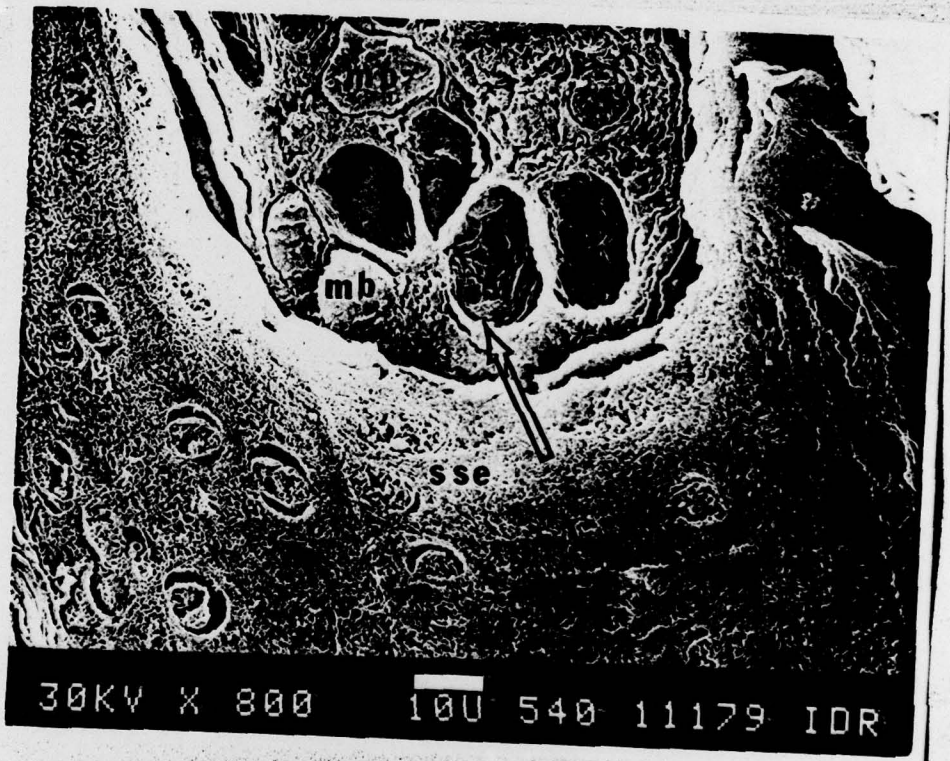
Accession For	
NTIS GRA&I	<input checked="" type="checkbox"/>
DDC TAB	<input type="checkbox"/>
Unannounced Justification	<input type="checkbox"/>
By _____	
Distribution/	
Availability Codes	
Dist	Avail and/or special
A	

Captions

- Figure 1. Lesion near midline of lower lip at junction of the vermillion surface and skin of chin.
- Figure 2. Photomicrograph showing epithelial lobules containing intracytoplasmic inclusion bodies and cellular segments in process of exfoliation. (Hematoxylin and eosin stain. Magnification X 300)
- Figure 3. Photomicrograph showing pseudocyst with intraluminal cellular and viral debris. Note viral bodies forming in lower epidermis. (Hematoxylin and eosin stain. Magnification X 300)
- Figure 4. S.E.M. photomicrograph demonstrates the honeycomb arrangement (arrow) of the molluscum bodies (mb) formed by the underlying stratified squamous epithelium (sse). Magnification X 800.

Bibliography

1. Solomon, L.M. and Telner, P.: Eruptive Molluscum Contagiosum in Atopic Dermatitis, *Canad. Med. Ass. J.* 95:978-79, November, 1966.
2. Lutzner, M.A.: Molluscum Contagiosum, Verruca and Zoster Viruses, *Arch. Derm.*: 87:436-444, April, 1963.
3. Woods, B.: Edward Jenner and Molluscum Contagiosum, *Br. J. of Derm.* 96:91-93, 1977.
4. Goldschmidt, H. and Kligman, A.M.: Experimental Inoculation of Humans with Ectodermotropic Viruses, *J. of Invest. Derm.* 31:174-182, 1958.
5. Parr, R.P., Burnett, J.W. and Garon, C.F.: Structural Characterization of the Molluscum Contagiosum Virus Genome, *Virology*, 81:247-256, 1977.
6. Cobbold, R.J.C. and MacDonald A.: Molluscum Contagiosum as a Sexually Transmitted Disease, *The Practitioner*, 204:416-419, March, 1970.
7. Lynch, P.J. and Minkin, W.: Molluscum Contagiosum of the Adult, *Arch. Derm.* 98:141-143, Aug. 1968.
8. Henao, M. and Freeman, R.G.: Inflammatory Molluscum Contagiosum, *Arch. Derm.* 90:479-482, Nov., 1964.
9. Curtin, B.J. and Theodore, F.H.: Ocular Molluscum Contagiosum, *Am. J. Ophthom.* 39:302-307, 1955.
10. Rosenberg, E.W. and Yusk, J.W.: Molluscum Contagiosum - Eruption Following Treatment with Prednisone and Methotrexate, *Arch. Derm.* 101: 439-441, April, 1970.
11. Jarratt, M.: Viral Infections of the Skin, *Ped. Cl. of N.A.* 25:339-355, May, 1978.
12. Lever and Schaumburg-Lever: *Histopathology of the Skin*, 5th Edition, J.B. Lippincott Company, Philadelphia-Toronto 1975, pp. 347-348.
13. Barsh, L.I.: Molluscum Contagiosum of the Oral Mucosa, *Oral Surg.* 22:42-46, July, 1966.



30KV X 800

10U 540 11179 IDR

