

AD-A087 885

FOREIGN TECHNOLOGY DIV WRIGHT-PATTERSON AFB OH
A CASE OF INFECTIOUS SEROSITIS IN DUCKS, (U)
FEB 80 P GAZDZINSKI, Z MINTA
FTD-ID(RS)T-2024-79

F/6 2/5

UNCLASSIFIED

NL

For J
50,8000+




END
DATE
FILMED
9-80
DTIC


PHOTOGRAPH THIS SHEET

ADA 087885

DTIC ACCESSION NUMBER



LEVEL



INVENTORY

FTD-ID(RS)T-2024-79

DOCUMENT IDENTIFICATION

DISTRIBUTION STATEMENT A

Approved for public release;
Distribution Unlimited

DISTRIBUTION STATEMENT

ACCESSION FOR	
NTIS	GRA&I <input checked="" type="checkbox"/>
DTIC	TAB <input type="checkbox"/>
UNANNOUNCED	<input type="checkbox"/>
JUSTIFICATION	
BY	
DISTRIBUTION /	
AVAILABILITY CODES	
DIST	AVAIL AND/OR SPECIAL
A	

DISTRIBUTION STAMP

DTIC
ELECTE
S AUG 15 1980 D
D

DATE ACCESSIONED



DATE RECEIVED IN DTIC

PHOTOGRAPH THIS SHEET AND RETURN TO DTIC-DDA-2


FOREIGN TECHNOLOGY DIVISION



A CASE OF INFECTIOUS SEROSITIS IN DUCKS

By

Piotr Gazdzinski, Zenon Minta



Approved for public release;
distribution unlimited.

ADA 087885

80 7 1 224

EDITED TRANSLATION

FTD-ID(RS)T-2024-79

15 February 1980

MICROFICHE NR: FTD-80-C-000225

A CASE OF INFECTIOUS SEROSITIS IN DUCKS

By: Piotr Gazdzinski, Zenon Minta

English pages: 7

Source: Medycyna Weterynaryjna, Vol. 34,
Nr. 4, April 1978, pp. 202-204

Country of Origin: Poland
Translated by: LINGUISTIC SYSTEMS, INC.
F33657-78-D-0618
Ilia Kimmelfeld

Requester: FTD/PHE

Approved for public release; distribution unlimited.

THIS TRANSLATION IS A RENDITION OF THE ORIGINAL FOREIGN TEXT WITHOUT ANY ANALYTICAL OR EDITORIAL COMMENT. STATEMENTS OR THEORIES ADVOCATED OR IMPLIED ARE THOSE OF THE SOURCE AND DO NOT NECESSARILY REFLECT THE POSITION OR OPINION OF THE FOREIGN TECHNOLOGY DIVISION.

PREPARED BY:

TRANSLATION DIVISION
FOREIGN TECHNOLOGY DIVISION
WP-AFB, OHIO.

A CASE OF INFECTIOUS SEROSITIS IN DUCKS

Piotr Gazdzinski, Zenon Minta

Infectious inflammation of the serous membrane (serositis) in ducks was recorded for the first time by Hendrickson and Hilbert (USA) in 1932 [11]. Serositis has also been described in England [2], Canada [17], Holland [6], USSR [4], and Australia [8]. In 1974 Polish scientists Podlewska and Wachnik^[14] reported the first case of isolation of *Moraxella anatipestifer*, the virus causing sirositis in ducks. In a recent publication of "Bergey's Manual", this virus is called *Pasteurella anatipestifer*.

Serositis cases frequently diagnosed in the Research Center of Poultry Disease under the Institute of Veterinary Sciences as well as difficulty in diagnosing this disease have led scientists to describe one of these cases.

C a s e H i s t o r y. In a flock consisting of 4500 broiler ducklings at the age of 5 weeks there were cases of serositis which amounted to 100 birds on the third day of the disease; this level remained unchanged during the following three days. According to the data of the veterinarian called to the farm, the birds infected with serositis revealed uncoordinated head and neck motions, unstable walk, and finally, leg and wing paralysis. Death ensued several hours after these symptoms appeared. Autopsy of the dead birds confirmed the following: fibrous inflammation of the pericardiac sac, the hepatic capsule, and air sacs.

Starting on the 2nd day of the disease, scientists applied Trimerazin for 4 days at therapeutic dose. However, the result was quite negative. The disease persisted. The research examinations initiated in the Department of Veterinary Hygiene brought negative results.

Laboratory Research

Four ducklings that died on the 6th day of the disease were examined. When the autopsy was performed on these ducklings, the following anatomopathological changes were noted: severe lung congestion; fibrous inflammation of the pericardial sac (pericarditis), hepatic capsule (perihepatitis), and air sacs (aerosacculitis). In addition, greyish-white deposits in the air sacs were detected and the intestines revealed an inflammation of the mucous membrane.

Bacteriological examination was performed through culture examination of the internal organs (liver and lungs) on the blood agar, on the McConkey agar, and on the Capek breeding ground. After the 72 hour incubation at 37°C on blood agar, both the liver culture and that of the lungs revealed the growth of a numerous, hardly visible colony resembling the *Pasteurella multocida* colony. In addition, it became possible to isolate *E. coli* as well as *Aspergillus fumigatus* from the lungs.

Individual, unidentified colonies from blood agar were inoculated on the chocolate brown agar as well as on agar with yeast extract and with peptone. Then, the above colonies were incubated at approximately 10% CO₂ atmosphere in a conditioning chamber. After the 48 hour incubation period the colony growth achieved a diameter of 1-1.5 mm. The colonies were protruberant, transparent, and of grey color (Fig. 1).



Fig. 1. Growth of *Pasteurella antipestifer* colony on chocolate brown agar after a 48 hour incubation period.

The microscopic preparations reveal Gram-negative short sticks of intensive coloration.

The isolate obtained has been used in biochemical research the results of which are given in Table 1.

Table 1. Biochemical properties of the isolated strain

Reaction	Result	Reaction	Result
Glucose fermentation	-	Catalase formation	+
Lactose fermentation	-	Oxydase formation	+
Saccharose	"	Urease formation	-
Maltose	"	Indole formation	-
Arabinose	"	H ₂ S formation	-
Xylose	"	Gelatine rarification	+
Levulose	"	Nitrate reduction	-
Rhamnose	"		
Mannutole	"		
Dulcitol	"		
Sorbitol	"		

Explanation: + is a positive biochemical reaction; - is a negative biochemical reaction.

The test of the susceptibility of the strain to amprolium was performed according to the Harry method and proved to give positive results. A significant area of the growth inhibition amounting to 30 mm was discovered. On the basis of the above mentioned results the strain identified as *Pasteurella anatipes-tifer* was isolated from the ducklings.

In order to prove that the cause of disease and mortality among the ducklings examined is the isolated strain, a biological test was performed on ducklings and mice.

Twenty ducklings 2 weeks of age and 4 white mice were used for the test. The material for infection was a 48 hour culture of *Pasteurella anatipestifer* on chocolate brown agar which was flushed by a peptone water in the amount of 5 ml per plate.

The ducklings were divided into 4 groups. The birds belonging to the first group were infected intravenously; the second group was infected through the natatorial membrane (through the midskin); the third group was infected through the trachea with a dose of 0.2 ml of bacterial suspension. The fourth group was designated as the control.

The serositis symptoms appeared only in the group which was infected intravenously. Twenty four hours after infection the duckling limbs were paralyzed, they lost their appetite, and had discharges from their nostrils and eyes. Two of them also showed swelling of ankle joints. Forty hours later all ducklings died.

Besides the fibrous inflammation of air sacs (Fig. 2), the pericardium sac, and the hepatic capsule (Fig. 3), the autopsy also revealed inflammation of the ankle joints and the presence of purulent exudation of the sinus cavity.

The attempt to reisolate *P. anatipestifer* from brain and liver was successful. It was isolated from both organs.

The remaining groups of ducklings which were under-permanent observation during two weeks did not reveal any symptoms of serositis. No mortality has been observed.



Fig. 2. Serositis of the air sacs and pericardium sac in a 2 week old duckling which was experimentally infected with *Pasteurella anatipestifer*.

The mice were infected subcutaneously and through the intestine with a dose of a 2 ml bacterial rinse. Observation was conducted for 2 weeks. During this observation no serositis symptoms or mortality was recorded.

Discussion of Results

The above mentioned disease case seems to be typical for serositis in ducklings. The age at which the disease revealed itself, the course of the disease, clinical symptoms, and anatomopathological changes were identical to those described by other authors [1, 2, 7, 8, 9, 10, 11, 13, 15, 16]. Somewhat different clinical symptoms and those changes detected by the autopsy, which were not typical, were described in the case of Podlewska and Wachnik [14]. These authors isolated *Vibrio hepatidis* as well as *Pasteurella anatipestifer*, and showed the presence of helminths in the ducklings intestines which can affect the picture of the disease.

The *Pasteurella anatipestifer* growth from the examined material was achieved on blood agar after a 72 hour incubation in oxygenic conditions. The colonies observed at that time were hardly visible. The application of enriched breeding grounds as well as incubation in an increased amount of CO₂ resulted in faster and more intensive growth of the virus.

It seems proper in cases of suspected serositis in ducklings to use chocolate brown agar and to conduct incubation of the culture in vessels when the amount of CO₂ and moisture are increased.

Both the morphology of the colonies of isolate received and the microscopic picture of the viruses painted by the Gram method corresponded to the *P. anatipestifer* properties described by other authors [5, 9, 10, 12, 13]. Also, the results of

biochemical tests, the ability to dissolve gelatin, the ability to produce catalase and oxydase, and the ability to reduce nitrate and produce indole and hydrogen sulphide were analogous to those confirmed by other authors [5, 9, 10, 12]. The *P. anatipestifer*'s ability to respond to amprolium was also detected in this particular case of isolate.

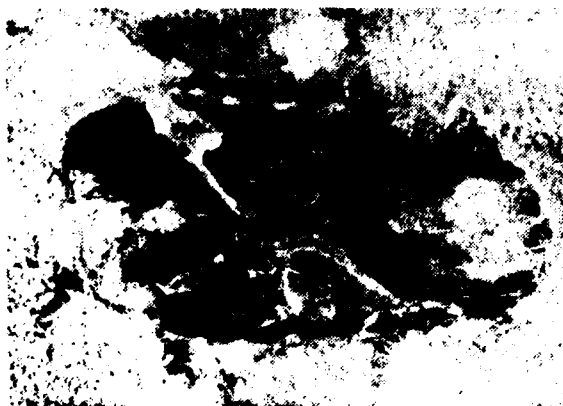

Fig. 3. Serositis of the hepatic capsule and pericardium sac in a 2 week old duckling which was experimentally infected with *Pasteurella anatipestifer*.

During examination of artificial infection of ducklings, scientists used three methods of infection by isolated virus. Only intravenous infection revealed clinical symptoms in ducklings. There were also mortality and anatomopathological changes in the observed ducklings. Similar results were achieved by Pickrell [15].

Asplin [3] diagnosed the disease after the ducklings were infected in the natatorial membrane. Price [16] has diagnosed the same disease after the ducklines were infected in the trachea. In the experiments conducted by the above mentioned Polish scientists, similar results have not been achieved.

Instead, these experiments revealed lack of pathogenicity of the isolated strain of *P. anatipestifer* for white mice which coincides with the data given in medical literature [5, 9, 10, 12].

The experimental results presented appear to fit the diagnosis of infectious inflammation of serous membrane as a reason for duckling loss. They fit the Koch postulate. Since the virus isolate has been received, it becomes possible to picture the disease after artificial infection of susceptible ducklings (as well as an infectious agent) was received from these ducklings.

References

1. *A. J. W. J.*: Avian Dis. 11, 38, 1967.
2. *Asplin F. D.*: Vet. Rec. 67, 301, 1955.
3. *Asplin F. D.*: Vet. Rec. 63, 38, 1958.
4. *Aworoni A. A., Kozlechnikow E. M., Glaukow D. A.*: Tr II Wsyt. Konf. Patol. Anat. Ziwotn. Mosk. Wet. Akad. 171, 1963.
5. *Breed R. S., Murray G. D., Smith N. H.*: „Bergey's Manual" (6 w.) 1964.
6. *Doolittle-Voet J.*: Tijds. br. V. Diergeneesk. 87, 741, 1962.
7. *Doanphelt L., Saunders L. Z., Parsons E. H.*: Am. J. Path. 31, 43, 1965.
8. *Grimes T. J.*: Aust. Vet. J. 48, 368, 1972.
9. *Hedderston K. L.*: „Isolation and Identification of Avian Pathogens" A.A.V.P. 1973.
10. *Hedderston K. L.*: „Disease of Poultry" 6 wyd. Hofstad M. S. 1972.
11. *Hendrickson J. M., Hilbert K. F.*: Cornell Vet. 22, 239, 1932.
12. *Harry E. G.*: Vet. Rec. 61, 673, 1969.
13. *Leibovitz L.*: Avian Dis. 16, 566, 1972.
14. *Podlewski D.*, Wscholn: Zb. Biuletyn V Zjazdu PTNW Olsztyn. 361, 1974.
15. *Pickrell J. A.*: Avian Dis. 10, 281, 1966.
16. *Price J.*: Avian Dis. 3, 466, 1959.
17. *Taylor J. R. E.*: Proc. 27th Ann. Meet. Northeast Conf. Lab. Workers on Pullorum Disease Control. 1955.

DISTRIBUTION LIST

DISTRIBUTION DIRECT TO RECIPIENT

<u>ORGANIZATION</u>	<u>MICROFICHE</u>	<u>ORGANIZATION</u>	<u>MICROFICHE</u>
A205 DMATC	1	E053 AF/INAKA	1
A210 DMAAC	2	E017 AF/RDXTR-W	1
B344 DIA/RDS-3C	9	E403 AFSC/INA	1
C043 USAMIA	1	E404 AEDC	1
C509 BALLISTIC RFS LABS	1	E408 AFWL	1
C510 AIR MOBILITY R&D LAB/FIO	1	E410 ADTC	1
C513 PICATINNY ARSENAL	1	FTD	
C535 AVIATION SYS COMD	1	CCN	1
C591 FSTC	5	ASD/FTD/NIIS	3
C619 MIA REDSTONE	1	NIA/PHS	1
D008 NISC	1	NIIS	2
H300 USAICE (USAREUR)	1		
P005 DOE	1		
P050 CIA/CRB/ADD/SD	2		
NAVORDSTA (50L)	1		
NASA/NST-44	1		
AFIT/LD	1		
LLI/Code I-389	1		
NSA/1213/TDL	2		