

AD-A095 533

ALABAMA UNIV IN BIRMINGHAM

F/G 6/5

RESPONSE OF COMBINED ELECTRICAL STIMULATION AND BIODEGRADABLE C--ETC(U)


JUL 79 J E LEMONS

DAMD17-75-C-5044

UNCLASSIFIED

NL

1 of 1
AD A
095533



A
955

PHOTOGRAPH THIS SHEET

AD-A095533

DTIC ACCESSION NUMBER

II

LEVEL

ALABAMA UNIV. in BIRMINGHAM

I

INVENTORY

RESPONSE OF COMBINED ELECTRICAL STIMULATION AND BIODEGRADABLE CERAMICS. ANNUAL REPT. JULY 1979

DOCUMENT IDENTIFICATION

Lemons, Jack E. Contract DAMD17-75-C-5044 Rept No. 4

DISTRIBUTION STATEMENT A
Approved for public release;
Distribution Unlimited

DISTRIBUTION STATEMENT

ACCESSION FOR	
NTIS	GRA&I <input checked="" type="checkbox"/>
DTIC	TAB <input type="checkbox"/>
UNANNOUNCED	<input type="checkbox"/>
JUSTIFICATION	
BY	
DISTRIBUTION /	
AVAILABILITY CODES	
DIST	AVAIL AND/OR SPECIAL
A	

DISTRIBUTION STAMP

DTIC ELECTE
S MAR 3 1981 D
D

DATE ACCESSIONED

81 3 3 001

DATE RECEIVED IN DTIC

PHOTOGRAPH THIS SHEET AND RETURN TO DTIC-DDA-2

AD-A095533

Report Number 4

RESPONSE OF COMBINED ELECTRICAL STIMULATION AND
BIODEGRADABLE CERAMICS

Annual Report

J. E. Lemons

July, 1979

Supported by
U. S. ARMY MEDICAL RESEARCH AND DEVELOPMENT COMMAND
Fort Detrick, Frederick, Maryland 21701

Contract Number DAMD17-75-C-5044

University of Alabama in Birmingham
Birmingham, Alabama 35294

Approved for public release; distribution unlimited

The findings in this report are not to be construed
as an official Department of the Army position unless
so designated by other authorized documents.

REPORT DOCUMENTATION PAGE		READ INSTRUCTIONS BEFORE COMPLETING FORM
1. REPORT NUMBER	2. GOVT ACCESSION NO.	3. RECIPIENT'S CATALOG NUMBER
4. TITLE (and Subtitle) Response of Combined Electrical Stimulation and Biodegradable Ceramics		5. TYPE OF REPORT & PERIOD COVERED Annual Report June, 1978, to July, 1979
7. AUTHOR(s) Jack E. Lemons, Ph.D.		6. PERFORMING ORG. REPORT NUMBER
9. PERFORMING ORGANIZATION NAME AND ADDRESS University of Alabama in Birmingham University Station Birmingham, Alabama 35294		8. CONTRACT OR GRANT NUMBER(s) DAMD 17-75-C-5044
11. CONTROLLING OFFICE NAME AND ADDRESS US Army Medical Research and Development Command Fort Detrick, Frederick, Maryland 21707		10. PROGRAM ELEMENT, PROJECT, TASK AREA & WORK UNIT NUMBERS 62775A 3S162775A825.00.048
14. MONITORING AGENCY NAME & ADDRESS (if different from Controlling Office)		12. REPORT DATE July, 1979
		13. NUMBER OF PAGES 30
		15. SECURITY CLASS. (of this report) Unclassified
		15a. DECLASSIFICATION/DOWNGRADING SCHEDULE
16. DISTRIBUTION STATEMENT (of this Report) Approved for public release; distribution unlimited.		
17. DISTRIBUTION STATEMENT (of the abstract entered in Block 20, if different from Report)		
18. SUPPLEMENTARY NOTES		
19. KEY WORDS (Continue on reverse side if necessary and identify by block number) Tricalcium phosphate Biodegradable ceramic Chronic implants Animal model Biomaterials Granular Tricalcium Phosphate Surgical implants		
20. ABSTRACT (Continue on reverse side if necessary and identify by block number) Investigations on rod and granular forms of porous tricalcium phosphate ceramic for the surgical correction of bone lesions have been extended to segmental replacements at the mid-radii position in dogs and nonunions of rabbit tibias. Two year follow up studies on rod form implants along dog radii show the presence or residual ceramic and incomplete anatomical remodeling. Relative ceramic to iliac crest bone ratios of 100/0, 50/50, and 0/100 percent by weight showed callus bridging of 8 mm. surgically created rabbit tibia defects at		

Form DD 1473 continued:

Block 20 continued:

§

14-16, 6, and 4-6 weeks respectively for the ceramic/bone filled lesions. Nonunions of rabbit tibias subjected to similar ratios of ceramic and bone showed 3 of 8 bridged for a 100/0 ratio, 2 of 6 bridged at 50/50, and 6 of 7 bridged at a 0/100 percent ratio. Radiographically, the 50/50 ratio looked much better than the total ceramic implants. In all cases, the tissue reactions to the porous tricalcium phosphate ceramic showed good biocompatibility.

SUMMARY

This report summarized studies from the fourth year program on a porous tricalcium phosphate ceramic biomaterial. Surgical procedures were extended to include 1 cm rod form segmental replacements along radii of eight dogs, granular form mixtures with bone for tibial lesions in twenty one rabbits, and granular form mixtures with bone for tibial nonunion lesions in thirty six rabbits. Histological and biomechanical studies were extended for selected samples.

The rod form radius implants in the dogs showed residual ceramic and incomplete anatomical remodeling by radiographic evaluations at approximately two years post surgery. The granular form ceramic and bone mixtures showed healing for all of the rabbits, but a significantly delayed union for the total ceramic implant series. The rabbit tibia nonunions showed a relatively low probability for adequate healing for the total ceramic and 50/50 ratio of ceramic to bone, In contrast the autogeneous bone implants showed a high probability of correction.

In all cases, the gross tissue reactions to the porous tricalcium ceramic were minimal and histological sections showed good biocompatibility.

FOREWORD

In conducting the research described in this report, the investigator adhered to the "Guide for Laboratory Animal Facilities and Care", as promulgated by the Committee on the Guide for Laboratory Animal Resources, National Academy of Sciences - National Research Council.

TABLE OF CONTENTS

	<u>Page</u>
<u>Summary</u>	2
<u>Foreword</u>	3
<u>Introduction</u>	6
<u>Materials and Methods</u>	7
Materials	
Implant Fabrication	
Animal Models	
Surgical Techniques	
Rabbit Nonunions	
Animal Follow Up	
Necropsy and Histology	
Biomechanical Testing	
<u>Results and Discussion</u>	11
Materials and Implant Fabrication	
Surgical Techniques	
Animal Follow Up	
Rabbit Granular Form Implants	
Rabbit Nonunion Granular Form Implants	
Dog Rod Form Implants	
Necropsy and Histology	
Biomechanical Testing	
<u>Conclusions</u>	23
<u>References</u>	26

TABLES

Table I.	Rabbit and Dog Follow Up Summary Data.....	12
Table II.	Force Magnitudes for "Nonunion" Samples of Rabbit Tibia Tested by.....	24
	Four Point Bending	

FIGURES

Figure 1.	Schematic Drawing of Segmental Lesion in a Rabbit Tibia Showing the..	8
	Relative Placement Positions of the Stabilization Pins	
Figure 2.	Schematic Drawing of the Segmental Bone Replacement and Bone.....	10
	Stabilization Plate for the Dog Studies.	
Figure 3.	Radiographs of Rabbit Tibia at 4 and 6 Weeks Comparing Tricalcium....	18
	Phosphate (a), 50/50 Ratio (b), and Bone (c) Implants.	
Figure 4.	Radiographs of Rabbit Tibias Comparing the Tricalcium Phosphate (a),.	19
	50/50 Ratio (b), and Bone (c) Implants at 44 and 48 Weeks.	

FIGURES (continued)

	<u>Page</u>
Figure 5. Radiographs showing a Nonunion Lesion and a Total Tricalcium Phosphate Implantation at 6 Weeks Post Surgery (a), and 11 Weeks (b), and 23 Weeks (c) Post Implantation.	20
Figure 6. Radiographs showing a Nonunion Lesion and a 50/50 Ratio of Ceramic and Bone Implant at 11 Weeks Post Surgery (a), and 5 Weeks (b) and 13 Weeks (c) Post Implantation.	21
Figure 7. Radiographs Showing a Nonunion Lesion and an Autogeneous Bone Implant at 21 Weeks Post Surgery (a), and 2 Weeks (b), and 12 Weeks (c) Post Implantation.	22

INTRODUCTION

Inorganic biomaterials for the replacement of, or addition to autogeneous bone for surgical procedures have been investigated for many years. Although maxillofacial and orthopaedic surgical procedures have evolved significantly, no completely acceptable bone substitute material exists. This is especially true for bone lesions such as major segmental defects and nonunions. Most procedures continue to utilize reduction, mechanical stabilization, and autogeneous bone grafts. To obtain the bone graft in most situations, a second surgical site is required with its related morbidity. The overall objective of the present study is to more fully investigate one candidate bone substitute material, porous tricalcium phosphate ceramic, in an attempt to improve conditions for the surgical correction of lesions in bone. Salient results of this program for the treatment of maxillofacial and orthopaedic conditions could be major reduction in surgical time, deformities, and morbidity.

The technical objectives of the fourth year program were a direct continuation of the third year and were as follows:

1. To evaluate surgical methods and combinations of the granular tricalcium phosphate ceramic and autogeneous bone for the correction of surgical lesions and nonunions in rabbits and;
2. To evaluate long term tissue responses to porous rod form tricalcium phosphate ceramic segmental replacements in dogs.

This report summarizes studies on: (1) granular form tricalcium phosphate ceramic and autogeneous bone mixtures for tibial lesion corrections in rabbits; (2) the development of nonunions of rabbit tibia and the correction of these sites using mixtures of granular form ceramic and bone; (3) rod form porous ceramic segmental replacements for radii of dogs; (4) histological evaluations of long term implants in rabbits; and (5) biomechanical testing of healed non-union tibias from rabbits.

A general interest in the development and application of tricalcium phosphate ceramics has continued in many different locations. Shepherd et al¹ introduced methods for subcortical placement of a porous tricalcium phosphate ceramic for alveolar ridge augmentations. This interposition technique appears quite promising. However no long term follow up studies on the resorption of this ceramic were presented. Cameron, McNab and Pilliar² continue to propose the general application of the tricalcium phosphate ceramics for a number of maxillofacial and orthopaedic procedures. Their animal studies in dogs do not appear to be extensive. In all cases the biocompatibility of the ceramic appears quite good. Nery, Lynch and Rooney³ have proposed the use of their tricalcium phosphate ceramic for alveolar ridge augmentations from a study on dogs. In general, the results showed good biocompatibility, but very limited biodegradation over a one year period. The ridge implants were not functionally loaded, so the results may change significantly in a true clinical situation.

DeGroot and Gregonis⁴ continue to investigate various biodegradable apatite structures as do Jarcho et al⁵. Some of these "minimally biodegradable" materials have reached the stage of clinical trials. In most cases, these materials appear to have a good future in surgery. Lemons and Niemann⁶ reviewed the tricalcium phosphate ceramic studies at the University of Alabama in Birmingham before the Orthopaedic Research Society. This report summarized the four years of study supported by the U.S. Army Medical Research and Development Command Contract DAMD17-75-C-5044.

MATERIALS AND METHODS

Materials

Rods of porous tricalcium phosphate ceramic were received from Battelle Memorial Institute Columbus Laboratories* for the present studies. Analyses of the chemical constituents of this material by x-ray showed 100 percent $\text{Ca}_3(\text{PO}_4)_2$ ** . The wet densities of the 0.475 inch diameter rods were 50.96 percent of theoretical while the 0.40 inch diameter rods showed 51.10 percent of theoretical density. These materials were reported to be from the same starting powders as the previously supplied tricalcium phosphate ceramic⁷.

Implant Fabrication

The various implant designs were cut directly from the supplied rods after removing the outer surface layer. The rod form implants for segmental replacements were cut using diamond discs. All cutting products were retained and each specimen was weighed to the nearest milligram. The granular forms were produced by crushing the rods in a mortar and pestle followed by size fractioning using standard ASTM mesh sieves. The granular size fraction for implantation was -40 +100 mesh. The various forms were dry heat sterilized by placing the specimens in pyrex glass containers and exposing them at 300C for 0.5 to 2 hours in a muffle furnace.

Animal Models

The New Zealand White rabbit and large mongrel dogs were used for the animal models. This area will be considered by separating the methods into surgical technique, rabbit nonunion, and the animal follow up procedures.

Surgical Techniques

The segmental lesion and the stabilization pin arrangement for the rabbit animal model are shown schematically in Figure 1. The mixtures of granular tricalcium phosphate ceramic and autogeneous bone from the iliac crest were placed within 8 mm length tibial lesions. Surgical procedures were similar to those described

* G.L. Messing, Research Scientist, Battelle Memorial Institute, Columbus, Ohio.

** Investigations conducted at Battelle Laboratories.

U. S. Army Medical Research and Development Command Report DADA17-69-C-9118, 1975.

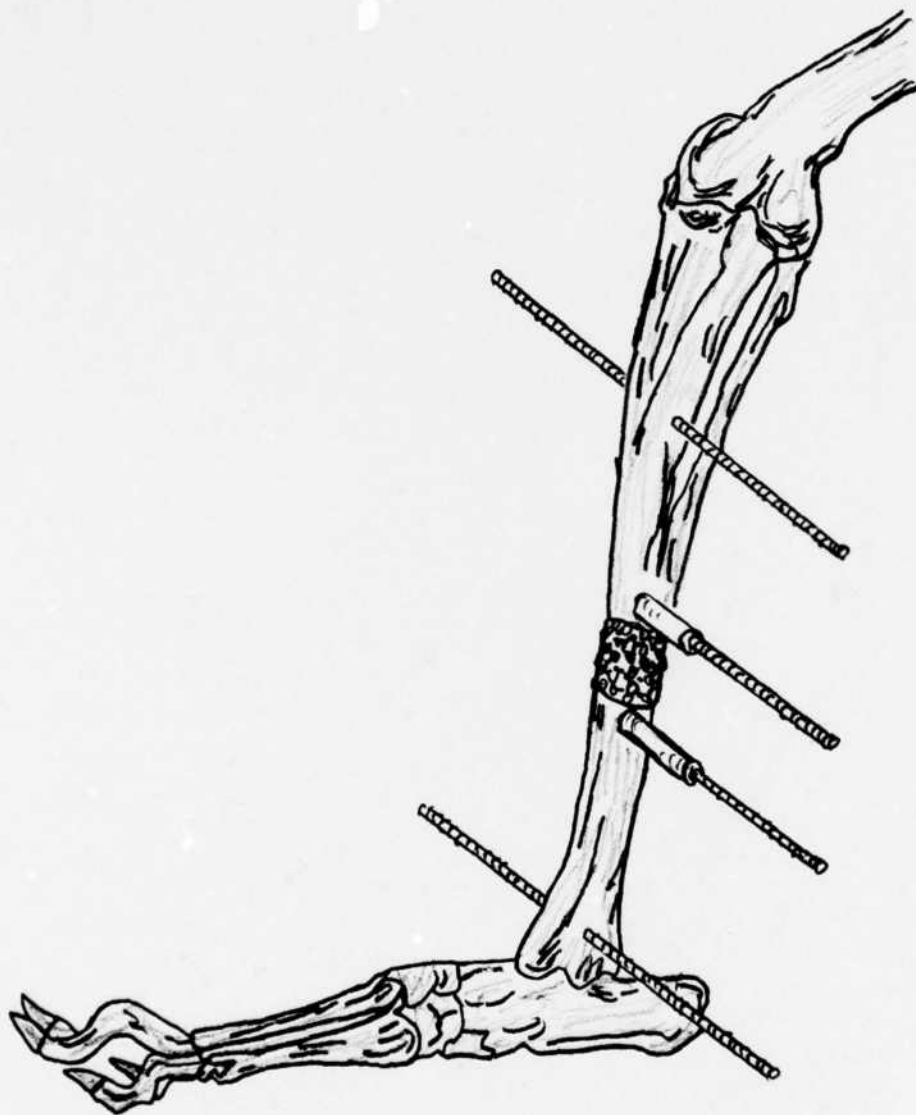


Figure 1. Schematic drawing of segmental lesion in a rabbit tibia showing the relative placement positions of the stabilization pins.

previously⁷. The granular ceramic and bone were weighed on the surgery table using a stainless steel balance. Pilot studies used ratios of 1 gram bone, 0.5 gm bone/0.5 gm ceramic, or 1 gram of ceramic alone. Subsequent studies utilized 2 gram total quantities.

The dog rod form segmental replacement surgical procedures were the same as used previously. The 1 cm length implant was placed near the center of the radius utilizing a six hole onlay bone plate for stabilization of the bone. This situation is shown schematically in Figure 2. No significant problems were encountered with the rabbit or dog surgical procedures.

Rabbit Nonunions

The rabbit nonunion procedures increased the bone lesion to 12 mm length with removal of the periosteum. These did not result in a high percentage of nonunions from the first series. Therefore, silicone rubber plugs approximately 1 cm in diameter and 12 mm length were fabricated and placed into the bone lesion sites for a number of the rabbit nonunion series. The periosteum was removed by sharp dissection as previously. The inclusion of the silicone plug did not delay the surgical procedures.

Animal Follow Up

The various animals were evaluated regularly by general observation and radiography. Some problems were experienced with the rabbit nonunion series. Steinmann pin fracture and pin tract infections caused the most difficulties. The animals were evaluated by the laboratory staff with consultation with the Department of Comparative Medicine Staff (Animal Services) where required.

The nonunion rabbits were reoperated when a definite nonunion was observed radiographically. After the second surgery the stabilization pins were removed, where possible, when the lesions were firmly bridged by radiographic evaluation.

Necropsy and Histology

The rabbits were euthanized by drug overdose, the soft tissues removed by sharp dissection, the bones photographed, and the various specimens removed and fixed in buffered formalin as indicated. A number of the tibias were biomechanically tested prior to fixing and sectioning. The ceramic implant sites were observed macroscopically and by probing prior to testing. Standard hematoxylin and eosin stained sections were prepared. Additionally, selected nondecalcified thin sections were processed. The various sections were evaluated by a histopathologist and the laboratory staff.

Biomechanical Testing

In an attempt to evaluate the biomechanical strength of the healed rabbit tibia, samples were tested by four point bending. The irregular anatomies of the nonunion series caused considerable difficulty in obtaining reasonable alignments and general

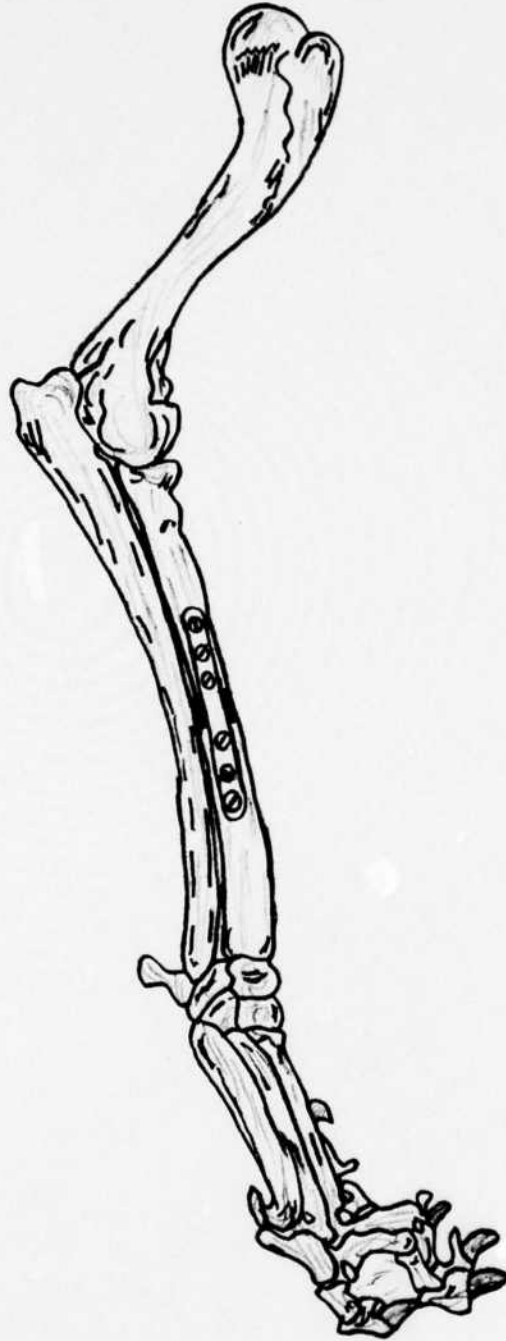


Figure 2. Schematic drawing of the segmental bone replacement and bone stabilization plate for the dog studies.

testing conditions. With the complex cross sections at the fracture sites, no attempts were made to determine cross sectional areas and work to fracture measurements.

RESULTS AND DISCUSSION

Materials and Implant Fabrication

The tricalcium phosphate ceramic materials received in May, 1978 provided sufficient samples for the present studies. Limited evaluations showed these samples to be similar to the previously studied samples. No problems were encountered in handling, fabricating, or sterilizing. The outer surface of these rods appeared to have a dense layer similar to the previous rod stock from Battelle. Therefore, the surface was removed with a diamond cutting disc prior to shaping the rod form implants.

We feel that it is quite important that our intercomparisons on tissue responses to this porous tricalcium phosphate ceramic utilize the same basic material. The use of the original powder and processing conditions by Battelle should provide a relatively consistent chemical analysis and physical form.

Surgical Techniques

The surgical procedures and immediate post operative care was relatively uneventful. With the experience of the surgical and technical support staff, most difficulties have been minimized. The animals were ambulatory within their cages shortly after the surgical procedures.

The introduction of the silicone rubber "plugs" into the surgical sites was included in an attempt to obtain a reasonable number of nonunions. It is realized that this procedure is not the same as used previously for developing a nonunion series. It was felt, however, that this method did not compromise the objectives of the investigation.

Animal Follow Up

The data on the various rabbit and dog procedures are summarized in Table I. Table I includes information on thirty six rabbits from the nonunion series, twenty one rabbits of the granular ceramic implant groups from studies by Dr. Chang*, and eight dogs with rod form implants. One long term nonunion rabbit from the previous studies has also been included. The separate groups of animals are listed chronologically according to the date of the original surgery. The rabbit number is the general laboratory number for record purposes while the comments were taken directly from the log book records.

* Master of Science in Dentistry Thesis Investigation, 1979.

TABLE I. RABBIT AND DOG FOLLOW UP SUMMARY DATA

<u>RABBIT #</u>	<u>DATE</u>	<u>PROCEDURE</u>	<u>DURATION (WKS)</u>	<u>COMMENTS</u>
<u>Nonunions</u>				
591	08/12/77	Original surgery	5	
	10/14/77	Callus removed	7	Callus growth
	12/09/77	Implant rod form	89	Biomechanically tested
	07/25/79	Sacrifice		
637	10/06/78	Original surgery		Bridged
	01/18/79	Silicone plug	16	Became nonunion
	04/23/79	Total granular form	14	
	06/20/79	Sacrifice	8	Did not bridge
638	10/06/78	Original surgery		Bridged
	02/16/79	Silicone plug	19	Not bridged
	03/26/79	50 - 50	5	Fix pin
	06/20/79	Sacrifice	12	Did not bridge
631	10/09/78	Original surgery		Callus growth
	01/16/79	Silicone plug	15	Not bridged
	03/30/79	Total bone	10	Fix pin
	06/20/79	Sacrifice	12	Bridged, biomechanically evaluated
362	10/09/78	Original surgery		Callus growth
	01/18/79	Silicone plug	15	Not bridged
	03/30/79	Total granular form	10	
	06/20/79	Sacrifice	12	Did not bridge
363	10/16/78	Original surgery		Bridged
	01/17/79	Silicone plug	14	Callus growth
	04/18/79	50 - 50	13	
	05/11/79	Died	3	
364	10/16/78	Original surgery		Bridged
	01/30/79	Sacrifice	16	Infection
365	10/20/78	Original surgery		Bridged
	01/18/79	Silicone plug	13	Not bridged
	05/15/79	Total bone	17	Looks bridged
BX4			6	In progress
	10/20/78	Original surgery		Bridged
	01/18/79	Silicone plug	13	Infection
VB4	01/29/79	Sacrifice	1	Tibial displacement
	10/25/78	Original surgery		
366	11/09/78	Died	2	Tibial displacement
	10/25/78	Original surgery		
C2	11/22/78	Died	4	Bilateral brachial plexus palsey
	10/27/78	Original surgery		Bridged
	02/02/79	Silicone plug	14	Bridged on lateral aspect
	04/23/78	Total granular form	11	Looks bridged
			9	In progress

TABLE I. RABBIT AND DOG FOLLOW UP SUMMARY DATA (continued)

<u>RABBIT #</u>	<u>DATE</u>	<u>PROCEDURE</u>	<u>DURATION (WKS)</u>	<u>COMMENTS</u>
367	11/06/78	Original surgery		Not bridged
	01/12/79	Total granular form	11	Bridged
	06/21/79	Sacrifice	23	Biomechanically evaluated
368	11/06/78	Original surgery		
	01/30/79	Sacrifice	13	Infection, tibial displacement
369	11/10/78	Original surgery		Bridged, though not much callus
	02/02/79	Silicone plug	12	Bridged, though not much callus
	05/04/79	Total bone	13	Bridged, considerable callus
	06/21/79	Sacrifice	7	Biomechanically evaluated
370	10/11/78	Original surgery		Bridged
	02/09/79	Silicone plug	13	Fix pin, not bridged
	05/15/79	50 - 50	13	Not bridged, though considerable callus
	06/20/79	Sacrifice	5	
371	11/13/78	Original surgery		Bridged
	02/02/79	Silicone plug	13	Not bridged
	04/27/79	Total bone	12	Not bridged, but has callus
			9	In progress
372	11/17/78	Original surgery		
	12/11/78	Died	4	Unknown cause
373	11/27/78	Original surgery		Bridged
	02/09/79	Silicone plug	12	Bilateral brachial plexus palsey
	04/02/79	Total bone	7	Not bridged
	06/20/79	Sacrifice	11	Severe infection
374	12/01/78	Original surgery		Bridged
	02/16/79	Silicone plug	11	
	04/23/79	Total granular form	9	Fix pin
	06/20/79	Sacrifice	8	Not bridged, infected
428B	12/01/78	Original surgery		Fix pin
	01/24/79	Total granular form	8	Infection, not bridged
	04/05/79	Sacrificed	10	Severe infection
375	12/04/78	Original surgery		Not bridged
	01/26/79	Total granular form	8	Did not heal
	05/11/79	Total bone	14	
			7	In progress
376	12/06/78	Original surgery		Not bridged
	01/26/79	Total granular form	9	Fix pin, not bridged
	04/04/79	Total bone	10	Fix pin, bridged
	06/21/79	Sacrifice	11	Biomechanically evaluated

TABLE I. RABBIT AND DOG FOLLOW UP SUMMARY DATA (continued)

<u>RABBIT #</u>	<u>DATE</u>	<u>PROCEDURE</u>	<u>DURATION (WKS)</u>	<u>COMMENTS</u>
377	12/08/78	Original surgery		Not bridged
	01/26/79	Total granular form	9	Fix pin, not bridged
	04/09/79	Total bone	11	Bridged
	06/21/79	Sacrifice	10	Biomechanically evaluated
378	12/08/78	Original surgery		Bridged
	02/09/79	Silicone plug	9	Bridged
	04/23/79	Total granular form	10	
379	12/11/78	Original surgery	9	In progress
	02/02/79	Silicone plug	9	Bridged
	04/16/79	50 - 50	10	Infection, bridged
	06/21/79	Sacrifice	9	Bridged
B19	12/15/78	Original surgery		Biomechanically evaluated
	03/09/79	Silicone plug	12	bridged
	04/21/79	Total bone	6	Infection, not bridged
	06/20/79	Sacrifice	9	Bridged
380	12/15/78	Original surgery		Had some mechanical strength
	01/30/79	Sacrifice	7	Ankle fracture
52	01/05/79	Original surgery		
	01/10/79	Died	1	Unknown cause
125	01/08/79	Original surgery		
	01/27/79	Died	3	Unknown cause
381	01/08/79	Original surgery		Not bridged
	03/23/79	50 - 50	11	Infection
	06/20/79	Sacrifice	13	Not bridged
623	01/03/79	Original surgery		Not bridged
	03/21/79	50 - 50	11	Bridged
	06/20/79	Sacrifice	13	Biomechanically evaluated
T0	01/03/79	Original surgery		Not bridged
	03/11/79	Died	10	Unknown cause
382	02/23/79	Original surgery		Not bridged
	05/17/79	Total bone	13	Infection
	06/25/79	Died	6	Callus, but not bridged
383	02/26/79	Original surgery (silicone plug)		
	03/07/79	Died	1	Unknown cause
384	03/02/79	Original surgery (silicone plug)		Not bridged
	05/16/79	Total granular form	11	Fix pin, infection
	06/20/79	Sacrifice	5	Not bridged
385	03/02/79	Original surgery (silicone plug)		Not bridged
	05/16/79	50 - 50	11	Infection
			6	In progress

TABLE I. RABBIT AND DOG FOLLOW UP SUMMARY DATA (continued)

<u>RABBIT #</u>	<u>DATE</u>	<u>PROCEDURE</u>	<u>DURATION (WKS)</u>	<u>COMMENTS</u>
<u>Standard</u>				
<u>8 mm Lesions</u>				
736	12/13/77	Granular form		
	02/08/78	Pins removed		
	02/09/78	Sacrifice		Fractured tibia
737	12/13/77	50 - 50 mixture		
	02/08/78	Pins removed		
	11/26/78	Sacrifice		Dense callus
738	01/06/78	50 - 50 mixture		
	02/28/78	Pins removed		
	12/13/78	Sacrifice		
JL13	01/13/78	Granular form		
	12/20/78	Sacrifice		
JL11	01/16/78	Granular form		
	06/30/78	Sacrifice		
T3	01/23/78	Bone		Nonunion
	07/17/78	Sacrifice		
H50	02/24/78	Granular form		
	04/14/78	Sacrifice		Fractured tibia at distal pin site
K3	03/03/78	Granular form		
	03/29/78	Sacrifice		Fractured pin, tibial displacement
B97	03/24/78	50 - 50		
	05/08/78	Sacrifice		Fracture - tibia at proximal pin site
H250	03/27/78	Granular form		
	09/25/78	Sacrifice		
R248	03/31/78	Bone		
	02/05/79	Sacrifice		
R249	04/07/78	Bone		
	05/19/78	Sacrifice		
R281	05/22/78	Bone		
	07/17/78	Sacrifice		
H181	05/25/78	Bone		
	05/30/78	Died		
BV2	05/25/78	Bone		
	07/17/78	Sacrifice		
R318	06/07/78	Bone		
	07/24/78	Sacrifice		
R334	06/09/78	Granular form		
	07/24/78	Sacrifice		Nonunion

TABLE I. RABBIT AND DOG FOLLOW UP SUMMARY DATE (continued)

<u>RABBIT #</u>	<u>DATE</u>	<u>PROCEDURE</u>	<u>DURATION (WKS)</u>	<u>COMMENTS</u>
R335	06/09/78	Granular form		
	07/24/78	Sacrifice		Little callus
R360	06/12/78	50 - 50		
	07/24/78	Sacrifice		
R358	07/07/78	50 - 50		
	08/24/78	Sacrifice		
R359	07/12/78	50 - 50		
	08/29/78			

<u>DOG #</u>	<u>DATE</u>	<u>PROCEDURE</u>	<u>DURATION (WKS)</u>	<u>COMMENTS</u>
229	08/05/77	Rod form implant		Not much callus growth
	10/07/77	Bone graft	9	Bridged
	01/27/78	Bone plate removed	16	Healed
			75	In progress
363	08/19/77	Rod form implant		Bridged
	12/02/77	Bone plate removed	14	Healed
			83	In progress
2629	04/06/79	Rod form implant		
			12	In progress
2634	04/10/79	Rod form implant		Suture line opened, wound is granulating in
			11	In progress
2730	04/13/79	Rod form implant		Slight skin necrosis over wound
			11	In progress
2915	06/12/79	Rod form implant		
			2	In progress
3020	06/18/79	Rod form implant		
			1	In progress
2930	06/22/79	Rod form implant		
			1	In progress

Rabbit Granular Form Implants

The granular form series for the 8 mm lesions and the ratios of tricalcium phosphate and bone were evaluated short term (approximately 6 weeks) and long term (23-48 weeks). Comparative average radiographs comparing lesion sites at four and six week for the ceramic, 50/50 ratio, and bone implants are shown in Figure 3. The autogeneous bone showed the best condition radiographically with respect to healing. Good bridging was evident at approximately four weeks. The 50/50 ratio shows bridging of the lesion at 6 weeks while the total ceramic had not healed at the same period. Radiographs comparing the ceramic, 50/50 ratio, and bone implants at 44-48 weeks are shown in Figure 4. The lesions have healed for all three conditions. However, an area associated with residual ceramic can be noted radiographically for the total ceramic implant tibia. This radiograph was taken at necropsy and is the same total ceramic tibia shown previously in Figure 3. The anatomy of the tibia appears most normal for the autogeneous bone implant.

The total autogeneous bone implant lesions showed callus bridging at 4-6 weeks, the 50/50 ratio at approximately 6 weeks, while the total ceramic showed longer times with bridging at 14-16 weeks post surgery. The quantity of material (2 grams) added to the lesion site was in excess, compared to the pilot study⁷, and the original proposal. The larger quantity may have caused the delay in bridging for the total ceramic implant group.

Rabbit Nonunion Granular Form Implants

The nonunion series compared the total ceramic, 50/50 ratio, and total bone implant materials. The ceramic implants showed bridging (clinical union) for three of the eight implanted. The 50/50 ratio group showed two of six with bridging while six of the seven implanted with autogeneous bone alone showed a clinical union. The one rabbit in the autogeneous bone series that did not heal, experienced a significant pin tract infection with bone lesion involvement. An example of one total granular ceramic implant series radiographs showing the nonunion before implantation (6 weeks after first surgery), after implantation (11 weeks) and before necropsy (23 weeks post implantation) is shown in Figure 5. A similar series for the 50/50 ratio and total autogeneous bone implants are shown in Figures 6 and 7 respectively.

The autogeneous bone implant series shows the best probability for correction of the nonunion lesions. The 50/50 ratio and total ceramic implants show very similar, but low probabilities for lesion bridging. General radiographic and clinical evaluations show the 50/50 ratio series to be much better than the total granular form series. However, for nonunions the 50/50 ratio of ceramic to bone is far from optimum.

Dog Rod Form Implants


The segmental replacements along the radii of dogs continue without unusual developments. The two long term dogs show retained implant material radiographically



(a - 6 wk)



(b - 6 wk)




(c - 4 wk)

Figure 3. Radiographs of Rabbit Tibia at 4 and 6 weeks comparing Tricalcium Phosphate (a), 50/50 Ratio (b), and Bone (c) Implants.


.40-185



(a - 48 wks)

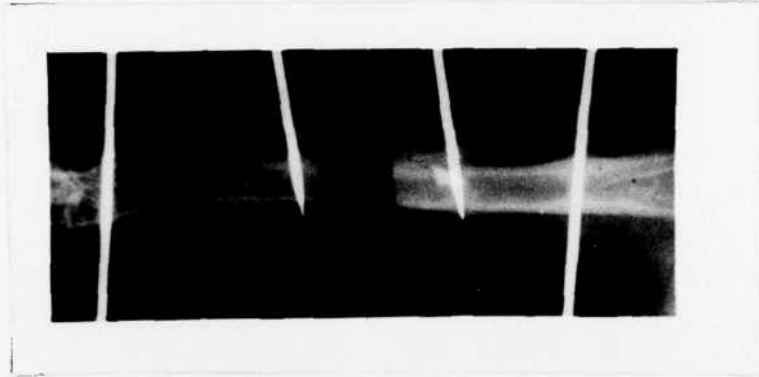


(b - 48 wks)

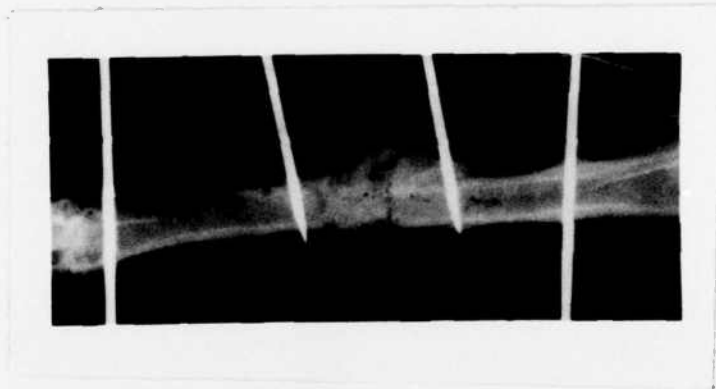


(c - 44 wks)


Figure 4. Radiographs of Rabbit Tibias comparing the Tricalcium Phosphate (a), 50/50 Ratio (b), and Bone (c) Implants at 44 and 48 weeks.



(a)

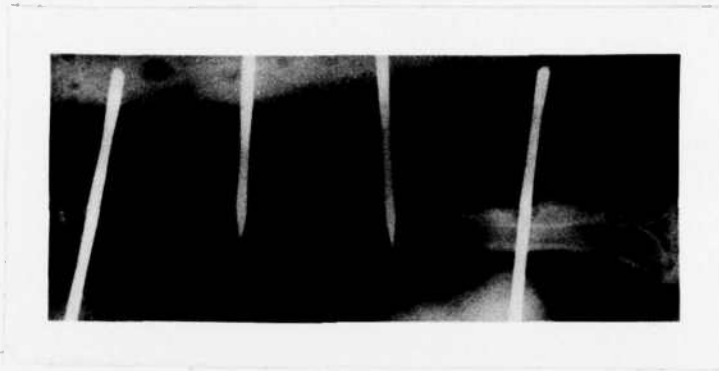


(b)



(c)

Figure 5. Radiographs showing a Nonunion Lesion and a Total Tricalcium Phosphate Implantation at 6 weeks post surgery (a), and 11 weeks (b), and 23 weeks (c) post implantation.



(a)

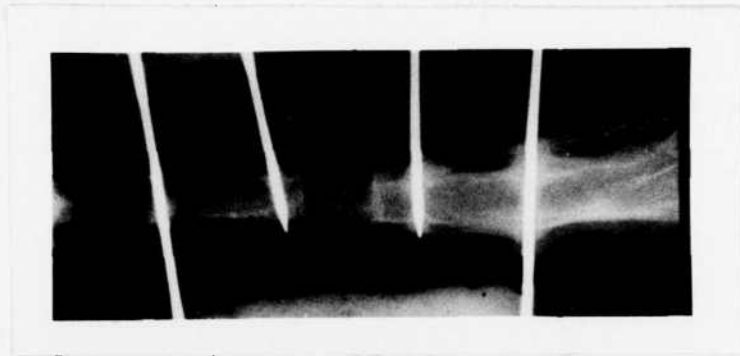


(b)



(c)

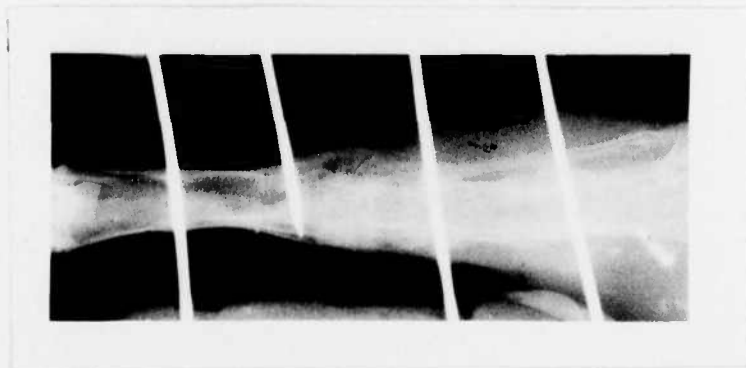
Figure 6. Radiographs showing a Nonunion Lesion and a 50/50 Ratio of Ceramic and Bone Implant at 11 weeks post surgery (a), and 5 weeks (b) and 13 weeks (c) post implantation.



(a)



(b)



(c)

Figure 7. Radiographs showing a Nonunion Lesion and an Autogenous Bone Implant at 21 weeks post surgery (a), and 2 weeks (b), and 12 weeks (c) post implantation.

with unions in both cases. One of the more recent dogs experienced a suture line infection which was handled by an antibiotic therapy. A skin area was lost on one animal, but this site healed and is currently in a stable condition. This series is in progress and the bone plates will be removed as indicated radiographically. No further implantations of rod form tricalcium phosphate ceramic in dogs are planned at this time.

Necropsy and Histology

General clinical observation, and gross observation at necropsy showed no significant tissue reactions associated with any of the tricalcium phosphate ceramic implants. Histologically, the granular ceramic was incorporated into the tissues with the bone sections showing bone directly adjacent to the ceramic interfaces. The bone sites did not show inflammatory reactions. The ceramic implant sites where soft tissues surrounded the implant showed some giant cells, but in general, minimal inflammatory responses. In all cases the ceramic was quite biocompatible.

Some of the long term ceramic implants showed a mixture of hard and soft (to sharp probe penetration) ceramic products. In one rabbit (R 591) the ceramic within the bone was hard while the ceramic within the soft tissues was soft and rubber like. The histological sections stained with hematoxylin and rosin showed a gray diffuse interface between fibrous tissues and some ceramic granules. This area was a narrow band that may represent biodegradation products with an associated tissue reaction. No localized cellular reactions of significance were noted, with the exception of giant cells which contained products that appeared to be tricalcium phosphate ceramic residues.

Biomechanical Testing

The nonunion rabbits where the lesion was bridged and the stabilization devices had been removed were subjected to biomechanical strength studies. The four point bending fixture and test technique developed previously was used⁷. Work to fracture data were not developed because of the complex cross sections of these bones. The forces required for fracture are summarized in Table II. Some other tibia had some mechanical strength but could not be tested. Although a quantitative comparison between these samples is not valid because of the differences in shape, the values provide a relative intercomparison of maximum force the tibia could withstand in bending.

CONCLUSIONS

The conclusions from the fourth year animal model studies on granular and rod form porous tricalcium phosphate ceramic are as follows.

1. Two year radiographic and clinical evaluations of rod form segmental replacements in dog radii show retained ceramic and a localized remodeling of bone around the ceramic, but otherwise a normal and uneventful follow up. The dogs have maintained full function of the limbs.

TABLE II. FORCE MAGNITUDES FOR "NONUNION SAMPLES OF RABBIT TIBIA TESTED BY FOUR POINT BENDING

<u>RABBIT NUMBER AND CONDITION</u>	<u>FORCE MAGNITUDE (lbs)</u>
<u>Total Ceramic</u>	
R367	13
<u>50/50 Ratio</u>	
R379	40
R623	19
<u>Total Bone</u>	
R361	81
R369	44
R376	33
R377	52

2. Mixtures of granular form ceramic and autogeneous bone placed in 8 mm length lesions in rabbit tibias showed bridging of the defect at 4-6 weeks for total bone, bridging at 6 weeks for a 50/50 mixture, and bridging at 14-16 weeks for total ceramic implants. All of the lesions healed and became fully functional without stabilization devices.
3. Mixtures of granular form ceramic and autogeneous bone placed in non-union lesions in rabbit tibias showed bridging of the defect for six of seven with total bone, bridging for two of six with a 50/50 ratio, and bridging for three of eight with total ceramic implants.
4. All samples studied by gross observation at necropsy, hematoxylin and eosin stained sections, and nondecalcified thin sections showed minimal tissue reaction a good biocompatibility of the ceramic.
5. One long term (23 months) rabbit tibia implant showed retained ceramic at the lesion site.
6. Biomechanical testing of healed nonunion rabbit tibia samples showed fracture forces from 13 to 81 pounds.

REFERENCES

1. Shepherd, N., Malhoney, P., Biggs, A., Stanwich, L. and Doku, H.C., Subcortical Ceramic Implants for Elevation of Alveolar Ridges, *J.D.R.*, 55B, Abst.729, B 244, 1976.
2. Cameron, H.U., McNab, I., and Pilliar, R.M., Evaluation of a Biodegradable Ceramic, *J. Biomed. Mater. Res.*, 11, 179, 1977.
3. Nery, E.B., Lynch, K.L., and Rooney, G.E., Alveolar Ridge Augmentation with Tricalcium Phosphate Ceramic, *J. Pros. Dent.*, 40, 668, 1978.
4. DeGroot, K., and Gregonis, D., Phosphate - Ethyl Methacrylate as a Coating for Apatite Structures, *J. Biomed. Mater. Res.*, Abst. 72, 2, 113, 1978.
5. Jarcho, M., Jasty, V., Gumaer, K.I., Kay, J.F. and Doremus, R.H., Electron Microscopic Study of Bone - Hydroxylapatite Implant Interface, *J. Biomed. Mater. Res.*, Abst. 71, 2, 112, 1978.
6. Lemons, J.E. and Niemann, K.M.W., Porous Tricalcium Phosphate Ceramic for Bone Replacement, *Orthop. Res. Soc.*, Abst., 4, 162, 1979.
7. Lemons, J.E., Response of Combined Electrical Stimulation and Biodegradable Ceramic, Annual Reports 1-3, USAMRDC Contract DAMD17-75-C-5044, 1975-1978.

DISTRIBUTION LIST

4	copies	HQDA (SGRD-SI) Fort Detrick Frederick, MD. 21701
12	copies	Defense Technical Information Center (DTIC) ATTN: DTIC-DDA Cameron Station Alexandria, Virginia 22314
1	copy	Dean School of Medicine Uniformed Services University of the Health Sciences 4301 Jones Bridge Road Bethesda, Maryland 20014
1	copy	Superintendent Academy of Health Sciences, US Army ATTN: AHS-COM Fort Sam Houston, Texas 78234

ATE
LMED
-8