

AD-A112 309

ARMY INST OF DENTAL RESEARCH WASHINGTON DC

F/G 4/5

A BIFID MANDIBULAR NERVE AS A POSSIBLE CAUSE OF ANESTHETIC DFFI--ETC(11)

FEB 82 P S GROVER, L LORTON

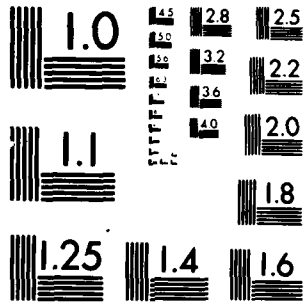
UNCLASSIFIED

NL

1 of 1
5/2/82



END
DATE
FILMED
4 82
DTIC



MICROCOPY RESOLUTION TEST CHART
NATIONAL BUREAU OF STANDARDS-1963-A

UNCLASSIFIED

SECURITY CLASSIFICATION OF THIS PAGE (When Data Entered)

12

REPORT DOCUMENTATION PAGE

READ INSTRUCTIONS BEFORE COMPLETING FORM

1. REPORT NUMBER	2. GOVT ACCESSION NO.	3. RECIPIENT'S CATALOG NUMBER
4. TITLE (and Subtitle) A Bifid Mandibular Nerve as a Possible Cause of Anesthetic Deficiency in the Mandible		5. TYPE OF REPORT & PERIOD COVERED Submission of paper Jan 1980 - July 1980
AUTHOR(s) P.S. Grover and Lewis Lorton		6. PERFORMING ORG. REPORT NUMBER
PERFORMING ORGANIZATION NAME AND ADDRESS U.S. Army Institute of Dental Research Walter Reed Army Medical Center Washington, DC 20012		8. CONTRACT OR GRANT NUMBER(s) N/A
CONTROLLING OFFICE NAME AND ADDRESS U.S. Army Medical Research & Development Command HQDA-IS Fort Detrick, MD 21701		11. PROGRAM ELEMENT, PROJECT, TASK AREA & WORK UNIT NUMBERS N/A
1. MONITORING AGENCY NAME & ADDRESS (if different from Controlling Office)		12. REPORT DATE February 1982
		13. NUMBER OF PAGES 12
		15. SECURITY CLASS. (of this report) UNCLASSIFIED
		15a. DECLASSIFICATION/DOWNGRADING SCHEDULE

DISTRIBUTION STATEMENT (of this Report)

This document has been approved for public release and sale; its distribution is unlimited.

17. DISTRIBUTION STATEMENT (of the abstract entered in Block 20, if different from Report)

18. SUPPLEMENTARY NOTES

19. KEY WORDS (Continue on reverse side if necessary and identify by block number)

Complete mandibular anesthesia .

20. ABSTRACT (Continue on reverse side if necessary and identify by block number)

The failure to achieve complete mandibular anesthesia is a problem that occurs in as high as 20% of all cases. The explanations vary from faulty anesthetic solutions to faulty technique, to anatomic or physiologic variations. Accessory nerve innervation from the mylohyoid nerve or the contra-lateral mental nerve has also been suggested. Bifurcation of the mandibular nerve is rarely mentioned in the literature, but may be a cause for inadequate anesthesia in some small percentage of cases.

82

20

DTIC ELECTE
MAR 22 1982
S H

ADA 112309
DTIC FILE COPY

UNCLASSIFIED

SECURITY CLASSIFICATION OF THIS PAGE (When Data Entered)

A bifid mandibular nerve as a possible cause of
anesthetic deficiency in the mandible

P.S. Grover, DMD*

Lewis Lorton, DDS, MSD*

*Division of Clinical Operations, U. S. Army Institute of Dental Research,
Walter Reed Army Medical Center, Washington, DC 20012

Corresponding Author:

CPT Pushpinder Grover
Division of Clinical Operations
US Army Institute of Dental Research
Walter Reed Army Medical Center
Washington, DC 20012

MILITARY DISCLAIMER

The opinions expressed herein are those of the authors and are not to be construed as those of the Department of the Army or the Department of Defense.

Copyright Statement

This article was written as part of the authors' official duties as United States Government employees; therefore there is no transferable copyright to the article. As a United States government work, the article cannot be copyrighted. It is freely available to you for publication without restrictions on your use of it, now or subsequently.



Accession For	
NTIS GRA&I	<input checked="" type="checkbox"/>
DTIC TAB	<input type="checkbox"/>
Unannounced	<input type="checkbox"/>
Justification	
By _____	
Distribution/	
Availability Codes	
Dist _____ or	
Dist _____	
A	

INTRODUCTORY SUMMARY

The failure to achieve complete mandibular anesthesia is a problem that occurs in as high as 20% of all cases.⁶ The explanations vary from faulty anesthetic solutions to faulty technique, to anatomic or physiologic variations. Accessory nerve innervation from the mylohyoid nerve or the contra-lateral mental nerve has also been suggested. Bifurcation of the mandibular nerve is rarely mentioned in the literature, but may be a cause for inadequate anesthesia in some small percentage of cases.

INTRODUCTION

Pain control is an essential requirement for most dental procedures. The problem of inadequate anesthesia is often encountered during attempts at inferior alveolar nerve block. A radiographic image of the mandibular canal usually is readily seen on a panoramic radiograph. A periapical radiograph of the second molar area may show a part of the canal's image. This canal usually appears as a horizontal linear radiolucent band with definite borders of two radiopaque lines.^{1,2}

The traditional method of achieving anesthesia in the mandible is with a block of the mandibular branch of the trigeminal nerve before it enters the mandible just posterior to the lingula.⁴ Some attention has been paid to anatomic variation and the possible role of branches from the mylohyoid nerve.⁵ Variations in innervation due to innervation from the posterior-superior alveolar, auricula-temporal, or lingual branches of the temporomandibular nerve or the facial nerve have also been cited.^{3,4,6} One source⁷ reported the aberrant retro-molar branch of the mandibular nerve which may innervate the mandibular third molar. Various additional injection sites have been suggested: buccal or sublingual injections,⁵ alternate block techniques,^{8,9} and periodontal ligament injections.¹⁰

Slight attention has focused on the possibility of a bifid mandibular nerve and the possible consequences of an inferior second mandibular foramen. This may not be anesthetized by traditional block or auxiliary injection techniques.

Nortje *et al.*¹² conducted a panoramic radiographic survey of 3,612 patients and concluded that there are three different patterns of duplication or division of the mandibular canal. They reported that such bifurcation occurred in 33 individuals (0.9 percent). Twenty cases were bilateral bifurcations and 13 were unilateral.

Mandibular canals are usually bilaterally symmetrical.⁶ On occasions a bifurcation may exist and can be recognized by a panoramic radiograph. This report reviews the incidence of bifurcation of the inferior alveolar nerve and presents four cases seen during a routine panoramic radiographic survey.

MATERIAL AND METHOD

A panoramic radiographic survey of 5,000 U. S. Army recruits, age 17-26, was taken to determine their oral health status.¹⁵ Four cases, highly suggestive of bifurcation of the inferior alveolar nerves, were noticed (an incidence of 0.08 percent). These four cases included one case where bifurcation seems to be bilateral.

CASE 1:

An 18-year-old male came to the dental clinic for the treatment of pericoronary infection around third molars. History of prior dental treatment was absent. A panoramic radiograph revealed bifurcation of the right inferior alveolar nerve ascending at the mandibular foramen. Two distinct radiolucent lines outlined by radiopacities can be seen on the panoramic radiograph (Fig. 1).

CASE 2:

A 22-year-old male was seen for routine care. A panoramic radiograph revealed bifurcation of the left inferior alveolar nerve. The superior division seen to bifurcate at a midpoint of the body of the ramus. Patient's history of anesthesia during dental treatment was inconclusive (Fig. II).

CASE 3:

A 20-year-old male presented at the clinic for treatment of pericoronal infection around the third molars. A panoramic radiograph revealed a radiolucency on left ascending ramus highly suggestive of bifurcation of inferior alveolar nerve. In this case, the inferior branch seems to further bifurcate posterior-inferior to the third molar roots (Fig. III). No history of anesthetic difficulty was given.

CASE 4:

A 19-year-old male came into the dental clinic for a routine checkup. A panoramic radiograph revealed radiolucency indicative of bifid nerves in both rami nerves. No attempt was made to establish any relation between this occurrence and profoundness of anesthesia (Fig. IV).

DISCUSSION

Patterson and Funke¹³ reported on case of bifid inferior alveolar canal and pointed out that the dental literature including standard anatomy texts have little information on the incidence of such a rare entity. According to Nortje,¹² this is, after all, not a rare finding.

Sutton,¹⁴ in his study, pointed out the practical significance of mandibular accessory foramina. He conducted his study on 300 human mandibles employing various techniques, such as dissection, radiographic interpretation, and histological examination to demonstrate the presence of a number of accessory foramina containing nerve fibers. Certain pathological conditions of the mandible and their possible influence on the radiographic appearance of the inferior dental canal have been reported by Farman.¹⁶ However, neither of the studies^{14,15} encountered the bifid inferior alveolar nerve.

Various modified techniques have been reported to obtain inferior alveolar nerve block claiming high success rate.^{8,9} Even a supplemental periodontal ligament injection¹⁰ has been suggested to achieve adequate pulpal anesthesia in addition to standard injection. Some anatomical and physiological causes of failure to achieve mandibular analgesia has been discussed.¹¹ But little information is available on failure to achieve profound anesthesia due to bifurcation of inferior alveolar nerve by a routine block.

Mandibular canals are usually bilaterally symmetrical. On occasions a bifurcation may exist that can easily be recognized by a panoramic radiography.^{12,15} This report indicated an incidence of 0.08 percent that seemed very low as compared to Nortje's observation

In situations where bifid canals are recognized and the possibility of a second, more inferiorly placed foramen exists, alternate sites for placement of the anesthetic solution should be considered if routine

attempts to achieve total anesthesia are not successful. In cases where a second mandibular foramen is possibly present, deposition of the anesthetic solution inferiorly to the normal anatomic landmarks may provide more complete anesthesia.

REFERENCES

1. Kerr, D.A.; Ash, M.M.; and Millard, D.H. Oral Diagnosis, ed 5. St. Louis, The C.V. Mosby Company, 1979, p 273
2. Wood, K.N., and Goaz, P.W. Differential Diagnosis of Oral Lesions, ed 2. St. Louis, The C.V. Mosby Company, 1980, p 294.
3. Jorgensen, N.B., and Hayden, J. Sedation - Local and General Anesthesia in Dentistry, ed 3. Philadelphia, Lea & Febiger, 1980, p 222.
4. Monheim, L.M. Local Anesthesia and Pain Control in Dental Practice, ed 4. St. Louis, The C.V. Mosby Company, 1969, pp 103-122.
5. Frommer, J. *et al.* The possible role of the mylohyoid nerve in mandibular posterior tooth sensation. JADA 85(6):113-117, 1972.
6. Rood, J.P. The analgesia and innervation of mandibular teeth. Brit. Dent. J. 140:237-238, 1976.
7. Schejtman, R. *et al.* The origin and distribution of the elements of the human mandibular retromolar canal. Arch Oral Biol. 12: 1261-1267, 1967.
8. Gustainis, J.F., and Peterson, J.L. An alternative method of mandibular nerve block. JADA 103(7):33-36, 1981.
9. Levy, T.P. An assessment of the Gow-Gates mandibular block for third molar surgery. JADA 103(7):37-41, 1981.
10. Walton, R.E., and Abbott, B.J. Periodontal ligament injection: a clinical evaluation. JADA 103(10):571-575, 1981.
11. Rood, J.P. Some anatomical and physiological causes of failure to achieve mandibular analgesia. Brit. J. of Oral Surg. 15:75-82, 1978.

12. Nortje, C.J.; Farman, A.G.; and Grotepass, F.W. Variation in the normal anatomy of the inferior dental (mandibular) canal: a retrospective study of panoramic radiographs from 3612 routine dental patients. *Brit. J. of Oral Surg.* 15:55-63, 1973.
13. Patterson, J.E., and Funke, F.W. Bifids inferior alveolar canal. *Oral Surg* 36:287-288, 1973.
14. Sutton, R.N. The practical significance of mandibular accessory foramina. *Aust. Dent. J.* 6:167-173, 1974.
15. Grover, P.S.; Carpenter, W.M.; and Allen, G.W. A panoramic radiographic survey of 5,000 U.S. Army Recruits. *J. Mil. Med.* (in print), 1982.
16. Farman, A.G.; Nortje, C J.; and Grotepass, F.W. Pathological conditions of the mandible: their effect on the radiographic appearance of the inferior dental canal. *Brit. J. Oral Surg.* 15: 64-75, 1977.

LEGEND

- Figure 1 Bifurcation of the right inferior alveolar nerve.
- Figure 2 A bifid left inferior alveolar nerve and its bifurcated superior division.
- Figure 3 The bifurcation of the inferior division of the left inferior alveolar nerve.
- Figure 4 Bilateral bifurcation of the inferior alveolar nerves.

DATE
ILME
—8