


**NAVAL SUBMARINE MEDICAL  
RESEARCH LABORATORY  
SUBMARINE BASE, GROTON, CONN.**



**REPORT NUMBER 1022**

**ECG INTERPRETATION TRAINING PROGRAM  
REFERENCE MANUAL**

by

**LT Steven F. OSBORNE, MC, USNR**


and

**Karen D. FISHERKELLER, M.A.**

**Naval Medical Research and Development Command  
Research Work Unit M0095PN-001-1025**

**Released by:**

**W. C. MILROY, CAPT, MC, USN  
Commanding Officer  
Naval Submarine Medical Research Laboratory  
8 May 1984**



ECG INTERPRETATION TRAINING PROGRAM  
REFERENCE MANUAL

by

LT Steven F. OSBORNE, MC, USNR

and


Karen D. FISHERKELLER, M.A.

NAVAL SUBMARINE MEDICAL RESEARCH LABORATORY

Report Number 1022

Naval Medical Research and Development Command  
Research Work Unit M0095PN.001-1045

Approved and Released by:



W. C. MILROY, CAPT, MC, USN  
Commanding Officer

Naval Submarine Medical Research Laboratory

## SUMMARY PAGE

### THE PROBLEM

To provide a reference manual and documentation for the Electrocardiogram (ECG) Interpretation Training Tape developed under work unit #63706N - M0095PN.001-1045.

### FINDINGS

Presentation is made of the desirability of generating electrocardiographic data in the evaluation of chest pain syndromes. A description of the ECG Interpretation Training Tape is given along with instructions for usage.

### APPLICATION

Use of the ECG Interpretation Training Tape will provide submarine Hospital Corpsmen with a general understanding of an ECG and enable them to assess a computer-read ECG for accuracy.

### ADMINISTRATIVE INFORMATION

This report was submitted for review in March 1984 and approved for publication in April 1984. It is designated as NAVSUBMEDRSCHLAB Report Number 1022.

PUBLISHED BY THE NAVAL SUBMARINE MEDICAL RESEARCH LABORATORY

## Abstract

Medical evacuation from a patrolling nuclear submarine is costly in terms of risk to the patient, the expense of evacuation, and the compromise to the submarine's mission. The medical responsibilities are borne by an Independent Duty (8402) Corpsman who must independently diagnose and manage any serious illnesses which present during patrol. This includes making recommendations regarding evacuation to a shore-based facility. His diagnostic task is complicated by mission constraints which often prevent communication with shore-based medical facilities and by the limited medical diagnostic facilities aboard nuclear submarines.

Chest pain is the second or third most common presentation of serious illness aboard ship, being clearly outnumbered only by abdominal pain cases. In the course of developing a system to assist in the diagnosis of chest pain syndromes, it became clear that ECG data was necessary. An attempt to pattern a system after the at-sea abdominal pain diagnostic system demonstrated inadequate efficacy. The chest pain diagnostic system is being re-evaluated using ECG data as an integral component. A breakthrough in technology has led to the development of a compact, three-channel ECG recorder which interacts by computer with the strip. Wide availability and demand for this recorder is anticipated. It is desirable that the submarine Hospital Corpsman be able to scan and (if necessary) overread the strip and computer-reading. To this end, an Electrocardiogram Interpretation Training Tape has been developed and distributed prior to delivery of a complete chest pain diagnostic system.

This manual will be utilized by the staff of the Naval Submarine Medical Research Laboratory, by individual submarine group and squadron medical personnel, and by the staff of the Naval Undersea Medical Institute in training the corpsmen who will utilize the ECG recorder. While the manual and the tape may be used independently, it is desirable that they be used as a unit. After an appropriate period of study of the manual, the user interacts with the tape. Repeated usage will reinforce the understanding of basic ECG parameters.

TABLE OF CONTENTS

SECTION I	INTRODUCTION .....	1
SECTION II	OUTLINE OF THE ECG INTERPRETATION .....	2
	TRAINING MODULE	
	- brief discussion of ECG's	
	- format and contents of tape	
	- the overlay	
SECTION III	COMPUTER INTERACTION .....	3
APPENDIX 1	DESCRIPTION OF METHOD OF TRANSFER .....	A1
	OF ECG FROM SOURCE TO COMPUTER TAPE	
APPENDIX 2	ABSTRACT OF LCDR R. LUCE'S MANUAL: .....	B1
	"EKG BASICS FOR SUBMARINE CORPSMEN"	

# ECG INTERPRETATION TRAINING PROGRAM - REFERENCE MANUAL

## I. INTRODUCTION

A. Medical evacuation from a patrolling nuclear submarine is costly in terms of risk to the patient, the expense of evacuation, and the compromise to the submarine's mission. The medical responsibilities are borne by an Independent Duty (8402) Corpsman who must independently diagnose and manage any serious illnesses which present during patrol. This includes making recommendations regarding evacuation to a shore-based facility. His diagnostic task is complicated by mission constraints which often prevent communication with shore-based medical facilities and by the limited medical diagnostic facilities aboard nuclear submarines. The Naval Submarine Medical Research Laboratory (NSMRL) is tasked with, among other things, developing techniques that assist the corpsman in his diagnostic task.

Chest pain syndromes are the second or third most common presentation of serious illness aboard ship, being clearly outnumbered only by abdominal pain cases. The electrocardiogram (ECG), chest roentgenogram (CXR), and cardiac enzyme determinations are commonly used in shore-based evaluation of chest pain, yet these tests are not available aboard submarines.

The Naval Submarine Medical Research Laboratory attempted to pattern a chest pain diagnostic system after the at-sea abdominal pain diagnostic system. The dependence on history and physical exam data alone proved inadequate in chest pain evaluation. About the time that it became clear the ECG data was necessary, a move to place ECG capability aboard submarines gained momentum. Thus, the chest pain diagnostic system is being re-evaluated using ECG data as an integral component.

A breakthrough in technology has led to the development of a compact, three-channel ECG recorder with computer interpretation of the strip. Ship-to-shore transfer will be possible. Wide availability and demand for this recorder is anticipated. In the event that ship-to-shore communication is unfeasible, it is desirable that the corpsman be able to scan for accuracy and, if necessary, overread the computer-read ECG strip. To this end, an Electrocardiogram Interpretation Training Tape has been developed. It is being distributed prior to delivery of a complete chest pain diagnostic system because such system is still under development using ECG data.

Using the Tektronix 4051 desktop microcomputer and 4631 hard copy unit already aboard nuclear submarines, this training tape will familiarize the user with basic ECG parameters and with the recognition of common arrhythmias. A discussion of the ECG findings and how they relate to various illnesses will be presented with the forthcoming diagnostic system.

An excellent manual describing the basics of ECG interpretation was written by LCDR R. Luce, MC, USN, and approved by the Naval Undersea Medical Institute in 1982. With permission, it has been abstracted and presented in Appendix 2 for those who do not have a copy. It should be read and understood prior to use of this tape and prior to running an ECG strip. Details concerning the method of determination of axis can be found in any standard text.

B. While this manual and the accompanying computer tape may be used independently, it is desirable that they be used as a unit. After an appropriate period of study, the user interacts with the tape. Repeated usage will foster an understanding of the basic ECG parameters.

An optimal plan for using the system would involve a four-tiered approach, as follows:

1. Six hours of study of a basic ECG text in a classroom setting led by a medical officer in in-service training classes.
2. One hour of study of this manual by all potential users.
3. A one hour sit down session of using the computer tape to disclose any problems the user may have in understanding the training system. Questions about the system to be answered through consultation with the manual and supervising medical officer.
4. Repeated usage in any areas of weakness (i.e., Arrhythmia Anne for arrhythmia detection; three-channel unknowns for parameters).

If the plan outlined above, or a reasonable substitute, is implemented, then the corpsman will be well-equipped to take an ECG in evaluating a case of chest pain. Some submarines already have ECG recorders aboard with the trend growing. NSMRL foresees the ideal situation of a complete chest pain diagnostic system using a history, physical exam, and computer-read, three-channel ECG tracing. If ship-to-shore communication is not feasible, the corpsman will be prepared.

## II. OUTLINE OF THE ECG INTERPRETATION TRAINING MODULE

A. The electrocardiogram (ECG) is a valuable aid in the diagnosis of chest pain syndromes. Recent literature (1982-83) indicates that history and physical exam alone are often inadequate to diagnose chest pain syndromes. The ECG, chest roentgenogram, and "cardiac" enzymes are routinely used in emergency rooms, with

ECG usage being most common. There are many possible abnormalities and an appreciation of the acceptable variations from normal ("normal variant") is essential to understanding the tracing obtained. Consulting the manuals that have been distributed to you prior to, and at the time a tracing is obtained, is encouraged. These training ECG strips are meant to complement, and not replace, those manuals.

With the exception of the tracings from "Arrhythmia Anne" (an electronic rhythm strip generator), all ECG's shown are from actual patients, some healthy and some ill. Bear in mind that even in a patient with evolving myocardial infarction (M.I.), the changes that take place in the heart require a finite period of time (often 4 hours or more) to be reflected in the ECG. Also, the ECG detects myocardial infarction only 90% of the time, and that ½% of the time it shows a myocardial infarction there is none present. The ECG changes in a M.I., in part, resolve over a few days to weeks (the ST segment elevation and/or T wave inversion) and, in part, persist for a lifetime (the loss of R waves and/or appearance of Q waves). While in some sense an ECG can be interpreted "in the abstract", it is best to interpret it with knowledge of the condition of the patient.

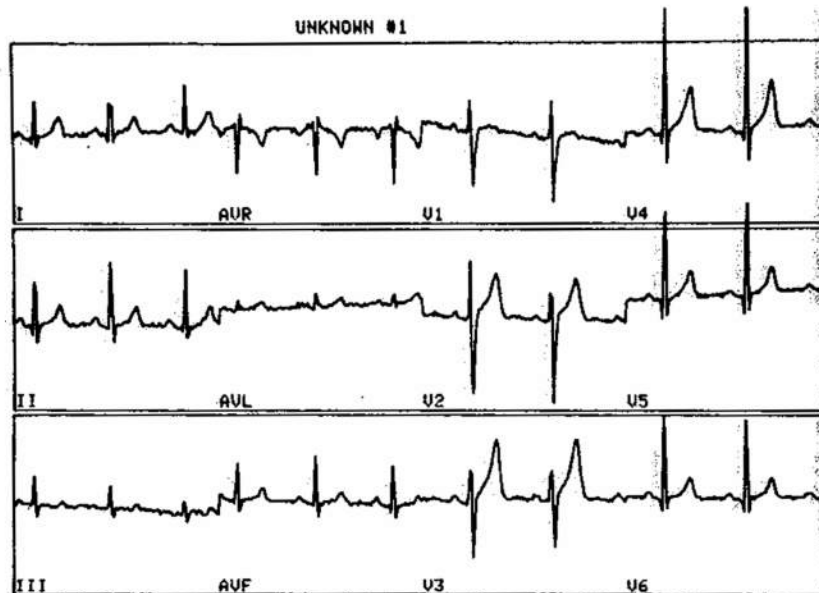
B. The ECG Interpretation Training Tape is divided into three sections. Section one is a compilation of 14 common single-channel strips identical to those of Arrhythmia Anne®, a programmed arrhythmia generator. These strips illustrate the following patterns:

1	NORMAL SINUS RHYTHM (NSR)	8	VENTRICULAR FIBRILLATION
2	1ST DEGREE HEART BLOCK	9	ASYSTOLE
3	2ND DEGREE HEART BLOCK	10	SINUS TACHYCARDIA
4	3RD DEGREE HEART BLOCK	11	NSR WITH OCCASIONAL PVC'S
5	ATRIAL FLUTTER	12	NSR WITH OCCASIONAL PAC'S
6	ATRIAL FIBRILLATION	13	SINUS BRADYCARDIA
7	VENTRICULAR TACHYCARDIA	14	NSR 60Hz INTERFERENCE

The user may access the specified arrhythmia (1-14) directly (on demand) or may have an unknown presented which he must recognize. If the unknown option is selected, the user may further opt to complete the series of fourteen recognition strips after which a score is presented.

Section Two is a compilation of 8 common three-channel, single page, recordings taken from ECG-normal subjects in a study of response to hyperbaric exposure or from patients in a hospital ICU. The greater likelihood of ECG abnormalities in these two settings prompted their selection. The ECGs are presented either on demand, (1-8) as selected, or may be presented as unknowns. The appearance of the ECG on the computer display (Figure 1) is similar to what might be expected from a live recording although there is some distortion of the QRS height and the baseline.

FIGURE 1: Three-Channel, Single-Page ECG Recording



A description of the method used for transfer of the electrical signal from the source to the computer tape is presented in Appendix 1. Refinements in this method may be possible so as to eliminate distortion of the signal baseline and height.

After the three-channel recording is presented on the computer display (Figure 1), and the hard copy unit produces a copy of the strip, the user is asked to complete a display of ECG parameters. These parameters are:


1. Heart Rate (i.e. 30-150) :
  2. Axis (i.e. -30-+120) :
  3. PR Interval (i.e. .08-.25) :
  4. QRS Interval (i.e. .06-.16) :
  5. ST Elevation (Y or N) :
  6. ST Depression (Y or N) :
  7. Q Waves (Y or N) :
  8. T Wave Inversion (Y or N) :
  9. Arrhythmia(s) (Y or N) :
  10. Overall Impression (1-3) :
- (Normal=1, Mildly Abnormal=2,  
Seriously Abnormal=3)

Evaluation of these basic parameters requires use of a graphic overlay (Figure 2) with the hard copy. Section Two should not be accessed if the overlay and hard copy are unavailable. In assessing #10, overall impression, criteria for left ventricular hypertrophy should be ignored because of inherent signal height distortion in the lateral leads. ST elevation or depression is minimally affected and can be readily and accurately assessed.

Following user input for these parameters, an overall score is presented along with a listing of incorrect entries. Numerical estimates (intervals) are "correct" if within 1 millimeter = 1 small block = 0.04 seconds or if within approximately 15% error (heart rate, axis).

The graphic overlay (Figure 2) is a duplicate of common ECG recording paper and is bonded to the enclosed plastic overlay to avoid tearing or inadvertent damage.

FIGURE 2: GRAPHIC OVERLAY



When the plastic overlay is placed atop the hard copy of the three-channel ECG, all parameters are easily assessed. The smallest blocks are 1 millimeter (mm), which is equal to 0.04 seconds when strips are run at 25 mm/sec per convention. Ten small blocks (vertical) equals one millivolt, but no evaluation should be based on voltage criteria because of the aforementioned inherent distortion of QRS height. Coordination of the sizes of the strips and the overlay, exactly as supplied, has been accomplished (see Appendix 1 for further details).

Section Three consists of an explanation of the makeup of the entire tape. The intended purpose and basic method for using the tape are described.

### III. COMPUTER INTERACTION

A. COMPUTER OPERATION - The Tektronix 4050 series desktop computer will operate smoothly if these instructions are followed:

- 1) TURN THE COPIER ON 5 to 8 minutes ahead of time if a copier is attached to the computer and its use is anticipated. This will allow sufficient warm-up time for proper copier operation.
- 2) TURN ON THE MACHINE using the rocker switch located below the right side of the console.
- 3) INSERT THE TAPE into the slot just to the right of the display screen.
- 4) PRESS THE "AUTOLOAD" KEY - this will automatically load and activate the program and bring the user to the starting point.
- 5) FOLLOW THE INSTRUCTIONS given during program operation.
- 6) ENTER RESPONSES when requested. A flashing "?" will appear where a response is requested. Simply type in the response and press the "RETURN" key to enter it. If a mistaken entry has been made, it can easily be corrected before the "RETURN" key is depressed by backspacing to the incorrect entry using the "BACKSPACE" key and typing the correct entry over the incorrect entry. If the error is noticed after the "RETURN" is keyed, the program will either not accept the entry or the correction can be easily made as will be described in number 9.
- 7) COPIES can be made of any display at any time by pressing the "MAKE COPY" key.
- 8) PROGRAM APPEARANCE - Following "AUTOLOAD", Figure 3 appears on the display screen.
- 9) COMPUTER MALFUNCTION - Press the "BREAK" key twice, then the "AUTOLOAD" key.

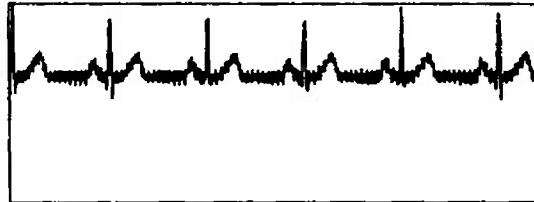
FIGURE 3: OPTIONS

DO YOU WISH TO: 1) WORK WITH ARRHYTHMIA ANNE?  
2) WORK WITH OTHER ECG UNKNOWNNS?  
3) HAVE AN EXPLANATION OF THIS TAPE?  
4) END INTERACTION?  
( ENTER 1,2,3, OR 4 )

If Arrhythmia Anne is selected, PROGRAM #2 on the computer tape is accessed and a brief description of it is given followed by an opportunity to request one of the 14 strips or an unknown (quiz format). If the quiz format is selected, the program displays a strip and ways for the user's answer. If the answer is correct (Figure 4), then "RETURN" is pressed allowing the initial options to again be selected.

FIGURE 4: CORRECT ANSWER IN ARRHYTHMIA ANNE QUIZ

- ARRHYTHMIA
- |   |                         |    |                           |
|---|-------------------------|----|---------------------------|
| 1 | NSR                     | 8  | VENTRICULAR FIBRILLATION  |
| 2 | 1ST DEGREE HEART BLOCK  | 9  | ASYSTOLE                  |
| 3 | 2ND DEGREE HEART BLOCK  | 10 | SINUS TACHYCARDIA         |
| 4 | 3RD DEGREE HEART BLOCK  | 11 | NSR WITH OCCASIONAL PAC'S |
| 5 | ATRIAL FLUTTER          | 12 | NSR WITH OCCASIONAL PAC'S |
| 6 | ATRIAL FIBRILLATION     | 13 | SINUS BRADYCARDIA         |
| 7 | VENTRICULAR TACHYCARDIA | 14 | NSR 60 HZ INTERFERENCE    |

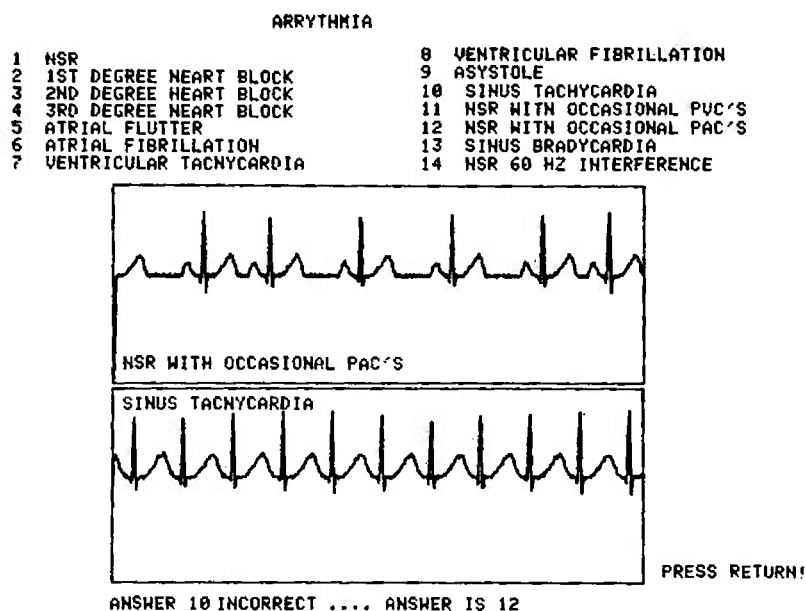


ANSWER 14 CORRECT!!!

PRESS RETURN!

If an incorrect answer is given, the computer notes this fact and supplies the correct answer. A second strip is immediately supplied corresponding to the user's answer and both strips are correctly labelled by the computer (Figure 5).

FIGURE 5: INCORRECT ANSWER IN ARRHYTHMIA ANNE



A score is provided after all 14 strips have been presented. Selection of the order of presentation of the fourteen strips is semi-random.

If the user selects option #2 from Figure 3 (WORK WITH OTHER ECG UNKNOWNNS - three channel), then PROGRAM #17 on the tape is accessed. An opportunity to have three channel recordings displayed directly (user-selected) or randomly is offered. In addition, one can return to the original menu (Figure 3) or end the interaction. If the random three channel ECG is selected, a brief set of instructions for answering the quiz questions is displayed (Figure 6).

FIGURE 6: RANDOM THREE CHANNEL UNKNOWN SELECTED

DO YOU WANT TO:           1) SELECT A PARTICULAR UNKNOWN?  
                          2) HAVE AN UNKNOWN RANDOMLY SELECTED?  
                          3) RETURN TO THE ORIGINAL MENU?  
                          4) END INTERACTION?  
                          (ENTER 1,2,3 OR 4 ): 2

FOR THE ECG UNKNOWN #1 CALCULATE THE FOLLOWING PARAMETERS AND ANSWER THE FOLLOWING QUESTIONS. INPUT YOUR RESPONSE AFTER THE PROMPTING QUESTION MARK. ALWAYS FOLLOW YOUR RESPONSE WITH A RETURN. YOU MUST BE WITHIN 0.04 SECONDS=1 MILLIMETER=1 SMALL BLOCK ON THE ECG PAPER TO BE CORRECT, OR WITHIN A 15% ERROR, WHICHEVER IS GREATER. LEADS I-III AND/OR V1-V6 ARE NORMALLY USED. FOR NON-NUMERICAL ANSWERS(YES/NO) YOU MUST GIVE THE CORRECT ANSWER. IN THIS PRELIMINARY TAPE A SIMPLE SCORING SYSTEM HAS BEEN DEvised. BE PERSISTENT AND YOU WILL IMPROVE YOUR TECHNIQUE. IF YOU FIND AN ERROR LET NSMRL KNOW!

PRESS RETURN TO CONTINUE

Then the computer selects and displays a three channel recording (Figure 1) and a copy is automatically made. The ECG immediately disappears from the computer display. This discourages any attempt to interpret complex strips "from a distance" and mandates that a paper copy and the overlay be utilized.

A set of questions is then displayed (Figure 7) with prompting for answers supplied. There are certainly minor variations in some of the intervals and other parameters from lead to lead so it is suggested that leads I-III and V<sub>1</sub>-V<sub>6</sub> be "averaged" by the user. The approximately 15% permitted error should minimize user disagreement with the assigned "correct" answers.

FIGURE 7: QUESTIONS CONCERNING THE THREE-CHANNEL ECG

TYPE YOUR ANSWER AND FOLLOW WITH RETURN

1. HEART RATE (i.e. 30-150) :
2. AXIS (i.e. -30-+120) :
3. PR INTERVAL (i.e. .08-.25) :
4. QRS INTERVAL (i.e. .06-.16) :
5. ST ELEVATION ( Y OR N ) :
6. ST DEPRESSION ( Y OR N ) :
7. Q WAVES ( Y OR N ) :
8. T WAVE INVERSION ( Y OR N ) :
9. ARRHYTHMIA(S) ( Y OR N ) :
10. OVERALL IMPRESSION ( 1-3 ) :  
( NORMAL=1, MILDLY ABNORMAL=2,  
SERIOUSLY ABNORMAL=3)

A score is given following input of answers with incorrect items shown (Figure 8). A special screen display is presented for a perfect score. Following the score, the user can continue with Program 17 options or return to the original menu (Figure 3).

FIGURE 8: INCORRECT ITEMS SHOWN FOR THREE-CHANNEL ECG QUIZ

YOU SCORED 80% OR 8 OF TEN. THE INCORRECT ITEMS ARE THE NUMBERS SHOWN BELOW:

1--HEART RATE

4--QRS INTERVAL


PRESS RETURN TO CONTINUE

#### ACKNOWLEDGEMENTS

The authors wish to thank George Moeller, Ph.D. for advice and editorial comment; HMC(SS) D. G. Johansen and HM3 M. M. Speckhahn for technical assistance; LCDR K. St.Andre, MC, USN, and LT P. G. Gray, MC, USNR, for review; and E. M. Perkins for manuscript preparation. The Intensive Care Unit Staff at the Naval Hospital Groton, CT, assisted in the collection of data. Douglas Wray outlined the method of transfer of ECG data from source to computer display and provided bioengineering support.

#### BIBLIOGRAPHY

1. Braunwald, E., Cohn, P. F., Ross, R. S.: Ischemic Heart Disease, chapter 144 in Harrison's Principles of Internal Medicine, 9th Edition, McGraw-Hill, 1980.
2. Luce, R. F.: EKG Basics for Submarine Corpsmen. Naval Undersea Medical Institute, 1982.
3. Dubin, D.: Rapid Interpretation of EKG's, 3rd Edition, Cover Publishing Company, 1982.
4. Friedman, H. H.: Outline of Electrocardiography, McGraw-Hill, 1963.



APPENDIX 1. DESCRIPTION OF METHOD OF TRANSFER OF ECG FROM SOURCE TO COMPUTER TAPES.

Electrocardiograms were taken on patients in a Naval Hospital Intensive Care Unit or on healthy subjects in a Navy hyperbaric chamber. In the latter instance, subjects were under pressure up to 5 atmospheres absolute. All electrocardiograms were taken on a Marquette Electronics 3100 three-channel ECG recorder. The ECG signal was stored on the reel-to-reel tape of a Hewlett Packard 3964A Instrumentation Recorder, which was connected via cable to the ECG recorder. This recorder has 4 channel input/output capability and a "counter" permitting the location of each ECG on the reel-to-reel tape to be noted by voice input or numerical designation.

The reel-to-reel tape was later placed in a separate (identical) 3964A Instrumentation Recorder for playback. This recorder was connected to a Tektronix R5103N oscilloscope and an analog-to-digital converter (A to D converter). The analog-to-digital converter was an AMS unit or a TransEra 752-ADC and was, in turn, connected via cable, or cable and ROM pack, to a Tektronix 4051 or 4052 desktop microcomputer.

When the recorded ECG signal is played back, its typical three-channel appearance is viewed on the oscilloscope and fed to the A-to-D converter. An NSMRL in-house software package instructs the microcomputer to accept the digital output when the user directs. The user makes this designation based upon the appearance of the signal on the oscilloscope. In this manner, any areas between ECGs or areas of poor signal can be bypassed.

There is a limited amount of data that can be fed through the A-to-D converter during any one data transfer session. In general, this was a 10-13 second period. Since a typical ECG may last 30 seconds, the computer program dictating digital signal acquisition was run several times per ECG to obtain the entire strip. Each section of an ECG had to be stored on a computer magnetic tape prior to acquisition of the next section. This process "cleared" the computer memory bank.

The computer program directing digital signal acquisition also displayed the ECG in graphic form on the Tektronix 4051 or 4052 display screen. The integrity of the transfer could be monitored in this manner. Each data acquisition period led to one "page" of stored data.


The speed at which the recorded ECG was played back through the Instrumentation Recorder was varied to achieve the best signal transfer. Too rapid a playback caused the A-to-D converter to "miss" some of the analog data presented to it. This led to QRS peak "cut off" and a non-uniform appearance. Additionally, there was an enlarging effect when the ECG was displayed on the screen.

Following storage of the (usually) three "page" ECG, a separate in-house software program formed a user-directed collage of the best sections of each "page." These "best sections" were assessed from a hard copy printout of each page using the Tektronix 4631 Hardcopy machine attached via cable to the microcomputer. The resultant single-page three channel ECG is thus a collage of the original ECG and is itself then stored on the computer magnetic tape. A separate software program directs playback of the ECG from the computer tape.


When compared to the original ECG on the patient/subject, the tracing obtained from the computer tape is quite similar. If occasional QRS peak truncation and tall QRS peaks in the V leads are ignored, the overall ECG reading is the same. All interval segment characteristics are reproduced nicely. It should be noted that all leads in a vertical column are simultaneous as on the original ECG (i.e., I-III, AvR-AvL, V1-V3). Because of the collage nature of the reproduced strip, there may be several seconds between each vertical grouping of leads. For example, AvR-AvL while simultaneous, may have been acquired seconds after Leads I-III instead of immediately afterwards. This is no impediment to reading the ECG. It is possible to demonstrate rhythm strips by the methods above, if desired.

Besides development of sample ECGs for viewing on the Tektronix microcomputer onboard nuclear submarines, additional applications can be envisioned from these methods. For example, a patient aboard ship could be connected via standard ECG leads to an A-to-D converter (measuring 6"x9"x2"), which in turn is connected to the Tektronix microcomputer. With appropriate software, an ECG could be displayed in the format described and a hardcopy could be printed and the ECG stored on magnetic tape (if desired). A very small ECG recorder would, of course, serve the same purpose yet such a small recorder is not yet on the market. If a computer program providing simple interpretations and requiring minimal (<64,000 bytes) memory were available, the methods described herein would allow immediate computer interpretation of the strip.

EKG BASICS  
for  
SUBMARINE CORPSMEN



NAVAL UNDERSEA MEDICAL INSTITUTE  
NSHS BETHE SDA DETATCHMENT  
NAVAL SUBMARINE BASE NEW LONDON  
GROTON, CONNECTICUT, 06349



APPENDIX 2





TABLE OF CONTENTS

Title Page.....	i
Abstract.....	ii
Summary.....	iii
Section I: Introduction.....	pg.I-1
Section II: EKG Theory.....	pg.II-1 thru 6
Section III: Patient Preparation: Obtaining.. The EKG	pg.III-1 thru 5
Section IV: Approach to Interpretation..... of the EKG	pg.IV-1 thru 11
Section V: The Arrhythmias.....	pg.V-1 thru 10
Section VI: Changes of the EKG With..... Myocardial Infarction	pg.VI-1 thru 3
Section VII: Suggestions For Further Study...	pg.VII-1
Bibliography/References.....	iv
Enclosure #1: Operator's Manual for the..... Cambridge VS-550 Single Channel Electrocardiograph	56 pages
Enclosure #2: NUMI guidelines For Treatment of.. MI on Deployed Submarines	6 pages



EKG BASICS FOR SUBMARINE CORPSMEN

by RONDA F LUCE LT. MC USN

1982

## ABSTRACT


This paper is designed specifically to introduce the submarine corpsman to the onboard use and interpretation of the electrocardiogram. Topics included are theory of operation, actual instruction on preparing the patient, assembly of equipment, basic interpretation of EKGs, arrhythmias and changes indicative of myocardial infarction. This brief coverage is not intended to be all inclusive. The purpose is to introduce those corpsmen who will be receiving this machine in its basic use and interpretation, to make them aware of its capabilities, and to help them in learning to master this new onboard diagnostic procedure.

## SUMMARY

Currently, portable twelve lead electrocardiographic (EKG) monitors are being introduced to the submarine force for use by the submarine corpsman while underway. While some MDRs will be fully familiar with EKGs, the majority will have had little or no training in this field. Certainly for any corpsman who has been with the submarine force for any length of time, this is a little used topic, much in need of review.

Despite the plan to have telemetric capability for the fully developed model, the current machine does not have this option. Even when all units do have the capability of sending the EKG tracing via radio to a waiting MD for interpretation, this would only be a "best case" scenario. The submarine corpsman and his supporting physicians are all too aware that an underway submarine faces multiple situations - meteorological, tactical and mechanical - when rapid outside assistance is simply not available. Even in the "best case" the corpsman must be capable of setting up the equipment and obtaining an acceptable tracing. In the case of an evolving MI, the necessary delays in obtaining a reading from a medical officer could be life threatening. Therefore it is necessary for the corpsmen who will be using these machines to be familiar with the basics of EKG monitoring and interpretation.

The following pages are an attempt to help the MDR obtain this basic understanding necessary to use the EKG effectively in the care of his patients.



## INTRODUCTION


Electrocardiographic capability has technically been available to submarine corpsmen for several years. In March of 1970 a Naval Submarine Medical Center paper was published detailing the procedure for converting a Tektronic 545-A oscilloscope into a passable twelve lead EKG. The author, LT. M.A. Prosin, MC USN, had actually performed this feat while underway on a SSBN cruise. His efforts were prompted by the occurrence of a myocardial infarction among the crew. Subsequent attempts by other individuals have proved less successful. To the best of this author's knowledge, no other individual has been able to duplicate Dr. Prosin's success. Subsequent attempts to adapt other oscilloscopes have also proven fruitless.

Recently, Dr. R.D. Tanksley closely studied the need for EKG capability aboard submarines and also the possibility of using the new miniature EKG monitors during deployment. His work cited a clear ongoing need for the EKG, both in avoiding unnecessary MEDEVACS for the improper diagnosis of cardiac problems, and to aid in the more timely evacuation and appropriate care of those individuals who had indeed suffered myocardial infarctions.

Subsequently a portable Ekg monitor has been selected for trial use aboard submarines. The machine currently being studied is the Cambridge VS-550 single channel electrocardiograph. ( Enclosure 1 is the Operator's manual) This machine is currently undergoing modification by the company to provide for telemetric capability. Field testing of the basic model is currently in progress. The ultimate goal is to have every submarine with onboard EKG machines capable of sending a tracing to a shore based facility for rapid interpretation.

It is to be hoped that by thus making use of the EKG a readily available option, that its use will indeed be effective in reducing unnecessary MEDEVACS and aiding care of cardiac cases. However, no corpsman is going to use a piece of diagnostic equipment he either does not know how to operate, or can't interpret its results. Unless the corpsman feels comfortable obtaining a tracing, then relying in the results obtained, the machine will never be unpacked.

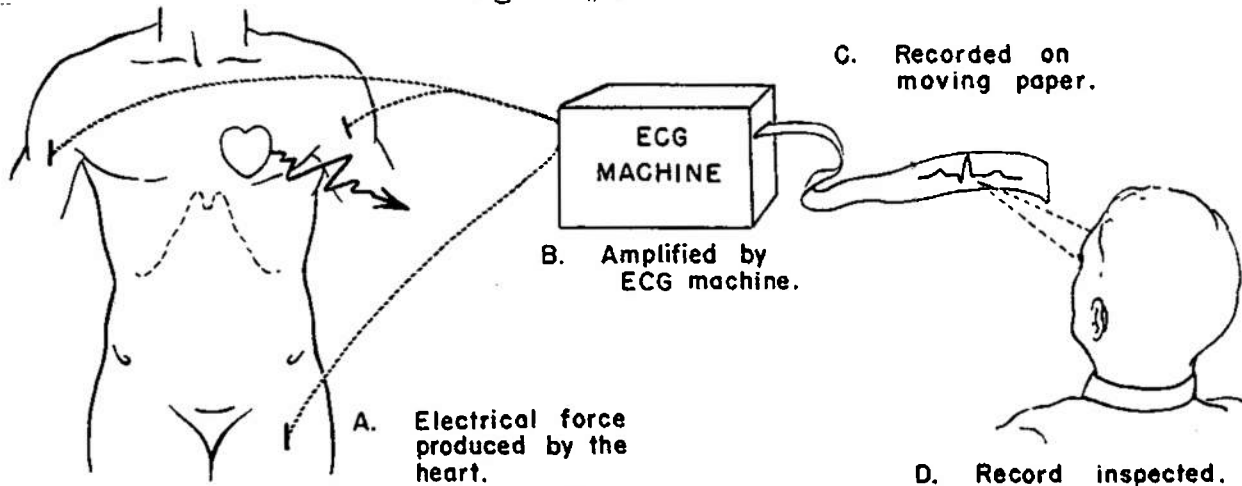
This paper is written to familiarize the MDR with this particular EKG machine and to impart the basics of interpreting the tracings obtained. It is not intended to make them experts. The goal is to impart basic understanding and to debunk the opinion that reading EKGs is the job of cardiologists alone.



## EKG THEORY

The electrocardiogram is simply a graphic representation of the electrical activity of the heart. This very small amount of electrical energy, approximately one millivolt, is detected by the EKG machine, amplified, then recorded on a moving piece of paper. ( fig. #1 )


figure #1



Each individual heart muscle cell will "beat", or contract on its own. The coordination of all the cells in the heart results in the efficient flow of blood through the heart to the rest of the body. The EKG is the summation of these cells' electrical activity. Most cells in the heart behave like a stretched spring held by a trigger. When some outside force releases the trigger the cell contracts then immediately resets itself. The "firing" phase is called depolarization, and the "reset" phase repolarization. This entire process is achieved by the cells ionic components creating an electrical charge. The stimulus received is normally from another cell's depolarization.

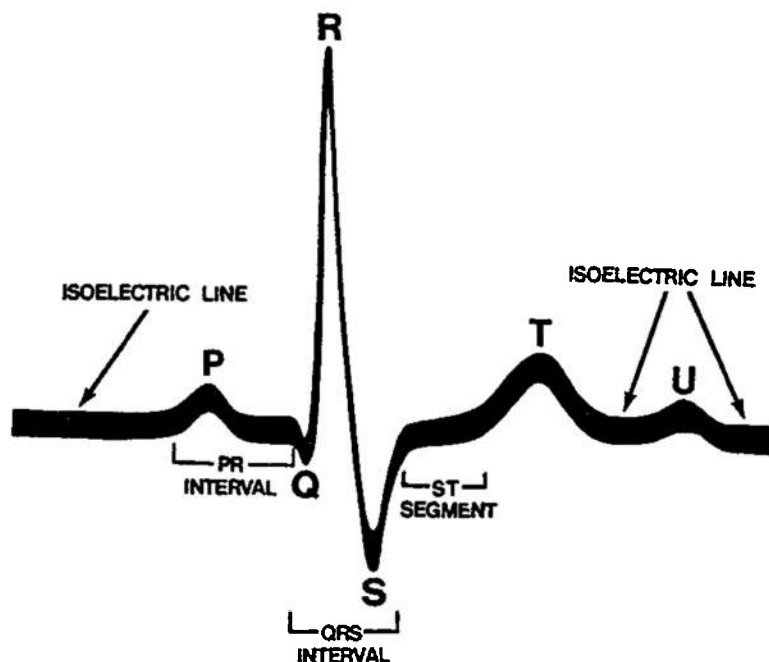
Certain cells of the heart have the ability to "fire" or depolarize on their own. They depolarize at a fixed rate. Obviously the faster cells will "drive" the rest of the heart by triggering first and thus stimulating the remaining cells.

The normal pacemaker of the heart is the SINOATRIAL (SA) NODE. Its cells have the fastest automatic firing. This area, located in the right atrium, fires and the surrounding cells of the right and left atria are stimulated to contract. The atria take a relatively long period of time to contract because they have no specialized conduction system. The ventricles however have a well developed system. The atrial firing gradually reaches the ATRIOVENTRICULAR (AV) NODE situated at the top of the ventricular septum. This node acts primarily to slow the impulse, giving the atria time to completely contract and empty. The cells of the ventricular conduction system are specially developed muscle cells which carry the impulse to the ventricles in a rapid and almost simultaneous manner. Thus the ventricular contraction is a well coordinated and powerful event.



The normal EKG tracing is the place to start. Now that the hows and whys are clear, how does this tracing actually look? Figure #3 shows the basic landmarks.

figure #3



P WAVE : The P wave represents the depolarization of the atria.

QRS COMPLEX : The QRS represents the depolarization of the ventricles. The repolarization of the atria also occurs during this time, but is overwhelmed by the more powerful ventricular activity and does not register as a separate event.

THE Q WAVE : The Q wave is the first downward deflection of the QRS complex.

THE R WAVE : The R wave is the first upward component of the QRS complex.

THE S WAVE : The S wave is the first downward deflection of the QRS following the R wave.

THE R' WAVE : The R prime wave is the second upward deflection of the QRS wave, frequently absent.

QS COMPLEX : A qrs complex with no upward deflection. The entire complex is below the isoelectric line.

THE T WAVE : The T wave represents repolarization of the ventricles.

THE U WAVE : Seldom seen. Thought to represent late repolarization of the Purkinje system.

INTERVALS : The spaces between the landmarks are also important.

THE PQ or PR INTERVAL : This interval represents the time required for the electrical impulse to travel thru the atria and the delay in the AV node. The length of this interval varies with age and heart rate. ( see table 1 ) This interval is measured from where the first deflection of the P wave begins to the start of the Q, or R if the Q is absent.

Table #1

Rate	Below 70	71-90	91-110	111-130	Above 130
Large adults .....	0.21	0.20	0.19	0.18	0.17
Small adults .....	0.20	0.19	0.18	0.17	0.16
Children, ages 14-17 .....	0.19	0.18	0.17	0.16	0.15
Children, ages 7-13 .....	0.18	0.17	0.16	0.15	0.14
Children, ages 1½-6 .....	0.17	0.165	0.155	0.145	0.135
Children, ages 0-1½ .....	0.16	0.15	0.145	0.135	0.125

Upper limits of normal PR interval (seconds)

THE QRS INTERVAL: The length of time for ventricular depolarization. This is measured from the first deflection of the QRS from baseline to its final return to baseline. The normal QRS should not exceed .10 second.

THE QT INTERVAL: Measured from the beginning of the QRS to the end of the T wave. This interval also varies with age, sex and heart rate. (see Table #2 )

THE ST SEGMENT: That portion of the tracing from the end of the QRS to the beginning of the T wave. This segment is especially important in myocardial infarction.

Measuring the height and length of these various components and intervals is made possible by the characteristics of the EKG machine and the tracing paper.(fig.#4)

The smallest squares are 1 mm. per side. The paper moves at 2.5 cm per second, thus each small square equals 0.04 seconds. ( 1 second 25 spaces= .04 sec. per space ) Each fifth line is slightly darker and represents 0.20 seconds.(5 x .04= .2 ) The vertical scale is calibrated such that each small square equals one tenth of a millivolt. By convention an upward deflection indicates positive voltage and a downward deflection negative voltage.

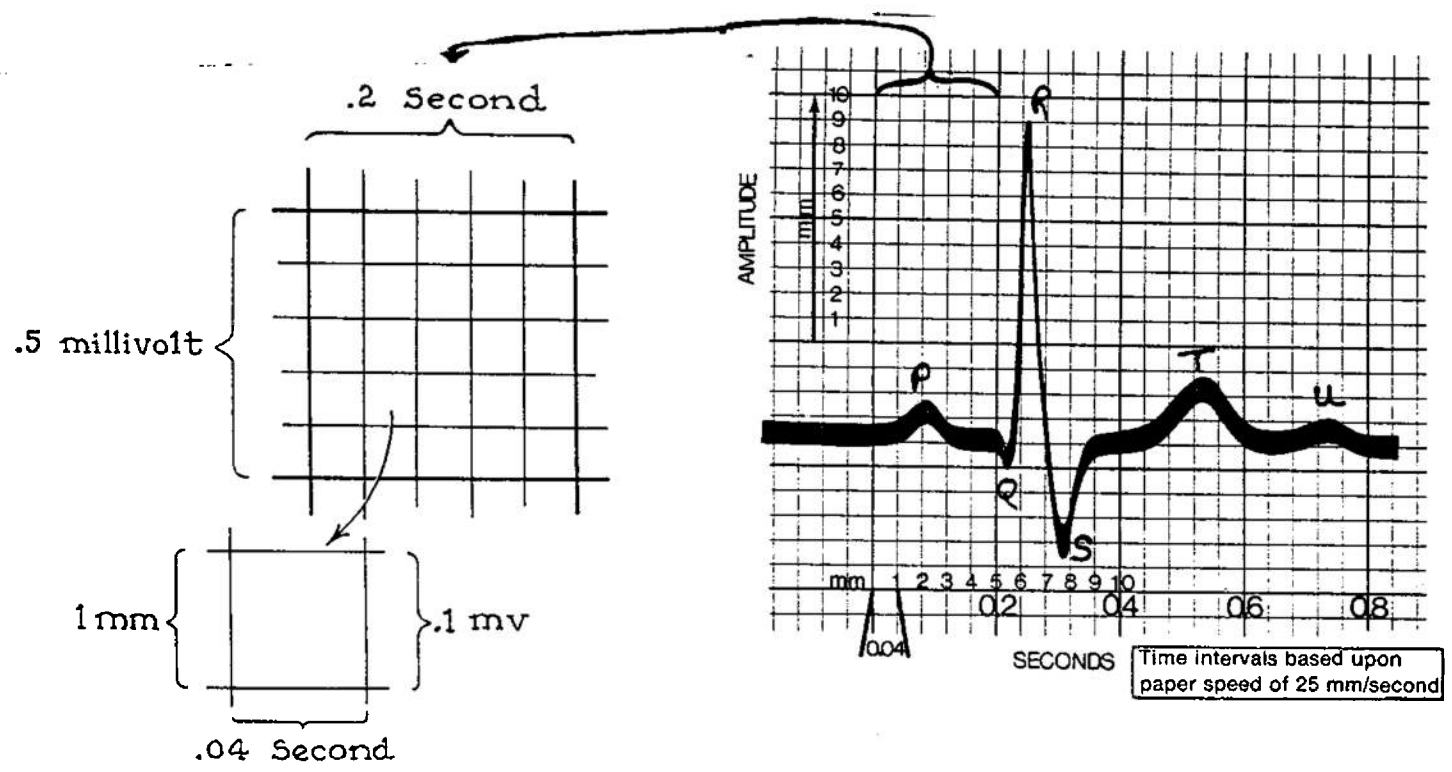
Using these guidelines length and size of intervals and deflections may be measured accurately directly from the EKG.

Table #2

Cycle lengths, sec.	Heart rate per min.			Upper limits of normal	
		Men and children, sec.	Women, sec.	Men and children, sec.	Women, sec.
1.50	40.0	0.449	0.461	0.491	0.503
1.40	43.0	0.438	0.450	0.479	0.491
1.30	46.0	0.426	0.438	0.466	0.478
1.25	48.0	0.420	0.432	0.460	0.471
1.20	50.0	0.414	0.425	0.453	0.464
1.15	52.0	0.407	0.418	0.445	0.456
1.10	54.5	0.400	0.411	0.438	0.449
1.05	57.0	0.393	0.404	0.430	0.441
1.00	60.0	0.386	0.396	0.422	0.432
0.95	63.0	0.378	0.388	0.413	0.423
0.90	66.5	0.370	0.380	0.404	0.414
0.85	70.5	0.361	0.371	0.395	0.405
0.80	75.0	0.352	0.362	0.384	0.394
0.75	80.0	0.342	0.352	0.374	0.384
0.70	86.0	0.332	0.341	0.363	0.372
0.65	92.0	0.321	0.330	0.351	0.360
0.60	100.0	0.310	0.318	0.338	0.347
0.55	109.0	0.297	0.305	0.325	0.333
0.50	120.0	0.283	0.291	0.310	0.317
0.45	133.0	0.268	0.276	0.294	0.301
0.40	150.0	0.252	0.258	0.275	0.282
0.35	172.0	0.234	0.240	0.255	0.262

Normal QT intervals and upper limits of normal

Figure #4



## SECTION II

Being able to identify and measure accurately the various landmarks and intervals is the foundation of EKG interpretation. Learning to easily recognise the landmarks is only achieved with practice. There should be several EKG tracings among the medical records aboard. Studying and comparing these (hopefully) normal Ekg tracings will give you some familiarity with the landmarks. Try to go thru a few, picking out first the QRS, its the only pointed one!, then the P and T waves. Notice how they will vary from lead to lead and differ between individuals.

Further sections will detail more specifically what to be looking for in each of these to indicate abnormality. Knowing a normal tracing when you see it can be more difficult than an obvious abnormality.

PATIENT PREPARATION : OBTAINING THE EKG

In order to have Ekg information which is of any use whatsoever, the operator must first correctly assemble the machine and then obtain a technically acceptable tracing.

As insurance against loss during shipment, a copy of the Operator's Manual for the VS-550 electrocardiograph machine is included as Enclosure I. When details are available on the telemetric model, they will also be included.

The basic Cambridge model is very simple to assemble and operate. Thoroughly read the operator's manual before assembly. This machine when properly used gives excellent tracings.

Practice with the machine is the only way to gain proficiency. The touch controls and automatic or manual options on this model make it very flexible. Inserting the paper and adjusting the stilus are the only tricky items, follow the directions!

Once assembled and running, the only hitch with operating the Ekg is attaching the leads properly. The ultimate goal is to obtain a twelve lead electrocardiogram. This consists of two parts. First the six standard LIMB LEADS :

<u>NAME</u>	<u>SYMBOL</u>	<u>MACHINE MARKING</u>
one	I	-
two	II	--
three	III	---
(just say	aVr	---
letters)	aVl	--- --
	aVf	--- -- --

The machine automatically marks the paper with the appropriate dot/dash code for the lead being recorded.

The wires are both letter and color coded to aide in proper placement on the patient:

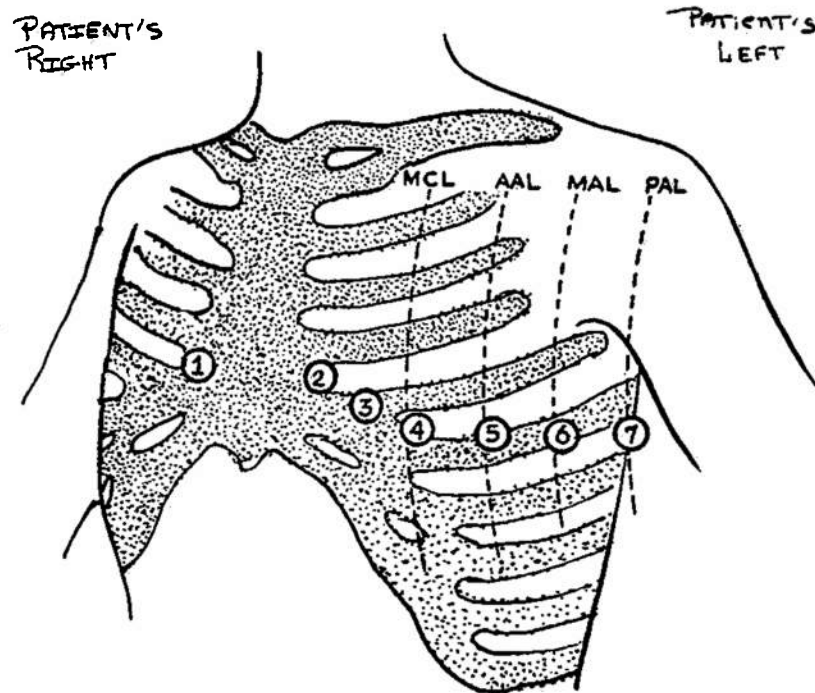
<u>COLOR</u>	<u>POSITION</u>	<u>LABEL ON LEAD</u>
Red	left leg	LL
Green	right leg	RL
White	right arm	RA
Black	left arm	LA

This can be easily remembered via the brief memmonic: "Christmas on the bottom, green and white on the right". Interpretation: the red and green leads go to the legs, with green on the right. The black and white leads go to the arms, with white on the right arm.

Apply the leads to the ankles and wrists. EKG paste should be used to enhance the reception of the monitor. Alcohol pads

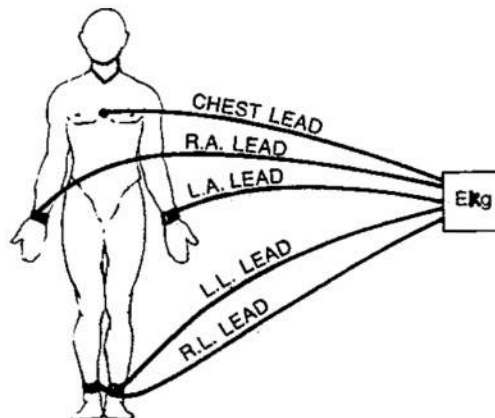
also work very well and are less messy. If neither are available, surgical lubricant with a little table salt added is an excellent substitute. The leads should be strapped on snug, but not so tight as to impede circulation. Try to get the lead on as flat an area as possible to maximize surface contact. The last lead attached is a chest lead. This is color coded brown, has a suction cup attachment and is labeled C. It should be attached in the V-1 position. (See fig.#1) This chest lead acts as a ground during the first phase of the tracing. The final arrangement should resemble figure #2.

figure #1



MCL = mid-clavicular line  
 AAL = anterior axillary line  
 MAL = mid-axillary line  
 PAL = posterior axillary line

figure #2



Once the leads are properly attached you are ready to record. First ascertain that the machine is calibrated properly. The sensitivity should be set at 10mm/mV and the chart speed at 25 mm per second. The frequency response should be 100Hz. Set the stylus position. This may need to be reset later in the V leads. You may elect to run the monitor manually. If so, obtain the leads in the standard order : I,II,III, AVR,AVL,AVF. Using the manual mode allows you to obtain longer strips of a particular lead if so desired. On auto, the machine will only monitor each lead for 2.8 seconds before advancing.

After you obtain all of the six limb leads, go on to the V leads, also called the precordial leads. Placement for these is shown in figure #1 . There are six standard V leads, but additional leads may be placed further around the body.

V1 : Placed in the fourth intercostal space just to the right of the sternum. Finding this spot is all important. First, with the patient flat on his back and the chest fully exposed, palpate the suprasternal notch. This is the very top of the sternum, just between the medial ends of the clavicles or collar bones. From this point palpate down the sternum onto the chest. About one third of the distance to the xiphoid there is a transverse bump across the sternum, marking the point of fusion of the two upper components. This ridge is called the Angle of Louis. In some people it is very obvious, in others very difficult to locate. Once you have found it, move laterally to the nearest intercostal space. This should be space #2, between the second and third ribs. Move down two more spaces to #4 and here is where V1 should be placed. To help, in most men this space is just above the nipple line. Place the lead about one cm. to the right of the sternum. (REMEMBER, its always the PATIENT'S right or left!)

V2 : Fourth intercostal space ,about one cm out from the sternum on the left.

V3 : Midpoint on a line connecting V2 and V4. Therefore do V4 first !

V4 : Fifth intercostal space in the mid-clavicular line. This is usually just below the patient's left nipple.

V5 : At the same level as V4 but on the anterior axillary line.

V6 : At the same level as V4 on the mid-axillary line.

Patient position should be absolutely flat. If position is otherwise, so note. Usually the V leads are attached one at a time and moved for each reading i.e., attach at V1 site, record, advance to V2, record etc. Thus it is often helpful to find the spots before hand and mark them with a felt tip marker. This is especially helpful if you are going to be doing serial tracings.

Another hint, very hairy chests make for very poor suction cup attachment. You may be able to get the cup to stay on long enough with copious amounts of electrode paste. Sometimes gently holding the lead in place will give decent results. If all fails, especially if you need to do serial studies, just shave off the hair over the sites.

To reduce background noise and artifact, have the patient flat, breathing shallow and quiet. That means no talking or moving. Do not have him touching anything metal. Minimize all operation of electrical equipment in the immediate area.

In some cases a rhythm strip is helpful. This is merely a long tracing of a single lead, usually lead II, but any lead in which all of the landmarks are easily identified.

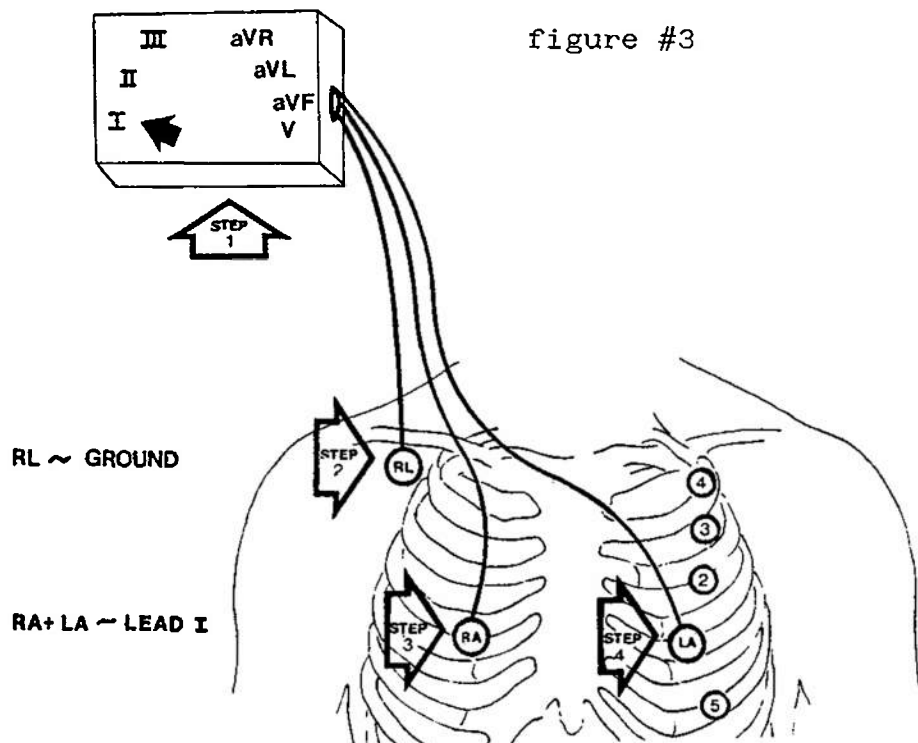
To avoid confusion, label the tracing obtained with the patient's name, date, time and any other additional comments, such as "Taken during episode of chest pain."

Save the tracings obtained for a formal reading once in port. If you MEDEVAC, send the tracings with the patient.

Again, PRACTICE this procedure. It is really very simple. Accurate tracings are obtainable with a little experience. In the midst of an emergency is no time to be unpacking your machine for the first time.

ADDENDUM: If the patient requires frequent monitoring, it may be more convenient to place electrodes in the "ideal Monitoring" position. This allows freedom of the limbs and gives a good tracing. This is particularly useful with oscilloscope or constant monitoring systems, but is adaptable to intermittent monitoring with this model. REMEMBER you do not have constant monitoring capability.

Figure#3 illustrates this procedure.



First set the machine to monitor lead I. Attach the RL (green) lead to the right side of the anterior chest or arm. Placement is not critical as this is the ground line. With the flat contacts this would best be achieved by taping the contact plate to the patient. If stick-on contacts are available use them.

Next attach the RA (white) lead to the right of the patient's sternum, approximately in the V1 position.

Now take the LA (black) lead and move it over the patient's left anterior chest until a good tracing is obtained. Once a satisfactory site is obtained, attach the electrode.

This method is frequently used for constant monitoring in intensive care units, ambulances, operating rooms, etc. The tracing obtained is NOT equivalent to any of the standard leads, but still allows the observer to look for any acute changes or arrhythmias.



APPROACH TO INTERPRETATION OF THE EKG

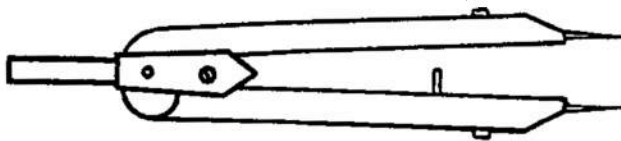
Experts who read EKG's daily seem to be able at a glance to interpret even the most complex tracing. Theirs is an ability earned by years of experience. The less experienced observer gains the best results by approaching the EKG in a systematic fashion.

A suggested method of interpretation is to identify or measure all of the following in this order:

1. Determine the rate
2. Determine the rhythm
3. Identify all landmarks
4. Measure the intervals
5. Note all observations of abnormalities
6. Last, based on the above, make a presumptive diagnosis

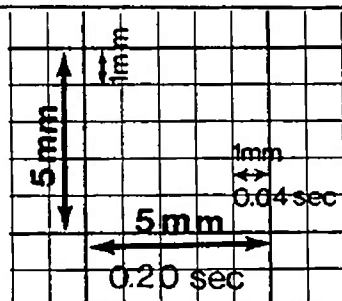
Useful aides, but not absolute necessities, are a pen or pencil, 3x5 cards, calipers (figure #1 ) and a quiet place. The last will be the only difficult item to obtain.

fig.#1



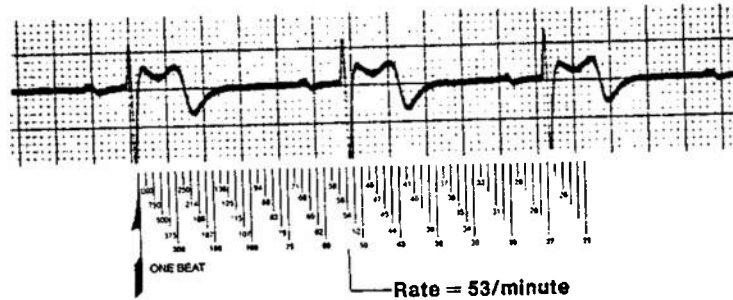
1. Determine the Rate : This refers to the heart rate, i.e. how many beats per minute. Due to the time calibration of the paper, (Fig.#2) there are several methods for using the EKG to determine rate.

fig#2



Various "rulers" are available commercially which allow the reader to quickly and accurately determine the rate by measuring the distance between two or more landmarks. These rulers can often be found in the standard texts, medical bookstores or on drug company representatives. (Fig.#3)

fig.#3



The Grid Method is another rate determining system. This counts the number of large blocks between two beats. (table 1) Normal rates have from five to three large blocks between beats. Often it is easier to measure the distance between two beats with a pair of calipers and transfer this reading to the paper. When measuring, always use the same landmark. The peak of the QRS is usually easiest. If the landmarks do not fall directly on the whole number of large blocks, extrapolation is necessary. ( i.e. 4 1/2 blocks = 67 )

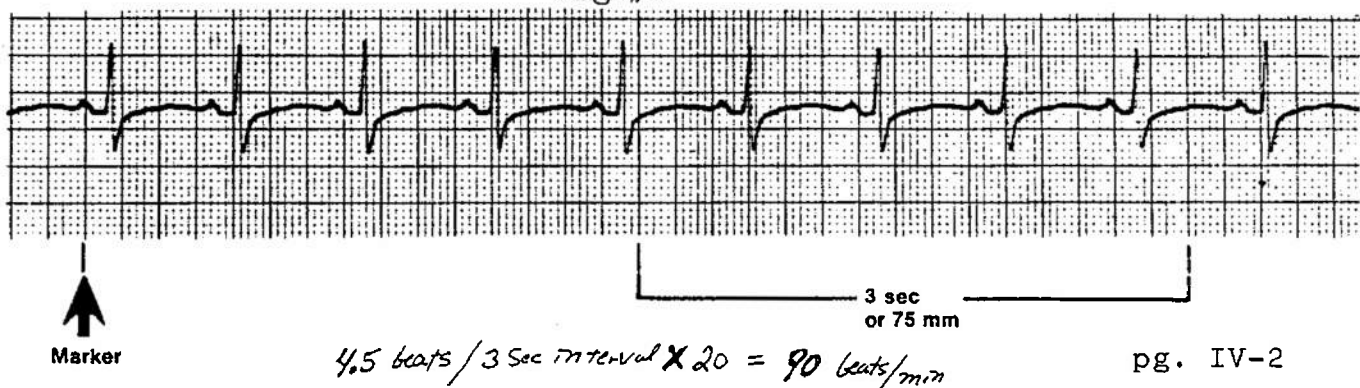
Table 1

Number of Large Squares	Interval Between Beats	Rate Per Minute
1	0.2 sec	300
2	0.4 sec	150
3	0.6 sec	100
4	0.8 sec	75
5	1.0 sec	60
6	1.2 sec	50
7	1.4 sec	43
8	1.6 sec	37
9	1.8 sec	33
10	2.0 sec	30

} normal sinus rhythm

The scan method makes use of the three second markers found at the bottom of the EKG strip. (Fig.#4) Multiply the number of complexes per three second interval by twenty to obtain the number of beats per minute. Fractions of beats are used to improve accuracy. To obtain better results, average your calculations from three sites on the tracing.

Fig.#4




Once you have the rate, what is considered normal? Rates faster than 100 are tachycardias, rates slower than 60, bradycardias. MOST normal values are between these figures. Realize however that a heart rate of 48 may be just fine for a well conditioned athlete. Similarly, it could be fatal for an older individual. ALWAYS interpret the heart rate with the clinical picture of the patient firmly in mind.

2. Interpret the rhythm : Rhythmicity of the heart beat simply refers to the distance between beats. Do the intervals vary (irregular rhythm), or are they the same (regular rhythm)? Normally the heart beats with a regular rhythm regardless of the heart rate. Sometimes irregular rhythms also have a pattern, these are called regularly irregular, as opposed to those which have no pattern at all, irregularly irregular.

Figure #5 shows a regular rhythm. To measure and compare intervals, use the calipers. First, set the points on two adjacent identical landmarks. Again the peak of the QRS is best. Try to choose an area of the tracing where the baseline is level. The "rhythm strip" is usually the best for this, since it is a long run of a single lead, usually lead 2. Once the calipers are set, it should be possible to walk them from peak to peak without resetting them. If this is possible, then all the intervals are the same and the rhythm is regular.

fig.#5

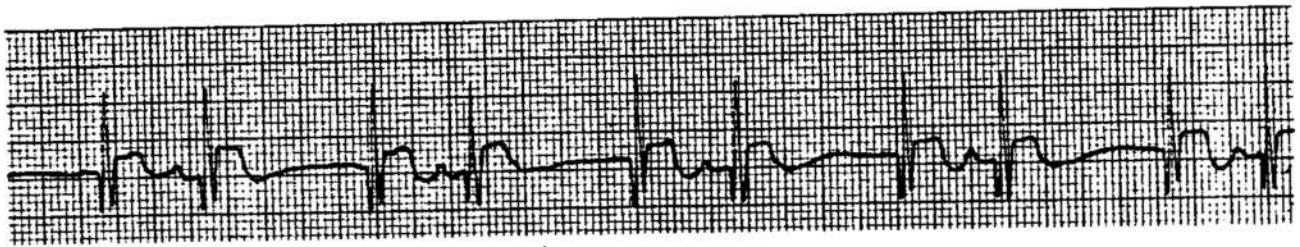


Another method of determining rhythm uses a 3X5 card. Place the card parallel to the base line and mark on it where two adjacent identical landmarks are located. Then just slide the card over one landmark and see if the next one falls on the mark.

There are normal variations from a regular rhythm. These will be addressed in the arrhythmia section.

If a tracing has an irregular rhythm, i.e. the spaces between similar landmarks are not equal, this is an arrhythmia. Some arrhythmias may have a pattern. (fig.#6) Other variations are possible and will be addressed later.

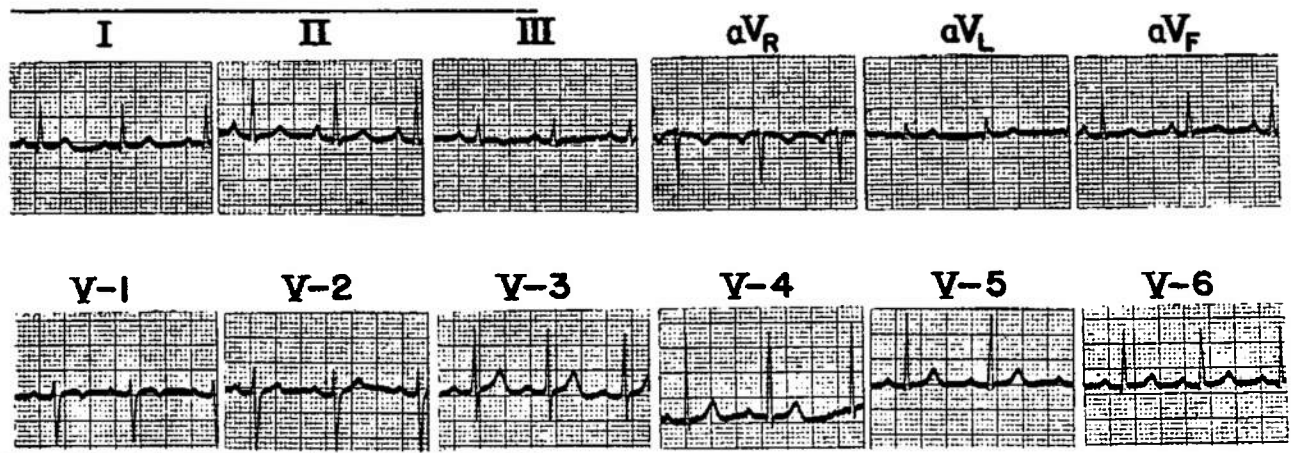
Fig.#6



AREGULARLY IRREGULAR RHYTHM

NOTE: ALWAYS MEASURE. Don't trust your eyes, its too easy to be fooled, especially with a rapid rate.

3. IDENTIFY ALL THE LANDMARKS: In each lead identify and measure all of the landmarks. (refer back to Fig.#3, Section II ) The landmarks will appear slightly different in each lead, but should still be identifiable. Some leads are better views of individual landmarks. (fig.#7)

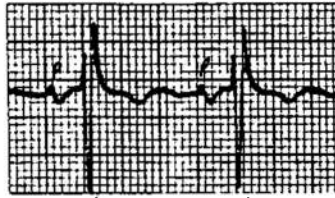


The P WAVE: A P wave should occur before every normal QRS. (fig.#8) The p waves should all look alike on the same lead, and be the same distance from each other and the QRS. P waves should only be 2 or 3 mm. in height, with a smooth contour, gently rounded, not peaked or notched. The P wave is usually upright in leads 1 and 2, but may be diphasic, both above and below the baseline, or inverted in 3. (fig. #9 & #11) P waves are normally inverted in aVr and upright in aVf. It's direction is variable in other leads, but a good general rule is the P should point the same direction as the QRS.

fig.#8

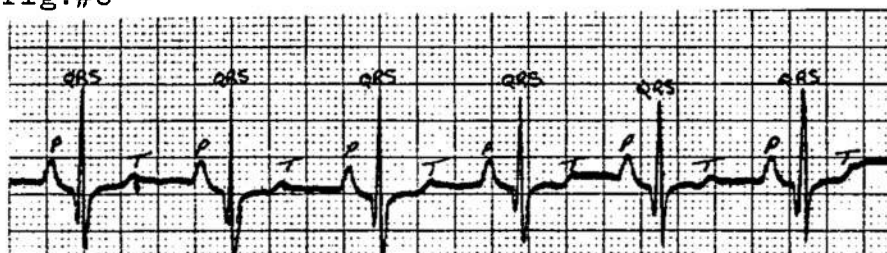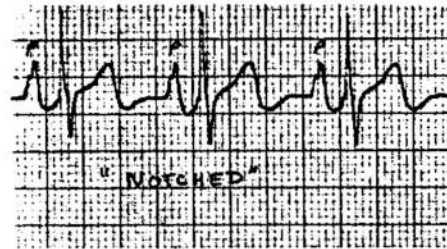


fig.#9



biphasic

fig.#10




---

P Wave Abnormalities to Observe:

A. INVERSION. The P wave is inverted from its usual position in the lead. Usually it is also opposite from the QRS. (fig.#11) The presence of an upright P wave in aVr is also abnormal. Inversion usually means there is an abnormal or ectopic pacemaker firing the heart. If available, an old EKG may show a change in the shape and direction of the P wave.

---

fig.#11

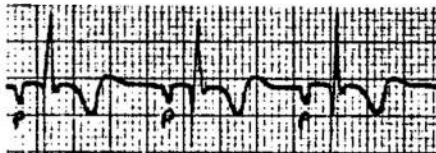

fig.#12





fig.#13



B. Increased AMPLITUDE, i.e., an abnormally tall P wave. This indicates an enlarged or dilated atrium, as found in congestive heart failure, hypertension or valvular heart disease. (fig.#12)

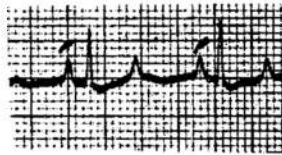
C. INCREASED WIDTH. Normally P waves are not more than 0.11 sec. in duration, less than three small boxes. Wide P waves usually indicate enlarged atria or diseased atrial muscle. (fig #13)

D. DIPHASIC WAVES. Here the second half of the P wave is negative, especially in leads 3 or V1. This usually indicates significant left atrial enlargement. (fig.#9)

E. NOTCHING. The P wave appears to have two peaks. The P wave will also appear to be wider and taller in lead 1 than lead 3. This occurs when the left atrium primarily is involved, usually due to mitral valve disease or dysfunction. (fig.#10)

F. PEAKING. The P wave is sharply pointed. Right atrial strain is the usual cause, as in pulmonary hypertension. The P waves will be taller in lead 3 than in lead 1. (fig.#14)

fig.#14



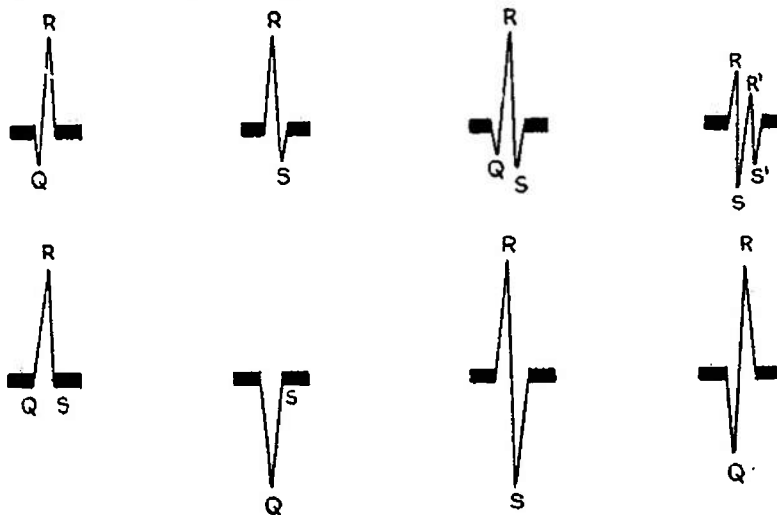
PEAKED-P WAVES

G. ABSENCE OF P WAVES: The P waves are not identifiable or missing. Usually the ventricles are firing on their own due to failure of the SA node.

THE QRS COMPLEX : This is the major landmark to be considered. The QRS represents the depolarization of the ventricles, the major working portion of the heart. Sometimes it is difficult to determine which is the Q, the R or the S. THE RULES:

- A. If the first deflection is downward, it is a Q wave.
- B. The first upward deflection is an R, whether or not it is preceded by a Q.
- C. A negative deflection following an R is an S.
- D. Subsequent excursions above the isoelectric line are labeled R', R'' ( R prime, double prime etc.)
- E. Subsequent excursions below the line are S', S'' etc..

fig.#15 Labeling the QRS

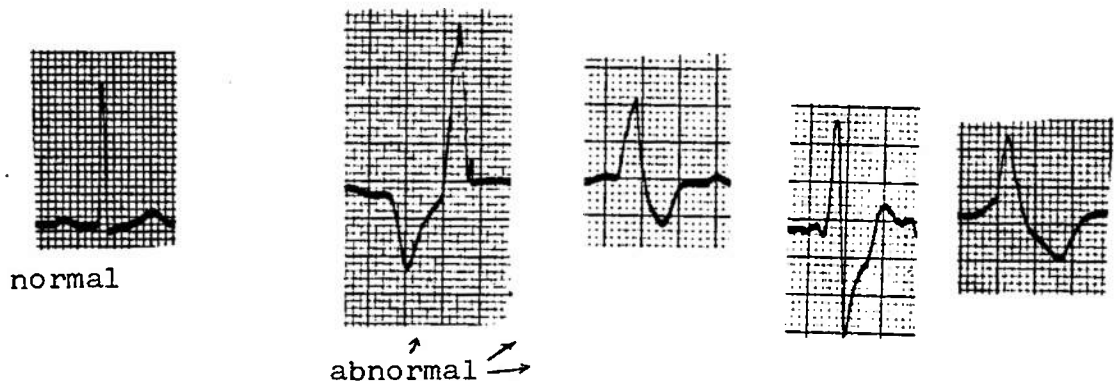


If the complex consists entirely of an upright wave (R), the points at which the complex begins and ends are labeled Q and S respectively. When the complex consists entirely of a Q wave it is referred to as a QS complex.

In interpretation of the QRS itself, several features should be examined: duration, amplitude, Q waves, and general shape. The QRS is usually from .05 to .10 seconds in duration. The duration is measured from the first deflection from baseline

to final return to baseline. The QRS is usually measured in the limb leads, and is slightly longer in the V leads. If the QRS is longer than 0.12 seconds (three small boxes) it usually indicates a problem with ventricular conduction, a Bundle Branch Block, or a ventricular arrhythmia. A good rule to follow is that the QRS should be narrow, sharp, and appear the same in on each beat within a lead. If the impulse which drives the heart comes from above the AV node, the QRS will be narrow and appear normal. If the impulse arises below the AV node, the QRS complex will be wide, with smoothed contours and look markedly different from a normal QRS. (fig. #16)

fig. #16



Amplitude of the QRS has wide parameters. The lower limit is usually placed at 5mm. If below 5mm. in all three of the standard leads ( I, II, & III) it is abnormal. This is called "low voltage" and may be caused by many factors: wrong sensitivity setting on the machine, diffuse coronary disease, cardiac failure, pericardial effusion, obesity, emphysema, and generalized edema. Either the heart itself is sending out a weak signal or there is something interfering with the signal transmission.

Upper limits vary, but generally if the total height exceeds 25mm. (5 large boxes) in any of the limb leads it is considered abnormal. Very thin people may have very large QRS complexes; there is simply very little to dampen the signal. Cardiac causes are topped by left ventricular hypertrophy, there is a lot of signal being produced.

Q waves occur normally in leads I, aVl, aVf, V5 and V6. Their presence in other leads, especially if wide or tall, may indicate an old or recovering myocardial infarct. Be sure to correlate with the patient's condition and medical history. An old EKG for comparison can be invaluable here.

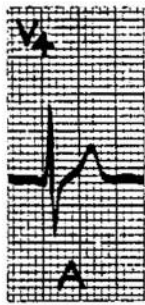**T-WAVE** : This wave represents the repolarization of the ventricles. Three important items should be noted: direction, shape and height. The T wave is normally upright in leads I, II, and V3 to V6. It is usually inverted in aVr and variable in all other leads.

The shape of the T is usually slightly rounded and assymetrical. Notched or peaked T waves should be closely examined, although they can be found normally in healthy

individuals. Notched Twaves are quite common and benign in children. In adults they may indicate pericarditis. A sharply pointed T wave may be indicative of a myocardial infarct.

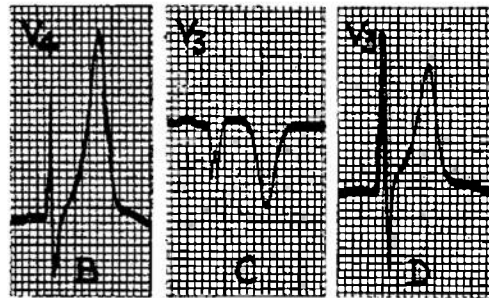
T waves are normally 5mm. or less in height in the limb leads and 10mm. or less in the V leads. Markedly tall Ts may indicate myocardial infarction or elevated serum potassium levels. A good thing to remember if you are adding some KCL to intravenous solutions. (fig.#17)

fig.#17



normal

abnormal:



angina

MI

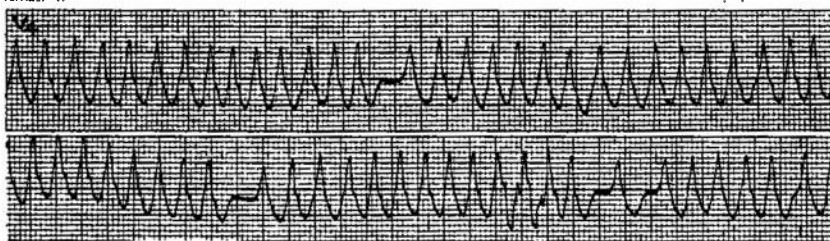
MI

4. MEASURE THE INTERVALS : The time between cardiac events is also crucial. Again, carefully measure these, don't trust your vision.

The following intervals should be measured and closely examined: P-R interval, S-T segment, and the Q-T duration.

- A. The P-R Interval is measured from the start of the P wave to the start of the QRS. It represents the time taken for the electrical impulse from the SA node to travel through the atrium, the AV node, the Bundle of His, the Purkinje System, and at last to fire the ventricles. It is usually 0.12 to 0.20 seconds. Customarily, several intervals are measured and the longest is taken as the measurement. Prolongation of the PR for more than 0.20 sec. is most often indicative of latent Rheumatic or coronary disease effecting the heart's conduction system. Digitalis will also delay the conduction and prolong the PR interval. This slowing of the electrical impulse is called atrioventricular block, abbreviated AV block. Isolated prolonged PR intervals are found in a very small percentage of normal young men. A good clue is to stand the patient up and obtain a standing tracing. The PR will often return to normal in the normal variant.

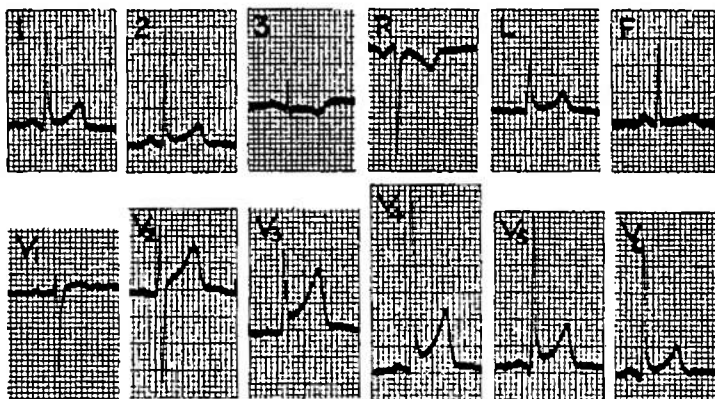
Short PR intervals occur when the impulse arises lower in the conduction system, and in the Wolf-Parkinson-White Syndrome. WPW is a purely electrocardiographic diagnosis. Associated cardiac illnesses are idiopathic hypertrophic subaortic stenosis, and atrial arrhythmias. Because WPW also has markedly widened QRS complexes, a rapid arrhythmia may mimic ventricular tachycardia. (fig.#18)



WPW at a rapid rate, mimics ventricular tachycardia

**B. THE S-T SEGMENT :** This is the portion of the tracing immediately following the QRS complex. It begins where the S returns to the baseline. This starting or junctional point is called the J point. The ST segment should be closely examined for both its shape and whether it is level with the baseline. Usually the ST is on the same level as the TP segment, ie. is isoelectric. The ST segment may be slightly elevated or depressed, but not more than 0.5mm. A normal variation of this occurs in young black males. The ST segment is slurred, as if the S never returned to baseline, but just flowed directly into the T wave. This is especially prominent in the V leads, up to 4mm. and closely mimics the ST elevation associated with myocardial infarct (section VI). (fig.#19). Again, carefully interpret the findings with the clinical picture firmly in mind.

fig.#19



ST slurring in a healthy 29 y.o. Black man mimics ST elevation of acute MI

**C. QT DURATION:** Measured from the beginning of the QRS to the end of the T wave. This is a highly variable measurement. Normal values are obtained via the Ashman tables. ( table#2) The QT should roughly equal slightly less than half of the preceding R-R interval. This approximation fails with rapid or slow heart rates.

The QT can be effected by several conditions. A longer than normal QT may indicate congestive heart failure, MI, hypocalcemia, or toxicity from quinidine, procaine amide, or phenothiazines. Sometimes diffuse myocarditis , such as with rheumatic heart disease, may prolong the QT.

table #2

TABLE 2  
Normal Q-T Intervals and the Upper Limits of the Normal

Heart Rate per Minute	Men and Children		Upper Limits of the Normal	
	Men and Children	Women	Upper Limits of the Normal	
			Men and children	Women
	sec.	sec.	sec.	sec.
40.0	0.449	0.461	0.491	0.503
43.0	0.438	0.450	0.479	0.491
46.0	0.426	0.438	0.466	0.478
48.0	0.420	0.432	0.460	0.471
50.0	0.414	0.425	0.453	0.464
52.0	0.407	0.418	0.445	0.456
54.5	0.400	0.411	0.438	0.449
57.0	0.393	0.404	0.430	0.441
60.0	0.386	0.396	0.422	0.432
63.0	0.378	0.388	0.413	0.423
66.5	0.370	0.380	0.404	0.414
70.5	0.361	0.371	0.395	0.405
75.0	0.352	0.362	0.384	0.394
80.0	0.342	0.352	0.374	0.384
86.0	0.332	0.341	0.363	0.372
92.5	0.321	0.330	0.351	0.360
100.0	0.310	0.318	0.338	0.347
109.0	0.297	0.305	0.325	0.333
120.0	0.283	0.291	0.310	0.317
133.0	0.268	0.276	0.294	0.301
150.0	0.252	0.258	0.275	0.282
172.0	0.234	0.240	0.255	0.262

A shortened QT may indicate hypercalcemia, hyperkalemia or Digitalis toxicity.

The QT by itself is not a highly useful interval because of its variability.

##### 5. Observation of Abnormalities: and

6. Diagnosis of findings are the natural follow on to your careful analysis of the EKG tracing. The last page of this section is a form for keeping track of all your findings. It covers all of the areas that should be studied and helps to organize the work. Write your observations as you do each part, that way there will be no guesswork. With all the data at your disposal, you are ready to analyze your findings.

First, is this a normal or abnormal tracing? If you have found no abnormalities, its normal! If abnormal, you need to further clarify the situation. Are any of the findings diagnostic of particular causes? There have been mentioned several changes and their probable causes, there are many more. Try to look for a common cause for a group of findings. Also stick to the SIMPLEST common cause. For instance, an EKG with an irregular rhythm, tachycardia and elevated ST segments is far more likely to be indicative of an MI than a misfiring pacemaker in a young Black man who is hyperthyroidic.

CORRELATE CLINICAL FINDINGS.

If an arrhythmia is present, diagnosis of its nature can be particularly helpful. SECTION V deals with this topic.

1. Patient Profile:

Name: \_\_\_\_\_ SSN: \_\_\_\_\_  
Age: \_\_\_\_\_ Ht: \_\_\_\_\_ Wt: \_\_\_\_\_ Build: \_\_\_\_\_  
Sex: \_\_\_\_\_  
Medications: \_\_\_\_\_

2. Brief Clinical Synopsis:

\_\_\_\_\_  
 \_\_\_\_\_  
 \_\_\_\_\_

3. EKG FINDINGS (normal values in parenthesis)

Rate: (60-100) \_\_\_\_\_  
Rhythm: Regular, sinus \_\_\_\_\_ Regular, Irregular \_\_\_\_\_  
 Irregular, irregular \_\_\_\_\_  
P Wave: One before every QRS? \_\_\_\_\_  
 Configuration: normal \_\_\_\_\_ abnormal \_\_\_\_\_  
 More than one shape? \_\_\_\_\_ Peaked \_\_\_\_\_ Notched \_\_\_\_\_  
 Upright in I \_\_\_\_\_ II \_\_\_\_\_ aVf \_\_\_\_\_ (all normal)  
 Inverted or Diphasic in aVr \_\_\_\_\_ (normal)  
 In same direction as QRS \_\_\_\_\_ Hieght \_\_\_\_\_ (2-3mm.)  
 Width \_\_\_\_\_ (max .11 sec.)  
QRS: Shape: sharp \_\_\_\_\_ narrow \_\_\_\_\_ widened \_\_\_\_\_  
 Duration \_\_\_\_\_ (.05-.10 sec.) Hieght \_\_\_\_\_ (5mm.-25mm.)  
 Abnormal Q waves \_\_\_\_\_ (nl. in I, II, V3-V6)  
T Wave: Shape: (smooth, assymetric) \_\_\_\_\_ Notched \_\_\_\_\_  
 Peaked \_\_\_\_\_ Hieght \_\_\_\_\_ (5mm less in limb, 10mm. in V)  
 In same direction as QRS? \_\_\_\_\_  
ST Segment: Isoelectric: \_\_\_\_\_ (only .5mm. variance allowed)  
 Elevated: \_\_\_\_\_ Depressed: \_\_\_\_\_  
PR Interval : (.12-.20) \_\_\_\_\_  
QT Interval : (see table) \_\_\_\_\_

4. List of Abnormalities Noted:

\_\_\_\_\_  
 \_\_\_\_\_  
 \_\_\_\_\_  
 \_\_\_\_\_

5. List of Differential Diagnosis:

\_\_\_\_\_  
 \_\_\_\_\_  
 \_\_\_\_\_



THE ARRHYTHMIAS

If you have analyzed the tracing and found that the heart rhythm is irregular, or too fast or too slow, there is an arrhythmia present. In diagnosing the various arrhythmias and their causes, the EKG is absolutely essential. Without it only educated guesses are possible. (fig.#1)

fig.#1	Atrial Rate	Ventricular Rate	Vagal Response	Notes
Sinus Tachycardia	100-160	same	gradual	
P.A.T.	150-200	same	+or-	
Atrial Flutter	40-300	2:1,3:1,4:1	by	
Atrial Fibrillation	>300	irregular	gradual	
Atrial Tach.with Block	>200	variable	gradual	Dig. Tox.
Multifocal Atrial Tachy.	foci.	Variable	gradual	COPD
Ventricular Tach.	-	100	0	poorly tolerated

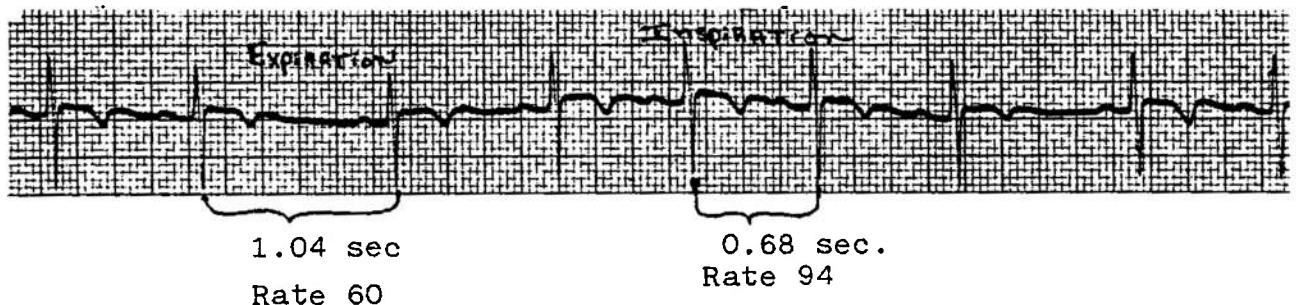
Arrhythmia analysis without EKG

In addressing the arrhythmias, the approach will be anatomical. First the atrial, then the ventricular rhythms. There are several other methods, regular vs irregular, rapid vs slow etc. be aware of this when seeking out other sources of information. The arrhythmias are the same, just the format in changed.

1. Atrial Arrhythmias:

A. Sinus arrhythmia: This is a normal finding in many children and young adults. All of the landmarks appear perfectly normal. The heart rate simply varies with respiration, so that the intervals between beats will vary, giving an irregular rhythm. The best way to see this is to obtain a long rhythm strip and observe the patient's breathing as the strip runs. You can easily change the pattern by having the patient breath rapidly, hold their breath, or repeat the strip after they run in place. This finding is diagnostic of nothing but a healthy heart. (fig.#2)

fig.#2 Sinus arrhythmia



## SECTION V

B. SINUS TACHYCARDIA: The heart rate is 100 to 160 and regular. All landmarks are normal, the rate is simply too fast. Sinus tachycardia is usually indicative of a NON-cardiac source, ie elevated temperature, hypovolemia, excitement, exercise or drug effects. To cure the tachycardia, find the underlying disease and treat it.

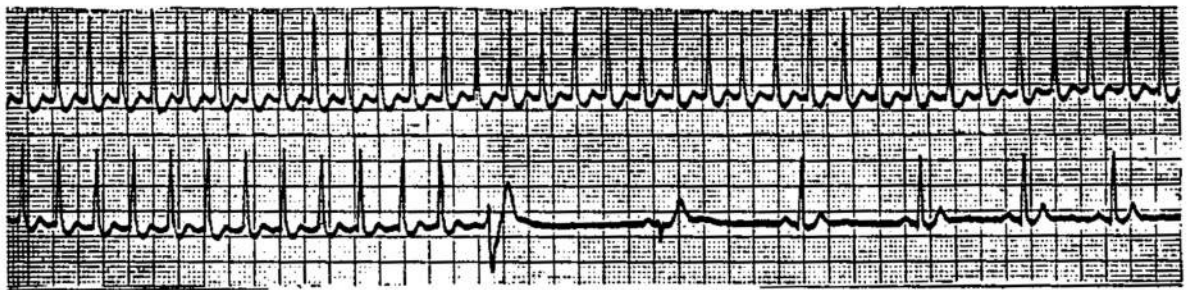
C. SINUS BRADYCARDIA: This is just the opposite of B. , here the rate is slower than normal- usually less than 60 . This can be a normal finding in young people, especially athletes. If very slow, say 40 or lower, it may indicate heart disease. Once more, interpret your findings in the light of the clinical picture. Other causes are hypothermia, hypothyroidism, and medications, especially Beta blockers like Inderal. ALWAYS ask your patient if they are taking any medications whatsoever, prescription or otherwise. The cause of their cardiac disease may be that simple to diagnose and treat.

D. PAROXYSMAL ATRIAL TACHYCARDIA:(PAT) There are several names for this very common atrial arrhythmia, don't let them confuse you. This is a rapid (160-200) arrhythmia, very regular, of rapid onset. The patient will often complain that their heart suddenly started racing or pounding, they are very aware that something is quite wrong. Frequently these episodes are very brief, lasting only seconds or a few minutes. This makes it very difficult to catch on an EKG strip. The onset may be precipitated by excitement, fatigue, exercise, medications or stimulant abuse( chocolate, coffee, tea, NO-DOZE, cokes etc.) The patient will frequently give a history of past similiar episodes. They usually seek medical advice if the episodes become prolonged, more frequent, or are associated with any physical discomfort. In the otherwise healthy individual, these runs of PAT are not particularly dangerous. The patient may complain of feeling faint, short of breath, dizzy or easily fatigued. The healthy heart can withstand this rate without any ischemic damage. Older individuals with more compromised cardiac blood flow do not tolerate these well and may quickly develop anginal pain and progress to infarction if the rate is not slowed. ANY patient who experiences discomfort with PAT needs further evaluation and warrants vigorous efforts to stop the arrhythmia.

Frequently the episode will cease with simply placing the patient at rest in a quiet environment (definitely not on the AMAL). Do the best you can to provide suce a place. Give oxygen to assure good myocardia oxygenation, especially if ther is any associated chest pain. Mild sedation with Bedadryl or small amounts of Valium may also be helpful. If this does not work, try some of the maneuvers aimed at slowing the heart by increasing Vagal tone. Frequently patients have already learned to stop their runs by one of the maneuvers. First is the Carotid Sinus massage. With the patient supine, the EKG running, carefully press one side of the patient's neck over the carotid sinus. This area is just below the angle of the jaw, over the Carotid pulse. Some individuals respond rather remarkably to this move, be ready to assist with ventillation and/or CPR. A brief period of Carotid sinus massage will markedly slow most normal individuals pulse. Try it on yourself for practice, just be sure you are seated first. This maneuver may succeed

in slowing or breaking the PAT to a normal sinus rhythm.  
(fig.#3)

(fig.#3)



PAT breaking with Carotid sinus massage

Other Vagal maneuvers you may wish to try are gagging, Valsalva maneuver, pressing on the (closed) eyes, or splashing the face with ice cold water. If the maneuver works, back it up with some mild sedation, put the man in his rack, and give him a good rest. He should fully recover within a few hours, assuming no precipitating cardiac abnormality. Caution this individual about stimulant abuse: no coffee, tea, nicotine, caffeine containing sodas, etc.. Carefully examine the heart and lungs during normal sinus rhythm. The man should be referred to your squadron medical officer to determine if any further evaluation is needed. Some individuals with PAT have underlying cardiac problems and require study.

Isolated infrequent episodes of PAT, with no evidence of angina or underlying cardiac disease is not disqualifying for submarine duty as a rule, but each individual case must be considered closely. PAT is thought of as a benign arrhythmia, quite common in young people, resolving with age. If occurring in older individuals or associated with cardiac pain or symptoms it is not a benign disease and may require chronic medication.

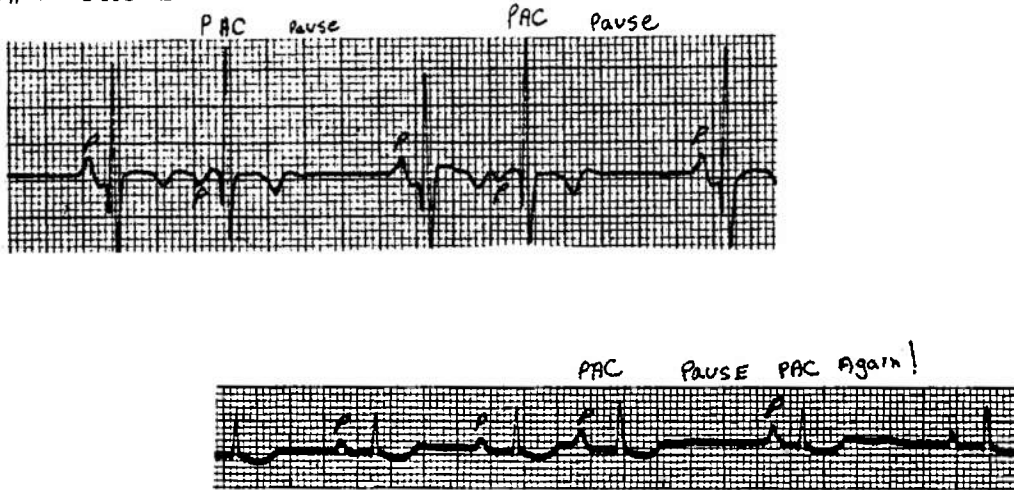
A note on pharmacological means of breaking runs of PAT. Although currently unavailable, the drug of choice is Verapamil, both for stopping acute runs and to suppress other supraventricular tachycardias. Inderal can also be used for chronic management. Edrophonium is still used by many for acute management. DC shock is necessary in some very refractory cases.

5. PREMATURE ATRIAL CONTRACTIONS: ( PAC's, APC's, etc.)

PAC's are heart beats which occur out of step from the normal sinus rhythm. They usually occur early in the cycle, ie following the last QRS at a much shorter interval than normal. These beats are triggered by an ectopic pacemaker, one other than the SA node, in the atrium. The atrium is thus depolarized in an abnormal sequence, but the ventricles fire normally. This results in a tracing with a changed P wave, but a narrow identical QRS as compared to the other beats. (fig#4)

A compensatory pause may follow the PAC. Thus the leading clue is that there are occasional pauses in the rhythm.. Closely examine the beat just before the pause to see if it indeed did occur early, and if the P wave is different.

fig.#4 PAC's



Occasionally the P wave will be so early it will be superimposed on the previous T wave.

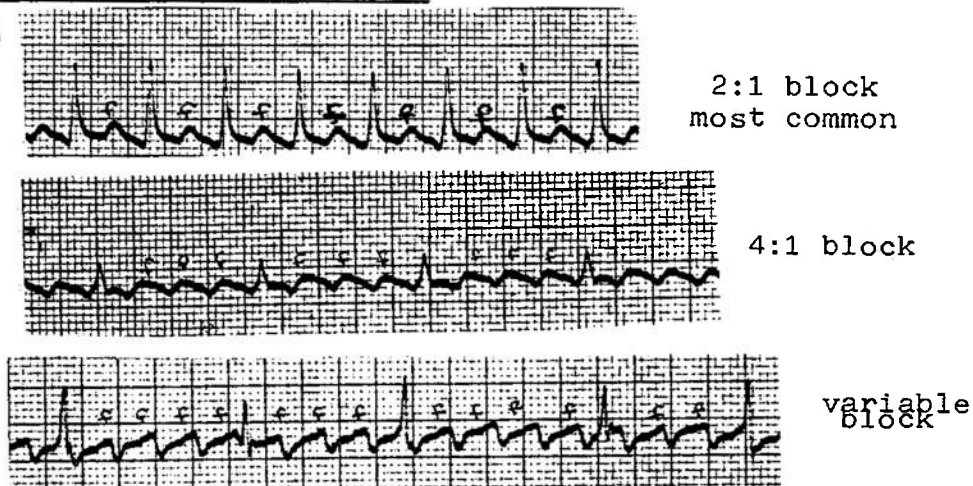
The patient may notice these beats and tell you that their heart stops or skips a beat. While taking the pulse you will notice a pause. Auscultation may pick up muffled or irregular beats followed by a pause then a very loud beat. This is because the premature beat only allows the heart to partially fill, whereas the long pause allows a large volume of blood to enter the heart.

PAC's may arise from more than one ectopic site, and are then called multifocal.

While these premature beats may signify underlying heart disease, they are also caused by pulmonary disease (emphysema), stimulant excess or fatigue.

7. ATRIAL FLUTTER: This is a rapid and very regular arrhythmia. The atria may be firing at a rate of 200 to 350, but the ventricles rarely respond in a 1:1 ratio. Often there will be one QRS for every two or four P's, rarely for every 3. This is referred to as 2 to 1, 4 to 1, or 3 to 1 block. The P waves at these very high rates become more prominent and peaked and are called f, for flutter, waves. These patterns tend to be very regular, with the flutter waves the key to interpretation. (fig.#5)

fig.#5



A very rapid ventricular response can often be slowed by Carotid sinus massage. This allows the flutter waves to become more prominent and aides in the diagnosis. Compare the 2:1 block with the 4:1 block in fig#5. The massage will not break the flutter, just convert it briefly to a higher degree of block. The characteristic saw toothed flutter waves are then more obvious.

Atrial flutter is not a benign finding. It is found in conjunction with cardiac diseases such as valvular dysfunction or coronary artery insufficiency. Patients are generally symptomatic with this arrhythmia. They are severely short of breath, faint, and may be experiencing anginal pain or frank infarction. The sudden appearance of this arrhythmia requires prompt treatment. Electrical conversion is the best method, but is not available on submarines (clinically at least). Digitalis will slow the ventricular response to an even higher atrial rate. That is, Digitalis increases the AV block. For example, the original rate for a flutter pattern is 240 atrial, with a 2:1 block, thus a ventricular rate of 120. Digitalis may increase the atrial rate to 300, but increase the block also to 4:1, thus the ventricular rate is now 75.

Flutter may become extremely rapid, then irregular, then convert to fibrillation. The ventricles then beat irregularly in response to the disorganized atrial stimulation. This may or may not be an improvement.

8. ATRIAL FIBRILLATION: This is the classic irregular/irregular rhythm. The rate may vary from 40 to well over 200. The atrial rate is very rapid, greater than 300. The atria are firing in a totally confused manner. There is no effective atrial contraction. The P wave is essentially gone, replaced by an irregular wavy baseline. This atrial dysfunction results in a drop of about 20% in the cardiac output. This may or may not be of clinical significance to the patient. Hemodynamically, atrial fibrillation is a very inefficient rhythm, blood flow is severely diminished, especially in the faster rhythms.

Atrial fibrillation is not found in healthy hearts. It usually indicates atrial enlargement, as in mitral stenosis, congestive heart failure or many other cardiac and systemic diseases. You have a patient with an underlying disease that should NOT be kept aboard.

The best treatment on the boat is again Digitalis. This will slow the ventricular rate and may even convert the rhythm to normal. Slow rates of fibrillation, less than 50 and not tolerated well by the patient, may be treated with atropine. The drug of choice is Quinidine, but is not on the AMAL. Cardioversion is also a frequent treatment.

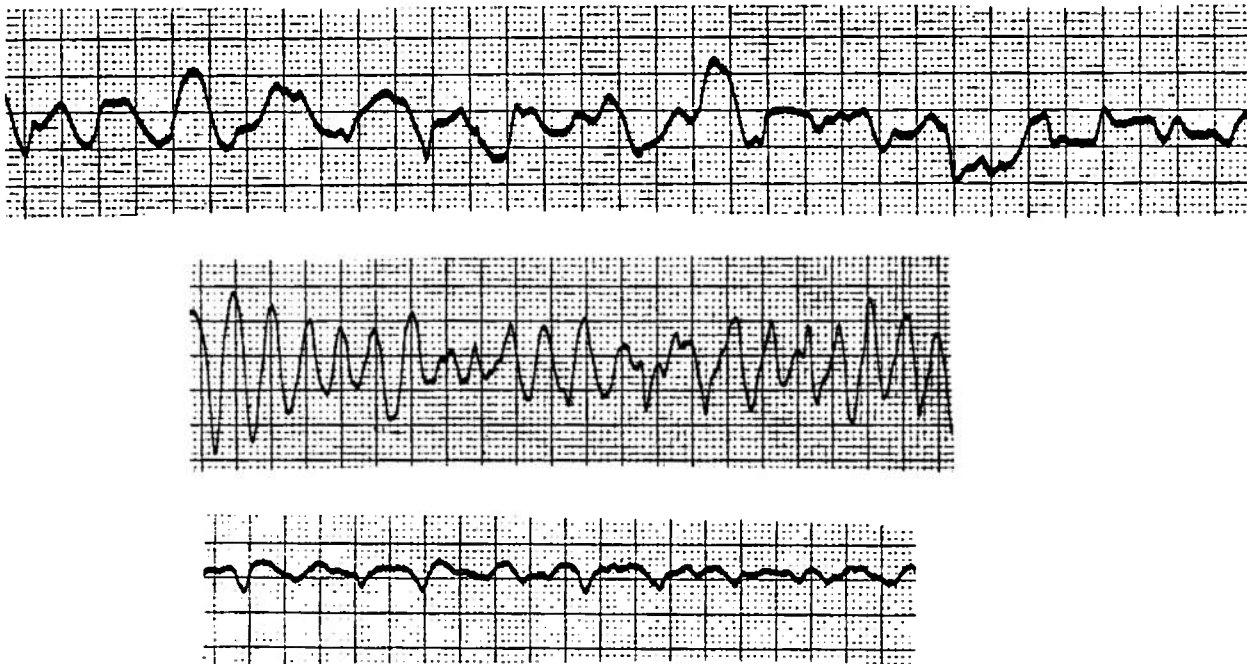
NOTE: Give oxygen to all patients with symptomatic arrhythmias. A well oxygenated myocardium responds much better to all medications and may correct the problem itself. Also watch the patient's fluid balance closely. Keep the load in the heart minimal with careful management of intake, perhaps even use of diuretics if there is evidence of fluid overload.

Ventricular tachycardia is a very poorly tolerated rhythm. The patient will usually become unresponsive, cyanotic, and may experience seizure activity. This is because the brain is being hypoperfused. Slower rates are tolerated only slightly better. If the patient is still conscious, bolus with 50-100 of Lidocaine and repeat in three minutes. Maintain on a continuous infusion of 1-3 mg. of Lidocaine per minute in D5W. DC shock is the treatment of choice in the unconscious patient. Essentially all you can do is try the lidocaine, do CPR and hope for the best.

### 3. VENTRICULAR FIBRILLATION : V-Fib.

This is the very least effective arrhythmia short of cardiac standstill. There is no coordinated contraction of the heart, all of the muscle is nothing but a writhing mass, often referred to as a "bag of worms." The patient is usually moribund, pulses are absent, CPR is essential to sustain life. DC shock is again the preferred treatment. All you can do is give good CPR, Oxygen, correct acidosis, give lidocaine and epinephrine and hope the rhythm converts to something more manageable.(fig#9)

fig.#9 Ventricular Fibrillation



Note: no identifiable landmarks, No rate discernable


NO PULSE

III A-V BLOCK

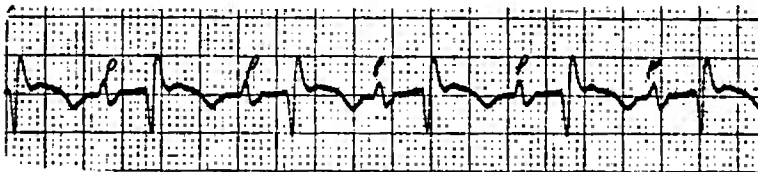
These types of arrhythmias occur when the atrioventricular node (AV node) is diseased and unable to transmit the atrial impulse effectively to the ventricles. There are various types and degrees of AV block.

1. First Degree AV Block: Here the AV node transmits the impulse to the ventricles, but it is delayed. This results in an abnormally long PR interval. (fig.#10) The QRS complexes will appear normal, as will the P waves. Every P wave is followed (eventually!) by it's own QRS. Recall the PR is usually .21sec. or less.

fig.#10 First Degree AV Block- Note long PR intervals



PR=.41 sec.



PR=.24 sec.

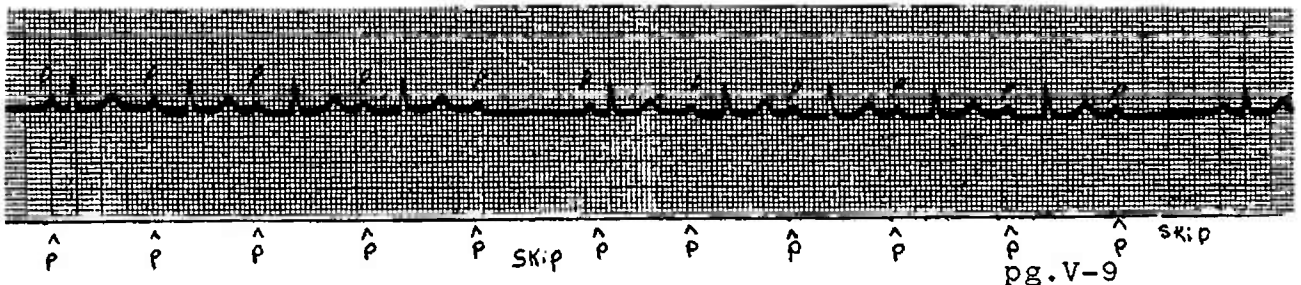
First degree block generally does not diminish cardiac output. It usually denote damaged tissue in the area of the AV node or the effects of drugs, especially Digitalis. It can be a tip off for more severe heart block in the future.

2. SECOND DEGREE HEART BLOCK:. This is divided into two categories:

- A. Mobitz Type 1 (Wenckebach Phenomenon)
- B. Mobitz Type 2

A. Mobitz Type 1: The PR intervals become progressively longer until finally a beat is dropped. (fig.#11) The next impulse is transmitted, but the PR again lengthens and the cycle is repeated. This type of block may be caused by Digitalis or an MI. It is usually self limited and reverts to normal with decrease in the Digitalis level or resolution of the MI. If the rate becomes very slow, Atropine may be used.

fig.#11 Mobitz Type 1- Wenckebach Block



^ P ^ P ^ P ^ P ^ P SKIP ^ P ^ P ^ P ^ P ^ P SKIP  
pg.V-9

B. Mobitz Type 2 : Here some beats are blocked completely. The other beats are normal. There are simply P waves with no subsequent QRS. (fig.#12) These usually have a fixed rate of occurrence ie. four regular beats then one dropped. Another variant of this is just occasional dropped beats with no pattern. In both there is no change in the PR interval.

If the block and the ventricular rate sufficiently slow, cardiac output may be down enough to cause symptoms. To increase the rate give Atropine. Give oxygen also.

Mobitz Type 2 is far more likely to deteriorate to a greater degree of block. Often a pacemaker is necessary, and may be placed as a precautionary measure. These patients have sick hearts and must seek expert care.

3. Third Degree or Complete Heart Block: Here the P waves are not conducted to the ventricles at all. The QRS originates on its own from a junctional or ventricular source. (fig.#13) The lower it arises in the conduction system, the wider and more bizarre the complexes and the slower the rate.

Both the P waves and the QRS complexes are regular in rhythm, but they occur at different rates and have no effect on each other.

Treatment of choice is an artificial pacemaker. Atropine will NOT help since it will only increase the atrial rate. Isoproterenol (Isuprel) can be used as a stand-by, but is not on the AMAL. The best choice available is to MEDEVAC as soon as possible.

fig.#12

Mobitz Type 2

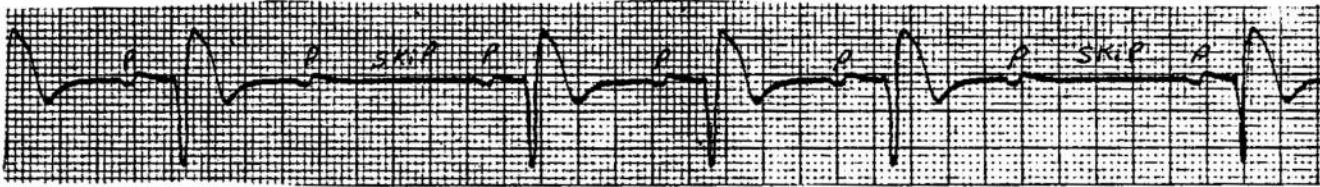
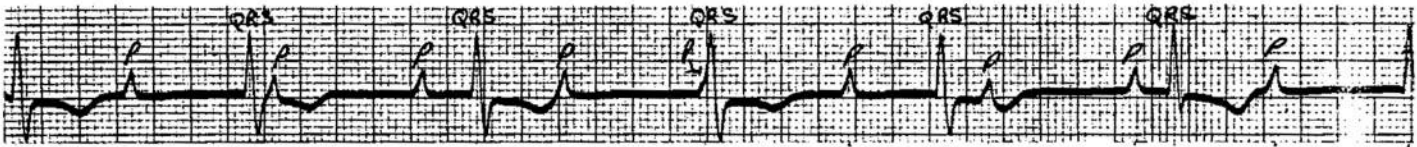


fig.#13 Complete heart block



Note that the P and Qrs proceed at their own pace, with no effect on each other.

CHANGES OF THE EKG WITH MYOCARDIAL INFARCTION

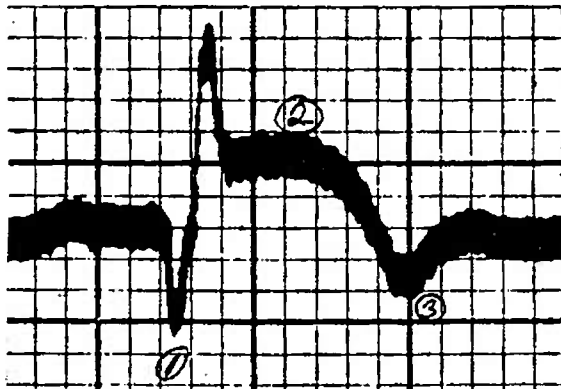
With a myocardial infarct heart muscle tissue is damaged or lost due to loss of blood flow. This dead or damaged tissue does not transmit the electrical impulses or repolarize properly. This results in characteristic changes in the EKG.

There are three major changes in the EKG landmarks indicative of infarction: (fig#1)

1. Q waves
2. ST elevation
3. T wave inversion

1. Abnormally wide or deep Q waves. These must be at least 0.04 seconds in duration and at least as deep as 25% of the R wave following it, provided that the R wave is at least 5mm. tall. The Q wave is thought to represent heart tissue that is actually dead and necrotic.

fig.#1 The three changes of MI



1. Q wave
2. ST elevation
3. T wave inversion

2. Elevation of the St segment : The ST is elevated from the baseline in the area of injury and depressed in reciprocal leads. (table #1) Elevation of 1mm. on the limb lead tracing and 2mm for the V leads is significant. NOTE: Acute pericarditis also produces ST elevation. Correlate this finding closely with the clinical findings. Do daily EKGs to look for other changes indicative of MI. ST segments may also be depressed in areas of ischemia- ie. where the heart muscle is compromised but not yet dead or injured. this would be seen in anginal episodes or areas adjacent to the injury. These ischemic changes result in the ST segment being shifted in a direction away from the direction of the QRS. For example, if the QRS is upright, the ST would be depressed.

3. T WAVE INVERSION: The T wave will be inverted in areas of ischemia, and will point opposite to the QRS.

Table #1 The Leads in Relation To Heart Anatomy

Right side of heart : V1 , aVr  
 Transition between right and left : V2, V3, V4  
 Left side of heart : V5, V6, I, aVl  
 Inferior of heart : II, III, aVf  
 Anterior of heart : I, aVl, V3 - V6

These changes may occur or evolve over a period of time. Thus daily EKGs are necessary in a suspected MI. DON'T be overly relieved by a normal EKG very early in the process, the changes just might not be that evident yet! The above changes are also found primarily in transmural infarct, when the entire heart wall muscle is involved. Less extensive but no less serious infarcts, such as the subendocardial, may have very few or confusing changes. The diagnosis here often depends on the clinical picture, findings on physical exam and lab studies. A mild elevation of the white count, 12,000 to 15,000, may be very helpful. It is an excellent idea to draw blood and save the frozen serum for later analysis.

The changes on EKG may revert to nearly normal with time, leaving only the Q wave in most old MIs. (fig.#2)

fig.#2 Evolution of the EKG in Myocardial Infarction

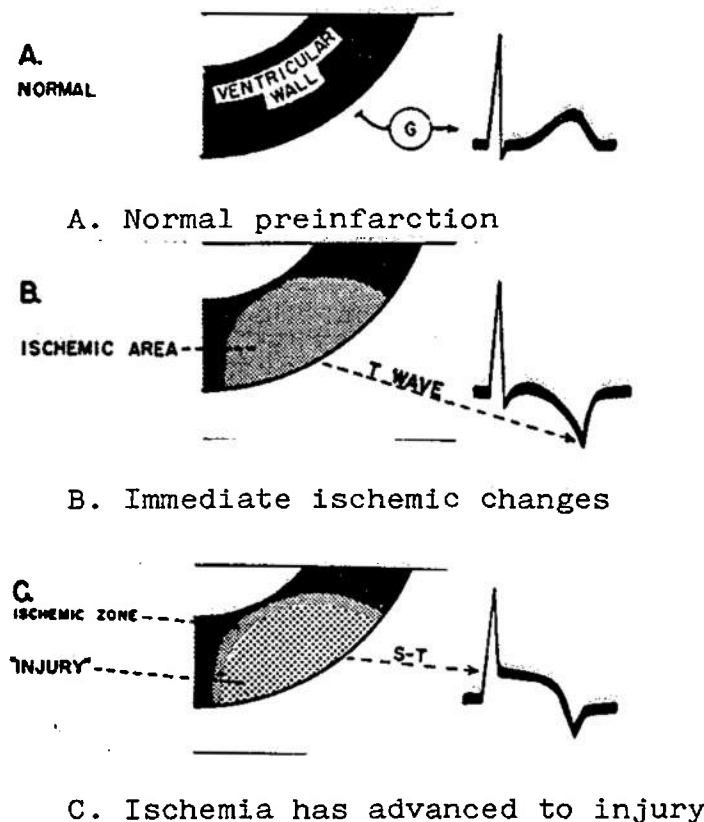
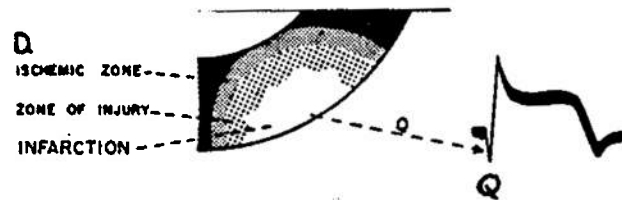


fig.#2 -continued-



D. True death of tissue



E. Injury resolves to either dead or ischemic tissue



F. Healed infarct leaving only the scar

Location of the infarct can be determined by which leads show changes of injury. (Table #1) Don't get too involved with trying to locate the infarct or estimate the extent of the injury. These are really moot points in your case. Your concern is whether or not there is an infarct present. Render your best medical care. The decision on MEDEVAC is a touchy one. You must weigh the condition of the patient, the risks of the transfer on worsening the infarct, the mission and schedule of the boat, and, most importantly, your own ability to handle this man if he remains aboard. A most difficult situation for which there is no pat answer.

For details on medical management of MI, refer to your references. The most recent NUMI instructions on the subject is included as ENCLOSURE #2.



SUGGESTIONS FOR FURTHER STUDY

The study of electrocardiograms is the topic of several texts, not just one brief paper. These few pages are but an attempt to familiarize the reader with some very basic and pertinent aspects of this field.

The bibliography of this paper contains several good texts on EKG interpretation. There are many others available, from beginners programmed learning modules to extensive works on the finer details of interpretation.

Topics NOT included in this paper, but which are commonly dealt with in longer texts are: axis determination and interpretation, bundle branch blocks, hemiblock, junctional arrhythmias, pacemakers, pediatric and congenital anomalies, and many more fine points of interpretation. Please don't feel the field is exhausted after reading this paper!

Some notes on the books in the bibliography:

1. Blowers and Smith: This is a very basic ring bound soft cover volume geared to the Non-physician. Good illustrations and easy to read text make it a good starter text. It has no actual EKGs however, just illustrations.
2. Dubin: This is an older text, but there are more recent editions. This is a great A to Z programmed learning text excellent for self instruction or review. It even has little cut out pages for your rapid reference book(better known as an idiot book).
3. Goldman: This is a more detailed text. The illustrations and EKG examples are great, and it has a comprehensive index. A good reference text, but not a good learning text for the beginner.
4. Hurst and Myerburg: Rather heavy going due to marked emphasis on the vector analysis system. A good coverage of that topic but little else. Lacks good tracings.
5. Marriot: This is one of the favorite texts of medical school students. While not too complex, it covers all the major topics well, gives lots of helpful hints and has good illustrations and tracings.
6. Phillips and Feeney. While this is probably the best text overall for both self teaching and reference, it has very little on changes with MI.
- 7.&9. Brief exerpts only used
8. American Heart Association Booklet. This is one of a series of five booklets in "Examination of the Heart" .They are brief, small and excellent. Other topics are History Taking, Inspection and Palpation of the Venous and Arterial pulses, Auscultation, and Inspection of the Anterior Chest. These are available (CHEAP) from your local AHA office. Just look them up in the yellow pages and give them a call.