

AD-A173 761


PORTABLE DIAGNOSTIC RADIOMETER(U) DAVID SARNOFF  
RESEARCH CENTER PRINCETON NJ R W PAGLIONE JUN 86  
PRRL-86-CR-10 N00014-83-C-0524


1/1

UNCLASSIFIED

F/G 6/12

NL





MICROCOPY RESOLUTION TEST CHART  
NATIONAL BUREAU OF STANDARDS-1963-A

12

AD-A173 761

# PORTABLE DIAGNOSTIC RADIOMETER

Prepared for  
Department of the Navy  
Naval Medical Research and Development Command  
National Naval Medical Center  
Bethesda, MD 20014

**DTIC**  
**ELECTE**  
OCT 28 1986  
**S** **D**  
**D**

Prepared by  
RCA Laboratories  
David Sarnoff Research Center  
P.O. Box 432  
Princeton, NJ 08543-0432

DTIC FILE COPY

June 1986  
Final Report — Phase II  
Contract N00014-83-C-0524

**DISTRIBUTION STATEMENT A**  
Approved for public release;  
Distribution Unlimited

86 10 10 115

UNCLASSIFIED

SECURITY CLASSIFICATION OF THIS PAGE (When Data Entered)

REPORT DOCUMENTATION PAGE		READ INSTRUCTIONS BEFORE COMPLETING FORM	
1. REPORT NUMBER	2. GOVT ACCESSION NO.	3. RECIPIENT'S CATALOG NUMBER	
	AD-A123 761		
4. TITLE (and Subtitle) PORTABLE DIAGNOSTIC RADIOMETER		5. TYPE OF REPORT & PERIOD COVERED Final - Phase II (7-1-84 to 9-15-85)	
		6. PERFORMING ORG. REPORT NUMBER PRRL-86-CR-10	
7. AUTHOR(s) R. W. Paglione		8. CONTRACT OR GRANT NUMBER(s) N00014-83-C-0524	
9. PERFORMING ORGANIZATION NAME AND ADDRESS RCA Laboratories Princeton, New Jersey 08543-0432		10. PROGRAM ELEMENT, PROJECT, TASK AREA & WORK UNIT NUMBERS	
11. CONTROLLING OFFICE NAME AND ADDRESS Office of Naval Research Naval Medical R&D Bethesda, Maryland 20014		12. REPORT DATE June 1986	
		13. NUMBER OF PAGES 32	
14. MONITORING AGENCY NAME & ADDRESS (if different from Controlling Office)		15. SECURITY CLASS. (of this report) Unclassified	
		15a. DECLASSIFICATION/DOWNGRADING SCHEDULE N/A	
16. DISTRIBUTION STATEMENT (of this Report)			
17. DISTRIBUTION STATEMENT (of the abstract entered in Block 20, if different from Report)			
18. SUPPLEMENTARY NOTES			
19. KEY WORDS (Continue on reverse side if necessary and identify by block number) Microwave Radiometer                      Non-Invasive Temperature Sensor Appendicitis Diagnosis			
20. ABSTRACT (Continue on reverse side if necessary and identify by block number) Research effort culminated in a hand-held non-invasive monitor capable of discerning an increase in temperature caused by an inflamed appendix. Preliminary tests on a limited number of patients are reported.			

**PORTABLE DIAGNOSTIC RADIOMETER**

**FINAL REPORT - PHASE II**

**CONTRACT N00014-83-C-0524**

**PREPARED FOR**

**DEPARTMENT OF THE NAVY  
NAVAL MEDICAL RESEARCH AND DEVELOPMENT COMMAND  
NATIONAL NAVAL MEDICAL CENTER  
BETHESDA, MD 20014**

**PREPARED BY**

**RCA LABORATORIES  
DAVID SARNOFF RESEARCH CENTER  
PRINCETON, NJ 08543-0432**

**JUNE 1986**

TABLE OF CONTENTS

Section	Page
Preface .....	1
I. Introduction .....	2
II. Program Objective .....	2
III. Phase I Review .....	3
IV. Phase II Prototype .....	6
A. Microwave Components .....	6
B. Low Frequency Circuitry .....	6
C. DC Supply .....	7
V. Prototype Evaluation .....	7

Accession For	
NTIS CRA&I	<input checked="" type="checkbox"/>
DTIC TAB	<input type="checkbox"/>
Unannounced	<input type="checkbox"/>
Justification	
By <i>Ctrl on file</i>	
Distribution	
Availability Codes	
Dist	Avail and/or Special
<i>A-1</i>	



## FIGURE CAPTIONS

- Fig. 1. Photograph of the Phase I breadboard radiometer.
- Fig. 2. Microwave section of the breadboard radiometer.
- Fig. 3. Dual-frequency microwave antenna. Antenna circuit board shown in foreground.
- Fig. 4. Microprocessor and display section of the breadboard radiometer.
- Fig. 5. Schematic of the basic Dicke radiometer.
- Fig. 6. Schematic for the 4 GHz radiometer.
- Fig. 7. Chart of first patient measured with the breadboard radiometer.
- Fig. 8. Sketches showing the location of the appendix in the body.
- Fig. 9. Chart of the second patient measured with the breadboard radiometer.
- Fig. 10. Chart of the third patient measured with the breadboard radiometer.
- Fig. 11. Chart of the fourth patient measured with the breadboard radiometer.
- Fig. 12. Patient history for the fourth patient.
- Fig. 13. Physical information taken at the time of admission for the fourth patient.
- Fig. 14. Dictated record of the operative procedure performed on the fourth patient.
- Fig. 15. Pathology report for the appendix removed from the fourth patient.
- Fig. 16. Schematic for Section 1 of the printed-circuit board.
- Fig. 17. Schematic for Section 2 of the printed-circuit board.
- Fig. 18. Schematic for Section 3 of the printed-circuit board.
- Fig. 19. Photograph of the assembled printed-circuit board.
- Fig. 20. Photograph showing the comparison in size between the DC supplies of the breadboard radiometer and the switching regulator of the prototype radiometer.

Fig. 21. Schematic for the switching regulator.

Fig. 22. Photograph of the switching regulator.

Fig. 23. Photograph showing an exploded view of the prototype radiometer.

Fig. 24. Photograph of the assembled prototype radiometer.

## PREFACE

This Final Report for Phase II was prepared by RCA Laboratories, Princeton, New Jersey under Contract No. N00014-83-C-0524 for the Naval Medical Research and Development Command, Bethesda, Maryland. The work on Phase II was performed from July 1, 1984 through March 31, 1985 at the RCA Microwave Technology Center, Dr. Fred Sterzer, Director. The program was supervised by Markus Nowogrodzki, Head of the Microwave Subsystems and Special Projects Group. The Project Scientist was Robert W. Paglione, Member of the Technical Staff, with technical support provided by Francis J. Wozniak and Eugene C. McDermott.

The computer modeling and other software support was provided by Morris Ettenberg, Consultant.

## I. INTRODUCTION

There exists a need for a portable diagnostic instrument that can non-invasively monitor and display internal body temperatures. This instrument would be extremely important on U.S. Navy ships whose complement does not include the services of competent medical professionals. In this case it would be important to determine whether a particular medical emergency does or does not exist in a patient. This would determine whether the patient should or should not be evacuated to a suitable medical facility for treatment.

The instrument would determine, by radiometric means, if there is an elevated temperature within the body. For example, this may be an aid in the diagnosis of appendicitis or nephritis.

The instrument described in this report is a dual-frequency microwave radiometer. The radiometer measures the amount of noise power being radiated from a localized tissue volume within the patient. The amplitude of this noise power over a frequency spectrum determined by the microwave components is proportional to the average temperature of the volume in question. Making this measurement at two separate frequencies can give an indication of the temperature profile over a depth as great as 6 cm.

## II. PROGRAM OBJECTIVE

The objective of Phase II of this program is to develop a prototype radiometer. The instrument should be a miniaturized, portable version of the bread-board radiometer developed under Phase I.

To meet this objective, the following tasks would be addressed:

1. Redesigning the 4 GHz amplifiers for miniaturization.
2. Incorporating all of the i.f. processing and computer circuitry on a single printed-circuit board.

3. Designing a switching regulator for the DC power supply.

A detailed discussion of the work performed on these tasks will be presented after a review of Phase I.

### III. PHASE I REVIEW

The "proof-of-concept" breadboard radiometer developed under Phase I is shown in Fig. 1. The breadboard unit includes the microwave hardware section, shown in Figs. 2 and 3; the microprocessor and display circuitry, shown in Fig. 4; and the DC supplies.

The microwave section contains an 800 MHz and a 4 GHz radiometer. Each radiometer is basically a Dicke-type radiometer<sup>1</sup> as shown in Fig. 5. In this circuit, the target noise power entering through the antenna is compared to the noise power emanating from a temperature-controlled termination. The difference between the two signal levels is displayed on the DC meter -- this reading is proportional to the temperature of the target. An improvement can be made in the accuracy of this system if the reference noise signal, in this case the oven-controlled termination, is always adjusted to give a zero reading on the DC meter; then the temperature of the reference noise source is equal to the temperature of the target. This self-balancing scheme can be realized by replacing the oven-controlled termination with a diode noise source. The mixer can also be replaced with a synchronous detector to improve the system sensitivity and reduce the system noise.

The single-throw-double-pole switch is usually realized with an electronically-switched, latching ferrite circulator; however, at these frequencies, the size, weight and current drawn by these components are limiting factors when considering a portable instrument. The switch can also be designed using switched low-noise amplifiers. In this case each amplifier is pulsed on and off asynchronously with the other, and the output of each amplifier is combined

through a 3 dB hybrid coupler to produce a single switched output. The complete schematic of the 4 GHz radiometer that is incorporated into the breadboard is shown in Fig. 6. The 800 MHz radiometer is similar, however low-noise bipolar transistors are used in the amplifiers instead of FETs.

Folded-dipole antennas as shown in Fig. 3 were chosen for the radiometer since they can easily be made on a printed-circuit board; they can be made balanced; and they operate over a wide bandwidth.<sup>2</sup>

The 800 MHz radiometer section was not used in the final version of the breadboard unit. The extraneous pickup of T.V. and f.m. signals caused this section of the breadboard to continuously show a maximum temperature reading. No shielding of these signals could be effectively incorporated into the radiometer since the human body acts as an antenna in this range.

In the final version of the Phase I breadboard, shown in Fig. 1, the UV-erasable EPROM was programmed to measure only the 4 GHz radiometric-temperature; and the 4 GHz antenna was removed from the dual-antenna housing and attached in its own housing by a cable to the side of the microwave enclosure.

A total of four patients (three at The Hospital Center at Orange, Orange, NJ; and one at St. Barnabas Medical Center, Livingston, NJ) were measured with the breadboard radiometer. Approval was granted by the Institutional Review Committee of each hospital for these measurements on the patients that were examined.

A patient chart was designed, an example of which is shown in Fig. 7. The chart contains a figure showing the four quadrants about the umbilicus, plus a lateral and posterior section on the left and right side. The skin temperature of each patient was measured using a non-contacting infrared thermometer (Linear Laboratories, Los Altos, CA, Model C-600M).

The chart for the first patient that was examined is shown in Fig. 7. The patient, a 24 year old female, presented with the classical symptoms of acute appendicitis. The skin temperatures in all four quadrants were normal and uniform at 32.2<sup>0</sup>C. The 4 GHz radiometer however measured elevated temperatures in the right upper and right lower quadrants with the highest temperature being in the right lower quadrant. This type of temperature pattern is indicative of an inflamed appendix in the retrocecal position. Referring to Fig. 8, the appendix is located at the cecum -- the junction of the large and small intestine.<sup>3</sup> If it is behind the cecum, or retrocecal, then it tends to be higher up in the abdominal cavity. This tends to produce elevated temperatures in both right quadrants rather than just in the lower right quadrant.

At the time of surgery on this patient the appendix was found to be inflamed and in the retrocecal position. It was removed and pathology verified a suppurative appendix.

The chart for the second patient is shown in Fig. 9. This patient presented most of the symptoms of acute appendicitis. The skin temperatures were normal and uniform at approximately 30<sup>0</sup>C. The radiometric temperatures were also normal with slightly decreased temperatures in the lower quadrants. X-rays showed a blocked bowel and no surgery was performed.

The third patient, chart shown in Fig. 10, also presented with symptoms of acute appendicitis. Skin temperatures were normal and so were radiometric temperatures, except for a slight elevation in the lower right quadrant. This patient was obese and it was estimated that abdominal fat was about 8-10 cm thick in the four quadrants. The fat layer was relatively normal however on the patient's side and back, and these measurements showed elevated temperatures on the right side (the left side and back were not measured). Surgery and pathology showed a normal retrocecal appendix. The patient's symptoms were later found to be caused by an abdominal infection. If the radiometer had been used

to measure the left side and back as well, these temperatures would have probably agreed with the right side showing something other than an inflamed appendix was causing the elevated temperatures.

The chart for the fourth patient is shown in Fig. 11. The patient's history, physical, operation, and pathology records are shown in Figs. 12 through 15. This patient showed normal and uniform skin temperatures and the radiometer showed elevated left lower and right lower quadrant temperatures (the highest temperature was actually measured midline). Surgery and pathology showed an acute suppurative appendix located midline. The appendix was out of its normal location presumably due to a previous kidney transplant operation.

#### IV. PHASE II PROTOTYPE

The main design objectives for the prototype unit were miniaturization and low power consumption. These objectives required modifications to the bread-board circuitry which will now be discussed.

##### A. Microwave Components.

A resistive feedback network was designed and implemented into the 4 GHz FET amplifiers. This network improved the input/output VSWR and stability of the amplifiers so that the ferrimagnetic isolators could be removed. This reduced the overall length of the 4 GHz amplifier chain by nearly 7 cm. Shorter detector diodes were found and used in the design, and as many unnecessary interface connectors as possible were eliminated.

##### B. Low-Frequency Circuitry

The i.f. processing circuit, the A-to-D converter, and the microprocessor were implemented using CMOS components wherever possible for low power consumption. All of the circuits were integrated onto one printed-circuit board measuring 8.5 cm x 29 cm x 1.5 mm. The schematics for the board are shown in Figs. 16 through 18, and a photograph of the board is shown in Fig. 19.

### C. DC Supply

The DC Supply was designed as a switching regulator operating at 200 KHz. This design produces a small, high-efficiency power supply that replaces all of the laboratory supplies used in the breadboard. Figure 20 shows the comparison between the sizes of the breadboard and prototype supplies. The switching regulator is a "flyback" design with a bifilar wound transformer feeding post-regulators. The schematic for the DC supply is shown in Fig. 21, and a photograph of the unit is shown in Fig. 22.

The supply operates on a +12V input supplied by a 3.2 A battery (Panasonic model LCR-3012PF). The overall radiometer current draw from the battery is -0.4A. At this rate the battery should operate for 5 hours before requiring a recharge.

### V. PROTOTYPE EVALUATION

The prototype unit is shown in an exploded view in Fig. 23, and assembled with the battery in Fig. 24.

No patients have been evaluated with this unit.

## BIBLIOGRAPHY

1. Dicke, RH, "The Measurement of Thermal Radiation at Microwave Frequencies,"  
Rev. Scient. Instr., Vol. 17, pp 268-275, July 1946.
2. The Radio Amateur's Handbook, Goodman, B, Editor, The American Radio League,  
Newington, CT, pp 389-392, 1967.
3. Melloni's Illustrated Medical Dictionary, The Williams & Wilkins Company,  
Baltimore, MD, 1979.





FIGURE 1

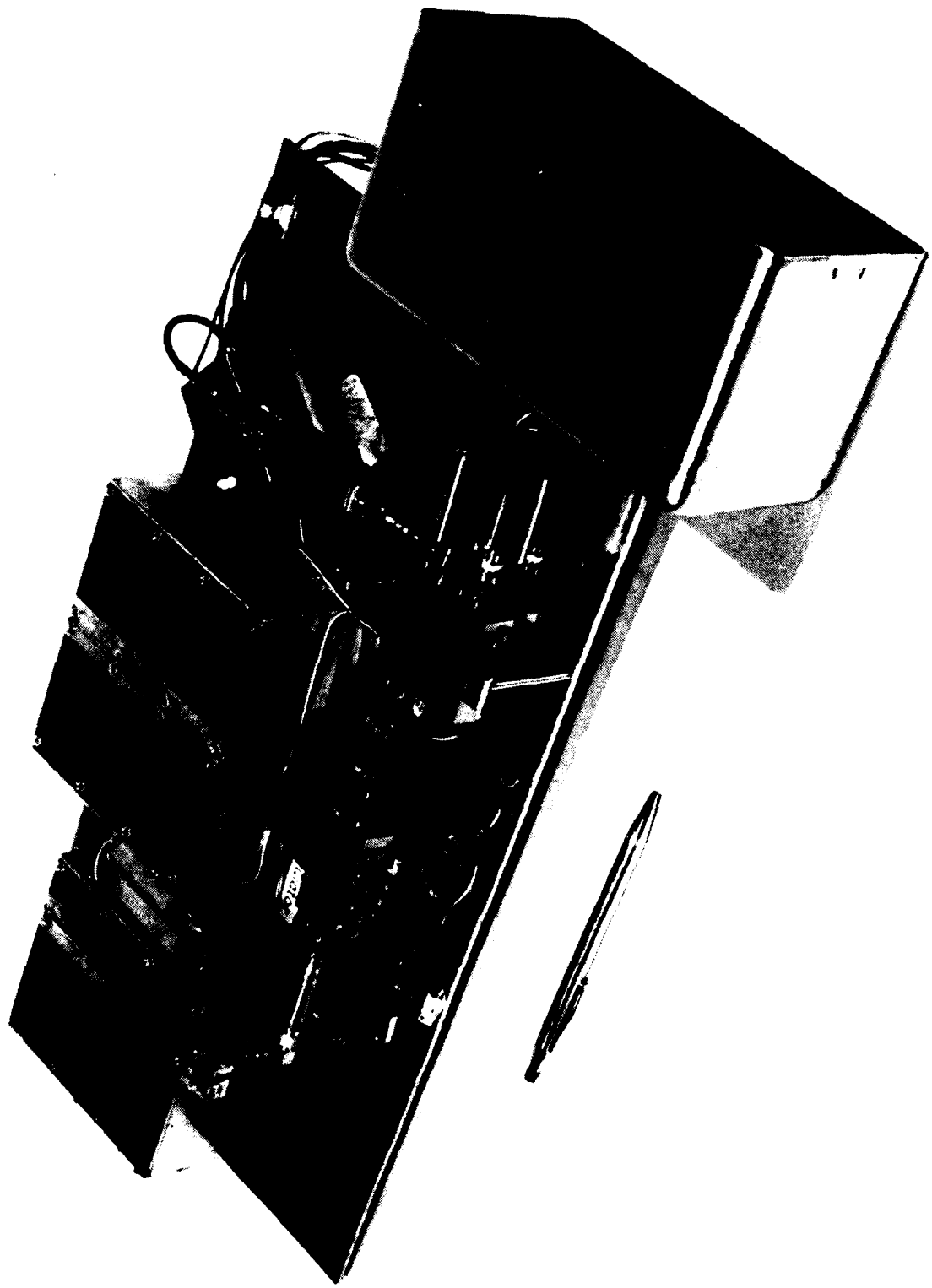


FIGURE 2




FIGURE 3




FIGURE 4

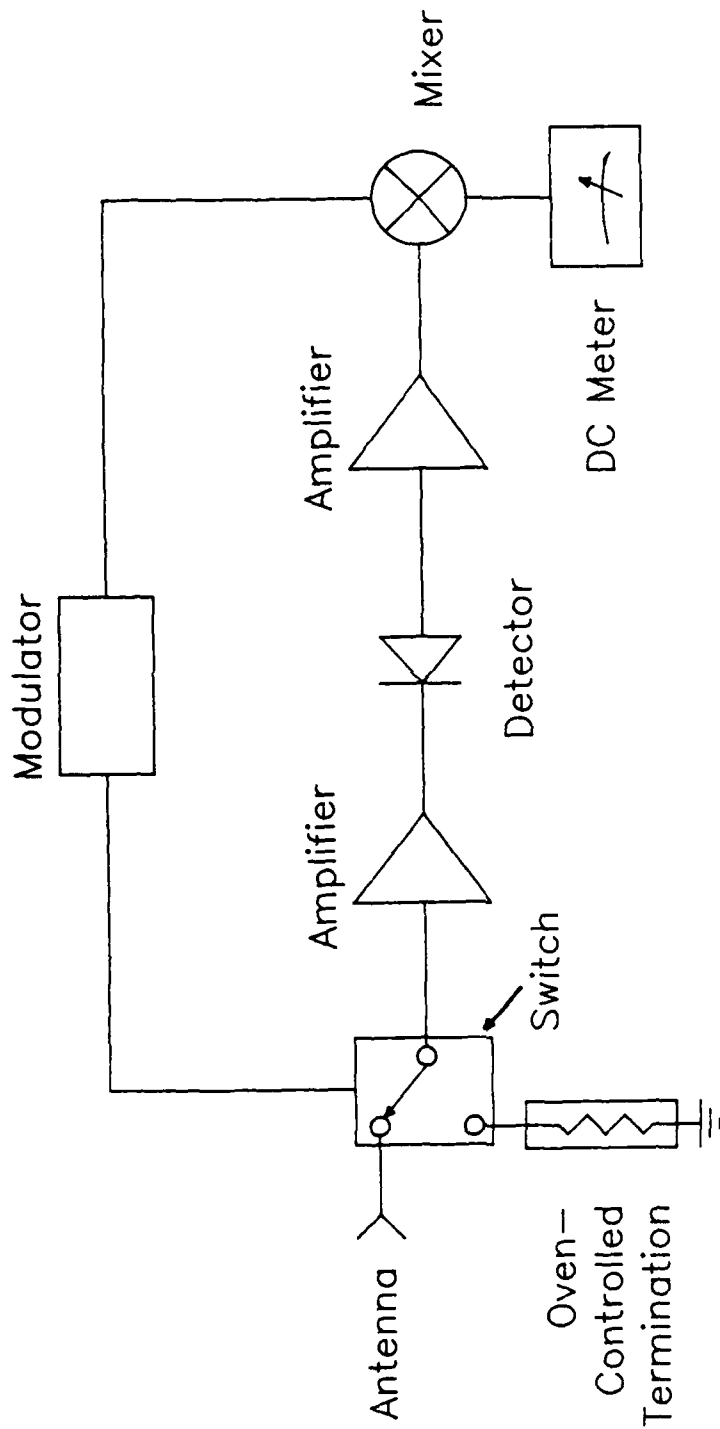


FIGURE 5

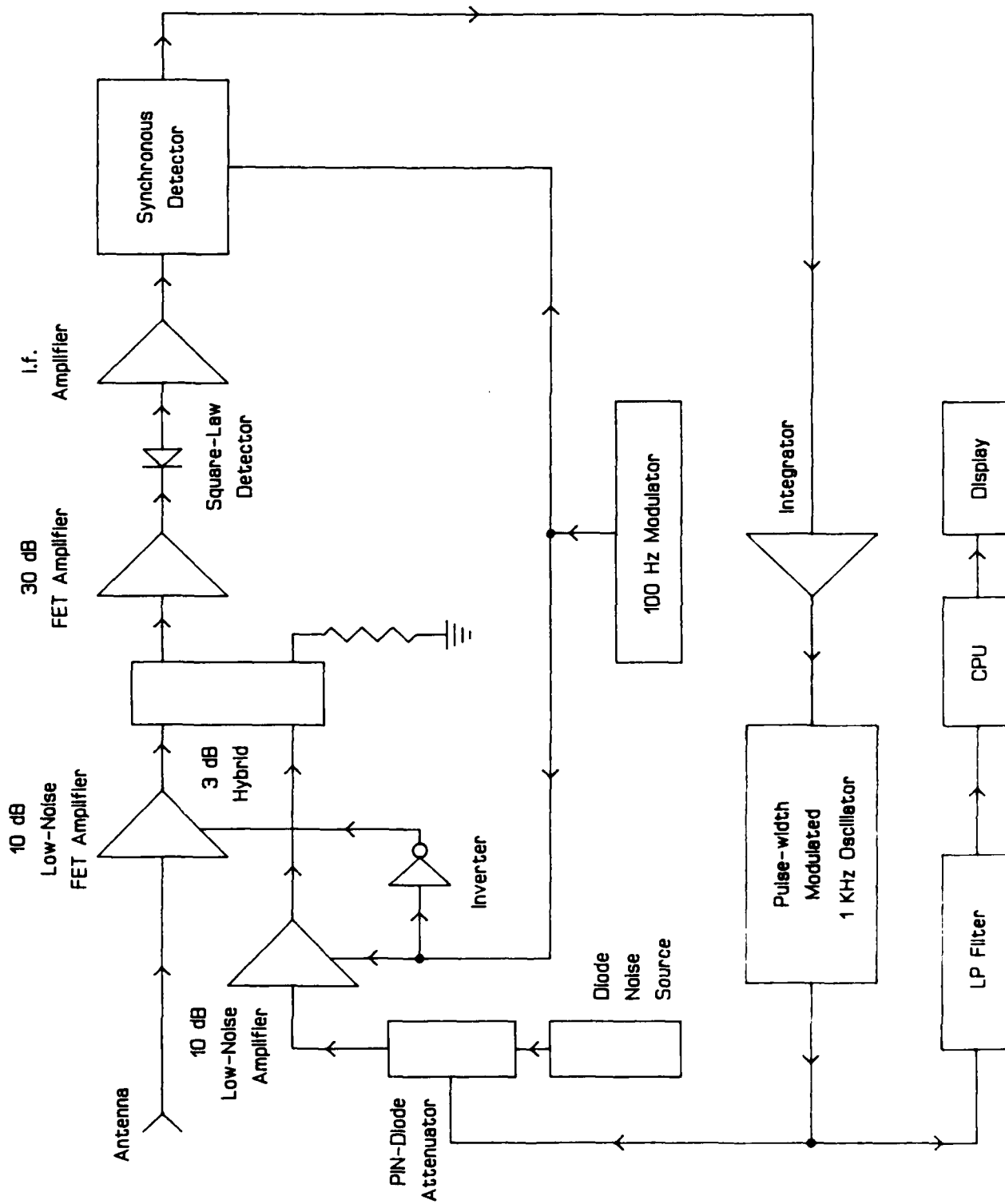


FIGURE 6

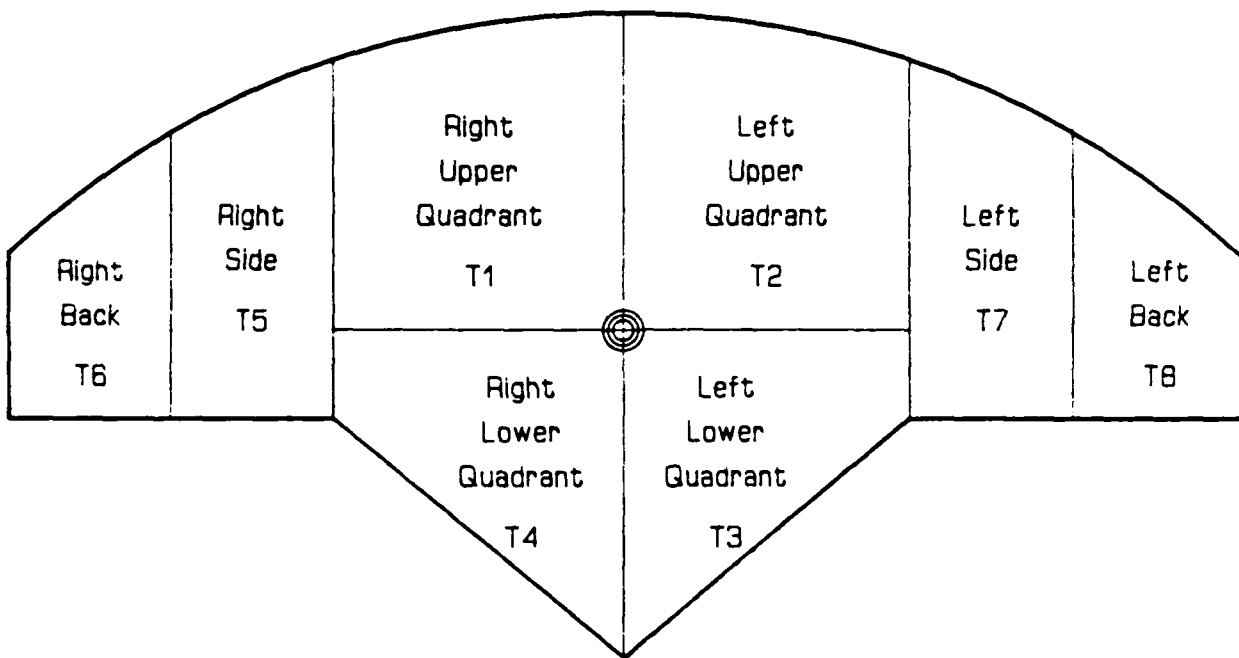
Patient: \_\_\_\_\_ Date: 12/9/85

Hospital: OMH Physician: CHUDIO

Diagnosis: ACUTE APPENDICITIS

Comments: LOW-GRADE FEVER, NAUSEA

18-25mm OF ABDOMINAL FAT FEMALE - 24 YRS.



Radiometric Temperatures

Skin Temperatures

T6 \_\_\_\_\_ T5 \_\_\_\_\_ T1 35.2 T2 34.7 T7 \_\_\_\_\_ T8 \_\_\_\_\_

T4 35.6 T3 34.0

T6 \_\_\_\_\_ T5 \_\_\_\_\_ T1 32.2 T2 32.2 T7 \_\_\_\_\_ T8 \_\_\_\_\_

T4 32.2 T3 32.2

Pathology: ACUTE SUPPURATIVE APPENDIX - RETROCECAL

FIGURE 7

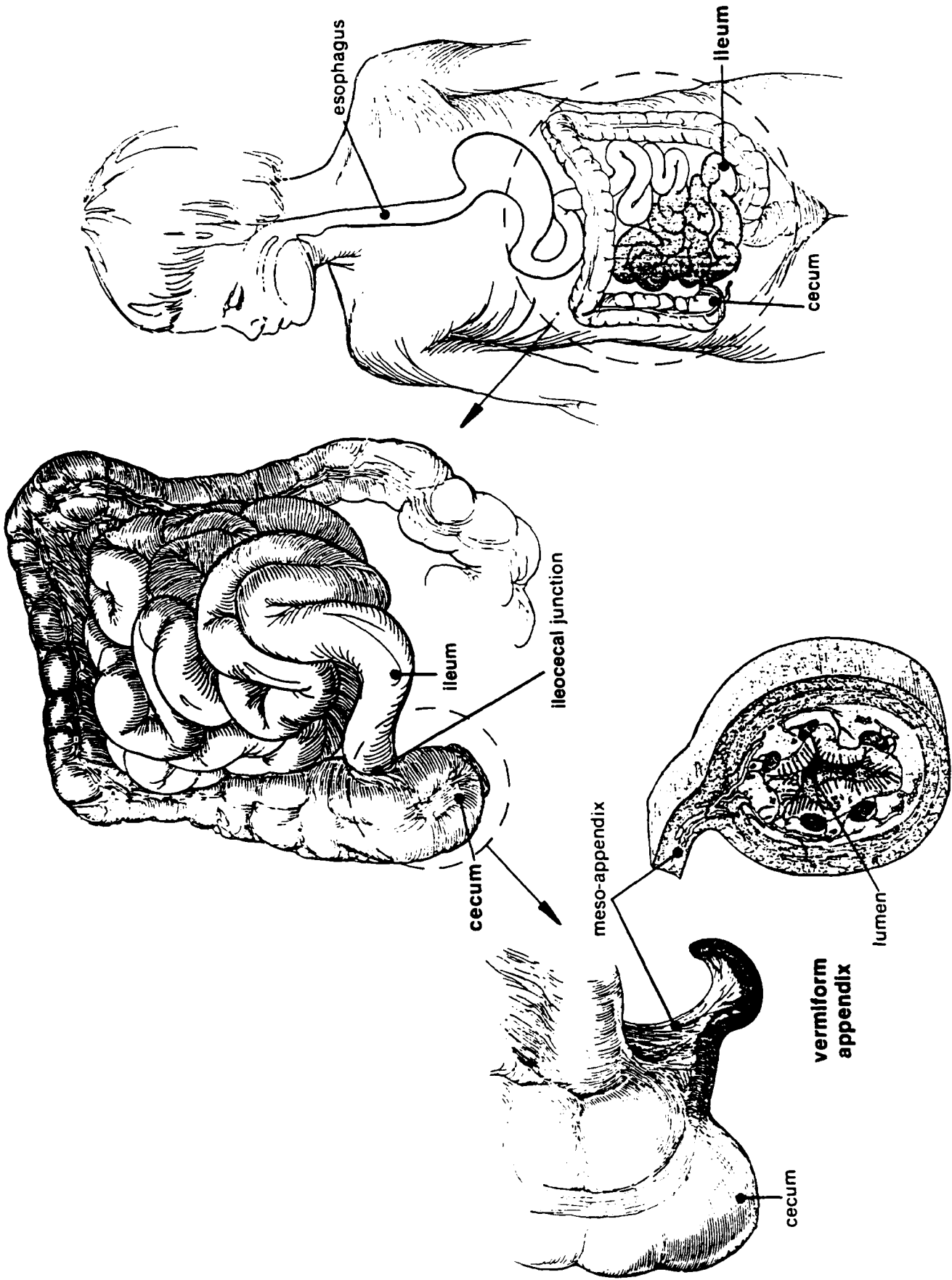


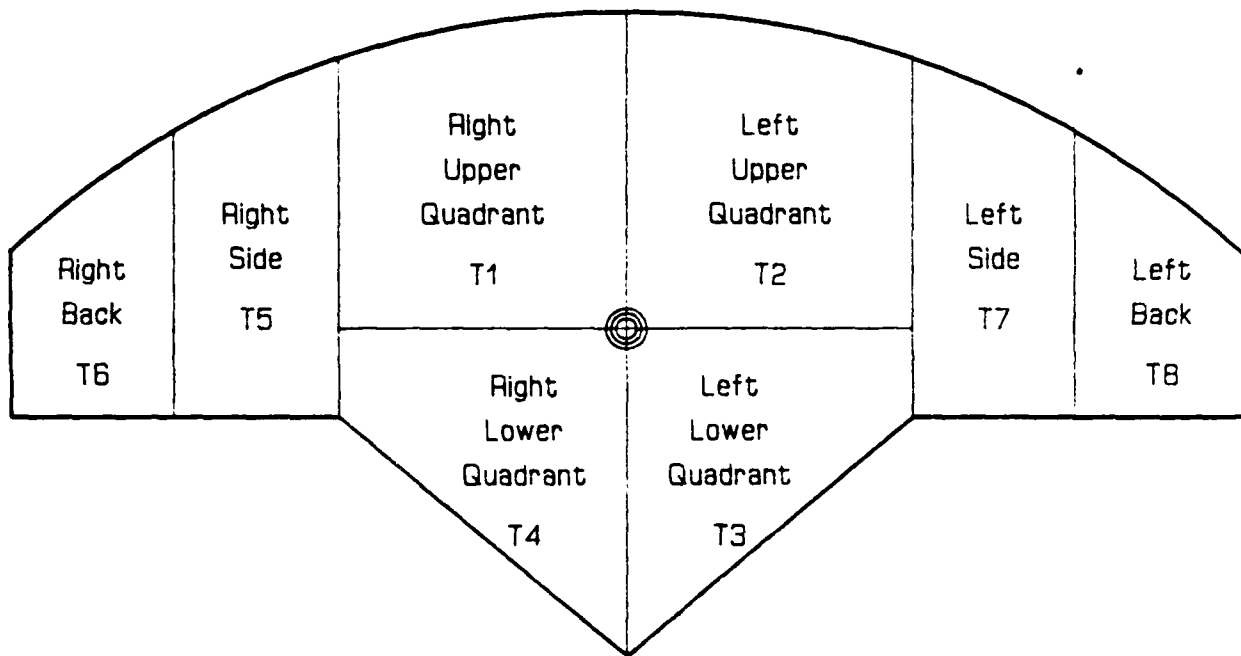
FIGURE 8

Patient: \_\_\_\_\_ Date: 12/19/85

Hospital: OMH Physician: PATEL

Diagnosis: BLOCKED BOWEL

Comments: LOW-GRADE FEVER



Radiometric Temperatures

Skin Temperatures

T6 \_\_\_\_\_ T5 \_\_\_\_\_ T1 34.6 T2 34.3 T7 \_\_\_\_\_ T8 \_\_\_\_\_ T6 \_\_\_\_\_ T5 \_\_\_\_\_ T1 30.0 T2 30.0 T7 \_\_\_\_\_ T8 \_\_\_\_\_  
T4 33.8 T3 33.2 T4 30.0 T3 29.5

Pathology: NO SURGERY PERFORMED

FIGURE 9

Patient: \_\_\_\_\_ Date: 12/19/85

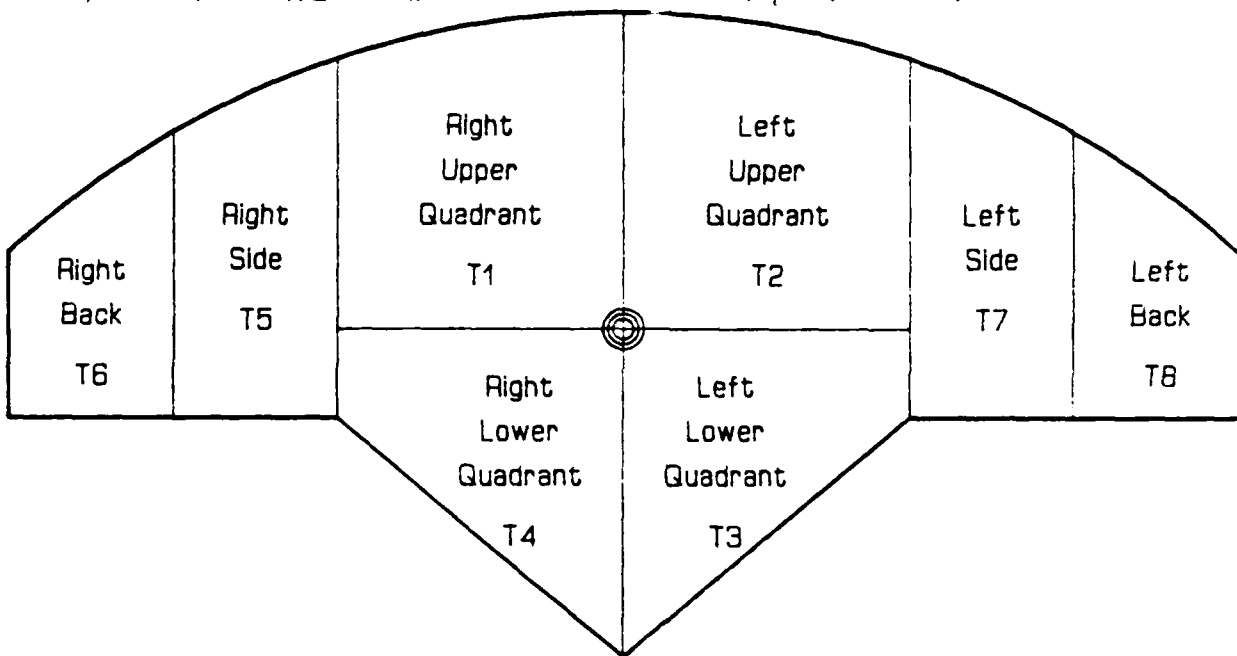
Hospital: OMH Physician: PATEL

Diagnosis: ACUTE APPENDICITIS

Comments: OBESSE, DIABETIC

8-10 cm OF ABDOMINAL FAT FEMALE - 61 YRS.

\* CONTRA LATERAL SIDE WAS NOT MEASURED



Radiometric Temperatures

Skin Temperatures

T6 36.0 T5 35.2 T1 33.4 T2 33.5 T7 \* T8 \*

T4 33.9 T3 33.5

T4 30.3 T3 30.3

Pathology: NORMAL RETROCECAL APPENDIX

FIGURE 10

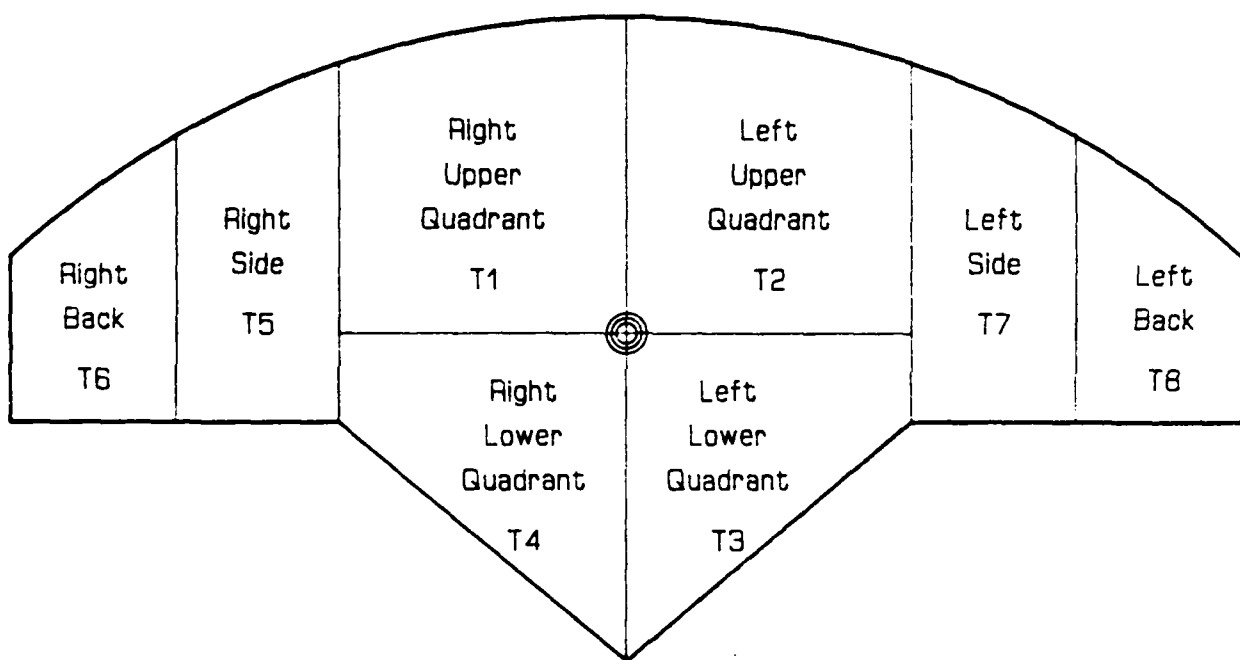
Patient: \_\_\_\_\_ Date: 12/27/85

Hospital: ST. B. Physician: LIVA

Diagnosis: ACUTE APPENDICITIS

Comments: LOW-GRADE FEVER, NAUSEA

PREVIOUS KIDNEY TRANSPLANT, DIABETIC THIN BUILD



Radiometric Temperatures

Skin Temperatures

T6 \_\_\_\_\_ T5 \_\_\_\_\_ T1 37.1 T2 37.0 T7 \_\_\_\_\_ T8 \_\_\_\_\_ T6 \_\_\_\_\_ T5 \_\_\_\_\_ T1 31.2 T2 31.2 T7 \_\_\_\_\_ T8 \_\_\_\_\_  
T4 38.7 T3 38.8 T4 31.2 T3 31.6

Pathology: ACUTE APPENDIX - MIDLINE RETROCECAL

FIGURE 11

SAINT BARNABAS MEDICAL CENTER  
LIVINGSTON, NEW JERSEY

HISTORY

Adm: 12/27/85  
L.Alterman, M.D.  
M.Gutkin, M.D.  
L.Byrd, M.D.  
C.Gelber, M.D.

CHIEF COMPLAINT: Nausea, vomiting, abdominal pain.

PRESENT ILLNESS: This is one of numerous SBMC admissions for this thirty-eight year old white male with a history of diabetic nephropathy who has had a cadaver renal transplant in May of this year. He has been doing reasonably well with a serum creatinine of approximately 1.5 to 2.0 and has been reasonably well controlled in terms of medications, hypertension, and chronic diarrhea (see below).

On the morning of admission he awoke from sleep with excruciating periumbilical pain and nausea. The pain gradually moved to the entire abdomen but seemed to be most localized in the right lower quadrant. He was admitted from the Emergency Room for further observation.

PAST HISTORY:

Medical: As noted the patient has a history of diabetic nephropathy. He has been dialysis dependent from December, 1983 until the time of his transplant. His post transplant course has been somewhat eventful. He had numerous readmissions to the hospital because of diarrhea. Numerous stool cultures were performed and on several occasions CMV has been isolated from his stool. He has been receiving symptomatic treatment for this only, however, as there has been no documented specific therapy. His hypertension has also been quite difficult to control since transplantation and this has required numerous changes in this as well. His most recent serum creatinine in the office was 1.9.

FAMILY HISTORY AND SOCIAL HISTORY: Please obtain from old charts.

FIGURE 12

LA:rlm  
dt 12/27/85  
tr 12/30/85  
765

HISTORY

20

MD \_\_\_\_\_  
L ALTERMAN, M.D.

SAINT BARNABAS MEDICAL CENTER  
LIVINGSTON, NEW JERSEY

PHYSICAL

Adm: 12/27/85  
L.Alterman, M.D.  
M.Gutkin, M.D.  
L.Byrd, M.D.  
C.Gelber, M.D.

VITAL SIGNS:

Blood pressure 175/100 supine right arm  
Pulse  
Respirations  
Temperature

GENERAL APPEARANCE: Physical examination at this time reveals a somewhat chronically ill appearing young white male in mild acute distress.

HEENT: No scleral icterus. Conjunctivae not pale. Mucosa are somewhat dry.

Neck: There is no jugular venous distension.

Lungs: Clear.

Heart: Rapid regular rhythm with an S4 gallop. There is no murmur or rub.

Abdomen: Soft but there is diffuse tenderness in all quadrants as well as rather marked tenderness in the right lower quadrant especially above his cadaver renal allograft. There is no rebound present. His bowel sounds are somewhat hypoactive at this time.

Rectal: Boggy ampulla and there is no tenderness elicited.

Extremities: No edema. No calf tenderness.

Admitting laboratory work revealed a white blood count of 7, 800 with no left shift. His electrolytes were within normal limits and serum creatinine is 1.6. His serum amylase is 92.

IMPRESSION: PROBABLE VIRAL GASTROENTERITIS, CANNOT HOWEVER EXCLUDE ACUTE  
APPENDICITIS AND EARLY TRANSPLANT REJECTION (DOUBT)  
UNCONTROLLED DIABETES  
UNCONTROLLED HYPERTENSION

PLAN: The patient will be kept NPO and will be observed for changes in his physical examination, and his laboratory parameters. His blood sugar will be controlled with frequent monitorings and appropriate doses of insulin as required. Blood pressure will be controlled with Catapres TTS and sublingual Nifedipine. He will be seen in surgical consultation in view of the possibility of appendicitis.

FIGURE 13

LA:rlm  
dt 12/27/85  
tr 12/30/85  
675

PHYSICAL

MD

L.ALTERMAN, M.D.

SAINT BARNABAS MEDICAL CENTER  
LIVINGSTON, NEW JERSEY

OPERATION

PT. NAME

DATE: 12/27/85

HOSP #

PRE OP DX Acute appendicitis.

POST OP DX Acute suppurative appendicitis.

OPERATION Appendectomy with cultures.

SURGEON D. Filippone, M.D. 1st ASSIST. W. Bradshaw, M.D.

ANESTHESIA General ANES. OGIST S. Pak, M.D.

ESTIMATED BLOOD LOSS: 25 cc.

FLUIDS: D5 ringers lactate 300 cc.

SPECIMEN: Appendix and aerobic and anaerobic cultures of the peritoneal fluid was taken.

FINDINGS: Patient was noted to have an acutely inflamed suppurative appendix with cloudy peritoneal fluid.

PROCEDURE: Patient was placed in the supine position and the right lower abdomen was prepped and draped in a sterile fashion. A skin incision was made through the upper pole of the previous renal transplant scar and carried down through the subcutaneous tissue until the external oblique fascia was identified. The external oblique fascia was opened along the length of its fibers and spread and then the internal oblique fascia was then identified and it was opened along the length of its fibers. Using blunt dissection the internal oblique muscle was divided along its fibers and the transversalis fascia was then opened along its fibers exposing the peritoneum. The peritoneum was grasped between two Kelly clamps and sharply opened this time using Babcock clamps. The appendix was then delivered from the wound. Aerobic and anaerobic cultures were then taken of the peritoneal fluid. The mesoappendix was then divided using clamps and tied off using 0 chromic suture. The base of the appendix was then tied off using an 0 chromic tie and this was then repeated a second time. Then using a Betadine soaked knife the appendix was excised from the cecum. Betadine was then placed on the exposed appendiceal stump and the appendix was then returned to the peritoneum. Once this was done the peritoneum was then closed using a 2-0 chromic running stitch. The transversalis fascia was approximated using an 0 chromic simple suture. The internal oblique fascia was then reapproximated using an 0 chromic figure-of-eight suture. The external oblique fascia was also approximated using an 0 chromic figure-of-eight suture. The subcutaneous tissue was then copiously irrigated with normal saline and the skin edges were loosely approximated using three 3-0 nylon mattress sutures. Sterile dressing was applied to the wound and the patient was brought to the Recovery Room in satisfactory condition.

W. Bradshaw, M.D./ip  
dt: 12/28/85  
tr: 12/30/85  
0704C

FIGURE 14

22

MD

D. Filippone, M.D.

SAINT BARNABAS MEDICAL CENTER  
OLD SHORT HILLS ROAD LIVINGSTON, N.J. 07039

DEPARTMENT OF PATHOLOGY

PHYSICIAN RESPONSIBLE: Dr. Filippone      PHYSICIAN #

OPERATION: Appendectomy

ANATOMIC SITE OF SPECIMEN: Appendix

PATIENT: NAME / ADDRESS / ROOM NO. 744  
DATE TODAY: 27 12 85      AGE: 38      SEX:  MALE  FEMALE  
DAY      MO.      YR.      REPORT F.S. TO O.R. # 3

PRE-OP DIAGNOSIS AND CLINICAL SUMMARY:

*Acute appendicitis*

DO NOT WRITE BELOW THIS LINE		ACCESSION DATE / NUMBER
<input checked="" type="checkbox"/> SPECIMEN	#1 <u>Appendix</u> = 4	<u>15</u> 28 DEC 85-22627
<input type="checkbox"/> SLIDES	= 2      = 5	
<input type="checkbox"/> BLOCKS	= 2      = 5	
<input type="checkbox"/> PX	= 3      = 6	
<input type="checkbox"/> NC	= 3      = 6	

#1. APPENDIX: The specimen is received in formalin and consists of a vermiform appendix and mesoappendix measuring 5.7 cm. in length by 0.8 cm. in diameter. The segment of mesoappendix measures 0.7 cm. The serosal surface is granular firm and covered by a yellow-white thick exudate. Representative sections are submitted.

SUMMARY OF SECTIONS

1X1: three pieces.

J. ESTEVA, M.D./dil

DIAGNOSIS:

#1. APPENDIX:  
- ACUTE APPENDICITIS AND PERIAPPENDICITIS.

kf

FIGURE 15

CONTINUED. PAGE 1 OF 1

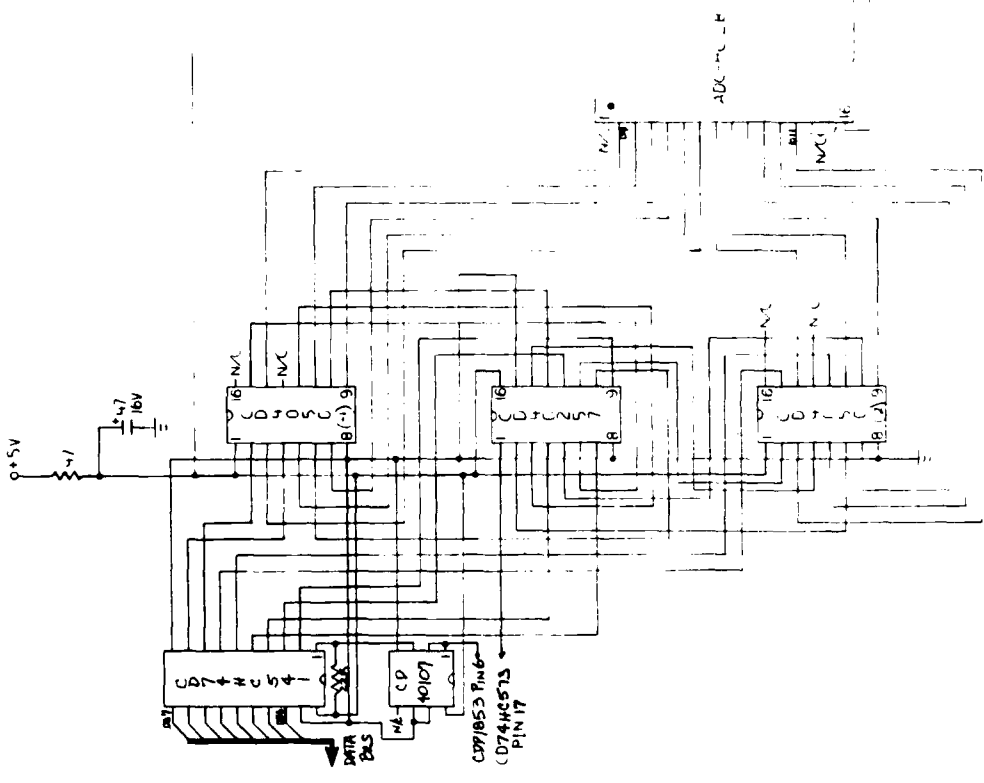
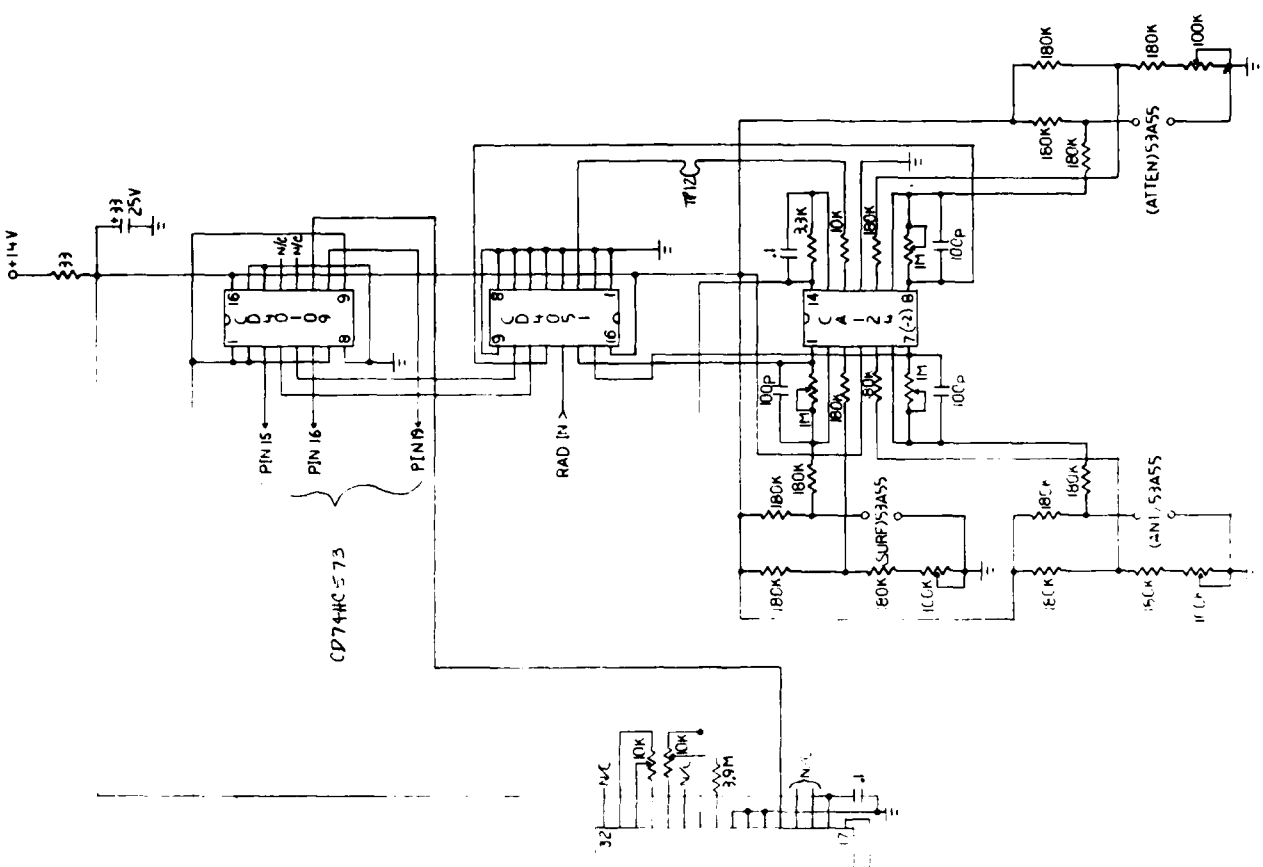
30:ec85  
DATE OF REPORT

23

MARILETTA KINTIROCLOU, M.D.  
PATHOLOGIST

TUMOR REGISTRY





I.E. & CPU CIRCUIT - SECTION 2

FIGURE 17

I.F. & CPU CIRCUIT - SECTION 3

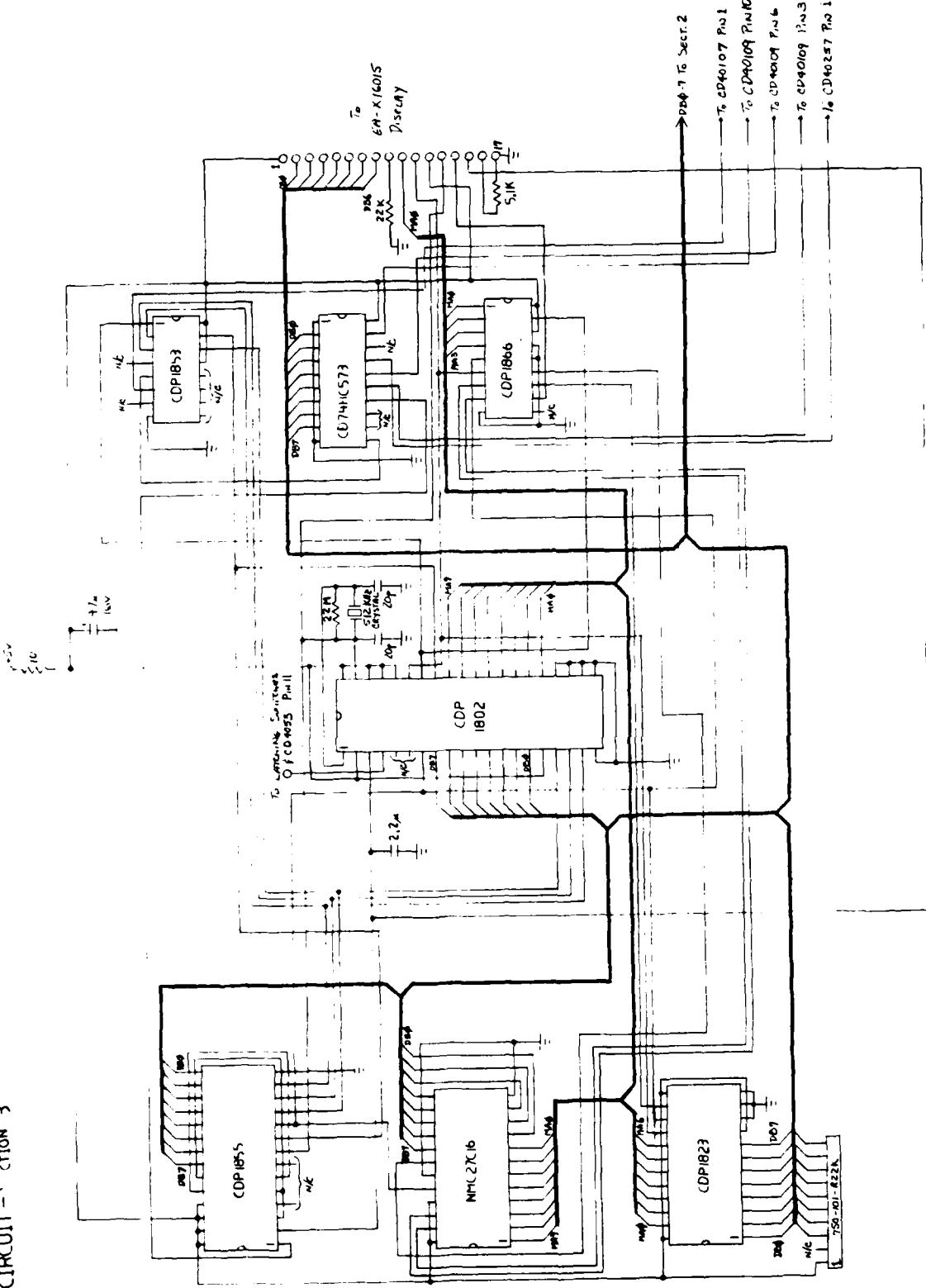


FIGURE 18




FIGURE 19

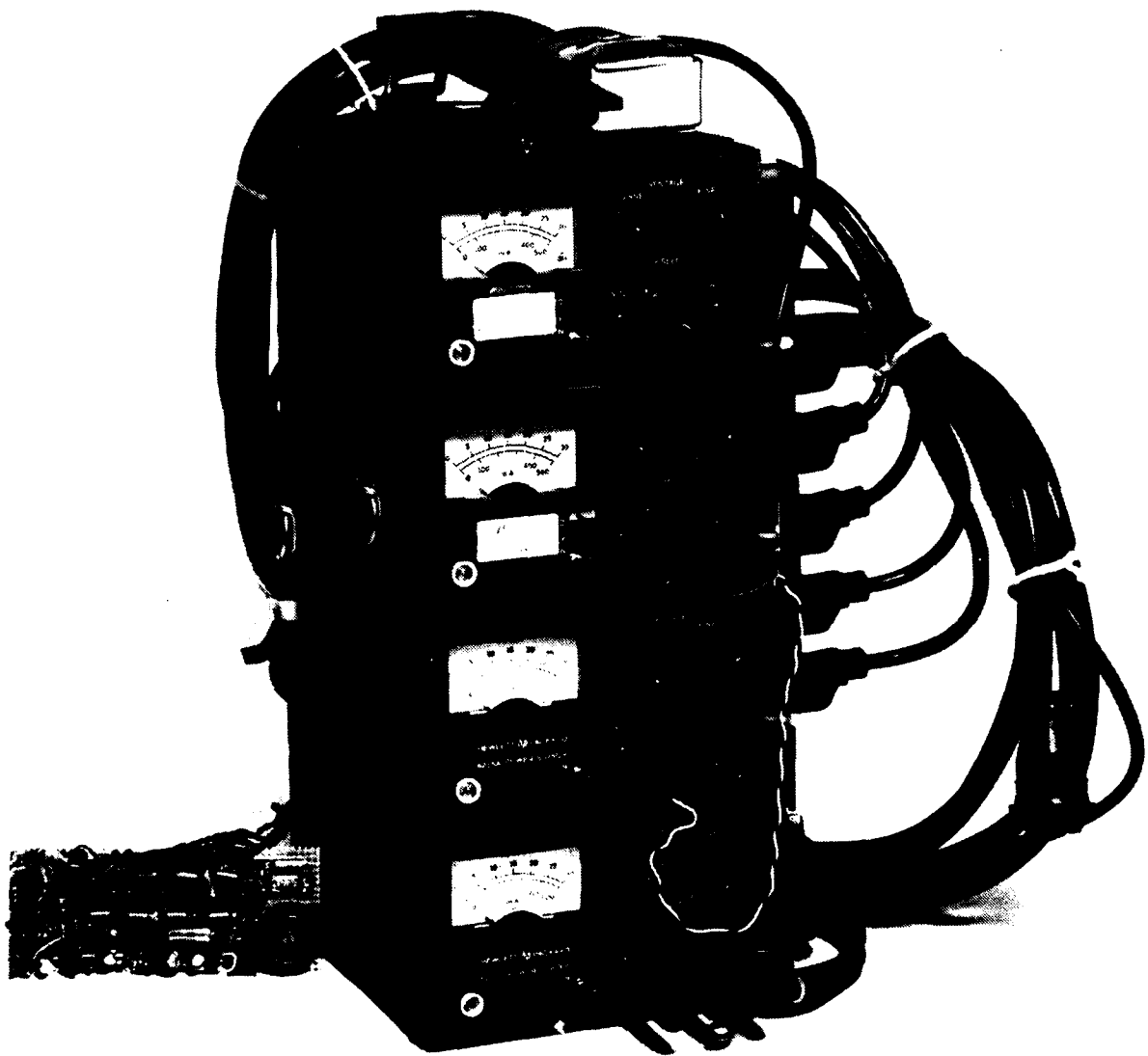


FIGURE 20






FIGURE 22




FIGURE 23




FIGURE 24

END

12-86

DTIC