

2

AD-A240 001



INSTITUTE REPORT NO. 463

# Two Informative Cases of Q-Switched Laser Eye Injury


H. Zwick, B.E. Stuck,  
D. Gagliano, V.C. Parmley,  
J. Lund, J. Molchany,  
J.J. Kearney, and M. Belkin

Division of Ocular Hazards Research

91-09348



July 1991



LETTERMAN ARMY INSTITUTE OF RESEARCH PRESIDIO OF SAN FRANCISCO CALIFORNIA 94129

91 0 00 01 0

Two Informative Cases of Q-Switched Laser Eye Injury, H. Zwick, et al

Destroy this report when it is no longer needed. Do not return to the originator.

Citation of trade names in this report does not constitute an official endorsement or approval of the use of such items.

This material has been reviewed by Letterman Army Institute of Research and there is no objection to its presentation and/or publication. The opinions or assertions contained herein are the private views of the author(s) and are not to be construed as official or as reflecting the views of the Department of the Army or the Department of Defense. (AR 360-5)

*Donald G. Corby*  
DONALD G. CORBY  
COL, MC  
Commanding

*17 July 91*  
\_\_\_\_\_  
(date)

This document has been approved for public release and sale; its distribution is unlimited.

REPORT DOCUMENTATION PAGE

Form Approved  
OMB No. 0704-0188

1a. REPORT SECURITY CLASSIFICATION		1b. RESTRICTIVE MARKINGS	
2a. SECURITY CLASSIFICATION AUTHORITY		3. DISTRIBUTION / AVAILABILITY OF REPORT	
2b. DECLASSIFICATION / DOWNGRADING SCHEDULE		UNLIMITED	
4. PERFORMING ORGANIZATION REPORT NUMBER(S) Institute Report # 463		5. MONITORING ORGANIZATION REPORT NUMBER(S)	

6a. NAME OF PERFORMING ORGANIZATION Letterman Army Institute of Research	6b. OFFICE SYMBOL (if applicable) SGRD-ULY-OH	7a. NAME OF MONITORING ORGANIZATION	
6c. ADDRESS (City, State, and ZIP Code) Division of Ocular Hazards Presidio of San Francisco, CA 94129-6800		7b. ADDRESS (City, State, and ZIP Code)	

8a. NAME OF FUNDING / SPONSORING ORGANIZATION	8b. OFFICE SYMBOL (if applicable)	9. PROCUREMENT INSTRUMENT IDENTIFICATION NUMBER	
8c. ADDRESS (City, State, and ZIP Code)		10. SOURCE OF FUNDING NUMBERS	
		PROGRAM ELEMENT NO. 62787	PROJECT NO. A878
		TASK NO. 878/BA	WORK UNIT ACCESSION NO. WU163

11. TITLE (Include Security Classification)  
Two Informative Cases Of Q-Switched Laser Eye Injury (UNCLASSIFIED)

12. PERSONAL AUTHOR(S) Zwick, H., Stuck, B. E., Gagliano, D., Parmley, V. C., Lund, J., Molchany, J., Kearney, J. J., Belkin, M.

13a. TYPE OF REPORT Institute	13b. TIME COVERED FROM July '89 to July '91	14. DATE OF REPORT (Year, Month, Day) 11 JUL 91	15. PAGE COUNT 23
----------------------------------	--	--	----------------------

16. SUPPLEMENTARY NOTATION

17. COSATI CODES			18. SUBJECT TERMS (Continue on reverse if necessary and identify by block number)		
FIELD	GROUP	SUB-GROUP	parafoveal	scotoma	lesion
			retinal injury	exposure	contrast sensitivity
			Q-switched laser	visual acuity	

19. ABSTRACT (Continue on reverse if necessary and identify by block number)

We describe two cases of parafoveal Q-switched laser retinal injuries which illustrate the variability of the processes set in motion by retinal laser injuries. The first case demonstrates that a parafoveal lesion may cause an immediate degradation in visual functions which may recover spontaneously to almost normal levels. In the second, multiple parafoveal exposure sites produced a central retinal scar at the parafoveal lesion sites and resulted in retinal traction over an extensive region of the retina with local retinal hole formation at the edge of the central scar. A central arcuate absolute scotoma appeared shortly after exposure. The central scotoma, as well as visual acuity, stationary and dynamic contrast sensitivity functions were permanently altered. No treatment presently exists to alleviate or minimize the effects of this retinal scarring process.

20. DISTRIBUTION / AVAILABILITY OF ABSTRACT <input checked="" type="checkbox"/> UNCLASSIFIED/UNLIMITED <input type="checkbox"/> SAME AS RPT <input type="checkbox"/> DTIC USERS		21. ABSTRACT SECURITY CLASSIFICATION UNCLASSIFIED	
22a. NAME OF RESPONSIBLE INDIVIDUAL DONALD G. CORBY, COL, MC, Commanding		22b. TELEPHONE (Include Area Code) (415) 561-3600	22c. OFFICE SYMBOL SGRD-ULY-X-AD

**ABSTRACT**

We describe two cases of parafoveal Q-switched laser retinal injuries which illustrate the variability of the processes set in motion by retinal laser injuries. The first case demonstrates that a parafoveal lesion may cause an immediate degradation in visual functions which may recover spontaneously to almost normal levels. In the second, multiple parafoveal exposure sites produced a central retinal scar at the parafoveal lesion sites and resulted in retinal traction over an extensive region of the retina with local retinal hole formation at the edge of the central scar. A central arcuate absolute scotoma appeared shortly after exposure. The central scotoma, as well as visual acuity, stationary and dynamic contrast sensitivity functions were permanently altered. No treatment presently exists to alleviate or minimize the effects of this retinal scarring process.



A-1

**TWO INFORMATIVE CASES OF Q-SWITCHED LASER EYE INJURY --**  
H. Zwick, B. E. Stuck, D. Gagliano, V. C. Parmley, J.  
Lund, J. Molchany, J. J. Kearney, M. Belkin

**Introduction**

The damage to vision caused by laser exposure of the retina depends primarily on the amount of energy absorbed in the eye - the higher the energy, the higher the damage (1,2,3,4). However, the location of the lesion is just as important. Foveal or parafoveal lesions may reduce visual performance, while lesions of the peripheral retina might go unnoticed if significant hemorrhage does not occur.

The pathogenesis of foveal and parafoveal lesions depends on the body's reaction as well. The immediate effect is a decline in visual function which may occur as a result of direct destruction of foveal photoreceptors or associated neural pathways by the laser radiation. Foveal involvement in the inflammatory process and retinal edema spreading from parafoveal lesions, or by retinal, preretinal, or vitreous hemorrhage represent another immediate retinal damage process from laser exposure. The long-term effects of the injury depend on the retinal healing processes which determine whether the inflammation will resolve with restoration of the photoreceptor mosaic or whether the scarring process will prevent recovery of visual functions.

We describe two cases of parafoveal retinal injuries which illustrate the variability of the processes set in motion by retinal laser injuries.

The first case demonstrates that a parafoveal lesion may cause an immediate degradation in visual functions which may recover spontaneously to almost normal levels. The other case demonstrates that the scarring process triggered by the parafoveal lesions can be detrimental to visual recovery.

Animal investigations (5,6,7,8) involving foveal damage have often revealed recovery from severe deficits in visual acuity. Such recovery requires from 1 to 6 months after exposure depending on the extent of foveal damage. Studies in which the entire fovea has been destroyed require the longest periods of recovery. On the other hand, studies involving minimal spot threshold damage exposures may require 20 minutes for recovery, although repetitive exposure often results in delayed permanent change in spatial visual function (4,9). Some investigators have suggested that the retinal capacity for recovering visual acuity may involve passive or

active foveal photoreceptor realignment and movement to reestablish both the density of the foveal receptor matrix and its orientation toward the pupillary plane. Although the retinal receptor mosaic may appear near normal in receptor matrix density, the spectral sensitivity of the foveal area might remain significantly altered because damaged foveal receptors may be replaced with parafoveal photoreceptor elements which are functional, but which have different photopigments (7).

Recent human laser eye accidents point to retinal complications secondary to the insult itself. The complications might delay or further impede visual acuity recovery. Such effects may counter passive or active movement of photoreceptors so that foveal repopulation is retarded or halted. Scarring processes such as the development of macular pucker or retinal traction bands emanating from the lesion may represent such a secondary mechanism. In one case, accidental foveal exposure to a single infrared Q-switched laser pulse was associated with development of macular pucker (i.e. retinal traction bands) noticed 1 month after exposure. Visual acuity initially recovered, but with the onset of pucker, it decreased to 6/60 (10). Similarly, macular pucker developed 4 months after multiple parafoveal exposure from a Q-switched repetitively pulsed neodymium laser source (11). Visual acuity in this case measured over a 1 year time period remained at 20/40 even though all exposure sites were parafoveal. Retinal traction in both these cases may have retarded or halted passive movement of parafoveal receptors thereby adversely affecting the visual acuity recovery process described above. Furthermore, in both these cases concern was raised regarding subsequent development of retinal holes that might be produced by the traction forces associated with central scar formation (10,11). While retinal holes have been reported in association with vitreous hemorrhage (1), they have not been previously reported in association with retinal scarring.

#### **Methods:**

The two patients were interviewed to obtain their descriptions of the accidents and were evaluated by ophthalmoscopy, fluorescein (case 2 only), Snellen visual acuity, Amsler grid, color vision, dark adaptation, contrast sensitivity, and electroretinography (ERG). The Amsler grid was used to map the absolute changes in the central visual fields. The area of the absolute scotoma was digitized using a Delta Technologies Image Processing system. Color vision testing consisted of monocular testing with Ishihara plates and the Farnsworth-Munsell 100-

Hue test. Spectral dark adaptation was measured by an LED dark adaptometer using long and intermediate wavelength LED sources for either foveal or parafoveal adaptation (12,13). Two contrast sensitivity tests were administered: the Nicolet CS2000 and the Neuroscientific contrast sensitivity test. Both these tests used the CS2000 video monitor. The CS2000 test was run under normal room illumination (100 nits). The neuroscientific test was run in ambient illumination (10 nits). The CS2000 provided stationary measurements of contrast sensitivity, whereas, both stationary and 8 Hz temporally modulated contrast sensitivity (dynamic) were measured for the Neuroscientific test. Measurements of the ERG were made under both light and dark adapted conditions. Light adaptation was achieved by 15 minute hemispheric exposure at 40 cd/m<sup>2</sup>. ERG waveforms were evoked at four flash intensities ranging from 0.07 to 0.18 microjoules/cm<sup>2</sup>. Photopic flash stimuli were flickered at 5 Hz.

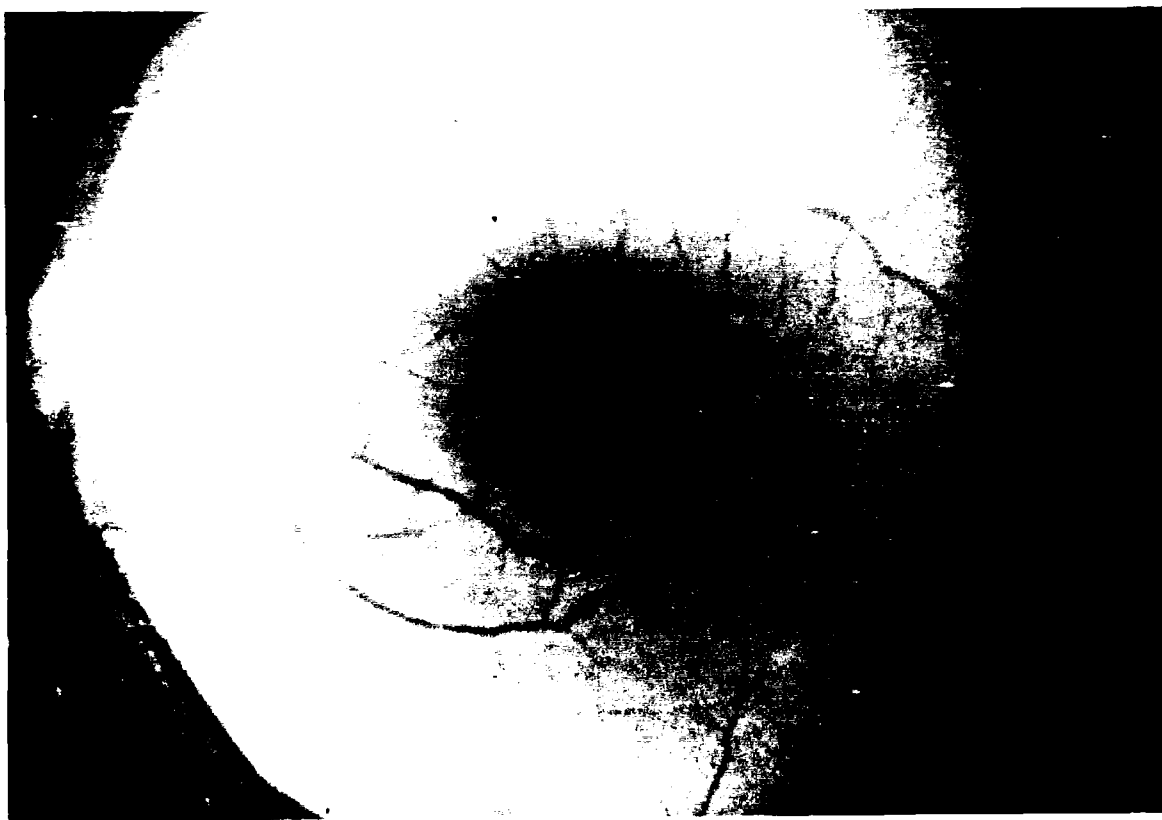
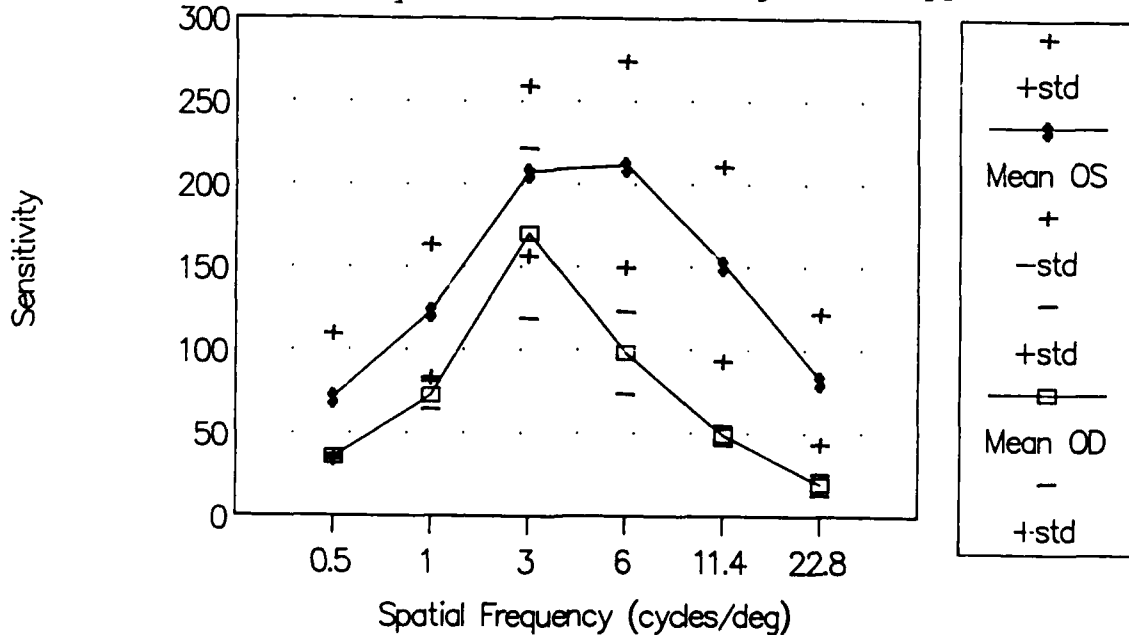


Figure 1. Case 1 at 5 weeks postexposure

**Results**

Case 1. The right eye of this 29 year old individual was accidentally exposed to a single 5mJ (estimated) Q-switched Nd:YAG laser. The beam was centered on a point half a disc diameter superior to his fovea. The patient reported an immediate and very significant reduction in the visual acuity of this eye. The left eye was unaffected. When we examined the individual 5 weeks later, visual acuity of the injured eye was 6/15 (20/50). Ophthalmoscopy (Fig 1) revealed a minute dark lesion surrounded by a pale halo which was in turn surrounded by an oval, hyper-pigmented zone which included the fovea. Over ten weeks of observation without treatment the visual acuity recovered to 6/7.5 (20/25) while no change in ophthalmoscopic appearance occurred. The small (1.5°) scotoma which the individual had perceived above the point of fixation disappeared at his last examination.

Measurement of color vision, spectral dark adaptation, and ERG were all within normal range. Contrast sensitivity measured in the unexposed eye relative to the exposed eye is shown in Figure 2. Loss in contrast sensitivity is greater for the higher spatial frequencies. A postexposure shift in peak stationary contrast sensitivity from 6 to 4 Hz/degree is apparent.



**Figure 2. Stationary Contrast Sensitivity Case 1. (OS vs OD).**

Recovery in contrast sensitivity over a 65 day postexposure period is shown in Figure 3. Although both eyes increased in sensitivity during this period, the difference in contrast sensitivity between eyes decreased as well.

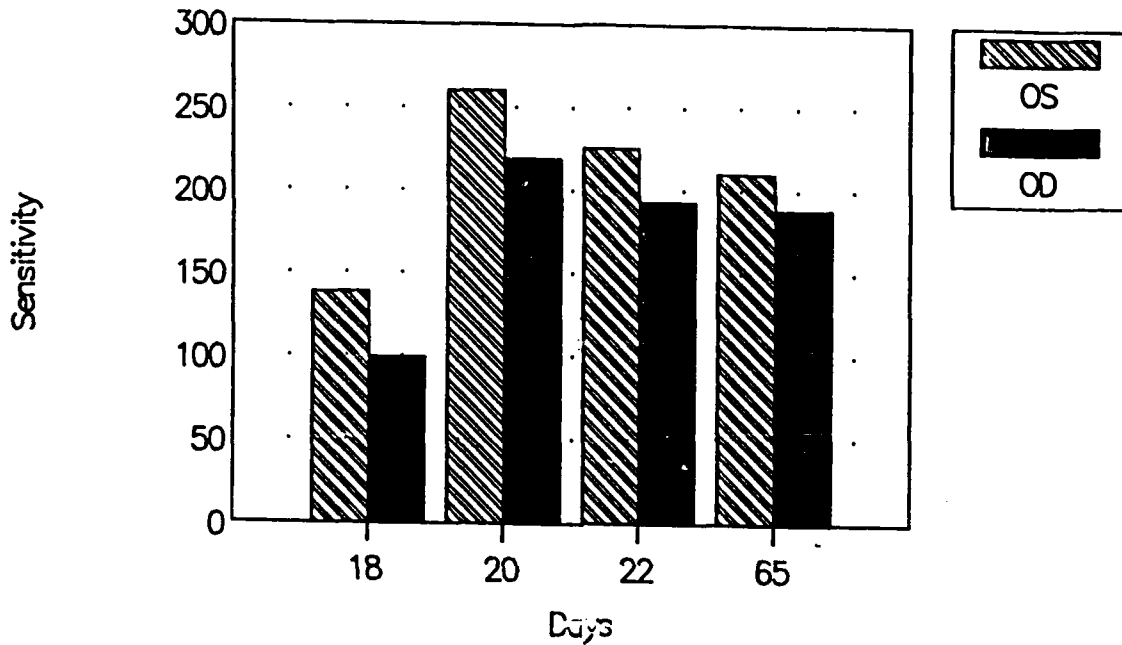


Figure 3. Recovery of contrast sensitivity at 3 Hz/deg for case 1.

Amsler grid measurements made 5 weeks postexposure revealed a small parafoveal scotoma (Fig 4). Approximately two months later this scotoma had reduced in size and was no longer measurable on the Amsler grid, although a small paracentral disturbance was still reported by the patient.

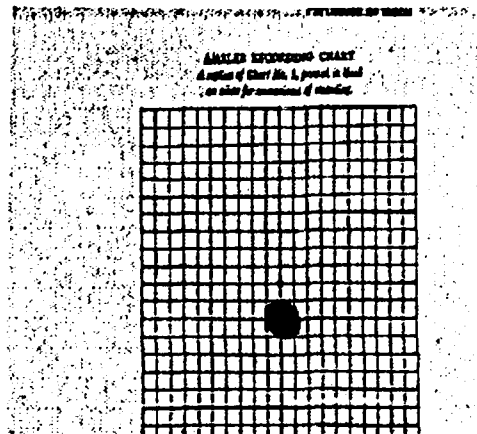


Figure 4. Amsler grid parafoveal scotoma Case 1.

Case 2. This 19 year old patient accidentally exposed himself to at least 4 ND:YAG laser pulses of 5 mJ (estimated) per pulse from a military hand held laser rangefinder. (The patient had limited experience with this type of laser and apparently was unaware that its infrared laser emission was outside of the visible range.) Exposure caused an immediate reduction in visual acuity. On examination by an ophthalmologist one day following exposure, two severe, one moderate, and one or two minor retinal burns were found. The two intense burns were located approximately 0.5 mm from the fovea, and the others were further away. The intense lesions had the appearance of a retinal explosion from within, and formation of central retinal holes surrounded by four retinal flaps (Figure 5a). The two major lesions and one moderate lesion were amid a wide zone of deep retinal edema with the fovea in its center.

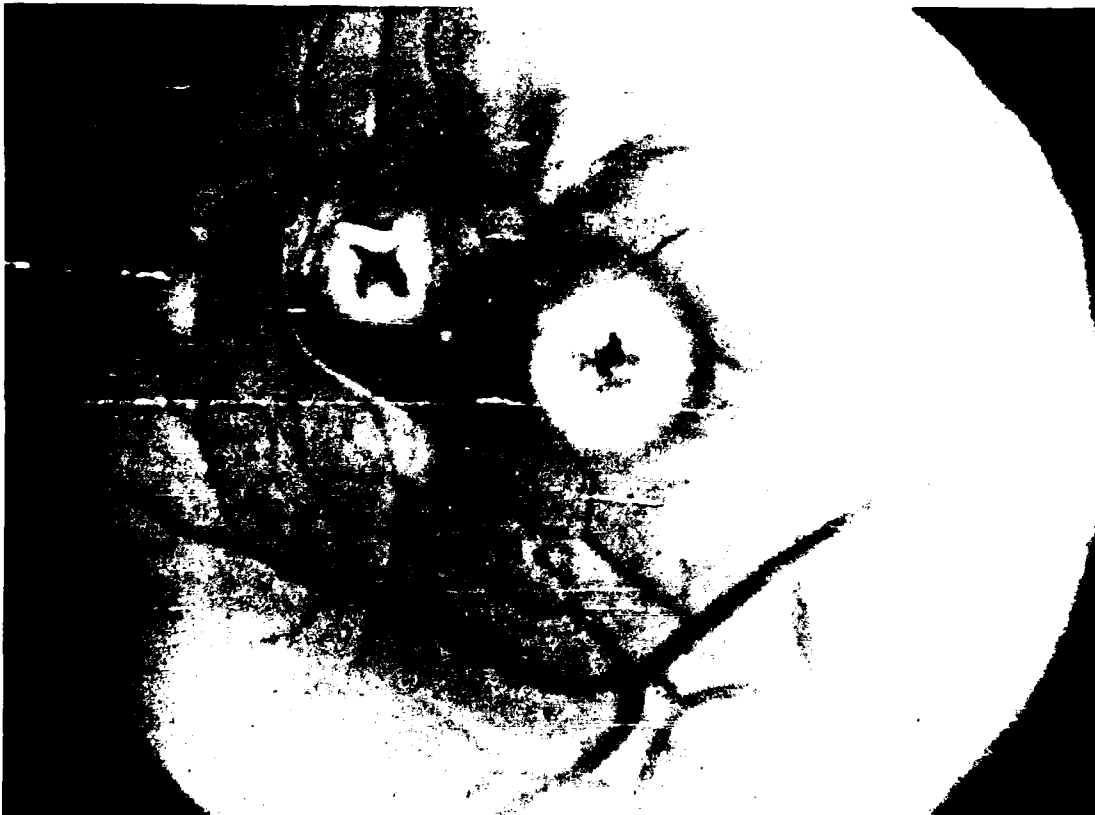
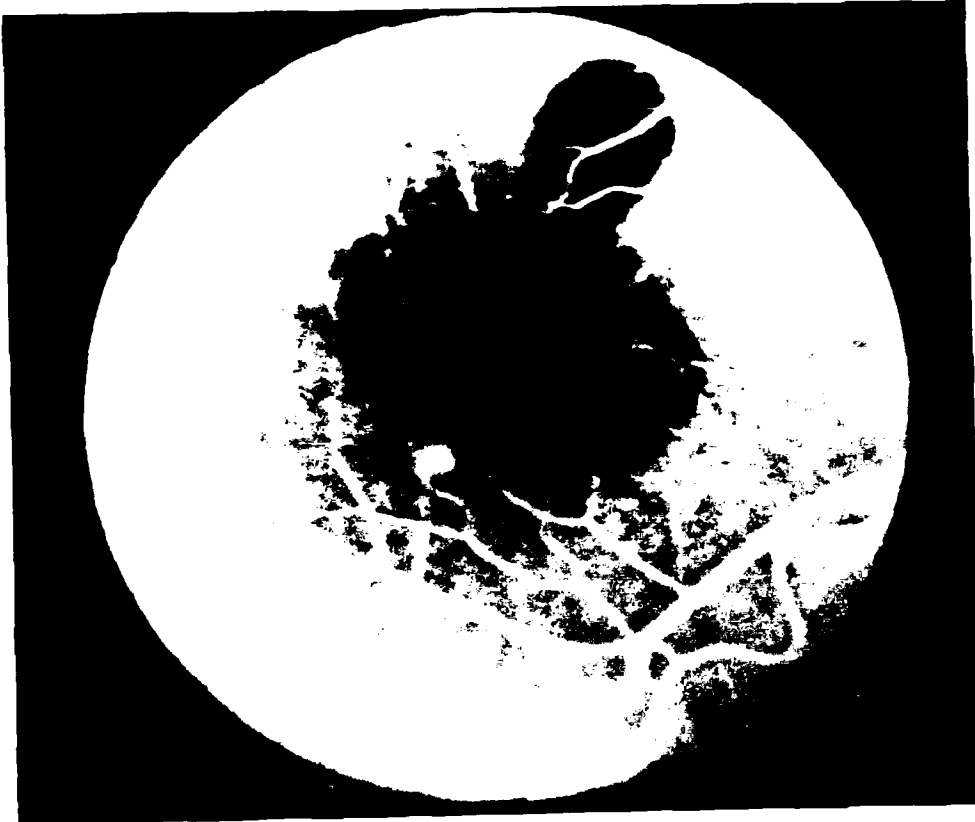


Figure 5a. Case 2- Five days postexposure.



**Figure 5b. Fluorescein angiography five days postexposure.**

Fluorescein angiography, performed 5 days after the accident (Fig 5b), demarcated three lesions, each surrounded by a well circumscribed zone of deep edema, about a disc diameter in size. This edematous zone blocked the choroidal fluorescence, while the area immediately around the center of the lesion exhibited autofluorescence which appeared early in the injection. The edematous zones were confluent and involved the foveal area.

Extensive scarring activity ensued in the posterior pole of the injured eye. As early as two weeks after the



**Figure 5c Two weeks postexposure.**

injury (Fig 5c) both deep burns were scarred with their holes sealed. The scar extended between the two lesions, over the fovea, and into the surrounding retina. The scarring continued unabated and one month after the injury, a thick, pigmented, lobulated scar covered the central part of the posterior pole, including the foveal area. Contraction of the scar created retinal holes at the tips of the scar's lobules and traction lines appeared radially around the lesions (Fig 5d).

Visual acuity examined during the first week and thereafter measured at least 20/200 using eccentric viewing. Visual acuity was not measurable when the patient was asked to view the acuity chart with central vision.

Amsler grid measurements made during the first 6 months postexposure showed a large arcuate scotoma that decreased in size by nearly one-half during this time with intermittent appearance of fragment scotomas away from the central scar (Fig 6). This absolute scotoma was surrounded by a region of relative scotoma extending through most of the visual field.

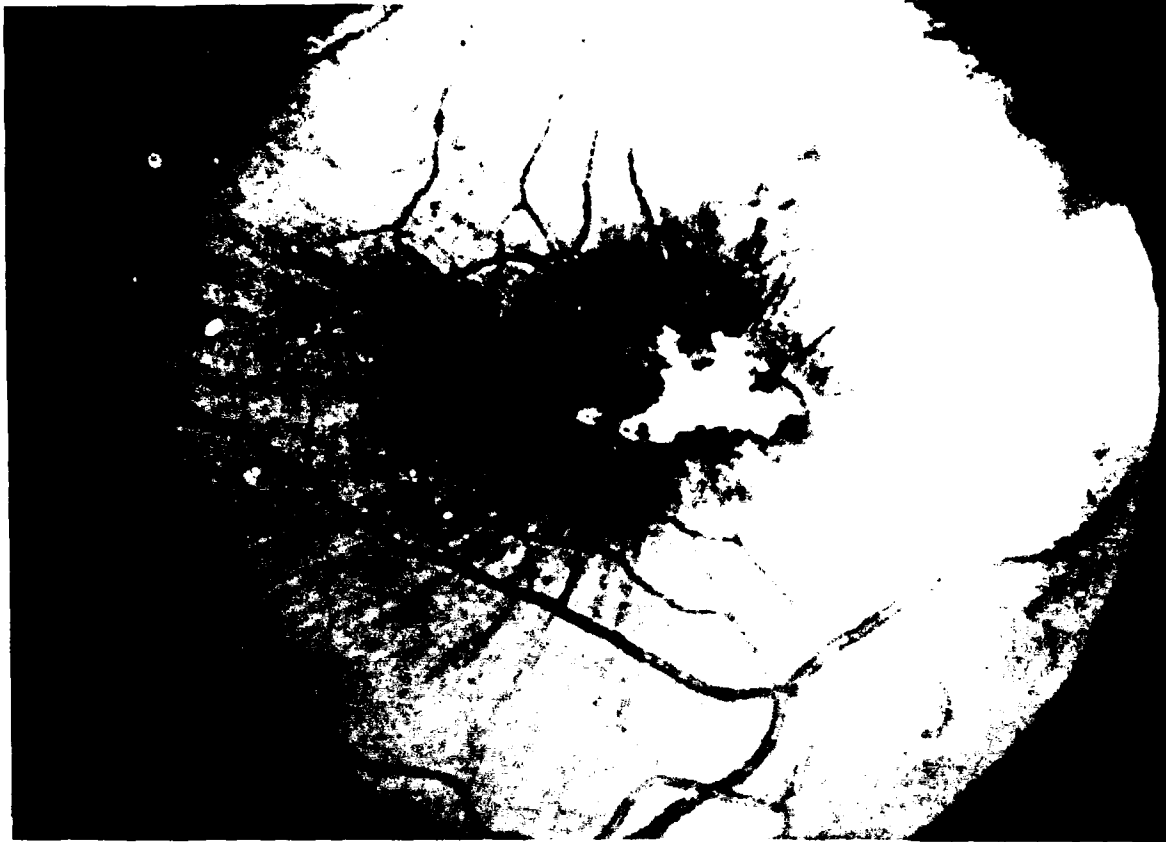


Figure 5d. One month postexposure.




Figure 6. Amsler grid measurements Case 2

Measurements of color vision using the Farnsworth 100-Hue test revealed extensive loss in color discrimination with a noisy red-green axis. If fixation requirements were relaxed, the patient could identify the color of the chips or dots in both this test and the Ishihara color plate test. It appeared that he had nearly normal color vision when allowed to use a region of his visual field that was not obscured by the absolute scotoma.

Similarly, the central scotoma affected measurements of central dark adaptation to a greater degree than those measurements taken in the peripheral retina. Central retinal measurements were consistently more than two standard deviations above the norm whereas peripherally determined measurements were within normal limits and reflected the normal peripheral relationships between red and green LED test sources (11,12).

The results of stationary contrast sensitivity measurements are shown in Figure 7. Horizontal bars represent the standard deviation about the mean sensitivity for each spatial frequency. This patient, as was the case with the first patient, shows a shift in contrast sensitivity from a peak at six cycles per degree to four cycles per degree. Unlike the first patient, the second patient shows significant loss in contrast sensitivity over the entire range of spatial frequencies tested.

Comparison of stationary and dynamic contrast sensitivity measurements reveals a differential spatial frequency sensitivity loss between the eyes. The stationary contrast sensitivity of the affected eye is reduced and shifted toward the lower spatial frequencies. The maximum difference between the eyes occurs at three and four cycles per degree (Fig 8a). For dynamic contrast sensitivity, the maximum difference occurs at the lowest spatial frequency, one cycle per degree (Fig 8b). Figure 9 shows the maximum difference sensitivity between the eyes for both the stationary and the dynamic contrast sensitivity tests. A 3-way analysis of variance shows a significant interaction of eye, test type (stationary vs dynamic), and spatial frequency ( $p < .01$ ). A least squares difference test on these data indicates that the interaction of eye vs spatial frequency is differentially affected for stationary vs dynamic contrast sensitivity test spatial frequencies.

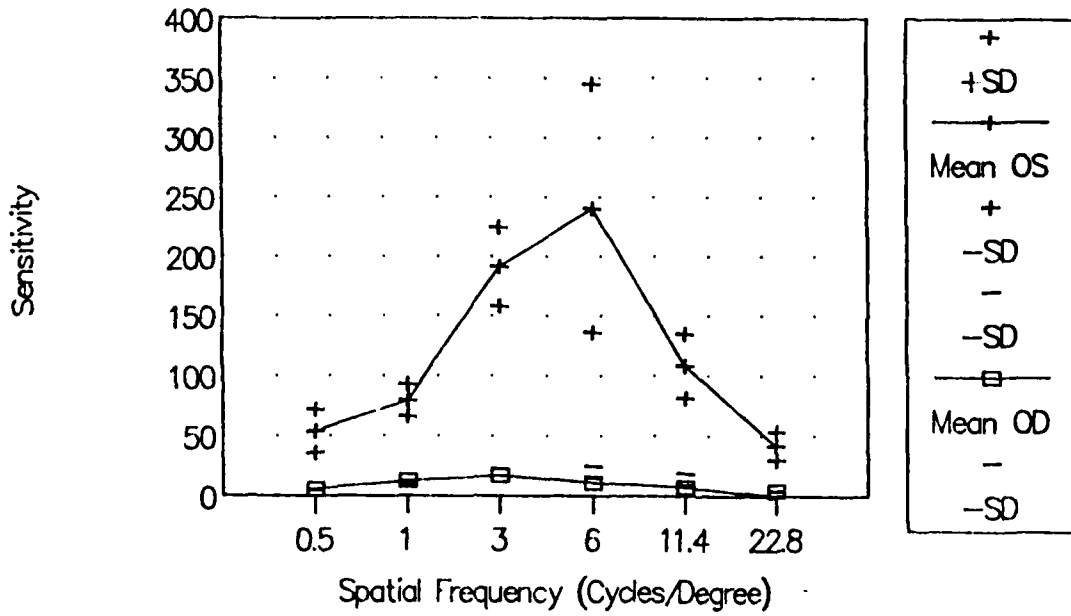


Figure 7. Stationary contrast sensitivity - Case 2 (OS vs OD)

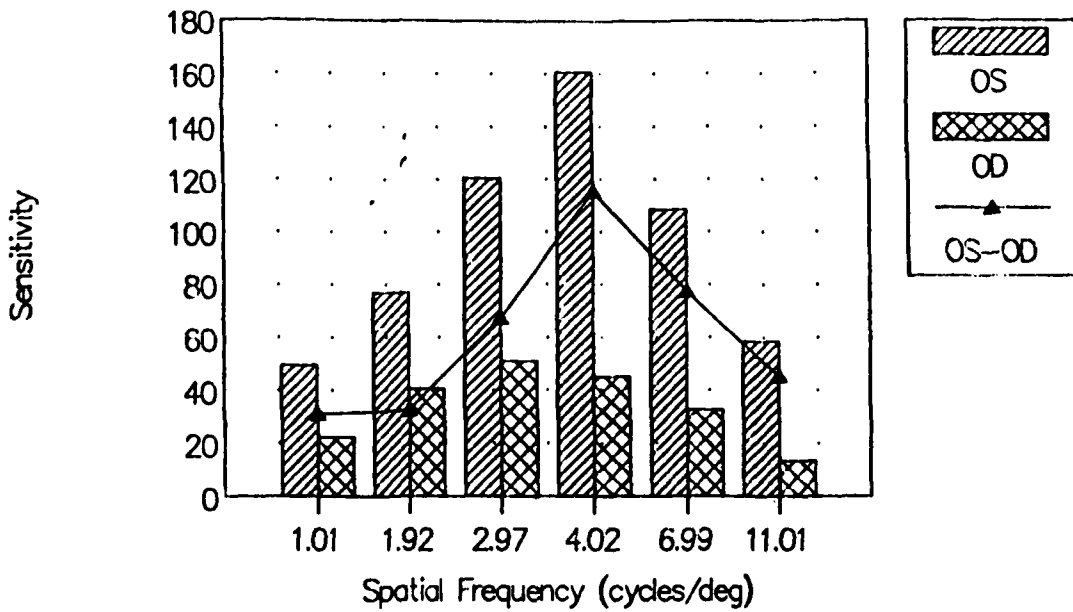


Figure 8a Stationary contrast sensitivity - Case 2

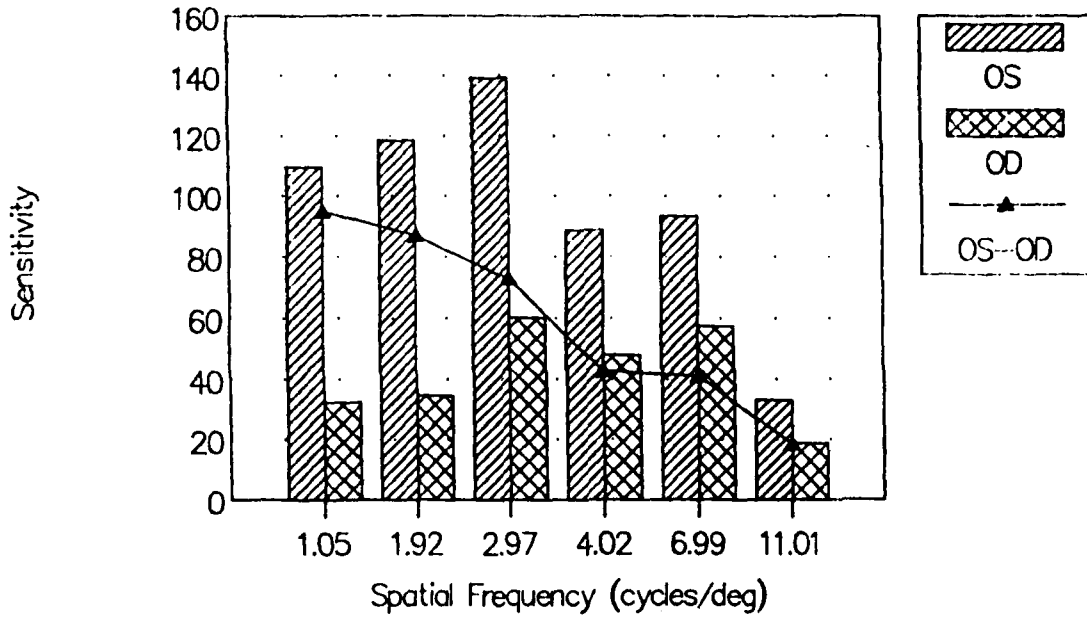


Figure 8b Dynamic Contrast sensitivity - Case 2

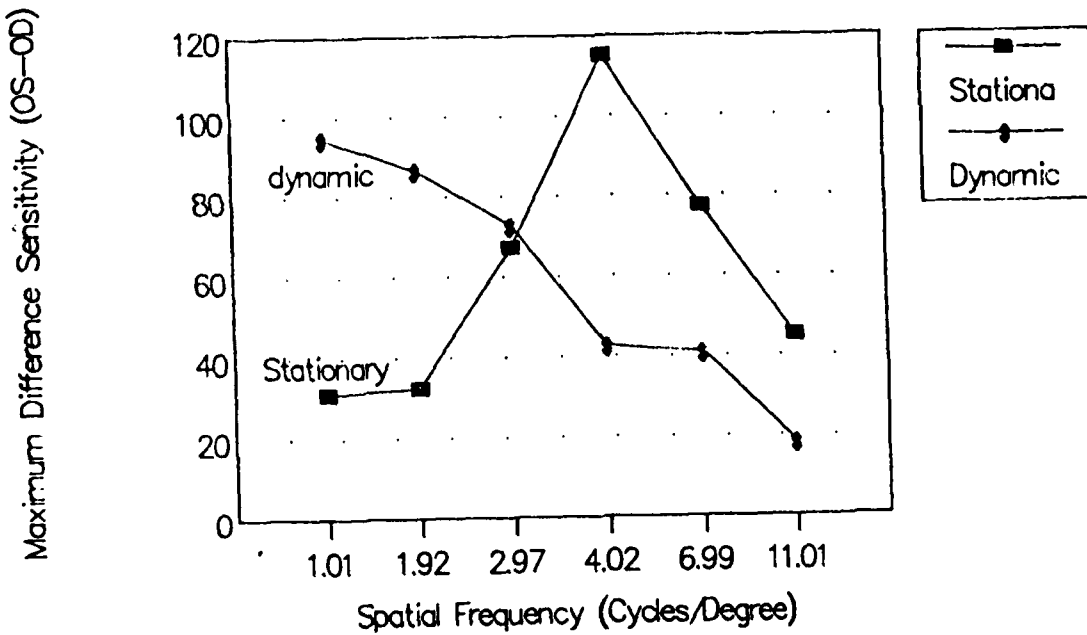
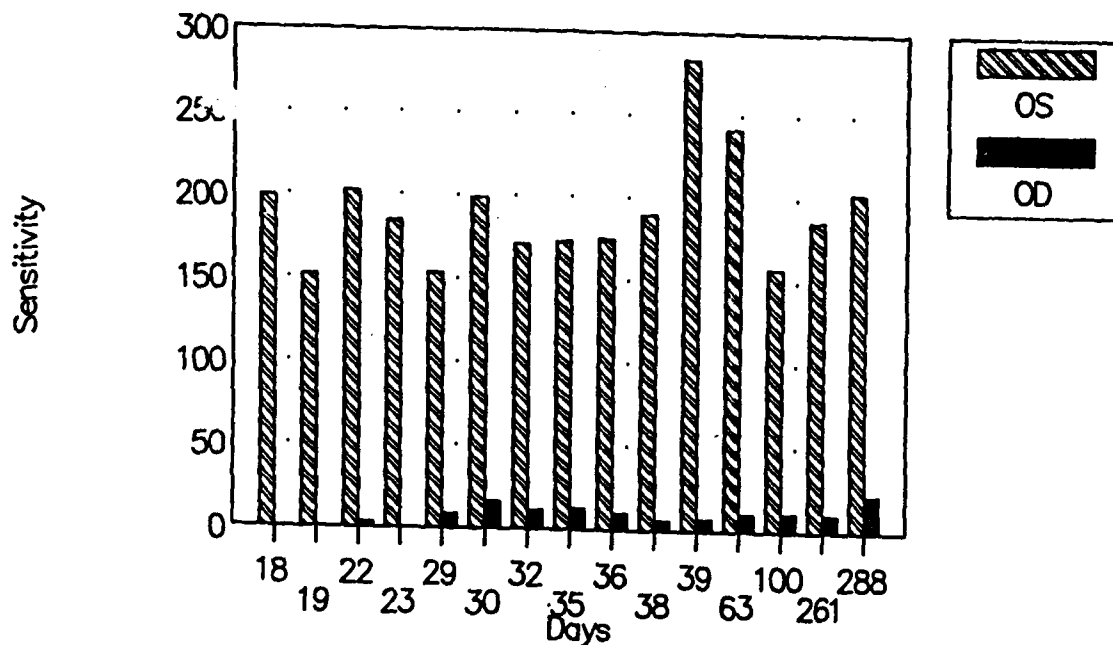


Figure 9 Maximum difference sensitivity between eyes for stationary and dynamic contrast sensitivity.

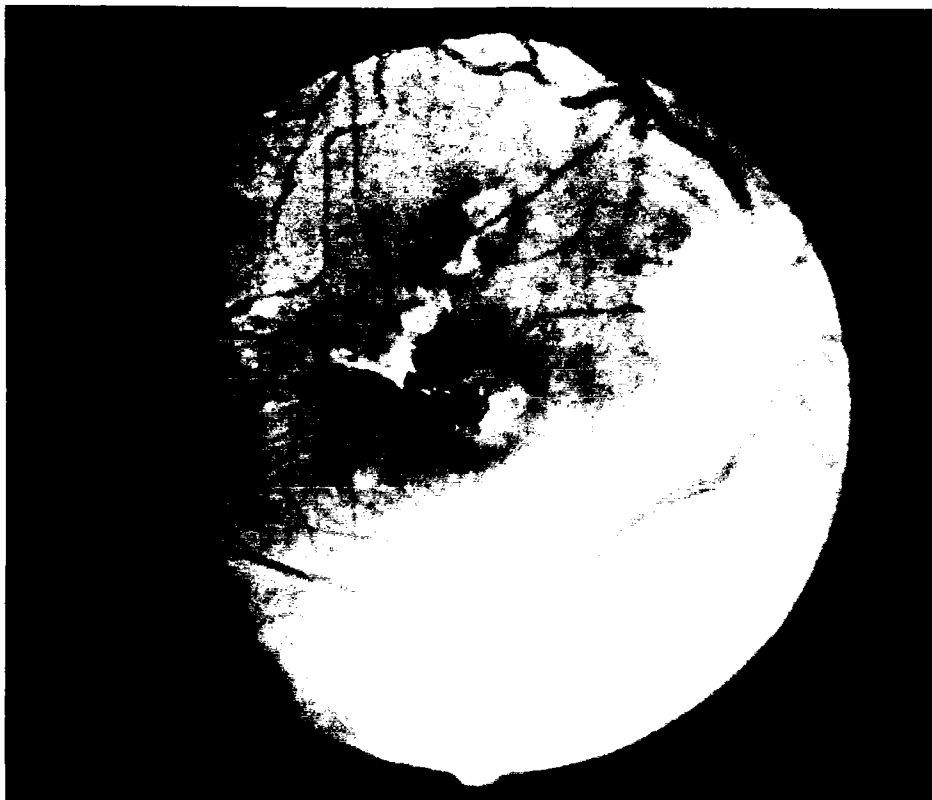


**Figure 10 Contrast sensitivity recovery - Case 2.**

In Figure 10, stationary contrast sensitivity (Nicolet) shows little or no recovery during approximately 7 months of postexposure testing at three cycles per degree. Comparable recovery functions were obtained for all spatial frequencies measured in the stationary contrast sensitivity test.

Electroretinographic measurements revealed alteration in scotopic function in the exposed eye relative to the unexposed eye. As test light intensity increased, the difference between the two eyes (ratio) decreased from 0.82 to 0.42. Photopic ERG measurements showed no difference between eyes.

Further retinal changes and visual function deterioration occurred between 10 and 14 months after exposure. The central retinal scar became deeply pigmented and contracted (Fig 11). All the retinal holes but one healed and the remaining one did not enlarge. The relative scotoma region surrounding the absolute scotoma darkened and was accompanied by a reduced tolerance for central glare in the affected eye. Photophobic reactions were commonly observed in bright daytime light or clinical light sources.



**Figure 11. Retina Case 2 10-14 months postexposure.**

### **Discussion**

We have described two accidental laser exposure cases that illustrate simple and more complex variations of parafoveal retinal damage effects on visual function. In the first case, a single parafoveal exposure from a Q-switched neodymium laser rangefinder produced immediate loss of central vision. An immediate and central relative scotoma was described by this patient, even though the lesion was half a disc diameter from the fovea. This may be the first well-documented report of a parafoveal lesion inducing visual acuity loss in the absence of acute secondary complications such as hemorrhage, scarring, and retinal traction (1,2,3).

Several explanations might be offered for the effects of parafoveal damage on visual acuity reduction. First, the ensuing edema might have spread sufficiently to encompass the foveal region. However, the patient

reported that a concentric scotoma centrally located in the visual field appeared and became absolute within 24 hours. If fluid leakage alone were involved, one would expect this concentric scotoma to be located off the visual axis and appearing slightly eccentric to the center of the visual field.

Alternatively, foveal photoreceptors might have been damaged without alteration in ophthalmoscopic appearance. Adams, Beatrice, and Bedell (14) demonstrated that outer-segment photoreceptor alteration, disorientation of outersegment lamelli, could be disrupted by a Q-switched Ruby laser exposure not sufficient to produce ophthalmoscopically visible retinal alterations. Again, one might expect that this effect would be concentric around the parafoveal lesion site. No evidence of serious peripheral functional alteration was found in case 1, although significant low frequency contrast sensitivity loss was obtained in case 2. In case 1, however, contrast sensitivity losses were restricted mainly to high spatial frequencies.

More subtle factors might have been involved. Damage to the normal orientation of parafoveal photoreceptors might have induced mechanical or neural change in the communication which normally exists between foveal and parafoveal photoreceptors. It is possible that the immediate, temporary reduction in visual function was a result of all of these mechanisms.

The second case of accidental parafoveal exposures was complicated by the multiple damage sites induced by laser exposure. Visual function failed to recover. This failure was evidence of continuing deterioration 14 months after the injury.

Failure to recover in case 2 was due to both the extent of central retinal damage as well as the formation of retinal scars radiating from the central lesions. Spatial vision loss was severe and distributed over the entire spatial frequency spectrum, indicative of sensitivity dysfunction in both foveal and parafoveal spatial contrast. Dynamic measures of contrast sensitivity, which normally measure peripheral retinal function, showed maximal low frequency sensitivity loss in the affected eye. Electrophysiological measurements of ERG scotopic function suggested peripheral retinal dysfunction as well. Parafoveal scar tissue has either replaced or altered the normal orientation of the photoreceptors, thereby reducing their sensitivity.

On the other hand, the color vision of this patient reflects the basic differences in retinal physiology between spatial and color vision mechanisms. Spatial visual function depends less on the presence of individual receptor types than on the matrix of detector elements maintained intact with regard to interphotoreceptor distance and orientation; color vision requires three qualitatively different receptor systems with less dependence on the above spacing parameters. It is likely that sufficient numbers of cone photoreceptors in the parafoveal regions provided an adequate retinal color vision system whereas normal photoreceptor packing and orientation were severely altered, thus causing a severe loss of spatial visual function in both the foveal and peripheral retinal regions. Furthermore, the rigidity of fibrotic scar tissue was probably a significant factor in preventing the return of a more normal photoreceptor orientation and thereby, normal visual sensitivity.

The formation of retinal holes and their subsequent reattachment is unique in this case. No such observations have been noted in any previously reported laser accident cases, although their occurrence in the present case was not totally unexpected. The severe local scarring process in each of the holes provided local "welds" that prevented more extensive retinal detachment. Whether such welds reflect the natural course of such injuries cannot be determined from the present case, although such scarring processes do occur in other forms of retinal trauma.

### **Conclusion**

In summary, we have presented two new cases of laser accidental exposure. The first case demonstrated that foveal acuity loss can be experienced even if the exposure is peripheral to the fovea. The mechanism of this loss is not clear, but could involve edema leakage from the damaged site, photoreceptor matrix disturbance, photoreceptor outersegment alteration, and mechanical modulation of the foveal receptor orientation via parafoveal injury. Case 2 involves similar processes, but is additionally complicated by central retinal scar formation and retinal traction. These scarring mechanisms probably prevented recovery. The functional consequence of the scarring is reflected in low spatial frequency loss observed in contrast sensitivity measured for stationary and dynamic contrast sensitivity tests as

well as peripheral ERG. The natural course of such hole formation is unclear at the present time, but under the present circumstances healing occurred via the scarring over of these holes.

Development of future drug therapies (15) for such laser injury should include morphological and functional endpoints which evaluate primate retinal damage models for both the inflammatory and the scarring processes.

### References

1. Wolfe JA. Laser retinal injury. *Milit Med* 1984;150:170-185.
2. Boldrey EE, Little HL, Flocks M, Vassiliadis A. Retinal eye injury due to industrial laser burns. *Ophthalmology* 1981;88:101-107.
3. Pieven C. A description of fourteen accidents caused by lasers in a research environment. In: Court LA, Duchene A, Courant D, ed. *First International Symposium on Laser Biological Effects and Exposure Limits: Lasers et Normes de Protection* Paris, November 1986:406-417.
4. Lang GK, Lang G, Naumann GOH. Akzidentelle Bilaterale asymmetrische Rubin-Laser-Makulopathie. *Klin Mbl Augenheilk* 1985;186:366-370.
5. Zwick H. Visual function changes associated with low-level light effects. *Health Physics* 1989;56: 657-663.
6. Tso M. Photic maculopathy in rhesus monkey. *Invest Ophthalmol* 1973;12:17-34.
7. Zwick H, Bedell RB, Bloom KR. Spectral and visual deficits associated with laser irradiation. *Mod Prob Ophthalmol* 1974;13:299-306.
8. Zwick H, Bloom KR, Beatrice ES. Permanent visual change associated with punctate foveal lesions In: Drum B, Verriest G, eds. *Colour Vision Deficiencies IX*. Annapolis, MD, July 1987;251-260.
9. Merigan WH, Pasternak T, Zehl D. Spatial and temporal vision of macaques after central retinal lesions. *Invest Ophthalmol* 1981;21:17-26.
10. Glovinsky Y, Regenbogen L, Bartov E, Blumenthal M. Macular pucker following accidental laser burn. *Metabolic, Pediatric, and Systemic Ophthalmology*. 1982;6:355-359.
11. Kearney JJ, Cohen HB, Stuck BE, Rudd GP, Beresky DE, Wertz FD. Laser injury to multiple retinal foci. *Lasers in Surgery and Medicine* 1987;7:499-502.
12. Zwick H, Garcia TA, Beatrice ES, Bloom KR. Effects of broadbanded eye protection on dark adaptation. *LAIR Laboratory Note*. 1986, #86-58,1-11.

13. O'Mara PA, Zwick H, Beatrice ES, Lund DJ. Micro-processor controlled light-emitting diode dark adaptometer. Med Biol Eng Comp 1982;20:70-76.

14. Adams DO, Beatrice ES, Bedell RB. Retina: Ultrastructural alterations produced by extremely low levels of coherent radiation. Science 1972;177:58-59.

15. Naveh N, Weissman C. Corticosteroid treatment of laser retinal damage affects prostoglandin E<sub>2</sub> response. Investigative Ophthalmology. 1990;31: 9-13.

Acknowledgements: We express our sincere appreciation for the clinical efforts and clinical data analysis provided by S. Ruiz and N. Echano of the Visual Clinic, Division of Ocular Hazards, Letterman Army Institute of Research.

OFFICIAL DISTRIBUTION LIST (CON'T)

OTSG  
ATTN: TSG-PSP/COL Day  
5109 Leesburg Pike  
Falls Church, VA 22041-3258

DIRECTOR  
US Army AMMRC  
ATTN: AMXMR-O/Fitzpatrick  
Watertown, MA 02172-0001

COMMANDER  
USA Aviation Systems Cmd  
ATTN: AMCPM-ALSE/H. Lee  
4300 Goodfellow Blvd  
St. Louis, MO 63120-1798

DIRECTOR  
Defence Intelligence Agency  
ATTN: DT-5A/H. Hock  
Washington, DC 20340-6053

COMMANDER  
USA Aeromed Research Lab  
ATTN: SGRD-UAC-D/COL Karney  
SGRD-UAC-D/COL Wiley  
Ft. Rucker, AL 36330-5000

DIRECTOR  
EWL/RSTA  
ATTN: AMSEL-EW-C/J. Allen  
Ft. Monmouth, NJ 07703-5303

COMMANDANT  
USA Infantry School  
ATTN: ATSH-CMD-D/Ken Sines  
Ft. Benning, GA 31905-5400

COMMANDER  
Letterman Army Institute of  
Research  
ATTN: SGRD-ULZ (1 copy)  
SGRD-UL-IR (7 copies)  
Presidio of San Francisco  
California 94129-6800

DIRECTOR  
DARPA  
ATTN: DARPA/DSO-Dr. Durvasula  
1400 Wilson Blvd  
Arlington, VA 22182

COMMANDER  
CNVEO  
ATTN: SFAE-IEN-NV(COL Michlik)  
Ft Belvoir, Va 22060

DIRECTOR  
Armed Forces Medical  
Intelligence Center  
ATTN: AFMIC-SA/MAJ Krikorian  
AFMIC-SA/MAJ Holahan  
Fort Detrick, MD 21701-5004

DIRECTOR  
DTD Directorate  
ATTN: EOGWCM-CCM  
WSMR, NM 88002-5519

COMMANDER  
HQ TRADOC  
ATTN: ATCD-ML/J.Gray  
Ft. Monroe, VA 23651-5000

DIRECTOR  
USA HEL  
ATTN: AMXHE-IS/D. Giordano  
Aberdeen Proving Grounds  
Maryland 21005-5001

PRESIDENT  
USA Armor & Engr Board  
ATTN: ATZK-AE  
Ft. Knox, KY 40121

COMMANDER  
USAMRDC  
ATTN:SGRD-PLC  
Fort Detrick  
Frederick, MD 20701-5012

## OFFICIAL DISTRIBUTION LIST (CON'T)

COMMANDANT  
Academy of Health Science  
ATTN: HSHA-FM( LTC Lindsay)  
Fort Sam Houston , TX 78236

DEAN  
School of Medicine  
Uniformed Service Universtiy  
of the Health Science  
4301 Jones Bridge Road  
Bethesda, MD 20814-4799

COMMANDER  
U.S Air Force School of  
Aerospace Medicine  
Brooks A F B, TX 78235-5000

HQDA  
Assistant Secretary of the Army for  
Research, Development and Acquisition  
ATTN: SARD-ZT  
Pentagon, Washington, DC 20310

HQDA  
Assistant Secretary of the  
Army for Research, Development  
Acquisition  
ATTN: SARD-TM  
Pentagon, Washington, D.C 20310

HQDA  
Deputy Chief of Staff for Operation  
and Plans  
Director of Training  
ATTN: DAMO-TR  
Pentagon, Washington, D.C 20310

HQDA  
Office of the Surgeon General  
ATTN: DASG-ZA  
5109 Leesburg Pike  
Falls Church, VA 22041-3258

HQDA  
Office of the Surgeon General  
Directorate of Health Care Operations  
ATTN: DASG-HCO  
5109 Leesburg Pike  
Falls Church, VA 22041-3258

COMMANDANT  
U.S Army Chemical School  
ATTN: ATZN-CM-C  
Fort McClellan, AL 36205-5020

COMMANDANT  
U.S Army Chemical School  
ATTN: ATZN-CM-S  
Fort McClellan, AL 36205-5020

COMMANDANT  
U.S Army Quartermaster School  
ATTN: ATZM-C  
Fort Lee, VA 01433-6301

COMMANDANT  
U.S Army War College  
ATTN: AWC-C  
Carlisle Barracks, PA 17013

COMMANDANT  
Command and General Staff  
College  
ATTN: ATZL-SW  
Fort Leavenworth, KS 66027-5000

COMMANDANT  
Academy of Health Sciences, U.S Army  
ATTN: AHS-COM  
Fort Sam Houston, TX 78234-6100

Dean  
U.S Army School of Aviation  
Medicine  
ATTN: HSHA-AVN  
Fort Rucker, AL 36362-5377

COMMANDER  
US Army Medical Research and  
Development Command  
ATTN: SGRD-ZC (COL Dangerfield)  
Fort Detrick, Fredrick, MD 21702-5012

COMMANDER  
USAMRDC  
ATTN: SGRD-ZS (COL Schakenburg)  
Fort Detrick, Frederick, MD 21702-5012

OFFICIAL DISTRIBUTION LIST

COMMANDER  
USAMRDC  
ATTN: SGRD-Z/MG Travis  
ATTN: SGRD-PLC/COL Sedge  
SGRD-RMS/Ms. Madigan  
SGRD-OP/Mr. Adams  
Fort Detrick  
Fredrick, MD 21701-5012

DIRECTOR  
Defence Technical  
Information Center  
ATTN: DTIC-DDA (2 copies)  
Cameron Station  
Alexandria, Va 22314

COMMANDER  
US Army SMO  
ATTN: SLCSM-SE/Dr. Elser  
SLCSM-SE/Dr. Brand  
2800 Power Mill Rd.  
Adelphi, MD 20783

COMMANDER  
USAMSAA  
ATTN: DRXSY-CSD/P. Beavers  
Aberdeen Proving Grounds  
Maryland 21010

COMMANDER  
ATTN: STRNC-YSD/F. Bissett  
Natick RDE Center  
Natick, MA 01760-5020

COMMANDER  
USAEHA  
ATTN: HSHB-MR-LL/D. Sliney  
Aberdeen Proving Grounds  
Maryland 21010-5422

Dr. John Ewen  
OSWR/STD/STB  
PO Box 1925  
Washington, DC 20013

COMMANDER  
HQ, USAMMDA COL Pederson  
ATTN: SGRD-UMA/MAJ Walsh  
Fort Detrick  
Frederick, MD 21701-5009

COMMANDER  
ATTN: WRDC/MLPJ/G. Kepple  
WRDC/MLPJ/B.Edmonds  
WRDC/MLPJ/R.Susnick  
Wright Research and Development  
Center, Ohio 45433

HEADQUARTERS  
Department of the Army  
ATTN: DASG-TLO  
Washington, DC 20310

COMMANDER  
USA CACDA  
ATTN: ATZL-OPS-SE/MAJ Mathews  
ATZL-OPS-SE/LTC Stokes  
Fort Leavenworth, Kansas 66027-5300

COMMANDER  
NADC  
ATTN: Code 6023/Dr. Sheehy  
Warminster, PA 18974-5000

COMMANDER  
NMRDC  
ATTN: CODE 43  
National Naval Medical Ctr  
Bethesda, MD 20814

COMMANDER  
USAF SAM  
ATTN: RZV/Dr. Farrer  
RZV/LTC Cartledge  
Brooks AFB, TX 78235-5301