

*sent 1/22/94*

5-36539

*year 01*

93-1-0844

4011

AIR FORCE OFFICE OF SCIENTIFIC RESEARCH

AEOSR-TR- 94 0682

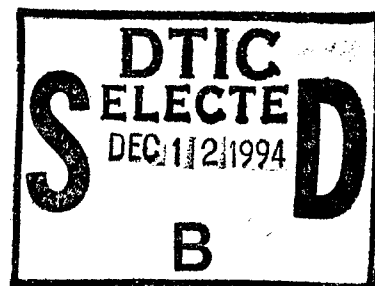
DIST. A

ANNUAL TECHNICAL REPORT

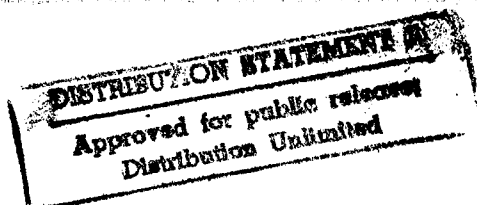
"ORGANIZATION OF THE HUMAN CIRCADIAN SYSTEM"

Principal Investigator: Robert Y. Moore, M.D., Ph.D.  
Department of Psychiatry  
University of Pittsburgh  
Pittsburgh, PA 15261

Project Period: 6/1/93-5/31/94



DTIC QUALITY INSPECTED 5



19941202 196

## TECHNICAL REPORT

Objectives: The overall objective of this project is a detailed description of the primate circadian timing system with special attention to the human. The specific objectives for this year were as follows: 1) characterization of the chemical neuroanatomy of the human suprachiasmatic nucleus (SCN); 2) characterization of a putative retinohypothalamic tract in the human; 3) characterization of the projections of the human SCN using antisera to vasoactive intestinal polypeptide (VIP).

Status of Research Effort. This will be described for each of the objectives noted above. During the past year we have obtained and analyzed 12 human hypothalamic and have obtained 2 lateral geniculates that are being held while we develop methodology for *in situ* hybridization.

Human SCN - Chemical Neuroanatomy. During the year we have obtained antisera to three calcium binding proteins, parvalbumin, calbindin and calretinin. The parvalbumin antisera have proven quite interesting in rodents but not, as yet in the human. In contrast, the calbindin antiserum has provided a new insight into the human SCN. Although we do see a few VIP+ neurons that are embedded in the rostral optic chiasm, these are very sparse. With the calbindin antiserum, however, we see a substantial plexus of axons and numerous perikarya in the rostral chiasm demonstrating that a significant number of SCN neurons receive a retinal input directly in the chiasm. It would seem likely that these neurons would project predominantly in local areas of neuropil and into the major portion of the SCN dorsally. In the more compact SCN, the calbindin neurons are confined to the area occupied by the VIP+ neurons. During the year we have worked on the construction of cDNA oligonucleotide probes directed against the human GABA-forming enzyme, glutamic acid decarboxylase. The intent is to demonstrate whether the majority of SCN neurons in the human are GABA-producing as they seem to be in other mammals. We have recently developed a probe that has worked quite well and has shown heavy labeling of film over the SCN. We have emulsion autoradiography in process - the material is being exposed and we expect to have definitive data in a few months.

The Human Retinohypothalamic Tract. Recent work in the rat has shown that a component of the retinohypothalamic tract is substance P-containing (SP+). In the last year we have examined 10 human hypothalamic prepared with antisera against SP. In each of these, we observed a plexus of SP+ axons in the ventral SCN at rostral levels that conforms in location to where we would expect the human retinohypothalamic tract to be located. The plexus is quite dense and, rostrally lies in the same area occupied by VIP+ neurons, extending ventrally into the optic chiasm where the SP+ plexus is present in the pockets of neuropil many of which also have VIP+ neurons. As the SCN extends dorsally above the chiasm, more caudally in the nucleus, the SP+ plexus similarly expands. But it is predominantly located in the region with VIP+ cells and surrounded by VP+ cells. More caudally, a plexus of SP+ axons develops in the anterior hypothalamic area with associated SP+ neurons, and in the caudal one-third of the SCN, this plexus invades the SCN such that it is not possible to distinguish an intrinsic SP+ plexus from one that comes from the adjacent area. Nevertheless, the location, distribution and organization of the SP+ plexus in the rostral SCN is strongly indicative that this is the human homologue of the SP+ retinohypothalamic projection in the rat.

SCN Projections. Over the last year, we have collected additional brains for an analysis of the projections of the human SCN as this is demonstrated by the VIP+ plexus arising from SCN neurons. About 18 months ago, we began collecting brains from patients with Alzheimer's disease in a pilot project funded by the local Alzheimer's Disease Research Center. When one of these patients dies, an autopsy is arranged and performed as rapidly as possible. Among all of the antisera we use, and antigens we look for, VIP is most sensitive to postmortem change with loss

of immunoreactive axons. This became particularly apparent in the Alzheimer brains with the relatively short postmortem intervals we obtain. Consequently, we have been procuring and processing control brains with short postmortem intervals to provide optimal material to complete the analysis of SCN projections in the human. This should be completed and ready for publication in the fall.

We also expect to complete our analysis of the monkey SCN and IGL in the next six months and to have publications ready to be submitted.

Professional Personnel: Robert Y. Moore, M.D., Ph.D.

Papers Presented: Moore, R.Y. and Speh, J.C. A putative retinohypothalamic tract in the human brain. Brain Research, Submitted for publication.

Inventions, Patents: None

<b>Accession For</b>	
NTIS GRA&I	<input checked="" type="checkbox"/>
DTIC TAB	<input type="checkbox"/>
Unannounced	<input type="checkbox"/>
Justification	
By	
Distribution/	
Availability Codes	
Dist	Avail and/or Special
A-1	