

AD \_\_\_\_\_

GRANT NUMBER DAMD17-94-J-4201

TITLE: Effect of Hormone Replacement Therapies and Dietary  
Phytoestrogens on the Mammary Gland of Macaques

PRINCIPAL INVESTIGATOR: J. Mark Cline, D.V.M., Ph.D.

CONTRACTING ORGANIZATION: Bowman Gray School of Medicine  
Winston-Salem, North Carolina  
27157-1040

REPORT DATE: July 1997

TYPE OF REPORT: Annual

PREPARED FOR: Commander  
U.S. Army Medical Research and Materiel Command  
Fort Detrick, Frederick, Maryland 21702-5012

DISTRIBUTION STATEMENT: Approved for public release;  
distribution unlimited

The views, opinions and/or findings contained in this report are those of the author(s) and should not be construed as an official Department of the Army position, policy or decision unless so designated by other documentation.

DTIC QUALITY INSPECTED 3

19971215 024

# REPORT DOCUMENTATION PAGE

Form Approved  
OMB No. 0704-0188

Public reporting burden for this collection of information is estimated to average 1 hour per response, including the time for reviewing instructions, searching existing data sources, gathering and maintaining the data needed, and completing and reviewing the collection of information. Send comments regarding this burden estimate or any other aspect of this collection of information, including suggestions for reducing this burden, to Washington Headquarters Services, Directorate for Information Operations and Reports, 1215 Jefferson Davis Highway, Suite 1204, Arlington, VA 22202-4302, and to the Office of Management and Budget, Paperwork Reduction Project (0704-0188), Washington, DC 20503.

1. AGENCY USE ONLY (Leave blank)		2. REPORT DATE July 1997	3. REPORT TYPE AND DATES COVERED Annual (1 Jul 96 - 30 Jun 97)	
4. TITLE AND SUBTITLE Effect of Hormone Replacement Therapies and Dietary Phytoestrogens on the Mammary Gland of Macaques			5. FUNDING NUMBERS DAMD17-94-J-4201	
6. AUTHOR(S)  J. Mark Cline, D.V.M., Ph.D.				
7. PERFORMING ORGANIZATION NAME(S) AND ADDRESS(ES)  Bowman Gray School of Medicine Winston-Salem, North Carolina 27157-1040			8. PERFORMING ORGANIZATION REPORT NUMBER	
9. SPONSORING/MONITORING AGENCY NAME(S) AND ADDRESS(ES) Commander U.S. Army Medical Research and Materiel Command Fort Detrick, Frederick, Maryland 2170-25012			10. SPONSORING/MONITORING AGENCY REPORT NUMBER	
11. SUPPLEMENTARY NOTES				
12a. DISTRIBUTION / AVAILABILITY STATEMENT  Approved for public release; distribution unlimited			12b. DISTRIBUTION CODE	
13. ABSTRACT (Maximum 200)  The purpose of this study has been to use histomorphometric and immunohistochemical techniques to study the incidence and characteristics of mammary gland hyperplasia, dysplasia and other possible indicators of breast cancer risk, in cynomolgus macaques given long-term hormonal treatments. Treatments evaluated to date include conjugated estrogens (CEE), medroxyprogesterone acetate (MPA), the combination of CEE and MPA, tamoxifen, estradiol (E2), 17 $\alpha$ -dihydroequilenin (DHEN), soybean phytoestrogens (SBE), and SBE + E2. Pathologic evaluation, histomorphometric evaluations, and staining for estrogen receptor, progesterone receptor, and the proliferation marker Ki-67 MIB were done. Results are as follows: The addition of MPA to CEE therapy increases, rather than decreases, mammary gland proliferation. Tamoxifen treatment does not induce mammary gland proliferation beyond that seen in controls; this is in contrast to a marked uterotrophic effect. DHEN does not induce mammary gland or endometrial proliferation. Soybean estrogens do not induce mammary or endometrial proliferation when given alone, and exert an antagonistic effect on E2-induced proliferation. New work includes dietary modulation of hormonal effects on mammary gland, interactions of tamoxifen and estradiol, identification of p53 expression in CEE-treated macaque mammary gland, and assessment of expression of estrogen receptor beta.				
14. SUBJECT TERMS  Breast Cancer - estrogen - hormone replacement therapy - macaques - phytoestrogens - progesterone -			15. NUMBER OF PAGES 64	
			16. PRICE CODE	
17. SECURITY CLASSIFICATION OF REPORT Unclassified	18. SECURITY CLASSIFICATION OF THIS PAGE Unclassified	19. SECURITY CLASSIFICATION OF ABSTRACT Unclassified	20. LIMITATION OF ABSTRACT Unlimited	

## FOREWORD

Opinions, interpretations, conclusions and recommendations are those of the author and are not necessarily endorsed by the U.S. Army.

\_\_\_\_ Where copyrighted material is quoted, permission has been obtained to use such material.

\_\_\_\_ Where material from documents designated for limited distribution is quoted, permission has been obtained to use the material.

*JMC* Citations of commercial organizations and trade names in this report do not constitute an official Department of Army endorsement or approval of the products or services of these organizations.

*JMC* In conducting research using animals, the investigator(s) adhered to the "Guide for the Care and Use of Laboratory Animals," prepared by the Committee on Care and Use of Laboratory Animals of the Institute of Laboratory Resources, National Research Council (NIH Publication No. 86-23, Revised 1985).

\_\_\_\_ For the protection of human subjects, the investigator(s) adhered to policies of applicable Federal Law 45 CFR 46.

\_\_\_\_ In conducting research utilizing recombinant DNA technology, the investigator(s) adhered to current guidelines promulgated by the National Institutes of Health.

\_\_\_\_ In the conduct of research utilizing recombinant DNA, the investigator(s) adhered to the NIH Guidelines for Research Involving Recombinant DNA Molecules.

\_\_\_\_ In the conduct of research involving hazardous organisms, the investigator(s) adhered to the CDC-NIH Guide for Biosafety in Microbiological and Biomedical Laboratories.

*J. Mark Clin*  
\_\_\_\_\_  
PI - Signature      2/29/97  
Date

## TABLE OF CONTENTS

	Page
Front cover .....	1
Report Documentation page .....	2
Foreword .....	3
Table of Contents .....	4
<b>Introduction</b> .....	5
<b>Methods</b> .....	8
Experimental designs (in chronological order by date of study termination)	
88-14 (Conjugated Estrogens+/- medroxyprogesterone acetate).....	9
91-20 (Conjugated estrogens, MPA, tamoxifen) .....	10
93-16 (17 $\alpha$ dihydroequilenin) .....	11
91-24 (Oral contraceptives).....	12
92-04 (Nandrolone) .....	13
93-18 (Soybean estrogens).....	14
94-33(Estradiol +/- soybean estrogens).....	15
95-13 (Estradiol +/- tamoxifen).....	16
91-12 (Oral contraceptives, conjugated estrogens, soybean estrogens).....	17
Drug doses/ Experimental Procedures .....	18
<b>Results and Discussion</b> .....	20
88-14 (Conjugated Estrogens+/- medroxyprogesterone acetate).....	23
91-20 (Conjugated estrogens, MPA, tamoxifen) .....	23
93-16 (17 $\alpha$ dihydroequilenin) .....	26
91-24 (Oral contraceptives).....	27
92-04 (Nandrolone) .....	28
93-18 (Soybean estrogens).....	28
94-33(Estradiol +/- soybean estrogens).....	29
95-13 (Estradiol +/- tamoxifen).....	30
91-12 (Oral contraceptives, conjugated estrogens, soybean estrogens).....	32
Ancillary Projects.....	32
Recommendations relative to Statement of Work .....	33
<b>Conclusions</b> .....	34
<b>References</b> .....	35
Personnel receiving pay .....	40
Appendix A: List of Publications .....	41
Appendix B: Presentations.....	42
Appendix C: Experiment 91-20 - Manuscript submitted to Breast Cancer Research and Treatment .....	44
Appendix D: Experiment 94-33 - Paper in press, American Journal of Clinical Nutrition.....	55

## INTRODUCTION

### • Background

Postmenopausal estrogen replacement has been shown to have major beneficial effects in the prevention of coronary heart disease (Avila, 1990; Bush 1987; Henderson 1988; Hunt 1987; Petitti 1986; Stampfer 1985) and osteoporosis (Ettinger 1985; Kiel 1987; Weiss 1980; Ravnikar 1992; Colditz 1990). Unfortunately, the public health impact of these benefits to postmenopausal health has been small because of poor patient compliance. In the United States, 15% of naturally postmenopausal women 45 to 54 years of age use hormone replacement therapy (HRT), while the number decreases to 6% at ages 55 and older. A recent review of this problem indicates that **concern over the risk of breast cancer is the greatest single disincentive for the use of HRT** (Ravnikar 1992). Identification and quantification of this risk is compromised by a lack of basic knowledge of the hormonal regulation of the breast.

The concerns of women regarding breast cancer risk associated with hormonal therapies have some basis in the results of recent epidemiologic studies (Colditz 1993; Colditz 1995; Coope 1992; Pike 1993). Colditz et al found a significant association between current estrogen replacement therapy and increased breast cancer risk (Colditz 1992, 1993). The mechanistic basis for this increased risk is unknown. The mitogenic effects of estrogens on both breast and endometrial tissue are well recognized, as are the beneficial effects of progestins on endometrial cell proliferation and cancer risk. The action of progestins on breast tissue is more controversial; the literature offers a number of conflicting results both *in vitro* (Mauvais-Jarvis 1986; Haslam 1988; Papa 1990; Moore 1991), and *in vivo* (Anderson 1989; de Lignieres 1992; Gompel 1993; Bergkvist 1989; Ohi 1992). The assumption that breast and uterus are regulated similarly leads to the conclusion that the combined hormone replacement therapy designed to decrease the risk of endometrial cancer (i.e. estrogen + a progestin) is also appropriate for breast. However, a recent meta-analysis of studies including women treated with estrogen plus a progestin did not show a protective effect of the use of progestin (Colditz 1993). Recently, data from the Nurse's Health Study has shown a similar result (Colditz 1995). **A particularly disturbing paper published in June of this year indicates that the overall survival advantage provided by hormone replacement therapy (HRT) is lost after 10 years of treatment, largely as a result of increased breast cancer incidence (Grodstein et al., 1997).**

Oral contraceptive use is generally considered to have minimal effect on breast cancer risk (WHO, 1992), although there is some evidence for increased risk in long-term current users (La Vecchia, 1995).

Studies of breast regulation, particularly in the postmenopause, are limited. Most studies have involved one of the following:

1. *in vitro* models which do not adequately mimic the hormonal milieu of the breast
2. *in vivo* studies in rodent models which are different in many ways from women
3. observational and epidemiologic studies of women which are confounded by lack of experimental rigidity.
4. studies in women using minimally invasive techniques such as fine-needle aspiration, which do not allow study of spatial/paracrine relationships within the breast.

Experimental studies using human tissues are subject to confounding errors: The apparently normal breast tissue in breasts operated for benign or malignant lesions may be subject to paracrine influence from the tumor, and the breasts of reduction mammoplasty operated women contain considerably more adipose tissue than the breasts from normal average women. Fine needle aspiration biopsies from healthy women also have limitations: Different epithelial areas of the

mammary gland can not be safely distinguished in such samples. The ideal model would be based on surgical samples from healthy women, which is a practical impossibility.

**Thus the problem lies in the lack of an adequate experimental system in which to test hypotheses relating to breast cancer risk. Our work is designed to use the cynomolgus macaque model to answer questions relating to breast regulation and breast cancer risk.**

The associations between proliferative breast lesions and breast cancer risk are quite strong in women. Within populations of cells *in vitro* and *in vivo*, high rates of cellular proliferation result in increased risk of transformation to the neoplastic phenotype (Cohen 1991, Butterworth 1992). Among women with benign breast lesions, ductal hyperplasia with atypia is a strong risk factor for the development of overt breast carcinoma (London 1992, Page 1992). Within populations of cells *in vitro* and *in vivo*, high rates of cellular proliferation increase the risk of transformation to the neoplastic phenotype. It is likely that this general phenomenon applies to the breast as well (Moolgavkar 1980).

- **Scope of the present work**

The effects of various hormone therapies on atherosclerosis and osteoporosis in female monkeys have been studied for some time at our institution (Adams 1991, Clarkson 1989). **The work described herein is an attempt to further utilize this model system for study of the breast.** Several studies currently underway offer a unique opportunity for evaluation of the effects of estrogens, progestins, and androgens on mammary gland and endometrium *in vivo*, using animals given doses equivalent to those used in women. Therapies used include postmenopausal estrogen (Premarin) with and without a progestin (MPA); postmenopausal treatment with Premarin, MPA, the combination, or tamoxifen; premenopausal administration of Triphasil; premenopausal Triphasil followed by postmenopausal HRT; and postmenopausal nandrolone, an androgenic steroid. Studies are also in progress to assess the effects of dietary (soy) phytoestrogens. This collection of material represents a unique resource for the study of proliferative lesions induced in target tissues by hormonal replacement therapy.

Macaques are similar to women in many aspects of reproductive physiology and anatomy. Macaques have a distinct menarche and menopause, at about 3 and 20 years of age, respectively. They have a 28-day menstrual cycle, with a hormonal profile similar to that of women (Mahoney 1970). Their endometrial responses to endogenous and exogenous hormones parallel those of women (Kaiserman-Abramof 1989). Mammary glands in these animals differ from the human breast grossly, but microscopically the mammary tissues of women and female macaques are quite similar (Schultz 1937, MacPherson 1974, Benirschke 1978). Primate mammary gland has unique cytokeratin phenotype which is identical in macaques and women, but is not shared by more distant species (Tsubura 1991). In this and other aspects of breast biology relevant to cancer risk (such as proto-oncogene and tumor suppressor gene expression), the mammary gland of macaques is quite similar to that of women (Cline, unpublished data). Mammary neoplasms are uncommon in macaques (Benirschke 1978, Warner 1979). However, there are occasional reports of mammary gland tumors in macaques (Beniashvilli 1989), and a recent paper by Uno indicates that long-term evaluation of macaques may reveal relatively high incidences of mammary and colonic neoplasms (Uno, 1997). We believe that the female macaque model provides a unique alternative for measurement of responses of the breast to exogenous and endogenous hormones. This model also allows for extensive studies of treatment effects in normal breast which could not be done in women, for example serial biopsy studies or determinations of regional variations in breast regulatory processes.

Very few studies have dealt with the responses of macaque mammary glands to exogenous

hormones (Speert 1948, Tavassoli 1988) Findings to date are that estrogens, progestins, and growth hormone can induce mammary gland proliferation, and that high doses of estrogens may induce neoplasms (Tavassoli 1988).

• **Purpose of the present work**

The specific aim of this work is to assess the effects of oral contraceptives and hormonal therapies on the incidence and severity of hyperplastic and dysplastic lesions in the mammary gland of macaques, and to assess regulatory alterations such as changes in sex steroid receptor expression. The following hormone therapies are being evaluated (specific doses are listed on page 18).

Treatments given to premenopausal animals

Triphasil  
Ethinyl estradiol (the more estrogenic component of Triphasil)  
Levonorgestrel (the more progestinic component of Triphasil)  
Soybean Phytoestrogens

Treatments given to postmenopausal animals

Estradiol  
Premarin (conjugated equine estrogens)  
Premarin + medroxyprogesterone acetate  
Medroxyprogesterone acetate  
Nandrolone  
Tamoxifen  
Tamoxifen+Estradiol  
17 $\alpha$ - dihydroequilenin  
Soybean Phytoestrogens  
Soybean phytoestrogens + estradiol

## METHODS

Our basic approach is the use of intermediate markers of breast dysregulation in macaques (hyperplasia, dysplasia, epithelial proliferation measured by Ki-67 expression, changes in estrogen and progesterone receptor expression, and expression of the p53 tumor suppressor gene product) in order to identify which hormonal treatments might induce a greater risk of breast cancer in women.

### *Study Design*

Animals subjected to a variety of hormonal manipulations are included in this work, as well as control monkeys from these studies, which has allowed concurrent study of the normal menstrual cycle. Studies from which tissues are being collected include the following:

#### **Three studies dealing with postmenopausal hormone replacement therapy:**

- 88-14 Estrogen replacement/secondary intervention trial
- 91-20 Estrogen replacement primary intervention trial
- 93-16  $17\alpha$ -dihydroequilenin study

#### **One study using premenopausal (contraceptive) steroids and postmenopausal comparison of estrogen replacement versus dietary soy supplementation:**

- 91-12 Oral contraceptive atherosclerosis primary prevention trial/ Soy as an estrogen alternative trial

#### **One study of contraceptive steroids alone:**

- 91-24 Oral contraceptive study (Triphasil and its components )

#### **One study of androgenic steroids used to prevent osteoporosis:**

- 92-04 Anabolic steroid study

*The above-listed studies were described in the original grant application. Additional opportunities arising during the past 3 years also include three very exciting studies of potential estrogen antagonists, namely:*

#### **Two studies of soybean phytoestrogens, given alone and in combination with estradiol:**

- 93-18 Effects of Soybean Estrogens in peripubertal macaques
- 94-33 Interactions of Mammalian and Plant Estrogens

#### **One study of concurrent administration of estradiol and tamoxifen:**

- 95-13 Interactions of Estrogen and Tamoxifen

A brief description of each study is given on the following pages.

## Experiment 88-14

### Estrogen replacement/atherosclerosis secondary intervention trial (Conjugated estrogens +/- medroxyprogesterone acetate)

#### Study design

Progression phase - surgically postmenopausal, adult female monkeys were fed an atherogenic diet, to allow progression of atherosclerosis and osteoporosis for 22 months.



Animals were then randomized into 3 groups:  
Ovariectomized control (n = 26)  
Premarin (n = 22)  
Premarin + Cycrin (n = 21)



Treatment phase (24 months)  
Diet changed to low fat and low cholesterol



Euthanasia and necropsy  
Termination date: July, 1993



Assessment of:

**Benefits:** Atherosclerosis regression, arrest of osteoporosis progression.

**Risks:** Hyperplastic, dysplastic or neoplastic lesions in breast and endometrium. In particular, the relative effect of Premarin and Premarin + MPA has been assessed.

**Experiment 91-20: Primary atherosclerosis intervention trial  
(Conjugated estrogens +/- medroxyprogesterone acetate; tamoxifen)**

Termination date: April 1995

Study design

Surgically postmenopausal, female cynomolgus monkeys



Randomization to 5 groups:

- Ovariectomized control (n = 15)
- Premarin (conjugated equine estrogens, CEE)(n = 15)
- Cycrin (medroxyprogesterone acetate, MPA) (n = 15)
- Premarin + Cycrin (n = 15)
- Tamoxifen (n = 15)



Treatment - fed moderately atherogenic diet, 35 months



Euthanasia and necropsy



Assessment of:

**Benefits:** Cardioprotective effect of Premarin alone and with Cycrin. Direct comparison of cardioprotective effect of Premarin and Tamoxifen.

**Risks:** Hyperplastic, dysplastic, and neoplastic lesions in breast and endometrium. This study is of particular interest because a) it allows comparison of the effects of Premarin and Premarin + MPA with MPA alone, and b) it provides an opportunity to examine the effect of Tamoxifen on normal mammary gland.

**Experiment 93-16:  $17\alpha$ -dihydroequilenin study**

Termination date: December 1993

Study design

Young, female rhesus monkeys



Randomization to 3 groups:

- Cycling control (n = 16)
- Ovariectomized control (n = 17)
- $17\alpha$ -dihydroequilenin (n = 17)



Treatments were given for 21 weeks. Animals received a moderately atherogenic diet.



Euthanasia and necropsy



Assessment of:

**Benefits:** Cardioprotective effect of  $17\alpha$ -dihydroequilenin.

**Risks:** Mammary hyperplasia, dysplasia, and neoplasia relative to either control group.

**Experiment 91-24**  
**Atherosclerosis/contraceptive steroids primary prevention trial**

Termination dates: June 1993 (interim sacrifice) and fall 1995

Study design

Premenopausal, female cynomolgus monkeys



Randomization to 4 groups:

Control (intact, normally cycling)  
Triphasil (n = 24)  
Cyclic ethinyl estradiol (n = 24)  
Cyclic levonorgestrel (n = 24)



Treatment was given for 35 months. Animals received a moderately atherogenic diet.



Euthanasia and necropsy



Assessment of:

**Benefits:** Cardioprotective effect of premenopausal estrogen use.

**Risks:** Mammary hyperplasia, dysplasia and neoplasia, and whether such effects relates to the ethinyl estradiol or levonorgestrel component of Triphasil.

**Experiment no. 92-04**  
**Osteoporosis primary prevention trial**

Termination date: June 1994

Study design

Pre- and postmenopausal female cynomolgus monkeys



Randomization:

Cycling control (n = 15)

Ovariectomized control (n = 15)

Nandrolone in year 1 after ovariectomy (n = 15)

Nandrolone in year 2 after ovariectomy (n = 15)



Treatment was given for 24 months. Animals were fed a moderately atherogenic diet.



Euthanasia and necropsy



**Benefits:** Prevention/treatment of osteoporosis

**Risks:** Coronary artery atherosclerosis exacerbation. Effect of androgenic/anabolic steroids on mammary gland and endometrium.

**Experiment No. 93-18**  
**Effects of Soybean Estrogens**

Termination date: January 1995

Study design

Peripubertal female cynomolgus monkeys



Randomization:

Untreated controls (n = 13)

Soybean estrogens (n = 14)



Treatment was given for 12 months. Animals were fed a moderately atherogenic diet.



Euthanasia and necropsy



**Benefits:** Prevention/treatment of atherosclerosis.

**Risks:** Potential adverse estrogenic effects of soybean estrogens, such as induction of mammary or endometrial proliferation.

**Experiment No. 94-33**  
**Interactions of Mammalian and Plant Estrogens**

Termination date: October 1995

Study design

Postmenopausal female cynomolgus monkeys



Randomization:

Ovariectomized control (n = 15)

Estradiol (n = 15)

Soybean estrogens (n = 15)

Estradiol + Soybean estrogens (n = 15)



Treatment was given for 6 months. Animals were fed a moderately atherogenic diet.



Euthanasia and necropsy



**Benefits:** Prevention/treatment of atherosclerosis; potential additive effect of soy and estradiol in the prevention of arterial and bone disease. Potential antagonistic effect of soy and estradiol, which might prevent breast and endometrial proliferation caused by estradiol.

**Risks:** Potential antagonistic effect of soy and estradiol, which might reduce the effectiveness of coronary artery protection. Potential additive effect of soy and estradiol on mammary gland and endometrium, resulting in increased proliferation and cancer risk.

**Study No. 95-13**  
**Interactions of Estrogen and Tamoxifen**

Termination date: June 1996

Study design

Postmenopausal female cynomolgus monkeys



Randomization:

Ovariectomized control (n = 6)

Estradiol (n = 6)

Estradiol + tamoxifen (n = 6)



Treatment was given for 2 months. Animals were fed a moderately atherogenic diet.



Euthanasia and necropsy



**Benefits:** Protective effect of tamoxifen on breast, which will presumably be reflected in lower proliferation in breast .

**Risks:** Endometrial proliferation induced by tamoxifen and estradiol, leading to hyperplasia and increased risk of neoplasia.

## **Experiment 91-12**

### **Oral contraceptives/Soy as an Estrogen Alternative**

Termination date October 1993 (interim) and December 1996

#### Study design (phase I)

Premenopausal, female cynomolgus monkeys



Randomization to 2 groups:

Control (n = 100)

Triphasil (n = 100)



Treatment phase - Animals are fed a moderately atherogenic diet and treated for 24 months.



Interim arterial biopsy



Assessment of:

Benefits - cardioprotective effect of premenopausal estrogen use, particularly for stressed females.  
Increase in peak bone mass from premenopausal estrogen use.



#### Study design (phase II)

Surgically postmenopausal monkeys



Randomization of the two groups from part I (estrogen use or not) into three groups:

1) Control (n = 63)

2) Premarin (conjugated equine estrogens, CEE) (n = 63)

3) Soy phytoestrogens (n = 63)

for a treatment period of 36 months.



Final necropsy



Assessment of:

**Benefits:** Does premenopausal estrogen use add to the postmenopausal hormone replacement therapy effects on atherosclerosis and osteoporosis?

**Risks:** Hyperplasia and dysplasia of target tissues.

Possible protective effect of premenopausal contraceptive use on endometrium, and possible increased mammary tumor risk

What are the uterotrophic and mammatrophic effects of phytoestrogens?

*Diets/Drug Dosing*

The hormones were administered twice daily in the diet, with the exception of nandrolone. Most animals consume a moderately atherogenic diet (40% of calories from fat, 0.2 mg of cholesterol per Calorie). Monkeys are fed approximately 120 Calories per kg of body weight per day. Doses were as follows:

Drug	Abbreviation	Dose equivalent per woman per day
Conjugated equine estrogens	CEE	0.625 mg
Medroxyprogesterone acetate	MPA	2.5 mg
17 $\beta$ -Estradiol	E2	2 mg (experiment 94-33) 0.25 mg (experiment 95-13)
Tamoxifen	TAM	20 mg
Ethinyl estradiol	EE	Days 1-6: 0.03 mg Days 7-11: 0.04 mg Days 12-21: 0.03 mg Days 22-28: no drug
Levonorgestrel	LN	Days 1-6: 0.05 mg Days 7-11: 0.075 mg Days 12-21: 0.125 mg Days 22-28: no drug
17 $\alpha$ -Dihydroequilenin	DHEN	0.312 mg/kg
Soybean estrogens	SBE	99.7 mg
Nandrolone	-	No daily equivalent; animals were given injections of 25 mg nandrolone decanoate by intramuscular injection every 3 weeks.

Drug doses were computed as:

human dose divided by 1800 Calories/woman/day = dose per Calorie of diet

*Doses arrived at by this means were therefore consistently scaled, and adjusted for metabolic rate. They are similar to the dose calculated by scaling on the basis of body surface area (Mordenti 1986).*

*Tissue collection*

Mammary glands were collected at the end of each study, when all monkeys are euthanized and necropsied. Tissues were fixed in 4% buffered paraformaldehyde at 4°C. The tissue was removed from paraformaldehyde after 24 hours, stored in 70% ethanol at 4°C, and later trimmed to 3 mm in thickness, embedded in paraffin using standard histologic procedures, and sectioned at 5  $\mu$ m for immunostaining.

*Histopathology*

Mammary gland slides were subjectively classified as atrophic, hyperplastic, or neither. The treatment group of each animal was obscured during the procedure to prevent observer bias. Hyperplasia, atypia, cystic lesions, and secretory activity were noted. Lesions were independently graded as none, mild, moderate or severe. The criteria of the World Health Organization were used for tumor classification (WHO, 1982)

*Morphometry*

Mammary gland thickness, mammary lobular size, and area fraction of the mammary tissue occupied by glands are measured from histologic sections using video microscopy and a Macintosh-based video imaging system and public domain software (NIH Image, available via the Internet by anonymous FTP [file transfer protocol] from zippy.nimh.nih.gov).

### *Stereology*

In early studies prior to acquisition of the image analysis system, estimates of the relative proportions of tissue components in the mammary gland were made by point counting, after the method of Chalkley (Chalkley, 1945). These included percentage of gland occupied by epithelium, connective tissue and fat. Numbers of points intercepting each lobule were also recorded, as a relative indicator of lobular size.

### *Sex steroid receptors and proliferation marker staining methods.*

Staining procedures were done on fixed, paraffin-embedded tissues. The basic staining procedure uses an avidin-biotin-peroxidase method (Wordinger 1987) modified for antigen retrieval from paraffin-embedded tissue. The estrogen receptor and progesterone receptor analyses were performed with either antibodies from Dako laboratories (Dako Corporation, Carpinteria, CA, USA), and Immunotech laboratories (Immunotech, Marseille, France), or the mouse monoclonal antibodies NCL-ER-LH2 and NCL-PGR antibodies for detection of estrogen and progesterone receptor expression respectively (Novocastra, Newcastle-upon-Tyne, U.K.), depending on the study.

### *Assessment of proliferation (Ki67-MIB)*

We first used the Ki-67 MIB-1 (MIB) monoclonal antibody (Immunotech, Marseille, France) that gives an immunostaining identical to Ki-67 antibody and which can be used on paraffin embedded tissue sections (Cattoretti 1992). We have also used the NCL-Ki-67-MM1 mouse monoclonal antibody (Novocastra, Newcastle-upon-Tyne, U.K.), which has provided us with identical results. As for the receptor analysis, the MIB basic staining procedure is done by an avidin-biotin-peroxidase method modified for antigen retrieval from paraffin embedded tissue. The murine monoclonal antibody Ki-67 reacts with a human DNA-binding protein that is present in proliferating cells but absent in quiescent cells. A detailed cell cycle analysis showed that the Ki-67 antigen is expressed in G1, S, G2 and mitosis (with maximum levels during G2 and M phases) but not in G0 and using this antibody an exact determination of the growth fraction of a given human cell population, regardless of whether it is normal or malignant, has been possible (Gerdes 1991).

### *Immunostaining for p53 expression*

The antibody that was used for p53 was DO-7 (Dako A/S Glostrup Denmark) and the staining procedure was an avidin-biotin-peroxidase method modified for antigen retrieval from paraffin-embedded tissues, similar to that used for Ki-67 staining.

### *Quantification of immunohistochemical staining*

Immunostained cells were quantified by cell counting in sections, by an observer blinded to treatments. Epithelial cells lining the alveoli, the terminal and major ducts were considered separately in order to assess regional differences. Labeled cell nuclei were identified as unlabeled (0), weakly (+), moderately (++) or intensely (+++) labeled. At least 100 cells per slide were counted at 3 different sites for each combination of animal, tissue site and stain type. Major ducts and alveoli were easily identifiable, but clearly defined terminal ducts could not be identified in some cases.

### *Statistical methods*

Statistical analysis is performed using the Mann-Whitney U-test with Bonferroni corrections for multiple comparisons, Kruskal Wallis test, Chi-square test, and Spearman's rank correlation test.

### *Ancillary Projects*

Several ancillary projects have been carried out which enhance the understanding of mammary data collected. These include:

- 1) development of methods for detection of the newly-described estrogen receptor beta (ER $\beta$ ) in macaque tissues.

- 2) development of vaginal cytology methods for prospective screening of live macaques for estrogenic effects on the reproductive tract;
- 3) development of a method to retrospectively approximate the reproductive history of monkeys; and
- 4) development of a morphometric protocol to assess treatment-related changes in ovaries of oral contraceptive-treated macaques, in order to document treatment effects.

## RESULTS

A brief outline of accomplishments to date is followed by a presentation of specific experimental findings. Progress to date includes:

1. Collection of approximately 500 paired, frozen and fixed breast and endometrial samples, from macaques treated with conjugated estrogens with and without medroxyprogesterone acetate, tamoxifen, triphasic oral contraceptives, nandrolone, estradiol, dietary phytoestrogens, and controls.
2. Development of morphometric and cell counting methods for evaluation of breast and endometrium, including acquisition of a computerized video microscopy/image analysis system and development of standard measurement procedures.
3. Refinement and application of immunohistochemical methods for detection of the proliferation marker Ki-67, estrogen receptors and progesterone receptor; tissues from approximately 300 animals have been stained and evaluated to date.
4. Publication of a manuscript to the American Journal of Obstetrics and Gynecology detailing morphologic and immunohistochemical changes in the breast of surgically postmenopausal macaques given conjugated estrogens with or without the addition of MPA (from study 88-14).
5. Results in mammary gland have been compared to endometrial morphology and Ki-67, ER, and PR staining in endometrium, in the same animals used for the above manuscript (via a separate grant, received from the Office of Research on Women's Health). This parallel study was the basis of a Young Investigator Award to Dr. Cline for presentation of the findings at the North American Menopause Society meeting.
6. Study of the regional variation in breast regulation, by quadrant and distance from the nipple. Identification of regional variations provides us with an assessment of the degree of random or predictable intrinsic variation in within breast tissue, a parameter of considerable interest should we plan biopsy-based studies in the future. Results of this study are in press in the journal *Gynecologic and Obstetric Investigation* (Cline, 1997)
7. Development of histopathologic criteria for retrospectively distinguishing the uteri of parous and nulliparous macaques. Since some animals in our studies were acquired as adults with an unknown reproductive history, and parity affects long-term breast regulation, this is an important source of variation in the breast which we needed to identify. This work was presented at the 1995 meeting of the American College of Veterinary Pathologists (Cline, 1995), and a manuscript is in preparation for submission to the journal *Veterinary Pathology*.
8. Vaginal cytologic studies demonstrated classical estrogenic effects of estradiol and conjugated estrogens in macaques, a weak estrogenic effect of tamoxifen on the vagina, and no estrogenicity of soybean estrogens in the vagina. These results were published in the journal *Fertility and Sterility*; the manuscript was included in last year's report.
9. Ovarian histomorphometric studies identified distinct atresia-inducing effects of oral contraceptives, including progestin-only contraceptives, in follicles of treated animals.

10. Whole-mount methods for assessing mammary gland development have been developed in our laboratory; based on preliminary examination of a few samples, we believe that this method will provide an important adjunct to our existing procedures for evaluating mammary gland proliferation.

11. Our demonstrated interest in dietary chemoprevention of breast cancer has led to the generation of an invited review of the potential chemopreventive properties of phytochemicals (Cline and Hughes, 1997).

12. We have demonstrated that the tumor suppressor gene p53 is up-regulated in the mammary glands of macaques given hormone replacement therapies (Isaksson et al., manuscript in preparation).

13. International collaborations in conjunction with this work have continued; scientists in training have been sent to Bowman Gray from the Karolinska Institute in Stockholm, and Ernst-Moritz-Arndt University in Griefswald, Germany, to study the macaque model of breast and endometrial regulation.

14. We have recently developed a collaborative effort with Dr. Thomas Register of our department, in order to evaluate expression of the newly-described estrogen receptor beta.

15. The work accomplished through this grant has led to an invitation from the Comprehensive Cancer Center of Wake Forest University to establish a Primate Resource Core laboratory so that the type of collaborative work done in these studies can reach a broader group of cancer researchers in our institution.

The following are the specific technical objectives proposed from July, 1994 to July, 1997, accompanied by a report of what has been accomplished.

**Technical Objective**

**Work Accomplished**

*Year 1 (1994/1995)*

Processing, staining, and measurement from tissues collected in 1993; studies 88-14 (final sacrifice), 91-24 (interim sacrifice), 91-12 (interim sacrifice).

Completed.

Collection of tissues from studies 92-04 and 93-16.

Completed.

*Year 2 (1995/1996)*

Collection of tissues from studies 91-20, 91-24, and 91-12 (final sacrifices).

Collections have been made from 91-20 and 91-24. Collections from 91-12 have been delayed by a change in the design of the parent study.

Processing, staining, and measurement of tissues collected.

Completed.

Presentation and publication of interim results from studies 91-24 and 91-12, final results from study 88-14.

Final results from studies 88-14 (CEE+/-MPA) and 93-16 have been published. Preliminary data from experiments 94-33, 91-20, 93-18, and 91-24 have been presented. Interim endpoints from experiment 91-12 have been published (vaginal cytology), but mammary gland evaluation awaits tissue collection.

*Year 3 (1996/1997)*

Presentation and publication of results from studies 91-20, 91-24, and 91-12

Papers regarding the results of study 91-20 have been submitted. Manuscripts from studies 91-24 and 95-13 are in preparation. Tissue collection continues from study 91-12.

### *Specific Results Listed By Study*

Substantial results are available from several studies, and are described below. Ancillary projects relevant to this work are described at the end of the results section.

#### **I. Conjugated Estrogens with or without MPA (Study 88-14)**

This is a long-term comparison of the effects of CEE and CEE+MPA in surgically postmenopausal macaques (the study design is shown on page 9).

The most relevant finding in this study was that the addition of the progestin MPA to estrogen (CEE) treatment had differing effects on the mammary gland and endometrium of macaques: That is, MPA antagonized the proliferative effect of CEE in the endometrium, but not the mammary gland. In fact, the addition of MPA to CEE treatment *increased* proliferation in the mammary gland (Figure 1).

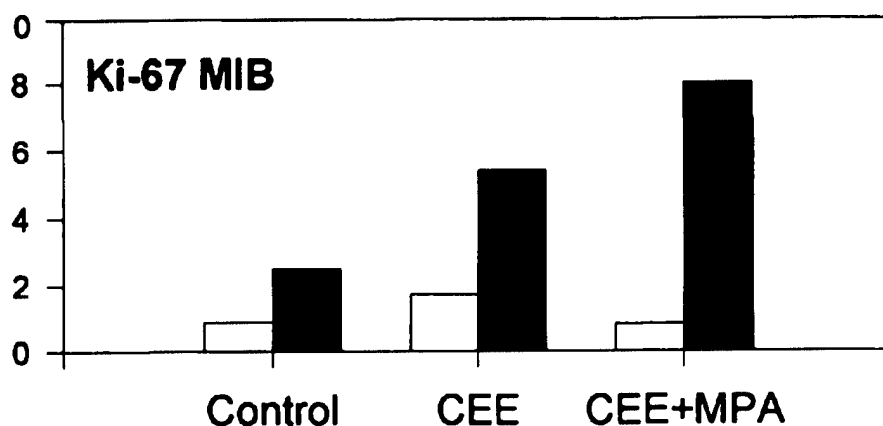


Figure 1. Divergent effects of combined estrogen/progestin treatment on the endometrium (white bars) and mammary gland (black bars) of macaques. Bars indicate the percentages of cells labeled with the proliferation marker Ki-67.

This study is essentially complete, and the results have been published (Cline et al., 1996).

#### **II. Conjugated estrogens, MPA and Tamoxifen (Study 91-20)**

This is a study of the comparative effects of CEE, MPA, CEE+MPA, and tamoxifen in surgically postmenopausal macaques (the study design is shown on page...). Preliminary morphometric and proliferation data were presented in last year's report and are briefly outlined below; in the past year the data have been finalized, and measurements of estrogen and progesterone receptor expression were done. This work has been submitted for publication, and is included as an appendix (Appendix C)

In this second study, results in the groups given CEE, and CEE+MPA, are similar to those in the preceding experiment. Proliferation data on these groups, and the additional groups given MPA alone and tamoxifen, are shown in Figure 2. Again, it is apparent that CEE+MPA exerts a greater mammatrophic effect than CEE alone (Figures 2 and 3), in contrast to the findings in the uterus (Figure 4). As might be expected, tamoxifen does not cause an increase in mammary gland proliferation.

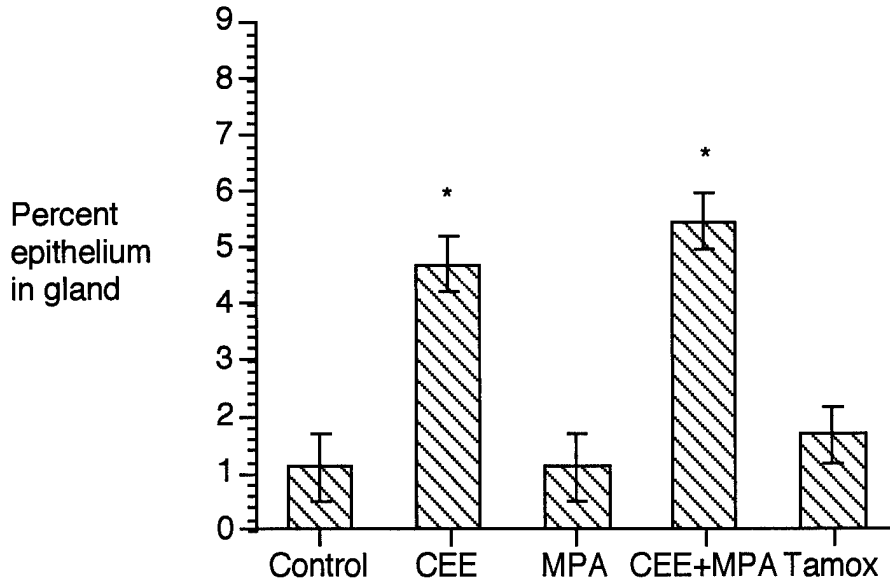


Figure 2. Percentage of mammary epithelium in the mammary gland of macaques given CEE, MPA, the combination, or tamoxifen. Combined CEE+MPA produced maximal glandular proliferation. Stars indicate groups differing from controls at  $p < 0.05$ .

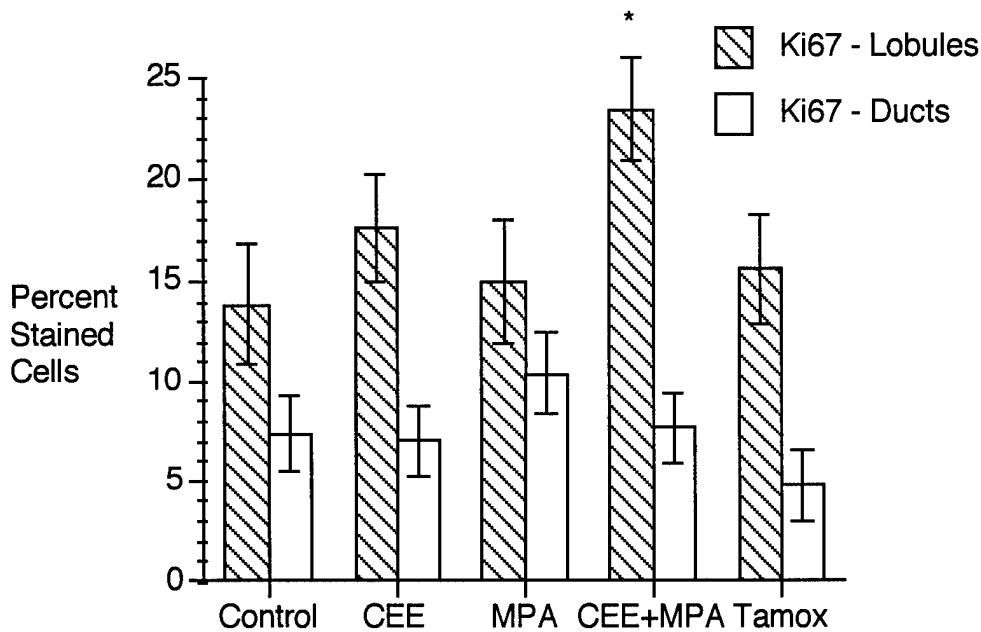


Figure 3. Ki-67 staining in mammary epithelial cells, expressed as percentage positively-stained cells. Stars indicate groups differing from controls at  $p < 0.05$ .

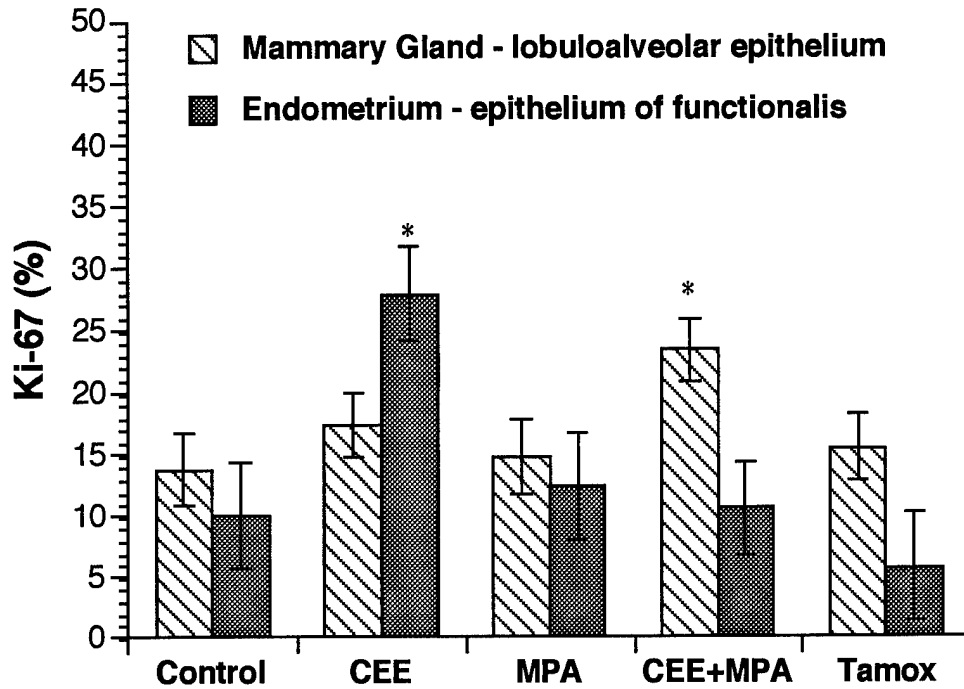


Figure 4. Ki-67 staining in mammary gland and endometrium, expressed as percentage positively-stained cells. Maximal proliferation was induced by CEE+MPA in the mammary gland, in contrast to maximal proliferation induced by CEE alone in the endometrium. Stars indicate groups differing from controls at  $p < 0.05$ .

Estrogen and progesterone receptor staining has been completed for the mammary glands. No significant differences in estrogen receptor expression were induced in the mammary glands by any of the treatments. However, progesterone receptor expression was increased by both CEE and tamoxifen treatment. Adding MPA to CEE treatment diminished PR expression (Figure 5).

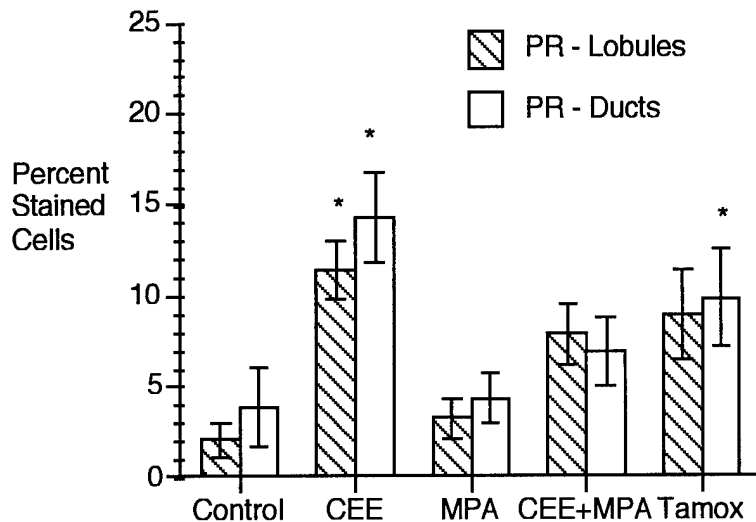


Figure 5. - Progesterone receptor (PR) staining in mammary epithelial cells, expressed as percentage positively-stained cells. Stars indicate groups differing from controls at  $p < 0.05$ . CEE and MPA also differ at  $p < 0.05$  for both sites.

### Measurement of p53:

A subset of animals in this study were used to evaluate expression of the apoptosis-inducing regulatory protein p53 in mammary gland and endometrium. Work done in collaboration with our colleagues at the Karolinska Institute in Stockholm has shown that wild-type p53 is up-regulated in the mammary glands of estrogen-treated macaques and can be detected using commercially available antibodies. This work has also shown that there are differences in the relative expression of the proliferation marker Ki67 and p53 in animals given estrogen (CEE) as opposed to tamoxifen. We found in this study that mammary and endometrial p53 is elevated by CEE but not tamoxifen treatment (Figures 6 and 7), thus potentially pointing out a new manifestation of the mixed agonist-antagonist activity of tamoxifen. This particularly exciting finding has been the subject of another publication recently submitted to Breast Cancer Research and Treatment (Isaksson et al., submitted).

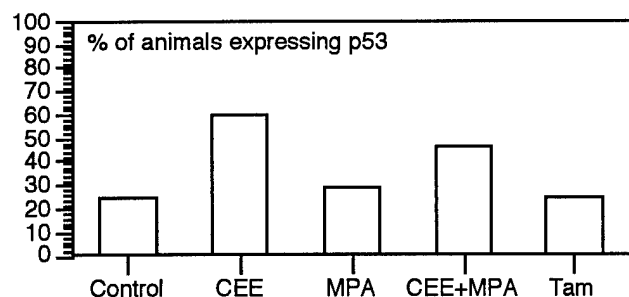


Figure 6. Immunohistochemical detection of the p53 tumor suppressor gene product in animals given conjugated equine estrogens (CEE). MPA - medroxyprogesterone acetate; Tam - tamoxifen

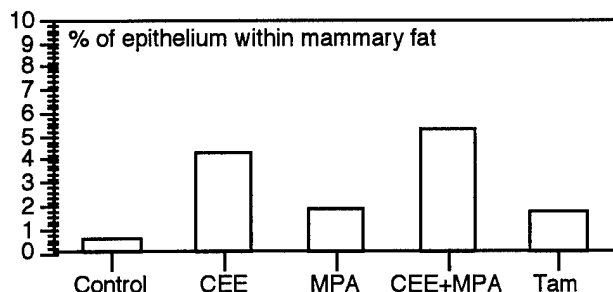


Figure 7. Morphometric assessment of mammary gland proliferation in the same animals shown in the preceding figure.

### III. DHEN versus Conjugated Estrogens (Study 93-16)

This is a study of the relative effects of  $17\alpha$ -dihydroequilenin (DHEN) in pre- and post-menopausal macaques (the study design is shown on page 11). DHEN has considerable potential for use as a "selective" estrogen, exerting beneficial effects on the cardiovascular system and bone without producing increased breast and endometrial proliferation. In this study, DHEN did not exert mammotrophic or uterotrophic effects. The data was given in last year's report, and are summarized in Figure 8. Endometrial data from this study have been published (Washburn et al., 1996).

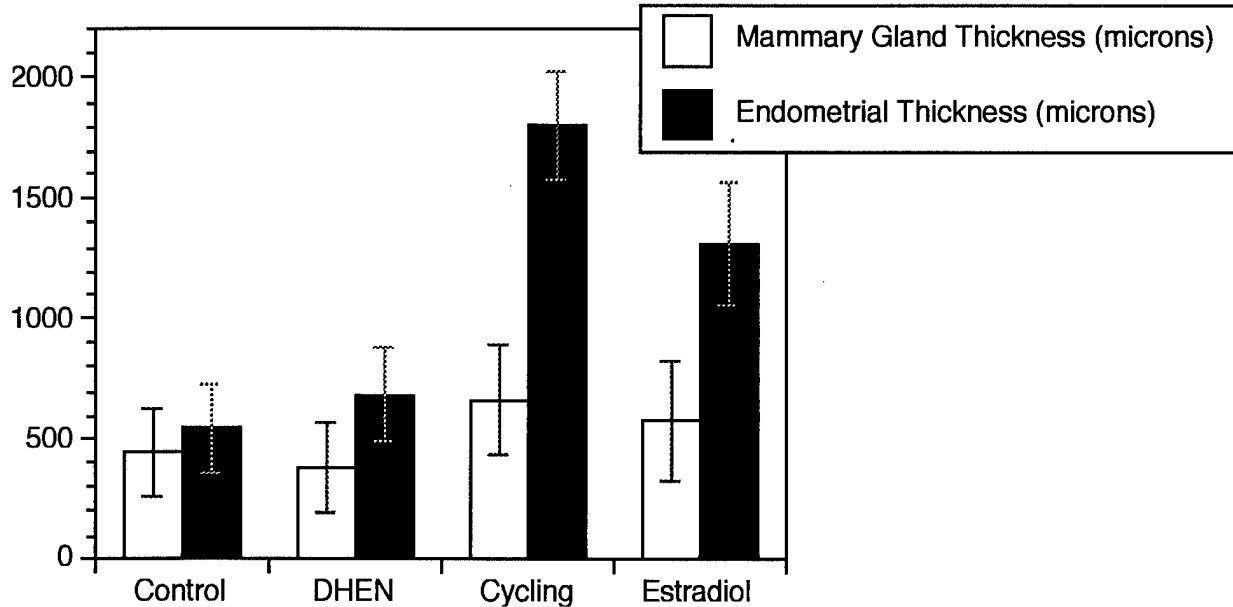


Figure 8. Dihydroequilenin does not induce proliferation in mammary gland or endometrium of macaques (not statistically different from controls).

**IV. Triphasic Oral Contraceptives (Experiment 91-24)**

This study seeks to explore the possible role of triphasic oral contraceptive use on chronic disease risk in the monkey model (see experimental design, page 12). A particularly interesting aspect of this study is the concurrent evaluation of typical triphasic oral contraceptives (modeled after the widely used Triphasil™), and the individual components of the contraceptive, namely ethinyl estradiol and levonorgestrel. To date, no statistically significant treatment-related differences have been identified in mammary glands of animals treated with the whole preparation or its components (Figures 9 and 10).

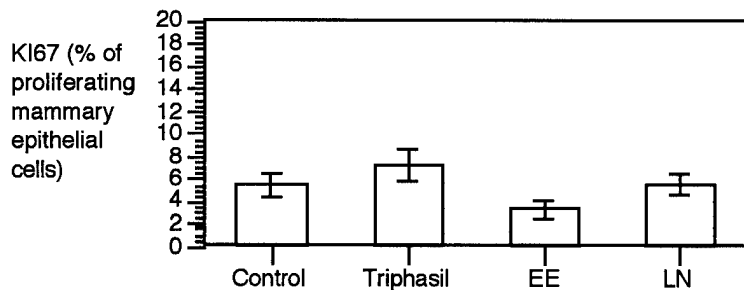


Figure 9. Effects of Triphasil (TRI), ethinyl estradiol (EE) and levonorgestrel (LN) on proliferation in lobuloalveolar tissue of the macaque mammary gland. There are no statistically significant differences.

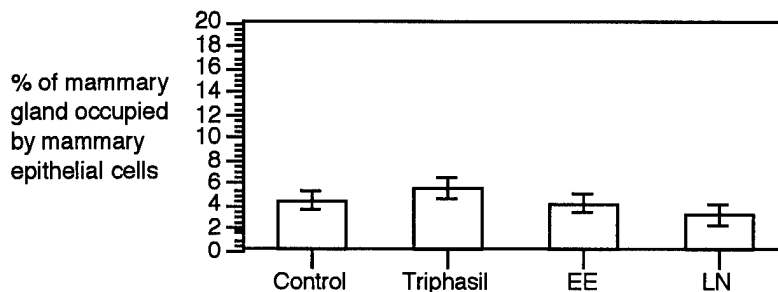


Figure 10. Effects of Triphasil (TRI), ethinyl estradiol (EE) and levonorgestrel (LN) on a morphologic indicator of glandular hyperplasia. There are no statistically significant differences.

It is of interest to contrast this study with experiment 88-14, and in particular to note that the combination of an estrogen and a progestin does not increase epithelial proliferation in these premenopausal animals. This reflects the biology of breast cancer risk in women, in which oral

contraceptive use does not produce profound changes in breast cancer risk. Possible sources of this difference include 1) differences between breast regulation in pre- and post-menopausal animals; 2) differences due to the specific estrogen and progestins used; or 3) differences resulting from cyclic, as opposed to continuous, administration of hormones.

**V. Effects of Nandrolone (Experiment 92-04)**

The design of this study is given on page 13; it is a trial of the osteoporosis preventive anabolic androgenic steroid nandrolone. Mean estradiol concentrations in the two nandrolone groups after treatment began ranged from 76.8 to 171.0 pg/ml and 60 to 130.2 pg/ml for the OVX+ND and OVX+NDdelay groups, respectively whereas concentrations in the ovariectomized control group ranged between 0 and 9.08 pg/ml. These estradiol concentrations correlated with increased uterine weight (Obasanjo, in preparation), and were interpreted as resulting from conversion of nandrolone to estradiol (Obasanjo 1996).

Mammary gland effects of nandrolone were minimal, consisting of an insignificant trend for greater glandular epithelial area (Figure 11). Endometrial changes were more pronounced, and consisted of increases in uterine weight, mucometra, and adenomyosis (Obasanjo, in preparation)

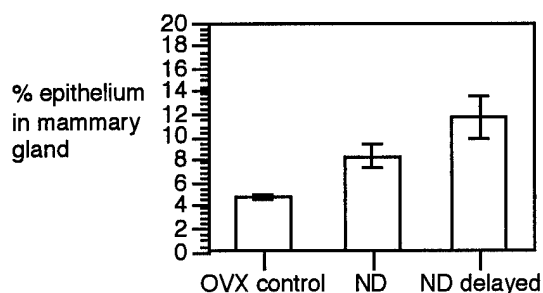


Figure 11. Percentage of mammary tissue occupied by glandular epithelium in ovariectomized macaques given nothing (OVX control), nandrolone immediately after ovariectomy (ND) or nandrolone beginning 1 year after ovariectomy (ND delay). No groups are statistically different.

**VI. Effects of Soy Phytoestrogens on Peripubertal Macaques (Experiment 93-18)**

Our recent work with dietary modulation of intermediate markers of cancer risk has produced some intriguing results. This first of our soy studies (see page 14 for study design) was done as a pilot project in a small cohort of female monkeys fed soy phytoestrogens, and demonstrates (as do the vaginal cytology data) that soy phytoestrogens do not induce increases in mammary or endometrial proliferation, as estimated by morphometric measurement of the percentage of each tissue made up of epithelial cells.

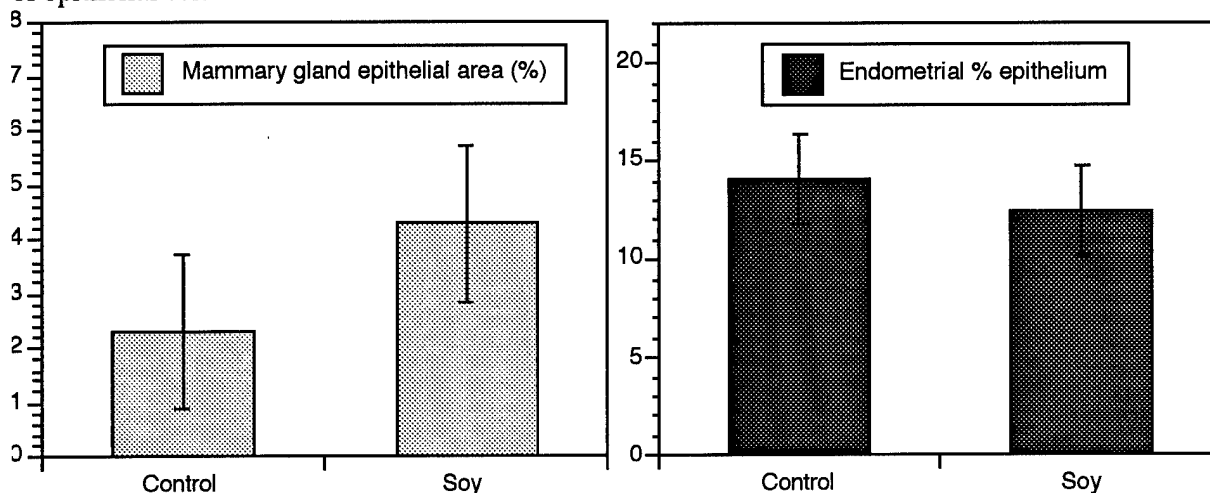


Figure 12. Soy phytoestrogens do not induce mammary gland or endometrial hyperplasia.

**VII. Interactions of Mammalian and Plant Estrogens (Experiment 94-33)**

Further explorations of soy effects on mammary gland led us to examine the effects of estradiol in concert with dietary soy supplementation. The study design is outlined on page 15. Findings to date indicate that soy phytoestrogens are not themselves classically "estrogenic" (i.e. proliferation-inducing) in mammary gland or endometrium (Figures 13-15).

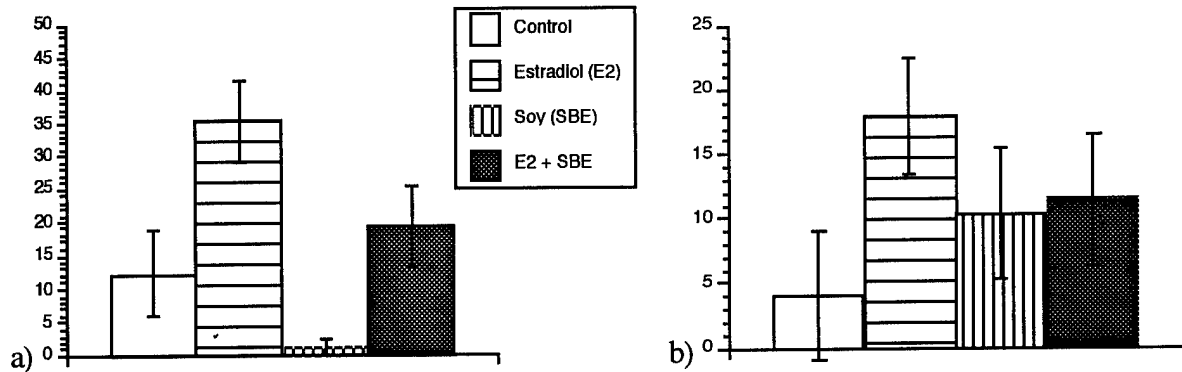


Figure 13. - Immunohistochemical staining for the proliferation marker Ki-67 in a) endometrium and b) mammary gland of cynomolgus macaques. Estrogen-induced proliferation is antagonized by the addition of soybean estrogens (SBE). Soy phytoestrogens do not induce mammary gland proliferation alone, and exert an antagonistic effect on estrogen-induced proliferation. Only the estrogen-treated group differs from controls at  $p < 0.05$ .

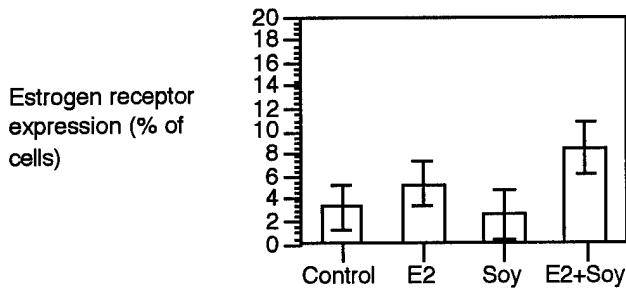


Figure 14. - Immunohistochemically detectable ER expression induced by E2 and Soy treatment.

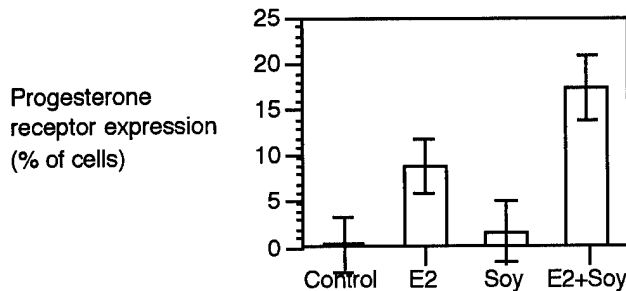


Figure 15. - Immunohistochemical staining for progesterone receptor in mammary gland of cynomolgus macaques. Both estrogen-treated groups differ from controls at  $p < 0.05$ .

Other details of this study are given in the attached manuscript, in press in the American Journal of Clinical Nutrition (Foth and Cline, in press - Appendix D).

**VIII. Effects of Estradiol and Tamoxifen in Combination (Experiment 95-13)**

This study (design given on page 16) was a unique opportunity to assess low-dose estradiol (0.25 mg/woman/day equivalent) and the combination of estradiol and tamoxifen.

Findings to date indicate first that different thresholds for proliferative responses are operative for mammary gland and endometrium; serum concentrations for estradiol were in the range of 50-60 pg/mL, which induced a significant proliferative response in endometrium but not breast (Figures 16 and 19). Secondly, it is apparent that a dose of tamoxifen which has no effect or even an antiproliferative effect on estrogen-induced proliferation does not antagonize the induction of progesterone receptor (Figures 18 and 19).

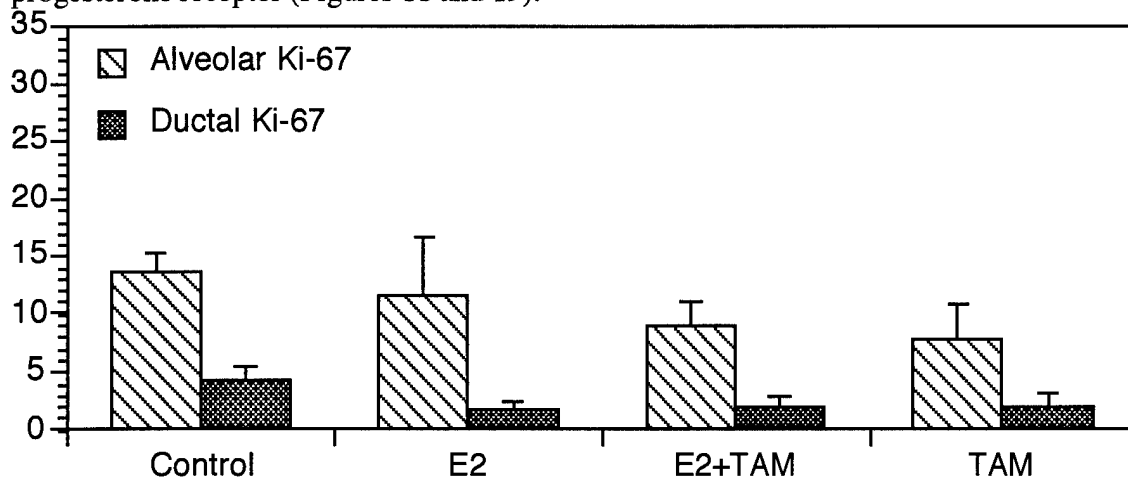


Figure 16. - Immunohistochemical staining for the proliferation marker Ki-67 in the mammary gland of cynomolgus macaques. No groups are statistically different.

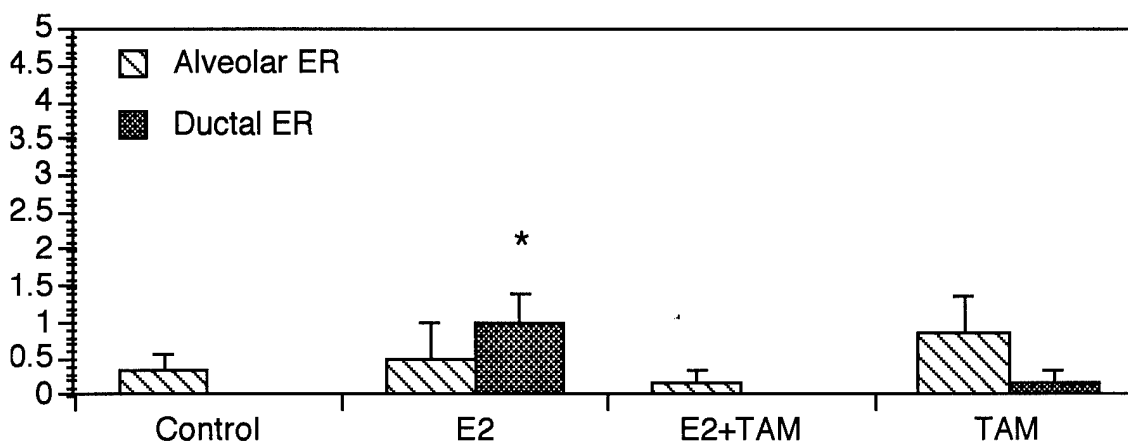


Figure 17. - Immunohistochemical staining for estrogen receptors in the mammary gland of cynomolgus macaques. Asterisks indicate statistical differences from controls at  $p < 0.05$ .

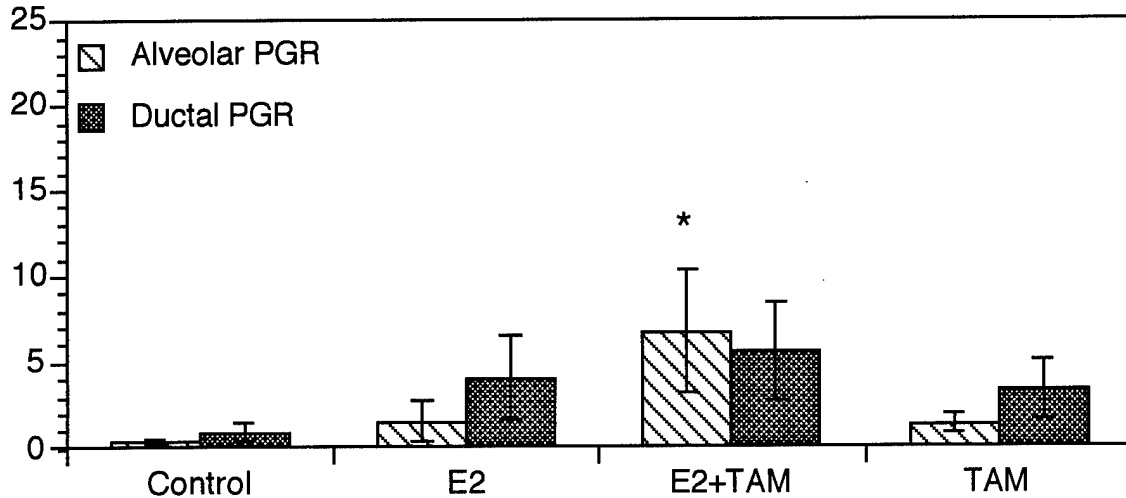


Figure 18. - Immunohistochemical staining for progesterone receptor in the mammary gland of cynomolgus macaques. Asterisks indicate statistical differences from controls at  $p < 0.05$ .

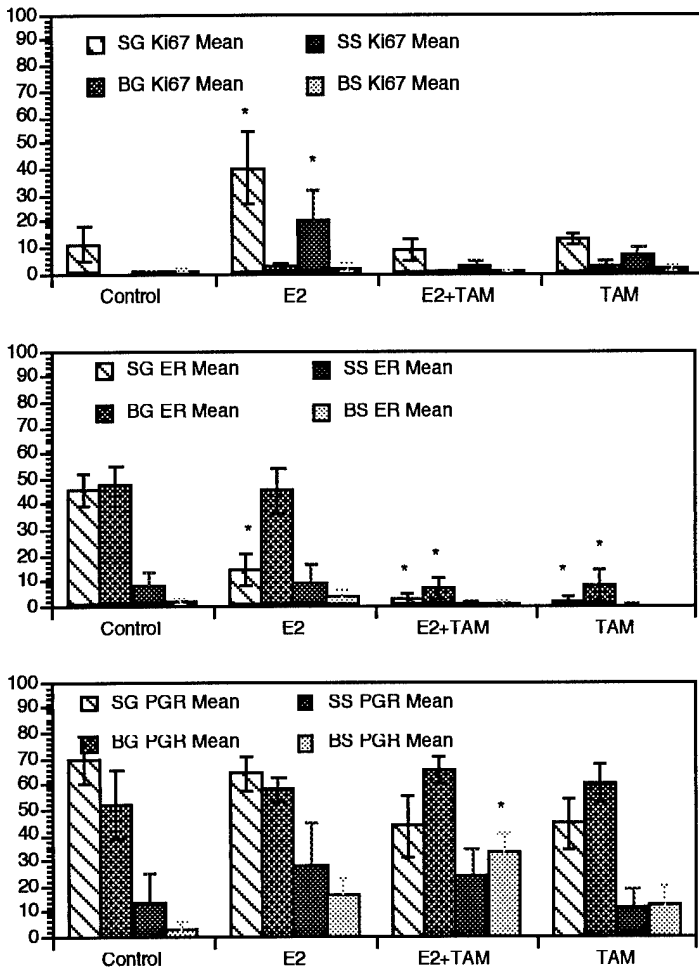


Figure 19. Endometrial findings. Ki67 (top), ER (middle), and PR (bottom) from endometrium of animals given estradiol, tamoxifen or the combination (Experiment 95-13). SG = superficial glandular tissue; BG = basal glandular tissue; SS = superficial stroma; BS = basal stroma. The marked effect of treatment on endometrial proliferation (Ki67) and ER expression stands in contrast to the minimal effect seen in the mammary gland. PR was induced in both tissues, although to a lesser degree in endometrium than mammary gland.

**IX. Oral contraceptives/Soy as an Estrogen Alternative (Experiment 91-12)**

Tissue collection continues from this study, through December of 1997. Results will be presented in the final report for this grant.

**X. Ancillary Projects**

*Measurement of ER beta in macaque tissues*

The background of data provided by this project has led to increased interest in use of the macaque model to understand estrogen-mediated events. During this past year Dr. Thomas Register and I successfully competed for intramural pilot project funds to assess the possibility that the newly described ER beta occurs in macaques. We found that the beta receptor is expressed in macaque tissues, in a pattern similar to that described in humans. Data from this study were presented at the Triangle Conference on Reproductive Biology and have formed the basis of a publication currently in preparation.

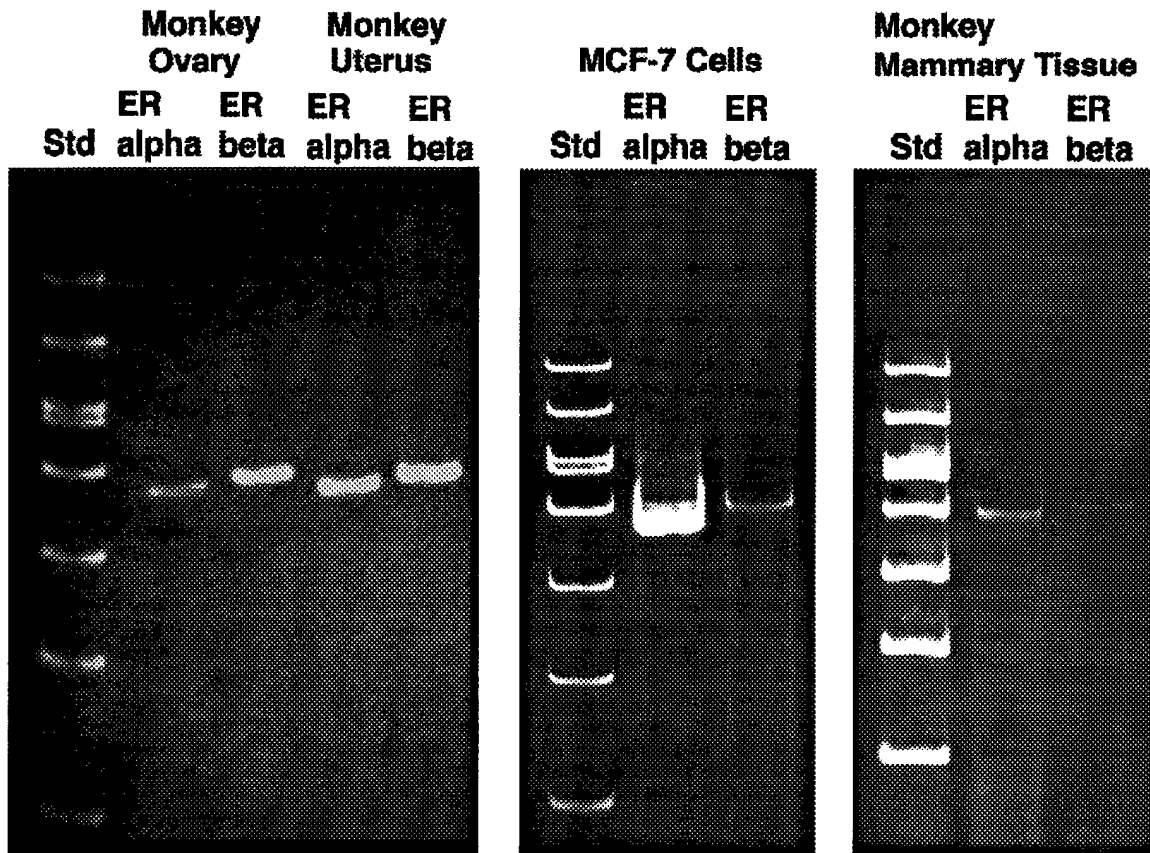


Figure 20. Expression of ER beta mRNA in macaque tissues, as determined by RT-PCR. ER beta expression is similar to that of ER alpha in ovary and uterus, but less in MCF-7 mammary carcinoma cells and mammary gland tissue. Courtesy of Dr. Thomas Register.

*Vaginal cytologic evaluation of hormone-treated animals*

Vaginal cytologic examinations have been made on animals in studies 91-12 during the latter half of the experiment (see page ... for the study design), and in study 91-20 (the study design is on page...). Published results presented in last year's report indicate that CEE and tamoxifen exert an estrogenic effect on the vaginal epithelium, and that SBE does not (Cline et al., 1996).

*Identification of Previously Pregnant animals*

The presence of perivascular extracellular mucinous matrix deposits was identified as an indicator of prior pregnancy. This study was briefly described in last year's report, but has since been finalized and presented. Data summarized in Table 1 indicate that parity status of macaques can be determined from histopathologic examination of the uteri, with a reasonable degree of certainty.

Table 1. Accuracy of retrospective determination of parity status in macaques, based on uterine histopathologic examination.

	Cynomolgus macaques		Rhesus macaques		Stumptailed macaques	All animals	
	Nulliparous	Parous	Nulliparous	Parous	Parous	Nulliparous	Parous
<b>Number evaluated</b>	13	24	13	38	5	67	26
<b>Mean age</b>	5.0	8.4	5.8	9.8	7.3	5.44	9.16
<b>Range</b>	3.1-10.2	3.8-15	3.3-12.3	4.7-16.7	5.4-8.9	4.75-12.3	8.5-16.7
<b>Mean parity number</b>	-	3.1	-	2.3	1.6	0	2.5
<b>Range</b>	-	1-7	-	1-6	1-3	-	1-7
<b>Months since last delivery</b>	-	8.9	-	24.8	15.6	-	18.45
<b>Range</b>	-	1-32	-	3-78	7-35	-	1-78
<b>Number correctly classified</b>	12	23	12	33	5	24	61
<b>False positives</b>	1	-	1	-	-	2	-
<b>False negatives</b>	-	1	-	5	0	-	6

*Assessment of oral-contraceptive-related changes in monkey ovaries*

This project was undertaken by a summer student in my laboratory, and was not funded by this grant; nonetheless, it has produced interesting data indicating that oral contraceptives do in fact alter the ovarian function of macaques at the doses given. This work has resulted in beneficial collegial interactions between investigators at Bowman Gray, Duke University, and the National Institute of Environmental Health Sciences. In the past year, this collaboration has led to the finding that progestin-containing oral contraceptives induce increased apoptosis in the ovarian surface epithelium. This observation has important implications for understanding the ovarian cancer-preventive effects of oral contraceptives, and was the subject of a plenary presentation at this year's meeting of the Society of Gynecologic Investigation (Rodriguez, 1997)

**•Recommendations**

The data presented herein clearly demonstrate that the macaque mammary gland can be used to provide a model of breast regulation in the post-menopausal period. This model is unique in that it provides an in vivo assessment of hormone effects on the primate breast, and can also be used to make comparisons of breast and endometrial effects in the same subject.

Several significant findings have been made to date. In the first year of this grant, we observed that the addition of MPA to conjugated estrogens did not result in suppression of the mammotrophic effects of CEE, but instead in a greater proliferative response than is seen with CEE alone. This finding addresses precisely the type of question the project is designed to target, providing a result which is of great relevance to public health, but which can only be explored with great difficulty in human subjects. This is in agreement with recent reports such as that of the Nurses' Health Study (Colditz 1995).

During the second year, we made the observation that dietary soy supplementation has the potential to protect the mammary gland from the tumor-promoting proliferative effects of estrogens. This finding has broad implications for the use of dietary modulation of breast cancer risk.

During the third year, we explored the effects of tamoxifen alone and in concert with estrogens on the endometrium and breast, and observed that cyclic oral contraceptives do not induce the same type of mammary hyperplasia induced by postmenopausal hormone replacement therapy.

A great deal of important information can be gained within the scope of this project as initially written. However, after making the initial observations of hormone effects of these intermediate markers of cancer risk in breast, it will be vital to proceed on to more mechanistic studies of the role of growth factors and growth factor receptor expression in the proliferative response. The continuing controversy over breast cancer risk associated with hormonal therapies, particularly with regard to the role of progestins, indicates a lack of understanding of basic regulatory processes in the breast. The recent paper by Grodstein et al. (1997) indicates that breast cancer is likely to be a limiting factor on the use of hormonal replacement therapies in at least some subset of postmenopausal women. This has led our group to seek further exploration of alternatives to traditional hormone replacement therapy, such as dietary soy supplementation. The potential cancer chemopreventive effects of soy isoflavones is well documented in rodent models and has logical mechanistic bases in terms of the antioxidant, antiproliferative, and tyrosine-kinase inhibiting effects of these compounds (Barnes, 1995). We would also like to continue our exploration of normal breast regulation, since there is evidence that the breast of human and non-human primates shares regulatory features that are not common to other species such as rodents. The number of mediators potentially involved in breast regulation is large, and we have begun explorations of some (p53, ER beta, IGF) that we would like to continue.

## **CONCLUSIONS**

### **General Summary:**

Technical objectives outlined in the initial application have been met on schedule, with only minor changes.

The morphometric and immunohistologic methods proposed in the initial application have been applied successfully to a number of mammary gland samples from macaques.

Publication of results continues, and this work has been reconized intramurally and extramurally in via meeting presentations, invited presentations, and invitations to expand the scope of cancer-related work using the monkey model.

### Specific Conclusions:

In surgically post-menopausal cynomolgus macaques,

- CEE induced PR expression and focal to diffuse lobuloalveolar proliferation
- The addition of progestins to estrogen treatment increased mammary gland proliferation, in contrast to the antagonistic effects of progestins in the endometrium of the same animals.
- Medroxyprogesterone alone induced ductal but not lobulolaveolar proliferation in macaque mammary gland.
- Low-dose E2 had a threshold effect, inducing proliferation in the uterus but not the mammary gland.
- Tamoxifen induced mammary ER and PR, but did not induce mammary gland proliferation in macaques, in contrast to cystic hyperplasia induced in the endometrium of the same animals.
- When given with E2, tamoxifen inhibited estrogen-induced proliferation, but not PR induction.
- DHEN does not induce mammary gland or endometrial proliferation, relative to controls and in contrast to CEE.
- Dietary soy phytoestrogens antagonized the proliferation-inducing effect of estrogens in the mammary gland and endometrium.
- 17-alpha dihydroequilenin did not induce mammary gland or endometrial proliferation.
- Nandrolone did not alter breast histology or histomorphometry.
- p53 expression in response to estrogen treatment is novel finding in this model, and may lead to new insights regarding the role of p53 in modulation of estrogen-induced proliferative responses and the effects of mixed estrogen agonist-antagonists such as tamoxifen.
- ER beta can be detected in macaque tissues; this new aspect of the model may allow us to explore the differential expression and function of the classical and beta receptors.

### REFERENCES

- Adams MR, Williams JK, Clarkson TB, Jayo MJ. Effects of oestrogens and progestogens on coronary atherosclerosis and osteoporosis of monkeys. *Baillieres Clinical Obstetrics & Gynaecology* 1991;5:915-34.
- Anderson TJ, Battersby S, King RJB, McPherson K, and Going JJ.: Oral contraceptive use influences breast cell proliferation. *Human Path* 1989;20:1139-1141.
- Avila MH, Walker AM, Jick H. Use of replacement estrogens and the risk of myocardial infarction. *Epidemiology* 1990;1:128-133.
- Barnes S. 1995. Effect of genistein on in vitro and in vivo models of cancer. *J Nutr* 125(3 Suppl):777S-783S.
- Beniashvilli DS. An overview of the world literature on spontaneous tumors in nonhuman primates. *J. Med. Primatol* 1989, 18:423-437
- Benirschke K, Garner FM, Jones TC, eds. *Pathology of Laboratory Animals*, New York:Springer-Verlag 1978:1204-1206.

Bergkvist L, Adami H-O, Persson I, Hoover R, Schairer C. The risk of breast cancer after estrogen and estrogen-progestin replacement. *N Engl J Med* 1989;321:293-297

Bush TL, Barrett-Connor E, Cowan DL, Criqui MH, Wallace RB, Suchindran CM, Tyroler HA, Rifkind BM. Cardiovascular mortality and noncontraceptive use of estrogen in women: Results from the Lipid Research Clinics Program Follow-Up Study. *Circulation* 1987;75:1102-1109.

Butterworth BE, Goldsworthy TL. The role of cell proliferation in multistage carcinogenesis. *Proc Soc Exp Biol Med* 198;683-687, 1991

Cattoretti G, Becker MH, Key G, Duchrow M, Schluter C, Galle J, Gerdes J. Monoclonal antibodies against recombinant parts of the Ki-67 antigen (MIB 1 and MIB 3) detect proliferating cells in microwave-processed formalin-fixed paraffin sections. *J Pathol* 1992;168:357-63

Chalkley HW. Method for the quantitative morphologic analysis of tissues. *J Nat Cancer Inst* 1943; 4:47-53.

Clarkson TB, Adams MR, Kaplan JR, Shively CA, Koritnik DR. From menarche to menopause: coronary artery atherosclerosis and protection in cynomolgus monkeys. *American Journal of Obstetrics & Gynecology* 1989;160:1280-5.

Cline JM, Soderqvist G, Skoog L, von Schoultz B. Divergent effects of hormone replacement on mammary and endometrial tissues of macaques. *Menopause*. 1995;2:278

Cline JM, Bain FT. Uterine vascular changes indicating prior pregnancy in macaques. *Vet Pathol* 32:585, 1995.

Cline JM, Soderqvist G, von Schoultz E, Skoog L, von Schoultz B. Effects of hormone replacement therapy on the mammary gland of surgically postmenopausal cynomolgus macaques. *American Journal of Obstetrics & Gynecology*. 1996;174:93-100

Cline JM, Paschold JC, Anthony MS, Obasanjo IO, Adams MR. Effects of hormonal therapies and dietary soy phytoestrogens on vaginal cytology in surgically postmenopausal macaques. *Fertil Steril*. 1996;65:1031-1035

Cline JM, Soderqvist G, Skoog L, von Schoultz B. Regional distribution of proliferating cells and hormone receptors in the mammary gland of surgically postmenopausal macaques given hormone replacement therapy. *Gynecologic and Obstetric Investigation*, in press, 1997.

Cline JM, Hughes CL. Phytochemicals for the prevention of breast and endometrial cancer. In Biological and Hormonal Therapies of Cancer, eds. H Muss and K Foon. Kluwer Academic Publishers, . In press.

Cohen SM, Purtilo DT, Ellwein LB. Pivotal role of increased cell proliferation in human carcinogenesis. *Modern Pathol* 4:371-382, 1991

Colditz GA, Hankinson SE, Hunter DJ, Willet WC, Manson JE, Stampfer MJ, Hennekens C, Rosner B, Speizer FE. The use of estrogens and progestins and the risk of breast cancer in postmenopausal women. *NEJM* 1995;332:1589-1593.

Colditz GA, Egan KM, Stampfer MJ. Hormone replacement therapy and risk of breast cancer: Results from epidemiologic studies. *Am J Obstet Gynecol* 1993;168:1473-1480.

Colditz GA, Stampfer MJ, Willett WC, Hennekens CH, Rosner B, Speizer FE. Prospective study of estrogen replacement therapy and risk of breast cancer in postmenopausal women. *JAMA* 1990;264:2648-2653.

Coope J, March J. Can we improve compliance with long-term HRT? *Maturitas* 1992 15:151-158.

de Lignières B, Linares G, Barrat J. Effects of progesterone on epithelial cell mitotic activity in human breast. In: *Progesterone in Hormone Replacement Therapy*, eds RA Lobo and F Naftolin, Parthenon Press, Carnforth, U.K. 1992:47-56.

Ettinger WB, Genant HK, Cann CE. Long-term estrogen replacement therapy prevents bone loss and fractures. *Ann Intern Med* 1985;102:319-324.

Gerdes J, Li L, Schlueter C, Duchrow M, Wohlenberg C, Gerlach C, Stahmer I, Kloth S, Brandt E, Flad HD. Immunobiochemical and molecular biologic characterization of the cell proliferation-associated nuclear antigen that is defined by monoclonal antibody Ki-67. *Am J Pathol* 1991;138:867-873.

Gompel A. Progestin treatments of menopause. *Revue du Praticien* 1993;43(20):2645-50.

Haslam SZ. Progesterone effects on deoxyribonucleic acid synthesis in normal mouse mammary glands. *Endocrinology* 1988;122:464-70.

Grodstein F, Stampfer MJ, Colditz GA, Willett WC, Manson JA, Joffe M, Rosner B, Fuchs C, Hankinson SE, Hunter DJ, Hennekens CH, Speizer FE: Postmenopausal hormone replacement therapy and mortality. *The New England Journal of Medicine* 336 (25): 1769-1775, 1997.

Haslam SZ. Progesterone effects on deoxyribonucleic acid synthesis in normal mouse mammary glands. *Endocrinology* 1988;122:464-70.

Henderson BE, Pike MC, Ross RK, Mack TM, Lobo RA. Re-evaluating the role of progestogen therapy after the menopause. *Fertil Steril* 1988;49(Suppl)9S-12S.

Hunt K, Vessey M, McPherson K, Coleman M. Long-term surveillance of mortality and cancer incidence in women receiving hormone replacement therapy. *Br J Obstet Gynecol* 1987;94:620-635.

Kaiserman-Abramof IR, Padykula HA. Ultrastructural epithelial zonation of the primate endometrium (rhesus monkey). *Am J Anat* 1989;184:13-30.

Kiel DP, Felson DT, Anderson JJ, Wilson PW, Moskowitz MA. Hip fractures and the use of estrogens in postmenopausal women. *N Engl J Med* 1987;317:1169-1174.

La Vecchia C, Negri E, Franceschi S, Talamini R, Amadori D, Filiberti R, Conti E, Montella M, Veronesi A, Parazzini F, et al. Oral contraceptives and breast cancer: a cooperative Italian study. *International Journal of Cancer*. 1995;60:163-7

London SJ, Connolly JL, Schnitt SJ, Colditz GA. A prospective study of benign breast disease and the risk of breast cancer. *JAMA* 1992; 267(7):941-4

MacPherson EE, Montagna W. The mammary glands of rhesus monkeys. *J Invest Dermatol* 1974;63:17-18.

Mahoney CJ. A study of the menstrual cycle in *Macaca* with special reference to the detection of ovulation. *J Reprod Fertil* 1970;21:153-163.

Mauvais-Jarvis P, Kuttann F, Gompel A. Antiestrogen action of progesterone in breast tissue. *Breast Cancer Res Treatment* 1986;8:179-188.

Moolgavkar SH, Day NE, Stevens RG. Two-stage model of carcinogenesis: Epidemiology of breast cancer in females. *J Natl Cancer Inst* 1980; 65:559-569.

Moore MR. Hathaway LD. Bircher JA. Progestin stimulation of thymidine kinase in the human breast cancer cell line T47D. *Biochimica et Biophysica Acta* 1991;1096(2):170-4

Mordenti J. Dosage regimen design for pharmaceutical studies conducted in animals. *J Pharmaceut Sci* 1986; 75:852-857.

Obasanjo IO, Clarkson TB, Weaver DS. Effects of the anabolic steroid nandrolone decanoate on plasma lipids and coronary arteries of female cynomolgus macaques. *Metabolism Clin Exp* 1996;45:463-8.

Ohi Y, Yoshida H. Influence of estrogen and progesterone on the induction of mammary carcinomas by 7,12-dimethylbenz(a)anthracene in ovariectomized rats. *Virchows Archiv - B - Cell Pathology* 1992;62:365-270.

Page DL. Dupont WD. Indicators of increased breast cancer risk in humans. *Journal of Cellular Biochemistry - Supplement*. 16G:175-82,1992.

Papa V. Reese CC. Brunetti A. Vigneri R. Siiteri PK. Goldfine ID. Progestins increase insulin receptor content and insulin stimulation of growth in human breast carcinoma cells. *Cancer Research* 1990;50(24):7858-62

Petitti DB, Perlman JA, Sidney S. Postmenopausal estrogen use and heart disease (letter). *N Engl J Med* 1986;315:131-132.

Pike MC. Spicer DV. Dahmouh L. Press MF. Estrogens, progestogens, normal breast cell proliferation, and breast cancer risk. *Epidemiologic Reviews* 1993;15(1):17-35.

Ravnikar VA. Compliance with hormone replacement therapy: are women receiving the full impact of hormone replacement therapy preventive health benefits?. *Womens Health Issues* 1992;2(2):75-80

Rodriguez GC, Walmer D, Lessey B, Cline M, Krigman H, Hughes CL. The effect of contraceptive progestins on the ovarian epithelium: cancer prevention through apoptosis. *Society for Gynecologic Investigation*, March 1997.

Schultz AH. Fetal growth and development of the rhesus monkey. *Carnegie Contributions to Embryology* 1937;26:71-97

Speert H. The normal and experimental development of the mammary gland of the rhesus monkey with some pathologic correlations. *Contributions to Embryology, The Carnegie Institute of Washington* 1948;32:9-65.

Stampfer MJ, Willett WC, Colditz GA, Rosner B, Speizer FE, Hennekens CH. A prospective study of postmenopausal estrogen therapy and coronary heart disease. *N Engl J Med* 1985;313:1044-1049.

Tavassoli FA, Casey HW, Norris HJ. The morphologic effects of synthetic reproductive steroids on the mammary gland of rhesus monkeys: Mestranol, ethynerone, mestranol/ethynerone, chloroethynyl norgestrel-mestranol, and anagestone acetate-mestranol combinations. *Am J Pathol* 1988 131:213-234.

Tsubura A, Hatano T, Hayama S, Morii S. Immunophenotypic difference of keratin expression in normal mammary glandular cells from five different species. *Acta Anatomica* 140:287-293, 1991

Uno, H. Age-related pathology and biosenescent markers in captive rhesus macques. *Age*. 20:1-13, 1997

Warner MR. Mammary pathology. In *Aging in Nonhuman Primates*, DM Bowden, ed. Van Nostrand Reinhold, New York, 1979

Washburn SA, Honoré EK, Cline JM, Helman M, Wagner JD, Adelman SJ, Clarkson TB. Effects of 17 $\alpha$ -dihydroequilenin sulfate on atherosclerotic male and female rhesus monkeys. *Am J Obstet Gynecol* 1996;175:341-351.

Weiss NS, Ure CL, Ballard JH, Williams AR, Daling JR. Decreased risk of fractures of the hip and lower forearm with postmenopausal use of estrogen. *N Engl J Med* 1980;303:1195-1198.

Wordinger RJ, Miller GW, Nicodemus DS. *Manual of Immunoperoxidase Techniques*. American College of Clinical Pathologists, 1987

World Health Organization. Histological typing of breast tumors. *Tumori* 1982; 68:181-192.

World Health Organization Technical Report Series No. 817. *Oral contraceptives and neoplasia*. WHO, Geneva, 1992.

**Personnel Receiving Pay:**

Name	Social Security No.	Role	Percentage of Salary
J. Mark Cline		Principal Investigator	25%
Brian A. McCollough		Laboratory Technician II	50%
Shannon Schmotzer		Laboratory Technician II	50%

**Graduate Degrees Received:**

None. No graduate student stipends are supported by this grant.

Brian McCollough is currently pursuing a Master's Degree in Biology from North Carolina Agricultural and Technical University, Greensboro, NC. He is not receiving stipend support from this grant, but the development of immunohistochemical methods of measuring cell proliferation in this grant has formed the basis of his thesis work, entitled. "Immunohistochemical Markers of Cell Proliferation in Macaques" We anticipate awarding of his degree in late 1997.

Gunnar Soderqvist, MD, received his doctorate (PhD) from the Karolinska Institute in 1996. His thesis work consisted in part of collaborative projects supported in part by this grant; however, his degree and primary support were from Sweden.

Erika Isaksson, MD, is currently working as a doctoral candidate at the Karolinska. Her doctoral work will include parallel studies of oral contraceptive effects in women and macaques, using in part materials from this project. Her primary support is also from the Karolinska.

## APPENDICES

### Appendix A: Publications

(copies of items in **bold** are attached)

Cline JM, Soderqvist G, von Schoultz E, Skoog L, von Schoultz B. Effects of hormone replacement therapy on the mammary gland of surgically postmenopausal cynomolgus macaques. *American Journal of Obstetrics & Gynecology*. 1996;174:93-100

Cline JM, Paschold JC, Anthony MS, Obasanjo IO, Adams MR. Effects of hormonal therapies and dietary soy phytoestrogens on vaginal cytology in surgically postmenopausal macaques. *Fertil Steril*. 1996;65:1031-1035

Cline JM, Soderqvist G, Skoog L, von Schoultz B. Regional distribution of proliferating cells and hormone receptors in the mammary gland of surgically postmenopausal macaques given hormone replacement therapy. *Gynecologic and Obstetric Investigation*, in press, 1997.

Cline JM, Hughes CL. Phytochemicals for the prevention of breast and endometrial cancer. In *Biological and Hormonal Therapies of Cancer*, eds. H Muss and K Foon. Kluwer Academic Publishers. In press.

**Foth D, Cline JM. Effects of mammalian and plant estrogens on mammary glands and uteri of macaques. Am J Clin Nutr, in press**

Von Schoultz B, Söderqvist G, Cline M, von Schoultz E, Skoog L. Hormonal regulation of the normal breast. *Maturitas* 1996, 23:S23-S25

Washburn SA, Honoré EK, Cline JM, Helman M, Wagner JD, Adelman SJ, Clarkson TB. Effects of 17 $\alpha$ -dihydroequilenin sulfate on atherosclerotic male and female rhesus monkeys. *Am J Obstet Gynecol* 1996;175:341-351.

**Cline JM, Soderqvist G, von Schoultz E, Skoog L, von Schoultz B. Effects of conjugated estrogens, medroxyprogesterone acetate, and tamoxifen on the mammary glands of macaques. Breast Cancer Research and Treatment, submitted.**

Isaksson E, Cline JM, Skoog L, Soderqvist G, Wilking N, von Schoultz E, von Schoultz B. p53 expression in breast and endometrium during estrogen and tamoxifen treatment of surgically postmenopausal cynomolgus macaques. *Breast Cancer Research and Treatment*, submitted.

## Appendix B: Abstracts and Presentations

(copies of items in **bold** are attached)

Cline JM, von Schoultz B, Skoog L, Clarkson TB. Can the cynomolgus macaque be used as a model for studying the effect of exogenous hormones on women? The Seventh International Congress on the Menopause, Stockholm, Sweden, June 21-25, 1993

Cline, JM; Soderqvist, G; von Schoultz, E; Skoog, L; von Schoultz, B Addition of medroxyprogesterone acetate to conjugated equine estrogens in surgically postmenopausal macaques: Divergent effects on mammary and endometrial tissue. Triangle Conference on Reproductive Biology, Research Triangle Park, NC, January 14, 1995

Divergent effects of hormone replacement on mammary and endometrial tissues of macaques. Cline, JM; Soderqvist, G; Skoog, L; von Schoultz, B Sixth Annual Meeting of the North American Menopause Society, San Francisco, CA, September 1995.

Cline JM, Bain FT. Uterine vascular changes indicating prior pregnancy in macaques. *Vet Pathol* 32:585, 1995.

Cline JM, Soderqvist G, Skoog L, von Schoultz B. Divergent effects of hormone replacement on mammary and endometrial tissues of macaques. *Menopause*. 1995;2:278

Cline JM, Foth D. Effect of mammalian and plant estrogens, tamoxifen, and medroxyprogesterone acetate on epithelial proliferation in the mammary glands and uteri of macaques. *Proceedings, American Association for Cancer Research*. 1996;37:284.

Cline JM, Foth D. Effects of mammalian and plant estrogens, tamoxifen, and medroxyprogesterone acetate on epithelial proliferation in the mammary glands and uteri of macaques. Triangle Conference on Reproductive Biology, Research Triangle Park, NC, January 16, 1996

Cline M. Endometrial changes induced by estrogens, tamoxifen, progestins, androgens, and soy in macaques. *Vet Pathol*. 1996;33:602

Cline JM, Söderqvist G, Foth D, Römer T, von Schoultz B. Effects of estrogens, tamoxifen, progestins, androgens and dietary soy on the mammary gland and endometrium of macaques The Eighth International Congress on the Menopause, Sydney, Australia, November 3-7, 1996

Cline JM, Söderqvist G, Foth D, Römer T, von Schoultz B. Effects of estrogens, tamoxifen, progestins, androgens and dietary soy on the mammary gland and endometrium of macaques The Eighth International Congress on the Menopause, Sydney, Australia, November 3-7, 1996

Davis VL, Cline JM, Tansey G, McCullough B, Hughes CL Jr. The effects of dietary isoflavones and conjugated equine estrogens on mammary proliferation in ovariectomized rats. *Breast Cancer Symposium of the Comprehensive Cancer Center of Wake Forest University, Winston-Salem, NC, August 29, 1996.*

Foth D, Cline JM. Effekte einer estrogenmonotherapie auf das mammagewebe von cynomolgus macaques. [The effect of an estrogen monotherapy on the mammary glands of cynomolgus macaques]. Bremen, German Society for Obstetrics and Gynecology, June 7-9, 1996.

Foth D, Cline JM. Die Wirkung von estradiol und phytoestrogenen (isoflavone) auf das mamma- und uterusgeweben von macaquen. [The effect of estradiol and phytoestrogens (isoflavones) on

the mammary glands and uterus of macaques]. Congress of Obstetrics and Gynecology, Dresden, October 1-5, 1996.

Hughes CL, Davis VL, and Cline, JM. Dietary soy isoflavones antagonize conjugated equine estrogen-induced proliferation of mammary gland epithelium in ovariectomized female rats. Society for Gynecologic Investigation, March, 1997.

Isaksson E, Cline JM, Soderqvist G, von Schoultz E, Wilking N, von Schoultz B, Skoog L. Immunohistochemical detection of p53 in breast and endometrial tissue of surgically postmenopausal cynomolgus macaques after HRT and tamoxifen treatment. 19th Annual San Antonio Breast Cancer Symposium, December 11-14, 1996.

McCollough BA, Cline JM. Characterization of proliferation markers in cynomolgus macaques. Triangle Conference on Reproductive Biology, "Ligands and Receptors in Reproduction", Research Triangle Park, NC, January 25, 1997

Ray S, Cline JM. Combined treatment with tamoxifen and low dose estradiol in surgically postmenopausal macaques: Effects on mammary and endometrial tissue. Triangle Conference on Reproductive Biology, "Ligands and Receptors in Reproduction", Research Triangle Park, NC, January 25, 1997

Register TC, Bora T, Cline JM, Hughes C, Adams M. The Classical Estrogen Receptor (ER alpha) and the newly described estrogen receptor beta are expressed in reproductive and non-reproductive tissues of cynomolgus monkeys. Triangle Conference on Reproductive Biology, "Ligands and Receptors in Reproduction", Research Triangle Park, NC, January 25, 1997

Rodriguez GC, Walmer D, Lessey B, Cline M, Krigman H, Hughes CL. The effect of contraceptive progestins on the ovarian epithelium: cancer prevention through apoptosis. Society for Gynecologic Investigation, March 1997.

**Appendix C: Experiment 91-20 - Manuscript submitted to Breast Cancer Research and Treatment**

**Effects of conjugated estrogens, medroxyprogesterone acetate, and tamoxifen on the mammary glands of macaques**

J. Mark Cline, DVM, PhD<sup>a</sup>; Gunnar Soderqvist, MD<sup>b</sup>; Eva von Schoultz, MD, PhD<sup>c</sup>; Lambert Skoog, MD, PhD<sup>d</sup>; Bo von Schoultz, MD, PhD<sup>b</sup>

From <sup>a</sup>the Department of Comparative Medicine, Bowman Gray School of Medicine of Wake Forest University, Winston-Salem, North Carolina, and the Departments of

<sup>b</sup>Obstetrics and Gynecology, <sup>c</sup>Oncology, and <sup>d</sup>Pathology and Cytology, Karolinska Hospital, Stockholm, Sweden.

Running Title: Estrogens, MPA and Tamoxifen

Address for offprints and correspondence:

J. Mark Cline, DVM, PhD

Assistant Professor of Comparative Medicine

Bowman Gray School of Medicine of Wake Forest University

Medical Center Boulevard

Winston-Salem, NC 27157-1040

Telephone: 910 716 9234

E-mail: jmcline@cpm.bgsu.edu

**Summary**

The purpose of this work was to examine the mammary glands of adult, ovariectomized female cynomolgus macaques (*Macaca fascicularis*) in a long-term study of the effects of hormone treatments on chronic disease. Treatments included conjugated equine estrogens (CEE), medroxyprogesterone acetate (MPA), CEE+MPA, and tamoxifen. Doses were scaled from those given women. Treatments were given in the diet for three years, followed by necropsy and tissue collection. Endpoints evaluated included glandular histology, histomorphometry, and immunohistochemical detection of the proliferation marker Ki-67, estrogen receptor (ER) and progesterone receptor (PR), in mammary epithelial cells. Major findings were as follows: CEE induced PR expression and focal to diffuse lobuloalveolar proliferation. Proliferation was increased by the addition of MPA, but was not induced by MPA alone. Tamoxifen induced ER and PR but not Ki-67 expression or glandular hyperplasia. Neoplasms were not seen. These findings indicate that progestogens may exacerbate, not antagonize mammary gland proliferation induced by estrogen replacement therapy; and that tamoxifen has both estrogen agonist and antagonist effects on sex steroid receptor expression in the normal primate breast.

Key words:

conjugated estrogens

estrogen receptor

medroxyprogesterone acetate

progesterone receptor

proliferation

tamoxifen

macaques

## Introduction

The hormonal regulation of proliferation in the normal breast is controversial and incompletely understood. Estrogen is generally accepted as a promoter of breast epithelial cell proliferation and also thought to be involved in the development and growth of breast cancer. The controversy concerns the action of progesterone/progestogen. In the endometrium it has been established that estrogen in high doses enhances proliferation and increases the risk of cancer, and that the addition of a progestogen counteracts this effect. Both combined and progestogen only contraception reduce endometrial cancer risk (1, 2). Virtually all glandular endometrial cells proliferate at rather low estradiol levels ( $\geq 200$  pmol/l) during the follicular phase and progestogen effects combine during the luteal phase to inhibit proliferation and to cause differentiation into a secretory endometrium (3). Whether the breast is affected in a similar manner is unclear and highly controversial. The literature on this issue is conflicting. The vast majority of *in vitro* studies of both breast cancer cell lines and normal breast cells in culture have shown that estrogens enhance breast cell proliferation and that the addition of a progestogen reduces this effect (4, 5). In contrast, most *in vivo* studies of the normal breast have shown the proliferation of breast epithelial cells to be highest during the luteal phase of the menstrual cycle (6-9). Studies of postmenopausal women have been too few to provide a clear understanding of the interactions of estrogens and progestins in the breast; epidemiologic evidence suggests that the addition of a progestin to estrogen replacement therapy does not protect the breast (10). One group has reported that high-dose topical progestin application exerts an antiproliferative effect in the face of estrogen treatment (11).

Tamoxifen is a widely used drug for adjuvant treatment of breast cancer, acting as an estrogen antagonist with antiproliferative effects (12). However in other target organs such as bone, endometrium and vaginal epithelium it has estrogen agonistic properties which are different in different organs (13, 14).

Macaques have well-documented similarities to women in terms of reproductive physiology and anatomy, mammary gland development, peripheral steroid hormone metabolism, mammary gland sex steroid receptors and cytokeratin immunophenotype (15-19). Thus the macaque model offers a unique opportunity for the study of hormonal and dietary effects on women's health, since it enables parallel evaluation of the effects of treatments on endometrium, mammary gland, cardiovascular system, bone, and behavioral endpoints in a primate. Effects of treatments in this study on atherosclerosis are published elsewhere (20, 21).

In a recent study on surgically postmenopausal macaques combined estrogen/progestogen treatment caused more breast proliferation and hyperplasia than treatment with estrogen alone (18). In the present study, breast proliferation and sex steroid receptors were assessed by immunohistochemistry in five different treatment groups of surgically postmenopausal macaques, including tamoxifen alone and a progestogen-only group. The latter group was included to elucidate progestogen effects on proliferation and sex steroid receptors during estrogen-deprived conditions.

## Methods

### *Animals and Study Design*

The subjects of this study were 125 feral adult female cynomolgus monkeys (*Macaca fascicularis*) imported from Indonesia (Charles River Primates, Port Washington, NY). Animals were treated continuously with either conjugated equine estrogens (CEE), medroxyprogesterone acetate (MPA), the combination of CEE+MPA, or tamoxifen for 2 years; a control group was also included. Eleven animals died during the course of the study, from causes unrelated to treatment; these animals were not included in analyses. Animals were housed in social groups of 4-8 monkeys each, in an AAALAC-accredited facility;

experimental protocols were approved by the Institutional Animal Care and Use committee. Bilateral ovariectomies were done on all animals 3 months prior to treatment. Test compounds were administered in the diet, at doses equivalent on a caloric basis to 0.625 mg/woman/day for CEE, 2.5 mg/woman/day for MPA, and 20 mg/day for Tamoxifen. The duration of treatment was 35 months. The base diet was modelled on a typical moderately atherogenic North American diet (40% of calories from fat, 0.2 mg/kcal cholesterol). Before treatment serum estradiol and progesterone were measured to confirm completeness of ovariectomy. Estradiol, estrone, medroxyprogesterone acetate and tamoxifen were measured during the treatment phase. Samples were taken 4 hours after feeding and dosing. Estrone, estradiol, and MPA analyses were performed using radioimmunoassay methods optimized for macaques (22) (by Dr. Mark Wilson, at the Comparative Endocrinology Laboratory of the Yerkes Regional Primate Center of Emory University, Atlanta). Tamoxifen analyses were performed by high-performance liquid chromatography (23).

#### *Tissue Collection and Processing*

Animals were euthanized by intravenous pentobarbital injection at the conclusion of the study. Mammary tissues were removed and immediately fixed in 4% formalin made fresh from paraformaldehyde, at 4°C. After 24 hours tissues were transferred into 70% ethanol, followed by trimming to 3 mm in thickness, embedding in paraffin, and sectioning at 5 microns. Mammary glands were sectioned sagittally through the nipple, including a 3-cm-long strip of underlying mammary gland. Tissues were then embedded in paraffin, and sectioned at 5 µm for immunostaining.

#### *Immunohistochemistry*

Sections were stained using a biotin-streptavidin staining method for the proliferation marker Ki-67. We used the NCL-Ki-67-MM1 mouse monoclonal antibody (Novocastra, Newcastle-upon-Tyne, U.K.) for detection of proliferating cells, and the mouse monoclonal antibodies NCL-ER-LH2 and NCL-PGR antibodies for detection of estrogen and progesterone receptor expression (Novocastra, Newcastle-upon-Tyne, U.K.). Our basic staining procedure uses a streptavidin-biotin-alkaline phosphatase method modified for antigen retrieval from paraffin-embedded tissue by the method of Cattoretti et al. (24).

#### *Assessment of sections*

Histopathological assessments of tissue sections were made by a board-certified veterinary pathologist (JMC) blinded to the treatment groups. Proliferation was assessed by histopathologic, morphometric, and immunohistochemical means. Sections were measured and counted using a Macintosh-based video imaging system and public domain software (NIH Image, public-domain software available via the Internet by anonymous FTP {file transfer protocol} from zippy.nimh.nih.gov). Measurements of mammary gland thickness, and of the percentage of the gland occupied by lobulolaveolar tissue versus fat and stroma, were made by manual tracing of the structures of interest on the video image. Thickness was measured at 20x, and percentage area was measured at 40x. Immunostained (proliferating) cells were randomly identified in both ducts and lobuloalveolar tissue at 400x using a randomly-placed grid to objectively select cells for counting; this method reduces variance (25). For the purposes of analysis, cells with any amount of staining were considered positive.

#### *Statistical methods*

Data analysis was performed using the JMP statistical program (SAS Institute, Cary, NC, U.S.A.). Statistical analysis was performed using the Mann-Whitney U-test with Bonferroni

corrections for multiple comparisons, Kruskal Wallis test, Chi-square test, and Spearman's rank correlation test.

## **Results**

### *Hormone Measurements*

Before treatment estradiol concentrations in the ovariectomized animals were low (averaging <10 pg/ml for estradiol and <1 pg/ml for progesterone), and did not differ by group. Serum hormone concentrations during the treatment phase reflected the clinically relevant doses of hormones and drugs given. These data are summarized in table 1.

### *Subjective Evaluation of Mammary Morphology*

Mammary gland proliferation was induced by CEE, and this effect was further increased by the addition of MPA. Neither MPA alone nor tamoxifen induced mammary gland proliferation. Mammary hyperplasia consisted of diffuse lobular enlargement; ductal hyperplasia and atypia were not seen (see Table 2). No neoplasms were encountered.

### *Morphometry and Stereology*

Mammary gland thickness, lobular size, and lobule numbers per unit area were significantly increased by treatment with CEE with or without MPA; all values were greatest for animals given CEE+MPA. Lobular area measurements are illustrated in figure 1.

### *Immunohistochemistry*

Estrogen and progesterone receptor expression were limited to glandular epithelium of the breast. For Ki-67, positively stained cells were also seen in the basal layers of the skin and particularly in hair follicles. Stromal staining was not seen with any immunostain. Proliferation as measured by Ki-67 expression was maximal in animals given CEE+MPA (Kruskal-Wallis,  $p < 0.05$ ). In pairwise comparisons by the Mann Whitney test, results of animals given CEE+MPA differed from controls, tamoxifen-treated animals, and MPA-treated animals ( $p < 0.05$ )(figure 2). Ki-67 expression correlated well with lobular area ( $\rho = 0.3683$ ,  $p < 0.0001$ ), as would be expected for the two complementary measures of proliferative effect. Estrogen receptor expression was not markedly altered by treatment. There was a slight ER-inducing effect on CEE alone on large ducts ( $p < 0.05$ ). In lobuloalveolar tissue, there was no significant difference between CEE and the other treatments. Overall treatment group effects for PR expression were strongly significant (Kruskal-Wallis test,  $p < 0.0001$ ). Both CEE and tamoxifen induced progesterone receptor expression in ductal and lobuloalveolar tissue, relative to controls and MPA-treated animals ( $p < 0.05$ ). The addition of MPA to CEE reduced PR expression to control levels (figure 3). Alveolar PR expression was significantly correlated with lobular area ( $\rho = 0.2446$ ,  $p = 0.0090$ ). Lobuloalveolar ER and PR expression correlated positively ( $\rho = 0.3012$ ,  $p = 0.0011$ ).

Regarding serum concentrations of hormones, the following correlations were found: In the entire study population, alveolar PR correlated with serum estradiol and estrone concentrations. Lobuloalveolar Ki67 staining and the percentage of the gland occupied by epithelium correlated with serum estrone, estradiol, and MPA concentrations. Among Tamoxifen-treated animals, there was a significant correlation of serum tamoxifen with ductal and lobuloalveolar ER. Results are summarized in Table 3.

## Discussion

The proliferative effect of conjugated equine estrogens on breast epithelium and its further enhancement by the addition of medroxyprogesterone acetate confirms previous data in the macaque model (26). These findings parallel those of a recent large clinical trial of HRT-associated breast cancer risk which has shown that MPA does not reduce the breast cancer risk associated with estrogen replacement therapy (10). Meta-analyses of clinical trials addressing this question have pointed to the relatively weak association between breast cancer and HRT (relative risk is generally considered to be around 1.5 to 2.0), and to the paucity of studies of combined HRT (27, 28). The present results also are in line with the well-documented evidence that *in vivo* in the normal menstrual cycle of women, breast cell proliferation occurs at the highest rate during the luteal phase (6-8, 29). This indicates a similarity between the actions of endogenous progesterone and exogenous progestogens on breast cell proliferation. The finding that long-term estrogen/progestagen treatment induced marked proliferation despite downregulation of both ER and PR is interesting. It is possible that very low receptor levels are needed to mediate proliferation. A direct sex steroid stimulating effect on growth factors and/or their receptors is another tentative explanation. The progestogen R 5020 stimulates insulin-mediated breast cancer cell proliferation by increasing insulin receptors and insulin receptor mRNA content (30). Estrogens, progestogens and several growth factors (e.g. IGF-1, bFGF, and EGF) can independently initiate cell cycle progression in breast cancer cell lines. Progestogens have been shown to increase cyclin D1 and the rate of cell cycle progression. Steroid hormones probably act by increasing transcription of target genes intimately involved in cell cycle progression (31, 32). However while the combination of CEE+ MPA increased breast epithelial proliferation there was no proliferative effect of MPA alone under the estrogen-deprived conditions in surgically postmenopausal macaques. In women of fertile age both intramuscular injection of MPA and progestogen only oral contraceptives have been shown to increase breast epithelial proliferation and cancer risk (6, 33, 34). Thus it seems that in the normal breast MPA has no proliferative effect when serum estradiol levels are low. This finding contrasts to the proliferative effect of synthetic progestogens without addition of estrogens found in several *in vitro* studies on breast cancer cell lines (30, 35, 36).

As expected there was no induction of breast epithelial proliferation in the group of monkeys receiving tamoxifen. Tamoxifen is widely used in the therapy of breast cancer, and has a well documented antitumoral effect. It is believed to act as a general estrogen antagonist in breast tissue, primarily via estrogen receptor-mediated mechanisms (37). However, tamoxifen has clear estrogen agonist effects in many other systems such as bone, endometrium, vaginal epithelium and certain aspects of liver function (13, 14). Therefore the upregulation of progesterone receptor found in this study is of great interest. Here we demonstrate a clear estrogen agonistic effect of tamoxifen in normal breast tissue. Encarnation et al found that PR expression was maintained in breast carcinomas in the face of tamoxifen treatment (38). The enhanced progesterone receptor content during tamoxifen treatment may be the basis for the therapeutic effect of intermittent tamoxifen + progestogen treatment under estrogen deprived conditions of breast cancer in postmenopausal women. In a previous study Walker et al found no significant changes in PR, Ki-67, or epidermal growth factor receptor in tamoxifen-treated women. However they demonstrated induction of ER by tamoxifen in normal breast tissue adjacent to tumor tissue in women (39). In contrast, Lundgren et al. found induction of ER by tamoxifen in breast tumors (40). Although a distinct treatment group effect for tamoxifen induction of ER was not seen in this study, correlation analysis within the tamoxifen-treated group did reveal a positive

correlation between ER and serum tamoxifen, as well as a negative correlation between serum tamoxifen and estradiol concentrations.

In conclusion, we have found that progestogens augment rather than antagonize the proliferation-inducing effects of estrogen in the primate breast. Another important finding in this study is that the divergent agonistic/antagonistic effects induced by tamoxifen in different organs are not limited to a between-organ variation; that is, within the normal breast divergent effects are also apparent. Tamoxifen acts like an estrogen antagonist on proliferation and ER expression, but in contrast it has a clear estrogen agonistic influence on progesterone receptor expression. Interpretation of this observation will require further study.

### **Acknowledgments**

We are grateful for the support of Drs. Michael Adams and Koudy Williams, and for the technical assistance of Brian McCollough and Shannon Schmotzer.

Supported by grant DAMD17-94-J-4201, US Army Medical Research Acquisition Activity, Fort Detrick, MD; by grants HL-490852 and HL-45666, National Heart, Lung and Blood Institute, National Institutes of Health, Bethesda, MD; and by the Swedish Medical Research Council (project No. 5982); the Karolinska Institute Research Funds; and the Swedish Cancer Society.

### **References**

1. Vihko R, Isomaa V. Endocrine aspects of endometrial cancer. In: Voight K, Knabbe C, eds. *Endocrine Dependent Tumors*. New York: Raven Press LTD, pp. 197-2124, 1989.
2. Pike M. Hormonal contraception with LHRH agonists and the prevention of breast and ovarian cancer. In: Mann R, ed. *Oral contraceptives and breast cancer*. Lancaster, England: Parthenon Publishing Group, pp. 323-348, 1990.
3. Key TJ, Pike MC: The dose-effect relationship between 'unopposed' oestrogens and endometrial mitotic rate: its central role in explaining and predicting endometrial cancer risk. *British Journal of Cancer* 57 (2): 205-12, 1988.
4. Gompel A, Malet C, Spritzer P, Lalandrie JP, Kuttenn F, Mauvais-Jarvis P: Progesterin effect on cell proliferation and 17 beta-hydroxysteroid dehydrogenase activity in normal human breast cells in culture. *Journal of Clinical Endocrinology & Metabolism* 63 (5): 1174-80, 1986.
5. Mauvais-Jarvis P, Kuttenn F, Gompel A: Antiestrogen action of progesterone in breast tissue. *Breast Cancer Research & Treatment* 8 (3): 179-88, 1986.
6. Anderson TJ, Battersby S, King RJ, McPherson K, Going JJ: Oral contraceptive use influences resting breast proliferation. *Human Pathology* 20 (12): 1139-44, 1989.
7. Longacre TA, Bartow SA: A correlative morphologic study of human breast and endometrium in the menstrual cycle. *American Journal of Surgical Pathology* 10 (6): 382-93, 1986.
8. Potten CS, Watson RJ, Williams GT, Tickle S, Roberts SA, Harris M, Howell A: The effect of age and menstrual cycle upon proliferative activity of the normal human breast. *British Journal of Cancer* 58 (2): 163-70, 1988.
9. Vogel PM, Georgiade NG, Fetter BF, Vogel FS, McCarty KS, Jr.: The correlation of histologic changes in the human breast with the menstrual cycle. *American Journal of Pathology* 104 (1): 23-34, 1981.
10. Colditz GA, Hankinson SE, Hunter DJ, Willett WC, Manson JE, Stampfer MJ, Hennekens C, Rosner B, Speizer FE: The use of estrogens and progestins and the risk of

breast cancer in postmenopausal women. *New England Journal of Medicine* 332 (24): 1589-93, 1995.

11. Chang KJ, Lee TT, Linares-Cruz G, Fournier S, de Lignieres B: Influences of percutaneous administration of estradiol and progesterone on human breast epithelial cell cycle in vivo. *Fertility & Sterility* 63 (4): 785-91, 1995.
12. Rose C, Thorpe SM, Andersen KW, Pedersen BV, Mouridsen HT, Blichert-Toft M, Rasmussen BB: Beneficial effect of adjuvant tamoxifen therapy in primary breast cancer patients with high oestrogen receptor values. *Lancet* 1 (8419): 16-9, 1985.
13. Helgason S, Wilking N, Carlstrom K, Damber MG, von Schoultz B: A comparative study of the estrogenic effects of tamoxifen and 17 beta-estradiol in postmenopausal women. *Journal of Clinical Endocrinology & Metabolism* 54 (2): 404-8, 1982.
14. Fornander T, Rutqvist LE, Wilking N, Carlstrom K, von Schoultz B: Oestrogenic effects of adjuvant tamoxifen in postmenopausal breast cancer. *European Journal of Cancer* 29A (4): 497-500, 1993.
15. Mahoney C: A study of the menstrual cycle in *Macaca* with special reference to the detection of ovulation. *J Reprod Fertil* 21: 153-163, 1970.
16. Kaiserman-Abramof I, Padykula H: Ultrastructural epithelial zonation of the primate endometrium (rhesus monkey). *Am J Anat* : 13-30, 1989.
17. Martel C, Melner MH, Gagne D, Simard J, Labrie F: Widespread tissue distribution of steroid sulfatase, 3 beta-hydroxysteroid dehydrogenase/delta 5-delta 4 isomerase (3 beta-HSD), 17 beta-HSD 5 alpha-reductase and aromatase activities in the rhesus monkey. *Molecular & Cellular Endocrinology* 104 (1): 103-11, 1994.
18. Cline JM, Paschold JC, Anthony MS, Obasanjo IO, Adams MR: Effects of hormonal therapies and dietary soy phytoestrogens on vaginal cytology in surgically postmenopausal macaques. *Fertility & Sterility* 65 (5): 1031-5, 1996.
19. Tsubura A, Hatano T, Hayama S, Morii S: Immunophenotypic difference of keratin expression in normal mammary glandular cells from five different species. *Acta Anatomica* 140: 287-293, 1991.
20. Adams MR, Register TC, Golden DL, Wagner JD, Williams JK: Medroxyprogesterone acetate antagonizes inhibitory effects of conjugated equine estrogens on coronary artery atherosclerosis. *Arteriosclerosis Thrombosis & Vascular Biology* 17 (1): 217-221, 1997.
21. Williams JK, Wagner JD, Li Z, Golden DL, Adams MR: Tamoxifen inhibits arterial accumulation of LDL degradation products and progression of coronary artery atherosclerosis in monkeys. *Arteriosclerosis Thrombosis & Vascular Biology* 17 (2): 403-408, 1997.
22. Wilson ME, Gordon TP, Rudman CG, Tanner JM: Effects of a natural versus artificial environment on the tempo of maturation in female rhesus monkeys. *Endocrinology* 123 (6): 2653-61, 1988.
23. Langan-Fahey SM, Tormey DC, Jordan VC: Tamoxifen metabolites in patients on long-term adjuvant therapy for breast cancer. *European Journal of Cancer* 26 (8): 883-8, 1990.
24. Cattoretti G, Becker MH, Key G, Duchrow M, Schluter C, Galle J, Gerdes J: Monoclonal antibodies against recombinant parts of the Ki-67 antigen (MIB 1 and MIB 3) detect proliferating cells in microwave-processed formalin-fixed paraffin sections. *Journal of Pathology* 168 (4): 357-63, 1992.
25. Lindholm J, van Diest PJ, Haffner D, Mikuz G, Wegner AR: A morphometric filter improves the diagnostic value of morphometric analyses of frozen histopathologic sections from mammary tumors. *Analytical Cell Pathology* 4: 443-449, 1992.
26. Cline JM, Soderqvist G, von Schoultz E, Skoog L, von Schoultz B: Effects of hormone replacement therapy on the mammary gland of surgically postmenopausal

- cynomolgus macaques. *American Journal of Obstetrics & Gynecology* 174 (1 Pt 1): 93-100, 1996.
27. Colditz GA, Egan KM, Stampfer MJ: Hormone replacement therapy and risk of breast cancer: results from epidemiologic studies. *American Journal of Obstetrics & Gynecology* 168 (5): 1473-80, 1993.
  28. Grady D, Rubin SM, Petitti DB, Fox CS, Black D, Ettinger B, Ernster VL, Cummings SR: Hormone therapy to prevent disease and prolong life in postmenopausal women. *Annals of Internal Medicine* 117 (12): 1016-37, 1992.
  29. Soderqvist G, Isaksson E, von Schoultz B, Carlstrom K, Tani E, Skoog L: Proliferation of breast epithelial cells in healthy women during the menstrual cycle. *American Journal of Obstetrics & Gynecology* 176 (1 Pt 1): 123-8, 1997.
  30. Goldfine ID, Papa V, Vigneri R, Siiteri P, Rosenthal S: Progesterin regulation of insulin and insulin-like growth factor I receptors in cultured human breast cancer cells. *Breast Cancer Research & Treatment* 22 (1): 69-79, 1992.
  31. Sutherland RL, Hamilton JA, Sweeney KJ, Watts CK, Musgrove EA: Steroidal regulation of cell cycle progression. *Ciba Foundation Symposium* 191: 218-28; discussion 228-34, 1995.
  32. Truss M, Beato M: Steroid hormone receptors: interaction with deoxyribonucleic acid and transcription factors. *Endocrine Reviews* 14 (4): 459-79, 1993.
  33. Kaunitz AM: Depot medroxyprogesterone acetate contraception and the risk of breast and gynecologic cancer. *Journal of Reproductive Medicine* 41 (5 Suppl): 419-27, 1996.
  34. Anonymous: Breast cancer and hormonal contraceptives: collaborative reanalysis of individual data on 53 297 women with breast cancer and 100 239 women without breast cancer from 54 epidemiological studies. Collaborative Group on Hormonal Factors in Breast Cancer. *Lancet* 347 (9017): 1713-27, 1996.
  35. Moore MR, Hathaway LD, Bircher JA: Progesterin stimulation of thymidine kinase in the human breast cancer cell line T47D. *Biochimica et Biophysica Acta* 1096 (2): 170-4, 1991.
  36. Kloosterboer HJ, Schoonen WG, Deckers GH, Klijn JG: Effects of progestagens and Org OD14 in *in vitro* and *in vivo* tumor models. *Journal of Steroid Biochemistry & Molecular Biology* 49 (4-6): 311-8, 1994.
  37. Nayfield SG: Tamoxifen's role in chemoprevention of breast cancer: an update. *Journal of Cellular Biochemistry - Supplement* 22: 42-50, 1995.
  38. Encarnacion CA, Ciocca DR, McGuire WL, Clark GM, Fuqua SA, Osborne CK: Measurement of steroid hormone receptors in breast cancer patients on tamoxifen. *Breast Cancer Research & Treatment* 26 (3): 237-46, 1993.
  39. Walker KJ, Price-Thomas JM, Candlish W, Nicholson RI: Influence of the antioestrogen tamoxifen on normal breast tissue. *British Journal of Cancer* 64 (4): 764-8, 1991.
  40. Lundgren S, Soreide JA, Lea OA: Influence of tamoxifen on the tumor content of steroid hormone receptors (ER, PgR and AR) in patients with primary breast cancer. *Anticancer Research* 14 (3B): 1313-6, 1994.

**Table 1. Serum hormone concentrations.**

Group	N	Estrone pg/ml	SEM	E2 pg/ml	SEM	MPA pg/ml	SEM	Tamoxifen ng/ml	SEM
Control	23	19.5	3.2	8.7	8.1	nd	-	nd	-
CEE	26	84.0	6.3	136.0 $\Delta$	7.6	nd	-	nd	-
MPA	21	19.1	2.9	15.3	8.4	80.3	10.8	nd	-
CEE+MPA	27	81.0	8.4	126.6 $\Delta$	7.4	68.2	4.9	nd	-
TAM	25	23.3	1.4	6.8	7.7	nd	-	5.0	1.0

$\Delta$ significantly different from groups not given CEE (p<0.0001)

**Table 2. Histopathologic assessment of the degree of mammary gland hyperplasia.**

Mammary Epithelial Proliferation Grade	Control	CEE	MPA	CEE+MPA	Tamoxifen
0 (none)	<b>11/20</b>	2/25	<b>13/19</b>	0/26	<b>14/24</b>
1 (mild)	6/20	5/25	4/19	2/26	4/24
2 (moderate)	3/20	5/25	2/19	6/26	5/24
3 (marked)	0/20	<b>13/25</b>	0/19	<b>18/26</b>	1/24

**Table 3. Correlations between serum hormone concentrations and measures of mammary gland proliferation and regulation.**

Hormone	Response	Spearman Rho	Prob> Rho
Estradiol	Lobuloalveolar PR	0.2893	0.0017
Estradiol	Lobuloalveolar Ki67	0.2769	0.0029
Estradiol	Lobuloalveolar area	0.6007	<.0001
Estrone	Lobuloalveolar PR	0.2433	0.0088
Estrone	Lobuloalveolar Ki67	0.2617	0.0049
Estrone	Lobuloalveolar area	0.6192	<.0001
Tamoxifen	Ductal ER	0.5331	0.0155
Tamoxifen	Lobuloalveolar ER	0.4619	0.0403

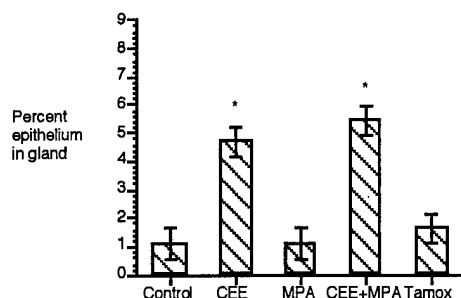


Figure 1 - Percentage of mammary glandular tissue (including skin, fat and connective tissue) occupied by glandular epithelium. Asterisks indicate groups differing from controls (p < 0.0001).

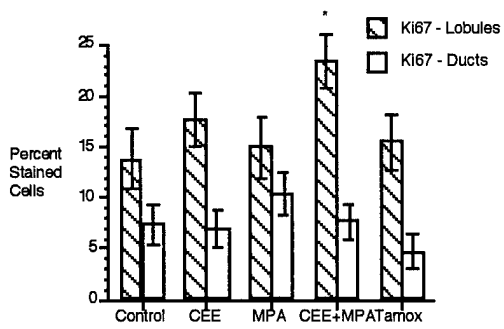


Figure 2 - Ki-67 staining in mammary epithelial cells, expressed as percentage positively-stained cells. Stars indicate groups differing from controls at  $p < 0.05$ .

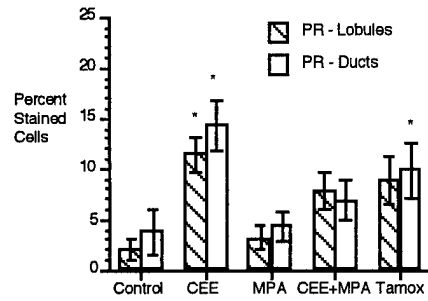


Figure 3 - Progesterone receptor staining in mammary epithelial cells, expressed as percentage positively-stained cells. Stars indicate groups differing from controls at  $p < 0.05$ . CEE and MPA also differ at  $p < 0.05$  for both sites.

**Appendix D: Experiment 94-33 - Paper in press, American Journal of Clinical Nutrition**

**Effects of mammalian and plant estrogens on mammary glands and uteri of macaques**

Dolores Foth\*, J. Mark Cline†

From \*the Department of Obstetrics and Gynecology, Ernst-Moritz-Arndt University, Greifswald, Germany, and † the Department of Comparative Medicine, Bowman Gray School of Medicine of Wake Forest University, Winston-Salem, North Carolina, U.S.A.

Correspondence to: Dr. J. Mark Cline, Department of Comparative Medicine, Bowman Gray School of Medicine of Wake Forest University, Medical Center Boulevard, Winston-Salem, North Carolina, U.S.A. 27157. Telephone 910 716 9234 Fax 910 716 5073 Email [jmcline@cpm.bgsu.edu](mailto:jmcline@cpm.bgsu.edu)

This study was supported in part by grants DAMD 17-94-J-4201 from the US Army Medical Research Acquisition Activity, Fort Detrick, MD, U.S.A.; and by a supplement to Grant RR008562-02 from the Office of Research on Women's Health, National Institutes of Health, Bethesda, MD, U.S.A.

Running head: Estradiol and soy effects on uterus and breast

**Abstract**

Because of their beneficial effects on atherosclerosis and cancer risk, soy phytoestrogens may be useful as a dietary alternative or supplement to postmenopausal hormone replacement therapy. We examined this possibility in a well-characterized primate model of the postmenopause. Adult, surgically postmenopausal female macaques (*Macaca fascicularis*) were treated continuously with either estradiol (E2), isoflavone-rich soy isolate (SBE), or E2+SBE. Doses were equivalent on a caloric basis to 1 mg/woman/day for estradiol, and 148 mg/woman/day for soy isoflavones. After 6 months histopathologic, morphometric and immunohistochemical measurements of endometrium and mammary glands were done. Increases in endometrial thickness, gland area, and epithelial proliferation were induced by E2 and E2+SBE. Morphometric changes were accompanied by increased epithelial Ki-67 staining in the E2-treated group. The effects of E2 were partially antagonized by SBE (manifested as decreased Ki-67 staining). Mammary gland proliferation was induced by E2 and E2+SBE. The effects of E2 were also antagonized by SBE in the mammary gland. Morphometric and immunohistochemical measures of proliferation were in agreement in both tissues. In this nonhuman primate model, SBE treatment did not induce proliferation in endometrium and mammary tissue. The results indicate that SBE may have antiproliferative effects in the endometrium and mammary gland when given along with exogenous estrogen.

Key words: cynomolgus monkeys, uterus, breast, plant estrogens, mammalian estrogens

**Introduction**

Compliance to traditional estrogen replacement therapy is very low due to unwanted side effects and concern about the associated risk of breast and uterine cancer (1). A postmenopausal regimen is needed that provides the benefits of traditional hormone replacement therapy and at the same time protects against endometrial and breast cancer

without adding a progestin. For many reasons, phytoestrogens of soybeans (e.g., genistein and daidzein) alone, or in combination with mammalian estrogens, may provide this alternative.

The cynomolgus macaque (*Macaca fascicularis*) model offers a unique opportunity for the study of hormonal and dietary effects on the endometrium and mammary gland. Macaques have a distinct menarche and menopause, at about 3 and 20 years of age. They have a 28-day menstrual cycle, with a hormonal profile similar to that of women (2). Their endometrial responses to endogenous and exogenous hormones parallel those of women (3).

Human and nonhuman primate mammary glands and endometrium have many similarities, in terms of anatomy, hormonal regulation (4), and cytokeratin immunophenotype (5), that are not shared by the commonly used laboratory rodents. Mammary neoplasms are uncommon in macaques (6). Importantly, this monkey model is well-characterized (7,8) and enables concurrent evaluation of the effects of treatment in mammary gland, endometrium, cardiovascular system, bone, and brain. Mammary glands of the female macaque undergo hyperplasia in response to estrogen and estrogen/progestin treatment, in a manner analogous to that seen in women (9). These responses mirror the effect on cancer risk caused by estrogen and estrogen-progestin hormone replacement therapy in postmenopausal women (10), and we believe they provide a reasonable model of a cancer-prone state. We believe that the female cynomolgus macaque provides a good model for assessing the benefits and risks of estrogens and estrogen alternatives.

### Materials and Methods

In a recent study of hormone replacement therapy and diet, adult, surgically postmenopausal female macaques were treated continuously with either estradiol (E2), isoflavone-rich soy isolate (Soybean estrogens: SBE), or E2+SBE for 6 months. There were 15 animals per group. Test compounds were administered in the diet at doses equivalent on a caloric basis to 1 mg/woman/d for E2, and 148 mg/woman/d for soy isoflavones. The base diet was modeled on a typical moderately atherogenic North American diet (40% of calories from fat, 0.2 mg/kcal cholesterol). Serum estradiol and progesterone were measured after 5 months of treatment, to confirm completeness of ovariectomy. Hormone analyses were performed using methods optimized for macaques (by Dr. Mark Wilson, at the Comparative Endocrinology Laboratory of the Yerkes Regional Primate Center of Emory University, Atlanta).

Animals were euthanized by intravenous pentobarbital injection at the conclusion of the study. Tissues were removed and immediately fixed in 4% formalin made fresh from paraformaldehyde, at 4°C. After 24 hours tissues were transferred into 70% ethanol, followed by trimming to 3 mm in thickness, embedding in paraffin, and sectioning at 5 microns. Ovariectomy scars were sectioned to confirm completeness of ovarian excision. Animals with histologically detected ovarian remnants or ectopic ovarian tissue were excluded from the study; final numbers included are given in Table 1. Uteri were sectioned transversely at the point of greatest width. Mammary glands were sectioned sagittally through the nipple, including a 3-cm strip of underlying mammary gland. Adjacent sections were stained with hematoxylin and eosin, and using a biotin-streptavidin staining method for the proliferation marker Ki-67. We used the NCL-Ki-67-MM1 mouse monoclonal antibody (Novocastra, Newcastle-upon-Tyne, U.K.).

Histopathological assessments of tissue sections were made by a board-certified veterinary pathologist (JMC) blinded to the treatment groups. Proliferation was assessed by histopathologic, morphometric, and immunohistochemical means in endometrium and mammary gland. Sections were measured and counted using a Macintosh-based video imaging system and public domain software (NIH Image, available via the Internet by anonymous FTP [file transfer protocol] from [zippy.nimh.nih.gov](http://zippy.nimh.nih.gov)).

Measurements of endometrial and mammary gland thickness, and of the percentage of the endometrium and mammary gland occupied by luminal space, epithelium, and stroma, were made by manual tracing of the structures of interest on the video image. Thickness was measured at 20x, and percentage area was measured at 100x. For each feature, three fields were measured from a single section per animal; this number of measurements provides 90% statistical reliability in our laboratory (unpublished data).

Immunostained (proliferating) cells were randomly identified using the grid-filtering method of Lindholm (11). For the purposes of analysis, cells with any amount of staining were considered positive. Data analysis was performed using the JMP statistical program (SAS Institute, Cary, NC, U.S.A.). Means were compared using the analysis of variance and Student's t tests.

## Results

Mean serum estradiol concentrations attained were  $4.6 \pm 12.5$ ,  $241 \pm 11.9$ , 0, and  $201 \pm 14.3$  pg/ml for controls, E2 alone, SBE, and E2+SBE, respectively, reflecting successful dosing; the groups given E2 differed from controls and SBE alone, but not from each other, at  $p < 0.05$ . For serum progesterone, the corresponding concentrations were  $1.2 \pm 0.25$ ,  $1.1 \pm 0.23$ ,  $0.5 \pm 0.27$ , and  $1.0 \pm 0.29$  pg/ml, respectively (no groups differed).

### *Endometrium*

Uterine weights were significantly increased in the groups given E2 ( $4.66 \pm 1.03$  g) or E2+SBE ( $5.09 \pm 2.60$  g) relative to the control ( $1.81 \pm 1.45$  g) or SBE alone groups ( $2.30 \pm 1.06$  g) ( $p < 0.05$ ). There was histopathologic evidence of endometrial hyperplasia in all animals given E2 alone or E2+SBE; the degree and irregularity of the hyperplasia was less in the latter group (Table 1). Atypical hyperplasia was not seen. Mild endometrial hyperplasia was seen in 3 of 11 control monkeys and 3 of 9 monkeys fed SBE alone. Increases in endometrial thickness and gland area (as percentage of total endometrium area) were induced by E2, and the addition of SBE to the regimen did not decrease the morphological effect (Figure 1). Morphometric changes were accompanied by increased Ki-67 staining in the animals given E2 alone; this proliferative effect was antagonized by the addition of SBE (Figure 2).

### *Mammary gland*

There were varying degrees of diffuse mammary lobuloalveolar hyperplasia in some animals in each treatment group (Table 1). Hyperplasia was present in more monkeys in the E2-treated groups; however, because animals were of varying parity status, histopathologic interpretation was confounded by previous lactation in some animals.

Mammary thickness increased to an insignificant degree in the E2 and SBE+E2 groups, but mammary epithelial area was significantly increased in both groups, at  $p < 0.05$  (Figure 3). No atypical hyperplasia was noted in any mammary structures. The morphometric and immunohistochemical measurements of proliferation were in parallel; that is, E2-treated animals had a significant increase in Ki-67 labeling ( $p < 0.05$ ). The effects of E2 were somewhat antagonized by the addition of SBE, but the percentage of cells stained did not differ from controls in either the SBE or the E2+SBE groups (Figure 4).

SBE treatment was associated with increased body weight (mean  $4.34 \pm 1.62$  kg), whereas the E2+SBE-treated monkeys lost weight ( $3.04 \pm 0.39$  kg) compared to control monkeys ( $3.58 \pm 0.94$  kg). Only SBE-treated and E2+SBE-treated monkeys differed at  $p < 0.05$ .

## Discussion

We assessed several markers of estrogenic action in these surgically postmenopausal monkeys. Uterine weight demonstrated no estrogenic activity of SBE at the dose studied. We also found no estrogenic effects of the administered dose of phytoestrogens on morphometric, histopathologic, or immunohistochemical measurements in mammary gland or endometrial tissues. In addition, we found no evidence that the combination of SBE and E2 was additive in effect; on the contrary, in this study SBE appeared to antagonize the effect of E2. This finding is in contrast to some *in vitro* studies of phytoestrogens using mammary tumor cells (12). In the endometrium of monkeys we studied, the E2-caused proliferation was clearly antagonized by SBE. On the other hand, the mammary glands of SBE-treated monkeys showed slight ( $p = \text{NS}$ ) increases in proliferation, especially in the large ducts. However, the combination of SBE+E2 showed the same slight increase, suggesting that SBE blunted the proliferative response of mammary glands to E2.

Soy in general and genistein specifically prevent breast cancer in rodent models (13,14). In epidemiologic studies, the relatively lower risk of breast and endometrial cancer in some Asian populations compared to Western women is well documented (15-17). The observation that the lower risk of breast cancer disappears in Asian immigrants to the US (18), and urban subpopulations within Japan (19) suggests that epigenetic factors are responsible for the difference. This phenomenon may reflect either assimilation to a "Western" diet and/or a risk factor exerting an adverse effect during development. The increase in breast cancer in Asians consuming typically "Western" foods implicates diet as a cause for the lower breast cancer incidence in Asians consuming their native diet (19).

There are several potential mechanistic bases for antiproliferative effects of soy phytoestrogens in breast and endometrial tissues. Women consuming diets higher in grain fiber and isoflavones have higher concentrations of serum sex hormone-binding globulin and therefore less free estradiol in plasma (20,21). In addition, diphenolic phytoestrogen compounds also inhibit aromatase activity (22) and 17 $\beta$  hydroxysteroid oxidoreductase type 1 (12), thus potentially diminishing the formation of estradiol from other steroids.

Genistein binds with approximately 1/250th of the affinity of estradiol to the estrogen receptor (23). Interestingly, several investigators have shown that in the absence of estrogen, isoflavones have weakly estrogenic effects, whereas in the presence of estrogen, they may exert an antagonistic effect (24,25). This suggests a competitive estrogen receptor-mediated mechanism. However, it is likely that the weak estrogenicity of genistein has little to do with its cancer-protective effects (13). Martin (26) postulated that phytoestrogens might promote tumor growth upon demonstrating their proliferation-inducing effect on MCF-7 mammary carcinoma cells and their relatively low affinity (27% of E2) for sex hormone-binding globulin. Genistein at nanomolar concentrations may in fact have additive effects on estrogen-induced cell proliferation (12). At higher concentrations, genistein has antiproliferative effects in MCF-7 breast cancer cells without respect to their estrogen receptor positivity (27). This effect is therefore presumably not dependent on the receptor, and may be mediated by genistein's potent inhibition of tyrosine kinase activity (28). Genistein is also an inhibitor of DNA topoisomerase (29), an antioxidant (30), and induces apoptosis in breast cancer cell lines *in vitro* (31), all potential mechanisms by which it may exert antiproliferative effects. Serum isoflavone concentrations were not measured in this study; however, in animals of the same species consuming a diet of similar composition to that given the SBE-treated group in this study, free+sulfated genistein concentrations were 40 nM (32), and total serum genistein concentrations were approximately 200 nM (unpublished data).

The increased body weight in SBE-treated animals in our study has also been seen in women given SBE supplementation (Dr. G. Burke, personal communication). The significance of this finding is uncertain at this point; however, body weight in the

postmenopause affects the incidence of several chronic diseases, and therefore should be considered in experimental and clinical trials.

In conclusion, our data in a well-characterized, surgically postmenopausal cynomolgus macaque model indicate that addition of SBE to estrogen replacement therapy may protect breast and endometrial tissues from the tumor-promoting effects of estrogen-induced cell proliferation. The implication of this finding for postmenopausal women is that soy or soy isoflavone intake may be beneficial, because SBE may have antagonistic effects on endometrial and mammary proliferation when given with exogenous estrogen.

## References

1. Ravnkar VA. Compliance with hormone replacement therapy's: are women receiving the full impact of hormone replacement therapy preventive health benefits?. *Women's Health Issues* 1992;2:75-80.
2. Mahoney CJ. A study of the menstrual cycle in *Macaca irus* with special reference to the detection of ovulation. *J Reprod Fertil* 1970;21:153-63.
3. Kaiserman-Abramof IR, Padykula HA. Ultrastructural epithelial zonation of the primate endometrium (rhesus monkey). *Am J Anat* 1989;184:13-30.
4. Martel C, Melner MH, Gagne D, Simard J, Labrie F. Widespread tissue distribution of steroid sulfatase, 3 beta-hydroxysteroid dehydrogenase/delta 5-delta 4 isomerase (3 beta-HSD), 17 beta-HSD 5 alpha-reductase and aromatase activities in the rhesus monkey. *Mol Cell Endocrinol* 1994;104:103-11.
5. Tsubura A, Hatano T, Hayama S, Morii S. Immunophenotypic difference of keratin expression in normal mammary glandular cells from five different species. *Acta Anat* 1991;140:287-93.
6. Benirschke K, Garner FM, Jones TC, eds. *Pathology of laboratory animals*. New York:Springer-Verlag, 1978:1204-1206.
7. Adams MR, Williams JK, Clarkson TB, Jayo MJ. Effects of oestrogens and progestogens on coronary atherosclerosis and osteoporosis of monkeys. *Baillière's Clin Obstet Gynaecol* 1991;5:915-34.
8. Clarkson TB, Adams MR, Kaplan JR, Shively CA, Koritnik DR. From menarche to menopause: Coronary artery atherosclerosis and protection in cynomolgus monkeys. *Am J Obstet Gynecol* 1989;160:1280-5.
9. Cline JM, Soderqvist G, von Schoultz E, Skoog L, von Schoultz B. Effects of hormone replacement therapy on the mammary gland of surgically postmenopausal macaques. *Am J Obstet Gynecol* 1996;174:93-100.
10. Colditz GA, Hankinson SE, Hunter DJ, et al. The use of estrogens and progestins and the risk of breast cancer in postmenopausal women. *N Engl J Med* 1995;332:1589-93.

11. Lindholm J, van Diest PJ, Haffner D, Mikuz G, Wegner AR. A morphometric filter improves the diagnostic value of morphometric analyses of frozen histopathologic sections from mammary tumors. *Anal Cell Pathol* 1992;4:443-9.
12. Mäkelä S, Poutanen M, Lehtimäki J, Kostian ML, Santti R, Vihko R. Estrogen-specific 17 $\beta$ -hydroxysteroid oxidoreductase type 1 (E.C. 1.1.1.62) as a possible target for the action of phytoestrogens. *Proc Soc Exp Biol Med* 1995;208:51-9.
13. Barnes S. Effect of genistein on in vitro and in vivo models of cancer. *J Nutr* 1995;125(3 Suppl):777S-783S.
14. Lamartiniere CA, Moore JB, Brown NM, Thompson R, Hardin MJ, Barnes S. Genistein suppresses mammary cancer in rats. *Carcinogenesis* 1995;16:2833-40.
15. Yu H, Harris RE, Gao Y, Gao R, Wynder EL. Comparative epidemiology of cancers of the colon, rectum, prostate and breast in Shanghai, China versus the United States. *Int J Epidemiol* 1991;20:76-81.
16. Wynder EL, Fujita Y, Harris RE, Hirayama T, Hiyama T. Comparative epidemiology of cancer between the United States and Japan: A second look. *Cancer* 1991;67:746-63.
17. Parkin DM, Muir CS, Whelan SL, Gao YT, Ferlay J, Powell J, eds. 1992. *Cancer incidence in five continents, vol. VI*. Geneva: World Health Organization.
18. Ziegler RG, Hoover RN, Pike MC, et al. Migration patterns and breast cancer risk in Asian-American women. *J Natl Cancer Inst* 1993;85:1819-27.
19. Kato I, Tominaga S, Kuroishi T. Relationship between westernization of dietary habits and mortality from breast and ovarian cancers in Japan. *Jpn J Cancer Res* 1987;78:349-57.
20. Adlercreutz H, Hockerstedt K, Bannwart C, et al. Effect of dietary components, including lignans and phytoestrogens, on enterohepatic circulation and liver metabolism of estrogens and on sex hormone binding globulin (SHBG). *J Steroid Biochem* 1987;27:1135-44.
21. Adlercreutz H, Mousavi Y, Höckerstedt K. Diet and breast cancer. *Acta Oncol* 1992;31:175-81.
22. Adlercreutz H, Bannwart C, Wähälä K, et al. 1993. Inhibition of human aromatase by mammalian lignans and isoflavonoid phytoestrogens. *J Steroid Biochem Mol Biol* 44:147-153.
23. Miksicek RJ. Interaction of naturally occurring nonsteroidal estrogens with expressed recombinant human estrogen receptor. *J Steroid Biochem Mol Biol* 1994;49:153-60.
24. Messina MJ, Persky V, Setchell KDR, Barnes S. Soy intake and cancer risk: a review of the in vitro and in vivo data. *Nutr Cancer* 1994;21:113-31.
25. Folman Y, Pope GS. The interaction in the immature mouse of potent oestrogens with coumestrol, genistein and other utero-vaginitrophic compounds of low potency. *J Endocrinol* 1966; 34:215-25.

26. Martin PM, Horwitz KB, Ryan DS, McGuire WL. 1978. Phytoestrogen interaction with estrogen receptors in human breast cancer cells. *Endocrinology* 103:1860-1867.
27. Peterson TG, Barnes S. 1991. Genistein inhibition of the growth of human breast cancer cells: independence from estrogen receptors and the multi-drug resistance gene. *Biochem Biophys Res Commun* 179:661-667.
28. Akiyama T, Ishida J, Nakagawa S, et al. 1987. Genistein, a specific inhibitor of tyrosine-specific protein kinases. *J Biol Chem* 262:5592-5595.
29. Okura A, Arakawa H, Oka H, Yoshimari T, Monden Y. Effect of genistein on topoisomerase activity and on the growth of Ha-ras-transformed NIH 3T3 cells. *Biochem Biophys Res Commun* 1988;157:183-9.
30. Wei H, Bowen R, Cai Q, Barnes S, Wang Y. Antioxidant and antipromotional effects of the soybean isoflavone genistein. *Proc Soc Exp Biol Med* 1995;208:124-30.
31. Kiguchi K, Glesne D, Chubb CH, Fujiki H, Huberman E. Differential induction of apoptosis in human breast tumor cells by okadaic acid and related inhibitors of protein phosphatases 1 and 2A. *Cell Growth Differ* 1994;5:995-1004.
32. Honoré EK, Williams JK, Anthony MS, Clarkson TB. Soy isoflavones enhance coronary vascular reactivity in atherosclerotic female macaques. *Fertil Steril* 1996, in press.

**Figure Legends**

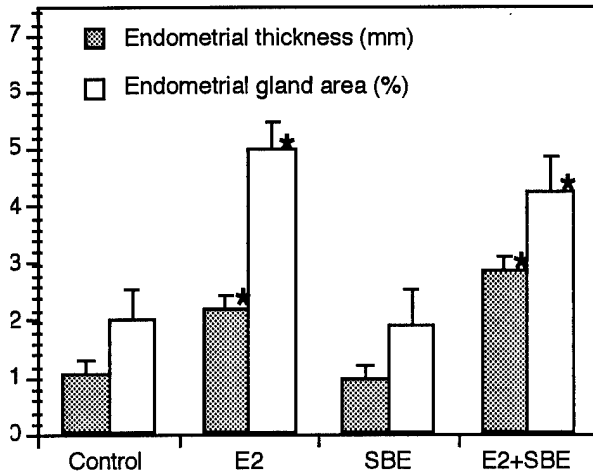


Figure 1: Endometrial measurements of surgically postmenopausal cynomolgus monkeys given no treatment (control) or treated with estradiol (E2), soybean phytoestrogens (SBE), or E2+SBE. \* =  $p < 0.05$  compared with untreated control monkeys.

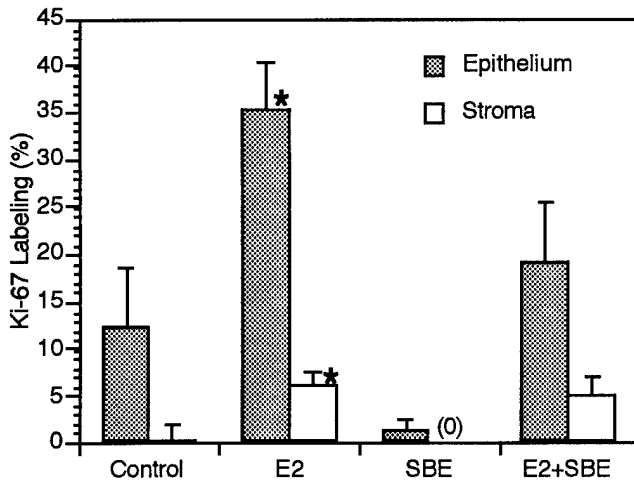


Figure 2: Cell proliferation (as % of cells stained with the marker Ki-67) in endometrial tissues of surgically postmenopausal cynomolgus monkeys given no treatment (control) or treated with estradiol (E2), soybean phytoestrogens (SBE), or E2+SBE. \* =  $p < 0.05$  compared with untreated control monkeys.

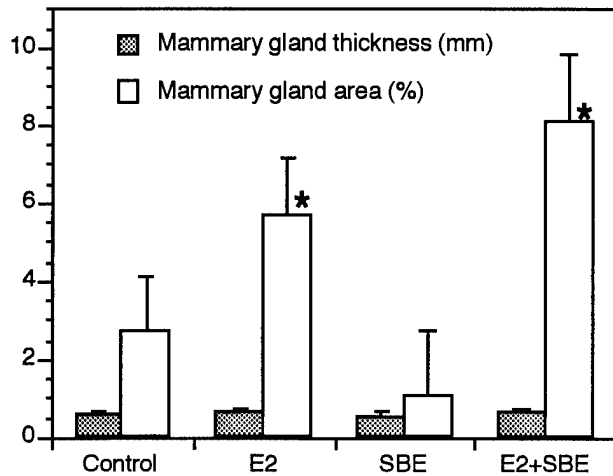


Figure 3: Mammary gland measurements of surgically postmenopausal cynomolgus monkeys given no treatment (control) or treated with estradiol (E2), soybean phytoestrogens (SBE), or E2+SBE. \* = p<0.05 compared with untreated control monkeys.

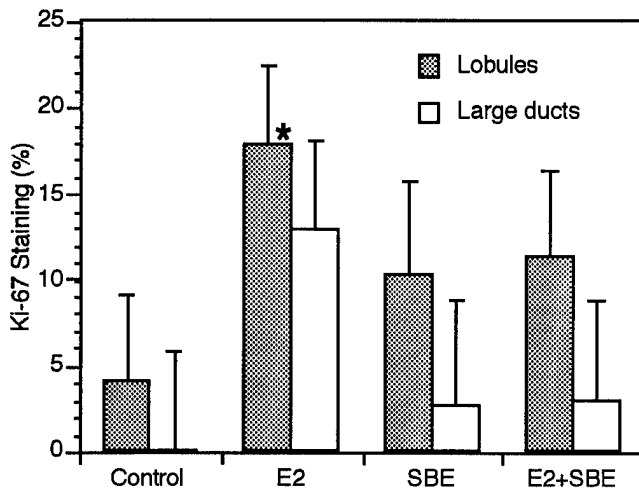


Figure 4: Cell proliferation (as % of cells stained with the marker Ki-67) in mammary gland tissues of surgically postmenopausal cynomolgus monkeys given no treatment (control) or treated with estradiol (E2), soybean phytoestrogens (SBE), or E2+SBE. \* = p<0.05 compared with untreated control monkeys.

**Tables**

Table 1. Histopathologic findings in the uteri and mammary glands of cynomolgus monkeys given E2 with or without SBE

Uterine Histologic Appearance	Control	Estradiol	Soy	Soy + Estradiol
Atrophic	11	0	9	0
Simple Glandular Hyperplasia	3	8	3	7
Cystic Glandular Hyperplasia	0	3	0	1
Irregular Glandular Hyperplasia	0	2	0	1

**Uterine Epithelial  
Hyperplasia Grade**

0 (none)	11	0	9	0
1 (mild)	2	2	2	4
2 (moderate)	1	10	1	4
3 (marked)	0	1	0	1
Number of uteri examined	14	13	12	9

**Mammary Epithelial  
Hyperplasia Grade**

0 (none)	4	1	4	1
1 (mild)	7	2	8	2
2 (moderate)	3	1	1	2
3 (marked)	0	9	0	4
Number of mammary glands examined	14	13	13	9