

AD _____

CONTRACT NUMBER DAMD17-96-C-6126

TITLE: Signal Enhancement Ratios (SERs) in Breast Carcinomas
Measured by 3D Contrast-MRI and Verified by Histopathology

PRINCIPAL INVESTIGATOR: Nola Hylton, Ph.D.

CONTRACTING ORGANIZATION: University of California
San Francisco, California 94143-0962

REPORT DATE: October 1997

TYPE OF REPORT: Annual

PREPARED FOR: Commander
U.S. Army Medical Research and Materiel Command
Fort Detrick, Frederick, Maryland 21702-5012

DISTRIBUTION STATEMENT: Approved for public release;
distribution unlimited

The views, opinions and/or findings contained in this report are those of the author(s) and should not be construed as an official Department of the Army position, policy or decision unless so designated by other documentation.

QUALITY INSPECTED &

19980310 058

REPORT DOCUMENTATION PAGE

Form Approved
OMB No. 0704-0188

Public reporting burden for this collection of information is estimated to average 1 hour per response, including the time for reviewing instructions, searching existing data sources, gathering and maintaining the data needed, and completing and reviewing the collection of information. Send comments regarding this burden estimate or any other aspect of this collection of information, including suggestions for reducing this burden, to Washington Headquarters Services, Directorate for Information Operations and Reports, 1215 Jefferson Davis Highway, Suite 1204, Arlington, VA 22202-4302, and to the Office of Management and Budget, Paperwork Reduction Project (0704-0188), Washington, DC 20503.

1. AGENCY USE ONLY (Leave blank)	2. REPORT DATE October 1997	3. REPORT TYPE AND DATES COVERED Annual (27 Sep 96 - 26 Sep 97)	
4. TITLE AND SUBTITLE Signal Enhancement Ratios (SERs) in Breast Carcinomas Measured by 3D Contrast-MRI and Verified by Histopathology		5. FUNDING NUMBERS DAMD17-96-C-6126	
6. AUTHOR(S) Nola Hynton, Ph.D.			
7. PERFORMING ORGANIZATION NAME(S) AND ADDRESS(ES) University of California San Francisco, California 94143-0962		8. PERFORMING ORGANIZATION REPORT NUMBER	
9. SPONSORING/MONITORING AGENCY NAME(S) AND ADDRESS(ES) Commander U.S. Army Medical Research and Materiel Command Fort Detrick, Frederick, Maryland 21702-5012		10. SPONSORING/MONITORING AGENCY REPORT NUMBER	
11. SUPPLEMENTARY NOTES			
12a. DISTRIBUTION / AVAILABILITY STATEMENT Approved for public release; distribution unlimited		12b. DISTRIBUTION CODE	
13. ABSTRACT (Maximum 200) Our work in breast MRI has focused on an imaging technique and analysis method, directed toward defining the extent of malignant lesions in patients with confirmed breast carcinoma. We developed a 3-point contrast-MRI method to maximize anatomic (sensitivity) and biologic (specificity) information in a single exam. One data set is acquired at baseline (pre-contrast), S_0 ; one early post-contrast, S_1 ; and one late post-contrast, S_2 . The SER index, defined as $(S_1 - S_0) / (S_2 - S_0)$, compares early to late enhancement. Preliminary studies suggested a relationship between SER value and tumor grade for invasive carcinomas. The focus of this work is to verify these findings in a larger population and investigate the potential of SER as a non-invasive prognostic marker. In a subsequent study of 57 patients, carcinoma was correctly identified by MRI in 98% of cases, versus 84% for mammography. True anatomic extent was correctly identified much more often with MRI than with mammography (96% vs. 44%), with the greatest value in cases of multi-focal disease, ductal carcinoma in situ (DCIS), or invasive carcinoma with an extensive intraductal component (EIC). In a subset of 28 patients, SER correlation with microvessel density counts (by CD 34 staining) was highly significant: $r = 0.62$ ($p < 0.002$). The correlation between SER and grade (by SBR number) was $r = 0.59$ ($p < 0.004$).			
14. SUBJECT TERMS Breast Cancer magnetic resonance imaging (MRI), high resolution, contrast dynamics histopathology, local staging, angiogenesis		15. NUMBER OF PAGES 12	16. PRICE CODE
17. SECURITY CLASSIFICATION OF REPORT Unclassified	18. SECURITY CLASSIFICATION OF THIS PAGE Unclassified	19. SECURITY CLASSIFICATION OF ABSTRACT Unclassified	20. LIMITATION OF ABSTRACT Unlimited

FOREWORD

Opinions, interpretations, conclusions and recommendations are those of the author and are not necessarily endorsed by the U.S. Army.

____ Where copyrighted material is quoted, permission has been obtained to use such material.

____ Where material from documents designated for limited distribution is quoted, permission has been obtained to use the material.

____ Citations of commercial organizations and trade names in this report do not constitute an official Department of Army endorsement or approval of the products or services of these organizations.

____ In conducting research using animals, the investigator(s) adhered to the "Guide for the Care and Use of Laboratory Animals," prepared by the Committee on Care and Use of Laboratory Animals of the Institute of Laboratory Resources, National Research Council (NIH Publication No. 86-23, Revised 1985).

MA For the protection of human subjects, the investigator(s) adhered to policies of applicable Federal Law 45 CFR 46.

____ In conducting research utilizing recombinant DNA technology, the investigator(s) adhered to current guidelines promulgated by the National Institutes of Health.

____ In the conduct of research utilizing recombinant DNA, the investigator(s) adhered to the NIH Guidelines for Research Involving Recombinant DNA Molecules.

____ In the conduct of research involving hazardous organisms, the investigator(s) adhered to the CDC-NIH Guide for Biosafety in Microbiological and Biomedical Laboratories.

Nola M. Hylt
PI - Signature

11.21.97
Date

TABLE OF CONTENTS

Cover	Page 1
Form SF 298	Page 2
Foreword	Page 3
Table of Contents	Page 4
Introduction	Page 5
Body	Page 5
Conclusions	Page 7
References	Page 8
Appendices	Page 10

ANNUAL REPORT FOR CONTRACT NUMBER DAMD17-96-C-6126

Principal Investigator: Nola Hylton, Ph.D., University of California, San Francisco
Grant Title: Signal Enhancement Ratios (SERs) in Breast Carcinomas Measured by 3D Contrast-MRI and Verified by Histopathology

INTRODUCTION

Our work in breast MRI has focused on an imaging technique, the triple acquisition rapid gradient echo technique (TARGET), and signal enhancement (SER) analysis method, directed toward defining the extent of malignant lesions in patients with confirmed breast carcinoma. We developed a 3-point contrast-MRI method to maximize anatomic (sensitivity) and biologic (specificity) information in a single exam. Previously reported methods have relied on separate imaging strategies for maximizing sensitivity and specificity¹⁻¹². TARGET acquires one data set at baseline (pre-contrast), S_0 ; one early post-contrast, S_1 ; and one late post-contrast, S_2 . The SER index, defined as $(S_1 - S_0) / (S_2 - S_0)$, compares early to late enhancement: SER values less than one indicate breast tissue that enhances gradually; SER values equal to one indicate breast tissue enhancement that is stable between the early and late post-contrast time points; SER values greater than one indicate breast tissue demonstrating uptake with contrast washout by the late time point¹³⁻¹⁵. In our preliminary data, we presented results in a group of 25 patients with pathology confirmation. MRI correctly identified carcinoma in 21/25 cases using a two-point comparison only: percent enhancement (PE) = $(S_1 - S_0) / S_0 > 80\%$. The one false positive was resolved when $SER > 1.2$ was used as an additional criteria for malignancy. Of particular interest, these preliminary studies also suggested a relationship between SER value and tumor grade in the group of 18 invasive carcinomas.

The focus of this grant is to verify these findings in a larger population of patients with confirmed breast carcinoma, and investigate the potential of SER as a non-invasive prognostic marker.

BODY

Experimental Methods, Assumptions and Procedures: 50 women subjects per year are enrolled in this research protocol and receive one breast MRI exam prior to undergoing surgery. Study eligibility include women with a confirmed breast carcinoma on the basis of fine needle aspiration (FNA), core biopsy, excisional biopsy, or lumpectomy with positive margins. The MRI procedure is performed on a General Electric 1.5 Tesla SIGNA scanner using a bilateral phased-array breast radiofrequency coil. The imaging exam consists of a bilateral, axial T1-weighted, spin echo localization scan, a sagittal, fat-suppressed T2-weighted fast spin echo scan of the symptomatic breast only, and a contrast-enhanced TARGET series of the symptomatic breast only, using a 3D fat-suppressed, fast gradient echo technique: TR = 11 ms, TE = 4.2 ms, 20 degree flip angle, 256 x 192 imaging matrix, 16-18 cm field of view, 60 sections, 2 NEX and no phase wrap option. The scan time for each data acquisition is 5.4 minutes, resulting in a three-point temporal sampling of 0, 2.7 and 8.1 minutes. Gadolinium-DTPA is administered intravenously through an indwelling catheter at a dose of 0.1 mmol/kg body weight, following the first scan of the TARGET series.

Following each patient exam, MRI image data are transferred off-line to a UNIX workstation for processing and analysis. Maximum intensity projections and region-of-interest calculations are performed to measure peak PE and SER values in the area of suspicion based upon the patient's reason for referral. Additional areas of suspicion and incidental MRI findings are also characterized.

Results and Discussion: During Year 1, we refined our patient recruitment and enrollment procedures, hired and trained a study coordinator, developed a more comprehensive patient questionnaire, created a database to track clinical, MRI, mammography and pathology data for all patients in the study, created an image display and analysis program for breast MRI and established tissue tracking and histopathology

procedures for improved correlation accuracy. We enrolled approximately 1-2 patients per week, for a total accrual in Year 1 of 55 patients, which exceeds the target accrual rate for this study.

In a recent report, we presented results in a group of 57 patients with confirmed carcinoma and subsequent surgical pathology confirmation¹⁶. Carcinoma was correctly identified by MRI in 98% of cases, versus 84% for mammography. True anatomic extent was correctly identified much more often with MRI than with mammography (96% vs. 44%), with the greatest value in cases of multi-focal disease, ductal carcinoma in situ (DCIS), or invasive carcinoma with an extensive intraductal component (EIC). In a subset of 28 patients, SER correlation with microvessel density counts (by CD 34 staining) was highly significant, $r = 0.62$ ($p < 0.002$). The correlation between SER and grade (by SBR number) was $r = 0.59$ ($p < 0.004$). SER increased with the grade of tumor, showing greatest separation between tumors of grade 2 and 3. Average SER values were 1.1, 1.25 and 1.56 for tumors of grades 1, 2 and 3 respectively.

For the purposes of analysis, patients from this study were added to the group of patients from studies to look at differences in specificity between a two-time point (standard) and three-time point (SER) method of diagnosis. In an abstract submitted this month to the International Society of Magnetic Resonance in Medicine (ISMRM) entitled "Clinical Evaluation of a Three-Time Point Breast MRI Method", we reported a 33% improvement in specificity using the 3-point method of data acquisition and analysis. If accepted, this paper will be presented at the Sixth Scientific Meeting of the ISMRM to be held in Sidney, Australia in April 1998.

In our Statement of Work, we estimated that Tasks 1-3 under Specific Aim 1, and Task 1 under Specific Aim 2, would be completed in Year 1. These tasks were as follows:

SPECIFIC AIM 1 (Determine the histologic basis for interpreting SER patterns)

Task 1: Develop software to facilitate SER analysis and generation of illustrations and reports for pre-surgical review.

Task 2: Implement and refine procedures for guiding pathology sectioning

Task 3: Develop software procedures for rapid spatial realignment of MRI data.

SPECIFIC AIM 2 (Investigate the possible prognostic value of SER characteristics)

Task 1: Develop software to facilitate SER analysis and generation of illustrations and reports for pre-surgical review.

We had made substantial progress in each of these areas. **Specific accomplishments** during the first year have been:

- A study coordinator was hired in April 1997 to coordinate patient studies, create and implement the database for study tracking and analysis.
- A Patient Study Database was designed and created by the study coordinator over a six month period using FileMaker Pro 3.0 software. Currently over 600 fields are included in ten data entry forms. The Tracking Form contains all information relevant to patient tracking and synopsis, including exam information and demographics; clinical history; results of recent diagnostic procedures performed prior to MRI; results of post-MRI surgery and pathology. The Patient Questionnaire form contains information given to us directly by the patient, including family history of breast cancer and medications taken. Four MRI Report Forms are designed to allow direct entry by multiple radiologists at remote sites. Each reader is self-identified as blinded or unblinded to patient outcome. MRI reports include lesion characteristics such as sizes, extent, location, margins, interior, as well as general findings, such as enhancement patterns, fibroglandular tissue density, cysts, lymph nodes, and likelihood of malignancy. Three Mammogram Report forms (to

allow multiple readers) and one Pathology Report Form are also included. The study coordinator performs all data entry, except for direct entry of MRI report form.

- An Image Analysis software program was designed and built to allow data to be analyzed and reports generated in a timely manner following each patient exam. Immediately following each patient exam, data are transferred off-line to a UNIX workstation. The analysis program is built in the Interactive Display Language (IDL) programming environment. Functionality includes: maximum intensity projection views, quick review and paging of volume data (180 images: 60-section volumes, 3 time points), transfer between spatial and temporal modes for analysis of anatomic and kinetic features, tumor size and volume, PE and SER region-of-interest analysis, pathology comparisons and generation of hardcopy records. Examples are included in the Appendix.
- Tissue Tracking and Histopathology Correlation Procedures were developed to increase the accuracy of MRI/pathology correlation. Specifically, a surgical fellow reviews the results of each MRI study with an MRI researcher prior to the patient's surgery date. The surgical fellow attends surgery and assists in specimen labeling, transports the specimen to pathology, assists the pathologist with orienting, sectioning and labeling the specimen. Pertinent information and illustrative diagrams are included on a tissue tracking form (example in the Appendix) which is generated at the time of patient enrollment and accompanies the patient to surgery, and the specimen to pathology. Placement of the surgical incision and size and location of the removed specimen are recorded on the tissue tracking form. Finally, correlating MRI and pathology sections are agreed upon by the surgical fellow and MRI researcher corresponding to the central sagittal cut of the specimen, sections corresponding to the major pathologic diagnoses and sections corresponding to the most significant MRI findings. H&E and CD34 microvessel staining are performed for all selected pathology sections.

CONCLUSIONS

Our results to-date indicate that MRI is superior to mammography in defining the extent of malignant lesions and may provide very valuable information for pre-operative planning and single stage resection in breast cancer. Our initial findings correlating SER to tumor grade and microvessel density, both markers for patient prognosis, suggest that MRI can provide a non-invasive assessment that may help stratify patients pre-operatively and decide the most appropriate treatment options. As this study continues, we expect to see greater accuracy as a result of improved procedures for MRI/histopathology correlation.

REFERENCES

1. Heywang SH, Wolf A, Pruss E, et al. *MR Imaging of the Breast with Gd-DTPA: Use and Limitations*. Radiology 1989; 171:95-103.
2. Kaiser WA, Zeitler E. *MR Imaging of the Breast: Fast Imaging Sequences with and without Gd-DTPA Preliminary Observations*. Radiology 1989;170:681-686.
3. Flickinger FW, Allison JD, Sherry RM, Wright JC. *Differentiation of Benign From Malignant Breast Masses By Time-Intensity Evaluation of Contrast-Enhanced MRI*. Magn Reson Imag. 11:617-620, 1993.
4. Heywang SH, Hilbertz T, Pruss E, et al. *Dynamische Kontrastmitteluntersuchungen mit FLASH bei Kernspintomographie der Mamma*. Digitale Bilddiag. 1988; 8:7-13.
5. Gilles R, Guinebretiere JM, Lucidarme O, Cluzel P, Janaud G, Finet JF, Tardivon A, Masselot J, Vanel D. *Non-palpable Breast Tumors: Diagnosis with Contrast-enhanced Subtraction Dynamic MR Imaging*. Radiology 1994; 191:625-631.
6. Turkat TJ, Klein BD, Polan RL, Richman RH. *Dynamic MR Mammography: A Technique for Potentially Reducing the Biopsy Rate for Benign Breast Disease*. J Magn Res Img 1994; 4:563-568.
7. Gilles R, Meunier M, Lucidarme O, Zafrani B, Guinebretiere JM, Tardivon AA, Le Gal M, Vanel D, Neuenschwander S, Arriagada R. *Clustered Breast Microcalcifications: Evaluation by Dynamic Contrast-Enhanced Subtraction MRI*. J Comp Assis Tomog. 1996; 20(1):9-14.
8. Boetes C, Barentsz JO, Mus RD, van der Sluis RF, van Erning LJTO, Hendriks JHCL, Holland R, Ruys SHJ. *MR Characterization of Suspicious Breast Lesions with a Gadolinium-Enhanced TurboFLASH Subtraction Technique*. Radiology 1994; 193:777-781.
9. Pierce WB, Harms SE, Flamig DP, Griffey RH, Evans WP, Hagans JE. *Three-dimensional Gadolinium-enhanced MR Imaging of the Breast: Pulse Sequence with Fat Suppression and Magnetization Transfer Contrast. Work-in-Progress*. Radiology 1991; 181:757-763.
10. Harms SE, Flamig DP, Hesley KL, et al. *MR Imaging of the Breast with Rotating Delivery of Excitation Off Resonance: Clinical Experience with Pathologic Correlation*. Radiology 1993; 187:493-501.
11. Oellinger H, Heins S, Sander B, et al. *Gd-DTPA Enhanced MR Breast Imaging: The Most Sensitive Method for Multicentric Carcinomas of the Female Breast*. Euro Rad, 1993.
12. Cross MJ, Harms SE, Cheek JH, Peters GN, Jones RC. *New Horizons in the Diagnosis and Treatment of Breast Cancer Using Magnetic Resonance Imaging*. Am J. of Surg. 1993; 166:749-755.
13. Hylton NM, Foo TKJ, Frankel SD, Esserman LJ, Shimakawa A, Proctor E, Bruce N, Sickles E. *Optimization of a Magnetization-Prepared 3D Fast Gradient Echo Technique for Local Staging of Breast Cancer*. Proceedings of the Third Scientific Meeting of the Society of Magnetic Resonance. 1995; 3:1595.
14. Hylton NM, Frankel SD, Esserman LJ, Moore K, Sickles E. *High Resolution 3D Maps of Contrast Enhancement Patterns in Breast Tumors*. Proceedings of the Third Scientific Meeting of the Society of Magnetic Resonance. 1995; 1:439.

15. Hylton NM, Frankel SD, Esserman LJ, Sickles EA. High Spatial Resolution MR Imaging Enhancement Patterns in Breast Malignancies: Usefulness in Distinguishing Invasive from Non-Invasive Carcinoma. *Radiology* 1995; 197(P):371.

16. Esserman LJ, Weidner N, Yassa L, George T, Frankel SD, Hylton NM. *MRI: A Window to Visualize Anatomic Extent and Angiogenesis in Breast Cancer*. (Abstract), Proceedings of the 19th Annual San Antonio Breast Cancer Symposium, 1996

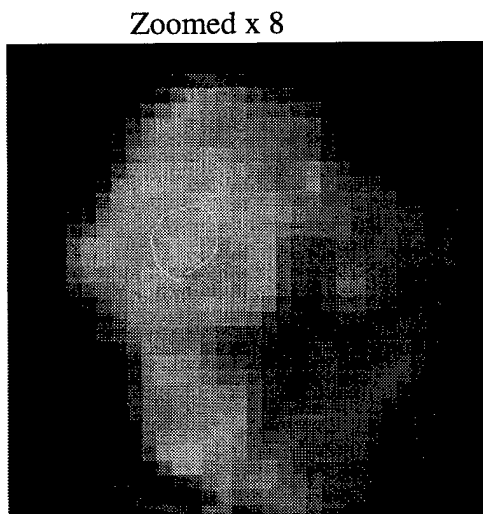
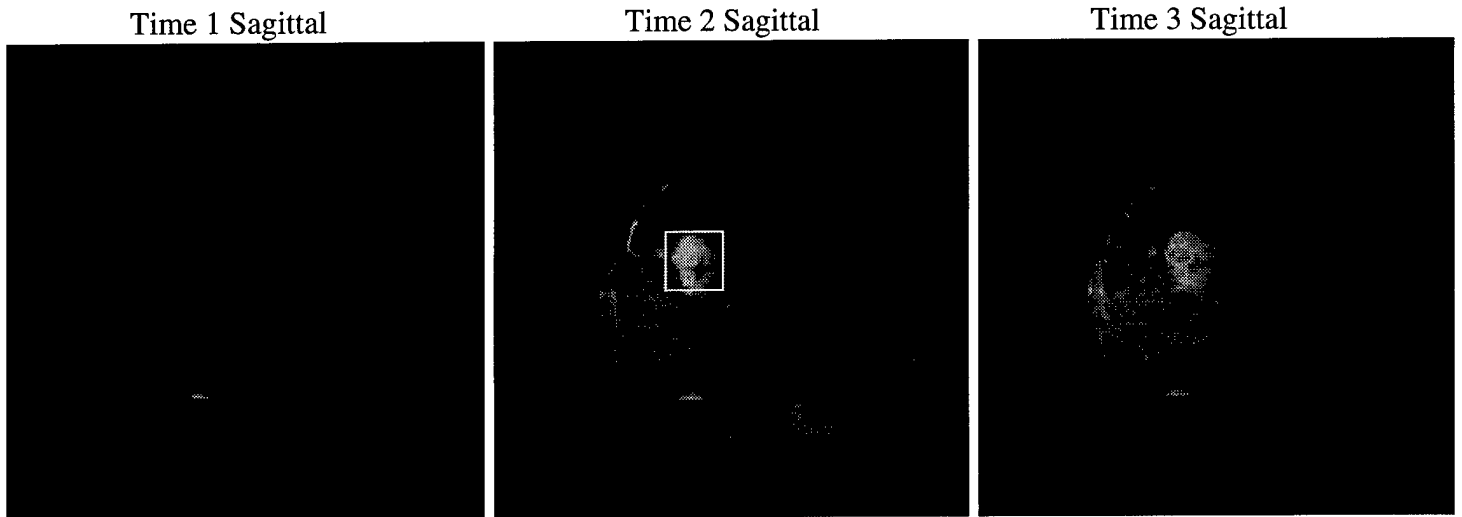
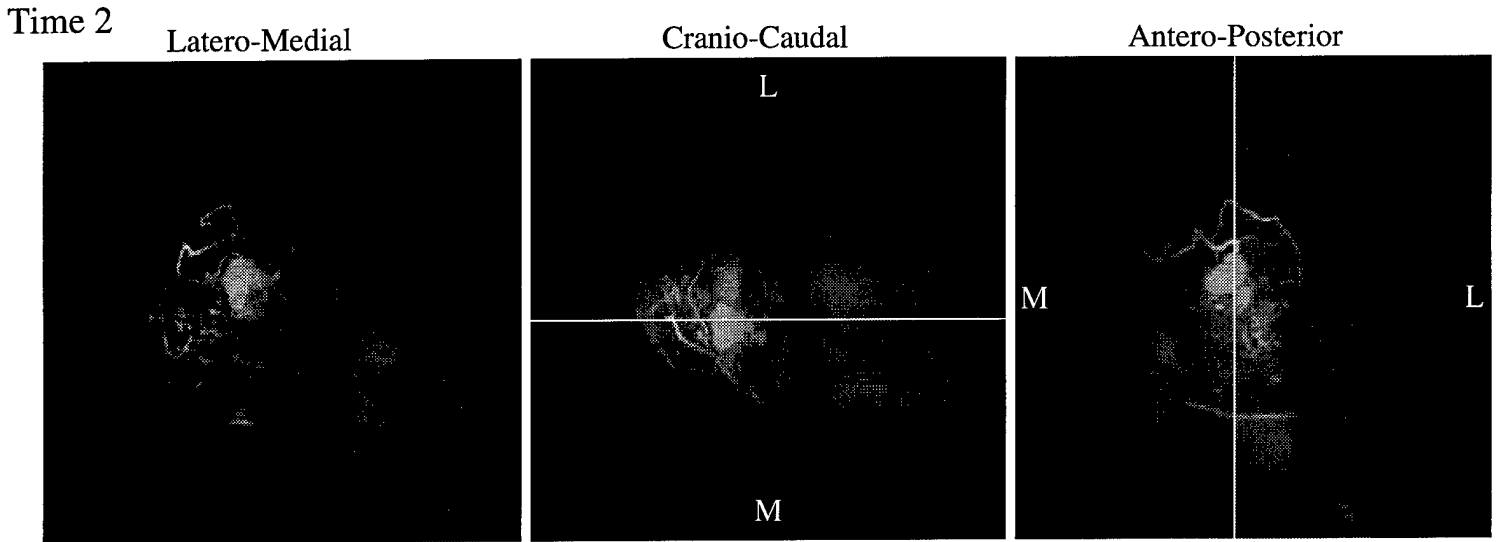
APPENDICES:

- A) Example: MRI/Pathology Comparison Record
- B) Example: Breast Tissue Tracking Form

Pathology Comparison

Patient: _5154 Left Breast

MRI Date: 03-20-1997



SER: 1.46
PE: 121
Count 1,2,3: 16, 16, 19

Sagittals
slice #s: 34, 35, 37 ;(135, 138, 142)
Resolution (mm): 0.703125
ROI Mean, Sdev, Max:
ROI1: 78.7500, 6.01664, 87
ROI2: 174.062, 5.01290, 181
ROI3: 143.842, 4.28516, 151

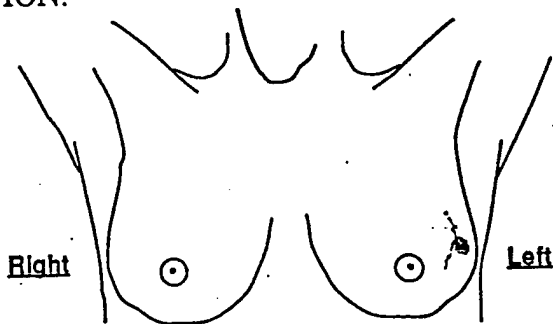
Comments:

BREAST TISSUE TRACKING FORM

NAME: _____
 DATE: 9/4/97
 MED #: _____

Tissue Banking:
 MRI Case:

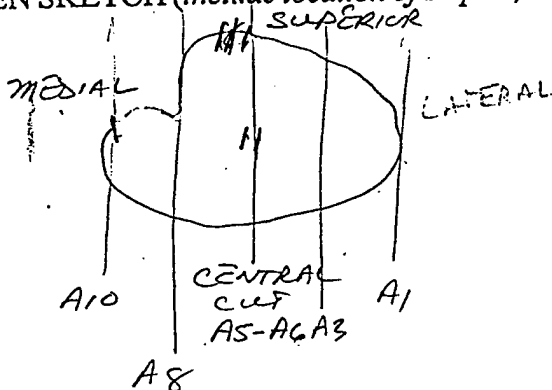
MARK EXCISION LOCATION:



*Between 2-3 @ 1 o'clock
 3cm x 3cm
 Palpable lesion
 3x3cm*

GROSS SPECIMEN SKETCH (include location of staples, central cut):

S 3
 A 2
 M 1



CORRESPONDING CASSETTES (Mark on above sketch):

SIZE: Tumor: 3cm x 3cm
 Specimen: 3.5 x 3.0 x 1.7 cm
 Skin: No Excision

SPECIMEN RADIOGRAPH PERFORMED: Yes No

COMMENTS: