


2712



34

JPRS: 2712

25 May 1960

ALTERATION OF THE PERIPHERAL SECTION OF THE SKIN
ANALYZER IN ACUTE RADIATION SICKNESS

- USSR -

by N. N. Garvey

19981203 102

DISTRIBUTION STATEMENT A

Approved for public release;
Distribution Unlimited

Distributed by:

OFFICE OF TECHNICAL SERVICES
U. S. DEPARTMENT OF COMMERCE
WASHINGTON 25, D. C.

~~Price \$0.50~~

U. S. JOINT PUBLICATIONS RESEARCH SERVICE
205 EAST 42nd STREET, SUITE 300
NEW YORK 17, N. Y.

DTIC QUALITY REQUESTED

JPRS: 2712

CSO: 3891-N

ALTERATION OF THE PERIPHERAL SECTION OF THE SKIN
ANALYZER IN ACUTE RADIATION SICKNESS

[This is a translation of an article written by N. N. Garvey in Zhur. Nevropatologii i Psikhatrii (Journal of Neuropathology and Psychiatry), Vol. 60, No. 2, Moscow, 1960, pages 135-139.]

We conducted experiments of fifty (50) albino rats of the same sex, weight, and age, in whom acute radiation sickness was produced by total body irradiation with a dose of 700 r. The irradiation was achieved with an RUM-3 apparatus and electrical current of 180 kilovolts, 10 milliamperes, a filter 0.5 millimeter of copper and one millimeter of aluminum, the focal distance to the skin was 40 centimeters, the intensity of the dose 38 r /minute.

Examinations of the skin taken from various areas of the body showed changes of the nervous elements even in the early period of acute radiation sickness (30 minutes - 3 days), these changes being pronounced mainly in the nervous endings in the epidermis and the hair follicles. While under normal circumstances silver impregnation of the skin nerves produces an even brownish color, 30-60 minutes after irradiation the impregnation becomes much weaker; in 24 hours the reverse can be observed; the nervous fibers and endings acquire a darker shade approaching black and become more distinct among the surrounding tissues.

Besides the above-mentioned change, the morphological shifts in the nerves of the superficial plexus are characterized by loss of the fibrillary structure of their endings and in deformation (the absence of their characteristic, button-like endings) the thin fibers penetrating into the thickness of the epidermis become tortuous, and acquire uneven, thorn-like endings (Fig. 1).

In the later stages of this period (1-3 days) the signs of irritation and dystrophy involve the nerve fibers of the superficial as well as of the deep layers of the derma and subcutaneous tissues (Fig. 2). These consist mainly of a relative increase of the total number of the nervous elements in the epidermis and derma. The subepidermal plexus acquires a more complex structure during this period - its component fibers seem to become longer and curl into spirals.

In the initial period of the skin reaction to irradiation (the first 24-48 hours), staining by the Gros-Bil'shovsky and Kampos method shows an uneven process of reduction of silver together

with an increased tortuosity of the bundles as well as of individual nerve fibers of the superficial plexus. In these cases the axis cylinders have irregular, uneven contours with knobs of neuroplasma in the form of varicose swellings. Bead-like varicosities appear at various distances from one another. In some segments of the nerve fibers the axis cylinder becomes narrow. The narrowing of the axon is particularly frequently noticed in the intervals between the varicose swellings. From time to time the nervous fibers show an increased argyrophily and become transformed into thick, coarse cords with uneven contours. Some axons have thorn-like protrusions.

The terminal nervous apparatus of the hair also undergoes considerable changes: the silver affinity of the circular and palisade fibers of the hair increases, they become tortuous and occasionally thickened. In the majority of cases the terminal fibers are situated disorderly, forming an excessive number of loops and spires. Considerable structural disturbances, consisting in the appearance of thick abnormal fibers without their typical palisade formation, become evident in the nervous apparatus of the down hair.

In the nerve stems leading to the hair, there is a noticeable increase in the number of thick darkish brown fibers and a decrease in the number of strongly impregnated, thin fibers with marked borders. Occasionally yellowish brown, irregularly delineated fibers can be seen, with quite visible varicose bulges of varying size. The changes in the nerve fibers surrounding the sebaceous glands consist in an uneven staining of some segments, formation of spires and tumescences along their course. The nerve fibers closely connected with the blood vessels either loop around the vessel or follow along its wall showing bead-like distentions seen also under normal circumstances; these however are spaced irregularly.

Spielmeyer staining showed that during this period the myelin sheath of the nerve fibers undergoes a series of changes consisting of swelling and uneven staining of various sectors of the myelin covering. The myelin sheath in the pale sectors is of a smaller diameter than in the rest, a fact which can be explained by the softening of the axis cylinders: the Schmidt-Lanterman notches in these cases are widened.

Beginning with the 5th day, the axis cylinders forming the thin, medium and thick nerve stems of the superficial and deep plexus become irregularly impregnated and as a rule show chewed-up contours, occasionally looking like a stem with thorn-like projections. Along the course of the axis cylinders there are noticeable bulb-like swellings of the neuroplasma.

At this time the endings of the free nerve fibers are decreased in number and are as a rule deformed, the fibrillary structure of the terminals cannot be seen. The terminal nervous

apparatus of the sebaceous and hair follicles also undergoes considerable change. The nerve fibers leading to them are thick, argyrophillic, and full of varicosities (Fig. 3). The terminal branchings of the receptors are considerably thickened, and lose the fibrillary structure and orderly distribution; a marked tortuosity of the nervous fibers and irregularity of their contours are frequently seen. These structural changes involve also the nerves of the vessels.

Occasionally the silver becomes reduced along the entire course of the axis cylinder of the neuroreceptor apparatus of the skin, which is expressed in the formation of separate sectors of sectors of varying size having rough and strongly impregnated borders, among which lie light, poorly stained sectors. In several places the nerve fibers acquire the form of a dotted line and consist of some angulated black granules, (Fig. 4).

On the 7th to 9th day there appears a more or less strongly pronounced disintegration of the axis cylinders into separate dark lumps of varying sizes. The degenerative changes involve not only the nerve apparatus of the hair, sebaceous glands and vessels, but also the free nerve endings in the epidermis.

The dystrophic process in the neuroreceptor apparatus of the skin has a very severe course bringing about a granular lumpy disintegration and resulting decrease in the number of detectable nervous elements.

The main changes involve the medullated fibers as well as their sheath and the axis cylinder. Damage can be seen in the epidermis and the derma, however, this is more pronounced in the deep layers of the skin especially in the nerve fibers supplying the vessels (Fig. 5).

Spielmeyer dye brings out irregular staining as well as swelling of the myelin sheath (in the poorly stained places the myelin sheath is of a larger diameter than in the other sector which could be explained with the loosening of the axis cylinders); swelling of the myelin and occasional formation of vacuoles and widening of the Schmidt-Lanterman notches. When Sudan 3 is used a reddish staining appears in the places where the myelin underwent changes.

As the radiation sickness progresses (11th to 23rd day) all the symptoms increase in intensity, becoming most pronounced in the perished animals.

In the recovery period (27th to 60th day) signs of regeneration of the neuroreceptor apparatus of the skin can be noticed; however, these are slightly pronounced and are detected mainly in the thickness of the skin as poorly staining, thin and tortuous lateral branchings of the proximal nerve ends. Most often this is seen around the follicles, the regenerative process being best pronounced where the hair stem was preserved. The thin regenerated fibers are

strongly branched and form thick plexuses surrounding the hair follicles. The circular fibers of the hair proliferate and become unusually twisted, giving off branches of varying sizes that end with marked thickenings. The palisade fibers are also changed; they are branched out, thin fibers occasionally penetrating into the epithelial sheath.

We have not noticed formation of microneuromas, as the branching fibers did not encounter obstacles in the form of growing scar tissue. The young regenerating fibers are weak and often disintegrate.

The dystrophic changes in the surrounding tissues and in the majority of the nerve fibers are still preserved during this period; however, they are less pronounced than at the height of the disease.

In the period of regeneration Spielmeier's stain brings out in some nerves segments of hyper-myelinization together with dystrophic changes. The Schwann elements along the course of these fibers are somewhat hypertrophic as evidenced by the increase of the nucleus and the perinuclear protoplasm.

The young nerve fibers can be distinguished from the old only by their pale staining, small caliber, and irregular diameter. The nerve fibers appear in the form of bifurcation or lateral branches.

During two months we were able to note a complete return of the normal structure of the skin nerves, a fact which coincides with clinical data testifying to the loss of cutaneous sensitivity.

The effect of X-rays upon the nerve fibers can be considered as a direct one, i.e., not dependent upon the changes in the surrounding tissues. That could be judged by the data of microscopic studies of the skin during the first day after irradiation when the routine staining with Hematoxylineosin 24 hours after the irradiation revealed practically no changes in the skin. Silver staining during the same period showed symptoms of irritation of the nerve fibers (uneven staining, tortuosity of the axis cylinder, and thorn-like processes).

In our observations the most pronounced changes in the nervous apparatus of the skin were observed during the period of the development of radiation sickness when the primary changes in the nervous structures are accompanied by secondary damage due to biochemical shifts in the surrounding tissues. All elements of the skin suffer in a greater or lesser fashion under the influence of X-rays, however, concurrently with damaged nervous structures there appear also, intact, nerve fibers and endings, a fact which testifies to the high plasticity of the nervous elements of the higher sectors with regard to a given external stimulus.

Changes in the appearance of the hair coincide in time with the damage to their nervous apparatus, a fact which indicates the

interference with nervous trophism as a result of damage to the nervous elements of the skin.

Poorly pronounced changes of regeneration confirm the general opinion that restorative processes in the organism are halted as a result of decreased reactivity in radiation sickness.





Fig. 1

Skin of thigh of mouse hour after irradiation. Medullated fiber ending in thickness of epidermis (unevenness of contours of axis cylinder with formation of sectors of swellings). Gros-Bil'shovskiy impregnation. Magnification 7 x 40.



Fig 2.

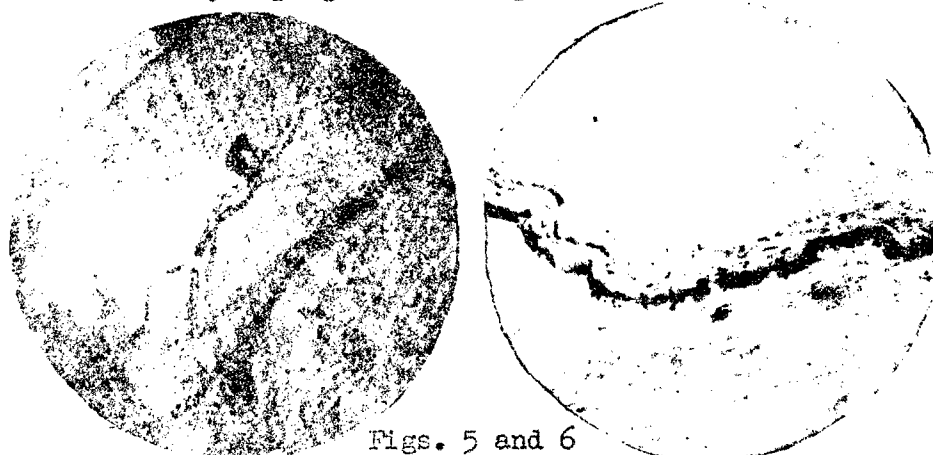
Skin of spine of mouse 24 hours after irradiation. Nerve trunk in deep layers of derma (argirophilly with formation of swellings along the course of the fiber) Kampos impregnation. Magnification 15 x 8



Figs. 3 and 4

Skin of upper lip of mouse. Fifth day of sickness. Sensory apparatus of sinuous hair (sliver-staining, formation of varicose swellings). Gros-Bil'shovskiy impregnation. Magnification 7 x 40

Skin of lower lip of mouse. Ninth day of sickness. Sensory apparatus of sinuous hair (sharp impregnation, with places of disintegration into lumps). Gros-Bil'shovskiy impregnation. Magnification 7 x 40.



Figs. 5 and 6

Skin of spine of mouse. Thirteenth day of sickness. Nerve trunk in deep layers of derma. Swelling of myelin sheath with formation of swellings and appearances of disintegration. Gross-Bil'shovskiy impregnation. Magnification 7 x 40

Skin of lower lip of mouse. Fiftieth day after irradiation. Thin unevenly impregnated lateral leads of nerves lead from the proximal section of the nerve trunk. Kampos impregnation. Magnification 7 x 40

END

FOR REASONS OF SPEED AND ECONOMY
THIS REPORT HAS BEEN REPRODUCED
ELECTRONICALLY DIRECTLY FROM OUR
CONTRACTOR'S TYPESCRIPT

THIS PUBLICATION WAS PREPARED UNDER CONTRACT TO THE
UNITED STATES JOINT PUBLICATIONS RESEARCH SERVICE,
A FEDERAL GOVERNMENT ORGANIZATION ESTABLISHED
TO SERVICE THE TRANSLATION AND RESEARCH NEEDS
OF THE VARIOUS GOVERNMENT DEPARTMENTS