

OTS: 60-41, 177

JPRS: 5316

22 August 1960

ON THE MORPHOLOGICAL CHARACTERISTICS OF THE TAKEABILITY  
OF FREE SKIN TRANSPLANTS IN ACUTE RADIATION SICKNESS

- USSR -

by K. K. Zaytseva

RETURN TO MAIN FILE

**DISTRIBUTION STATEMENT A**  
Approved for Public Release  
Distribution Unlimited

19990723 086

Reproduced From  
Best Available Copy

Distributed by:

OFFICE OF TECHNICAL SERVICES  
U. S. DEPARTMENT OF COMMERCE  
WASHINGTON 25, D. C.

U. S. JOINT PUBLICATIONS RESEARCH SERVICE  
205 EAST 42nd STREET, SUITE 300  
NEW YORK 17, N. Y.

JPRS: 5316

CSO: 4068-N

ON THE MORPHOLOGICAL CHARACTERISTICS OF THE TAKEABILITY  
OF FREE SKIN TRANSPLANTS IN ACUTE RADIATION SICKNESS

Following is a translation of an article by  
K. K. Zaytseva in Vestnik Khirurgii (Herald of  
Surgery)), Vol. LXXXIV, No. 3, pages 97-102.<sup>7</sup>

From the Military Medical Order of  
Lenin Academy imeni S. M. Kirov

The few data available in the literature on the subject of free skin grafts in combined lesions deal primarily with clinical studies in animals (V. M. Burmistrov, K. K. Zaytsev, V. G. Slinko, I. A. Chalisov, 1956; P. I. Burenin, B. L. Razgovorov, A. V. Agishev 1956; V. I. Petrov, 1956; V. M. Burmistrov, V. G. Slinko, 1957, 1958; S. G. Orel, 1957). Only a few studies (H. Gloriex, 1950; L. Dambrin, 1955; J. E. Armstrong, J. K. Schaeffer, C. R. Arter, 1956) are based on observations of victims of the atomic bomb explosions in Hiroshima and Nagasaki.

We were not able to find in the literature any articles dealing with the dynamics of the morphological processes in the take of a free autotransplant of skin during acute radiation sickness. Meanwhile, the knowledge of these dynamics is extremely important for the practical tasks of a surgeon.

The purpose of our investigation was the study of the morphological characteristics of the takeability of free autogenous skin grafts during acute radiation sickness.

The tests were conducted on 28 piglets.<sup>1</sup> The animals were subjected to a single total irradiation with a dose from 250-400 r. The control animals (14) were not irradiated. A third-degree burn on the side of the body was produced in all animals with an open flame 30 minutes after irradiation.

In 14 piglets the burns involved 2.3 -4.8 percent of

1. The tests and the clinical studies on the animals were performed by V. M. Burmistrov, V. G. Slinko and K. I. Shumikhina.

the body surfaces. In 15, 7-14 percent. The burn wounds of the piglets in the second group were additionally infected with suspensions of cultures of staphylococcus aureus and streptococcus. On the fourth day after the combined injury (i.e., in the initial period of the acute radiation sickness) all animals underwent surgical treatment of the burn wounds with dissection of the burned tissues and simultaneous covering of the surfaces of the wound with a perforated skin flap taken from the intact surface of the body. Histological studies showed that the autogenous grafts taken with a dermatome consisted of the epidermis, the papillae and part of the reticular layers of the skin in which there were hair follicles, the terminal sections of the sebaceous glands and the excretory ducts of sweat glands. The thickness of the autogenous grafts varied from 435 to 800 microns.

All experimental animals were divided into two groups according to the severity of the acute radiation sickness. **F i r s t g r o u p** : 11 piglets with acute radiation sickness of the third degree. Eight of these died within 10 to 22 days after irradiation with a typical picture of acute radiation sickness, the rest were sacrificed 4 to 55 days after the combined injury.

**S e c o n d g r o u p** : six piglets that had a second degree radiation sickness, and they were sacrificed 28 to 45 days after the experiment. Biopsies of the autogenous grafts and segments of the same taken in the sacrificed animals were subjected to histological examinations by means of the usual methods of fixation and staining, beginning with the third day and ending with the 50th day after the operation. A total of 31 autogenous grafts from irradiated animals and 22 from nonirradiated animals were studied.

According to our observations and the data in the literature, the morphological processes occurring during the take of the free autogenous skin graft consist of: 1) the formation of a so-called connecting layer between the graft and the tissues of the recipient, 2) dystrophic, proliferative and reactive changes occurring in the tissues of the graft and 3) inflammatory and regenerative processes developing in the tissues of the recipient.

In the initial period of the acute radiation sickness (one to eight days after the combined injury, and three to five days after the skin graft), during which a pronounced depression in regenerative and reparative processes has not yet taken place, there is practically no difference between the morphology of the take of the free autogenous skin grafts in the irradiated animals and the control group.

During the first three days after the transplant, the

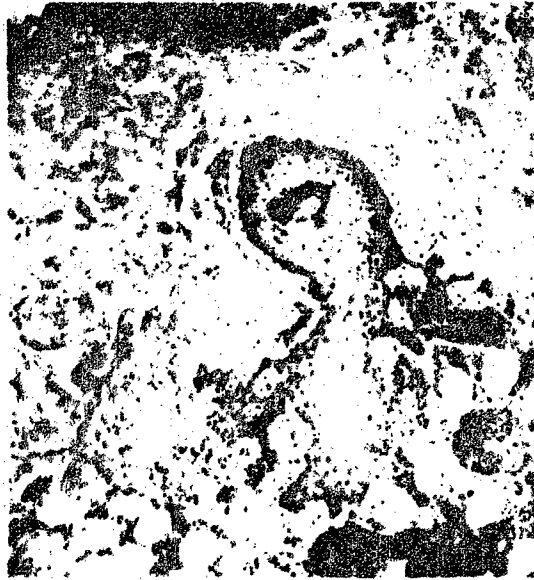

Fig. 1. Growth of epithelium of the external hair sheath of the auto-graft by infiltration in depth. (Irradiated piglet six days after graft; 10 days after irradiation. Staining with hematoxylin-eosin. Magnification 80 X.

supply of nourishing substances to the tissues of the skin flap is inadequate and takes place by means of the diffusion of tissue humors through a layer of inflammatory exudate that has formed between the tissues of the autogenous graft and the recipient. Therefore, in the first days after the transplant some elements of the skin flap undergo dystrophic and necrobiotic changes which are most pronounced in the epithelial cells of the epidermis, in the hair follicles and also in the blood vessels of the autogenous graft. The dystrophic processes were less pronounced in the reticular layer of the autogenous graft, where karyopyknosis of the connective tissue cells, swelling and homogenization of

the collagen fibers could be observed. Simultaneously with the dystrophic processes in the tissues of the skin flap there were also signs of regeneration, evidenced by active proliferation of epithelial cells of the basal layers of the epidermis and of the hair sheaths. The proliferating epithelial cells were growing not only on the surfaces of the transplant, but also into its thickness, forming in the tissues of the skin flap multiple epithelial strands with strange outlines (Fig. 1.). Growth of newly formed vessels from the tissues of the recipient through the connecting layer and into the tissues of the autogenous graft could be noticed.

On the fourth to the fifth days after the skin graft, the walls of the perforated wound were formed by the tissues of the autogenous transplant. The epithelium of the skin flap situated at the edge of the perforation became markedly thickened and formed regenerated epidermis moving over the bottom of the perforated wound, which consisted of the subcutaneous fat layers of the recipient, infiltrated by a large number of polymorphonuclear neutrophilic leucocytes.

At the end of the latent period of the acute radiation sickness (six to eight days after irradiation), the derma of the autogenous graft showed few hemorrhages situated around blood vessels and having the macroscopic appearance of dark purple spots.

The appearance of signs of hemorrhagic diathesis at the end of the latent period of the acute radiation sickness, preceding by one or two days the clinical symptoms of the height of the disease, indicates that the damaging influence of penetrating radiation appears first of all in those tissues in which metabolic processes are impaired and where the resistance to noxious agents is markedly reduced.

During the height of the acute radiation sickness there appeared essential peculiarities in the process of the take of the free skin graft that depended mainly on the severity of the course of the acute radiation sickness and the degree of the hemorrhagic syndrome. To these peculiarities belonged hemorrhages into and under the skin flap, necrotic and dystrophic changes taking place in the tissues into which, or what is more often, under which the hemorrhages took place. Some depression of the inflammatory processes can be noticed in the tissues of the transplant and of the recipient.

During the severe form of the acute radiation sickness occurring with a pronounced hemorrhagic syndrome with massive extravasations into the derma (Fig. 2.) of the autograft, the epithelial layers of the corresponding sectors of the skin flap undergo necrotic changes. Accumulation of single polymorphonuclear neucocytes takes place under the



Fig. 2. Extensive hemorrhages into the tissue of the autograft end and the "connecting" layer. (Irradiated piglet seven days after the graft; 11 days after irradiation. Staining with hematoxylin-picrofuchsin. Magnification 80 X.

necrotic part of the epithelium. Such a weakly pronounced inflammatory reaction at the site of injury depended most likely on the marked depression of the functions of the hemopoetic organs and particularly of the bone marrow. In the latter, a picture of complete "devastation" and extensive hemorrhages was seen during this period. The composition of the peripheral blood was a mirror of the condition of the hemopoetic organs. During the most pronounced symptoms of the acute radiation sickness, the number of leucocytes in the blood decreased by 80 to 90 percent as compared with the initial values.

In the presence of extensive hemorrhages into the derma of the skin flap, bundles of collagen fibers were ]

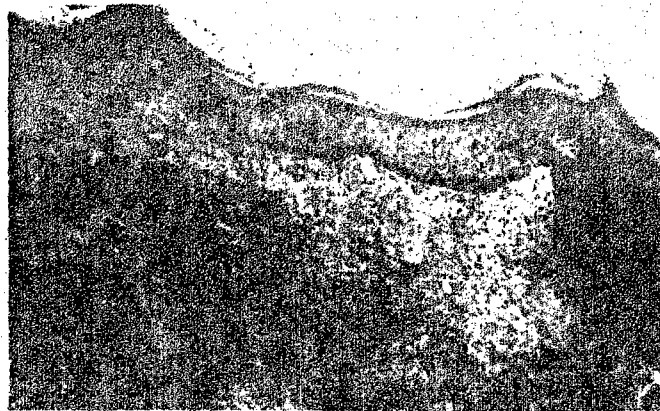


Fig. 3. Epidermal-connective tissue regeneration taking place at the site of a previous perforation of the dermatome flap. (Irradiated piglet 12 days after the graft; 16 days after irradiation. Staining with hematoxylin-picrorofuchsin. Magnification 80 X.




Fig. 4. Sebaceous gland and hair pouch in the tissues of the autograft. (Irradiated piglet 40 days after graft; 44 days after irradiation. Staining scarlet-rec. Magnification 80 X.

either totally undetectable or could be seen in the form of single strands giving a metachromatic reaction, and situated among masses of erythrocytes. Even the elastic fibers, so resistant to the action of noxious factors, were breaking up into multiple small and large lumps in the areas of extensive hemorrhages.

If the animals had the second degree of the acute radiation sickness and the hemorrhagic syndrome was not much pronounced, the above described changes were minimal or totally absent. In such cases the morphology of the process of the take of the free skin autograft in the irradiated animals did not differ from the takeability of the skin flaps in the control group of animals.

As compared with the third day, the fifth day after the skin graft the cover epithelium of the autotransplant became markedly thickened (155-250 microns between the papillae; whereas the thickness of the epithelium in the normal skin of the back of the piglets was 40 to 60 microns) and formed epithelial growths entering deep into the tissues of the autograft. Part of these growths separated from their maternal base and turned into islands of epithelium and cornified epithelial cysts. In the reticular layer of the skin of the autograft and also in the "connecting" layer as well as in the tissues of the recipient, there appeared a large number of young connective tissue cells, and penetration of blood vessels from the tissues of the recipient through the "connecting" layer into the tissues of the autotransplant proper was apparent. The majority of the hair follicles and sebaceous glands perished with the formation around them of inflammatory infiltrations with a large number of foreign body giant cells.

Ten to 12 days after the graft, macroscopic areas of the perforation were covered with dark brown crusts, histologically representing the necrotized superficial layers of the recipient's tissues. Under the crust, the wound was completely epithelized (Fig. 3.). Under the regenerated epidermis and throughout the thickness of the autograft there was a layer of reticular fibers among which were seen young connective tissue cells, blood vessels and extensive extravasations. The elastic fibers were absent in the area of the perforation.

During the convalescence period in the surviving animals, the tissues of the skin flap showed few hemorrhages, which were situated mainly around the blood vessels. In the "connecting" layer and in the tissues of the recipient, a large number of siderophages could be detected, giving a positive reaction for iron, thus indicating that a hemorrhage had previously taken place here. The reticular layer

of the autograft consisted of bundles of collagen fibers between which there was a large number of connective tissue cells, eosinophilic myelocytes and mature eosinophiles. In the sectors where hemorrhages took place into the tissues of the skin flap, there was formation of connective tissue scars covered with a thin layer of epithelium. Hair follicles and sebaceous glands appeared in the reticular layer of the autotransplant 50 days after the graft (Fig. 4.). The transplanted flap was firmly connected with the tissues of the recipient by a wide layer of scarred connective tissue, in which markedly thickened elastic fibers appeared on about the 50th day after the graft. During observations at later periods it was impossible to find a definite border between the "connecting" layer and the tissues of the recipient, the latter representing young granulating connective tissue separate fat globules and hair follicles could be seen, around which were concentrated numerous foreign body giant cells. By the twenty-first day after the skin transplant the perforated wounds were covered with a thickened epithelium with signs of hyperkeratosis and scanthosis. The cavity of the wound was filled with bundles of collagen fibers, among which were situated blood vessels. In the later periods of observation, 40 to 50 days after the operation, there appeared on the border of the perforation among bundles of collagen fibers, thin, palely staining threads of elastic fibers, growing most likely from the elastic fibers situated in the reticular layer of the autotransplant. For the practical tasks of the surgeon it is important to know not only how the autotransplants take, but also to know at what periods and from which tissular elements the healing of the donor areas takes place. It is known that the sooner the donor areas are epithelized the fewer are the possibilities for infection to penetrate through the wound; besides that desideratum the early healing of the donor areas permits once more the taking of skin flaps in order to cover wounds. However, definitely not enough light has been shed in the literature on the problem of the epithelization of the donor areas of the skin, and the few available data only indicate that the date of epithelization of the donor areas depends on the thickness of the flap taken with the dermatome and that the epithelization occurs mainly from the epithelium of the preserved hair sheaths and in part from the elements of the sebaceous glands (B. S. Vichriyev, 1955).

The dynamics of the healing of the donor areas of the skin was studied in eight irradiated piglets. It was determined that in the initial period of the acute radiation sickness (three days after the flap was taken and seven days

after irradiation), the donor areas of the skin were covered with a thick layer of erythrocytes (a result of the operative procedure), among which there were single white blood cells. Under the layer of erythrocytes there was visible a part of the reticular layer of the skin remaining after the removal of the dermatome flap as well as of the subcutaneous fat. The superficially situated bundles of collagen fibers and connective tissue cells, which underwent traumatization at the taking of the dermatome flap, became penetrated with leucocytes and perished. Simultaneously with the dystrophic processes there were also signs of a reparative character as evidenced by the increase in the number of connective tissue cells between the collagen fibers, by the marked thickening of the epithelial layer, the appearance of mitoses in the basal layer of the epidermis, and also by the ingrowing of the regenerating epidermis into the blood clot. Mitoses, which indicate active regenerative processes, were seen in the epithelium of the external hair sheaths and in the excretory ducts of the sebaceous and sweat glands. During the height of the acute radiation sickness the symptoms of the hemorrhagic syndrome in the donor areas of the skin were massive hemorrhages infiltrating and partly destroying bundles of collagen fibers in the reticular layer of the skin. In the cases where, in order to cover the donor areas, the surgeons used fibrin membranes, massive hemorrhages occurred under them as well as accumulation of necrotic masses containing a large number of microorganisms, which naturally interfered with the growth of granulation tissue and epithelization of the donor areas.

During fatal forms of radiation sickness the regenerated epithelial layers perished in the donor areas; the granulations necrotized and in the necrotic tissues a large number of microbes accumulated, the presence of which was not accompanied by an intensive inflammatory reaction.

However, in spite of the well-pronounced acute radiation sickness and extensive necrotic processes, there were visible mitoses and the development of granulation tissue under the necrotic masses in the tissues of the donor area (in the deep layers of the skin in the secretory parts and excretory ducts of the sweat glands in the epithelium of the external hair sheaths and also in the cells of connective tissue). All of this indicated the absence of a complete suppression of the immunobiological forces of the organism and indicated the capacity of the tissues for regeneration.

Complete epithelization of the donor areas of the skin occurred in the surviving animals within 30 to 34 days after the operation. Histologically these areas differed

from the surrounding skin by the absence of the papillary skin layer, by narrower bundles of collagen fibers and the presence of a large number of connective tissue cells located between them. Hair follicles and sebaceous glands were contained in the connective tissue layer of the derma.

The obtained data indicate that in the irradiated as well as in the nonirradiated animals there was no qualitative difference in the processes of takeability of free skin autotransplants. However, during the height of the acute radiation sickness and particularly in the perished animals, the tissues of the skin flap and of the donor area showed extensive hemorrhages, causing necrotic and dystrophic changes in the tissues in which a large number of microbes accumulated without causing around them a noticeable inflammatory reaction. Consequently, these particularities of the takeability of a skin flap during the height of acute radiation sickness are characteristic for radiation injuries and depend on the period and seriousness of the course of the acute radiation sickness.

#### Conclusions

1. In the initial period of the acute radiation sickness and during the period of convalescence the morphology of the takeability of a free skin autograft approaches qualitatively the takeability of skin flaps in animals not subjected to irradiation.
2. At the height of the development of acute radiation sickness the affected animals show a partial necrosis of the tissues of the autograft, death of the regenerated epithelium and necrosis of the granulations in the donor areas of the skin.
3. During the course of the acute radiation sickness the surviving animals show that a decline in the inflammatory reaction and the few hemorrhages into the tissues of the free skin flap and of the donor areas do not influence the subsequent processes of the take of the autograft and the healing of the donor areas. All of these processes occur in the same time as in the nonirradiated animals.
4. Some morphological peculiarities of the take of a free skin autotransplant and healing of the donor areas of the skin in irradiated animals are in direct relationship to the stage as well as to the severity of the course of acute radiation sickness.

### Bibliography

1. Burmistrov, V. M. and Slinko, V. G. Necrotomy and skin grafts of thermal burns of the third degree during the latent period of radiation sickness. Vestn. Khir., 6, 1958
2. Vikhriyev, B. S. Surgical treatment of third degree burns. Dissertation L. 1955
3. Orel, S. G., Experimental treatment of combined burns of the third degree with free skin grafts. Vestn. Khir. 10, 1957.
4. Petrov, V. I. Free skin grafts in radiation sickness Vestn. Khir. 9, 1956
5. Armstrong, J. E., Schaeffer, J. K., Arter, C. R., Treatment of burns in atomic disaster. United States Forces Medical Journal, 7, 3, 1956.

END

FOR REASONS OF SPEED AND ECONOMY  
THIS REPORT HAS BEEN REPRODUCED  
ELECTRONICALLY DIRECTLY FROM OUR  
CONTRACTOR'S TYPESCRIPT

THIS PUBLICATION WAS PREPARED UNDER CONTRACT TO THE  
UNITED STATES JOINT PUBLICATIONS RESEARCH SERVICE  
A FEDERAL GOVERNMENT ORGANIZATION ESTABLISHED  
TO SERVICE THE TRANSLATION AND RESEARCH NEEDS  
OF THE VARIOUS GOVERNMENT DEPARTMENTS