

AD \_\_\_\_\_

GRANT NUMBER DAMD17-97-1-7116

TITLE: Contract Enhanced 3D Color Amplitude Imaging of Breasts

PRINCIPAL INVESTIGATOR: Flemming Forsberg, Ph.D.

CONTRACTING ORGANIZATION: Thomas Jefferson University  
Philadelphia, Pennsylvania 19107

REPORT DATE: October 1998

TYPE OF REPORT: Annual

PREPARED FOR: U.S. Army Medical Research and Materiel Command  
Fort Detrick, Maryland 21702-5012

DISTRIBUTION STATEMENT: Approved for public release;  
distribution unlimited

The views, opinions and/or findings contained in this report are those of the author(s) and should not be construed as an official Department of the Army position, policy or decision unless so designated by other documentation.

19990928 404  
DTIC QUALITY INSPECTED 4

# REPORT DOCUMENTATION PAGE

*Form Approved*  
OMB No. 0704-0188

Public reporting burden for this collection of information is estimated to average 1 hour per response, including the time for reviewing instructions, searching existing data sources, gathering and maintaining the data needed, and completing and reviewing the collection of information. Send comments regarding this burden estimate or any other aspect of this collection of information, including suggestions for reducing this burden, to Washington Headquarters Services, Directorate for Information Operations and Reports, 1215 Jefferson Davis Highway, Suite 1204, Arlington, VA 22202-4302, and to the Office of Management and Budget, Paperwork Reduction Project (0704-0188), Washington, DC 20503.

1. AGENCY USE ONLY <i>(Leave blank)</i>	2. REPORT DATE October 1998	3. REPORT TYPE AND DATES COVERED Annual (15 Sep 97 - 14 Sep 98)	
4. TITLE AND SUBTITLE  Contract Enhanced 3D Color Amplitude Imaging of Breasts		5. FUNDING NUMBERS  DAMD17-97-1-7116	
6. AUTHOR(S)  Forsberg, Flemming, Ph.D.		8. PERFORMING ORGANIZATION REPORT NUMBER	
7. PERFORMING ORGANIZATION NAME(S) AND ADDRESS(ES)  Thomas Jefferson University Philadelphia, Pennsylvania 19107			
9. SPONSORING / MONITORING AGENCY NAME(S) AND ADDRESS(ES)  U.S. Army Medical Research and Materiel Command Fort Detrick, Maryland 21702-5012		10. SPONSORING / MONITORING AGENCY REPORT NUMBER	
11. SUPPLEMENTARY NOTES			
12a. DISTRIBUTION / AVAILABILITY STATEMENT  Approved for public release; distribution unlimited		12b. DISTRIBUTION CODE	
13. ABSTRACT <i>(Maximum 200 words)</i> This project is an add-on study to an already funded NIH project aimed at increasing the sensitivity and specificity of breast ultrasound by combining injection of an ultrasound contrast agent with 3D reconstruction of color amplitude images. The fundamental hypothesis is that the neovasculature of malignant lesions can be visualized with this novel combination, thus, improving the diagnosis of breast cancer. Image analysis software for the histomorphometry system has been developed to allow vessel distribution (i.e., histogram) and vessel density maps to be produced from 3D image data. Moreover, 3D parameter extraction algorithms for the LIS 6000A system has been designed and is currently being tested. To date 20 patients with 6 cancers and 14 benign lesions have been enrolled in the study. These numbers are less than anticipated, but efforts have been put in place to increase recruitment. There has been one adverse event. This was properly reported and judged to be a rated side effect of the ultrasound contrast agent which does not require any protocol changes. No data analysis has yet been carried out due to the limited data set available. However, this is expected to commence within the next 3 months.			
14. SUBJECT TERMS Breast Cancer Ultrasound contrast agent; 3D ultrasound imaging; color amplitude imaging; vascular morphology; tumor diagnosis;		15. NUMBER OF PAGES 30	
17. SECURITY CLASSIFICATION OF REPORT Unclassified		16. PRICE CODE	
		20. LIMITATION OF ABSTRACT Unlimited	
18. SECURITY CLASSIFICATION OF THIS PAGE Unclassified		19. SECURITY CLASSIFICATION OF ABSTRACT Unclassified	

FOREWORD

Opinions, interpretations, conclusions and recommendations are those of the author and are not necessarily endorsed by the U.S. Army.

\_\_\_ Where copyrighted material is quoted, permission has been obtained to use such material.

\_\_\_ Where material from documents designated for limited distribution is quoted, permission has been obtained to use the material.

\_\_\_ Citations of commercial organizations and trade names in this report do not constitute an official Department of Army endorsement or approval of the products or services of these organizations.


\_\_\_ In conducting research using animals, the investigator(s) adhered to the "Guide for the Care and Use of Laboratory Animals," prepared by the Committee on Care and Use of Laboratory Animals of the Institute of Laboratory Resources, National Research Council (NIH Publication No. 86-23, Revised 1985).

✓ For the protection of human subjects, the investigator(s) adhered to policies of applicable Federal Law 45 CFR 46.

\_\_\_ In conducting research utilizing recombinant DNA technology, the investigator(s) adhered to current guidelines promulgated by the National Institutes of Health.

\_\_\_ In the conduct of research utilizing recombinant DNA, the investigator(s) adhered to the NIH Guidelines for Research Involving Recombinant DNA Molecules.

\_\_\_ In the conduct of research involving hazardous organisms, the investigator(s) adhered to the CDC-NIH Guide for Biosafety in Microbiological and Biomedical Laboratories.

 10-14-98  
PI - Signature Date

## 4. TABLE OF CONTENTS

1. FRONT COVER.....	1
2. SF 298.....	2
3. FOREWORD.....	3
4. TABLE OF CONTENTS.....	4
5. INTRODUCTION.....	5
6. BODY.....	6
6.1 Methods	6
6.2 Results and Discussion	7
7. CONCLUSIONS.....	9
8. REFERENCES.....	11
9. CAPTIONS.....	12
10. APPENDICES.....	16

## 5. INTRODUCTION

The goal of any breast imaging modality is to improve the early detection of tumors and to improve the differentiation between benign and malignant lesions. While x-ray mammography is efficacious in diagnosing a high percentage of breast masses, it also produces a high rate of false positives [1]. The percentage of breast biopsies that are actually malignant vary between 10 % and 35 %. Thus, a technique which reliably differentiates between malignant and benign masses would improve the diagnosis of breast cancer and should, therefore, reduce the number of negative biopsies as well as the trauma of the patients. This project attempts to establish such a technique through the novel and innovative combination of three-dimensional (3D) ultrasound imaging with a contrast agent.

Ultrasound imaging is currently an auxiliary modality in breast imaging. It is mainly used to differentiate between cystic and solid lesions [2]. Investigations into the possibility of breast cancer diagnosis based on Doppler ultrasound flow detection have produced mixed results, due to overlap between flow measurements in benign and malignant tumors [3-4]. One problem may be the lack of sensitivity in flow detection in small tumor vessels using ultrasound. This hypothesis is supported by reports in the pathology literature describing angiogenic vascular morphology as an independent predictor of metastatic disease [5].

Ultrasound contrast agents produce increases of 15 to 25 dB in the echo intensities of blood flow signals; especially when combined with a new display technique called color amplitude imaging (CAI) [6-7]. Thus, an interesting research study can be devised, which compares the ability of two-dimensional (2D) color Doppler ultrasound with and without contrast to differentiate between benign and malignant masses relative to x-ray mammography. This is in essence the purpose of a 5 year National Institutes of Health (NIH) funded project recently awarded to Thomas Jefferson University. The current project (DAMD17-97-1-7116) is an expansion to the NIH project which adds 3D flow imaging with and without contrast, since 3D imaging should be better suited than 2D ultrasound to demonstrate the tortuous angiogenic vasculature associated with breast cancer.

Not only is the potential of the novel combination of 3D imaging and contrast in itself innovative, but because of the NIH funded study it will be possible to compare a number of new and unique approaches to breast cancer diagnosis i.e., 2D and 3D CAI with and without contrast as well as harmonic imaging directly to x-ray mammography. Furthermore, this project is extremely cost-effective because the NIH grant covers a majority of the personnel costs as well as all major equipment purchases. The amalgamation of the NIH project with the current proposal also allows for basic research into the correlation between Doppler flow signals and pathologically detected lesion vascularity. This will enable a deeper understanding of the relationship between tumor neovascularity and ultrasound flow measurements; again at very little cost to this proposal.

Consequently, this project is an add-on study to the already funded NIH project aimed at increasing the sensitivity and specificity of breast ultrasound by combining injection of an ultrasound contrast agent with 3D reconstruction of color amplitude images. The fundamental

hypothesis is that the neovasculature of malignant lesions can be visualized with this novel combination, thus, improving the diagnosis of breast cancer.

## 6. BODY

The central hypothesis of this project is that the differentiation between benign and malignant breast lesions can be improved by visualization of tumor neovascularity using 3D ultrasound imaging in conjunction with an ultrasound contrast agent. To investigate this hypothesis 150 women with breast lesions will be recruited over three years and imaged using contrast enhanced 3D CAI. The specific tasks of the project (as presented in the original Statement of Work) can be found in Appendix I.

First an outline of the methods applied will be given followed by a presentation of the results to date. Finally, the conclusions and future directions of the research will be discussed.

### 6.1 Methods

The 3D CAI reconstructions in this project are performed with a state-of-the-art ultrasound scanner connected to an LIS 6000A 3D Image Acquisition and Reconstruction system (Life Imaging Systems Inc, London, Canada). To date all 3d CAI acquisitions have been performed with an HDI 3000 scanner (Advanced Technology Laboratories, Bothell, WA). The 3D CAI data sets are reconstructed, with no loss of registration accuracy, to provide both multi-perspective Maximum-Intensity-Projection visualization and 2D planar views.

The patients used in this project will be women of a wide variety of ages having a breast mass or abnormality resulting in a breast excisional biopsy. Breast cancer in males accounts for only about 1 % of cases in our hospital and thus, were not be included in the patient population. All patients will be referred after X-ray mammography identifies a mass or suspicious area. The target enrollment is approximately 50 patients per year, which represents half of the patients being recruited for the NIH-supported study.

Following a baseline ultrasound gray scale scan, which identifies the mass seen by x-ray mammography, images for 3D CAI of the lesion are acquired. Next, an ultrasound contrast agent Levovist is administered intravenously via a peripheral vein, preferably the antecubital vein. An initial videotaped sweep of the mass will be made with the gain and CAI settings unaltered from the pre contrast settings. This will allow for side by side comparison of pre and post contrast CAI studies. Following this, the CAI settings will be optimized for the stronger contrast enhanced Doppler signals. As the SNR improves it should be possible to achieve higher frame rates and/or line density, improving spatial resolution of the color. Videotaped sweeps of the abnormality will be made every 1 to 2 minutes through the period of enhancement (up to 6 minutes). A second injection is made to acquire 3D CAI data with the gain and other settings unaltered from the pre contrast protocol. This will allow for side by side comparison of pre and post contrast 3D CAI

studies. Next the CAI settings will be optimized for the stronger contrast enhanced signal, and 3D data will be acquired again.

The ultrasound findings will be correlated to the pathology sections and the radiologist and pathologist will attempt to correlate the findings by each method. If the ultrasound and pathology sections do not match it is possible in the 3D case to resection the acquired volume until a match is found. The vascular morphology of the sections will be determined by a histomorphometry system based on an SMZ-10A microscope (Nikon, Melville, NY) and Image-Pro Plus software (Media Cybernetics, Silver Spring, MD). Each slide was mounted on the motorized stage of the Olympus microscope with a 10x objective and 10x ocular, a total magnification of 100x. Connected to the microscope was a Sony CCD camera which provided a digital view of the slide onto a desktop computer. ImagePro Plus (Media Cybernetics, Silver Spring, MD) software is used for central control, communicating with both the motorized stage and the CCD camera. The software was installed on a Micron Pentium 166 MHz 32 bit computer. Using the software, the stage was programmed to move across the entire specimen area, acquiring one image at every step. The Red Green Blue (RGB) color space was used to view and capture the image. The frame size captured was equal to 640 pixels by 480 pixels or 1.27 mm<sup>2</sup>. The image was named by its position in the scanning grid and saved as a JPEG formatted image on the hard drive for further analysis.

## 6.2 Results and Discussion

The first task was to develop image analysis software for the histomorphometry system to allow a computerized histogram of the distribution of vessels and the number of vessels within the tumor to be produced from the pathology slide. The aim of the image analysis was to develop a method in which only micro-vessels with lumen would be recognized by the software and hence be counted and measured. Only vessels with lumen were chosen so that the diameter of the vessels could be assessed directly, other structures sporadically stained would not give false positives, and a more repeatable and automated method could be performed. RGB color space poorly disperses the various color values and hence for biological images, where colored stains are commonly used to identify features, it is difficult to interpret the meanings of the separate RGB color channels. Therefore, the RGB images were converted to Hue Saturation Intensity (HSI) images which do separate different regions of color values. HSI color space is closely related to the concepts of tint, shade, and tone and the meanings of HSI color channels for stained biological images can be stated as follows:

- 1) The hue channel identifies where a particular stain is located
- 2) The saturation channel corresponds to the amount of the stain
- 3) The intensity channel indicates the overall density of the stain.

The method used in this analysis was patterned after the chromaticity or color based analysis method used by Barbareschi et al.[8] Additional processing techniques were applied due to the varying intensity of immunostaining and the use of a lower magnification power on the microscope. The steps in the method are as follows in Table 1 (steps not used in the Barbareschi method are marked with astericks):

**Table 1: Procedure for image analysis of breast tumor slides.**

- 1) \*Optional histogram map applied to original image if CD31 staining very poor
- 2) \*Open and Sharpen filters are used on the original image
- 3) Saturation and Blue images are extracted from the original image in RGB and HSI color models. In the Blue image, the brown stain appears the darkest and in the Saturation image, the brown stain appears lightest.
- 4) Subtraction of Blue image from the Saturation image resulting in an image in which only pixels corresponding to the brown stain of the original image are present. Theoretically automatic detection of the microvessels is possible by selecting all pixels greater than a gray value of 1.
- 5) Manual segmentation of the gray level pixels corresponding to the brown stain
- 6) Automated counting and measuring microvessels and exporting the raw data to Microsoft Excel

The measurements quantified by the software were the area, average diameter, and minimum diameter of each vessel. The average diameter is determined by the software as the average length of the diameters measured at 2 degrees of intervals and passing through the object's centroid. The minimum diameter is the length of the shortest line joining two points of the object's outline and must pass through the centroid. Depending on vessel orientation and cutting angle of the mass, the vessel diameter could be erroneously measured. If the vessel was parallel to the cutting angle then a larger diameter could result than if the vessel was oriented perpendicular to the cutting angle. To limit this particular error, the actual diameter of a vessel was determined by comparing the minimum and average diameter. If the average diameter was 3 times greater than the minimum diameter then it was assumed that the vessel appeared longitudinally and the minimum diameter was used as the vessels actual diameter. Otherwise the average diameter was accepted as the vessels actual diameter. The number of vessels and percent of area the vessels occupied were the results obtained and were divided into five categories: a) vessels that were 10-19  $\mu\text{m}$  in diameter, b) vessels that were 20-29  $\mu\text{m}$  in diameter, c) vessels that were 30-39  $\mu\text{m}$  in diameter, d) vessels that were 40-49  $\mu\text{m}$  in diameter, and e) vessels that were 50  $\mu\text{m}$  and above in diameter. Examples of the pathology evaluations are given in Figures 1 and 2.

While task 1a has been completed on time as described above task 1b has been slightly delayed mainly due to personnel turnover at the Robarts Research Institute where the consultant on this project Dr. Fenster is based. However, automatic 3D parameter extraction algorithms have been developed and the software has just been transferred to the LIS 600A system at Thomas Jefferson University. Other quantifiable parameters, such as the number of vessel interconnections ("AV-shunts") and vessel tortuosity, will be implemented shortly. The existing software generates the skeleton of a 3D object here, the tumor vascularity, following thresholding and smoothing to improve the segmentation algorithm. Post-processing steps to ensure vessel continuity and to remove redundancies have also been implemented. Testing of this software is ongoing and should be finalized within the next 3 months.

Task 2 data collection was scheduled to start in month 1. However, Life Imaging Sciences experienced some logistical problems and it took 3 months to get a LIS 600A color system to

Thomas Jefferson University. Following system calibration patient recruitment into the study commenced in January 1998. Table 2 provides a summary of the patient population recruited in Year 1. In total 20 women were studied using contrast enhanced 3D CAI. The patients had a mean age of  $50 \pm 11$  years (range 26 to 67 years). There were 6 cancers and 14 benign lesions studied in the period from January to September 1998 corresponding to 30 % and 70 % , respectively. In Figure 3 an example of a breast carcinoma is presented in 3D color amplitude mode before and after contrast injection. The enhanced 3D image clearly depicts the branching intra-tumoral vasculature (in two planes) as well as the much larger peripheral feeder vessels. The central portion of this lesion was avascular.

There was one adverse event following a contrast study on April 7<sup>th</sup> 1998 where a patient experienced upper arm pain. The patient was hospitalized on April 17<sup>th</sup> and discharged on the 18th. The event was upgraded from a mild to a serious adverse event on April 22<sup>nd</sup>, 1998 (due to the hospital admission). That day Cathy Smith of the US Army Medical Research and Material Command was notified by phone and a written report was sent on April 23<sup>rd</sup>, 1998. This adverse event has been classified as a rated side effect of Levovist and no changes to the study protocol has, therefore, been initiated.

It should be noted that patient recruitment is lower than the 50 patients per year anticipated in the original proposal. Over an 8 months period (mid January to mid September) we anticipated recruiting 33 patients but in reality we enrolled 20 subjects. Even accounting for the occasional hardware problems with the LIS 600A unit there is clearly a drop in the recruitment rate relative to the original proposal. It has been a lot more difficult to enroll patients into a 4 hour ultrasound contrast agent study immediately prior to their breast surgery than envisaged at the time of submission. In the same period the NIH funded study only managed to recruit 40 patients, which means that this project is on target for enrolling 50 % (20 out of 40 subjects) of the patients seen in the NIH project. To further boost recruitment we will attempt to enroll all women participating in the NIH supported study in Year 2 of the grant.

Given the problems in the execution of task 2, as described above, task 3 has not been initiated yet. However, once the 3D segmentation and analysis software has been finalized we will commence task 3 (data analysis). Consequently, no publications have been produced from this project in Year 1. However, selected cases have been presented as part of abstracts from the NIH funded study [9-10] as well as in a review paper on contrast agents [11] (see also Appendix II).

## 7. CONCLUSIONS

Image analysis software for the histomorphometry system has been developed to allow vessel distribution (i.e., histogram) and vessel density maps to be produced from 3D image data. Moreover, 3D parameter extraction algorithms for the LIS 6000A system have been designed and are currently being tested.

To date 20 patients with 6 cancers and 14 benign lesions have been enrolled in the study. These numbers are less than anticipated, but efforts have been put in place to increase recruitment. There has been one adverse event. This was properly reported and judged to be a rated side effect of the ultrasound contrast agent which does not require any protocol changes. No data analysis has yet been carried out due to the limited data set available. However, this is expected to commence within the next 3 months.

**Table 2: Patient enrollment details.**

Patient no.	age [years]	race	diagnosis
46	58	Caucasian	Fibroadenoma
47	38	Black	Fibroadenoma
49	55	Caucasian	Atypical Ductal Hyperplasia
50	40	Caucasian	Fibroadenoma
55	42	Caucasian	Ductal Carcinoma in Situ
56	65	Caucasian	Invasive/in-situ Lobular Carcinoma
57	37	Caucasian	Fibroadenoma
58	52	Caucasian	Focal Lobular Carcinoma in situ
59	43	Caucasian	Fibrocystic Changes
60	67	Caucasian	Intraductal Papilloma
61	49	Caucasian	Lipoma
63	54	Caucasian	Ductal Carcinoma in Situ
64	46		Fibrocystic Disease
65	65	Caucasian	Fibroadenoma
66	65	Black	Ductal Ectasia
67	26	Black	Fibroadenoma
68	53	Caucasian	Fibrocystic Disease
69	53	Caucasian	Atypical Lobular Hyperplasia
71	58	Caucasian	Lobular Hyperplasia
72	44	Caucasian	Residual Ductal Carcinoma in Situ

## 8. REFERENCES

1. Feig SA: Breast masses: Mammographic and sonographic evaluation. *Radiologic Clin North Am* 30:67-92, 1992.
2. Jackson VP: The Role of US in Breast Imaging. *Radiology*, 177:305-311, 1990.
3. Bohm-Velez M, Mendelson EB: Computed tomography, duplex Doppler ultrasound and magnetic resonance imaging in evaluating the breast. *Semin Ultrasound CT MR*, 10:171-176, 1989
4. Adler DD, Carson PL, Rubin JM, Quinn-Reid D: Doppler ultrasound color flow imaging in the study of breast cancer: preliminary findings. *Ultrasound Med. Biol.*, 16: 553-559, 1990.
5. Weidner N, Folkman J, Pozza F, et al. Tumor angiogenesis: a new significant and independent prognostic indicator in early-stage breast cancer. *J Natl. Cancer Inst.*, 84: 1875-1887, 1992.
6. Goldberg BB. *Ultrasound contrast agents*. Martin Dunitz Ltd., London, UK, 1997.
7. Forsberg F, Merton DA, Liu JB, Needleman L, Goldberg BB: Clinical applications of ultrasound contrast agents. *Ultrasonics*, 36: 695 - 701, 1998.
8. Barbareschi M, Girlando S, Mauri FM, Forti S, Eccher C, Mauri FA, Togni R, Dalla Palma P, Doglioni C. Quantitative growth fraction evaluation with MIB1 and Ki67 antibodies in breast carcinomas. *Am J Clin Path* 102: 171 - 175, 1994.
9. Forsberg F, Merton DA, Schultz SM, Goldberg BB, Needleman L, Rawool NM: Contrast induced waveform changes in women with breast lesions. *J Ultrasound Med*, 17: S97, 1998.
10. Forsberg F, Needleman L, Goldberg BB, Schultz SM, Merton DA, Rawool NM: Contrast enhancement of breast masses. *Ultrasonic Imaging*, 20: 52 - 53, 1998.
11. Forsberg F, Goldberg BB: Contrast-enhanced ultrasound imaging. *Science & Medicine*, 5: 54 - 63, 1998.

## 9. CAPTIONS

- Figure 1.** Contour map of the vascular area within a breast tumor (in  $\mu\text{m}^2$ ) established by pathological staining and analysis.
- Figure 2.** Contour map of the number of tumor vessels with a diameter between 10 and 20  $\mu\text{m}$  established by pathological staining and analysis.
- Figure 3.** Example of 3D CAI of a breast mass before (*left panel*) and after (*right panel*) contrast administration. Notice, the increase in vessel visualization post contrast.

Vessel Area(microns<sup>2</sup>) on Slide 1F

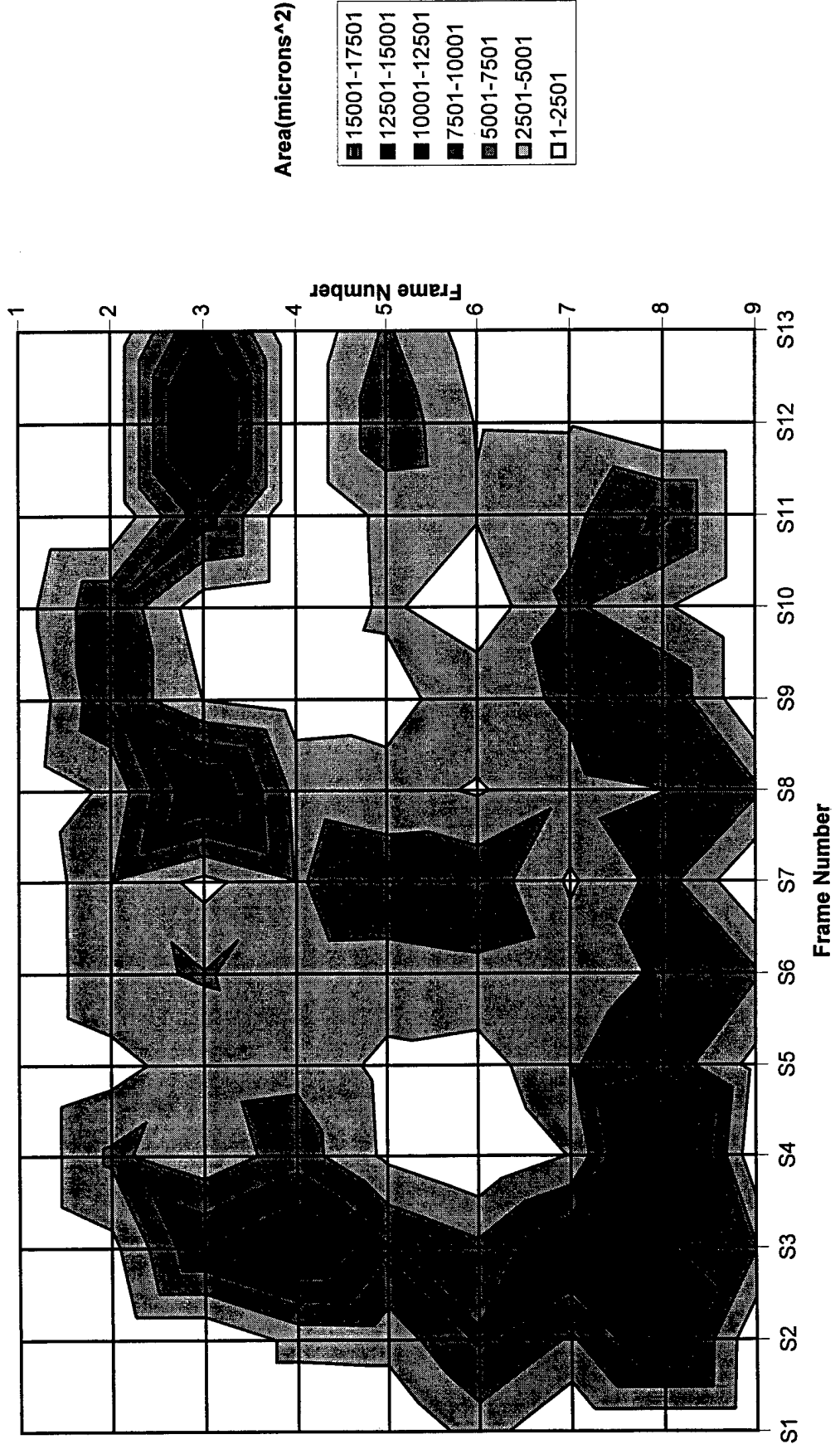


Fig 1

Number of Vessels Between 10 and 20 microns of Slide IF

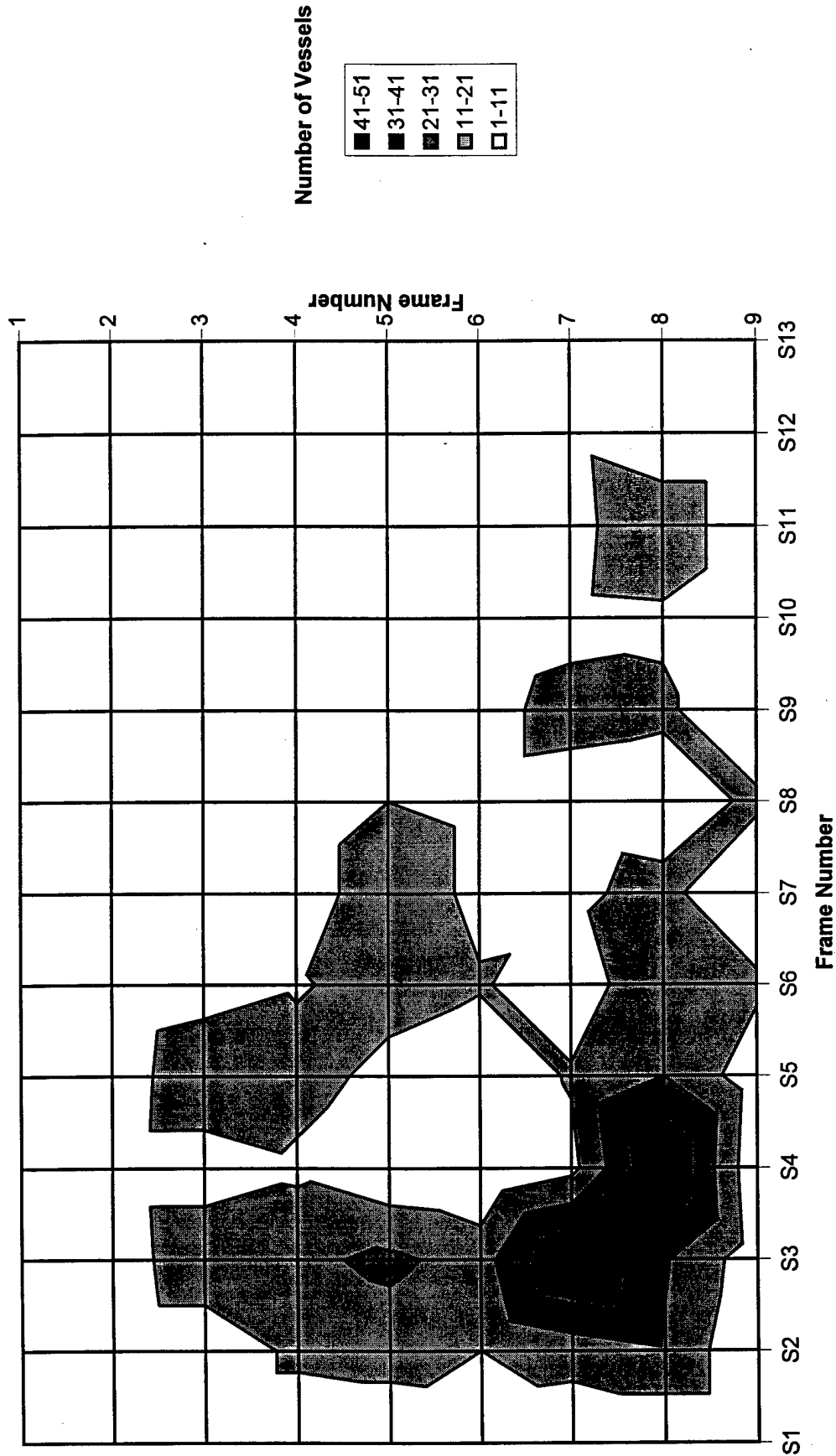


Fig 2





Fig 3

## Appendix I

The Statement of Work from the original proposal:

### **Technical objectives 2 - 3**

**Task 1:** Software development (months 1 - 6)

- a. Develop image analysis software for the histomorphometry system to allow vessel distribution (i.e., histogram) and vessel density maps to be produced from 3D image data.
- b. Develop 3D parameter extraction algorithms for the LIS 6000A system e.g., counting the number of interconnecting branches ("AV-shunts") and scoring the vessel tortuosity in collaboration with the consultant. Depending on the outcome of the statistical analysis, it is conceivable that new parameters will have to be extracted at a later date. Since the acquired 3D data volumes can be processed repeatedly this does not impact on the study design, it only demonstrates the flexibility of the data.

### **Technical objective 1**

**Task 2:** Data collection (months 1 - 36)

- a. recruit 50 patients per year. This is about half of the anticipated number of patients being enrolled in the NIH supported contrast study.
- b. perform 3D CAI contrast studies as part of the already funded NIH project. This involves an extra injection of contrast (within the permitted total dose) and will add no more than 20 minutes to the total duration of the contrast study.
- c. research coordinator to collect clinical information (pathology results, etc.).

### **Technical objectives 2 - 3**

**Task 3:** Data analysis (months 6 - 36)

- a. incorporate 3D imaging findings into the existing database (developed for the NIH supported contrast study).
- b. quantitate 3D CAI results in collaboration with the consultant.
- c. perform ROC analysis in collaboration with the statistician.
- d. perform remaining statistical analysis in collaboration with the statistician.

## Appendix II

Reprint of article from Science and Medicine

An Article From:

# SCIENCE & MEDICINE

MAY/JUNE 1998

VOLUME 5, NUMBER 3

COPYRIGHT © 1998 by SCIENCE & MEDICINE, INC. ALL RIGHTS RESERVED.

Vindication of this statement is seen in the example cited from autoimmunity, where an important target autoantigen from collagen turns out to be a glycopeptide. In anti-tumor responses, too, the role of glycopeptides as tumor-specific antigens must not be underestimated.

An important development to grow out of understanding the molecular basis for self-nonself recognition is the use of peptides as vaccines against both infectious organisms and the progression of malignancies. In particular, the use of glycopeptides to induce MHC-unrestricted anti-tumor T cells is exciting. Also, peptide therapy for autoimmune disease has been suggested by experiments showing that certain peptides that are structurally related to a disease-inducing autoepitope can actually antagonize the responding T cells, thus abating their pathogenic effects.

Expanding investigations into the use of glycopeptides in these arenas will place heavy demands on the organic chemists who so far have supported the biological investigations I have described. New glycosylated amino acid building blocks are being developed that can be used in automated solid-phase peptide synthesis techniques. This is no mean feat, as a whole new chemistry had to be devised to take into account the sensitivity of sugars to compounds that are routinely used in peptide synthesis.

Glycopeptides with monosaccharide modifications have been made in this way, with additional sugar units added to the peptide-linked sugar at a later stage. In a recent breakthrough in glycopeptide synthesis, larger saccharide units (for example, three) are assembled prior to being coupled to an amino acid that can be incorporated into a synthetic peptide. The improved efficiency of this method should make the preparation of synthetic glycopeptides for use as vaccines a more routine affair.

The importance of sugars on glycoprotein antigens also extends beyond the creation of new epitopes that are potential targets for vaccine therapy. The finding that glycosylation can have a negative effect on the immune response at the level of processing, presentation, and recognition may also be of practical value. For example, metabolic inhibitors of glycosylation might find a use in uncovering viral or tumor epitopes that have been cunningly hidden by the deployment of a well-placed glycosylation site.

Without doubt, another door has opened to the understanding of T cell responses to protein antigens. As more is learned about how protein glycosylation varies under different conditions such as viral infection, environmental assault, and malignant transformation, the easier it will be to assess the relevance of carbohydrate-specific T cells in infections, cancers, and autoimmune diseases.

#### RECENT REVIEWS

Pauline M. Rudd and Raymond A. Dwek: Glycosylation: Heterogeneity and the 3D structure of proteins. *Critical Reviews in Biochemistry and Molecular Biology* 32:1-100, 1997.

Tim Elliott et al.: Peptide selection by class I molecules of the major histocompatibility complex. *Current Biology* 3:854-866, December 1993.

Jan Kihlberg and Mikael Elofsson: Solid-phase synthesis of glycopeptides: Immunological studies with T cell stimulating glycopeptides. *Current Medicinal Chemistry* 4:85-116, 1997.

#### ORIGINAL PAPERS

John S. Haurum et al., *Journal of Experimental Medicine* 180:739-744, August 1994. [Recognition of carbohydrate by class I-restricted glycopeptide-specific CTL's.]

Erik Michaëlsson et al., *Journal of Experimental Medicine* 180:745-749, August 1994. [T cell recognition of carbohydrates on type II collagen.]

Ussama M. Abdel-Motal et al., *European Journal of Immunology* 26: 544-551, March 1996. [Generation of carbohydrate-specific unrestricted CTL's.]

Dalibor Sames, Xiao-Tao Chen, and Samuel J. Danishefsky, *Nature* 389:587-591, October 9, 1997. [Convergent total synthesis of a tumor-associated mucin motif.]

# Contrast-Enhanced Ultrasound Imaging

by *Flemming Forsberg and Barry B. Goldberg*

**Air conducts sound ineffectively, and ultrasound waves scarcely at all. Therefore, injected microbubbles are useful in improving the reflected signal intensity from flowing blood. Ultrasound contrast agents already on the market are composed of bubbles small enough to traverse capillaries and durable enough to endure several cardiac cycles. They appear to increase the sensitivity of Doppler ultrasound to the degree that slowly flowing blood can be delineated within the tortuous small vessels typical of malignant tumors. Microbubbles resonate when struck by an incident ultrasound pulse, so that harmonic and subharmonic frequencies are reflected along with the incident frequency. Targeting ultrasound contrast agents to specific tissues and loading them with drugs or DNA are under investigation.**

**D**iagnostic ultrasound is the most widely used imaging modality in the world for three important reasons. First, ultrasound is noninvasive, forming images by means of mechanical vibrations instead of ionizing radiation. Second, ultrasound produces a real-time depiction of anatomy as well as of blood flow. Finally, diagnostic ultrasound scanners are highly portable and can be acquired at a relatively low price compared to the equipment required in other imaging modalities.

Ultrasound imaging of soft tissue structures, or gray-scale imaging, is dependent on differences in the acoustic properties of body interfaces producing back-scattered sound waves or echoes. Doppler ultrasound techniques, which are used to detect blood flow, rely on additional processing of the back-scattered echoes to estimate the movement of red blood cells.

There are limits to the performance of even state-of-the-art ultrasound machines in both gray-scale and Doppler imaging modes. As ultrasound is employed for the study of smaller structures or those that lie deeper within the body, lower frequency transducers must be used to compensate for signal losses through attenuation, which increases exponentially with both depth and frequency. The spatial resolution of gray-scale imaging becomes insufficient, and the reduction in signal-to-noise ratio affects Doppler sensitivity even more, especially when the attempt is




being made to detect slow-moving blood in small vessels such as those that typically arise in tumors by angiogenesis.

These limitations are the rationale behind the rapid development of contrast agents for ultrasound, a variety of which are currently being investigated. Contrast agents have long since become a routine component of other imaging modalities, but ultrasound has yet to benefit from the potential of contrast enhancement. In this article, we describe some of the clinical uses of ultrasound contrast agents and discuss some new contrast-specific imaging techniques.

## **Microbubbles Enhance Ultrasound Echoes**

Contrast agents promise to improve the sensitivity and specificity of diagnostic ultrasound imaging and have the potential to expand ultrasound's already broad range of applications by opening the door to new and unique clinical uses. Ultrasound contrast agents can improve the signal-to-noise ratio of sonography either by increasing the reflectivity of desired acoustic interfaces, thus increasing the intensity of the back-scattered signal, or by decreasing the reflectivity of the undesired interfaces, thus reducing the noise in the signal.

The latter approach is taken by oral ultrasound contrast agents used for examining the upper gastrointestinal tract. Sonographic assessment of the upper GI tract is



hampered by the presence of gas, which produces shadowing artifacts. Ingestion of an oral contrast agent displaces the gas and results in a homogeneous transmission of sound.

The majority of ultrasound contrast agents are injected intravenously and are intended to increase the back-scattered signal intensity from blood. Vascular enhancing ultrasound agents were introduced by Raymond Gramiak and Pravin M. Shah of the University of Rochester in 1968. They injected agitated saline through a catheter into the ascending aorta and the cardiac chamber during echocardiographic examinations. Strong but short-lived echoes were observed within the heart, and subsequent studies revealed these to be reflections from free air microbubbles that had been produced in the saline solution by the agitation.


The acoustic mismatch between the gas and the surrounding blood resulted in strong echoes that produced a marked increase in the signal-to-noise ratio. However, microbubbles produced by hand agitation are large and unstable, and they diffuse back into solution in less than 10 seconds.

To make contrast-enhanced ultrasound a viable alternative to other diagnostic imaging modalities, certain properties are desirable in a vascular ultrasound contrast agent. It should be nontoxic, injectable, and small enough to traverse the capillaries. It should also provide marked enhancement of the signal-to-noise ratio and be stable enough to last through multiple cardiac cycles.

A number of contrast agents in various stages of testing appear to possess these characteristics. Most of them consist of microbubbles 1

**Vascular definition** is dramatically improved by ultrasound contrast agents. The *upper panels* show a rabbit kidney imaged in color Doppler mode and the *lower panels* the same kidney imaged in color amplitude (also called power Doppler) mode, before and after injection of contrast.

**FLEMMING FORSBERG** and **BARRY B. GOLDBERG** are in the Division of Diagnostic Ultrasound, Department of Radiology, at Thomas Jefferson University Hospital in Philadelphia. Dr. Goldberg is Professor of Radiology and Director of the Division as well as of the Jefferson Ultrasound Research and Education Institute. Dr. Forsberg is Associate Professor of Radiology and Head of Research for the Institute.



**New blood vessels** supplying malignant tumors often develop anastomoses and shunts, which produce a disorderly and chaotic angiogenic vasculature quite different from that of benign tumors or for that matter normal tissues, as shown here schematically.

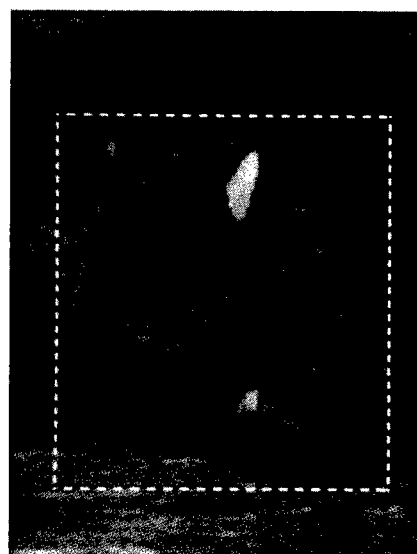

to 10  $\mu\text{m}$  in diameter, which are often filled with poorly soluble gases and stabilized with a coating of surfactants or with an encapsulating elastic shell.

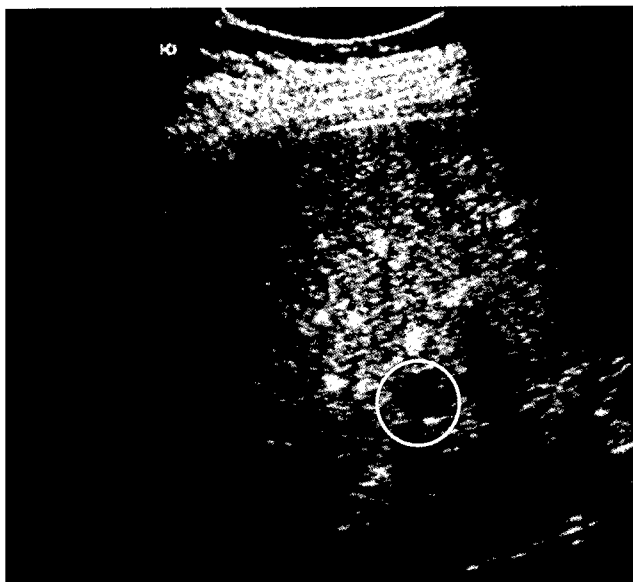
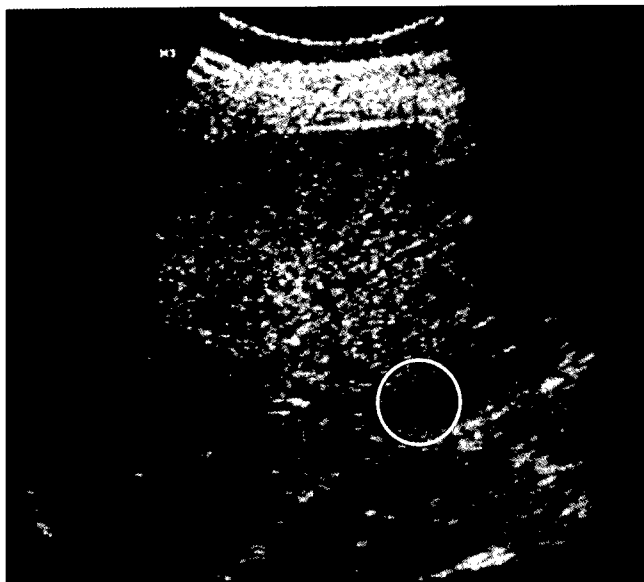
Vascular ultrasound contrast agents have been shown to enhance the back-scattered Doppler flow signals by 8 to 25 dB in both color and spectral modes. The associated improvement in vascular definition is dramatic. Ultrasound contrast agents are particularly well suited for display in the color amplitude imaging mode, because amplitude imaging directly depicts the parameter affected by the agent, namely the signal intensity, whereas conventional color Doppler imaging depicts the mean Doppler frequency shift.

Some agents even improve the gray-scale visualization of flowing blood to such a degree that tissue echogenicity increases (so-called parenchymal enhancement). Microbubbles within small vessels and capillaries of an organ can thus provide an indication, albeit qualitative, of perfusion. This in turn may improve lesion detection as well as the ability to differentiate between normal and abnormal areas using many of the criteria already routinely used in CT and MRI.

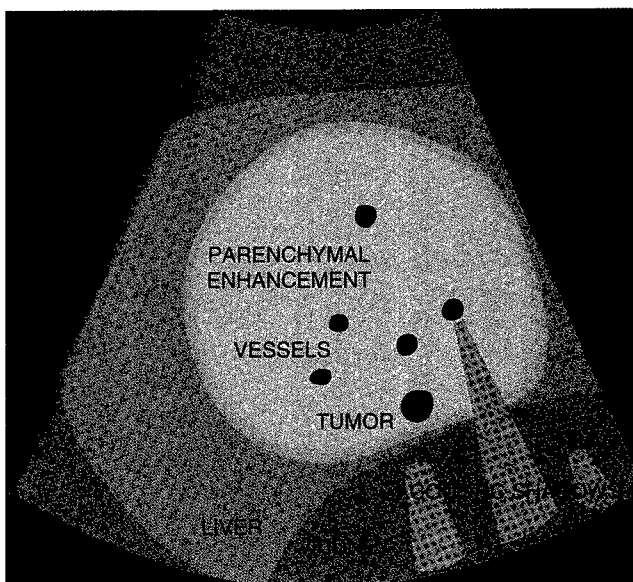
Several cardiac and vascular ultrasound contrast agents are already available commercially. Molecular Biosystems sells Alunex and Optison in the United States, and Schering markets Echovist and

**Direct visualization of tumor vascularity** using a second generation contrast agent. The tumor is an experimentally induced carcinoma in a rabbit. Vessels radiating from the tumor are clearly seen after contrast administration. The center of the mass is necrotic.





**Gray-scale images** of a patient with a liver tumor 10 mm or less in diameter. Before contrast injection (*left panel*), the tumor is inconspicuous. After injection (*right panel*), the normal liver parenchyma enhances, making the lesion easier to appreciate because of its lack of contrast uptake.



Levovist in a number of European countries. Some other agents currently in various stages of regulatory approval are EchoGen (Sonos Pharmaceuticals), Imagent US (Alliance Pharmaceutical Corp.), DMP-115 (DuPont Merck), and NC100-100 (Nycomed Amersham).

More generically, ultrasound contrast agents are often classified as first, second, or third generation agents, depending on their specific properties. Lack of control of bubble size distribution made first generation agents of limited clinical utility. Second generation agents truly improved ultrasound imaging by virtue of their prolonged half-life. Important new

capabilities, such as the direct assessment of myocardial perfusion, became possible with third generation agents, which rely almost exclusively on higher molecular weight gases to achieve significant enhancement for 10 minutes or more.

### **Contrast Enhancement Helps Detect Tumors**

Intravenous vascular ultrasound contrast agents are likely to find extensive use in oncology. A variety of tumors have been evaluated in humans, including malignant tumors in the liver, kidney, ovary, pancreas, prostate, and breast. In

#### **CONTRAST AGENT CLASSIFICATION**

##### **First generation**

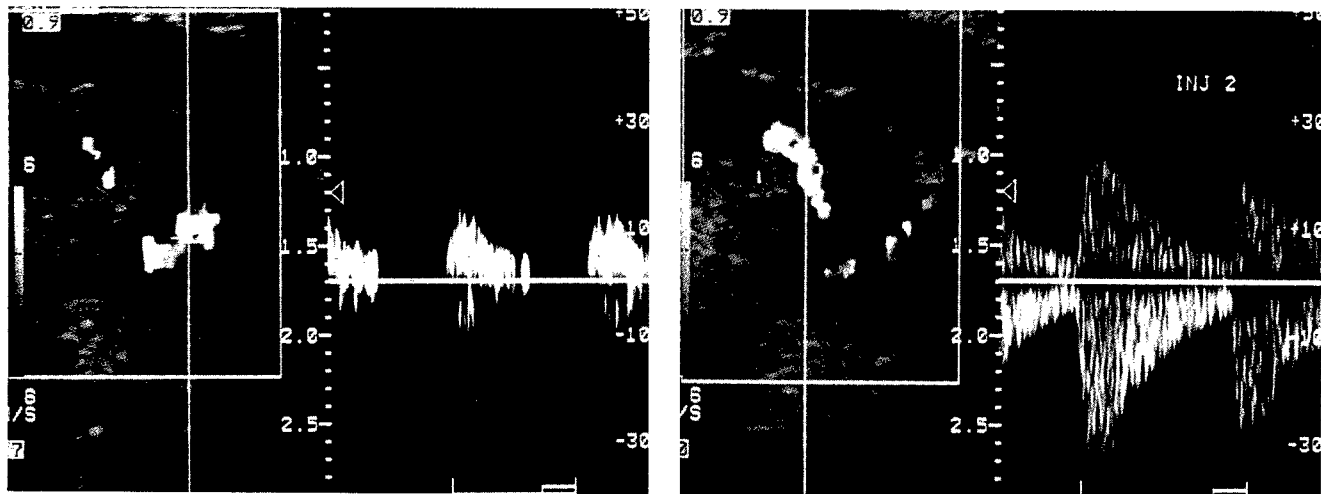
- Free air bubbles with limited duration
- One pass only

##### **Second generation**

- Marked vascular enhancement
- Prolonged duration

##### **Third generation**

- Parenchymal enhancement in humans
- Higher molecular weight gases



**Human fibroadenoma.** Before contrast injection (*left panel*), only two peripheral vessels are seen, and spectral Doppler tracing is relatively weak. After injection (*right panel*), a large vessel deep in the central part of the lesion enhances markedly, and the associated spectral waveform is easily measured.

In suboptimal Doppler ultrasound scans, a marked increase in diagnostic confidence is feasible after contrast administration, sometimes leading to a previously unobtainable firm diagnosis. In many cases, the need for more invasive procedures such as biopsy or angiography may be eliminated altogether.

these studies, enhancement of both color and spectral Doppler flow signals from intratumoral blood vessels was achieved. This is a significant result because tumor angiogenesis can be an independent marker of malignancy.

Malignant tumors less than 3 mm in diameter will stimulate the growth of new blood vessels by secreting angiogenesis factors. These blood vessels often develop anastomoses and shunts, which produce a chaotic angiogenic vasculature. The morphology of tumor vasculature may be an important criterion to evaluate, because the number and size of microvessels detected pathologically is an early and independent predictor of metastatic disease. Because of the small size of these vessels and their tortuosity, conventional Doppler ultrasound is not sufficiently sensitive to delineate them.

Lesion detection is the foremost problem in many types of carcinoma. For example, in the prostate, "blind" biopsies are often necessary, and in ovarian cancer, the high mortality rate is directly associated with the inability of diagnostic imaging to detect lesions at a sufficiently early stage. Direct visualization of focal liver lesions can be difficult, especially in patients with diffuse liver disease, because early-stage carcinoma may exhibit only minimal gray-scale abnormality.

Reported sensitivities for detection of hepatocellular carcinoma

with conventional ultrasound and CT vary widely, but even the combination of these two modalities has not exceeded 60% sensitivity for lesion detection and 80% for detection of hepatomas. The increased signal-to-noise ratio and, therefore, sensitivity of ultrasound imaging with the addition of a microbubble-based contrast agent should greatly increase the ability of physicians to identify small and inconspicuous liver neoplasms that were hitherto undetectable.

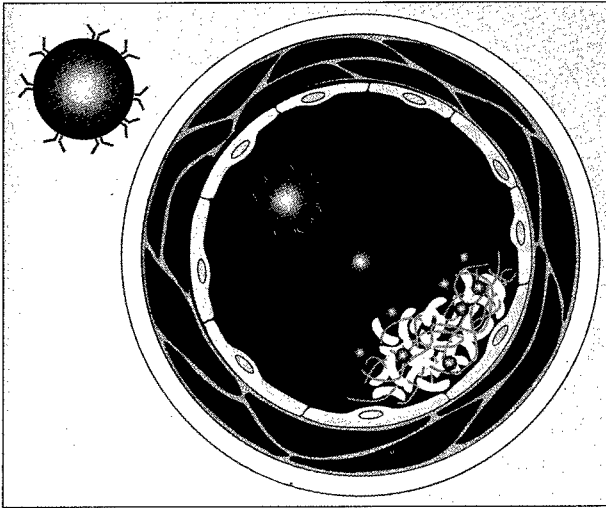
The next step after detection is lesion characterization and the ability to differentiate between benign and malignant masses. Characterization is the important diagnostic issue in many situations, such as when managing patients with breast tumors or renal masses. Likewise, once a lesion has been detected in, for example, the liver, it is of utmost importance to characterize the mass as either benign or malignant so that the correct treatment regimen can be selected. Studies of the uptake and washout of contrast over time are producing encouraging preliminary results in breast cancer patients, indicating that contrast kinetics may become important parameters in helping to distinguish benign from malignant tumors.

In an ultrasound contrast study of 34 breast tumors, investigators at the Royal Hammersmith Hospital in London under David Cosgrove found that tumor neovascu-

## Drug and Gene Delivery Using Contrast Microbubbles

Obviously, microbubbles can be filled with something other than a gas, and the prospect of using hollow microspheres as a highly specific drug delivery system is clearly attractive. Current research has demonstrated that the transported substance can be released locally and noninvasively simply by applying an external sound field to rupture the microspheres.

The DNA used in gene therapy would clearly be sensitive to enzymatic destruction by blood components if admini-



**Hollow microspheres** filled with a thrombolytic drug and coated with anti-fibrin antibodies would release the drug locally upon the application of an ultrasound pulse.

stered directly into the bloodstream. Instead, the genetic material could be protected by encapsulation in microspheres for subsequent release after intracellular uptake.

Such a strategy relies on targeted ultrasound contrast agents that are taken up at specific sites. Given the extensive knowledge now available on monoclonal antibodies, it is clearly possible to produce antibody-coated microbubbles that would be specific and sensitive for uptake at a wide range of pathological sites.

Currently, at least two agents that are taken up in the normal macrophages of the liver, spleen, and lymph nodes have been described at radiology conferences. These are SHU 563A, produced by Schering in Germany, and NC100-100, made by Nycomed Amersham in Oslo. These agents represent an important first step in the development of future drug delivery systems.

Evan Unger of the University of Arizona and ImaRx Pharmaceuticals recently described some encouraging results from his group's work on designing acoustically active drug carriers. While the efforts initially focused on thrombus therapy, Unger and associates also found that ultrasound increased gene expression after liposomal transfection in human cell lines.

As a next step toward using lipid-coated microbubbles as gene delivery agents, cationic liposomes were prepared from gaseous precursors. Unexpectedly, the rate of gene expression from transfection increased markedly, even compared to the ultrasound-enhanced results. It appears that the use of ultrasound and contrast agents may extend the role of clinical gene therapy significantly.

lar morphology, in particular the number of arterial-venous tumor vessel shunts seen after contrast injection, as well as contrast wash-out times were statistically significant in discriminating between malignant and benign lesions.

Uniquely, connections between adjacent vessels were demonstrated in all cancers after enhancement, presumably due to arteriovenous shunts. None of the benign lesions showed such connections, enabling a complete separation of malignant and benign tumors based on this feature. Two cases were reclassified from benign to malignant after administration of contrast and, likewise, two from malignant to benign. This increased the specificity and sensitiv-

ity of ultrasound imaging with contrast to 100%. The results are clearly influenced by the limited number of cases, but they indicate that vascular ultrasound contrast agents could have a major role to play in the future diagnosis of breast and other cancers.


**G**iven results such as these, our group at Thomas Jefferson University has begun a five-year breast cancer characterization study using ultrasound contrast. In this project, patients with breast lesions will be examined to evaluate whether the differentiation of benign from malignant masses detected by x-ray mammography can be improved by color Doppler or pulsed Doppler

### DIAGNOSES OF BREAST LESIONS BEFORE AND AFTER CONTRAST ADMINISTRATION

	Malignant	Benign
<b>Ultrasound:</b>		
Malignant	16	2
Benign	2	14
<b>With contrast:</b>		
Malignant	18	0
Benign	0	16

Modified from Rajendra Kadar et al., *Radiology* 198:679-686, March 1996.

**A three-dimensional ultrasound image** of a breast lesion. After contrast injection (*right panel*), both intratumoral and peripheral feeding vessels are seen. The central portion of the tumor is avascular.



with contrast enhancement. This is the first large-scale evaluation of the diagnostic potential of ultrasound contrast.

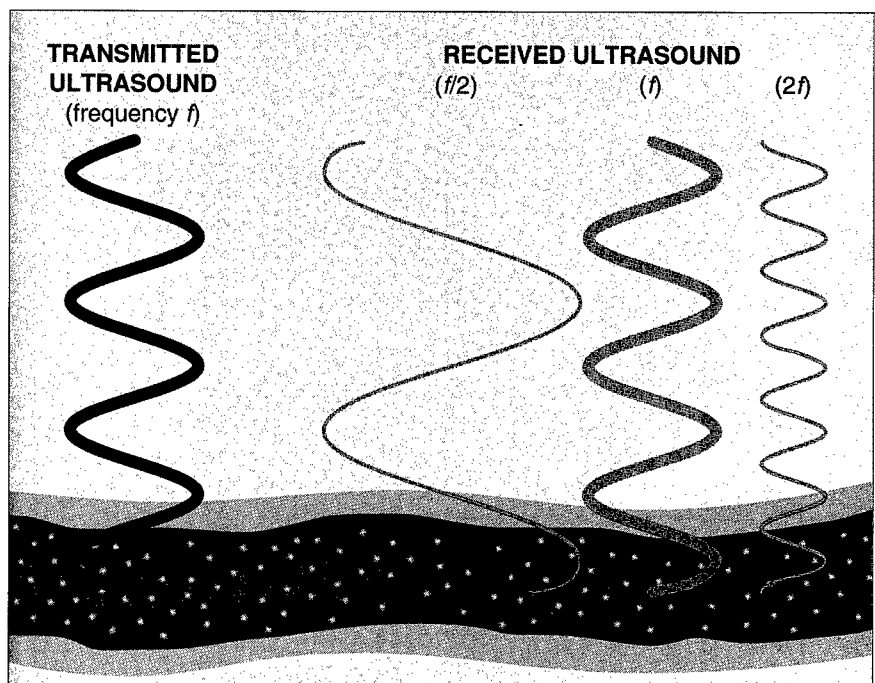
Another aspect, which is being investigated in a related project, is the use of contrast-enhanced three dimensional ultrasound imaging. Three-dimensional color Doppler appears better suited than two-dimensional ultrasound for demonstrating the vessel tortuosity associated with tumor neovascularity.

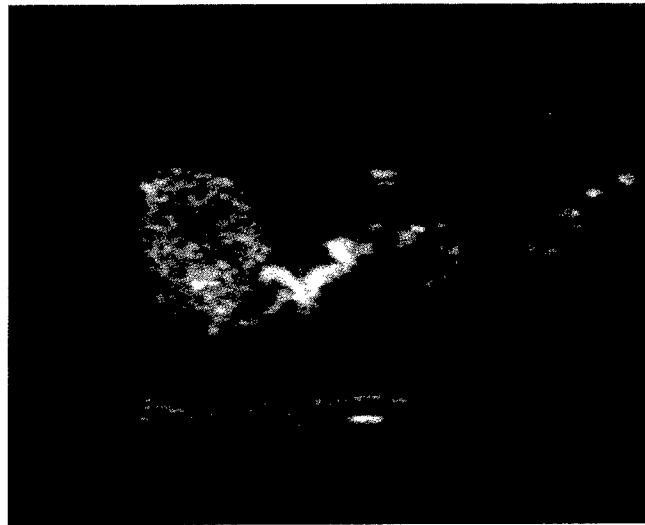
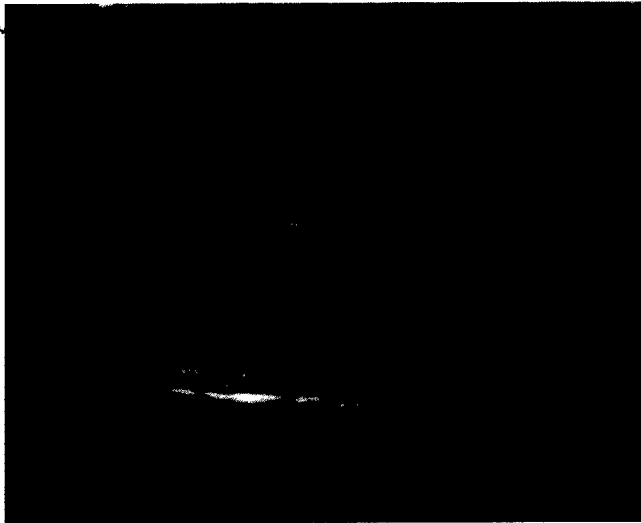
Color amplitude imaging, a new ultrasound technique that depicts vessels too small to be seen with color Doppler, provides an even better opportunity to improve on three-dimensional color Doppler displays. Color amplitude imaging shows the amplitude of the

Doppler ultrasound signal, whereas conventional color Doppler imaging depicts the mean Doppler frequency shifts. In color amplitude imaging, the signal-to-noise ratio is increased and aliasing is eliminated, making this technique well suited for three-dimensional reconstruction.

In a preliminary study conducted by William Lees at the Middlesex Hospital in London, three-dimensional color flow images were obtained from 40 patients with suspected prostate cancer. Half the images were in color amplitude mode and half were contrast-enhanced color Doppler images. The conclusion was that the three-dimensional color amplitude images without

**The principle of nonlinear contrast-specific imaging.** Microbubbles resonate when struck by incident pulses and produce echoes at subharmonic and harmonic frequencies as well as at the incident frequency. Ultimately, this technology has the potential to produce "contrast only" images, or in other words, an ultrasound angiogram.





**Harmonic imaging** can provide excellent depiction of tumor vascularity. Here, a naturally occurring woodchuck hepatocellular carcinoma is imaged in the so-called wideband harmonic gray-scale mode, initially without contrast (*upper left panel*). This is a variation of harmonic imaging that suppresses linear tissue signals more effectively.

The initial filling of the tumor feeding vessels with contrast is easily seen, including an overall uptake of agent within the tumor, which markedly improves lesion conspicuity (*upper right panel*). Over time, the contrast bubbles disappear from the hepatoma, but the echogenicity of the normal liver parenchyma is enhanced (*right panel*).

Studying the dynamics of contrast bubble kinetics suggests that harmonic imaging can be used to distinguish malignant from benign lesions. This assumes that human tumors and tissues will display enhancement differences similar to those shown in the woodchuck model illustrated here.



contrast were better. Contrast enhancement should further improve the advantage of color amplitude imaging, and this is supported by our preliminary results.


### **Harmonic Imaging and Tissue-Specific Agents Are Being Investigated**

Microbubble-based contrast agents produce marked enhancement of back-scattered ultrasound signals because the acoustic properties of a gas, namely its density and compressibility, are so different from those of blood and tissue. Moreover, when struck by incident ultrasound pulses, the microbubbles resonate, generating significant super- and sub-harmonics of the incident wave. This nonlinear

property is the basis for a contrast-specific ultrasound modality called harmonic imaging.

Images in harmonic mode are generated by transmitting sound pulses at one frequency but receiving echoes at twice that frequency (the second harmonic) or half that frequency (the subharmonic). Under optimal acoustic settings, the back-scattered signal from the contrast microbubbles at the second harmonic or subharmonic frequencies is much greater than that from tissue at those frequencies. In other words, the nonlinearity of the contrast agent produces "microbubble-only" images, which make it possible to detect slow, small-volume blood flow such as that associated with tumor neovascularity. This may even be possible deep in the abdomen in the pres-

**The principle of acoustic emission.** Contrast microbubbles (*purple*) are taken up by cells of the reticuloendothelial system (*green*). Application of acoustic energy pulses (*yellow*) ruptures the bubbles, causing random localized pressure waves and transient random phase shifts. Doppler imaging depicts the location of the contrast agent rather than its motion.



ence of much stronger tissue echoes, because harmonic and sub-harmonic imaging effectively eliminates parenchymal signals.

**E**xciting new clinical possibilities arise from tissue-specific ultrasound contrast agents, which have the potential to improve the assessment of certain organs by enhancing image contrast resolution through differential uptake. When injected into the blood, tissue-specific contrast agents are taken up by specific tissues, such as the reticuloendothelial system, or adhere to specific sites, such as a venous thrombus. By enhancing the acoustic difference between normal and abnormal regions over minutes or hours, these agents improve the detectability of abnormalities such as cancers.

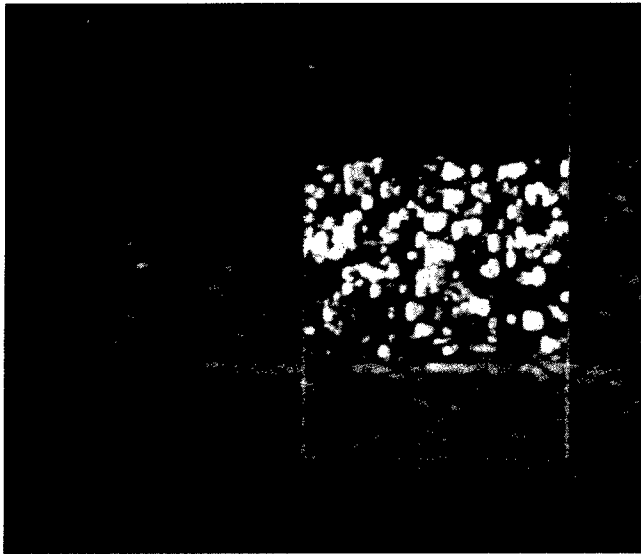
We have investigated one particular tissue-specific agent, Sono-vist, which consists of air-filled microbubbles protected by a biodegradable polymer shell. After being injected intravenously, this agent is phagocytosed by Kupffer cells of the liver and by macrophages of the spleen and lymph nodes.

In color Doppler imaging, the longer pulse lengths employed rel-

ative to gray-scale imaging, and therefore the increased acoustic energy, causes the microbubbles to oscillate and collapse. These collapses result in localized random pressure waves with transient random phase shifts being generated. The phase shifts are interpreted incorrectly by the autocorrelator as Doppler shifts, resulting in a random mosaic pattern of colors being displayed in regions containing Sono-vist.

This effect has been termed induced acoustic emission, and it constitutes a unique use of color Doppler imaging, all previous uses of which have been for the detection of motion (mainly blood flow within vessels). Acoustic emission does not rely on motion but rather on the location of contrast microbubbles.

The advantage of acoustic emission in cancer diagnosis occurs with masses that have destroyed normal liver cells, including the Kupffer cells, because these masses will be displayed as color-free areas, in effect a negative tumor image. Our initial work using induced hepatic tumors in rabbits has clearly demonstrated the ability of this effect to delineate tumors when the liver was scanned after a



15 to 30 minute delay, to allow for agent uptake by the reticuloendothelial system. Of 12 tumors found by pathology, four were detected by ultrasound alone and the remaining eight were seen after administration of contrast. Acoustic emission enabled detection of hepatic tumors as small as 3 mm in diameter. This achievement is unlikely to be repeated in humans because of increased signal attenuation at relevant tissue depths, but it is an encouraging result that merits further study.

**T**he benefits of contrast enhancement have long been realized in other imaging modalities such as CT and MRI. It now appears certain that ultrasound contrast agents with both Doppler and gray-scale capabilities will be available to physicians in the United States in the near future. They are likely to have a signifi-

cant impact on the diagnostic usefulness of ultrasound. The systemic echo enhancement provided by second and third generation agents should increase diagnostic confidence, especially in technically difficult cases with low signal-to-noise ratios. Moreover, contrast-specific imaging modalities such as harmonic imaging and induced acoustic emission promise to make completely new tools available for tumor diagnosis.

Estimates are that ultrasound procedures will benefit from contrast enhancement in 15% of cases when second generation agents are employed (Doppler enhancement only) and that this number will increase to 40% if gray-scale enhancement is available as well (third generation agents). In turn, these improvements may reduce the need for further diagnostic tests, and hence the cost of health care.

**Examples of induced acoustic emission.** *Left panel*, A color Doppler image of a gel phantom with stationary contrast microbubbles demonstrates the characteristic color pattern associated with bubble rupture. *Right panel*, An experimentally induced tumor measuring 8 x 10 mm in a rabbit, seen by color Doppler imaging approximately 20 minutes after injection of Sonovist. Because the tumor does not pick up the agent, it stands out as a "negative" region without color. The acoustic emission signals clearly delineate the tumor and its irregular margin.

#### RECENT REVIEWS

Barry B. Goldberg, Ji-Bin Liu, and Flemming Forsberg: Ultrasound contrast agents: A review. *Ultrasound in Medicine and Biology* 20:319-333, May 1994.

Laurence Needleman and Flemming Forsberg: Contrast agents in ultrasound. *Ultrasound Quarterly* 13:121-138, 1996.

Barry B. Goldberg (editor): *Ultrasound Contrast Agents*. London, Martin Dunitz Ltd., 1997.

#### ORIGINAL PAPERS

Gregory M. Lanza et al., *Circulation* 94:3334-3340, December 15, 1996. [A biotinylated perfluorocarbon emulsion contrast agent.]

Noel Weidner et al., *Journal of the National Cancer Institute* 84:1875-1887, December 16, 1992. [Tumor angiogenesis as an independent prognostic indicator of breast cancer.]

Beth A. Schrope and Vernon L. Newhouse, *Ultrasound in Medicine and Biology* 19:567-579, August 1993. [Second harmonic imaging.]

Flemming Forsberg et al., *Journal of Ultrasound in Medicine* 14:949-957, December 1995. [Vascular and parenchymal enhancement of tumors in animals.]

Rajendar P. Kedar et al., *Radiology* 198:679-686, March 1996. [Contrast agent evaluation of human breast masses.]

# A Is For . . .

## Homocysteine

**homocysteine** An amino acid intermediate in methionine metabolism, whose accumulation is an independent risk factor for vascular disease.

A link between deficiencies of B vitamins and vascular pathology was suggested shortly after World War II, when the development of a successful standardized diet first made the rhesus monkey a useful laboratory animal. Researchers at the University of California, San Francisco, found arteriosclerotic lesions in monkeys whose diets were deficient in pyridoxine, a form of vitamin B<sub>6</sub>.

Twenty years later, Kilmer S. McCully, then at Massachusetts General Hospital, studied the vascular lesions in two children who had died of homocystinuria, a rare inherited disorder of amino acid metabolism in which plasma levels of homocysteine are greatly elevated. He found that the lesions were similar whether the metabolic error was a deficiency in cystathionine synthase or an abnormality in cobalamin (B<sub>12</sub>) metabolism.

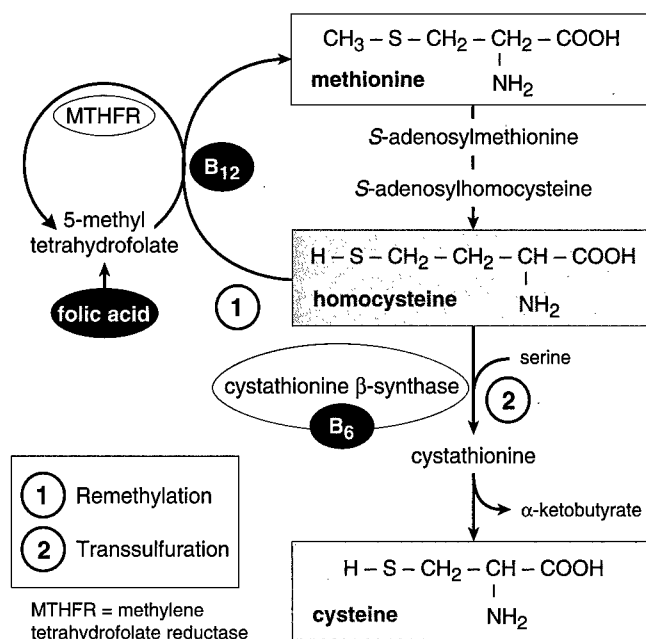
Suggesting that the accumulation of homocysteine might be to blame, McCully speculated on the possible significance of elevated homocysteine levels in people without the inborn enzyme defects. Subsequent attempts to produce experimental arteriosclerosis in rabbits by administering homocysteine compounds had equivocal results.

The amino acid cysteine is indispensable in proteins because its sulfhydryl group allows the formation of a disulfide bond with another cysteine. These covalent linkages help establish the shapes of proteins and in many instances connect two polypeptide chains to form a single molecule. Yet cysteine is not essential in the diet. Instead, it is formed by the metabolism of methionine, and homocysteine is an intermediate along this pathway. Homocysteine can also be remethylated back to methionine. In either case, B vitamins are required as cofactors in the enzymatic reactions.

Methionine in the diet is derived largely from animal protein, consumption of which is higher in societies that have more arteriosclerotic disease, so the possible connection between elevated homocysteine levels and vascular pathology was not completely ignored. With the tedious assay methods of the 1970's, however, studies were small and difficult to replicate. A reduced ability to metabolize homocysteine was reported in some patients with premature coronary artery disease and later in some patients with arteriosclerotic cerebrovascular disease.

Laboratory investigations disclosed that homocysteine could damage human endothelial cells, but only at much higher concentrations than are ever found in vivo. Homocysteine increases DNA synthesis in vascular smooth muscle cells, as occurs early in atherosclerosis, and also causes oxidation of low-density lipoprotein.

In body fluids, homocysteine is readily oxidized to a disulfide form, homocystine, or to a homocysteine-cysteine mixed disulfide. All three forms can be found free in plasma or bound to plasma proteins. When a rapid assay for total homocysteine was developed and larger numbers of people could be studied, it was found that the normal blood level



**Homocysteine** is either remethylated to methionine or transsulfurated to cysteine. Both reactions require B vitamins.

was about 10 μmol per liter. In the single enzyme defects that lead to homocystinuria, patients have blood levels of about 200 μmol per liter. Among patients with atherosclerosis, 20 to 30% are found to have total homocysteine levels between 20 and 40 μmol per liter.

At least seven specific autosomal recessive metabolic defects can cause homocystinuria. Heterozygotes or carriers for these disorders are not uncommon, but they cannot account for the observed population frequency of hyperhomocystinemia. In 1988, Soo-Sang Kang and colleagues at Rush-Presbyterian-St. Luke's Medical Center in Chicago discovered a variant form of methylenetetrahydrofolate reductase with about half the normal level of enzyme activity. The variant has been found in homozygous form in about 5% of the general population, in about 17% of patients with coronary artery disease, and in 28% of people with premature vascular disease and hyperhomocystinemia.

Elevated levels of total homocysteine associated with this enzyme variant can be reduced by administering folic acid, which circulates primarily as 5-methyltetrahydrofolate. Whether the response to folic acid is limited to these people is not known, and neither are the interactions between folic acid, B<sub>6</sub>, and B<sub>12</sub>. How homocysteine might induce vascular changes in vivo is unknown as well.

Carol J. Boushey et al.: A quantitative assessment of plasma homocysteine as a risk factor for vascular disease: Probable benefits of increasing folic acid intakes. *JAMA* 274:1049-1057, October 4, 1995.