

MAIN FILE

BR

RECORD
COPY

OTS: 60-41,646

JPRS: 5888

17 October 1960

CHANGES IN THE QRS COMPLEX IN
MYOCARDIAL INFARCTION

By T. E. Korenevskaya

- USSR -

DISTRIBUTION STATEMENT A
Approved for Public Release
Distribution Unlimited

RETURN TO MAIN FILE

Reproduced From
Best Available Copy

Distributed by:

OFFICE OF TECHNICAL SERVICES
U. S. DEPARTMENT OF COMMERCE
WASHINGTON 25, D. C.

~~Price: \$1.00~~

U. S. JOINT PUBLICATIONS RESEARCH SERVICE
1636 CONNECTICUT AVE., N. W.
WASHINGTON 25, D. C.

20000504 099

5888

CHANGES IN THE QRS COMPLEX IN MYOCARDIAL INFARCTION.

Following is the translation of an article by T.B. Korenevskaya entitled "Ob Izmenenii Kompleksa QRS Elektrokardiogrammy pri Infarkte Miodarda" (English version above) in Terapevticheskiy Arkhiv (Therapeutic Archives), Vol. 32, No. 5, Moscow, 1960, pages 53-66.]

From a group under the direction of Professor M.S. Vovsi, Active Member of the Academy of Medical Sciences USSR.

It is customarily considered that the signs of myocardial infarction in the initial portion of the ventricular complex are a reduction in the amplitude of the R wave and the appearance of Q waves or QS waves in the electrocardiographic leads located over the area of the necrotic focus. In the literature credence is given to the statement that changes in the QRS complex in myocardial infarction are brought about by tissue necrosis located under the "investigating" electrode and reflect a reduction in the electrical potential of this area up to the point where it completely disappears. At later periods after myocardial infarction in a number of patients an increase in the amplitude of the R wave and a reduction in the amplitude of the Q wave or a transformation of the QS wave

into a W-shaped QRS complex, in which a low R wave is seen between the Q and S waves, is seen in leads located over the necrotic focus.

Such electrocardiographic changes are usually considered evidence of a partial restoration of the electrical myocardial potential in the affected area. Therefore, for the purpose of evaluating the degree of expression of the lesion in myocardial infarction the amplitudes of the Q and R waves are compared in a lead located over the suspected infarction area.

We succeeded in determining another change in the QRS complex in myocardial infarction.

In all 108 patients with infarction during the acute period, which we observed, the occurrence of an S wave was noted in the left precordial leads, that is, in leads located at the peripheral portions of the necrotic focus. This sign was found both in extensive infarctions, in which the Q wave was found in the fifth and sixth chest leads of the electrocardiogram (47 patients) and in less diffuse infarcts, where the Q wave was seen in the third and fourth chest leads (15 patients) as well as in small-focus infarcts in the absence of a Q wave in the electrocardiogram (19 persons).

The appearance of an S wave in the left chest leads during the acute period was found also in those cases where

the infarction was localized simultaneously on the posterior and anterior walls (11 persons) and in infarcts of the posterior wall (16 persons).

The electrocardiographic changes during the acute period of myocardial infarction were noted both in the absence of cardiac insufficiency (72 out of 108) and in those cases where it was found beginning with the first few days of the disease (36 patients). Therefore, the appearance of an S wave in the left precordial leads during the acute period myocardial infarction was not customarily associated with cardiac insufficiency.

The S wave in the left precordial leads of the electrocardiogram during the acute period of the disease was noted both after the first infarct (92 patients) and after repeated infarctions (16 patients).

During the acute period of myocardial infarction a deep S wave was found in one, two or three left precordial leads, that is, in leads located over the periphery of the necrotic focus. In 89 patients it was seen in the fourth chest lead; in part of them this was in combination with an S wave in the fifth and sixth chest leads. In 100 patients the S wave was found in the fifth chest lead, sometimes in combination with an S wave in the fourth and fifth chest leads. In 79 persons the S wave was in the sixth chest lead; thereby, in part of them it was combined with the same

S wave in the fourth and fifth chest leads.

In patient V., age 52, an extensive myocardial infarction developed without preceding angina pectoris. On an electrocardiogram dated 3 February 1949 (Fig. 1,a) the QRS complex has the shape of a QS wave in the first three chest leads.

The S-T interval in these three leads was considerably elevated. In the fourth, fifth and sixth chest leads a deep S wave is seen; the S-T interval in the fourth chest lead is elevated; the T wave in the fifth and sixth chest leads is flattened.

After the infarction the patient developed anginal attacks. On the electrocardiogram dated 13 January 1950 (Fig. 1,b) the amplitude of the S waves in the left chest leads had decreased; otherwise, practically the same QRS complex changes remained which had been recorded during the acute period of the disease.

Seven years after the myocardial infarction the patient occasionally had anginal attacks. No cardiac insufficiency was noted. In an electrocardiogram dated 9 July 1956 (Fig. 1,c) the S wave had disappeared and the QRS complex had assumed the shape of a QR both in the left and right chest leads.

As is seen from these data, during the acute period of myocardial infarction a deep S wave was seen on the

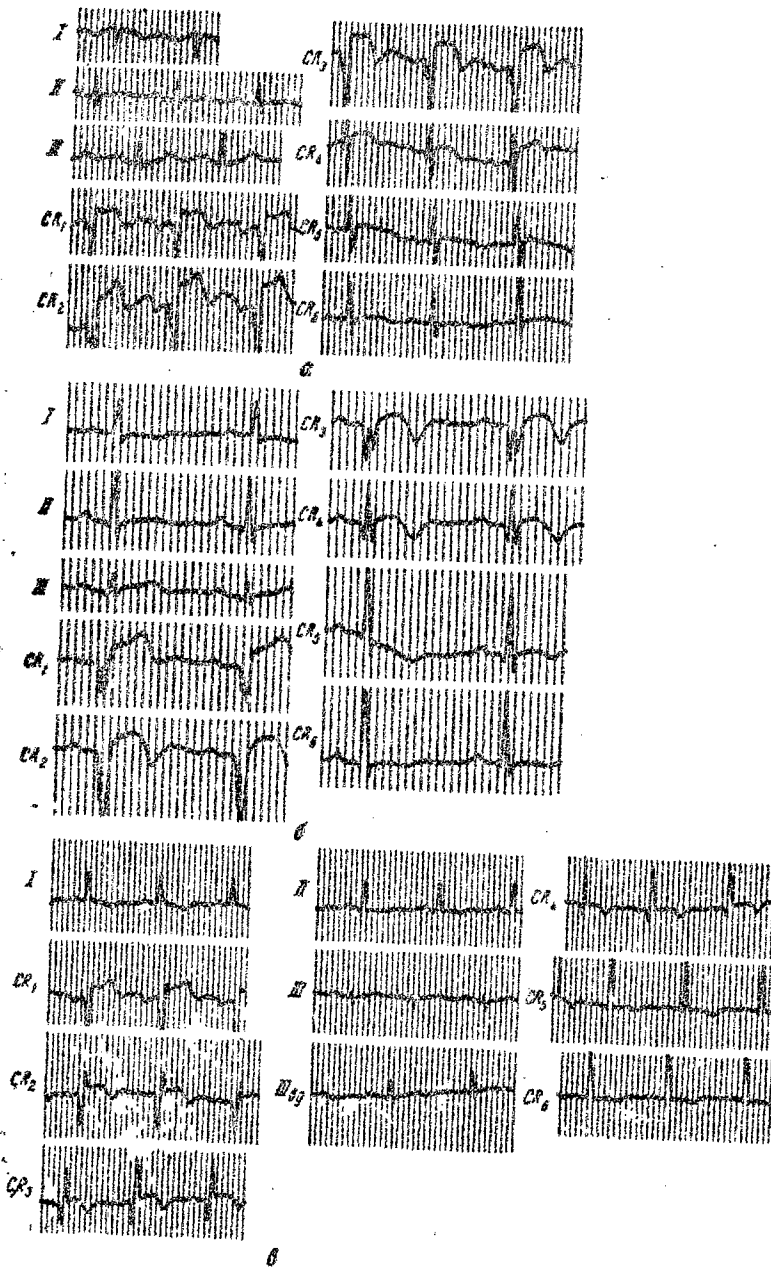


Fig. 1. Electrocardiograms of Patient V.

a--3 February 1949; b--13 January 1950; c--9 July 1956.

electrocardiogram in the left chest leads; a year after, the amplitude of this wave had decreased considerably, and seven years later the S wave had disappeared from these leads.

Patient P., age 35, had sustained a myocardial infarction of the anterior wall. On an electrocardiogram taken on the seventh day after the beginning of the disease, 6 June 1950 (Fig. 2,a) there was no R wave in the second chest lead; in the third, fourth and fifth chest leads a small Q wave was seen; in these leads a deep S wave was found. The T wave in all the chest leads was of a coronary type.

On an electrocardiogram dated 29 July 1950 (Fig. 2,b) the amplitude of the R wave had increased in the third and fourth chest leads, and the S wave had decreased; in the fifth and sixth chest leads the S wave had decreased considerably in size. The T wave in the first four chest leads was of the coronary type, and in the last two, it was flattened. Afterwards, angina on exercise persisted in the patient, but in February 1951 (Fig. 2,c) the electrocardiographic curve assumed almost a normal shape. In all three chest leads the R wave is clearly seen, although its amplitude in the second chest lead is smaller than in the first chest lead; the S wave in the fifth and sixth chest leads has disappeared, and in the fourth chest lead it has

decreased considerably in size.

An S wave was seen in this patient during the acute period of myocardial infarction in the left chest leads. After a month, its amplitude decreased, and after one and a half years it disappeared.

In recent years the attention of investigators has been attracted by the problem of "intermediate forms" between angina pectoris and myocardial infarction. Foreign authors--Zuckermann, Horn and others--use the term "læsion" for designating these conditions: Histological examination in these cases does not reveal any myocardial infarction but rather shows only small foci of necrosis, chiefly in the subendocardial layer. M.S. Vovsi, V.Ye. Fradkina, A.M. Tsyganova, Ye.A. Aleksandrova and M.M. Dodashvili, and G.K. Alekseyev have written about the clinical manifestations of this myocardial lesion.

We observed 19 patients with such small-focus lesions in the myocardium. In all of them, on electrocardiograms taken directly after the painful attack, the changes in the terminal portion of the ventricular complex were associated with the occurrence of an S wave in the left precordial leads, which in them was the only manifestation of pathology in the electrocardiographic ventricular complex.

Afterwards, in various periods of time--from several months to a year--the S wave disappeared; the S-T interval

became isoelectric, and the T wave became positive, that is, the electrocardiogram became normal.

The following observation may serve as an example of electrocardiographic changes in patients with small foci of necrosis in the myocardium.

Patient I., age 49. Following physical exertion signs of coronary insufficiency were noted for 30 days in the form of anginal attacks which occurred six to eight times a day both after walking and at rest.

On the first electrocardiogram (Fig. 3,a) taken during this period (4 October 1950) there was no Q wave in any of the chest leads, and a tall R wave was seen. In the third, fourth, fifth and sixth chest leads an S wave was seen the amplitude of which was maximal in the CR₃, CR₄ leads. In the CR₁, CR₂ leads the S-T interval was elevated; in the CR₃, CR₄ and CR₅ the altered T waves are seen.

After 30 days the attacks of angina stopped, and afterwards only occasionally (twice a month) did prolonged pains occur in the interscapular area which lasted many hours.

On the electrocardiogram dated 4 January 1951 (Fig. 3,b) the amplitude of the S wave in the third chest lead had decreased considerably, and in the fourth, fifth and sixth chest leads the S wave had almost disappeared. The great amplitude of the T wave in all the chest leads, attesting to a nutritional disturbance in the myocardium, attracts

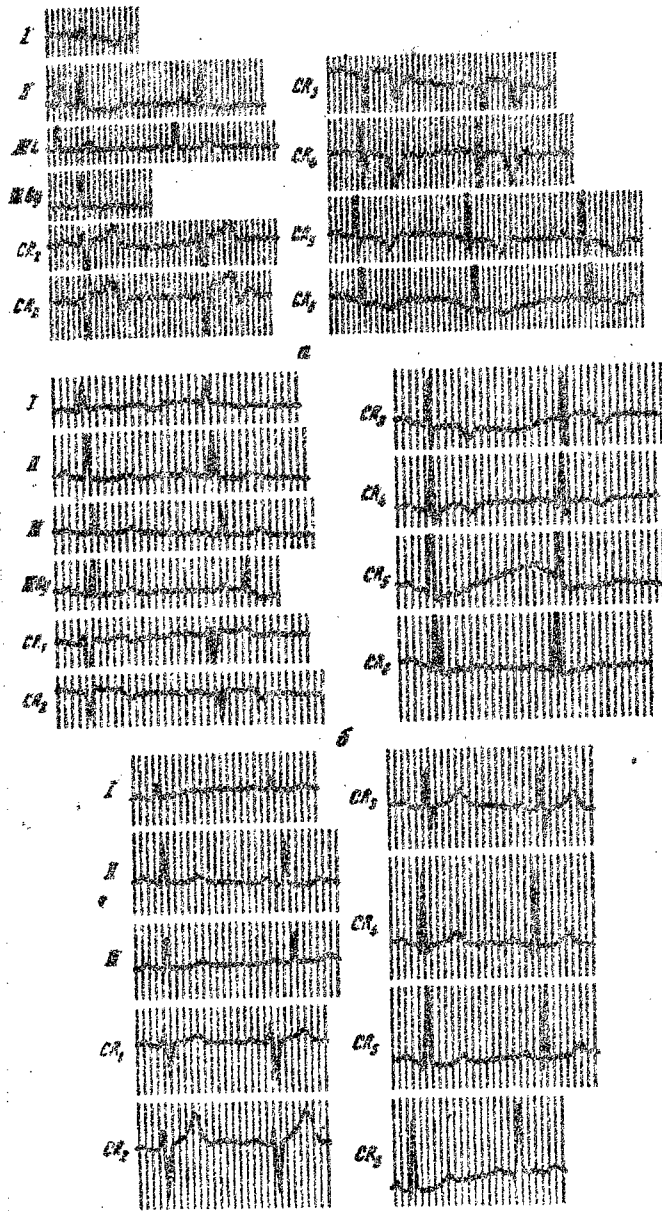


Fig. 2. Electrocardiograms of Patient P.

a--6 June 1950; b--29 July 1950; c--12 February 1951.

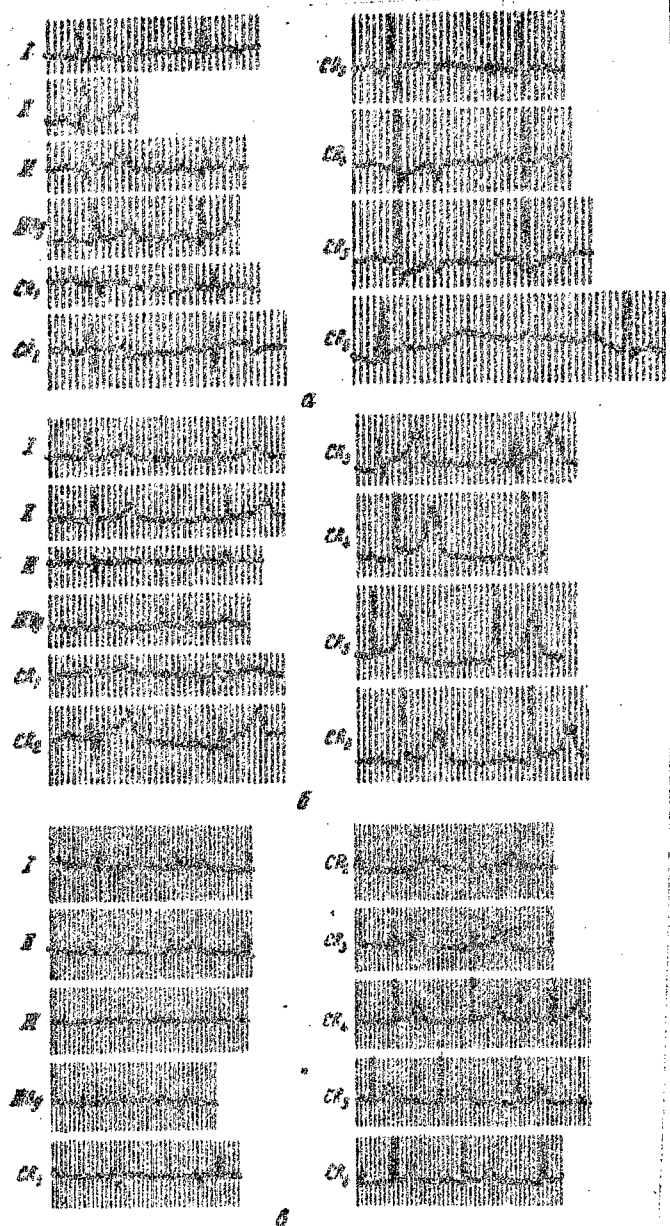


Fig. 3. Electrocardiograms of Patient M.
 a--4 October 1950; b--4 January 1951; c--18 June 1956

attention.

Afterwards, for a period of 10 years the patient did not have any anginal attacks, and prolonged pains in the interscapular area occurred only occasionally. On the electrocardiogram dated 18 June 1956 (Fig. 3,c) the QRS complex in the precordial leads showed no changes. The amplitude of the T waves had decreased.

Therefore, in a patient following attacks of pains in the heart an S wave appeared in the left chest leads on the electrocardiogram, which disappeared after three months. The changes in the S wave were not associated with any changes in the Q wave.

The data presented here show that in the case of small foci of necrosis in forms intermediate between angina pectoris and myocardial infarction, the appearance of an S wave on the electrocardiogram is pathognomonic for the diagnosis of a myocardial lesion.

Observing patients who have had a myocardial infarction we noted dynamic changes in the S wave.

In 83 patients (out of 108) the S wave either completely disappeared in the left chest leads or its disappearance in one or two of these leads was associated with a reduction of its amplitude in others. These changes were maintained throughout the first month after the occurrence of the infarction in eight patients; from one to six months, in 29

from six to twelve months, in 24; from one year to five years, in 17; and from six to ten years, in five persons. In ten patients only a considerable reduction in the amplitude of the S waves was noted in the left precordial leads. In 15 persons the S waves in the left precordial leads remained unchanged throughout the observation period.

These S wave dynamics were associated with various changes in other electrocardiographic elements. Thus, in 93 patients in whom the S wave had disappeared or decreased in size in the left precordial leads the Q wave in the same leads decreased or disappeared in 39; the Q wave was unchanged in 49 persons; the amplitude of the Q wave increased in five. Among these 93 patients the R wave appeared first in the left precordial leads instead of the previous QS complex in 12; the amplitude of the R wave in these leads increased in 34; the height of the R wave during the observation period did not change in 43; and the amplitude of the R wave decreased in four. The S-T interval in the left precordial leads became isoelectric (from being elevated above the isoelectric line or depressed below it) in 43 persons, was unchanged in 40, became elevated in two, and was depressed below the isoelectric line in eight. The T wave in the left precordial leads, following the disappearance of the S wave from them, became positive in 44, flattened in 21, unchanged in 24 and negative in four persons.

An analysis of our material shows that dynamic changes in the QRS complex in the majority of patients are found in leads taken from the area of the necrotic focus and its peripheral portions; however, they can appear also in other leads at some distance from the site of localization of the infarct.

The data presented here constitute evidence to the effect that scarring of the myocardial infarction is associated with very polymorphic dynamics in the Q, R, S, T waves and in the ST segment of the electrocardiogram. Because of this the use of dynamic observations is very difficult for solving problems associated with prognosis. At the same time, the impression has been created that the most constant electrocardiographic sign of anatomic healing of the necrotic focus is a disappearance of the S wave from the left precordial leads.

We have attempted to analyze the dynamic changes in the QRS complex in our patients in accordance with existing criteria for the prognostic evaluation of the electrocardiogram.

The disappearance or reduction in the amplitude of the S wave in 66 out of 93 patients coincided with the dynamic changes in the curve, which can be considered an improvement in the electrocardiographic data. These dynamics dealt either with all the waves and curve segments simultaneously

or with the QRS complex, ST segment and T wave individually or with various combinations of these three components. Here, simultaneously with the disappearance or reduction in the amplitude of the S wave the amplitude of the Q wave either decreased or disappeared, or the amplitude of the R wave increased, or the ST segment which had been elevated or depressed was displaced toward the isoelectric line, and the coronary T wave became flattened and positive, or various combinations of these changes were noted.

Such changes were seen both in the left and in the right chest leads. In 27 out of 93 patients the disappearance of the S wave or a reduction in its amplitude was associated with very polymorphic electrocardiographic dynamics, wherein favorable changes could be noted in some of the elements of the curve and unfavorable changes in others at the same time. Thus, in 10 patients a reduction in the amplitude of the S wave or a disappearance of it, a displacement of the elevated ST segment toward the isoelectric line and a conversion of the coronary T wave into a flattened or positive wave was associated with a reduction in the amplitude of the R wave or an increase in the amplitude of the Q wave which was seen in four patients in the right chest leads and in six patients in the left chest leads. In another six persons the disappearance of the S wave and favorable electrocardiographic dynamics of the QRS

complex and T wave were associated with a displacement of an ST segment, previously isoelectric, above or below the isoelectric line; this was noted in nine persons in the left precordial leads; in one person, in the right precordial leads.

In addition, in another seven patients, with disappearance or reduction in the size of the S wave, normalization of the QRS complex and displacement of the ST segment toward the isoelectric line, unfavorable changes in the T wave were noted which changed from positive to flattened or negative. Thereby, in four patients these changes in the T wave were seen simultaneously in the right and left chest leads of the electrocardiogram; in two, only in the left leads; in one, only in the right leads.

Therefore, in almost three-fourths of the cases following myocardial infarction the disappearance or reduction in the size of the S wave in the left precordial leads of the electrocardiogram was associated with changes in the curve, which can be considered signs of favorable dynamics. However, in approximately one-quarter of the cases a similar reduction in the amplitude of the S wave or disappearance of it was associated with unfavorable changes in the other elements of the curve.

In comparing the data of the electrocardiographic investigation with the nature and the degree of expression

of angina pectoris before and after the myocardial infarction it was made clear that even in those cases where the so-called "favorable dynamics" were associated with a change or reduction in the size of the S wave the clinical picture by far did not always improve.

Thus, among 66 patients whose electrocardiograms showed such favorable dynamics angina appeared for the first time in 26 during the postinfarction period; in five, there was an increase in the frequency of attacks of pain; in 23, the nature of the angina did not change, and only in 12 did the attacks stop (or there was no angina either before or after the infarction). In 16 persons during the acute period signs of cardiac insufficiency were noted.

In 25 patients the disappearance of the S wave in the left precordial leads coincided with the unfavorable electrocardiographic dynamics. In 11 of them the angina appeared for the first time after the infarction. In seven, the attacks increased in frequency; in five, the nature of the angina did not change, and only in two patients did its manifestations become less pronounced, but in both patients there were signs of cardiac insufficiency. In all, cardiac insufficiency occurred in seven persons among the 25 patients.

The data presented here show that the disappearance or decrease in the amplitude of the S wave in the left precordial

leads as well as the dynamic changes in the other elements of the tracing were noted with pronounced manifestations of angina, and for that reason they cannot be connected with the course of the pain syndrome.

In 15 out of 108 patients the S wave in the left precordial leads, which had appeared during the acute period of the disease, afterwards did not change. It should be noted that in the absence of dynamic changes of this wave the entire electrocardiographic tracing as a whole did not change usually. Thus, of these 15 patients the electrocardiograms remained unchanged in 13; in two, favorable dynamics were noted in the ST segment (in one) and in the T wave (in one) in the left precordial leads.

The S wave in the great majority of cases (13 out of 15) was unchanged in persons suffering from cardiac insufficiency beginning with the first few days of the disease and throughout the entire observation period. The course of the angina in patients of this group was no different from its course in people whose electrocardiograms showed the disappearance of the S wave or a reduction in its amplitude.

On the basis of what has been stated it seems to us permissible to regard the absence of dynamic changes in the entire electrocardiographic tracing as well as in the S wave in the left precordial leads following a myocardial

infarction as an unfavorable sign in the sense of development of cardiac insufficiency.

Observation of the patients showed that one to two years or later after the myocardial infarction, in the presence of an exacerbation of the angina pectoris (36 persons) or with the development of cardiac insufficiency (35 persons) an S wave appeared in the leads located at the periphery of the infarct, that is, the left precordial leads. In the left precordial leads the wave appeared at later periods both after the first myocardial infarction (64 persons) and after repeated infarctions (7 persons).

In 30 patients the electrocardiographic S wave in the left precordial leads was recorded in the acute period, and then again it appeared at later periods, which was associated with cardiac insufficiency in 11 persons, and in 19 persons, with an exacerbation of the angina pectoris. In another 41 patients the electrocardiographic sign noted appeared for the first time in the late period of the disease; in 24, it occurred in cardiac insufficiency; in 17, with an exacerbation of angina pectoris.

The appearance of the S wave in the left precordial leads of the electrocardiogram at late periods after the myocardial infarction as well as during the acute period was encountered with different locations and distributions of the lesion.

This electrocardiographic sign was noted in patients in whom the angina took on a more severe course following the infarction. In 36 persons severe angina pectoris was associated with cardiac insufficiency. In 24 patients following infarction it appeared for the first time; in 28, attacks of it increased in frequency; in eight, the nature of the angina remained unchanged; in five, it did not occur either before the infarction or in the postinfarction period; and in three patients after the infarction the angina disappeared.

The data presented here permit us to suppose that the appearance of an S wave in the left precordial leads of the electrocardiogram in the late period following myocardial infarction is an unfavorable prognostic syndrome attesting to a more severe course of the disease.

As an example of the appearance of an S wave in the left precordial leads of the electrocardiogram at the late stage of the course of myocardial infarction we should like to present a case history.

Patient B., age 66. Beginning with 1951 he began occasionally (once or twice a month) to have attacks of angina. Beginning with 1953, the attacks increased in frequency, up to two or three times a week and assumed the nature of angina of effort. In December 1955 there was an attack of severe pain in the chest, which lasted about 30

minutes. On the electrocardiogram dated 20 January 1956 (Fig. 4,a) a tall R wave was seen in all the precordial leads. The Q wave in these leads was not found, but the deep S wave attracts attention; this is seen not only in the right but also in the left (in the fifth and sixth) precordial leads. The T wave in all the precordial leads was deep and of the coronary type.

Until November, 1956 the patient's condition was satisfactory; the attacks of angina occurred very rarely; less often than before the infarction.

On an electrocardiogram taken 19 October 1956 (Fig. 4,b) the S wave in the fifth and sixth precordial leads disappeared; the T wave in the right precordial leads (V_1, V_2) became positive; in the left leads the waves of the coronary type remained. The only sign of infarction on this electrocardiogram is an absence of an R wave in the third precordial lead.

In December 1956, following pneumonia, the patient had a marked increase in dyspnea, and an attack of cardiac asthma occurred which was followed by circulatory insufficiency.

On the electrocardiogram dated 30 December 1956 (Fig. 4,c) in the fourth precordial lead the R wave has disappeared and in this lead a QS wave is seen. In the fifth and sixth precordial leads deep S waves have reappeared.

It may be supposed that a second myocardial infarction

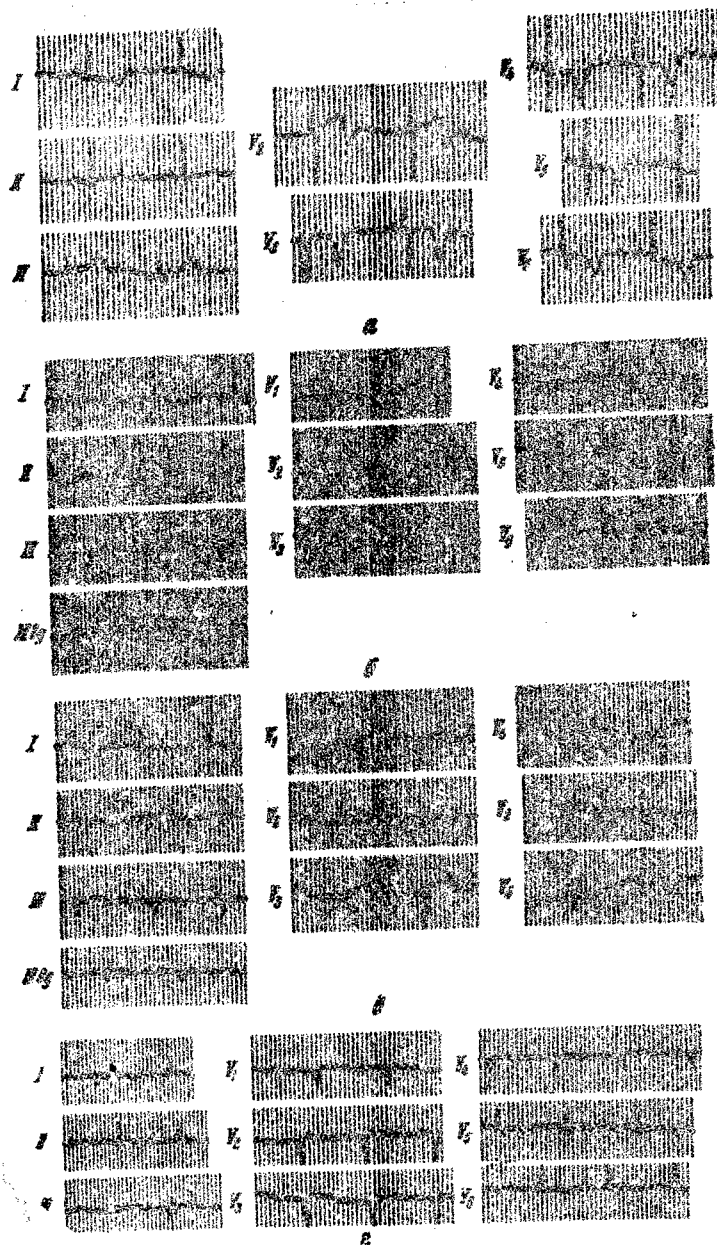


Fig. 4. Electrocardiograms of Patient B.

a--20 January 1956; b--19 October 1956; c--30 December 1956; d--16 November 1957.

developed in the patient on the anterior wall, which was expressed on the electrocardiogram as a disappearance of the R wave in the fourth precordial lead, the appearance of S waves in the fourth precordial lead, and the appearance of S waves in the fifth and sixth precordial leads.

From 1956 to October 1959 the patient was under our observation. He continued to have circulatory insufficiency the degree of expression of which decreased somewhat after the use of mersalyl and novurite. On the electrocardiogram (Fig. 4,d) the same changes remained which had been noted in December 1956, although the amplitude of the S waves in the fifth and sixth chest leads decreased periodically.

Therefore, in this patient, age 66, who had suffered for five years with angina pectoris, a myocardial infarction of the anterior wall developed. During the acute period the only pathology in the initial portion of the ventricular complex of the electrocardiogram was the appearance of deep S waves in the left precordial leads which were associated with a coronary T wave in all the precordial leads. Ten months after the infarction the S wave in the left precordial leads disappeared, and the QRS complex in these leads showed only a tall R wave. After 12 months, the patient developed a second infarction, which was again associated with the appearance of deep S waves in the left precordial leads of the electrocardiogram.

Afterwards, with the presence of cardiac insufficiency the amplitude of the S waves in the left precordial leads decreased, but they were distinctly demonstrated nevertheless.

A second appearance of the S wave in the left precordial leads of the electrocardiogram in those 30 patients in whom the tracing had already shown the appearance and disappearance of this wave during the acute period of the disease was associated with dynamic changes in the other waves and segments of the electrocardiographic tracing.

These changes were of a very polymorphic nature. Thus in four patients, with the second appearance of an S wave in the left precordial leads, there simultaneously appeared a Q wave in the same leads. In one patient, the amplitude of the Q wave increased; in three patients, it decreased considerably; and in 22, the Q wave was unchanged.

In 16 patients a second appearance of an S wave in the left precordial leads of the electrocardiogram coincided with the reduction in the R wave amplitude in the same leads; in 14, the R wave remained unchanged.

Even more polymorphic dynamics were noted with the second appearance of the S wave in the final portion of the ventricular complex in the same leads. Thus, in four persons the S-T interval became isoelectric, and ⁱⁿ six, it was elevated or depressed; in 20, it was unchanged. The

T wave became positive in three; flattened in 11; negative in six; and did not change in ten patients.

We attempted to analyze the dynamic changes in the electrocardiogram noted which were associated with the second appearance of an S wave in the left precordial leads in accordance with the existing prognostic evaluation of the dynamic changes in the tracing which we mentioned above.

Although in all 30 patients a second appearance of the S wave in the left precordial leads coincided with an exacerbation of the angina pectoris or the appearance of cardiac insufficiency, this electrocardiographic sign was associated with other changes in the tracing, which could be evaluated as unfavorable, in only ten persons. These changes in six persons were seen in both the left and right precordial leads; in four persons, only in the left. In five patients a second appearance of the S wave in the left precordial leads of the electrocardiogram was unassociated with dynamic changes in the electrocardiogram.

In 15 patients the repeat occurrence of the S wave in the left precordial leads was associated with very diverse changes in the other electrocardiographic components which could be considered favorable in some leads and simultaneously unfavorable in others; even in the same lead the initial and terminal portions of the ventricular complex not uncommonly showed dynamics of different kinds.

Thus, the appearance of the S wave in the left precordial leads was associated with an increase in the amplitude of the Q wave and the reduction in the amplitude of the R wave, wherein, as is well known, unfavorable dynamics are expressed; however, at the same time in the same leads the elevated ST segment was displaced toward the isoelectric line, or the coronary T wave was converted into a flattened or positive T.

As the data presented here show, the appearance of an S wave in the left precordial leads of the electrocardiogram in the late periods after the myocardial infarction is always associated with unfavorable changes in the course of the disease (the occurrence of cardiac insufficiency or an exacerbation of the pain syndrome), but hereby the curve undergoes various changes which can erroneously be taken as signs of normalization of the electrocardiogram.

We gained the impression that the appearance of the S wave in the left precordial leads at late periods after the infarction is a more reliable criterion, speaking for an unfavorable prognosis of the disease, than the unfavorable dynamic changes in the other waves and segments of the electrocardiogram.

We observed patients who had sustained a myocardial infarction for a very long time (more than 10 years).

An analysis of the electrocardiograms of these patients

showed that with the later appearance of the S wave in the left precordial leads a reduction in the amplitude or disappearance of this wave is encountered much less often. In 50 out of 71 patients we did not find any S wave dynamics, although after the appearance of this sign in them they were under our observation for a very long time. In 48 persons the absence of S wave changes in the left precordial leads coincided with their absence in the other waves and segments of these leads. In two persons, in whom the wave in the left precordial leads did not change, changes were noted in the S-T segment (displacement from the isoelectric position to above the isoelectric line) and of the T wave (conversion from flattened to negative). In 30 out of 50 patients there was a cardiac insufficiency which was almost of a permanent nature. In 15, the angina appeared for the first time after the myocardial infarction, and in 28 the attacks of pain were of a more overt nature.

In 13 out of 71 patients, even with the appearance of the S wave in the left precordial leads at later periods, it afterwards disappeared, or its amplitude decreased.

This S wave change in the left precordial leads of three persons remained for a year after the infarction; in four, from one year to five years; in six, from five to ten years. Just as during the acute period of myocardial infarction, the disappearance of the S wave was associated

with very polymorphic dynamics of the other electrocardiographic elements both in the left and right chest leads. In ten persons these changes could be considered favorable; in three, unfavorable in some leads and favorable in others.

The clinical course of the pain syndrome of these 13 patients did not show any distinct correlation with the dynamics of the electrocardiographic change. In six persons the angina appeared for the first time after the myocardial infarction; in one, its course became more severe; in three, its nature did not change; in one, the attacks of angina began to occur less often than before the infarction; in one, the angina stopped after the infarction; and in one patient it did not occur either before or after the infarction.

With respect to eight persons we did not have any information at our disposal concerning the dynamics in the S wave changes which appeared in the left precordial leads at the late periods after myocardial infarction.

The data presented here show that in 30 out of 50 patients, just as in the acute period of the disease, the absence of S wave changes in the left precordial leads coincided with the development of a persistent cardiac insufficiency.

In the literature available to us we have not found any studies indicating the appearance of an S wave in the

electrocardiographic leads from the peripheral portions of the myocardial infarct. However, for the purpose of explaining the electrocardiographic sign noted data given by Bayley concerning the electrophysiological myocardial changes in infarction can be used in our opinion.

The S wave apparently reflects the potential of the unaffected portions of the myocardium; demonstration of it becomes possible because of the reduction in the electrical potential of the tissue located at the periphery of the area of infarction. Disappearance of this wave as well as of the Q wave and the increase in the amplitude of the R wave does not necessarily speak for the restoration of the electrical potential at the periphery of the necrotic focus, but may be produced by scarring of the infarct.

Therefore, the same changes in the electrocardiogram in myocardial infarction may be of different significance. They depend not only on the presence of an area of dead muscle cells in the myocardium but also, to a considerable degree, are conditioned by associated disturbances during the course of the excitation and recovery process in the myocardium, which in turn depend on the presence of cicatricial changes at the periphery of the infarct focus and on the degree of expression of the myocardial fibrotic process, and on the metabolism of the cardiac muscle as a whole.

The degree of influence of each of these factors separately on the electrocardiographic tracing may be predicted and taken into consideration, but in far from all the cases. Therefore, in considering the course of the post-infarction period according to electrocardiographic data the dynamics of the changes should be evaluated beginning with the acute period of the disease. In addition, one should have an exceptionally cautious approach to "improvement of the electrocardiographic indices"--to an increase in the amplitude of the R wave and a disappearance in the Q wave, particularly in those cases where they are not associated with clinical improvement.

Conclusions

1. In 108 patients during the acute period of myocardial infarction, along with characteristic changes in the QRS complex in the electrocardiographic leads over the area of infarction, the appearance of an S wave was noted in the left precordial leads, that is, in the leads located over the peripheral portions of the infarct.
2. In 93 out of 108 patients in the postinfarction period the S wave disappeared or its amplitude decreased.
3. Disappearance of the S wave or decrease in its amplitude in the majority of cases was noted in patients who did not suffer from cardiac insufficiency. The absence of any changes in the S wave in the majority of patients was

associated with the absence of dynamic changes in the entire electrocardiographic tracing as a whole and was encountered in persons who had suffered from cardiac insufficiency.

4. During the acute period of the disease the dynamic changes in the S wave were not connected with the anginal syndrome. At later periods after the infarction, with an exacerbation of the angina and the development of cardiac insufficiency in 71 patients, the S wave appeared in the left precordial leads.

5. With the occurrence of an S wave in the left precordial leads at later periods it did not change in 50 patients; it decreased in size and disappeared in only 13.

6. Just as in the acute period of the disease the absence of any changes in the S wave in the left precordial leads coincided, in the majority of cases, with a more severe course of the disease.

7. The appearance of an S wave in the left precordial leads without any subsequent changes, noted both during the acute period of the disease and at the late stage, is apparently an unfavorable prognostic sign.

Bibliography

1. Alekseyev G.K. Ter. arkh. [Therapeutic Archives], 1959, No. 2, page 60.
2. Vovsi M.S. Opus cit, 1957, No. 1, page 19.
3. Fradkina V.Ye. Proceedings of the First All-Russian

Congress of Internists. Moscow, 1958, page 115.

4. Tsyganova A.M., Aleksandrova Ye.A., Dodashvili M.I.
in the book: "Angina Pectoris and Myocardial
Infarction". Moscow, 1959, page 126.
5. Bayley R.H. Am. Heart J., 1942, Vol. 24, page 514.
6. Horn H., Opus cit., 1950, Vol. 40, page 63.
7. Zuckermann R., Grundriss und Atlas der Elektrokardiographie.
Leipzig, 1957.

Received 23 September 1959

1288

END

FOR REASONS OF SPEED AND ECONOMY
THIS REPORT HAS BEEN REPRODUCED
ELECTRONICALLY DIRECTLY FROM OUR
CONTRACTOR'S TYPESCRIPT

THIS PUBLICATION WAS PREPARED UNDER CONTRACT TO THE
UNITED STATES JOINT PUBLICATIONS RESEARCH SERVICE
A FEDERAL GOVERNMENT ORGANIZATION ESTABLISHED
TO SERVICE THE TRANSLATION AND RESEARCH NEEDS
OF THE VARIOUS GOVERNMENT DEPARTMENTS