

OTS: 60-41,392

JPRS: 5590

20 September 1960

PHYSIOLOGICAL BASES AND RESULTS OF THERAPY OF CHRONIC
CORONARY INSUFFICIENCY WITH THE AID OF BILATERAL
LIGATION OF THE INTERNAL MAMMARY ARTERY

By V. I. Kolesov

- U S S R -

20000621 071

REPRODUCED FROM BEST AVAILABLE COPY FILE

Distributed by:

OFFICE OF TECHNICAL SERVICES
U. S. DEPARTMENT OF COMMERCE
WASHINGTON 25, D. C.

U. S. JOINT PUBLICATIONS RESEARCH SERVICE
205 EAST 42nd STREET, SUITE 300
NEW YORK 17, N. Y.

DISTRIBUTION STATEMENT A
Approved for Public Release
Distribution Unlimited

**Reproduced From
Best Available Copy**

JPRS: 5590

CSO: 4595-N

PHYSIOLOGICAL BASES AND RESULTS OF THERAPY OF CHRONIC
CORONARY INSUFFICIENCY WITH THE AID OF BILATE-
RAL LIGATION OF THE INTERNAL MAMMARY ARTERY

[Following is the translation of an article
by V. I. Kolesov entitled "Fiziologicheskiye
Obosnovaniya i Rezul'taty Lecheniya Khroniches-
koy Koronarnoy Nedostatochnosti pri Pomoshchi
Dvustoronney Perevyazki Vnutrenney Grudnoy Ar-
terii" (English version above) in Klinicheskaya
Meditsina (Clinical Medicine), Vol. XLI, No.
6, Moscow, 1960, pages 71-76.]

Presented to the Moscow Surgical Society on 25 Septem-
ber 1959.

The Department of Faculty Surgery (Director - Prof. V. I.
Kolesov) and the Department of Hospital Therapy (Director -
Prof. P. K. Bulatov) of the First Leningrad Medical Insti-
tute imeni Academician I. P. Pavlov

At the present time a number of surgical operations are
recommended for the treatment of chronic coronary insufficiency:
sympathectomy, removal of the stellate ganglion, suturing of
neighboring organs and tissues to the surface of the heart, cre-
ation of an aseptic adhesive pericarditis, abdominization of the
heart, and so forth. However, in advanced cases these operations
entail a certain risk and, because of this, are not much used.
Moreover, some of the above-delineated surgical interventions

disrupt the normal physiologic conditions of activity of the heart, which is especially undesirable.

Of the numerous surgical methods of treating angina pectoris, we use bilateral ligation of the internal mammary artery (the Hieski operation, 1939). Particular attention was drawn to this operation by Battezzati and associates, who published successful clinical cases (1955). Of foreign works published recently, attention is merited by the article of Glover (1957) and his coauthors and the newest publications of Battezzati (1959), in whose most recent work data were published on 304 operative cases (1959).

In the Soviet Union we were the first to perform the operation of ligating the internal mammary arteries in angina pectoris and were also the first to publish articles on this subject, in which we present both the immediate and long-term results of treatment of patients, as well as ECG data. The articles of B.V. Petrovskiy and associates, B.K. Osipov, A.A. Busalov were written and published after our work.

The operation of bilateral internal mammary artery ligation is based on the collateral vascular connections between this vessel and the myocardium. After ligation of the artery at the level of the second or third intercostal space, the arterial pressure proximal to the ligature increases by ten to 15 mm Hg. The blood flow from the proximal part of the artery passes through the pericardiophrenic artery to the vessels of the pericardium and partially reaches the myocardium.

Improvement of the collateral blood supply of the myocardium following ligation of the internal mammary arteries has been demonstrated by the experiments of an associate of our clinic, A. J. Trevina.

In dogs, in one series of experiments, the left descending coronary artery was ligated; in another series of experiments, both internal mammary arteries were first ligated and, after an interval of time, the left descending coronary artery was ligated. It turned out that, in the first series of experiments six of eight dogs died, whereas in the second series only three of 12 died. Consequently, in acute coronary insufficiency animals survive better following preliminary ligation of the internal mammary arteries. This fact may be explained by the development of collateral circulation to the myocardium due to the ligation of the internal mammary arteries.

By now we have operated on 180 patients with chronic coronary insufficiency. In this article we shall discuss the results of treatment of only 110 of those patients, with dates of subsequent observation ranging from four months to two years. All patients were subjected to bilateral ligation of the internal mammary arteries. There were 79 men and 31 women. The age groups of the patients were as follows: from 42 to 50, 32 patients; from 51 to 60, 53 patients; from 61 to 70, 25 patients. The majority of patients were sufferers of some duration (three to nine years) and in 19 the condition had lasted for more than ten years, i.e. a duration which, in the opinion of some surgeons, is incompatible

with successful surgical treatment. Of 110 patients, only 40 were capable even of light work; the majority (70 of the 110) were invalids and incapable of any work.

Almost half of the patients (52 of the 110) had suffered myocardial infarction, and ten had had repeated (two or three) infarctions. Hypertension was seen in 39 patients, circulatory disturbance of stage I in five, and of stage II in six. In two patients, in addition to angina, there were frequent attacks of paroxysmal tachycardia, and in two there was evidence of cardiac asthma.

Hence, all of our patients suffered severe atherosclerotic cardiosclerosis, often with the presence of myocardial infarction in the history, circulatory failure, and associated hypertension.

The most seriously ill patients, who constituted almost half of our operative series, had suffered for many years with angina pectoris. Attacks occurred eight to ten times a day in these people and lasted sometimes as long as an hour and a half. Most of the time these patients were confined to bed and were unable to care for themselves. In this group almost half of the patients used narcotics to relieve pain. More than 20 patients in this group of seriously ill had been hospitalized repeatedly in the therapeutic clinic. All means of conservative therapy had been exhausted, since these had either been ineffective or had led to only a transient improvement in the clinical state.

The second group of patients had coronary atherosclerosis without myocardial infarction in the history. These patients

had suffered angina pectoris for periods of three to five years. Attacks in them often occurred daily and lasted for 20 to 30 minutes. The majority of these patients also had been hospitalized in the therapeutic clinic or else were treated on an ambulatory basis. All means of conservative therapy had failed to produce lasting positive results.

In the majority of the operated patients, only ligation of the internal mammary arteries was attempted. No operations associated with opening of the pericardium or, much less, with incision into the pleural or peritoneal cavities are included in this series.

In all patients operated upon by us, bilateral internal mammary artery ligation was carried out under local anesthesia. The level of ligation was the second or third intercostal space. Sufficient access was gained to both arteries from a single incision ten to 12 cm in length, which was the form of a slightly curved arc (convex downward) passing transversely across the mediastinum and continuing to the other side into the corresponding intercostal space. After incising the skin and subcutaneous tissues and ligating the external mammary arteries, we used blunt dissection to free up the pectoralis major muscle slightly from the chest. The intercostal muscles were carefully dissected with small scissors, with care being taken not to enter the pleural cavity lying near them. At a distance of about one cm from the edge of the sternum, we incised the fascia and beneath it, in the fatty tissues, exposed the mammary arteries with the

accompanying veins. A ligature was passed under each artery and, in the narrow interchondral space, the vessels were freed up for a short distance. Then two ligatures were applied, a short distance from each other. The vessels were then transected near the upper ligature. The same procedure was carried out on both sides. The incision was then closed without drainage.

Although ligation of the intercostal mammary arteries is well tolerated by even the most seriously ill, it should be carried out with particular care, ^{given} to anesthesia and with appropriate psychological preparation of the patient. Under the influence of anxiety, an attack of angina may be induced in such patients. Poor anesthesia and absence of contact with the patient may be conducive to an attack of angina at the time of operation. The best influence which can be exerted on patients awaiting operation is that of patients previously operated upon. The disappearance of anginal attacks in them and discontinuation of the need for nitro-glycerin and narcotics is the strongest form of persuasion.

In the postoperative period it is necessary to ensure rest for the patient, to observe him carefully, and to meet all the requirements of a careful supportive regimen.

The immediate results of operation, upon observation of patients up to two months after operation, are characterized in the following way. Attacks of angina ceased completely in 56 patients, became less frequent in 45, and were unchanged in 11.

In all operated patients, the ECG prior to operation showed marked chronic coronary insufficiency (Ya.A. Vishnevskaya and Ye.

Ya. Tsololikhina, Ye. M. Ar'yeva). Patients with complaints of pain in the heart region against a background of functional disturbances but without obvious ECG changes of chronic coronary insufficiency were not advised to have operations.

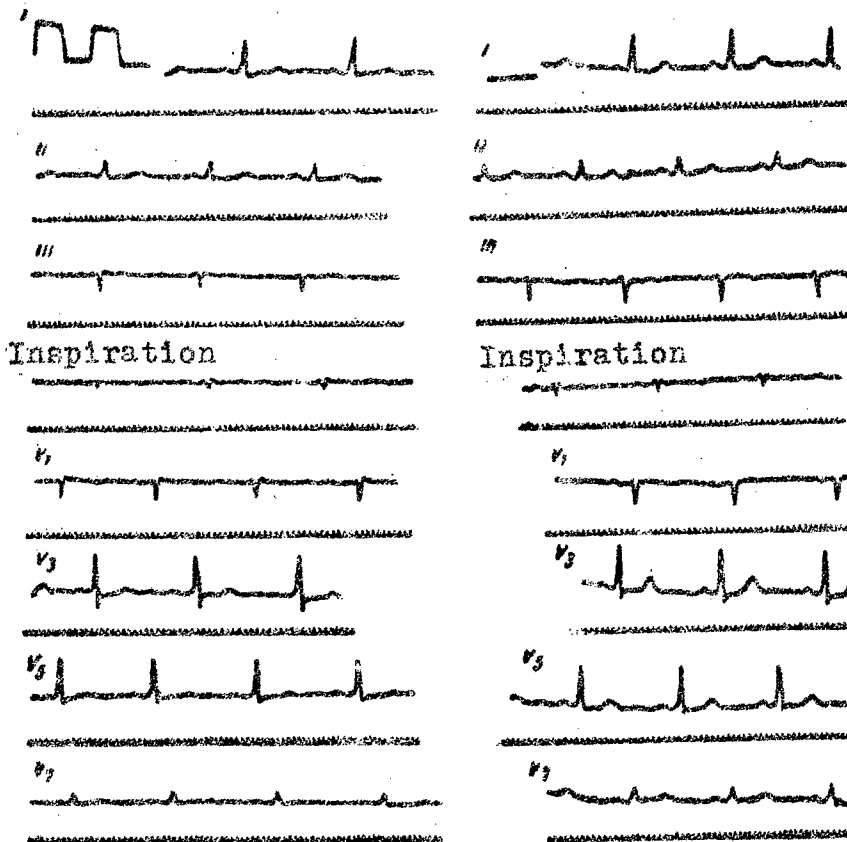


Fig. 1. Electrocardiogram of patient Z.

- a) prior to bilateral ligation of the internal mammary arteries;
- b) five and one-half months after operation.

ECG studies showed that, during the first days after operation

tion, the indices of the ECG improved in 40 patients, did not change in 68, and deteriorated slightly in two (progressive signs of chronic coronary insufficiency). Hence, in a significant number of patients, there was not only disappearance of anginal attacks after operation, but also an improvement in the degree of coronary insufficiency as recorded on the ECG, which is very valuable in the appraisal of the immediate results of treatment.

The long-term results of treatment were studied in 110 patients. The dates of follow-up observation ranged from four months to two years. During this period attacks of angina did not recur in 42 patients, were much less frequent in 48 (in addition to being less prolonged and less severe, despite relaxation of the strict regimen), and showed no substantial changes in 20 patients.

Of great importance are the findings of ECG investigation of patients at remote dates after operation. A distinct improvement in the ECG pattern was seen in 47 patients.

Let us cite two cases.

Patient Z., 65 years old. In 1946, with physical exertion, this patient began to experience transitory pains in the left chest; then the pains became more frequent and severe. Since 1957 the patient had noted severe pains appearing several times a day not only when she was active but also at rest, radiating into the left arm and hand and into the scapula. Signs of cardiac insufficiency began to develop. The patient was treated twice in the therapeutic clinic. The use of nitroglycerin and

validol, as well as repeated intracutaneous blockade, provided no improvement. Subsequently the patient became incapacitated for even the lightest work and was compelled to stay in bed for the greater part of the day.

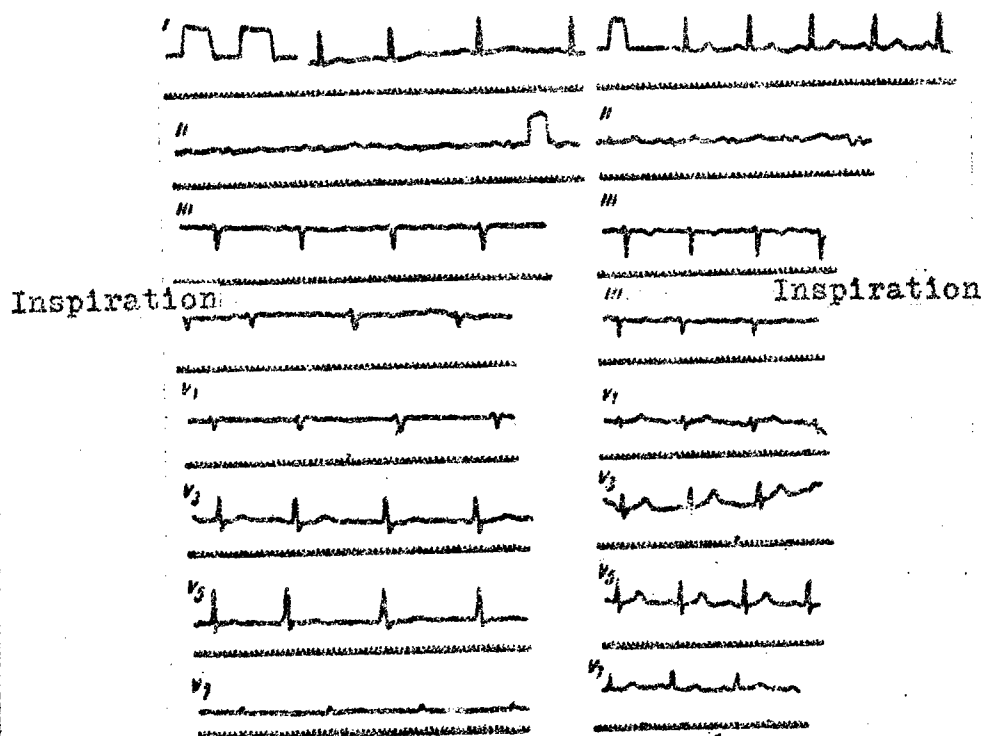


Fig. 2. Electrocardiogram of patient O.

a) Prior to bilateral ligation of the internal mammary arteries;

b) two months after operation.

Nutritional status was good. There was slight cyanosis of the lips. Heart rate was 70 per minute, and regular; the blood pressure was 180/100 mm Hg; the heart sounds were not sharp, and A2 was greater than P2.

The ECG prior to operation on 19 September 1958 (Fig.1,a) showed deviation of the electrical axis of the QRS to the left, and a horizontal electrical position of the heart; T_1 was positive but low, and T_V was scarcely positive. The S-T_{1,V3-5} was slightly below the isoelectric line. Diagnosis: hypertrophy of the left ventricle, coronary insufficiency in the area supplied by the left coronary artery.

On 24 September we ligated the internal mammary arteries. Attacks of angina ceased. The patient was released from the clinic on the 12th postoperative day.

Five and one-half months after operation, the patient's condition was still good. Attacks of angina had not recurred. The patient was able to carry out her domestic duties.

ECG on 6 March 1959 (Fig.1,b) showed the $T_1,V2-7$ waves to be distinctly positive. Conclusion was that there was no further evidence of coronary insufficiency.

Patient O., 53 years old. This patient had experienced anginal attacks for three years. Attacks of pain occurred three to four times a day and lasted 15 to 30 minutes. Diagnosis was atherosclerotic cardiosclerosis.

On 20 December 1958, the internal mammary arteries were ligated. After operation the anginal attacks disappeared and did not recur at any later time.

The ECG prior to operation (Fig.2,a) showed clear signs of chronic coronary insufficiency. Two months after operation the ECG had reverted to normal (Fig. 2,b.).

These examples show that sometimes the ECG indices improve somewhat; with this, there is disappearance of the changes of chronic coronary insufficiency which were pronounced prior to operation.

However, such good long-term results were not always forthcoming.

According to our observations, in eight percent of patients the long-term results were better than the immediate results, which may be due to the gradually increased collateral circulation of the myocardium due to ligation of the internal mammary arteries.

In general, however, the long-term results were less satisfactory than the immediate ones. The findings are shown in the table,

Table

Comparison of Immediate and Long-Term Results
in Patients with Angina Pectoris Treated
by Bilateral Internal Mammary Ar-
tery Ligation

| 1) Результат лечения | 2) Ближай- ший результат | 3) Отдален- ный результат |
|--|--------------------------------|---------------------------------|
| | 4) количество больных | |
| 5) Исчезновение приступов стенокардии | 56 | 42 |
| 6) Уменьшение частоты приступов стенокардии и ослабление их силы | 43 | 49 |
| 7) Течение заболевания не изменилось | 11 | 20 |
| 8) Всего . . . | 110 | 110 |

KEY:

- 1) results of treatment
- 2) immediate results
- 3) long-term results
- 4) number of patients
- 5) disappearance of anginal attacks
- 6) reduction in frequency of attacks and diminution in their severity
- 7) course of the disease unchanged
- 8) total.

In some patients, deterioration of the long-term results as compared with the immediate ones was due to the fact that, once relieved of the pains or sensations, these patients began to relax their observance of the regimen and to walk and work too much. Under these conditions the functional stress on the heart increased to a greater degree than could be compensated for by the increased blood supply. However, the very fact of disappearance of angina in 33 percent of the patients (42 of 110) at dates long after operation is highly significant. In another even larger group of patients (44 percent), improvement could be verified.

Of 180 operated patients (including the group of 110 patients analyzed in this article), no one died as the result of the operation. Five patients died from their underlying disease several months after surgery. Three of them died of myocardial infarction after four to eight months, one of pneumonia, against a background of severe decompensation, and one of increasing circulatory failure.

Apparently, ligation of the internal mammary arteries does not eliminate the possibility of development of myocardial infarction, as it does not reverse the sclerosis of the coronary vessels. Operation facilitates only the opening up and improvement of natural paths of blood supply to the myocardium. Artificial closure of the lumens of the internal mammary arteries only contributes somewhat to the blood supply to the cardiac musculature, but it does not replace any of the coronary circulation which still constitutes the basic source of nutrition to the heart.

Nonetheless the operation of ligating the internal mammary arteries is physiologically sound. In addition to not traumatizing the pericardium or the heart, it creates no mechanical impedance to cardiac activity, which is the disadvantage of other operative methods which are used to improve revascularization of the myocardium. Ligation of the internal mammary arteries is only slightly traumatic and is safe; the results are better than the results of other widely-used but dangerous operations which are of doubtful physiologic soundness.

Recently, in patients in whom, following bilateral internal mammary artery ligation, there was no relief from the anginal attacks, we have begun to ligate the pericardiophrenic artery as well.

Patient O., 59 years old, and an invalid of group II. This patient had suffered angina pectoris for nine years. Recently severe attacks of angina had occurred daily. The ECG showed changes characteristic of chronic coronary insufficiency.

On 16 December 1958, we carried out bilateral internal mammary artery ligation. Attacks of angina became less frequent but did not disappear. ECG remained unchanged.

On 5 October 1959, under intratracheal anesthesia, we performed a left thoracotomy. The pericardiophrenic artery was isolated and transected. Postoperative course was smooth. During the two-month period after operation there were no further attacks of angina. Observations are being continued.

It should be stated that this operation, in conjunction with

previous ligation of the internal mammary arteries, leads to an increase in the blood supply of the myocardium and, in these instances, may be used in the treatment of angina pectoris.

Conclusions

(1) Bilateral ligation of the internal mammary arteries is a physiologically justified operation based on an increase in the natural collateral circulation of the myocardium.

(2) In a considerable number of operated patients, bilateral internal mammary artery ligation causes a diminution in the attacks of angina pectoris or even complete disappearance of them, both in the immediate postoperative period and at dates long after operation.

(3) In approximately one-third of operated patients, there is improvement in the ECG indices, expressed as a reduction in the changes characteristic of myocardial ischemia.

(4) Bilateral ligation of the internal mammary arteries is only slightly traumatic and is a safe procedure. Because of this it has indisputable advantages over a number of other operations proposed for the treatment of angina.

(5) Bilateral internal mammary artery ligation is effective only in some operated patients. The operation is of value in cases in which an increase in the collateral circulation is capable of augmenting to some degree the coronary circulation, which is the basic source of nutrition of the cardiac musculature.

(6) Study is merited by an operation, proposed by us, of ligation of the pericardiophrenic artery following ligation of

the internal mammary arteries in cases in which attacks of angina pectoris continue beyond the first operation.

Bibliography

Busalov, A.A., Koladyuk, I.V., Kuratova, Kh.N., "Grudnaya Khir."

[Thoracic Surgery], 1959, No.5, 3

Kolesov, V.I., "Works of the First Congress of Surgeons of the USSR", Leningrad, 1959, 536

Kolesov, V.I., Vishnevskaya, Ya.N., Drevina, A.I., and others,

"Vestn. Khir." [Herald of Surgery], 1959, Vol.82, No.4, 53

Osipov, B.K., "Khirurgiya" [Surgery], 1959, No.10, 8

Petrovskiy, B.V., "Khirurgiya", 1959, No.10, 3

Petrovskiy, B.V., Nersesyan, A.A., Rybkin, I.N., "Klin. Med."

[Clinical Medicine], 1959, No.11, 52

—Battezzati M., Tagliafero A., Cattaneo A., Sc. med. Ital., 1959, v. 7, p. 49. — Idem, J. Internat. College Surgeons, 1958, v. 30, p. 501. — Glover R. P., Davila J. C. a. oth., J. Thoracic Surg., 1957, v. 34, p. 661.

FOR REASONS OF SPEED AND ECONOMY
THIS REPORT HAS BEEN REPRODUCED
ELECTRONICALLY DIRECTLY FROM OUR
CONTRACTOR'S TYPESCRIPT

THIS PUBLICATION WAS PREPARED UNDER CONTRACT TO THE
UNITED STATES JOINT PUBLICATIONS RESEARCH SERVICE
A FEDERAL GOVERNMENT ORGANIZATION ESTABLISHED
TO SERVICE THE TRANSLATION AND RESEARCH NEEDS
OF THE VARIOUS GOVERNMENT DEPARTMENTS