

BR

5606

RECORD
COPY

OTS: 60-41,408

JPRS: 5606

21 September 1960

MAIN FILE

CHANGES IN THE BRAIN STEM IN VIII NERVE NEURINOMAS

By S. M. Blinkov


- U S S R -

REMOVED TO MAIN FILE

20000621 060

Distributed by:

OFFICE OF TECHNICAL SERVICES
U. S. DEPARTMENT OF COMMERCE
WASHINGTON 25, D. C.



U. S. JOINT PUBLICATIONS RESEARCH SERVICE
205 EAST 42nd STREET, SUITE 300
NEW YORK 17, N. Y.

DISTRIBUTION STATEMENT A
Approved for Public Release
Distribution Unlimited

Reproduced From
Best Available Copy

JPRS: 5606
CSO: 4572-N

CHANGES IN THE BRAIN STEM IN VIII NERVE NEURINOMAS

[Following is the translation of an article by S. M. Blinkov entitled Izmeneniya v Stvole Mozga pri Nevrinome VIII Nerva (English version above), in Voprosy Neyrokhirurgii (Problems of Neurosurgery), Vol. XXIV. No.3, Moscow, 1960, pages 44-48.]

In the brain an extracerebral tumor apparently causes gross disturbances in the structure and function of the brain not so much as a result of direct pressure as by the disturbance in its blood supply (Scherer, Noetzel, 1951). Here, disturbances in the cerebral blood supply specifically may occur as the result of a disappearance of the arterial system of the pia mater under the tumor and the formation of common sources of blood supply for the brain and the tumor (S. M. Blinkov, 1955; A. S. Arutyunova, 1959). In the spinal cord, on the other hand, as the experiments of Tarlov have shown (1957), mechanical pressure itself, without any disturbance in the blood supply of the spinal cord, can cause a disturbance in function, specifically a compression paralysis.

In the cerebellum, in case of its compression by an VIII nerve tumor a dystrophic process develops as a result of a disturbance in the circulation and of the interstitial spinal fluid circulation (P. V. Yanchenko, 1947).

In the case of an VIII nerve neurinoma the brain stem under-

goes a gross compression and displacement (B. G. Yegorov, 1949). Here, changes in the microscopic structures occur as the result of mechanical pressure and, secondarily, as the result of a disturbance in blood supply (Nishikawa, 1923, and others). Up to the present time, both factors, acting on the brain stem in the case of an VIII nerve neurinoma (pressure and disturbance in blood supply) are not differentiated. It is not known which changes in the brain stem and which clinical symptoms depend on the effect of each of these factors separately. The brain stem structures which are compressed and displaced by the VIII nerve neurinoma are more or less known, but it is not clear how these displacements are revealed clinically, how the disturbances in blood supply influence the brain stem, and how and which changes in the brain stem lead to a fatal outcome. For the purpose of throwing light on these problems we are taking advantage of the results of a clinical-anatomical examination of three cases of VIII nerve neurinoma in which the entire brain stem was studied from continuous serial microscopic sections stained with thionine by the Spielmeyer method, with hematoxylin-eosin and hematoxylin-pyrofuchsin.

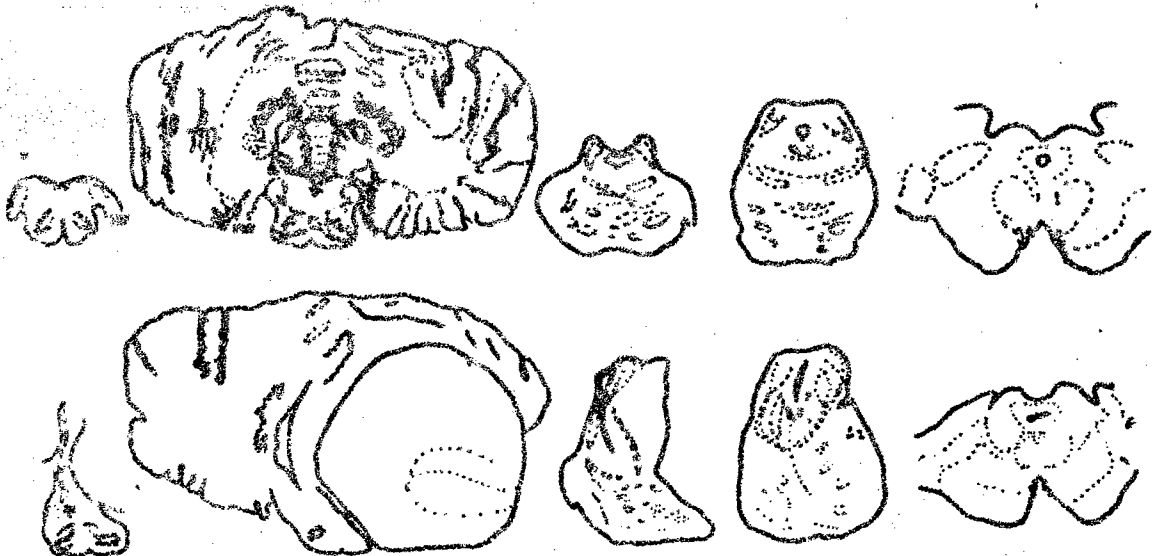
Observation 1. Patient V., age 27. Neurinoma of the right auditory nerve which had developed over the course of many years. Twenty-four hours after the operation of tumor removal breathing stopped. She was on artificial respiration for seven and a half days.

Observation 2. Patient M., age 38. Neurinoma of the left

auditory nerve. The disease had lasted more than three years.

An operation for tumor removal had been performed twice. Toward the evening after the second operation his condition became worse. Over the course of twenty-four hours his breathing stopped several times. He was on artificial respiration for two hours.

Observation 3. Patient M., age 38. Neurinoma of the right auditory nerve. The disease had lasted 12 years. Two weeks after the operation ^{of} partial removal of the tumor bulbar symptoms increased; after another two days respiratory disturbances appeared which after two days led to a fatal outcome (see Figure).



Compression and Displacement of the Brain Stem Structures in VIII Nerve Neurinoma. Above, Schematic Representation of Sections through the Medulla, Pons and Mid-Brain Normally. Below, the Same in Observation 3.

In all three observations, as a result of many years of tumor growth, which reached no less than four centimeters in diameter, a slowly progressive destruction occurred of the homolateral cerebellar hemisphere, of the lower inferior and middle cerebellar peduncles [the corpus restiforme and the brachium pontis, respectively] with dilatation of the blood vessels, stasis, cyst-formation, cortical atrophy and degeneration of the myelin fibers. (It should be noted that in all three observations the operation of partial tumor removal was performed without cerebellar resection). At the same time, compression occurred of the roots of the cranial nerves and compression of the brain stem, which in all three cases had similar features, namely, a predominant deformation of structures located on the floor of the fourth ventricle and around the aqueduct of Sylvius.

In all three observations acute disorders in the blood supply of the brainstem, which led to a disturbance of respiration and the death of the patients in periods from one day to two weeks after the operation, were superimposed on the slowly progressive changes produced by the pressure of the tumor.

On the side of the tumor and corresponding to the injury in the cerebellar hemisphere and peduncle, gradually increasing homolateral disorders of coordination were observed in the extremities as well as muscular hypotension in all patients. Disturbances in statics and in the gait

were less pronounced than the disorders of coordination of movement in the extremities.

The involvement of the cerebellar hemisphere and its inferior and middle peduncles, in which the tumor formed a deep bed, had the nature of a chronic process and led to the disappearance of ganglion cells of the cerebellar cortex as well as of the dentate nuclei, with proliferation of the glial cells as well ^{as} to a retrograde degeneration of cells of the inferior olive on the side opposite to the tumor.

The compression and degeneration of roots of cranial nerves was associated with a retrograde degeneration of cells of the motor nuclei. This process led to slowly increasing losses in functions of the V, VII, VIII and X cranial nerves on the side of the tumor. In observations 1 and 2, in addition, a disturbance occurred in the function of the IX nerve, and in observation 3, a disturbance in the function of the XII nerve on the side of the tumor.

On microscopic examination the vascular changes (marked dilatation of the arteries and veins) which had been seen between the tumor and the cerebellum were not found in any of the observations between the tumor and the brain stem. Retrograde degeneration was pronounced only in part of the cells the motor nuclei of the V, VII and X cranial nerves. In the area of the vestibular nuclei and the dorsal nucleus of the cochlear nerve the deformation was so gross, that these structures could be separated

roust with difficulty. The cells of the dorsal nucleus of the cochlear nerve were deformed, shrivelled and pycnotic; nevertheless, in the cells of the anterior nucleus of the cochlear nerve after thionine staining distinct abnormalities could not be found.

The chronic changes in the blood vessels were insignificant; the endothelium was unchanged; slight thickenings were seen in the adventitia which were stained a bright pink color with the proliferation of fibrils in the direction toward the brain tissue. In many cases, the ganglion cells of grossly displaced nuclei were unchanged; the tigroid was seen distinctly in them, and the nucleus and the nucleolus were no different from normal. Gross deformity of the long conducting systems was practically not found clinically. Thus, sensory disorders were observed only in one case (observation 1, in which there was a disorder of pain sensation in the hand).

Here, sensation was decreased on the side of the tumor, that is, the lemniscus was found to be less ^{deformed} on the side opposite to the tumor than the lemniscus on the side of the tumor.

In cases of VIII nerve tumors not uncommonly a homolateral, slight pyramidal tract symptomatology is observed (Henschen, 1910; V. M. Slonimskaya, 1936; I. S. Babshin, 1954, and others). A. D. Dinaburg and A. K. Shinkarenko (1957) explained this by the massive displacement of ^{the} brain stem and its compression against the opposite pyramid of the temporal bone. The authors believed that in the presence of homolateral pyramidal tract disorders a porosity of the temporal bone ^{petrous} pyramids is seen on X-ray films.

on the side opposite to the tumor, and when these disorders are absent the opposite pyramid is unchanged.

In observations 1 and 3 the homolateral pyramidal-tract disorders were expressed quite distinctly, and in observation 2 bilateral pyramidal tract signs could be produced regularly in the presence of an equality in the tendon and abdominal reflexes on both sides. However, there was no porosity of the temporal bone pyramids on the side opposite to the tumor in our observations.

A quadrigeminal syndrome in the form of paresis of upward gaze was found in all three observations before and after operation and was combined with a lively reaction of the pupils and multiple nystagmus, vertical on upward gaze and horizontal on looking to the sides.

In all three observations a compression occurred of the tegmen of the mid-brain. The displacement in the area of the inferior colliculi was more pronounced than in the area of the superior colliculi. The deformity of the quadrigeminal lamina was indistinct and might have passed unnoticed if there had not been a marked change in the shape of the aqueduct of Sylvius, which had been converted into a slit. On microscopic examination no disturbances in the architectonics were found in the inferior or superior colliculi. An abundance of satellite cells was noted, but they are also characteristic of the corpora quadrigemina normally (Olszewski and Baxter, 1954). No distinct changes occurred in the nerve cells, particularly in the large cells of the superior colliculi.

Therefore, our observations confirm the possibility of occurrence of paresis of upward gaze in the presence of an intact pupillary

reaction, as a result of simple pressure on the quadrigeminal lamina, without any gross disturbances in its cytoarchitectonics.

Gross disorders of vital functions which developed at various periods of time after the operation evidently were connected with acute disturbances in the blood supply of the brain stem.

The question of the causes of a disturbance in the blood supply of the brain stem in brain tumors, particularly in VIII nerve neurinomas may still be considered unsolved. Fulminant edema with increase in the blood pressure, dilatation and rupture of the cerebral vessels may occur from stimulation of the infundibulum of the hypophysis, medulla in the area of the vagus nerve nucleus, in the case of tumors in the area of the auditory nerve (N. N. Burdenko, L. A. Koreysha, 1959; E. I. Kandell' and L. O. Korst, 1959, and others).

The possibility of hemorrhages as a result of reflex influences produced by the high-powered stimulus cannot be eliminated in our observations, since therein the relationship of hemorrhages to operative trauma, the multifocal nature of the diapedetic hemorrhages are shown distinctly, while in observation 2 a hemorrhage occurred simultaneously into the ventricle.

In observation 1 a gross disorder of respiration, which occurred immediately after the operation, was associated with a loss of consciousness, the occurrence of anisocoria, hyperthermia, tonic extensor convulsions, and at times rapid clonic vertical twitchings of the eyeballs. On the sixth day there was the beginning of recovery of spontaneous

rhythmical respiration; however, a fatal outcome occurred as a result of the development of meningoencephalitis. Therefore, in this observation diffuse disorders of the brain stem functions occurred, beginning with the inter-brain and ending with the level where the pons changes into the medulla. Fresh hemorrhages were localized chiefly to the area of the right pneumotaxic center and the dorsomedial portion of the reticular formation of the medulla on both sides, as microscopic examinations showed. A very gross deformity of the brain stem did not prevent the recovery of spontaneous respiration on the sixth day, which had been ~~dis-~~impaired as a result of acute disturbances in the circulation of the brain stem. In observation 2 disorders of respiration suddenly appeared ~~wh~~ with subsequent stoppage of it. After two hours, during which artificial respiration was given, cardiac activity stopped. In this observation, in the revision of the wound, which was performed as soon as the patient's condition deteriorated, bleeding was found from small and large tumor vessels. It should be noted that, apart from the penetration of blood into the aqueduct of Sylvius and the third ventricle, as microscopic examinations showed, small hemorrhages occurred in the area of the pneumotaxic center, as well as in the nuclei located under the floor of the fourth ventricle.

In observation 3 the disturbance of respiration occurred only two weeks after the operation of removing the tumor, apparently in connection with late disorders in the circulation (at autopsy there was a hemorrhagic softening in the area of the operation). The use of pentamine

[a ganglion-blocking agent] during the operation possibly postponed the occurrence of vascular disorders. A gross dilatation of the blood vessels with petechial hemorrhages and small necrotic foci in the grey matter of the aqueduct of Sylvius and in the area of the pneumotaxic center was associated with fresh degenerations in the mesencephalic root of the trigeminal nerve.

Conclusions

1. A slowly progressive VIII nerve neurinoma produces a compression and destruction of the cerebellar hemispheres and peduncles, compression of the roots and a retrograde degeneration of the cells of the cranial nerve nuclei.

2. Very gross deformities of the brain stem, respectively, of the medial and lateral lemniscus, pyramidal tract, the nuclei of the reticular formation, etc. do not in themselves produce any disturbances in the functions of the brain stem structures or disturb them to an insignificant degree.

3. Severe disturbances in the function of the brain-stem structures in cases of tumor of the VIII nerve occur as the result of acute vascular disorders (multiple macroscopic and microscopic hemorrhages). These hemorrhages possibly occur reflexly.

4. In cases of severe disorders of respiration gross vascular disturbances are observed in the vicinity of the central grey matter of the aqueduct of Sylvius (in the area of the pneumotaxic center) along with a disorder of blood supply in the nuclei of the floor of the fourth

ventricle, particularly the vagus nuclei and the solitary tract.

Bibliography

1. Arutyunova A. S. In The Book: "Problems of Modern Neurosurgery".
Moscow, 1959, Vol. 3, page 363.
2. Blinkov S. M. Vopr neyrokhir. Problems of Neurosurgery, 1955,
No. 3, page 20.
3. Burdenko N. N. Collection of Works. Moscow, 1950.
4. Dinaburg A. D., Shinkarenko A. K. Zhurn. nevropatol. i psikiatr.
Journal of Neuropathology and Psychiatry, 1957, Vol. 57, No. 4,
page 488.
5. Yegorov E. G. Neurinoma of the VIII Nerve. Moscow, 1949.
6. Kandel' E. I., Korst L. O. In The Book: "Circulatory Disturbances in
Cases of Cerebral Lesions". Moscow, 1956, page 114.
7. Koreyska L. A. opus cit., page 95.
8. Slonimskaya V. M. In The Book: "Brain Tumors and Problems of Neuro-
surgery". Rostov-na-Donu, 1936, No. 3, page 49.
9. Yanchenko P. V. Secondary Changes of the Cerebellum Produced by
VIII Nerve Tumors and Operations on Them. Candidate's
dissertation. Moscow, 1947. In the Book: Scientific Works
During the 25 Years of the Institute of Neurosurgery imeni
N. N. Burdenko. Moscow, 1954, page 155.
10. Henschen F. Über die Geschwülste der hinteren Schädelgrube. Jena,
1910.
11. Nishikawa Y. Arb. neurol. Inst. Wien, 1922, Vol. 24, page 15.

12. Noetzel H. Beitr. path. Anat. u. allg. Path., 1951, Vol. 111,
page 391.
13. Olszewski J., Baxter D. Cytoarchitecture of the Human Brain Stem.
Basel. 1954.
- 14. Scherer H. Rev. neurol., 1936, Vol. 66, page 307.
15. Tarlov I. M. Spinal Cord Compression, Mechanism of Paralysis and
Treatment. Springfield, 1957.

Received 13 February 1960

FOR REASONS OF SPEED AND ECONOMY
THIS REPORT HAS BEEN REPRODUCED
ELECTRONICALLY DIRECTLY FROM OUR
CONTRACTOR'S TYPESCRIPT

THIS PUBLICATION WAS PREPARED UNDER CONTRACT TO THE
UNITED STATES JOINT PUBLICATIONS RESEARCH SERVICE
A FEDERAL GOVERNMENT ORGANIZATION ESTABLISHED
TO SERVICE THE TRANSLATION AND RESEARCH NEEDS
OF THE VARIOUS GOVERNMENT DEPARTMENTS